

Seasonal variation of the incidence of rhegmatogenous retinal detachment in Split-Dalmatia county and its management from 2005 to 2020

Vučemilović, Pia Antonia Franciska

Master's thesis / Diplomski rad

2022

Degree Grantor / Ustanova koja je dodijelila akademski / stručni stupanj: **University of Split, School of Medicine / Sveučilište u Splitu, Medicinski fakultet**

Permanent link / Trajna poveznica: <https://um.nsk.hr/um:nbn:hr:171:309208>

Rights / Prava: [In copyright](#)/[Zaštićeno autorskim pravom.](#)

Download date / Datum preuzimanja: **2024-07-23**



Repository / Repozitorij:

[MEFST Repository](#)



**UNIVERSITY OF SPLIT
SCHOOL OF MEDICINE**

Pia-Antonia Vučemilović

**SEASONAL VARIATION OF THE INCIDENCE OF RHEGMATOGENOUS RETINAL
DETACHMENT IN SPLIT-DALMATIA COUNTY AND ITS MANAGEMENT FROM
2005 TO 2020**

Diploma thesis

Academic year:

2021/2022

Mentor:

Assoc. Prof. Ljubo Znaor, MD, PhD

Split, September 2022

UNIVERSITY OF SPLIT

SCHOOL OF MEDICINE

Pia-Antonia Vučemilović

**SEASONAL VARIATION OF THE INCIDENCE OF RHEGMATOGENOUS RETINAL
DETACHMENT IN SPLIT-DALMATIA COUNTY AND ITS MANAGEMENT FROM
2005 TO 2020**

Diploma thesis

Academic year:

2021/2022

Mentor:

Assoc. Prof. Ljubo Znaor, MD, PhD

Split, September 2022

TABLE OF CONTENTS

1. INTRODUCTION.....	1
1.1. Anatomy of the eye.....	2
1.2. Histology and Physiology of the retina.....	2
1.2.1 Rods and Cones.....	5
1.2.2 Retinal Pigment Epithelium and Sub-retinal Space	6
1.3. Retinal Detachment.....	7
1.3.1. Pathogenesis of Retinal Detachment.....	8
1.3.2. Vitreous humor and Posterior Vitreous Detachment.....	9
1.4. Statistics Associated with RD.....	11
1.4.1. Incidence/ Prevaence.....	11
1.4.2. Risk Factors.....	11
1.5. Symptoms and Diagnostics.....	12
1.5.1. Symptoms.....	12
1.5.2. Diagnosis.....	13
1.6. Management and Prognosis.....	14
1.6.1. Management.....	14
1.6.1.1. Scleral Buckling.....	15
1.6.1.2. Vitrectomy.....	15
1.6.1.3. Pneumatic Retinopexy.....	16
1.6.2. Prognosis.....	16
2. OBJECTIVES OF RESEARCH.....	18
3. MATERIAL AND METHODS.....	20
3.1. Patients and place of study.....	21
3.2. Organization of the study.....	21
4. RESULTS.....	22
5. DISCUSSION.....	26
6. CONCLUSION.....	29
7. REFERENCES.....	31
8. SUMMARY	34
9. CROATIAN SUMMARY.....	36
10. CURRICULUM VITAE	38

Abbreviations

IPL- Inner Plexiform Layer

IPM- Interphotoreceptor Matrix

OPL- Outer Plexiform Layer

PVD- Posterior Vitreous Detachment

PVR- Proliferative Vitreoretinopathy

RD- Retinal Detachment

RPE- Retinal Pigment Epithelium

RRD- Rhegmatogenous RD

ACKNOWLEDGEMENT

First and foremost, I love to be able to thank God for using these past six years to show me to fully trust in him.

I would like to share my appreciation to my mentor, Assoc. Prof. Ljubo Znaor. Thank you for your kindness while guiding me through this thesis.

Thank you, Filip, for your guidance and friendship ever since histology.

To my parents, tata and mama, thank you for giving me strength during the most difficult moments.

To my grandparents, Dida Matić and Baka Franciska, for going through every step with me.

Hvala što ste prošli kroz svaki korak sa mnom.

Thank you, Marta, for helping a sister out, you know for what.

My dear friend, Ana, thank you for the first two years...

Last, but not at all least, my friends that bring me such joy, the RS. Thank you for making memories with me.

1. INTRODUCTION

1.1. Anatomy of the eye

When observing the gross anatomy of the eyeball, it can be distinguished into three separate layers. The first, the external layer, is made up of the sclera and the cornea. The cornea is the transparent covering that protects the pupil and the iris, and it is an incredibly powerful and important lens for the refraction of light. The sclera is the white of the eye, the structure that gives the eye its form. Anteriorly it continues into the cornea, while posteriorly it continues as the dura of the nervous system. The second layer, the intermediate of the eye is the iris and ciliary body anterior, and posteriorly the choroid. Light entry is through the pupil, the black opening in the middle of the colored iris, which contracts or dilates the pupil depending on the ambient light. A lens lies posteriorly to the iris, which, by the contraction and relaxation of the ligaments (zonule fibers), changes shape to accommodate light so that the image on the retina is sharp. Finally, the internal layer is the part of the eye that performs the function of sensing light, the layer of the retina. There are three areas where fluid is accumulated, the anterior chamber is between the cornea and the iris, the posterior chamber is between the iris and the lens, and the vitreous chamber is the viscous fluid found between the lens and the retina (1).

The cornea, iris, ciliary body, and the lens are the components of the eye that are used to focus the light for it to properly dispersed onto the sensory portion of the eye, the retina. The other structures, such as the choroid, the aqueous and vitreous humor, and even the lacrimal system has the purpose to maintain the physiology of the eye in balance and the keep the tissues well nourished (2).

1.2. Histology and Physiology of the Retina

The retina is the sensory layer of the eye that lines the inner part of the posterior two-thirds of the eye. Anteriorly to the retina lies the vitreous chamber, and posteriorly lies the choroid. The purpose of the retina is to convert absorbed photons into electric impulses, which will propagate into the brain through the optic nerve (3).

Amongst all the tissues found in the whole human body, the retina has the highest cell density (4). Indeed, when observed histologically, it is apparent that the retina is a complex sheet of multiple cell layers. In fact, there are nine layers within the sensory retina, which finally rest upon the final layer of the retina, the retinal pigment epithelium. When observing from the outer most portion (closer to the choroid) towards the inner most portion of the retina (closer to the

vitreal body), one can observe the following nine layers: 1) the photosensitive part of the photoreceptors (rods and cones); 2) the external limiting membrane; 3) the outer nuclear layer; 4) the outer plexiform layer; 5) the inner nuclear layer; 6) the inner plexiform layer; 7) the ganglion cell layer; 8) the nerve fiber layer; 9) the internal limiting membrane (3). Overall, there are three neural cells that propagate the stimulus from light and two locations of synapses (5).

The photoreceptors (the first of the neural cells to collect photons) span the first four aforementioned layers. The outer most segment is where the rods and cones are photosensitive, where light photons are absorbed and transformed for further propagation. The outer nuclear layer is comprised of the cell bodies of these photoreceptors, and the external limiting membrane separates the two segments. The first synaptic area is the outer plexiform layer where the rods and the cones synapse with the bipolar cells to further propagate the visual impulse. In addition, at this outer plexiform layer (OPL), there are other cells placed perpendicular to the vertically oriented photoreceptors (5). These are called horizontal cells and are supportive cells, whose function is to provide inhibitory stimulus to the photoreceptors and the bipolar cells (2).

The inner nuclear layer contains the body of the bipolar cells. These bipolar cells are the second neurons of the retina, whose dendrites synapse with the photoreceptors (the OPL) and whose axons synapse with the third, and final, order neurons, the ganglion cells (5). There are different types of bipolar cells, which connect varying amounts of cones or rods with single or multiple ganglion cells. For example, diffuse-cone bipolar cells are quite wide, and can connect to 15-20 cones. In contrast, midget bipolar cells connect with only a single cone (6). The layer in which the bipolar cells form a synapse with the ganglion cells is the inner plexiform layer (IPL). The IPL also contains amacrine cells which, like horizontal cells, do not take part in the transmission of the visual stimuli, but play a supportive role (5). These amacrine cells can form synapses with the dendrites of ganglion cells, the axons of the bipolar cells, or they can simply synapse with other amacrine cells. Most of the amacrine cells are also inhibitory in nature to prevent the over stimulation of ganglion cells (7).

As mentioned, the ganglion cells are the final neuron which receive the electrical stimulus created from the photon first absorbed by the photoreceptors. This photon crossed all the layers of the retina to first stimulate the photoreceptors, the outermost neurons, which then passed the information to the bipolar cells, and then finally to the ganglion cells. Each ganglion cell has one, very long, nonmyelinated axon, which, bundled together, they extend out from the ganglion cell layer

to form the nerve fiber layer of the retina, and eventually the optic nerve (9). An illustration of the layers of the retina is depicted in Figure 1.

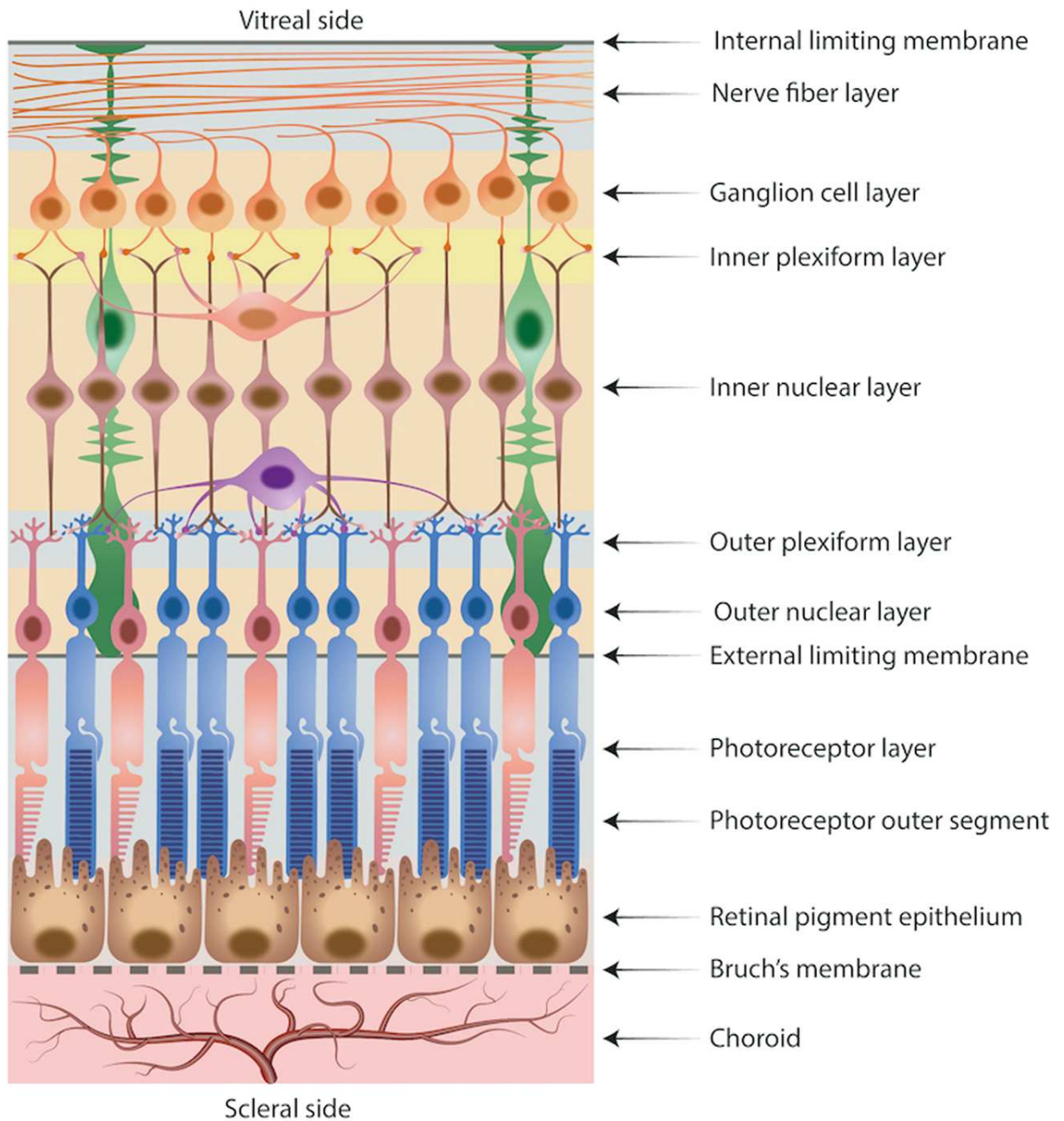


Figure 1. An illustration depicting the multiple layers found within the retina

Source: Ferrara M, Lugano G, Sandinha MT, Kearns VR, Geraghty B, Steel DHW. Biomechanical properties of retina and choroid: a comprehensive review of techniques and translational relevance. *Eye (Lond)*. 2021;35:1818-32.

1.2.1. Rods and Cones

As mentioned, photoreceptors are the cells that have the capability to absorb photons. There are two types of photoreceptors, called rods and cones, and they are distinguishable by their function. The rods are useful for vision when there is little ambient light, called scopic vision. Therefore, they have higher amounts of photopigment and sensitivity. In contrast, the cones require more light to be stimulated, but are key in processing color and spatial acuity (2). Rods are useful for viewing contrast, motion and objects viewed in the dark. Cones are useful for viewing objects in bright areas and with fine resolution (8). The reason cones are able to process light with greater visual acuity than rods is that they form individual connections with the optic nerve. This allows for a better distinction between the signals (2). There are more rods in the retina, with around 110 million to 125 million. There are around 6 million cones in total (9). However, the cones are located most densely in the area of the eye called the fovea, which is the location of the eye where visual acuity is the highest. In addition, there exists a blind spot of the retina where both kinds of photoreceptors are absent, this is the site of the optic nerve (2).

Although the visual cycle of the absorption of photons and its transformation into electrical information is beyond the scope of this paper, we will touch upon a few important facts in relation to this process. The most distal portion of the rods and the cones, also known as the outer segment, contains pigments that absorb the light, and have photo-transduction proteins that amplify the photon energy (which will eventually be converted into an electrical impulse) (8). The pigment in the cones is called photopsin, while the pigment from the rods is called rhodopsin. Rods have only one pigment, while cones have three types of pigment. These three types of cones are named by the wavelength of color to which they are most sensitive. However, each can sense a range of wavelengths and therefore are sensitive to a range of colors, not just one. The cones are categorized as S-cones (short wavelength), M-cones (medium wavelength), and L-cones (long wavelength). The photopsin and rhodopsin is composed of a protein (opsin) covalently bound with retinal. When the retina is in its inactive form, it remains the 11-*cis*-retinal conformation. This form of retinal is a Vitamin A derivative, which is why this vitamin is known for aid in proper vision. When it reaches the outer segment of the photoreceptors and the retinal found within their membranes, it changes shape (isomerizes) into the form all-*trans*-retinal. This transformation leads to a cascade of events that leads to transduction, the transmission of light into electrical signals into the

brain. During this process, photoreceptors become saturated and decrease their sensitivity to further stimuli. Rods are more easily saturated than cones, therefore quickly lose their sensitivity (2). In order for the pigments to regain their sensitivity to further stimuli, the retinal must change its conformation once more to 11-*cis*-retinal (10).

1.2.2. Retinal Pigment Epithelium and Sub-Retinal Space

In a general sense, the retina can be categorized as having two main layers: the neuro-sensory retina (the layers of the retina up to the photoreceptors) and the retinal pigment epithelium (RPE). The RPE is a single layer of epithelial cells that mark the outer most layer of the retina. It is the most outer segments of the rods and the cones (the light sensitive portions) that maintain close contact with the RPE (11).

The two layers must interact in order for vision to occur properly, however, they are not firmly attached. Rather, there exists a “virtual” space between the neuro-sensory retina and the RPE called the sub-retinal space (4). However, attachment of the retina does occur at two specific locations. Anteriorly, it is firmly attached to the ora serrata, which is where the anterior extension of the RPE ends. Posteriorly, the optic nerve secures the retina to the globe of the eye. The retina is around 0.1 mm in thickness at the ora serrata, while at the posterior end near the optic nerve, it is 0.23 mm thick (3). However, overall, the retina is roughly 0.5 mm in thickness (5).

The RPE forms a tough junction with the next layer of the eye, the choroid, and plays multiple roles in maintaining the health and function of the retina (4). Indeed, without the RPE, we could not have vision (11). Firstly, the pigment from these epithelial cells absorbs the scattered light which helps improve the optics of vision. In addition, this layer protects and renews the photoreceptors from photo-oxidative and free radical damage that is formed due to the high amounts of light energy saturating the retina. As a result of the visual cycle, the outer segments of the photoreceptors get damaged. They are then shed by the photoreceptors and then phagocytosed by the RPE (4). Around 10% of the photoreceptor’s outer segment must be shed and regenerated daily. The isomerized form of retinal, all-*trans*-retinal can lead to multiple toxic byproducts, which, if not properly phagocytosed by the RPE can cause retinal damage, including age-related macular degeneration (11). The RPE also resets, or re-isomerizes, the photoreceptors, which completes the visual cycles and prepares the rods and the cones for the next stimulation of photons. Specifically,

certain steps required for regeneration of 11-cis retinal from all-trans-retinal within the retinoid cycle takes place within the RPE (10). In addition, the RPE provides nourishment and protection to the retina by creating a so-called blood-retinal barrier, that keeps the retina separate from the vascular choroid. In fact, the choroid is so vascularized, that it has more blood perfusion than the kidney. As for nourishment, the photoreceptors are cells which have a high demand of metabolic energy and require glucose for energy, retinal for the cycle of photon accumulation and transmission, and ω -3 fatty acids for their phospholipid membranes. Each of these metabolites is transported to the photoreceptors by the RPE. Finally, this single layer of cells modulates the immune system of the eye. It is not only able to activate the immune system by secreting cytokines such as IL-8 and monocyte chemoattractant protein-1, but it is also able to suppress the immune system when required (4).

The RPE also maintains the sub-retinal space in homeostasis. This single layer of epithelial tissue has a very efficient transport system in order to control the level of ions, water, and the products remaining after metabolite use in this extracellular matrix. Water is driven into this space at high rates as a result of the water that is a by-product of the nutrient absorption as well as a result to the intra-ocular pressure that is constantly directing the water flow from the anterior portion of the eye towards the retina. The RPE removes the water from the sub-retinal space via an active transport. Furthermore, high concentrations of lactic acid are also known to accumulate in the sub-retinal space as a result of the high rates of metabolic activity. The RPE removes these lactic acids, and in this way maintains a normal pH in this area (4).

1.3. Retinal Detachment

Retinal detachment (RD) is defined as the separation of the sensory retina from the retinal pigment epithelium. There are three types of RD: rhegmatogenous RD, tractional RD, and exudate RD (12).

The most common kind of detachment is rhegmatogenous RD (RRD), and it occurs due to a retinal break or tear that allows the fluid from the vitreous chamber to flow into the sub-retinal space (between the neuro-sensory retina and the RPE) (13). This association with retinal breaks or tears is noted in its name, for, in fact, the root “rhegma” is Greek for breach or fissure (14). A retinal break is a full-thickness hole found in the sensory retina. A retinal tear, however, is a break that occurs in the presence of a posterior vitreous detachment (PVD), which we will delve into in

a further section of the thesis. Retinal breaks can also be caused by eye trauma and inflammation. An example of RD as a result of blunt force trauma includes retinal dialysis, which is when the retina separates from its insertion point at the ora serrata. In addition, retinal necrosis as a result of trauma or inflammation can cause retinal tears. The focus of this paper will be more on rhegmatogenous RD than on the other two kinds of detachment (13). The second type of detachment is the tractional RD, which occurs without a retinal break, but as a result of scar (fibrous) tissue that pulls the retina, where, again, the vitreous fluid fills the sub-retinal space. Diabetic retinopathy is an example of a pathology which can cause this fibrous tissue to grow. Finally, the least common type of RD is the exudative RD, which occurs without any tears or any tractional force that pulls on the retina which then permits fluid in the sub-retinal space, but rather, it occurs as a result of the accumulation of fluid due to secretion into the sub-retinal space. Intra-ocular tumors or exudative vascular diseases are examples of pathologies that can cause this excessive secretion into the sub-retinal space, which, with the increasing pressure, eventually leads to the RD (12). In addition, one can also have asymptomatic and non-progressive chronic RD (13).

1.3.1. Pathogenesis of RD – What keeps the retina attached?

There are two physiological processes that keep the retina attached. The first is due to the RPE which constantly removes fluid from the sub-retinal space and into the vascular choroid. The second factor that aids in retinal attachment are the proteoglycans found in the interphotoreceptor matrix (IPM) (15). The IPM is the intercellular matrix that is found between the rods and the cones which also extends into the sub-retinal space. Chondroitin sulfate proteoglycan is critical in maintaining adhesion between the RPE and the sensory retina (16). A study performed by Lazarus *et al.* demonstrated the importance of this proteoglycan to retinal adhesion, for when they injected it into the vitreous chamber of the eye, an inhibitor to chondroitin sulfate proteoglycan, named xyloside, retinal detachment and cone photoreceptor degeneration was noted (17). It is important to note that many other processes related to vision occur within the IPM, including the transport of retinoids involved in the visual cycle, and of other nutrients, metabolites and oxygen (16).

However, the most common cause of rhegmatogenous RD is vitreous body degeneration, which can lead to posterior vitreous detachment (PVD). Between 80% to 90% of the retinal detachments occur as a result of a retinal break during a PVD (13). Therefore, it is important to review

the anatomy, physiology, and pathophysiology of the vitreous humor, and how it is implicated in the development of RD.

1.3.2. Vitreous Humor and Posterior Vitreous Detachment

A healthy vitreous fluid resembles a jelly-like constitution. Although 98% is water, the fluid is not free flowing. The other small percentage that makes up the vitreous fluid includes hyaluronic acid and collagen fibers. The vitreous “gel” contacts the retina but only in specific locations does it adhere to the retina. Adhesion occurs at the margins of the optic disc, the base of the vitreous chamber (anterior portion which is lined near the ora serrata), along the major retinal vessels, and at the macula (14,15). The strongest adhesion occurs at the vitreous base (14). At these locations, collagen fibrils extend from the fluid and into the layers of the retina in order to provide structural support (12). However, pathological adhesions can also occur. These can be a result of uveitis, trauma, proliferative disease observed in diabetics, and post-laser treatment for an example (15).

A young and healthy vitreous chamber fills the posterior space of the eye and contacts the entire length of the retina. However, with age, this naturally changes (14). With age or with other accompanying ocular diagnosis such as myopia, the content of hyaluronic acid decreases and the collagen fibers release the water it had bound. This is called vitreous liquefaction. Already in a 20-year-old, 20% of the vitreous humor is liquid rather than gel. By 90 years old over 50% is liquid. When hyaluronic acid does not separate the collagen fibers, they can aggregate which float around in the portion that is fluid which can be perceived by the patient (these are called floaters) (15). These changes also lead to a decrease in elasticity and shrinkage of the fibrils which causes progressive separation of the vitreous from the retina. This separation most commonly occurs at the macula. Eventually, the vitreous body begins to resemble a funnel shape, firmly attached most widely anteriorly (the vitreous base), and at the posterior end being held at the optic disc (another place of firm adhesion) An illustration of PVD and the funnel-like shape can be viewed in Figure 2 (14). However, the vitreous can also remain in contact at other points posteriorly, for the separation commonly extends at locations found between the posterior pole to the equator of the eye. The equator of the eye is where the retina transitions from the central to the peripheral retina, and is where the retina is the thinnest. In either case, now the vitreous is partly detached posteriorly. This partial PVD is what carries the risk towards the development of RD, for the remaining points of attachment are placed under tension. If there was a complete PVD, there would no longer exist any

tension upon the retina. The equator has a strong propensity for tension-related injuries due to its thinness (12).

Whenever the head, and especially the eyeball, moves, rapid acceleration and deceleration occurs within the vitreous humor gel. Every movement can now cause strain on the remaining point of vireo-retinal attachment. Therefore, the length of time and frequency of traction will increase the risk of a retinal tear, the following step in the pathophysiology of rhegmatogenous RD. However, there exist opposing factors to try to prevent the tearing and detachment of the retina. These forces include the strength of the retina itself, the glue strength of the IPM, and the ability of the RPE to drain out the leaked intravitreal fluid into the sub-retinal space. If the retinal strength, RPE, and IMP do not sufficiently oppose the tensile pressures from the detaching vitreous the retina can tear. If a PVD ends up causing a symptomatic retinal tear, one has a 90% chance that it will progress into a RD. If a small retinal detachment occurs, the pumping of the RPE can be enough to prevent the progression into a detachment, however, if the amount of fluid that gushes into the sub-retinal space ends up surpassing the capacity of the RPE, then RD will occur (15).

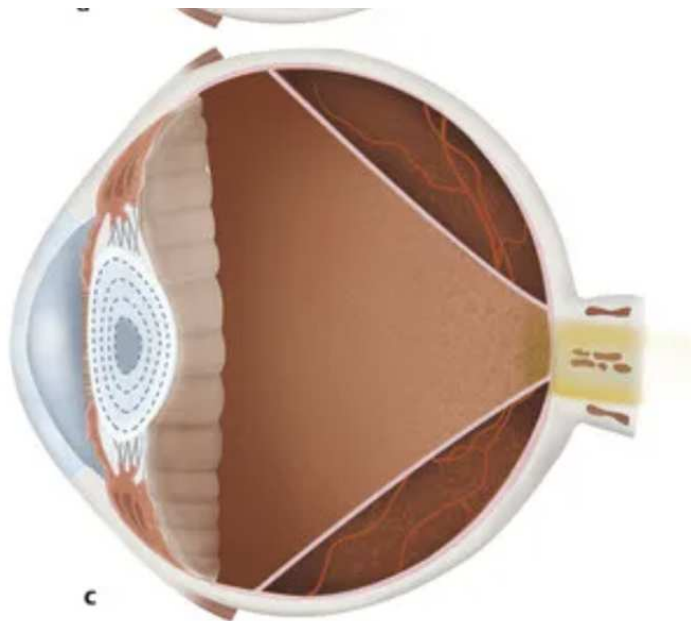


Figure 2. Illustration of a partial posterior vitreous detachment

Source: Schwartz SG, Flynn Jr. HW, Mieler WF, Tiedeman JS. Retinal Tears and Rhegmatogenous Retinal Detachments. Entokey: Fastest Otolaryngology & ophthalmology Insight Engine [Internet]. 2020. Available from: <https://entokey.com/29-retinal-tears-and-rhegmatogenous-retinal-detachments/>

1.4. Statistics Associated with RD

1.4.1. Incidence / Prevalence

Rhegmatogenous RD can occur within any age group, however, the peak prevalence is observed in people between 60-70 years old. It is interesting to note that naturally occurring PVD also increases in prevalence in the same age range. Men are more often affected than women. Evidence also suggests that white people are more affected than black people. Observational studies taken from the United States, Europe, and New Zealand demonstrate that Rhegmatogenous RD occurs at a frequency of 1/10,000 people per year (13).

1.4.2. Risk Factors

As seen in the aforementioned section, an incidence of PVD greatly increases the risk of rhegmatogenous RD. Once the vitreal fluid flows into the sub-retinal space in amounts that surpass the pumping capacity of the RPE, then it forces the separation of the retina from RP. In fact, around 80%-90% of RD occurs as a result of a previous PVD that caused a retinal break. PVD is naturally occurring, therefore age is a risk factor for the development of PVD and rhegmatogenous RD. In addition, it is important to note that already having RD in one eye increases the chances of having RD in the other, with the risk increasing with time. Within the first year of a RD, one has a 3.5%-5.8% risk of experiencing RD in the other eye, while within 4 years, the risk increases up to 10% (12). In addition, a positive family history of RD is another risk factor (13).

Other typical risk factors towards the development of rhegmatogenous RD are also closely linked with trauma in the vitreous chamber. These risk factors include myopia (shortsightedness), cataract surgery, and trauma to the eye (12).

A diopter of up to -3D increases the risk of RD 4 times compared to having perfect vision. If one has a diopter that is greater than -3, then the risk for RD increases 10 times. In certain study groups, 1 in every 2 patients with rhegmatogenous RD had myopia. This relation between myopia and RD is stemmed from the fact that myopia can cause early vitreous liquefaction. Cataract surgery, too, increases the risk of vitreous liquefaction. However, this risk is in association with even uncomplicated operations! Rhegmatogenous RD occurs in 1 in every 1000 uncomplicated cataract surgeries. Six years post-operation, the risk of detachment is increased 7 times, and the risk continues to increase as time moves on. A history of cataract surgery is present in 30% of the patients with RD. Blunt trauma to the eye, which causes a sudden jerking of the vitreous chamber can cause

tearing of the retina, especially near its base. It is alleviating to note that the risk of RD post ocular blunt trauma is low, around 0.2 patients in every 10,000 cases of trauma (12).

Finally, one important yet controversial risk factor is the intake of fluoroquinolones, more specifically, ciprofloxacin. Between 2000 and 2007, a cohort study collected data of just about 1 million people to assess the risk fluoroquinolone had on RD. The cohort results showed that 3.3% of all the RD that had occurred within those 8 years were from those who were on the medication. This is in comparison to the finding that the control group included only 0.6% of people on fluoroquinolone. The absolute increase in risk was 4 in 10,000 person-years, or better put, the number needed to harm was calculated to be 2500 people. For every 2,500 people who take fluoroquinolones, one may have an increased risk in developed RD. Research has not concluded that the risk of this medication outweighs the benefits, therefore physicians should simply bear this risk in mind and should share this information with their patients (18).

The risk factors for the development of tractional RD include pathologies that create proliferative membranes that will exude a tractional force upon the retina. Pathologies include proliferative diabetic retinopathy, proliferative vitreoretinopathy, sickle cell hemoglobinemia, trauma to the eye, retinal vein occlusion, and retinopathy of prematurity. The risk factor associated with the development of exudative RD includes pathologies that will increase the secretion of serous fluid into the sub-retinal space. These pathologies include primary ocular tumors or metastases, sarcoidosis, syphilis, toxoplasmosis, tuberculosis, corticosteroid therapy, pre-eclampsia and eclampsia, acute retinal necrosis, etc. (19).

1.5. Symptoms and Diagnosis

1.5.1. Symptoms

Most patients experience visual changes of effects before experiencing actual detachment. Such changes include new onset opacities, called floaters, which are threadlike or cobweb-like (12). Recall that these floaters are a sign of pathology of the vitreous humor, for they are aggregated collagen fibers that float in the fluid of the liquefacted vitreous (15). These floaters move as the gaze moves, and often the patient is unable to determine which eye is affected (12). Flashes of light, called photopsia, can also be a part of the patient history. Photopsia is another sign that is associated with vitreous pathology but is not diagnostic for a PVD. Photopsia is a sign that signals

that there exists strong traction within the vitreous. These flashes occur because the tugging movement is strong enough to cause a signal in the brain to perceive light. Therefore, photopsia is a more alarming sign than floaters (15). Photopsia can be provoked by sudden ocular movement, such as quickly changing the direction of gaze (12).

When the retina does get detached, then, depending on the location of the detachment, visual impairment occurs. In these cases, a shadow that ranges from dark grey to even black can occlude parts of the vision. These shadows do not move with a directional change of gaze (12). Typically, the impairment begins peripherally and can progress towards the center. If the detachment occurred at the macula, then there is a significant loss of vision (13).

1.5.2. Diagnosis

Once a patient arrives with a history of floaters, photopsia, and/or progressive loss of vision, then RD must be included in the differential diagnosis. RD is diagnosable from an ophthalmoscopic examination. If an acute rhegmatogenous RD has occurred, the physician can see an edematous retina that has lost transparency which is normally seen in a healthy retina. In addition, the pathologic hole that leads to the detachment can be observed, which may include a moving flap. An example of RD can be viewed in Figure 3. In addition, signs of PVD, vitreous hemorrhage, and even floating RPE cells within the vitreous humor can be noted. A sensitive sign of a retinal break is the visualization of these RPE cells in the anterior vitreous. This sign is called the Shafer's sign, and it is visible under a slit-lamp examination. In order to view the full length of the retina, up the ora serrata, then the examiner can perform an indirect ophthalmoscopic exam. If there are locations of the retina that cannot be visualized well enough then a B-scan ultrasound, CT scan, or MRI can be alternatively performed (13).

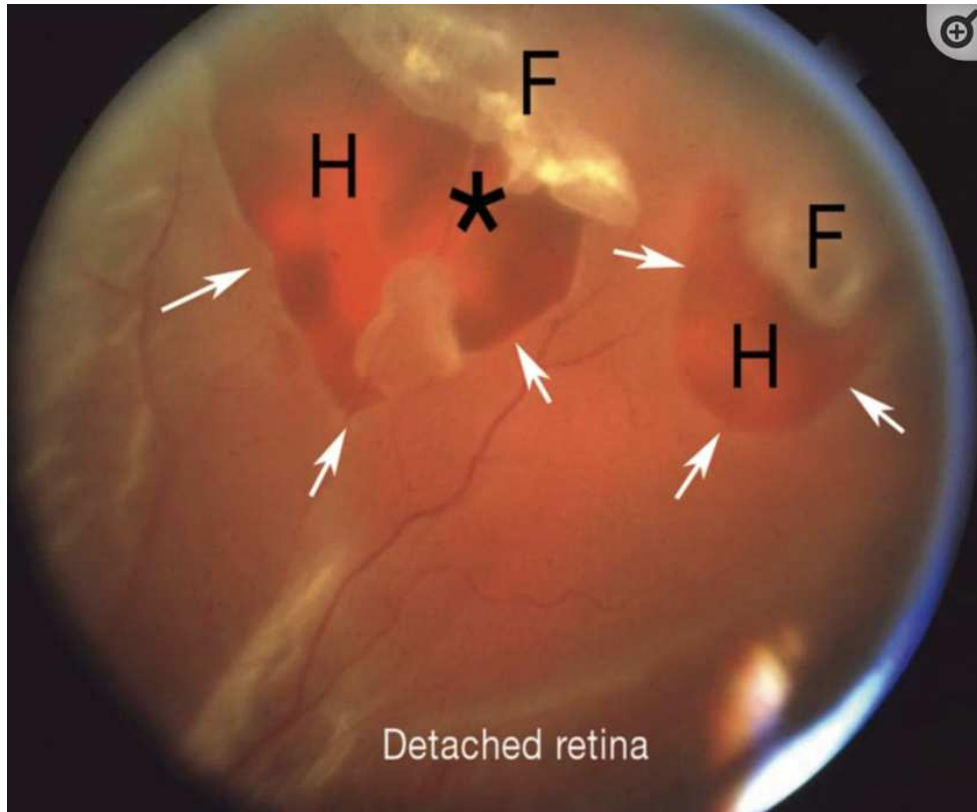


Figure 3. An ophthalmoscopic examination of the retina with an apparent retinal detachment

H: Retinal hole; F: Flap; *: artery that is bridging the flap at its apex.

Source: Feltgen N, Walter P. Rhegmatogenous retinal detachment--an ophthalmologic emergency. *Dtsch Arztebl Int.* 2014;111(1-2):12-22. doi:10.3238/arztebl.2014.0012.

1.6. Management and Prognosis

1.6.1. Management

The treatment for RD includes surgical intervention in order to reattach the retina. There exists a couple of different methods, which can be performed individually or in combination with one another. The first category of intervention includes the sealing of the hole formed in the retina from a break or tear. In this case, this intervention can also be a prophylactic treatment before the onset of actual detachment (12). A history of flashes highly indicates the need for prophylactic treatment (15). Two methods that can close a retinal hole include laser coagulation or cryocoagulation, which create a scar-induced closure. Both of these treatments can only be indicated if the retina still has points of attachment with the RPE (12).

Laser coagulation is performed by focusing a laser upon the pupil. The energy from the laser is absorbed by the RPE and can increase the temperature to around 60 °C. As a result, coagulation necrosis occurs. Cryocoagulation also creates a scar-like closure of the retinal hole, but via freezing. A cryo-probe, which achieves the temperature of –80 °C is placed near the eye, which from the outside can cause a scar to form on the retina (12). When detachment has occurred, then the surgical interventions include scleral buckling, vitrectomy, and pneumatic retinopexy. In these cases, laser and cryocoagulation are also commonly used in parallel to these interventions. Especially in cases with rhegmatogenous RD, it is imperative that the surgeon locates and closes all the retinal breaks (19). However, altogether, the primary goal of the interventions must include the removal of tractional forces upon the retina (15).

1.6.1.1. Scleral Buckling

In scleral buckling, a band is wrapped around the sclera of the eyeball to permanently contain the retina. However, first, the hole is sealed via the interventions that cause scar-induced closure. Afterwards, scleral buckling is performed, in which the surgeon sutures a sponge-like material to the sclera for the retina to stay in place and to diminish the traction on the sealed hole. Once the traction is removed, this gives the RPE the ability to reabsorb the fluid that had entered the sub-retinal space. As a result, re-attachment occurs within a few days. This intervention is successful in 85-90% of the cases. However, common complications of the operation includes eyeball deformation, which will change the refraction of light. This can cause double vision. In addition, eyeball movement issues can occur. However, these adverse complications can dissipate over time. Sponge infection is a very rare complication (0.3%) (12).

1.6.1.2. Vitrectomy

Vitrectomy is the surgical intervention that completely removes the vitreous humour, in effect completely removing that which can cause a tractional pull upon the retina. Once the vitreous is removed, laser or cryotherapy scars the holes of the retina into place. Tamponade, most commonly a mixture of air and gas is used to place the retina upon the RPE until the scar forms. This mixture is most used in simple cases of RD, for it does not require surgical removal afterwards. However, it causes a large change in refraction of around -50 D. The alternative to this air/gas mixture includes a silicone oil tamponade, which does require removal, however, the refraction is

less (+ 6 D). Vitrectomy also has success rates of around 85-90%. Complications to vitrectomy include cataract formation within the first year of the intervention (77%) and the accidental creation of new retinal holes during the surgery (17%) (12). The choice between vitrectomy and scleral buckling is determined by the presentation of the patient, the expertise of the surgeon, and, ultimately, the cost of the operation (19). However, the trend is more oriented towards performing vitrectomy compared to the other forms of treatment because it allows the surgeon to more carefully search and locate the breaks (13).

1.6.1.3. Pneumatic Retinopexy

The first surgical intervention includes pneumatic retinopexy, which is performed by introducing a gas bubble into the vitreous (13). This bubble pushes the retina upon the RPE. This decreases the inflow of fluid into the sub-retinal space through the hole, alleviating the pumping capacity of the RPE so that it absorbs the fluid (15). Once the gas bubble has properly placed the retina upon the RPE, then a scar-induced closure is performed, this intervention is most commonly only used in cases where the RD has one very small retinal tear (19). However, the gas bubble causes stretching of the vitreous, which ironically increases traction.

Due to this fact, pneumatic retinopexy causes new retinal breaks in 30% of the cases (15).

1.6.2. Prognosis

Retinal Detachment is divided into whether the retina is still attached to the fovea of the macula or not; therefore, it is not attached to the center. Those whose RD is still attached to the macula have a better prognosis. Their visual acuity is better and surgical treatment can help. In 90% of successful reattachments, the vision can be 6/12 or better. Overall, 95% of cases are successful repairs of rhegmatogenous RD, with the majority (70-90%) occurring within one surgical intervention (13). In addition, time until surgery has not been shown to affect the results of the intervention if the retina remained attached to the macula (19). Those who have no central attachment have a worse prognosis even if surgery has successfully attached the retina. In addition, their pre-op visual acuity is poorer. In these cases, only 50% of the operated eyes can regain a vision of 6/15. The prognosis worsens if the retina was detached from the macula for longer than one week. Then, even this visual acuity most likely is not achievable (13). However, even if there is macular

detachment, the patient does emergency surgical intervention within 24 hours of diagnosis but must at least operate within the week (19).

A common post-surgical complication and the most common reason for surgical failure is proliferative vitreoretinopathy (PVR). In PVR, RPE, glial, and other membrane cells are free to migrate and grow pathologically. They can grow from the inner and outer layers of the vitreous and retina. This growth leads to fibrotic membranes which eventually harden and contract which can detach the RPE and shrink the retina, leading to retinal folds (19). PVR occurs at a frequency of around 15%, regardless of which surgical intervention was performed. This statistic is even more increased in younger patients or with those who have a more advanced picture. In these cases, the rate of PVR can be up to 55% (12). Other risk factors for the development of PVR include large-sized RD and/or retinal tears, vitreous hemorrhage, cryotherapy, and a previous RD repair (19).

2. OBJECTIVES & HYPOTHESIS

This study has the following objectives:

1. Identify similarities in age, sex, eye affected, and visual acuity of rhegmatogenous RD,
2. Find a correlation between patient's visual acuity and rhegmatogenous RD,
3. Determine the seasonal variations of incidences.

Hypothesis:

1. There will be a higher prevalence of myopia in patients with rhegmatogenous RD.
2. There will be more cases of rhegmatogenous RD during the winter and spring.

3. PATIENTS & METHODS

3.1 Place of study and Patients

This retrospective study is based on data obtained from the Split registry for patients with rhegmatogenous retinal detachment. The subjects were admitted and treated at the Department of Ophthalmology, University Hospital of Split, Croatia. The data collected came from a sample of 105 patients. Of those, 68 were male and 37 were female; ages are a broad range from 20 to 91 years. The study included those patients living in the county of Spit-Dalmatia. Patients were diagnosed with RD from either traumatic or non-traumatic causes.

3.2 Methods and data analysis

This study's sample primarily took into account the patients admitted for rhegmatogenous RD, without the specific inclusion of previous comorbidities. The data in parameters in interest that were taken into account for each patient were their age at diagnosis, sex, which eye was being affected, and their visual acuity. The time frame in interest was the span from July 2005 to January 2022. The data collected from the Split Retinal Disorders registry was organized into Google Sheets format for extraction and was approved by the University Hospital of Split's Ethics Committee, by decision 2181-147/01/06/M.S.-21-02.

Statistical analysis was performed using the MedCalc program (MedCalc Software, Ostend, Belgium). Variables were presented as whole numbers and percentages (%). Quantitative variables were presented as mean values and average values. The statistical significance was set at $P < 0.05$.

4. RESULTS

The data collected for the study was taken between the years 2005 and 2020. During this period, a total of 105 patients were enrolled in the study from the Department of Ophthalmology at the University Hospital of Split, for emergency treatment of retinal detachment. Out of these 105 patients, 68 patients were male, while 37 patients were female. Therefore, 64.7% of the patient population who experienced emergency treatment for RD were males, while the remaining 35.2% were females.

The average age of the patients was 62 years old. The range of patients was varied, with a wide range extending from 20 years to 91 years old. However, even when eliminating the influence of the outlying ages, the median age of the patients was 63.5 years old.

In addition, the age of patients was also organized into 3 different subgroups; ages 20 to 50, 51 to 70, and 71 to 91. The ratio of males and females was considered within each age group to determine whether there was a predilection of gender within a certain age group. The data is depicted in table 1. Accordingly, within the first two age groups, group 20-50 and group 51-70, the ratio between males and females was very similar, with a slight, but an insignificant predilection for the male gender. However, in the oldest age group, group 71-91 years old, the ratio of males greatly outnumbered that of the females. In this eldest age group, 87.1% were males, while only 12.9% were females.

Table 1. Ratio of genders compared to the varying age groups

AGE GROUPS	Ratio of males	Ratio of females
20-50 years	52.6%	47.4%
51-70 years	51.4%	48.8%
71-91 years	87.1%	12.9%

It is apparent that the events of retinal detachment usually occurred within one eye at a time, for only in 2 cases did it affect both eyes at the same time. Therefore, the occurrence of RD in both eyes simultaneously occurred only in 1.8% of the cases. When comparing the remaining 103 cases of single-sided RD, there was shown no predominance between the left and right eye. The left eye was affected in 49.5% of the cases, while the right eye was involved in 49.5% of the cases as well. When comparing the sidedness of RD with the gender, again there was not shown any predominant pattern. Table 2 charts the events of left or right eye RD in each gender.

Table 2. Comparison of sidedness of retinal detachment with gender

Gender	Left	Right	Total
Males	33 (49.3%)	34 (50.7%)	67
Females	19 (52.8%)	17 (47.2%)	36
Total	53 (49.5%)	52 (49.5%)	103

Data about refractive status of the patients show that 55% of the cases involved the patients having a refractive error of the right eye, 45% had a refractive error of the left eye, with 72.5% of these cases involved a diopter of both the left and right eye. The diopter of the right eye ranged from Dsph -17 to +12. The average diopter was -2, and the median was -1.1. The diopter of the left eye ranged from -12 to 5, while the average and median diopter was -5.3 and -6.5, accordingly. Table 3 depicts this information in a graphical manner.

Table 3. The diopter of the patients experiencing emergency Retinal Detachment

Eye	Visual acuity	Average	Median
Left	-12 to 5	-5.8	-6
Right	-17 to 12	-2	-1.125

Due to the fact that retinal detachment is treated as an emergency, the time of operation closely follows the event timing. Therefore, the seasonality, or better put time of year, is also considered an important factor to evaluate. The time of year was grouped into the 4 parts of the year; winter, spring, summer, and fall. The data is represented in Figure 4, which clearly depicts that the greatest amount of events occurred during the winter quarter, with 41.9% of the events occurring at that time. During the summer season, 25% of the emergency RD occurred. Finally, 13.7% of RD

occurred during the fall season, while 19.4% occurred during the spring season. A chi-square test was performed, and it revealed statistically significant difference between winter, 35.2% patients, and all other seasons, $P=0.0011$. The proportion of patients which had RD during summer was 21%, 16.2% in spring, and 10.5% in fall.

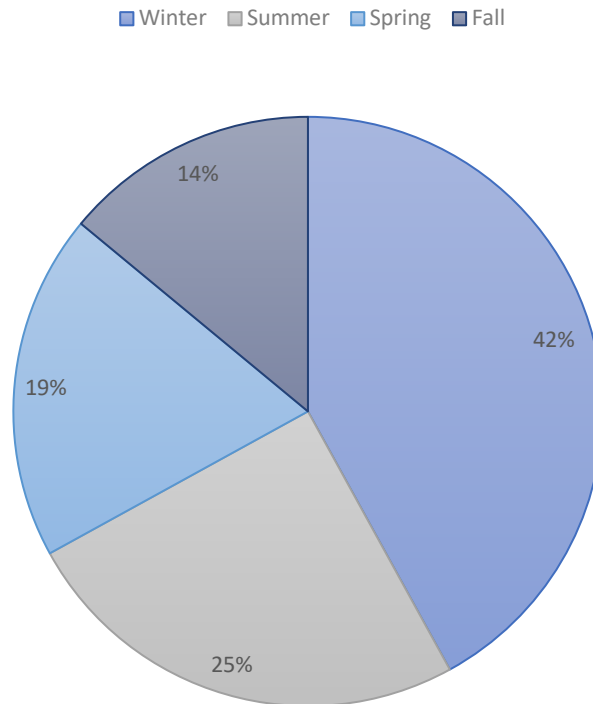


Figure 4. The seasonality of regmatogenous retinal detachment

5. DISCUSSION

Retinal detachment (RD) is defined as the separation of the sensory retina from the retinal pigment epithelium (RPE). It is recognized as the most common retinological emergency that may lead to vision loss (12). Patients may note symptoms prior to a RD, which are most commonly due to a pathology of the vitreous humour. These symptoms may include complaints of visual floaters or photopsia (flashes of light) (15). However, when RD does occur, the recognizable symptom will be shadows that impair vision. These shadows do not move with a directional change of gaze (12). Recognizing that RD is a medical emergency that requires immediate surgical intervention, it is important for hospitals to be aware of the estimated incidence rate of RD. This accurate information on the incidence and annual trends can help the health sector provide sufficient resources to serve the patient population. This is quite important for the University Hospital of Split, Croatia, for as it is the largest hospital center in the Dalmatian region, over 1 million citizens and 500,000 citizens of the neighboring country of Bosnia and Herzegovina go to be treated. Therefore, resource allocation is an especially important topic for this hospital (21).

According to a meta-analysis on the incidence of Rhegmatogenous RD, the annual incidence in Europe is 13.3 cases per 100,000 inhabitants (20). Recall that there are 1.5 million citizens of Croatia and Bosnia and Herzegovina that gravitate towards the University Hospital of Split (21). Based on the results of the meta-analysis, a population size of 1.5 million citizens should expect to have at least 200 cases of RD.

This retrospective review of the medical records between the years 2005 and 2020 took a sample size of 105 patients treated at the Ophthalmology center at the University Hospital of Split for RD. Another very similar study performed by Ivanisević M *et al.*, also performed a retrospective study of the incidence rate of RD in the same hospital, over a 12-year period, between the years 1988 and 1999. During those years, a total of 272 patients were treated (22).

In addition, the study collected that the majority of the patients were male (64.7%), and although the age range varied (20-91 years old), the median age of the patients was 63.5 years old.

This is comparable to the results of a study on the epidemiology of RD using the midline databases between 1970 and 2009, which found that the age range with the greatest risk of RD was between 55-70 years old (23). Another study that focused primarily on the German population also noted a similar age of 52 ± 10.7 years and a higher incidence amongst men (24).

According to the aforementioned epidemiological study, it found that the incidence of bilateral RD was 7.16% (23). This is significantly higher than the 1.8% cases of bilateral RD in this

study. In addition, this study found that the average diopter was -2 for the right eye and -5.3 for the left eye. This is comparable to the fact that myopia is a known risk factor for the development of RD (12).

Finally, the seasonal deviation was collected during this study. It found that 41.9% of the total cases were during the winter season, followed by 25% of the cases which occurred during the summer season. Finally, 14% of RD occurred during the fall season, while 19% occurred during the spring season. The most comparable study is the review performed by Ivanisević M *et al.*, which found that 25% of the cases occurred during the winter year and 28% of the cases occurred during the summer season (23). However, a German study that also observed the seasonal variations of RD between the years 1998 and 2008, discovered that there was a significantly higher incidence in July and a significantly low incidence in October (P value = 0.008). Overall, the topic of seasonal variation and the occurrence of RD remains inconclusive. Limitations found during the study include incomplete, inconsistent patient data to gather from. The sample size also came from one hospital data base, leading to statistics for a small geographic region. A larger sample size from a wider array of hospitals would be needed to make conclusions for broader populations.

6. CONCLUSION

Based on the study results, we can conclude the following:

1. Patients diagnosed with rhegmatogenous retinal detachment were more likely to be middle-aged, around 60,
2. Males have a slightly higher chance of RRD,
3. While which eye is affected does not bring an indication for occurrence, patients with myopia have a higher risk of RDD than those with hyperopia,
4. Winter is the season with a higher incidence rate.

7. REFERENCES

1. Kolb H. "Gross Anatomy of the Eye". Webvision: The organization of the retina and visual system [Internet]. University of Utah Health Sciences Center; 2005 (updated 2007). Available from: <https://www.ncbi.nlm.nih.gov/books/NBK11534/>
2. Ludwig PE, Jessu R, Czyz CN. Physiology, Eye. StatPearls [Internet]. StatPearls Publishing; 2022. Available from: <https://www.ncbi.nlm.nih.gov/books/NBK470322/>
3. McCaa CS. The eye and visual nervous system: Anatomy, Physiology, and Toxicology. *Environ Health Perspectives*. 1982;44:1-8.
4. Strauss O. "The Retinal Pigment Epithelium". Webvision: The organization of the retina and visual system [Internet]. University of Utah Health Sciences Center. 2011. Available from: <https://www.ncbi.nlm.nih.gov/books/NBK54392/>
5. Kolb H. "Simple Anatomy of the Retina". Webvision: The organization of the retina and visual system [Internet]. University of Utah Health Sciences Center. 2005 (Updates 2012). Available from: <https://www.ncbi.nlm.nih.gov/books/NBK11533/>
6. Kolb H. "Outer Plexiform Layer". Webvision: The organization of the retina and visual system [Internet]. University of Utah Health Sciences Center. 2005 (updated 2007). Available from: <https://www.ncbi.nlm.nih.gov/books/NBK11518/>
7. Kolb H. "Roles of Amacrine Cells". Webvision: The organization of the retina and visual system [Internet]. University of Utah Health Sciences Center. 2005 (updated 2007). Available from: <https://www.ncbi.nlm.nih.gov/books/NBK11539/>
8. Majumder PD. Anatomy of Retina. *eOphtha* [Internet]. 2021. Available from: <https://www.eophtha.com/posts/anatomy-of-retina>.
9. Kolb H. "Facts and Figures Concerning the Human Retina." Webvision: The organization of the retina and visual system [Internet]. University of Utah Health Sciences Center. 2005 (Updated 2007). Available from: <https://www.ncbi.nlm.nih.gov/books/NBK11556/>.
10. Choi EH, Daruwalla A, Suh S, Leinonen H, Palczewski K. Retinoids in the visual cycle: role of the retinal G protein-coupled receptor. *J Lipid Res*. 2021;62:100040.
11. Kiser PD, Golczak M, Palczewski K. Chemistry of the retinoid (visual) cycle. *Chem Rev*. 2014;114:194-232.
12. Feltgen N, Walter P. Rhegmatogenous retinal detachment--an ophthalmologic emergency. *Dtsch Arztebl Int*. 2014;111:12-22.
13. Steel D. Retinal detachment. *BMJ Clin Evid*. 2014;2014:0710.

14. Schwartz SG, Flynn Jr. HW, Mieler WF, Tiedeman JS. Retinal tears and rhegmatogenous retinal detachments. Entokey: Fastest Otolaryngology & ophthalmology Insight Engine [Internet]. 2020. Available from:<https://entokey.com/29-retinal-tears-and-rhegmatogenous-retinal-detachments/>
15. Kuhn F, Aylward B: Rhegmatogenous Retinal Detachment: A reappraisal of its pathophysiology and treatment. *Ophthalmic Res.* 2014;51:15-31.
16. Ishikawa M, Sawada Yu, Yoshitomi T. Structure and function of the interphotoreceptor matrix surrounding retinal photoreceptor cells. *Experimental Eye Res.* 2015;133:3-18.
17. H.S. Lazarus, G.S. Hageman. Xyloside-induced disruption of interphotoreceptor matrix proteoglycans results in retinal detachment Invest. *Invest Ophthalmol Vis Sci.* 1992;33:364-76.
18. Etminan M, Forooghian F, Brophy JM, Bird ST, Maberley D. Oral fluoroquinolones and the risk of retinal detachment. *JAMA.* 2012;307(13):1414-9.
19. Blair K, Czyz CN. Retinal Detachment. [Updated 2022 Jan 31]. In: StatPearls [Internet]. StatPearls Publishing; 2022 -. Available from:<https://www.ncbi.nlm.nih.gov/books/NBK551502/>
20. Li JQ, Welchowski T, Schmid M, Holz FG, Finger RP. Incidence of rhegmatogenous retinal detachment in europe – A Systematic Review and Meta-Analysis. *Ophthalmologica.* 2019;242:81–6.
21. Kbsplit.hr. 2022. About us KBC Split. [online] Available at: <<https://www.kbsplit.hr/en/about-us/about-us>> [Accessed 5 September 2022].
22. Ivanisevic M, Erceg M, Eterović D. Rhegmatogenous retinal detachment and seasonal variations. *Acta Med Croatica.* 2002;56:49-51.
23. Mitry D, Charteris DG, Fleck BW, Campbell H, Singh J. The epidemiology of rhegmatogenous retinal detachment: geographical variation and clinical associations. *Br J Ophthalmol.* 2010;94:678–84.
24. Gerstenberger E, Stoffelns B, Nickels S, Munzel T, Wild P, Beutel M, et al. Incidence of retinal detachment in Germany: results from the Gutenberg Health Study. *Ophthalmologica.* 2021;244:133-40.

8. SUMMARY

Objectives: The purpose of this study is to identify similarities in age, sex, eye affected, and visual acuity of rhegmatogenous retinal detachment (RRD) and to find a correlation between a patient's visual acuity and rhegmatogenous RD. In addition, this study aims to determine the seasonal variations of incidences.

Methods: This study included 105 patients diagnosed and treated for rhegmatogenous retinal detachment in Split-Dalmatia County. Patients' ages spanned 20-91 years. All patient data was extracted from the Split Retinal Disorders registry from 2005 to 2022.

Results: Out of 105 patients treated with RRD, 64.7% were male; the average age of the patients was 62 years old. In these patients, the left and right eyes were affected the same amount of 49.5%. Regarding visual acuity, myopia prevailed with an average of -2 and -5.3 in the right and left eyes respectively. The majority of cases occurred during winter (42%), with the remaining being summer (25%), spring (19%), and fall (14%).

Conclusion: Patients diagnosed with RRD were more likely to be middle-aged, around 60. Males have a slightly higher chance of RRD. While which eye is affected does not bring an indication for occurrence, patients with myopia have a higher risk of RRD than those with hyperopia. Winter is the season with a higher incidence rate.

9. CROATIAN SUMMARY

Naslov: Sezonalna varijacija incidencije regmatogenih mrežničnih odignuća u Splitsko Dalmatinskoj županiji i njegovo liječenje od 2005. do 2020.

Ciljevi: Svrha ovog rada je utvrditi sličnosti u dobi, spolu, zahvaćenosti oka i oštrini vida kod reumatogene RD i pronaći korelaciju između bolesnikove vidne oštrine i regmatogene RD. Osim toga, ova studija ima za cilj utvrditi sezonske varijacije incidencije.

Materijali I metode: Ovo istraživanje obuhvatilo je 107 bolesnika s dijagnosticiranom i liječenom regmatogenom ablacijom retine u Splitsko-dalmatinskoj županiji. Dob bolesnika kretala se od 20 do 91 godine. Podaci o svim pacijentima izdvojeni su iz Split Retinal Disorders registra od 2005. do 2022. godine.

Rezultati: Od 107 bolesnika liječenih s RRD-om, 64% su bili muškarci; prosječna dob bolesnika bila je 62 godine. U ovih bolesnika lijevo oko bilo nešto više zahvaćeno s 50,5%. Što se tiče vidne oštrine, prevladavala je kratkovidnost s prosjekom -2 i -5,3 na desnom i lijevom oku. Većina slučajeva dogodila se tijekom zime (43%), a ostali su bili ljeto (25%), proljeće (19%), jesen (13%).

Zaključci: Bolesnici s dijagnozom regmatogenog odvajanja mrežnice vjerojatnije su bili srednje dobi, oko 60 godina. Muškarci imaju nešto veće šanse za RRD. Dok koje je oko zahvaćeno ne daje indikaciju za pojavu, bolesnici s kratkovidnošću imaju veći rizik od RDD-a od onih s hiperopijom. Zima je godišnje doba s višom stopom incidencije.

10. CURRICULUM VITAE

Personal Data

Name: Pia-Antonia Vučemilović

Date of Birth: 19th December 1997

Place of Birth: New York, USA

Nationality: Croatian / American

Email: piavucemilovic@gmail.com

Education:

2016-2022 Medicine, MD, University of Split, School of medicine, Croatia

2012-2016 St. Petersburg Catholic Highschool, Florida

2004-2012 Primary school, St. Paul's Catholic School, Florida

Language:

English (Fluent)

Croatian (Fluent)

Extracurricular:

2021-2022 Board of University of Split Student Council

2021-2022 President of International Student Association

2018-2022 Member of ISA