

Usporedba magnetske rezonancijske venografije i vaskularnog ultrazvuka u dijagnostici kronične cerebrosposinalne venske insuficijencije u bolesnika s multiplom sklerozom i ispitanika bez neuroloških bolesti

Dolić, Krešimir

Doctoral thesis / Disertacija

2013

Degree Grantor / Ustanova koja je dodijelila akademski / stručni stupanj: **University of Split, School of Medicine / Sveučilište u Splitu, Medicinski fakultet**

Permanent link / Trajna poveznica: <https://um.nsk.hr/um:nbn:hr:171:992850>

Rights / Prava: [In copyright](#) / [Zaštićeno autorskim pravom.](#)

Download date / Datum preuzimanja: **2024-07-23**



Repository / Repozitorij:

[MEFST Repository](#)



**SVEUČILIŠTE U SPLITU
MEDICINSKI FAKULTET**

Krešimir Dolić

**USPOREDBA MAGNETSKE REZONANCIJSKE VENOGRAFIJE I
VASKULARNOG ULTRAZVUKA U DIJAGNOSTICI KRONIČNE
CEREBROSPINALNE VENSKE INSUFICIJENCIJE U
BOLESNIKA S MULTIPLOM SKLEROZOM I ISPITANIKA BEZ
NEUROLOŠKIH BOLESTI**

Doktorska disertacija

Split, 2013.

Ova doktorska disertacija sadrži rezultate znanstvenih istraživanja provedenih u „Buffalo Neuroimaging Analysis Center“, Buffalo, SAD, a izrađena je pod stručnim vodstvom prof .dr. sc. Roberta Živadinova.

Broj stranica: 52

Broj tablica: 3

Broj slika: 2

Broj literaturnih navoda: 64

Iznimno sam zahvalan svojem mentoru prof. dr. sc. Robertu Živadinovu što je na mene prenio svoj entuzijazam za znanstvenim istraživanjem i podučio me načinu razmišljanja istinskog znanstvenika.

Zahvaljujem se dragim kolegama sa Zavoda za dijagnostičku i intervencijsku radiologiju na čelu s prof. dr.sc. Stipanom Jankovićem koji me neprestano podupiru u mom stručnom i znanstvenom usavršavanju.

Zahvaljujem se i članovima Stručnog povjerenstva na vremenu i trudu kojeg su uložili u evaluaciji ove doktorske disertacije.

Posebno se zahvaljujem mojim roditeljima Antici i Anti te bratu Stipi koji su mi tijekom niza godina strpljivo pružali ljubav, potporu i razumijevanje. Ova disertacija je i vaš uspjeh.

Naposljetku, veliko hvala mojoj supruzi Maji, mom vjernom životnom pratitelju na nesebičnoj potpori i razumijevanju.

KAZALO

1. KAZALO.....	1
2. POPIS OZNAKA KRATICA.....	2
3. PREGLED OBJEDINJENIH RADOVA.....	3
3.1. Uvod.....	3
3.2. Pregled metodologije objedinjenih radova.....	6
3.2.1. Ispitanici metode.....	6
3.2.2. Analiza vena magnetskom rezonancijom.....	8
3.2.3. Analiza vena vaskularnim (dopler) ultrazvukom.	10
3.2.4. Statistički postupci.....	11
3.3. Sažeti pregled rezultata objedinjenih radova	12
3.3.1. Rad 1.....	12
3.3.2. Rad 2	14
3.3.3. Rad 3.....	16
4. Rasprava	18
4.1. Specifičnost i osjetljivost neinvazivnih dijagnostičkih metoda u dijagnostici kronične cerebropinalne venske insuficijencije.....	18
4.2. Strukturalne i funkcionalne venske abnormalnosti.....	22
4.3. Rizični i protektivni faktori u razvoju ekstrakranijskih venskih abnormalnosti.....	26
5. Zaključci.....	29
6. Sažetak	30
7. Summary	32
8. Literatura	34
9. Životopis.....	42
10. RADOVI OBJEDINJENI U DISERTACIJI.....	50

2. POPIS OZNAKA I KRATICA

MS	multipla skleroza (eng. Multiple sclerosis)
SŽŠ	središnji živčani sustav
HC	zdravi kontrolni ispitanici (eng. Healthy controls)
CCSVI	kronična cerebrospinalna venska insuficijencija (eng. chronic cerebrospinal venous insufficiency)
MRV	venografija magnetskom rezonancijom (eng. Magnetic resonance venography)
DS	vaskularni (doplerski) ultrazvuk (eng. Doppler sonography)
CV	kateter venografija (eng. Catheter venography)
VH	venska hemodinamika (eng. venous hemodynamic)
CTEVD	kombinirana transkranijaska i ekstrakranijaska venska doplerska studija (eng. Combined transcranial and extracranial venous doppler study)
EDSS	neurološka skala invalidnosti (eng. Expanded Disability Status Scale - EDSS)
RR	relaps remitirajući oblik multiple skleroze
PR	primarno progresivni oblik multiple skleroze
SP	sekundarno progresivni oblik multiple skleroze
IJV	unutrašnja jugularna vena (eng. internal jugular vein)
VV	vertebralne vene
TOF	venografija magnetskom rezonancijom bez kontrasta (eng. Time of flight)
TRICKS	venografija magnetskom rezonancijom s kontrastom (eng. Time Resolved Imaging of Contrast Kinetics)
BMI	indeks tjelesne mase (eng. Body mass index)

3. PREGLED OBJEDINJENIH RADOVA

Ova disertacija temelji se na objedinjenju slijedećih znanstvenih radova:

1. Dolic K, Marr K, Valnarov V, Dwyer MG, Carl E, Hagemeyer J, Kennedy C, Brooks C, Kilanowski C, Hunt K, Hojnacki D, Weinstock-Guttman, Zivadinov R. Sensitivity and specificity for screening of chronic cerebrospinal venous insufficiency using a multimodal non-invasive imaging approach in patients with multiple sclerosis. *Funct Neurol.* 2011;26(4):205-14.
2. Dolic K, Marr K, Valnarov V, Dwyer MG, Carl E, Karmon Y, Kennedy C, Brooks C, Kilanowski C, Hunt K, Siddiqui AH, Hojnacki D, Weinstock-Guttman, Zivadinov R. Intra- and extraluminal structural and functional venous anomalies in multiple sclerosis, as evidenced by 2 noninvasive imaging techniques. *AJNR Am J Neuroradiol.* 2012;33(1):16-23.
3. Dolic K, Weinstock-Guttman B, Marr K, Valnarov V, Carl E, Hagemeyer J, Kennedy C, Kilanowski C, Hojnacki D, Ramanathan M, Zivadinov R. Heart disease, overweight and cigarette smoking are associated with an increased prevalence of extra-cranial venous abnormalities. *Neurol Res.* 2012;34(8):819-27.

3.1. Uvod

Prema dosadašnjim spoznajama, multipla skleroza (MS) se smatra autoimunom bolešću središnjeg živčanog sustava (SŽS) koja se javlja kao posljedica kombinacije genetskih, okolišnih i infektivnih čimbenika, a od koje boluje preko 2,5 milijuna ljudi diljem svijeta¹. Međutim, nedavno prezentirana tzv. vaskularna etiologija nastanka MS-

a pod imenom kronična cerebros spinalna venska insuficijencija, (eng. Chronic cerebrospinal venous insufficiency, CCSVI), unijela je novo svjetlo u razumijevanje patofiziologije i pojavnosti MS-a. CCSVI postulira da poremećaj u venskoj drenaži mozga zbog patoloških promjena u glavnim ekstrakranijalnim vratnim venama i veni azygos dovodi do refluksa venske krvi s posljedičnim povećanjem intracerebralnog venskog tlaka te ekstrasvazacije metaboličkih produkata s povećanim taloženjem željeza perivenularno u parenhimu mozga ². To pak potiče upalni i neurodegenerativni odgovor koji može doprinijeti nastanku MS lezija.

U svom originalnom radu u kojem je i predstavio teoriju CCSVI Zamboni je opisao visoku učestalost CCSVI u bolesnika s multiplom sklerozom u odnosu na zdravu populaciju (eng. healthy controls, HC) što je privuklo veliku pozornost i interes širom svijeta, kako u znanstvenom svijetu tako i među bolesnicima oboljelim od MS-a ². Koristeći vaskularni (doplerski) ultrazvuk (eng. Doppler ultrasound, DS) i selektivnu kateter venografiju (eng. catheter venography, CV), Zamboni je pokazao da stenozе ekstrakranijalnih vena dovode do otvaranja kolaterala, visoke incidencije refluksa u intra i ekstrakranijalne venske segmente i gubitak posturalne regulacije cerebralne venske drenaže. Nadalje, pomoću transkranijalnog i ekstrakranijalnog DS-a kao neinvazivnih metoda, postavio je 5 kriterija koji se odnose na poremećaj venske hemodinamike (VH) i uz pomoć kojih je sa 100% specifičnošću i senzitivnošću mogao razlikovati MS bolesnike od HC obzirom na prisutnost CCSVI (dva ili više pozitivnih kriterija).

CCSVI je prouzročio brojne kontroverze i debate u znanstvenom svijetu ^{3,4}. Nekoliko nedavno objavljenih studija s većim brojem ispitanika pokušalo je reproducirati originalne rezultate objavljene od strane Zambonija koristeći DS ^{3,5-7}, venografiju magnetnom rezonancijom (MRV) ⁸⁻¹⁰ i CV ^{11,12}, ali bez uspjeha. Iako su neke od studija pronašle razliku između MS bolesnika i HC u odnosu na prisutnost CCSVI, rezultati su bili daleko od originalnih ⁷. Nadalje, uočeno je da venske abnormalnosti povezane sa CCSVI-om nisu isključivo vezane za MS bolesnike nego se mogu naći i u HC ili bolesnika sa drugim neurološkim bolestima. Tako je u prvoj fazi kombinirane transkranijalne i ekstrakranijalne venske doplerske studije (CTEVD) koja je uključila 499 ispitanika, CCSVI dijagnosticiran u 56.1% MS bolesnika, 42.3%

bolesnika s drugim neurološkim bolestima, 38.1% u bolesnika s klinički izoliranim sindromom i 22.7% u zdravih kontrolnih ispitanika ⁷. U drugoj pak studiji pronađena je još veća učestalost CCSVI među zdravom populacijom, 36% ¹³. Također, jedna od najvažnijih kritika na račun CCSVI je i činjenica da diljem svijeta sve više dolazi do nekritičke primjene intervencijskih postupaka u tretiranju venske patologije, a bez jasno utvrđenih sigurnosnih standarda i učinkovitosti istih ¹⁴.

Patološke promjene ranije spomenutih vena mogu se otkriti invazivnim metodama kao što su CV, koja se još uvijek smatra zlatnim standardom za procjenu anatomije krvnih žila, i neinvazivnim metodama kao što su DS i MRV. Jedna od glavnih kritika na račun neinvazivne dijagnostike CCSVI je da je DS izrazito subjektivna metoda, ovisna o iskustvu izvođača uz značajne teškoće u izvođenju slijepih pokusa. Također, i sama definicija VH kriterija 2 je kontroverzna iz razloga što smjer krvne struje u venama koje spajaju kortikalne i duboke intrakranijalne vene može varirati kao posljedica fizioloških inter-individualnih varijacija cerebralne venske anatomije, a dosada nije poznata ni reproducibilnost individualnih VH kriterija ³.

S druge pak strane MRV je neinvazivna, osjetljiva, i o izvođaču neovisna metoda sa širokom primjenom u svakodnevnom kliničkom radu u prikazu intra i ekstrakranijalne venske anatomije i morfologije, ali se ne zna njena pouzdanost u dijagnostici venske patologije u MS bolesnika s pozitivnim DS CCSVI kriterijima zbog nedostatka iskustva i standarda u korištenju iste u otkrivanju cerebrosposinalnih venskih anomalija. Također ne postoje dostupne MRV kontrolne studije u bolesnika s MS-om. U maloj pilot studiji Hojnacki i drugi su ispitivali vrijednost MRV kao neinvazivne dijagnostičke metode u procjeni morfologije i patologije vratnih vena u usporedbi s rezultatima dobivenim pomoću vaskularnog ultrazvuka i CV ¹⁵. Oni su pokazali da MRV ima ograničenu vrijednost u dijagnostici CCSVI prema Zambonijevim kriterijima.

Međutim nedostaci njegova rada bili su mali uzorak ispitanika (10 MS bolesnika i 7 zdravih ispitanika), nezavisni neuroradiolozi u analizi DS i MRV i izostanak evaluacije svih CCSVI kriterija, poput asimetrije unutrašnjih jugularnih i vertebralnih vena.

Nadalje, upravo nedostatak standardnih definicija venske patologije kod upotrebe različitih slikovnih metoda naglašava potrebu za multimodalnim pristupom u postavljanju dijagnoze CCSVI u studiji s velikom skupinom MS bolesnika i kontrolnih ispitanika. Ukoliko različite slikovne tehnike mogu pokazati iste patološke promjene vena to bi moglo utjecati na specifičnost i osjetljivost multimodalnog pristupa u dijagnostici CCSVI.

Ranije objavljene MS studije postavile su tezu da su ekstrakranijalne venske anomalije embrionalne (trunkularne) geneze ^{11,12,16} karakterizirane intraluminalnim (poput membrana, septuma, malformiranih zalistaka i dr.), ili ekstraluminalnim abnormalnostima (poput stenoze), međutim, daljnje *in vivo* i *postmortem* studije su potrebne za dokaz navedenih teza. Također, pretpostavlja se da podrijetlo spomenutih venskih abnormalnosti može biti fiziološko ^{5,17}, posljedica starenja ^{18,19}, kongenitalno ²⁰, posljedica upalnih procesa ⁷, kronične opstruktivne bolesti i plućne hipertenzije te okolišnih faktora ²¹.

Cilj istraživanja znanstvenih radova objedinjenih u ovoj disertaciji bio je:

- a) istražiti učestalost pozitivne CCSVI dijagnoze u dosad najvećoj kohorti MS pacijenata i zdravih ispitanika bez neuroloških bolesti upotrebom dviju neinvazivnih tehnika, MR venografije i vaskularnog ultrazvuka, te istražiti pružaju li ove dvije tehnike pružaju komplementarne informacije, odnosno je li se kombinacijom ovih dviju tehnika može povećati osjetljivost i specifičnost za skrining CCSVI-a.
- b) pod pretpostavkom da su ekstrakranijske venske abnormalnosti trunkularne geneze istražiti prevalenciju i broj venskih anomalija upotrebom vaskularnog ultrazvuka i MR venografije u velikog broja MS pacijenata i zdravih ispitanika kao i mogućnosti dijagnostičke reproducibilnosti istih.
- c) istražiti povezanost ekstrakranijalnih venskih abnormalnosti i rizičnih čimbenika te protektivnih demografskih, kliničkih i okolišnih čimbenika u kontrolnih ispitanika bez poznate bolesti centralnog živčanog sustava.

3.2. Pregled metodologije objedinjenih radova

3.2.1 Ispitanici i metode

U studiji 1 sudjelovao je 171 MS pacijent i 79 zdravih ispitanika podudarnih u odnosu na dob i spol. U studiji 2 bilo je uključeno 150 MS pacijenata i 63 kontrolna zdrava ispitanika. U obje spomenute studije ispitanici su podvrgnuti ultrazvučnom doplerskom pregledu intra i ekstrakranijalnih vena te MR venografiji vratnih vena prema ranije utvrđenim protokolima^{2,24}. Primjena kontrasta u snimanju vena zdravih ispitanika nije bila obvezatni dio protokola zbog etičkih razloga, a što je bilo preporučeno i od strane etičke komisije. Uključujući kriteriji su bili: klinički dokazana dijagnoza MS (relaps-remitirajući (RR), sekundarno progresivni (SP) i primarno progresivni bolesnici (PP) klasificirani po McDonaldsovim kriterijima iz 2005.godine), dob između 18-65 godina, vrijednost skale za procjenu invalidnosti kao posljedice bolesti (eng. Expanded Disability Status Scale -EDSS) između 0-6.5, sposobnost pristupanja doplerskim i MR pretragama. Kriteriji isključivosti bili su: granični nalazi na DS (pozitivan jedan VH kriterij uz nemogućnost detekcije drugog zbog tehničkih razloga), prisutnost relapsa i primjena steroidne terapije unutar 30 dana od uključivanja u studiju, pozitivna osobna anamneza o bolestima vratne regije i kongenitalnim cerebralnim vaskularnim abnormalnostima (Klippel-Trenaunay, Parkes-Weber, Servelle-Martorellu, Budd-Chiari, sindromi) i cerebralnim venskim trombozama, anamneza o ranije postavljenim kateterima u veni jugularis interni (IJV), aktivna trudnoća, anamneza o kroničnoj opstruktivnoj plućnoj bolesti i artritičke promjene vratne kralježnice (nemogućnost adekvatnog postavljanja u ležeći položaj), kontraindikacija za MRI (npr. srčani elektrostimulator), klaustrofobija, i postojanje kontraindikacija za primjenu gadolinijskih (Gd) kontrastnih sredstava.

U studiju 3 bila su uključena 240 kontrolna ispitanika bez pozitivne anamneze o patološkim promjenama CNS-a koji su odabrani na osnovi uključujućih i isključujućih kriterija korištenih u studiji koja je ispitivala rizične faktore povezane s pozitivnom dijagnozom CCSVI²³. Svim subjektima je učinjen doplerski pregled ekstrakranijalnih vena s ciljem utvrđivanja prisutnosti intraluminalnih i ekstraluminalnih strukturalnih te

funkcionalnih venskih abnormalnosti. Uz ultrazvučni doplerski pregled ispitanici su morali ispuniti i strukturalni upitnik koji je sadržavao pitanja o demografskim karakteristikama, postojanju autoimunih i drugih pridruženih bolesti, vaskularnih i okolišnih rizičnih faktora kao i informacijama o životnim navikama. Obzirom na vrijednost indeksa tjelesne mase (eng., body mass index, BMI) ispitanici su podijeljeni u četiri kategorije: a) ispod prosječne težine < 18.5, normalni raspon težine 18.5–24.9, prevelika težina 25–29.9 i adipozni BMI > 30 ili više. Ispitanici su bili regrutirani među bolničkim osobljem, preko oglasa u lokalnim novinama i među članovima obitelji MS pacijenata. Uključujući kriteriji bili su: ispunjen upitnik o zdravstvenom statusu (bolesti, operacije, lijekovi..), mogućnost izvođenja doplerskog pregleda (bez tehničkih poteškoća, npr. Nemogućnost rotacije vrata) i ispunjen strukturalni upitnik. Isključujući kriteriji su bili: pozitivna anamneza o patološkim stanjima povezanima sa CNS-om (neurodegenerativne bolesti, cerebrovaskularne bolesti, povijest o psihijatrijskim poremećajima, epilepsije, trauma i dr.) i patologijom vratne regije, genetska trombofilija i artritičke promjene vratne kralježnice.

3.2.2. Analiza vena magnetskom rezonancijom

U studiji 1 i 2 svim ispitanicima je učinjena MR venografija vratnih vena na 3 Tesla Signa Excite HD 12,0 “Twin Speed” 8-kanalnom skeneru (General Electric, Milwaukee, SAD), uz korištenje multi-kanalne zavojnice za glavu i vrat za dobivanje sljedećih sekvenci: 2D “Time-of-flight” (TOF) venografija (bez upotrebe paramagnetskog kontrastnog sredstva) i 3D-„Time Resolved Imaging of Contrast Kinetics“ (TRICKS) sekvencije uz primjenu kontrasta (samo MS pacijenti). Parametri korišteni za TOF su: TR / TE 17/4.3 msec (vrijeme ponavljanja / echo vrijeme), *flip* kut od 70 stupnjeva, 1,5 mm debljine slojevi, akvizicija matrice 320/192 i akvizicija u aksijalnoj ravnini skeniranja. Parametri korišteni za TRICKS su bili: TR / TE 4.2/1.6 msec, *flip* kut od 30 stupnjeva, 2 mm debljina sloja, akvizicija matrice 320/192 i akvizicija u koronarnoj ravnini skeniranja. Korišteno je paramagnetsko gadolinijsko kontrastno sredstvo aplicirano intravenski u kubitalnu venu putem automatske štrcaljke brzinom 2ml/s. Volumen ukupno datog kontrasta iznosio je 20 ml. Protokol skeniranja

sastojao se od 18 faza akvizicije, svaki u trajanju od 5s. MR presjeci su učinjeni od razine konfluensa intrakranijalnih sinusa do razine luka aorte.

Morfološka analiza protoka u IJV napravljena je na aksijalnim presjecima u 2D-TOF tehnici snimanja, kao i na rekonstruiranim aksijalnim presjecima dobivenima iz 3D TRICKS serije snimaka. Za ocjenu protoka korištena je ordinalna mjerna skala u rasponu od odsutnog protoka (bez vidljivog lumena) do elipsoidnog uzorka (normalni oblik lumena)¹⁵.

Ukupno je korišteno pet kvalitativnih kategorija za opis morfologije lumena, odnosno protoka u IJV: odsutan protok (eng. *absent*), izrazito suženje lumena (eng. *pinpoint*), spljošten lumen (eng. *flattened*), polumjesečast (eng. *crescentic*) i elipsoidni oblik (eng. *ellipsoidal*).

IJV smo podijelili na gornji i donji segment s tim da je crta razdjelnica bilo mjesto gdje se vena facialis ulijeva u jugularnu venu. Abnormalnim nalazom smatrali smo odsutnost protoka unutar lumena i izrazito suženje istog (> 50%) duž bilo kojeg segmenta IJV. Protok u vertebralnim venama je klasificiran kao prisutan (uredan nalaz) odnosno odsutan (abnormalan nalaz).

Za usporedbu MRV nalaza s nalazima DS koristili smo varijable „abnormal“ (odsutan protok, izrazito suženje, nasuprot normalni protok) za ocjenu protoka u IJV i za ocjenu protoka u vertebralnim venama (VV) varijablu „abnormal“ (odsutan protok). Također smo procijenili prisutnost i prominentnost ostalih venskih struktura vrata na MRV-u u smislu razvijenosti kolateralne mreže vena: vanjska jugularna vena, prednja jugularna vena, lična vena, tiroidna vena i duboke cervikalne vene. Prominentnost smo definirali kao širinu lumena veću od 5 mm duž cijelog toka, odnosno više od 7 mm u donjem segmentu EJV zvanom sinus, jer je taj dio često fiziološki dilatiran²⁴, a klasificirana je kao prisutna/odsutna. Također smo računali i ukupni broj kolaterala. Usporedili smo MRV varijable za kolateralnu cirkulaciju između MS bolesnika i zdravih ispitanika i između MS podgrupa. Nadalje ispitali smo i asimetriju IJV i VV obostrano koristeći kvalitativne kategoričke varijable (prisutno/odsutno).

Namjera nam je bila usporediti i asimetriju i prominentnost kolateralne venske cirkulacije vidljive na MRV s nalazima iste na DS, ali nismo uspjeli obzirom da naš specifični DS protokol (CCSVI kriteriji) nije uključivao spomenute varijable.

Sve MR venografije su pregledane od strane dva nezavisna neuroradiologa: oba radiologa su imali pristup MRV snimkama, ali ne i MR snimkama mozga i nisu bili upoznati s demografskim (osim datuma rođenja) i kliničkim podacima o ispitanicima.

3.2.3 Analiza vena vaskularnim (dopler) ultrazvukom

U sve tri nabrojene studije cerebralna venska drenaža ispitivana je pomoću obojenog doplerskog ultrazvučnog uređaja (DEK Esaote-Biosound, My lab 25, Italija) opremljenog sa 2,5 i 7,5-10 MHz sondama. Svi ispitanici su pregledani u ležećem (0°) i u sjedećem položaju (90°). Između promjene položaja postojala je pauza od nekoliko minuta kako bi venski sustav imao dovoljno vremena za prilagodbu. Svi ispitanici su pregledani po unaprijed utvrđenom protokolu za dijagnozu CCSVI koji^{2,25} se sastoji od trans-kranijskog i ekstra-kranijskog ultrazvuka s mjerenjem parametara indikativnih za CCSVI. Prvi parametar je refluks u IJVs i / ili u VV u sjedećem i ležećem položaju (90° i 0°) - refluks je definiran kao tok usmjeren prema mozgu u trajanju od > 0,88 sekunde; 2) refluks u dubokim cerebralnim venama (DCV). Refluks se definira kao reverzni tijek u trajanju od 0,5 sek u jednoj od DCV (unutarnje cerebralne vene, bazalna vena Rosenthal ili vena Galeni). Treći mjereni parametar se odnosio na intraluminalne abnormalnosti ili stenoze unutrašnjih jugularnih vena prikazanih u B načinu ultrazvučnog prikaza. IJV stenoza je definirana kao površina presjeka vene manje ili jednako 0,3 cm². U B-mod abnormalnosti se ubrajaju tanke linearne ehogene strukture koje se pružaju s unutarnje venske stijenke (eng. *flap*), multiple septe ili „flap“ u nakupini (eng. *web*), intraluminalne pregrade (eng. *septum*) te membrane i malformirani zalisci koji signifikantno remete cerebralni venski odtok. Četvrti mjereni parametar je odsutnost ultrazvučnim doplerom uočljivog protoka u IJVs i / ili VV unatoč višestrukim dubokim udisajima. Peti mejerni parametar se odnosio na gubitak posturalne kontrole glavnog cerebralnog venskog drenažnog puta mjerenjem razlika u površini presjeka

IJV-a između ležećeg i uspravnog položaja. Ispitanik se smatra CCSVI pozitivnim, ako su ≥ 2 VH kriterija bila ispunjena, kao što je već ranije objavljeno^{2,25}. DS preglede su obavili dva iskusna ultrasoničara po principu “slijepog pokusa”. Također u studiji 2 i 3 ispitanicima je učinjen ekstrakranijalni dopler unutrašnjih jugularnih vena poradi utvrđivanja prisutnosti intraluminalnih i ekstraluminalnih strukturalnih te funkcionalnih abnormalnosti. Intraluminalne promjene su obuhvaćale tanke linearne ehogene strukture koje se pružaju sa zidova venske stijenke (eng.flap), multiple septe ili *flap* u nakupinama (eng. Web), membrane (membranozne strukture koje gotovo u cijelosti okludiraju lumen vene) i malformirane zalistake: disdinamični ili fibrozni zalisci (eng.malformed valve). Ekstraluminalne promjene su predstavljali: stenoza i cirkumferentno zadebljanje stijenke uz nemogućnost adekvatnog rastezanja iste za vrijeme respiracije (eng. annulus). U funkcionalne pak abnormalnosti smo ubrajali prisutnost refluksa/protoka u dva smjera i odsustvo protoka.

Prilikom usporedbe ultrazvučnog nalaza s nalazima MRV, prisustvo najmanje jedne od sljedećih IJV VH anomalija se smatralo patološkim nalazom: zakrilca, membrane, malformirane valvule, septumi, web, stenoza, odsustvo detektabilnog protoka, i prisutnost refluksa u sjedećem i ležećem namještau ispitanika. Odsutnost dektektabilnog protoka (tzv. blok) u VV se smatralo patološkim nalazom i koristio se u usporedbi s MRV VV patološkim nalazom. Također smo usporedili intraluminalne i ekstraluminalne abnormalnosti na ultrazvuku između MS bolesnika i zdravih kontrolnih ispitanika te između MS podskupina u studiji 2.

3.2.4. Statistički postupci

Za statističku analizu dobivenih rezultata u prvoj i trećoj studiji korištena je aplikacija „Statistical Package for Social Sciences“ (SPSS, verzija 17.0), SAD, a u studiji 2 verzija 16.0. Vrijednost $p < 0,01$ je predstavljala granicu statističke značajnosti u 1. i 2. studiji, a $p < 0.05$ u trećoj studiji.

Za razlike između različitih skupina ispitanika korišten je nezavisni t-test, hi kvadrat test χ^2 i neparametrijski Mann-Whitney U-test. Prevalencija svakog od 5 VH kriterija kao i za CCSVI u različitim skupinama ispitanika analizirani su upotrebom χ^2

testa, a reproducibilnost korištenjem korelacijskih testova (Cohen's Kappa i inter-class correlation (ICC) testova). Specifičnost i osjetljivost između MS bolesnika i HC kao i između MS podgrupa analizirana je upotrebom parametrijskog „crosstabs“ testa.

U studiji 2 za procjenu prevalencije i broja venskih abnormalnosti korišteni su t-test, Fischer-ov test i Mann-Whitney U-test. Reproducibilnost je analizirana upotrebom Cohen's Kappa i ICC testa. Odnos između različitih DS i MRV venskih karakteristika analizirana je „Spearman-ovom korelacijom“.

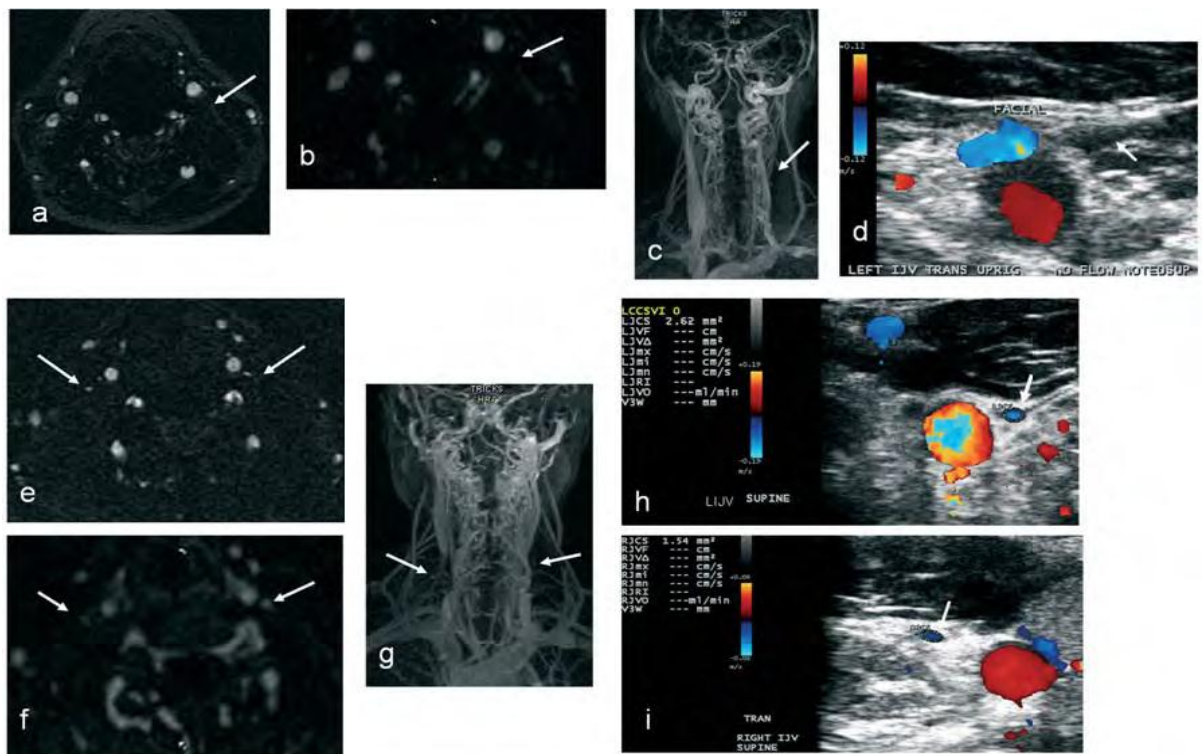
U studiji 3 za opisnu statistiku i utvrđivanje prevalencije i broja venskih abnormalnosti korišten je „student's *t*-test“, „Fischer-ov test i neparametrijski Mann-Whitney U-test. U svrhu povećanja osjetljivosti i specifičnosti rezultata studije, uzeli smo u obzir samo one varijable iz strukturiranog upitnika koje su imale postotak odgovora od 80%. Za procjenu koji je rizični odnosno protektivni faktor povezan s pojavnošću venskih abnormalnosti korištena je logistička regresijska analiza uz izračun omjera, eng. *odds-ratio* (OR), i 95% intervala pouzdanosti, eng. *confidence interval* (CI).

3.3. Sažeti pregled rezultata objedinjenih radova

3.3.1. Rad 1

U studiji 1 istraživali smo osjetljivost i specifičnost u detekciji CCSVI-a koristeći dvije neinvazivne dijagnostičke tehnike, MRV i DS. Prevalencija pozitivne dijagnoze CCSVI među MS bolesnicima je iznosila 64.3%, a 38% u kontrolnih ispitanika ($p < .001$), 58.4% za neprogresivne, a 75.9% za progresivne MS bolesnike ($p = .017$). VH kriterij 3 bio je pozitivan u 79.3% progresivnih te 63.7% neprogresivnih MS bolesnika i 45.6% ispitanika bez neuroloških bolesti ($p < 0.001$). Barem jedan pozitivan VH kriterij bio je zastupljen u 87.1% MS bolesnika i 72.7% kontrolnih ispitanika. Nadalje, pronašli smo da pozitivna 2 ili više doplerskih VH kriterija imaju visoku specifičnost, ali malu osjetljivost u razlikovanju MS bolesnika od zdravih ispitanika kao i MS podskupina obzirom na prisutnost CCSVI dijagnoze. Individualni VH kriteriji 1, 4 i 5 pokazali su visoku specifičnost, ali također nisku osjetljivost za

razlikovanje MS bolesnika od HC. Iako MRV nije pokazao signifikantne razlike na morfološkoj skali protoka između MS bolesnika i kontrolnih ispitanika, pokazao je visoku specifičnost, ali nisku osjetljivost, za diferenciranje ovih dviju skupina ispitanika kao i progresivnih i neprogresivnih MS bolesnika obzirom na abnormalni venski protok. MRV se pokazao kao komplementarna metoda dopleru u diferencijaciji progresivnih i neprogresivnih MS bolesnika, a posjeduje i mogućnost prikaza kolaterala.



Slika 1. Primjer korelacije nalaza MR venografije i vaskularnog ultrazvuka: a) odsutan protok u lijevoj unutrašnjoj jugularnoj veni prikazan u 2D TOF tehnici (strjelica) i (b i c) TRICKS tehnici MR venografije s i.v. kontrastom te (d) vaskularnim ultrazvukom (strjelice). Izrazita stenozna obje unutrašnje jugularne vene prikazane MR venografijom (e ,f, g) i vaskularnim ultrazvukom (h i j) (strjelice).

Abnormalni protok u VV na ultrazvučnom dopleru i MRV-u pokazao je visoku specifičnost za razlikovanje MS pacijenata od zdravih ispitanika kao i prisutnost više od jedne kolaterale na MRV-u, ali nisku osjetljivost. Jedan od najvažnijih nalaza ove studije je da se specifičnost za dijagnozu MS-a povećava iznad 90% kad se kombiniraju

IJV i VV abnormalnosti uočene na DS i MRV-u u kombinaciji s pozitivnim VH kriterijem 2 i nalazom više od jedne kolaterale na MRV-u.

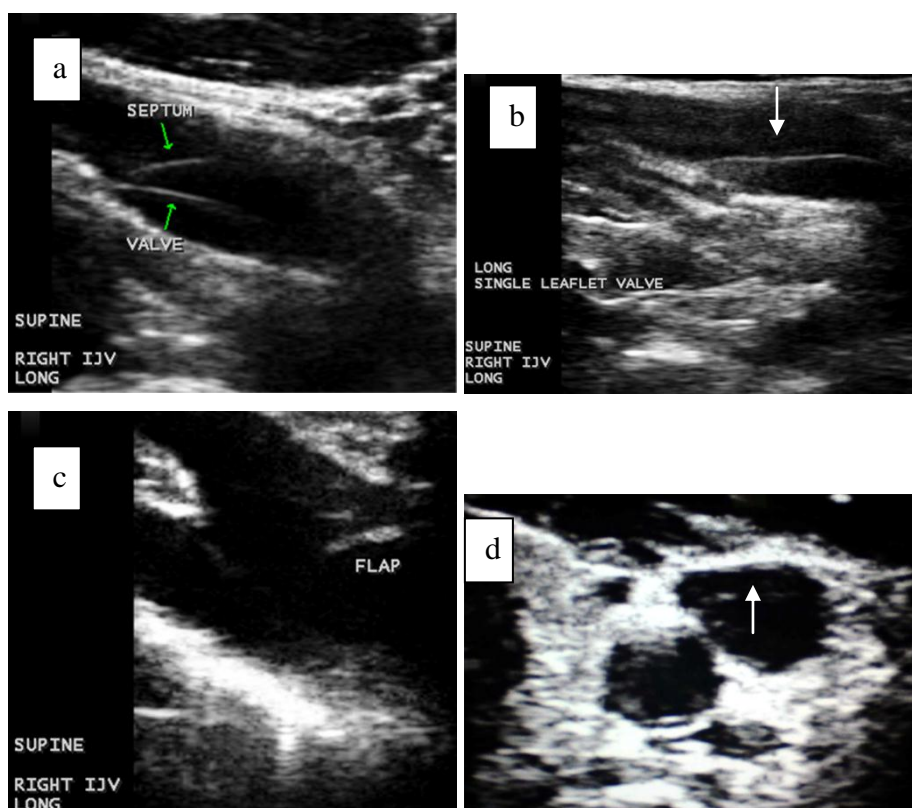
Multimodalna kombinacija kriterija	Osjetljivost MS vs. HC	Specifičnost MS vs. HC	Osjetljivost NPR-MS vs. PR-MS	Specifičnost NPR-MS vs. PR-MS
≥ 1 DS VH IJV pozitivnih kriterija i patološki MRV IJV protok	28.7%	84.8%	37.9%	76.1%
≥ 1 DS VH VV pozitivnih kriterija i patološki MRV VV protok	29%	92.4%	24.1%	92%
≥ 1 DS VH IJV kriterija i pozitivan DS VH criteria 2 i > 1 kolaterale	38.6%	81%	43.1%	63.7%
patološki MRV IJV protok i pozitivan DS VH criteria 2 te > 1 kolaterale	16.4%	91.1%	16.4%	83.6%
≥ 1 DS VH VV kriterija i pozitivan DS VH kriterij 2 te > 1 kolaterale	6.4%	94.9%	5.2%	92.9%
patološki MRV VV protok i pozitivan DS VH kriterij 2 te > 1 kolaterale	5.2%	94.8%	12.1%	99.1%

Tablica 1. *Specifičnost i osjetljivost kombinacije multimodalnih venskih hemodinamskih kriterija između MS bolesnika i kontrolnih ispitanika te MS podskupina.*

MS – Multipla skleroza; HC – zdravi ispitanici; NPR – neprogresivni bolesnici; PR - progresivni; VH – venski hemodinamski kriteriji.

3.3.2. Rad 2

U studiji 2 smo ispitivali prisutnost i broj intra i ekstraluminalnih strukturalnih i funkcionalnih abnormalnosti unutar IJV.



Slika 2. Primjeri intraluminalnih strukturalnih abnormalnosti unutar unutrašnjih jugularnih vena koje uzrokuju hemodinamske abnormalnosti u zdravih ispitanika i MS pacijenata. a) septum, b) neparni zalistak, c) flap, d) web.

MS bolesnici su imali signifikantno veći broj funkcionalnih ($p < 0.0001$), ukupnih strukturalnih ($p = 0.001$) te intraluminalnih strukturalnih ($p = 0.005$) abnormalnosti utvrđenih ultrazvučnim doplerom u odnosu na zdrave ispitanike. U MS bolesnika je također postojao trend za veću učestalost ekstraluminalnih abnormalnosti ($p = 0.023$). Nisu pronađene signifikantne razlike na morfološkoj skali protoka unutar IJV između MS bolesnika i zdravih ispitanika na MRV-u. Međutim progresivni MS bolesnici (primarni i sekundarno progresivni oblici bolesti) prezentirali su se s većom učestalošću ekstraluminalnih ($p = 0.01$) i više morfoloških abnormalnosti protoka na MRV-u u TOF ($p = 0.006$) i TRICKS ($p = 0.01$) tehnici snimanja u odnosu na neprogresivnu skupinu MS bolesnika (relaps-remitirajući). Postojao je trend za veći broj kolateralala, uočenih na MRV snimkama, u MS bolesnika u odnosu na kontrolnu skupinu ($p = 0.016$). U pogledu

reproducibilnosti, pronašli smo umjerenu do visoku podudarnost između ponovljenih pregleda od strane istog ispitivača (slijepi pokus) u odnosu na prisutnost ukupnih strukturalnih i funkcionalnih venskih abnormalnosti, a nisku ili umjerenu između dvaju ispitivača za istu skupinu abnormalnosti. Umjerenu do visoku podudarnost između dvaju ispitivača pronašli smo i za ekstraluminalne strukturalne abnormalnosti.

Individualna učestalost venskih abnormalnosti	HC (n=63)	MS (n=150)	p value^a	NPR-MS (n=104)	PR-MS (n=46)	p value^b
Ukupne strukturalne, n (%)	34 (54)	111 (74)	.004	72 (69.2)	39 (84.8)	.033
Intraluminalne strukturalne, n (%)	31 (49.2)	102 (68)	.008	67 (64.4)	35 (76.1)	.110
Web	0	6 (4)		5 (4.8)	1 (2.2)	
Flap	17 (27)	51 (34)		36 (34.6)	15 (32.6)	
Septum	9 (14.3)	43 (28.7)		34 (32.7)	9 (19.6)	
Membrane	0	0		0	0	
Malformirani zalistci	18 (28.6)	40 (26.7)		25 (24)	15 (32.6)	
Ekstraluminalne strukturalne, n (%)	7 (11.1)	33 (22)	.044	17 (16.3)	16 (34.8)	.01
Stenza	7 (11.1)	33 (22)		17 (16.3)	16 (34.8)	
Annulus	0	0		0	0	
Ukupne funkcionalne, n (%)	21 (33.3)	82 (54.7)	.003	55 (52.9)	27 (58.7)	.316
Refluks	20 (31.7)	74 (49.3)		49 (47.1)	25 (54.3)	
Paradoks	0	2 (1.3)		1 (1)	1 (2.2)	
Odsutan protok	2 (3.2)	16 (10.7)		8 (7.7)	8 (17.4)	

Tablica 2. Prevalencija intra i ekstraluminalnih strukturalnih i funkcionalnih abnormalnosti unutrašnjih jugularnih vena u zdravih ispitanika i MS bolesnika vidljivih vaskularnim ultrazvukom

3.3.3. Rad 3

Rezultati studije 3 pokazali su da su među ispitanom populacijom najčešće bile zastupljene intraluminalne strukturalne i funkcionalne abnormalnosti bez razlike između spolova ili različitih dobnih skupina. Subjekti s pozitivnom anamnezom bolesti

srca ($p=0.001$), prekomjernom tjelesnom težinom ($p=0.005$) i pušenjem cigareta ($p=0.016$) imaju signifikantno veći broj intraluminalnih strukturalnih venskih abnormalnosti.

Venske abnormalnosti		Risk/protective factors	Subjects n=240 totR/totA/tot	OR	95% CI	R	p
Ukupne intraluminalne strukturalne abnormalnosti	Rizični faktori	Srčane smetnje	223/80/41	3.01	1.7-5.4	1.1	<.001
		Pušenje	218/146/64	2.34	1.2-4.4	0.85	.005
	Protektivni faktori	-	-	-	-	-	-
Malformirani zalistci	Rizični faktori	Srčane smetnje	223/80/32	12.9	5.4-31.3	2.6	<0.001
		Pušenje	218/146/35	2.21	1-4.9	0.8	0.033
	Protektivni faktori	-	-	-	-	-	-
Flap	Rizični faktori	Mononukleoza	225/34/12	2.8	1.3-6.3	1.03	0.012
		Pušenje	218/146/34	2.1	0.9-4.7	0.75	0.042
	Protektivni faktori	-	-	-	-	-	-
Ukupne ekstraluminalne abnormalnosti	Rizični faktori	-	-	-	-	-	-
	Protektivni faktori	-	-	-	-	-	-
Ukupne funkcionalne abnormalnosti	Rizični faktori	-	-	-	-	-	-
	Protektivni faktori	Dijetalni dodaci	229/142/69	0.6	0.34-1.01	-0.53	0.037
		Biljni dodaci	229/39/23	0.5	0.2-0.9	-0.7	0.027

Tablica 3. Rizični faktori povezani s prisutnošću intraluminalnih i ekstraluminalnih strukturalnih i funkcionalnih abnormalnosti unutrašnjih jugularnih vena prikazani korištenjem logističke regresijske analize.

totR – ukupan broj ispitanika koji su odgovorili na upitnik; totA – ukupan broj ispitanika s pozitivnom nalazom za određeno stanje; tot - ukupne venske abnormalnosti.
; OR - odds ratio; CI – interval pouzdanosti; R – regresijski koeficijent

Prisutnost srčane bolesti povećava rizik za pojavnost malformiranih zalistaka unutrašnje jugularne vene 12.9 puta (95% C.I. 5.4-31.3, $p < 0.001$), a pušenje 2.2 puta (95% C.I. 1-4.9, $p = 0.033$). Prekomjerna tjelesna težina ($p = 0.003$), anamneza o preboljeloj infektivnoj mononukleози ($p = 0.012$) i pušenje ($p = 0.042$) povećavaju rizik za pojavnost *flap* abnormalnosti. Nije pronađena poveznica između ispitivanih rizičnih faktora i ekstraluminalnih strukturalnih kao ni funkcionalnih abnormalnosti. Međutim, upotreba dijetalnih i biljnih dodataka prehrani (62% ispitanika) u razdoblju od tri mjeseca ili više, pokazali su protektivnu ulogu za prisutnost funkcionalnih venskih abnormalnosti.

4. RASPRAVA

4.1. Specifičnost i osjetljivost neinvazivnih dijagnostičkih metoda u dijagnostici kronične cerebrospinalne venske insuficijencije

U studiji 1 smo istraživali osjetljivost i specifičnost neinvazivnih dijagnostičkih metoda za probir CCSVI dijagnoze na velikoj skupini MS bolesnika i zdravih kontrolnih ispitanika.

S dijagnostičkog stajališta gledano, glavna kritika na račun DS kriterija za postavljanje dijagnoze CCSVI-a je da je vaskularni ultrazvuk izrazito o operatoru ovisna metoda^{7,26,27} i da ovisi o treniranosti izvođača pretrage. U našoj nedavno objavljenoj studiji pokazali smo umjerenu do visoku podudarnost između dva operatera za dijagnozu CCSVI⁷. S ciljem da prikupimo još više informacija o reproducibilnosti individualnih i IJV/VV hemodinamskih kriterija, dva trenirana doplerska tehničara, metodom slijepog

pokusa, pregledali su 20 MS bolesnika i 7 HC u razmaku od tjedan dana. Pronašli smo umjerenu do visoku podudarnost između istih za postavljanje CCSVI dijagnoze kao i za pronalazak jednog ili više individualnih venskih hemodinamskih kriterija. Među individualnim VH kriterijima najreproducibilniji su bili kriterij 1, 3 i 4 dok su kriterij 2 i 5 u manjoj mjeri bili reproducibilni što sugerira da su globalni DS VH kriteriji za dijagnozu CCSVI reproducibilniji u odnosu na individualne. Iako DS CCSVI protokol zahtijeva adekvatnu obuku prije primjene istog^{7,27,28}, rezultati reproducibilnosti naše studije podupiru njegovu primjenu u multicentričnim studijama i za dijagnostičke svrhe.

U 64.3% MS bolesnika i 38% HC pronašli smo pozitivna 2 ili više hemodinamskih kriterija, odnosno pozitivnu CCSVI dijagnozu što je nešto veća prevalencija u odnosu na ranije objavljene rezultate prve faze CTEVD studije⁷, ali daleko manja u odnosu na originalne objavljene rezultate². Najčešći VH kriterij u obje ispitivane grupe bio je VH kriterij 3 kao i u našoj prijašnjoj studiji⁷ koji predstavlja proksimalnu stenozu IJV kao posljedicu intraluminalnih abnormalnosti^{10,24}. Ovo je također u skladu s našim ranijim istraživanjem u kojem smo pronašli da su najčešće abnormalnosti jugularnih vena indikativne za dijagnozu CCSVI intraluminalnog podrijetla²⁸. Nadalje, pronašli smo da više MS bolesnika ima pozitivan jedan ili više DS VH IJV kriterija nego kontrolni ispitanici što upućuje na činjenicu da se većina ekstrakranijskih venskih abnormalnosti nalazi unutar IJV. Bez izvođenja invazivne selektivne venografije teško je procijeniti u kojoj mjeri patologija vena azygos sudjeluje u dijagnozi CCSVI^{2,16}. Također, nismo pronašli razliku između ispitivanih skupina u odnosu na VH VV kriterije.

Osjetljivost i specifičnost DS podataka za dijagnozu CCSVI bila je znatno niža u odnosu na inicijalnu studiju², ali u korelaciji s našim ranijim studijama⁷. Iako je DS pokazao nižu osjetljivost, specifičnost za razlikovanje MS pacijenata i HC u odnosu na pozitivna 2 ili više VH kriterija i individualnih VH kriterija 1,4 i 5 je bila prilično visoka. Najčešći VH kriterij u obje ispitivane skupine bio je VH kriterij 3, ali je pokazao najnižu specifičnost u svim ispitivanim grupama. Nismo koristili "Quality Doppler Profile" (QDP) tehnologiju za detekciju DS VH kriterija 2 zbog tehničkih nemogućnosti našeg vaskularnog ultrazvuka što je moglo utjecati na rezultate osjetljivosti i specifičnosti naše studije. Specifičnost i osjetljivost za diferenciranje progresivnih od

neprogresivnih MS bolesnika obzirom na individualne DS VH kriterije i dijagnozu CCSVI bila je niža nego između MS pacijenata i HC.

U usporedbi s vaskularnim ultrazvukom, rezultati MR venografije su pokazali abnormalan protok unutrašnjih jugularnih vena u samo 32.2% MS bolesnika i 24.1% zdravih ispitanika što je u skladu s rezultatima nekoliko ranije objavljenih MRV studija^{8,9,10}. U našoj ranijoj studiji u kojoj smo istraživali potencijalnu vrijednost MR venografije u prikazu morfologije ekstrakranijskog venskog sustava¹⁰ nismo pronašli razliku između ispitivanih grupa (57 MS pacijenata bolesnika i 21 HC). U drugoj pak studiji, Wattjes i suradnici su analizirali intrakranijalne i ekstrakranijalne vene vrata u MS bolesnika i zdravih kontrolnih ispitanika (20:20) i također nisu pronašli razliku između dviju skupina u odnosu na morfologiju vena kao i na prisutnost alternativnih drenažnih puteva⁹. Usprkos činjenici da su vene vrata i glave jasno prikazane na MR venografiji, ista nema dovoljno veliku rezoluciju za prikaz intraluminalnih abnormalnosti kao ni mogućnost prikaza promjena u realnom vremenu što ujedno predstavlja glavne nedostatke ove tehnike u usporedbi s vaskularnim ultrazvukom⁹. To bi ujedno moglo objasniti proturječnost dobivenih rezultata na MRV-u i DS-u obzirom da intraluminalne abnormalnosti predstavljaju najčešći tip venske patologije u sklopu CCSVI kriterija. Međutim, MRV ima sposobnost prikaza ekstraluminalnih abnormalnosti poput stenoze vena, a što je i potvrđeno u našem prijašnjem istraživanju²⁸.

Značajno se više progresivnih MS bolesnika u odnosu na neprogresivne prezentiralo s morfološkim abnormalnostima protoka unutrašnjih jugularnih vena prikazanih korištenjem obje MRV tehnike (s i bez kontrasta). Također, postojao je trend za veću prevalenciju CCSVI kao i za učestalost pozitivnog jednog ili više VH kriterija u progresivnih MS bolesnika u odnosu na neprogresivne pri pregledu vaskularnim ultrazvukom što upućuje na zaključak da se progresivni MS bolesnici generalno prezentiraju s većim brojem venskih abnormalnosti, a što je također objavljeno u nedavno prezentiranoj studiji. Međutim, potrebne su daljnje studije koje će istražiti je li životna dob (progresivni MS pacijenti su generalno starije dobi) ili duljina trajanja bolesti mogu utjecati na prevalenciju IJV abnormalnosti u MS bolesnika, što je nedavno objavljeno u slučaju zdravih ispitanika^{18,19}.

Što se pak tiče osjetljivosti i specifičnosti, MRV rezultati su pokazali visoku specifičnost za dijagnozu multiple skleroze temeljenu na patološkim promjenama IJV na TOF sekvenci kao i za razlikovanje MS podgrupa na TOF i TRICKS sekvenci. Također je pokazao visoku specifičnost za abnormalan protok u vertebralnim arterijama. Ovi rezultati sugeriraju da se MRV može koristiti kao komplementarna neinvazivna dijagnostička metoda u odnosu na vaskularni ultrazvuk za probir pozitivne CCSVI dijagnoze usprkos manjoj osjetljivosti iste.

Zamboni je pretpostavio da bi ekstrakranijska venska kolateralna cirkulacija u MS bolesnika mogla biti kompenzatorni mehanizam za poremećeni venski protok, jer premoštava stenozirane vene i na taj način reducira drenažni otpor ²⁹. Ova studija je utvrdila da je MR venografija pouzdanija u odnosu na vaskularni ultrazvuk za globalni prikaz ekstrakranijskog venskog sustava. Upotrebom TOF tehnike ili aplikacijom intravenskog kontrasta, globalni intra i ekstrakranijski venski sustav može se neinvazivno prikazati što nije pak moguće upotrebom kateter venografije ili vaskularnim ultrazvukom (zbog tehničkih nemogućnosti prikaza vene cijelom dužinom njenog toka, osobito kolateralnih vena) ^{9,24}.

Rezultati naše MRV studije pokazali su da MS bolesnici imaju trend za veći broj kolaterala u odnosu na HC, međutim kolaterale su bile vrlo česte i u ispitanika s urednim nalazom vaskularnog ultrazvuka i MR venografije. Također, nismo pronašli značajnu razliku u broju kolaterala između MS podskupina, kako na TOF tako i na TRICKS sekvenci što je u skladu s našim ranije objavljenim rezultatima ²⁹. Međutim, našli smo visoku specifičnost za razlikovanje MS bolesnika i HC kao i MS podskupina na osnovi broja kolaterala (osobito više od jedne kolaterale) na TOF i TRICKS sekvenci. Stoga, mišljenja smo da kolateralne vene vjerojatno predstavljaju fiziološku varijaciju venskog sustava koji može služiti kao kompenzatorni mehanizam u slučaju stenotičnih promjena većeg broja ekstrakranijskih vena.

Nadalje, naša studija je pokazala da se kombinacijom doplerskih i MRV kriterija (DS VH IJV, MRV IJV, DS VH kriterij 2 i broj kolaterala) specifičnost za dijagnozu CCSVI povećala preko 85% dok je osjetljivost još uvijek ostala na razini 20-30%. S druge pak strane, kad smo upotrijebili drukčiju kombinaciju 4 kriterija (DS VH VV, MRV VV, DS VH kriterij 2 i broj kolaterala) specifičnost je porasla preko 90%, ali je

osjetljivost pala na manje od 10%. Mala osjetljivost upućuje na zaključak da se samo manja ili određena subpopulacija MS bolesnika prezentira s težom patologijom venskog sustava. Također, daljnja kvantitativna mjerenja za definiciju venskih abnormalnosti poput brzine krvne struje i volumena krvi mjereno vaskularnim ultrazvukom odnosno “phase contrast” MRV tehnikom mogla bi povećati osjetljivost za detekciju stupnja poremećaja venskog protoka unutar IJV i VV ³⁰.

U zaključku, usprkos nedostacima pri usporedbi različitih dijagnostičkih tehnika i upotrebi različitih kriterija, rezultati naše studije sugeriraju da MR venografija ima komplementarnu vrijednost u odnosu na vaskularni ultrazvuk u prikazu ekstrakranijalne venske patologije, iako je DS više osjetljiv za prikaz abnormalnosti povezanih s CCSVI dijagnozom. Također, studija je pokazala da multimodalni dijagnostički pristup za prikaz stupnja poremećaja ekstrakranijalnog venskog protoka može značajno povećati specifičnost za razlikovanje MS bolesnika od zdravih ispitanika kao i između MS podskupina.

4.2. Strukturalne i funkcionalne venske abnormalnosti

U studiji 2 smo istraživali prevalenciju intra i ekstraluminalnih strukturalnih i funkcionalnih abnormalnosti unutrašnjih jugularnih vena u bolesnika s multiplom sklerozom i kontrolnih ispitanika te vrijednost MR venografije i Doppler ultrazvuka u dijagnostici istih.

Od vremena od kada je prvi put prezentiran široj javnosti CCSVI koncept je izazvao brojne kontroverze kako u znanstvenoj javnosti tako i među populacijom MS pacijenata ^{14,31-33}. Nijedna od dosada objavljenih studija nije uspjela reproducirati originalne rezultate bez obzira na primijenjenu dijagnostičku metodu ^{3,5-10,14}. Glavni razlog takvih rezultata objašnjavao se činjenicom da se dijagnoza CCSVI-a prvenstveno temelji na osnovi rezultata ekstra i transkranijalnog vaskularnog ultrazvuka koji je izrazito subjektivna metoda ovisna o iskustvu izvođača. Također, izrazito je teško osigurati uvjete slijepog pokusa izvodeći pregled dopler ultrazvukom ³⁴.

Također, vrijednost MR venografije u postavljanju dijagnoze CCSVI još uvijek nije istražena ^{10,24}. U želji da istražimo koji je tip venskih abnormalnosti najviše

zastupljen u sklopu CCSVI koncepta u našoj studiji smo istražili prevalenciju istih upotrebom dviju neinvazivnih dijagnostičkih metoda. Venske abnormalnosti smo podijelili na strukturalne (intra i ekstraluminalne) te funkcionalne.

Rezultati vaskularnog ultrazvuka pokazali su prisutnost barem jedne strukturalne venske abnormalnosti unutrašnje jugularne vene u značajnom broju MS bolesnika i zdravih ispitanika što upućuje na zaključak da su najčešće venske abnormalnosti upravo intraluminalnog podrijetla (flap i septumi). Slični rezultati su bili i u pogledu broja spomenutih abnormalnosti.

Iako se MR venografijom mogu jasno prikazati vene glave i vrata, ona ipak nema dovoljnu rezoluciju za prikaz intraluminalnih abnormalnosti što predstavlja jedan od najvećih nedostataka pri usporedbi MRV i vaskularnog ultrazvuka ³⁴. Obzirom da intraluminalne abnormalnosti predstavljaju najčešći tip abnormalnosti u sklopu CCSVI koncepta upravo taj nedostatak MRV može objasniti razliku u rezultatima MRV i ultrazvučnih studija ^{2, 8-10, 15, 25}.

Prisutnost intraluminalnih abnormalnosti nije korelirala s prisutnošću funkcionalnih abnormalnosti ili znakovima signifikantne stenoze. U skladu s tim, rezultati ove naše studije upućuju da su i u zdravih ispitanika često zastupljene intraluminalne abnormalnosti kao što je već ranije objavljeno ^{2,4,7}. Moguće podrijetlo istih može biti kongenitalne prirode ²⁰, o godinama ovisne promjene ili pak posljedica upalnih procesa ⁷. Upravo stoga su potrebna daljnja istraživanja koja će definirati predstavljaju li ove anomalije patologiju ili su posljedica fizioloških varijacija. Nisu pronađene značajne razlike između progresivnih i neprogresivnih MS podskupina što može upućivati da se intraluminalne abnormalnosti javljaju kasnije u tijeku bolesti.

Nismo pronašli razliku u prevalenciji intraluminalnih abnormalnosti između progresivnih i neprogresivnih MS pacijenata što upućuje na zaključak da se iste pojavljuju u ranijoj fazi bolesti. Međutim, pronašli smo da životna dob progresivnih MS bolesnika korelira s prisutnošću intraluminalnih promjena detektiranih vaskularnim ultrazvukom. Iako nismo pronašli poveznicu između dobne starosti pacijenata i broja intraluminalnih abnormalnosti, kako među zdravim subjektima tako i između MS podskupina, ne može se sa sigurnošću isključiti da je prevalencija spomenute venske patologije ipak ovisna o životnoj dobi. U nedavno objavljenoj studiji koja je istraživala

promjene unutrašnjih jugularnih vena u korelaciji s godinama života u zdravih ispitanika pronašli su smanjenje volumena venske drenaže i povećanu prevalenciju refluksa u starijih ispitanika ¹⁸.

Nadalje pronašli smo veću prevalenciju i broj ekstraluminalnih abnormalnosti u MS bolesnika u usporedbi s zdravim kontrolnim subjektima upotrebom vaskularnog ultrazvuka kao i u MS progresivnih u odnosu na neprogresivne pacijente.

Rezultati pak reproducibilnosti sugeriraju da je evaluacija ekstraluminalnih abnormalnosti vaskularnim ultrazvukom manje ovisna o izvođaču istog u odnosu na druge abnormalnosti.

Bolesnici s multiplom sklerozom prezentirali su se većom učestalošću i brojem funkcionalnih abnormalnosti u odnosu na kontrolne ispitanike na vaskularnom ultrazvuku bez razlike između MS podskupina. Najčešća zabilježena abnormalnost bio je refluks u obje ispitivane skupine ispitanika, a zatim odsutnost protoka unutar unutrašnjih jugularnih vena. Nedavno objavljena studija pronašla je vrlo jaku korelaciju između jugularnog refluksa i promjena bijele tvari mozga povezanih s procesom starenja ¹⁹. Daljnja kvantitativna mjerenja su potrebna za jasnije definiranje funkcionalnih abnormalnosti poput mjerenja brzine protoka i volumena krvi, pouzdanijih parametara za određivanje opstruktivnih poremećaja vena.

Obzirom da nije bilo moguće razlikovati strukturalne i funkcionalne abnormalnosti uočene vaskularnim ultrazvukom upotrebom dviju MRV tehnika, iste smo klasificirali kao abnormalnosti protoka uzrokovane intra i ekstraluminalnim poremećajima. Nismo pronašli razliku u morfološkoj skali protoka na MRV-u između MS bolesnika i HC što je u korelaciji s nalazima triju nedavno objavljenih studija na manjem broju ispitanika ^{8,9,10}. Međutim pronašli smo značajno više abnormalnosti protoka u progresivnih u odnosu na neprogresivne MS bolesnika pri izvođenju obje MRV tehnike što je u korelaciji s nalazom DS. Jedan od nedostataka naše studije je i upotreba konvencionalnih MRV tehnika koje su osjetljivije na pojavu artefakata u usporedbi s drugim naprednijim MR tehnikama ^{9,35}. Iako nismo koristili kontrastne MRV tehnike pri pregledu HC prema uputstvima etičke komisije, pokazali smo visoku korelaciju između TOF i TRICKS tehnika kao i u ranijim studijama ¹⁵.

Pronašli smo trend za veći broj kolateralnih vena u MS bolesnika u odnosu na HC, protivno rezultatima naše prijašnje studije²⁴. MS bolesnici s većim brojem intraluminalnih IJV abnormalnosti protoka na DS prezentirali su se s značajno većim brojem kolateralnih vena na obje MRV tehnike u usporedbi s HC. Nismo pronašli razliku u odnosu na broj kolaterala između dviju MS skupina. Ovi rezultati upućuju na vrlo značajan pronalazak ove studije, a to je da veći broj kolaterala vjerojatno predstavlja kompenzatorni mehanizam prisutnosti većeg broja funkcionalnih i intraluminalnih abnormalnosti IJV kao što je već ranije objavljeno^{2,16}. Naša je pretpostavka da se kolaterale razvijaju kao posljedica ranije spomenutog kompenzatornog mehanizma i da se ekstraluminalne abnormalnosti pojavljuju kad se iscrpe njihove kompenzatorne mogućnosti. U prilog ovoj teoriji idu rezultati studije Yamuta i suradnika koji su koristili kateter venografiju za prikaz unutrašnjih jugularnih vena u 42 MS bolesnika u različitim fazama bolesti (početni stadij, nakon 5 i 10 godina) i pronašli da je stenoza ekstrakranijskih vena bila vrlo rijetko prisutna u početku bolesti, a da je učestalost istih rasla s dužinom trajanja bolesti¹². Htjeli smo također koristiti DS za evaluaciju kolaterala, ali obzirom na nemogućnosti vaskularnog ultrazvuka da prikaže iste u cijelosti, nismo bili u mogućnosti prikazati ih s 100% sigurnošću. Stoga proizlazi zaključak da je MRV pouzdanija tehnika od DS za prikaz kolaterala ekstrakranijalnog venskog sustava. U većini slučajeva bila je prisutna i korelacija između veličine ipsilateralne IJV i kolateralne vene u smislu da prominentne kolaterale prate izraženije stenotične promjene vena. Nismo pronašli razlike u abnormalnom protoku vertebralnih vena na DS i MRV između svih ispitivanih skupina što je u skladu s rezultatima ranijih studija^{10,24}.

Nedostatak naše studije je i taj što nismo direktno mjerili venski tlak i protok u duralnim venskim sinusima (glavni drenažni put prije ulaska u cervikalni venski sustav) kako bi registrirali povišen tlak ili abnormalan uzorak protoka poput refluksa ili bidirekcijskog protoka. Međutim, nema dokaza da su pacijenti kojima je učinjena radikalna disekcija vrata s jugularnom okluzijom ili pacijenti s trombozom venskog sinusa i povišenim intrakranijalnim tlakom ikada razvili demijelinizirajuću bolest mozga.

Iako se kateter venografija smatra zlatnim standardom u dijagnostici vaskularnih struktura ne postoje jasni kriteriji ili smjernice za dijagnozu CCSVI-a putem iste. Kateter venografija više predstavlja luminografiju koja daje malo ili uopće ne daje podatke o stijenci krvne žile i intraluminalnim strukturama. Prilikom izvođenja iste, malformirani zalisci mogu arteficialno ostati otvoreni prilikom prolaska katetera i na taj način spriječiti dokumentiranje stenoze³⁴. Nadalje, riječ je o invazivnoj metodi koja zahtijeva izlaganje iradijaciji te naša etička komisija ne bi odobrila upotrebu iste i na zdravim ispitanicima.

Usprkos ograničenjima pri usporedbi dviju različitih dijagnostičkih metoda i upotrebi različitih kriterija pronašli smo da konvencionalna MR venografija ima ograničenu vrijednost za detekciju ekstrakranijske venske patologije u usporedbi s vaskularnim ultrazvukom jer nije u mogućnosti razlučiti između strukturalnih i funkcionalnih venskih abnormalnosti. Međutim, MR venografija ima veću osjetljivost u prikazu venskih kolaterala.

4.3. Rizični i protektivni faktori u razvoju ekstrakranijaskih venskih abnormalnosti

U studiji 3 smo istraživali povezanost demografskih, kliničkih i okolišnih rizičnih čimbenika s prisutnošću intra i ekstraluminalnih strukturalnih i funkcionalnih abnormalnosti unutrašnjih jugularnih vena u velikoj skupini kontrolnih ispitanika bez poznate patologije središnjeg živčanog sustava. Naime, dok je patofiziologija perifernog venskog sustava relativno dobro poznata i istražena^{37,38}, još uvijek postoji nedovoljno informacija o etiologiji ekstrakranijske venske bolesti. Nedavno objavljene studije pretpostavile su da su ekstrakranijske venske abnormalnosti trunkularne geneze, odnosno posljedica poremećaja u embrionalnom razvoju, i da su karakterizirane prisutnošću intraluminalnih strukturalnih (poput membrana, septa, malformiranih zalistaka i dr.) odnosno ekstraluminalnih abnormalnosti (stenoza)^{2,20}. Obzirom da smo u našoj prethodnoj studiji²⁸ pronašli prisutnost strukturalnih abnormalnosti unutrašnjih jugularnih vena u više od polovice kontrolnih ispitanika te funkcionalnih poremećaja u trećine kontrolnih ispitanika, cilj nam je bio istražiti koji su rizični faktori povezani s

prisutnošću tih abnormalnosti u velikoj skupini kontrolnih ispitanika bez poznate patologije CNS-a.

Starija životna dob, ženski spol kao i etnička pripadnost se smatraju najvažnijim rizičnim čimbenicima za razvoj venske bolesti općenito ³⁹⁻⁴¹. U našoj studiji nismo pronašli poveznicu između različitih dobnih skupina, spolova i etničke pripadnosti obzirom na prisutnost ranije spomenutih venskih abnormalnosti što je sukladno rezultatima naše ranije studije o rizičnim faktorima za razvoj CCSVI. Nadalje, nismo pronašli vezu između prisutnosti funkcionalnih venskih abnormalnosti i ispitivanih rizičnih faktora iako su iste pronađene u više od trećine ispitanika. U 41.3% ispitanika pronašli smo refluks u IJV što je u koliziji s ranije objavljenim studijama u kojima je isti bio pozitivan u rasponu od 20-40% zdravih ispitanika ^{18,42-44}. U drugoj pak studiji s velikim uzorkom zdravih ispitanika ⁴³ refluks je bio učestaliji u starijih ispitanika i muškoj populaciji što nije bio slučaj u našoj studiji.

Jedan od najvažnijih pronalazaka naše studije je da je pozitivna anamneza o srčanoj bolesti (kongestivno zatajenje srca, preboljeli infarkt miokarda, valvularna bolest, uvećano srce, operacije na srcu, šum srca, aritmija, konstriktivni perikarditis, plućna hipertenzija i dr.) značajno povezana s povećanim rizikom za prisutnost intraluminalnih strukturalnih abnormalnosti kao i s povećanim brojem istih. Razlog tome može biti poremećaj matriksa metaloproteinaze, važnog enzima koji remodelira ekstracelularni matriks (kompleks kolagena, elastina, laminina, fibronektina i proteoglikana koji podupiru celularne komponente krvnih žila) ^{45,46}. U novije vrijeme otkriveno je da je upravo taj poremećaj povezan s razvojem ateroskleroze i arterijske bolesti kao i s bolestima vena, osobito pojavom varikoziteta ⁴⁷. Hemodinamski poremećaji snažno utječu na metabolizam kolagena preko matriks metaloproteinaze što može dovesti do remodeliranja stijenke vena i arterija ⁴⁸.

Također, jedan od vrlo važnih rezultata naše studije je da bolesti srca povećavaju rizik za pojavu malformiranih zalistaka za 12.9 puta koji su bili i najčešće zastupljene intraluminalne abnormalnosti što je u korelaciji s ranije objavljenim studijama ^{2,43,49-52}. U konstriktivnom perikarditisu, kod kongestivnog zatajenja srca, regurgitacije trikuspidalne valvule i primarne plućne hipertenzije postoji povišen središnji venski tlak

koji dovodi do inkompetencije zalistaka unutrašnjih jugularnih vena^{53,54}. Ovi rezultati podržavaju hipotezu da je insuficijencija venskih zalistaka stečena bolest i da je povezana s venskom hipertenzijom⁵¹.

Nadalje pronašli smo da ispitanici koji konzumiraju cigarete ili su iste konzumirali u prošlosti imaju značajno veću prevalenciju intraluminalnih IJV abnormalnosti u usporedbi s nepušačima. Poznato je da je pušenje značajno povezano s venskom insuficijencijom donjih ekstremiteta, u skladu s biološkim podacima i fizopatološkim mehanizmima^{55,56}. Naime, prihvaćene su činjenice da je pušenje glavni faktor u oksidativnom stresu^{57,58}. Žene koje puše imaju povećan rizik za razvoj duboke venske tromboze i posljedično veći rizik za razvoj plućne embolije⁵⁹. Također, u našoj studiji smo pronašli povećan rizik za pojavu malformiranih zalistaka i flapa u sadašnjih ili bivših pušača. Potrebna su daljnja istraživanja kako bi se razjasnio točan mehanizam odgovoran za štetne učinke duhana na venski sustav.

Mnogi rizični faktori za kardiovaskularne i trombotske bolesti su povezani s prehrambenim navikama i stoga se mogu prevenirati promjenom istih⁶⁰. Makronutrijenti i druge bioaktivne sastavnice hrane utječu na predispozicije za razvoj tromboze kao i na puteve hemostaze kroz različite mehanizme. U našoj studiji pronašli smo da svakodnevna upotreba određenih dodataka prehrani smanjuje učestalost funkcionalnih IJV abnormalnosti. Poznato je da dijetni režim prehrane ima pozitivan učinak na sniženje serumskih lipida koji čine važan dio patofiziologije nastanka kardiovaskularnih bolesti. Nadalje, biljni dodatci prehrani imaju široku primjenu u konzervativnom tretmanu kronične venske insuficijencije zbog svoje sposobnosti da povećaju elastičnost vena i reduciraju njihovu fragilnost i permeabilnost^{61,62}.

Pozitivna anamneza o preboljeloj infektivnoj mononukleozu pokazala je visoku korelaciju s prisutnošću flapa, intraluminalne strukturalne abnormalnosti, što je u skladu s rezultatima naše prijašnje studije u kojoj smo našli usku povezanost između pozitivne dijagnoze CCSVI i prisutnosti Epstein Barr virusa²³. Ranije studije su pokazale da perzistirajuća EBV infekcija u venskoj stijenci može oštetiti endotel vene potičući proinflamatorne, prokoagulirajuće i proaterogenetske čimbenike^{63,64}. Međutim, daljnje studije su potrebne za istraživanje pravih mehanizama putem kojeg EBV može dovesti do nastanka venske tromboze.

U 42.6% ispitanika s pozitivnim funkcionalnim abnormalnostima pronašli smo i intraluminalne strukturalne abnormalnosti. Nismo pronašli poveznicu između istraživanih rizičnih faktora i ekstraluminalnih ili funkcionalnih abnormalnosti iz čega zaključujemo da su funkcionalne i ekstraluminalne abnormalnosti sekundarni efekt intraluminalnih strukturalnih abnormalnosti ²⁸.

Nadalje, rezultati naše studije su u suprotnosti s ranije objavljenom hipotezom Lee-a i suradnika ²⁰ da su spomenute venske abnormalnosti embrionalne geneze bez mogućnosti progresije istih. Naša pretpostavka je da je intraluminalna venska patologija vjerojatno stečeno stanje, većinom kao rezultat životnog stila i kardiovaskularnih bolesti što naglašava potrebu rane prevencije ekstrakranijalnih rizičnih čimbenika.

Zaključno, naša studija je pokazala da postoji uska poveznica između intraluminalnih strukturalnih abnormalnosti ekstrakranijskog venskog sustava i prisutnosti srčanih bolesti te pozitivne anamneze pušenja.

5. ZAKLJUČCI

Vaskularni ultrazvuk ima veću osjetljivost u prikazu ekstrakranijalne venske patologije u odnosu na MR venografiju, ali nema sposobnost za globalni prikaz venskog sustava ³⁴. Vaskularni ultrazvuk izrazito je subjektivna, i o izvođaču ovisna metoda te zahtijeva dugotrajnu obuku rada na istom. MR venografija posjeduje mogućnost prikaza kolaterala, a pokazala se kao komplementarna metoda dopler ultrazvuku u diferencijaciji progresivnih i neprogresivnih MS bolesnika, ali ne i MS bolesnika i kontrolnih ispitanika. Jedan od najvažnijih nalaza je da se specifičnost za dijagnozu MS-a u odnosu na pozitivnu CCSVI dijagnozu povećava iznad 90% kad se kombiniraju abnormalnosti jugularnih i vertebralnih vena uočenih na dopleru i MR venografiji s pozitivnim hemodinamskim kriterijem 2 i nalazom više od jedne kolaterale na MR venografiji.

Intraluminalne strukturalne abnormalnosti predstavljaju većinu ekstrakranijskih venskih abnormalnosti s značajno većom prevalencijom istih među MS populacijom u odnosu na zdrave ispitanike. MR venografija nema dovoljno veliku rezoluciju za prikaz istih za razliku od vaskularnog ultrazvuka. MS pacijenti s većim brojem intraluminalnih

IJV abnormalnosti protoka na vaskularnom ultrazvuku imaju veći broj kolateralnih vena na obje MRV tehnike u usporedbi s kontrolnim ispitanicima što vjerojatno predstavlja kompenzatorni mehanizam prisutnosti većeg broja funkcionalnih i intraluminalnih abnormalnosti unutrašnjih jugularnih vena. Naša je hipoteza da se ekstraluminalne abnormalnosti, prvenstveno stenoze vena, pojavljuju kad se iscrpe kompenzatorne mogućnosti kolaterala što je u skladu s rezultatima ranijih studija ¹².

Obzirom da su intraluminalne strukturalne abnormalnosti veoma zastupljene i među zdravom populacijom rezultati naših istraživanja sugeriraju da bi moguće podrijetlo istih moglo biti kongenitalne prirode, odnosno promjene povezane sa starenjem ili da su pak posljedica upalnih procesa. Ispitanici s pozitivnom anamnezom bolesti srca, prekomjernom tjelesnom težinom i pušenjem cigareta imaju značajno veći broj intraluminalnih strukturalnih venskih abnormalnosti što upućuje na zaključak da je veća ekspresija venskih abnormalnosti posljedica rizičnih životnih navika i pridruženih bolesti, a ne specifična značajka samo jednog kliničkog entiteta, u ovom slučaju multiple skleroze. Međutim, upotreba dijetalnih i biljnih dodataka prehrani u razdoblju od tri mjeseca ili više, pokazala je protektivnu ulogu za prisustvo funkcionalnih venskih abnormalnosti što pak otvara nove mogućnosti za prevenciju nastanka istih.

6. SAŽETAK

Iako je od objave CCSVI teorije prošlo više od 3 godine još uvijek se vode rasprave o opravdanosti postojanja samog koncepta u sklopu etiologije MS-a te rizičnosti izvođenja endovaskularnih intervencija na ekstrakranijalnim venama. Također, još uvijek ne postoji opće prihvaćen stav o optimalnoj dijagnostičkoj metodi koja bi postala „zlatni standard“ u dijagnostici ekstrakranijalnih venskih abnormalnosti, a upitna je i sama klasifikacija i postojanje venske patologije obzirom da se iste mogu pronaći i u zdravoj populaciji.

Cilj ove doktorske disertacije je pokušati razjasniti može li se kombinacijom dviju neinvazivnih dijagnostičkih metoda povećati specifičnost odnosno osjetljivost u

dijagnostici venskih abnormalnosti i mogu li one u potpunosti zamijeniti invazivne dijagnostičke metode koje predstavljaju mnogo veći rizik za same pacijente. Nadalje, razjasniti patofiziologiju ekstrakranijskih venskih abnormalnosti u smislu njihova porijekla i prirode promjena koje mogu uzrokovati (funkcionalne i mehaničke) te je li postoji veća učestalost istih u bolesnika oboljelih od multiple skleroze u odnosu na kontrolne zdrave ispitanike. Naposljetku, cilj disertacije je i odrediti potencijalnu ulogu rizičnih i zaštitinih čimbenika za nastanak ekstrakranijske venske patologije u odnosu na iste za periferni venski sustav.

U tu svrhu u prve dvije studije ispitanike su činili MS bolesnici i kontrolni zdravi ispitanici, a u trećoj studiji ispitanici bez poznate bolesti centralnog živčanog sustava. U svim trima studijama ispitanicima je učinjen pregled vratnih vena vaskularnim ultrazvukom, a u prve dvije studije i MR venografija istih. Analizirali smo razliku u prevalenciji pozitivne dijagnoze CCSVI među ispitivanim skupinama kao i prisutnost ekstrakranijalne venske patologije obzirom na samu prirodu iste, mogućnosti neinvazivnih dijagnostičkih metoda za dokaz istih, a po prvi puta smo istražili i moguće čimbenike rizika za nastanak istih.

Rezultati znanstvenih radova 1 i 2 pokazali su da je prevalencija CCSVI dijagnoze među MS bolesnicima značajno manja u odnosu na originalno objavljene rezultate pri prvom predstavljanju koncepta. Štoviše, dokazali smo da se ista može postaviti i u relativno velikom postotku zdravih ispitanika bez poznate bolesti CNS-a. Nadalje, pokazali smo da se kombinacijom rezultata vaskularnog ultrazvuka i MR venografije može povećati specifičnost za postavljanje dijagnoze CCSVI što naglašava multimodalni pristup u dijagnozi iste. Ustanovili smo da većinu ekstrakranijske venske patologije predstavljaju intraluminalne strukturalne abnormalnosti unutrašnjih jugularnih vena i da je vaskularni ultrazvuk metoda izbora za detekciju istih koje su u većem postotku prisutne u MS bolesnika u odnosu na zdrave ispitanike. MR venografija nije pokazala dovoljno veliku osjetljivost za razlikovanje ovih dviju skupina na osnovi morfologije protoka unutar unutrašnjih jugularnih vena, ali se pokazala kao superiorna metoda za prikaz kolateralne cirkulacije.

Na osnovi rezultata treće studije zaključili smo da je veća ekspresija venskih abnormalnosti posljedica rizičnih životnih navika i pridruženih bolesti, a ne specifična značajka samo jednog kliničkog entiteta, u ovom slučaju multiple skleroze.

Zaključno, dobiveni rezultati će pridonijeti u razumijevanju patofiziologije ekstrakranijskih venskih abnormalnosti kao i u odabiru optimalne dijagnostičke metode za njihovu detekciju.

7. SUMMARY

Comparison of magnetic resonance venography and vascular ultrasound in diagnosis of chronic cerebrospinal venous insufficiency in patients with multiple sclerosis and subjects without neurological disease

Although, it has been more than three years since the original publication of CCSVI was published, there is still a great debate about justification of the existence of this concept in the etiology of MS, as well as about the risk for performing endovascular interventions in extracranial veins. Also, there is still no established diagnostic imaging modality that will serve as “gold standard” for detection of extracranial venous abnormalities, and also classification and existence of venous pathology is questionable by itself, given the fact that the same can be found among healthy populations.

The goal of this dissertation is to try to clarify whether the combination of the two non-invasive diagnostic methods can increase the sensitivity and specificity in the diagnosis of extracranial venous abnormalities and whether they can completely replace invasive diagnostic methods which represents much higher risk for the patients. Furthermore, to clarify the pathophysiology of extracranial venous abnormalities in terms of their origin and nature of changes that may cause (functional and mechanical) and whether there is a higher incidence of these in patients with MS compared to healthy control subjects. Ultimately, the goal of the dissertation is to determine the

potential role of risk and protective factors for the development of extracranial venous pathology in relation to the same for the peripheral venous system.

We analyzed the difference in the prevalence of CCSVI positive diagnosis between the two groups and the presence of extracranial venous pathology due to its nature, the possibilities of non-invasive diagnostic methods for their detection, and for the first time we have examined possible risk factors for the occurrence of those abnormalities.

The results of scientific publications 1 and 2 showed that the prevalence of CCSVI diagnosis among MS patients is significantly lower compared to the originally published results during the first presentation of the concept. Moreover, we showed that the same diagnosis can be placed in a relatively large percentage of healthy subjects without known disease of central nervous system. Furthermore, we demonstrated that the combination of the vascular ultrasound and MR venography results may increase specificity for the diagnosis of CCSVI emphasizing multimodal approach for its diagnosis. We found that most of the extracranial venous pathology represent intraluminal structural abnormalities of internal jugular veins with higher prevalence in MS patients compared to healthy subjects and that vascular ultrasound represents method of choice for their detection. MR venography did not show enough high sensitivity to distinguish these two groups based on the flow morphology within the internal jugular vein, but it proved to be a superior method for the demonstration of collateral circulation.

Based on the results of the third study, we concluded that the higher expression of venous abnormalities in people without CNS pathology is due to risky life habits and associated diseases. It is not a specific feature of a single disease entity like, in this case, multiple sclerosis.

In conclusion, the results obtained will greatly help in understanding the pathophysiology of extracranial venous abnormalities as well as in the selection of optimal diagnostic methods for their detection.

8. LITERATURA

1. Compston DAS, Coles AJ. Multiple sclerosis. *Lancet*. 2008;372:1502-17.
2. Zamboni P, Galeotti R, Menegatti E, Malagonil AM, Tacconi G, Dall'Ara S, et al. Chronic cerebrospinal venous insufficiency in patients with multiple sclerosis. *J Neurol Neurosurg Psychiatry*. 2009;80:392-9.
3. Doepp F, Friedemann P, Valdueza JM, Schmiere K, Schreiber SJ. No cerebrocervical venous congestion in patients with multiple sclerosis. *Ann Neurol*. 2010;68:173-83.
4. Mayer CA, Pfeilschifter W, Lorenz MW, Nedelmann M, Bechmann I, Steinmetz H, et al. The perfect crime? CCSVI not leaving a trace in MS. *J Neurol Neurosurg Psychiatry*. 2011;82:436-40.
5. Baracchini C, Perini P, Calabrese M, Causin F, Gallo P. No evidence of chronic cerebrospinal venous insufficiency at multiple sclerosis onset. *Ann Neurol*. 2011;69:90-9.
6. Krogias C, Schroder A, Wiendl H, Hohlfeld R, Gold R. Chronic cerebrospinal venous insufficiency and multiple sclerosis: critical analysis and first observation in an unselected cohort of MS patient. *Nervenarzt*. 2010;81:740-6.
7. Zivadinov R, Marr K, Cutter G, Ramanathan M, Benedicz RH, Kennedy C, et al. Prevalence, sensitivity, and specificity of chronic cerebrospinal venous insufficiency in MS. *Neurology*. 2011;77:138-44.
8. Sundstrom P, Wahlin A, Ambarki K, Birgander R, Eklund A, Malm J. Venous and cerebrospinal fluid flow in multiple sclerosis: A case-control study. *Ann Neurol*. 2010;68:255-9.

9. Wattjes MP, van Oosten BW, de Graaf WL, Seewann A, Bot JC, van den Berg R, et al. No association of abnormal cranial venous drainage with multiple sclerosis: a magnetic resonance venography and flow-quantification study. *J Neurol Neurosurg Psychiatry*. 2011;82:429-435.
10. Zivadinov R, Galeotti R, Hojnacki D, Menegatti E, Dwyer MG, Schirda C, et al. Value of MR Venography for Detection of Internal Jugular Vein Anomalies in Multiple Sclerosis: A Pilot Longitudinal Study. *AJNR Am J Neuroradiol*. 2011;32:938-46.
11. Ludyga T, Kazibudzki M, Simka M, Hartel M, Swierad M, Piegza J, et al. Endovascular treatment for chronic cerebrospinal venous insufficiency: is the procedure safe? *Phlebology*. 2010;25:286-95.
12. Yamout B, Herlopian A, Issa Z, Habib RH, Fawaz A, Salame J, et al. Extracranial venous stenosis is an unlikely cause of multiple sclerosis. *Mult Scler*. 2010;16:1341-8.
13. Centonze D, Floris R, Stefanini M, Rossi S, Fabiano S, Castelli M, et al. Proposed chronic cerebrospinal venous insufficiency criteria do not predict multiple sclerosis risk or severity. *Ann Neurol*. 2011;70:51-8.
14. Khan O, Filippi M, Freedman MS, Barkhof F, Dore-Duffy P, Lassmann H, et al. Chronic cerebrospinal venous insufficiency and multiple sclerosis. *Ann Neurol*. 2010;67:286-90.
15. Hojnacki D, Zamboni P, Lopez-Soriano A, Galleotti R, Menegatti E, Weinstock-Guttman B, et al. Use of neck magnetic resonance venography, Doppler sonography and selective venography for diagnosis of chronic cerebrospinal venous insufficiency: a pilot study in multiple sclerosis patients and healthy controls. *Int Angiol*. 2010;29:127-39.

16. Zamboni P, Galeotti R, Menegatti E, Malagoni AM, Giancesini S, Batolomei I, et al. A prospective open-label study of endovascular treatment of chronic cerebrospinal venous insufficiency. *J Vasc Surg.* 2009;50:1348-58.
17. Doepp F, Valdueza JM, Schreiber SJ. Incompetence of internal jugular valve in patients with primary exertional headache: a risk factor? *Cephalalgia.* 2008;28:182-5.
18. Chung CP, Lin Y, Chao A, Lin SJ, Chen YY, Wang YJ, et al. Jugular venous hemodynamic changes with aging. *Ultrasound Med Biol.* 2010;36:1776-82.
19. Chung CP, Wang PN, Wu YH, Tsao YC, Sheng WY, Lin KN, et al. More severe white matter changes in the elderly with jugular venous reflux. *Ann Neurol.* 2011;69:553-9.
20. Lee AB, Laredo J, Neville R. Embryological background of truncular venous malformation in the extracranial venous pathways as the cause of chronic cerebrospinal venous insufficiency. *Int Angiol.* 2010;29:95-108.
21. Doepp F, Bahr D, John M, Hoerniq S, Valdueza JM, Schreiber SJ. Internal jugular vein valve incompetence in COPD and primary pulmonary hypertension. *J Clin Ultrasound.* 2008;36:480-4.
22. Anderson FA Jr, Spencer FA. Risk factors for venous thromboembolism. *Circulation.* 2003;107:9-16.
23. Dolic K, Weinstock-Guttman B, Marr K, Valnarov V, Carl E, Haqemeier J, et al. Risk Factors for Chronic Cerebrospinal Venous Insufficiency (CCSVI) in a Large Cohort of Volunteers. *PLoS One.* 2011;6:e28062.

24. Zivadinov R, Lopez-Soriano A, Weinstock-Guttman B, Schirda CV, Magnano CV, Dolic K, et al. Use of MR venography for characterization of the extracranial venous system in patients with multiple sclerosis and healthy control subjects. *Radiology*. 2011;258:562-70.
25. Zamboni P, Menegatti E, Galeotti R, Malagoni AM, Tacconi G, Dall'Ara S, et al. The value of cerebral Doppler venous haemodynamics in the assessment of multiple sclerosis. *J Neurol Sci*. 2009;282:21-7.
26. Simka M, Kostecki J, Zaniewski M, Majewski E, Hartel M. Extracranial Doppler sonographic criteria of chronic cerebrospinal venous insufficiency in the patients with multiple sclerosis. *Int Angiol*. 2010;29:109-14.
27. Menegatti E, Genova V, Tessari M, Malagoni AM, Batolomei I, Zuolo M, et al. The reproducibility of colour Doppler in chronic cerebrospinal venous insufficiency associated with multiple sclerosis. *Int Angiol*. 2010;29:109-14.
28. Dolic K, Marr K, Valnarov V, Dwyer MG, Carl E, Karmon Y, Kennedy C, et al. Intra- and extraluminal structural and functional venous anomalies in multiple sclerosis, as evidenced by 2 noninvasive imaging techniques. *AJNR Am J Neuroradiol*. 2012;33:16-23.
29. Zamboni P, Consorti G, Galeotti R, Giancesini S, Menegatti E, Tacconi G, et al. Venous collateral circulation of the extracranial cerebrospinal outflow routes. *Curr Neurovasc Res*. 2009;6:204-212.
30. Zamboni P, Menegatti E, Weinstock-Guttman B, Schirda C, Cox JL, Malagoni AM, et al. The severity of chronic cerebrospinal venous insufficiency in patients with multiple sclerosis is related to altered cerebrospinal fluid dynamics. *Funct Neurol*. 2009;24:133-138.

31. Rudick RA. Multiple sclerosis: is multiple sclerosis caused by venous insufficiency? *Nat Rev Neurol.* 2010;6:472-74.
32. Filippi M, Rocca MA, Barkhof F, Bakshi R, Fazekas F, Khan O , et al. Multiple sclerosis and chronic cerebrospinal venous insufficiency: the neuroimaging perspective. *AJNR Am J Neuroradiol.* 2011;32:424-47.
33. D'Haeseleer M, Cambron M, Vanopdenbosch L, De Keyser J. Vascular aspects of multiple sclerosis. *Lancet Neurol.* 2011; 10:657-66.
34. Zivadinov R, Ramanathan M, Dolic K, Marr K, Karmon Y, Siddiqui AH, et al. Chronic cerebrospinal venous insufficiency in multiple sclerosis: diagnostic, pathogenic, clinical and treatment perspectives. *Eypert Rev Neurother.* 2011;11:1277-94.
35. Van Ameron JF, Vidarsson L, Wu S, Tessler R, Yoo SJ, Belik J, et al. Regional pulmonary blood flow: comparison of dynamic contrast-enhanced MR perfusion and phase-contrast MR. *Magn Reson Med.* 2009;61:1249-54.
36. Ayanzen RH, Bird CR, Keller PJ, McCully FJ, Theobald MR, Heiserman JE. Cerebral MR venography: normal anatomy and potential diagnostic pitfalls. *AJNR Am J Neuroradiol.* 2000;21:74-8.
37. Criqui MH, Denenberg JO, Bergan J, Langer RD, Fronek A. Risk factors for chronic venous disease: San Diego Population study. *J Vasc Surg.* 2007;46:331-7.
38. Eberhardt RT, Raffetto JD. Chronic venous insufficiency. *Circulation.* 2005;111:2398-409.
39. White RH. The epidemiology of venous thromboembolism. *Circulation.* 2003;107:4-8.

40. Dowling NF, Austin H, Dilley A, Whitsett C, Evatt BL, Hooper WC. Caucasians and African-Americans: the GATE Study. *J Thromb Haemost.* 2003;1:80-7.
41. White RH, Keenan CR. Effects of race and ethnicity on the incidence of venous thromboembolism. *Thromb Res.* 2009;123:S11-7.
42. Hsu HY, Chao AC, Chen YY, Yang FY, Chung CP, Sheng WY, et al. Reflux of jugular and retrobulbar venous flow in transient monocular blindness. *Ann Neurol.* 2008;63:247-53.
43. Akkawi NM, Agosti C, Borroni B, Rozzini L, Magoni M, Vignolo LA, et al. Jugular valve incompetence: a study using air contrast ultrasonography on a general population. *J Ultrasound Med.* 2002;21:747-51.
44. Silva MA, Deen KI, Fernando DJ, Sherifdeen AH. The internal jugular vein valve may have a significant role in the prevention of venous reflux: evidence from live and cadaveric human subjects. *Clin Physiol Funct Imaging.* 2002;22:202-5.
45. Jacob MP, Badier-Commander C, Fontaine V, Benazzoug Y, Feldman L, Michel JB, et al. Extracellular matrix remodeling in the vascular wall. *Pathol Biol.* 2001;49:326-32.
46. Lijnen HR. Metalloproteinases in development and progression of vascular disease. *Pathophysiol Haemost Thromb.* 2003;33:275-81.
47. Prandoni P. Links between arterial and venous disease. *J Intern Med.* 2007;262:341-50.
48. Prandoni P. Risk factors of recurrent venous thromboembolism: the role of residual vein thrombosis. *Pathophysiol Haemost Thromb.* 2003;33:351-3.

49. Al-Omari MH, Al-Bashir A. Internal jugular vein valve morphology in the patients with chronic cerebrospinal venous insufficiency (CCSVI): angiographic findings and schematic demonstrations. *Rev Recent Clin Trials*. 2012;7:83–7.
50. Lepori D, Papasso P, Fournier D, Genton CY, Schynder P. High-resolution ultrasound evaluation of internal jugular valves. *Eur Radiol*. 1999;9:1222-6.
51. Takase S, Pascarella L, Bergan JJ, Schmid-Schoenbein GW. Hypertension-induced venous valve remodeling. *J Vasc Surg*. 2004;39:1329-34.
52. Chung CP, Hu HH. Jugular venous reflux. *J Med Ultrasound*. 2008;16:210-22.
53. Dresser LP, McKinney WM. Anatomic and pathophysiologic studies of the human internal jugular valve. *Am J Surg*. 1987;154:220-4.
54. Fisher J, Vaghaiwalla F, Tsitlik J, Levin H, Brinker J, Weisfeldt M, et al. Determinants and clinical significance of jugular valve competence. *Circulation*. 1982;65:188-96.
55. Lindqvist PG, Epstein E, Olsson H. The relationship between lifestyle factors and venous thromboembolism among women: a report from the MISS study. *Br J Haematol*. 2009;144:234-40.
56. Pomp ER, Rosendaal FR, Doggen CJ. Smoking increases the risk of venous thrombosis and acts synergistically with oral contraceptive use. *Am J Hematol*. 2008;83:97–102.
57. Morrow JD, Frei B, Longmire AW, Gaziano JM, Lynch SM, Shyr Y, et al. Increase in circulating products of lipid peroxidation (F2-isoprostanes) in smokers. Smoking as a cause of oxidative damage. *N Engl J Med*. 1995;332:1198-203.

58. Hickey RJ, Clelland RC, Boyce DE. Carbon monoxide: smoking, air pollution, cardiovascular disease, and physiological homeostasis. *Lancet*. 1973;2:571–2.
59. Petitti DB, Wingerd J, Pellegrin F, Ramcharan S. Risk of vascular disease in women. Smoking, oral contraceptives, noncontraceptive estrogens, and other factors. *JAMA*. 1979;242:1150–4.
60. Phang SL, Wood LG, Garg M. Diet and thrombosis risk: nutrients for prevention of thrombotic disease. *Semin Thromb Hemost*. 2011;37:199–208.
61. Clarke R, Armitage J. Vitamin supplements and cardiovascular risk: review of the randomized trials of homocysteine-lowering vitamin supplements. *Semin Thromb Hemost*. 2000;26:341-8.
62. Jones W, Li X, Qu ZC, Perriott L, Whitesell RR, May JM. Uptake, recycling, and antioxidant actions of alpha-lipoic acid in endothelial cells. *Free Radic Biol Med*. 2002;33:83–93.
63. Mashav N, Mashav N, Saar N, Chundadze T, Steinvil A, Justo D. Epstein–Barr virus-associated venous thromboembolism: a case report and review of the literature. *Thromb Res*. 2008;122:570
64. Dalpke AH, Thomssen R, Ritter K. Oxidative injury to endothelial cells due to Epstein-Barr virus-induced autoantibodies against manganese superoxide dismutase. *J Med Virol*. 2003;71:408–16.

9. ŽIVOTOPIS

KREŠIMIR DOLIĆ

Zanimanje: Doktor medicine, specijalist radiolog
Adresa na poslu: Zavod za dijagnostičku i intervencijsku radiologiju, Klinički bolnički centar Split, Spinčičeva 2, 21000 Split
Telefon na poslu: 021/556 243
Mobilni telefon: 095/900 9425
E-mail: *kresimir.dolic@st.t-com.hr*
Kućna adresa: Braće Radić 14, 21210 Solin
Datum i mjesto rođenja: 04. srpanj 1979., Split
Bračno stanje: oženjen

Medicinsko obrazovanje:

1998.-2004. Medicinski fakultet Sveučilišta u Splitu
25.04.2005. položio stručni ispit za doktora medicine
2004/2005. Upisan poslijediplomski znanstveni doktorski studij iz temeljnih kliničkih medicinskih znanosti, smjer *Klinička medicina* na Medicinskom fakultetu Sveučilišta u Splitu.

Zaposlenje:

2005.-2006. liječnik-pripravnik na Hrvatskom zavodu za javno zdravstvo Splitsko-dalmatinske županije.
2006. rad u ambulantom obiteljske medicine na splitskom području
2007.-2012. specijalizant radiologije na Zavodu za dijagnostičku i intervencijsku radiologiju Split, KBC Split
2012.- specijalist radiologije, KBC Split

Stručno usavršavanje:

- 05.-07.09. 2008. simpozij iz neuroradiologije i dijagnostike muskuloskeletnog sustava održan u Pragu u organizaciji Europskog društva radiologa
- 22.9-10.10 2008. edukacija iz Transkranijuskog obojenog dopplera i Transkranijuskog doplera Willisovog kruga i vertebrobazilarnog sliva, Klinička bolnica „Sestre milosrdnice“, Zagreb
- „Summer stroke school“- Dubrovnik, lipanj 2009.
- Postgraduate medical education: „Diagnostic imaging seminar- Salzburg, September 2009“
- Poslijediplomski specijalistički studij: „Klinička radiologija“, na Medicinskom fakultetu Sveučilišta u Zagrebu, 2009/2010.
- 1.10.-26.10. 2012 - Observership in Neuroradiology, AKH Hospital Vienna, Austria

Znanstveno-istraživački projekti:

- Sudjelovanje u projektu Ministarstva znanosti „Rana dijagnostika i trombolitičko liječenje ishemijskog moždanog udara“ (2006.-).
- Od lipnja 2010. do lipnja 2011. boravio u „Buffalo Neuroimaging Analysis Center“, Buffalo (BNAC), SAD gdje sam radio na projektima koji su istraživali ulogu „Kronične cerebrospinalne venske insuficijencije“ (eng. CCSVI) u nastanku multiple skleroze (MS): „Combined Transcranial and Extracranial Venous Doppler (CTEVD) study“ i „Prospective Randomized Endovascular Therapy in multiple sclerosis (PREMiSe) study“.

Članstva u znanstvenim i strukovnim udruženjima:

- Hrvatska liječnička komora
- Hrvatski liječnički zbor
- Hrvatsko katoličko liječničko društvo

- Zbor splitskih liječnika pjevača
- European Society of Radiology (ESR)
- Radiology Society of North America (RSNA)
- American Academy of Neurology (AAN)

Znanstvena i druga aktivnost:

Znanstveni radovi indeksirani u drugim indeksnim publikacijama (SCIE, Medline):

- Titlic M, Tonkic A, Jukic I, Kolic K, **Dolic K**. Clinical manifestation of vertebrobasilar dolichoectasia. Bratisl Lek Listy. 2008;109:528-30.
- Titlic M, Jukic I, Tonkic A, Buca A, **Dolic K**. Vertigo associated with Chiari I malformation and syringomyelia. Bratisl Lek Listy. 2008;109:168-170.
- Lovric Kojundzic S, **Dolic K**, Buca A, Jankovic S, Besenski N. Hydatid Disease with Multiple Organ Involvement: A Case Report. Maced J Med Sci. 2010;3:154-158.
- Titlic M, Kolic K, **Dolic K**, Boschi V, Josipovic-Jelic, Bradic-Hammoud M. Lumbosacral spine herniation-computed tomography diagnostics. Acta Medica Croatica. 2010;64:201-4.

Znanstveni radovi indeksirani u Current Contents (CC):

- Britvic D, Aleksic-Shihabi A, Titlic M, **Dolic K**. Schizophrenia spectrum psychosis in a Croatian Genetic Isolate: Genealogical Reconstructions. Psychiatr Danub. 2010;22:51-6.
- Zivadinov R, Lopez-Soriano A, Weinstock-Guttman B, Schirda C, Magnano C, **Dolic K**, Kennedy C, et al. Use of magnetic resonance venography for

characterization of the extra-cranial venous system in patients with multiple sclerosis and healthy controls. *Radiology*. 2011;258:562-70.

- Janković S, Pavčić Ivelja M, Kolić K, Buca A, **Dolić K**, Lovrić Kojundzić S, Caljkusić K, Bilić I, Capkun V. CT perfusion and noncontrast CT in acute ischemic stroke diagnosing- is there influence on early thrombolytic therapy outcome? *Coll Antropol*. 2010;34:1391-6.
- Titlic M, **Dolic K**, Besenski N. Rare clinical manifestation of neurosarcoidosis“- case report. *Acta Clin Croat*. 2011;50:581-7.
- **Dolic K**, Marr K Valnarov V, Dwyer MG, Carl E, Kennedy C, Brooks C, Kilanowski C, Hunt K, Hojnacki D, Weinstock-Guttman B, Zivadinov R. Sensitivity and specificity for screening of chronic cerebrospinal venous insufficiency using multimodal non-invasive imaging approach in patients with multiple sclerosis. *Funct Neurol*. 2011;26:205-214.
- **Dolic K**, Weinstock-Guttman B, Marr K, Valnarov V, Carl E, Hagemeyer J, Brooks C, Kilanowski C, Hojnacki D, Ramanathan M, Zivadinov R. Risk factors for chronic cerebrospinal venous insufficiency (CCSVI) in a large cohort of volunteers. *PLoS One*. 2011;6:e28062.
- Zivadinov R, Ramanathan M, **Dolic K**, Marr K, Karmon Y, Siddiqui AH, Benedict RHB, Weinstock-Guttman B. Chronic cerebrospinal venous insufficiency in multiple sclerosis: Diagnostic, pathogenetic, clinical and treatment perspectives. *Expert Rev Neurother*. 2011;11:1277-1294.
- **Dolic K**, Marr K Valnarov V, Dwyer MG, Carl E, Karmon Y, Kennedy C, Brooks C, Kilanowski C, Hunt K, Siddiqui AH, Hojnacki D, Weinstock-Guttman B, Zivadinov R. Intra- and extra-luminal structural and functional extra-cranial venous anomalies in multiple sclerosis, as evidenced by two non-invasive imaging techniques. *AJNR Am J Neuroradiol*. 2012;33:16-23.
- **Dolic K**, Karen M, Zivadinov R. Unclear value of positional MR angiography in evaluating cerebral venous outflow hemodynamics. *AJNR Am J Neuroradiol*. 2012;33:E30..

- **Dolic K**, Weinstock-Guttman B, Marr K, Valnarov V, Carl E, Hagemeyer J, Kennedy C, Kilanowski C, Hojnacki D, Ramanathan M, Zivadinov R. Heart disease, overweight and cigarette smoking are associated with an increased prevalence of extra-cranial venous abnormalities. *Neurol Res.* 2012;34:819-27
- **Dolic K**, Siddiqui AH, Karmon Y, Marr K, Zivadinov R. The role of noninvasive and invasive diagnostic imaging techniques for detection of extracranial venous system anomalies and developmental variants. 2013 (in press)
- Zivadinov R, Karmon Y, **Dolic K**, Hagemeyer J, Marr K, Valnarov V et al. Multimodal noninvasive and invasive imaging of extracranial venous abnormalities indicative of CCSVI: Results of the PREMise study. 2013 (in press)

Kongresni sažeci:

- **Dolic K**, Lahman-Dorić M, Janković S, Kuštera-Ćurković S, Meštrović J. Hemolitičko uremički sindrom - prikaz slučaja. III. Kongres radiologa Bosne i Hercegovine; 2007., 4.10.-7.10., Sarajevo, Bosna i Hercegovina.
- **Dolic K**, Jankovic S, Buca A, Kolic K, Lahman-Dorić M, Glavina G, Kuštera-Ćurković S. „Our first experience with CT perfusion“. 9 th Hungarian – Croatian – Slovenian Radiological Symposium, Kehidakustany, Hungary, November 2009.
- **Dolic K**, Marr K, Valnarov V, Dwyer MG, Carl E, Karmon Y, Kennedy C, Brooks C, Kilanowski C, Hunt K, Hojnacki D, Weinstock-Guttman B, Zivadinov R. Comparative study of MR venography and doppler sonography in depicting extracranial venous abnormalities in multiple sclerosis patients and healthy subjects. *Neurology* 2011;76(Suppl 4):P05.071, A395.

- Karmon Y, Zivadinov R, Weinstock-Guttman B, Marr K, Valnarov V, **Dolic K**, Kennedy C, Carl E, Hopkins LN, Levy EI, Siddiqui AH. Multimodal diagnostic correlates between doppler sonography, catheter venography and intravascular ultrasound in detection of venous valve abnormalities during phase I PREMise (Prospective Randomized Endovascular therapy in Multiple Sclerosis) study. *Neurology* 2011;76 (Suppl 4):P04.187, A320.
- Karmon Y, Zivadinov R, Weinstock-Guttman B, Kennedy C, **Dolic K**, Marr K, Valnarov V, Siddiqui A. Intravascular Ultrasound for detection of Azygous and Internal Jugular vein (IJV) abnormalities as part of the PREMise (Prospective Randomized Endovascular therapy in Multiple Sclerosis) study. 2nd Annual ISNVD Scientific Meeting, Orlando FL, 2012:A165.
- **Dolic K**, Marr K, Valnarov V, Dwyer MG, Carl E, Kennedy C, Kilanowski C, Hojnacki D, Weinstock-Guttman B, Zivadinov R. Multimodal imaging approach sclerosis for screening of chronic cerebrospinal venous insufficiency in patients with multiple sclerosis. 2nd Annual ISNVD Scientific Meeting, Orlando FL, 2012:A141.
- Karmon Y, Zivadinov R, Weinstock-Guttman B, **Dolic K**, Kennedy C, Marr K, Valnarov V, Siddiqui A. Comparison of intravascular ultrasound (IVUS) to gold standard catheter venography (CV) for detection of extra-cranial venous abnormalities indicative of CCSVI: Results of the PREMise (Prospective Randomized Endovascular therapy in Multiple Sclerosis) study. 28th European Committee for Treatment and Research in Multiple Sclerosis, Lyon, France, October 10-13, 2012:P632.
- **Dolic K**, Weinstock-Guttman B, Marr K, Valnarov V, Carl E, Hagemeyer J, Kennedy C, Kilanowski C, Hojnacki D, Ramanathan M, Zivadinov R. Heart disease, overweight and cigarette smoking are associated with increased

prevalence of extra-cranial venous abnormalities. 28th European Committee for Treatment and Research in Multiple Sclerosis, Lyon, France, October 10-13, 2012:P634.

Poster prezentacije:

- **Dolic K**, Kolic K, Buca A, Titlic. Kriptokokni meningitis-prikaz slučaja. V. Alpe-Adria neuroradiološki kongres. 23-25.10.2008., Supetar, Hrvatska.
- **Dolic K**, Kolic K, Buca A, Titlic M. Utjecaj standardnih čimbenika rizika na lokalizaciju ishemijskih lezija na CT-u. IV. Kongres Hrvatskog društva za neurovaskularne bolesti i Hrvatskog društva za prevenciju moždanog udara sa međunarodnim sudjelovanjem, prosinac 2008, Zagreb, Hrvatska
- Kolić K, Bešenski N, Rumboldt Z, Buča A, **Dolić K**. Primary diffuse leptomenigeal gliomatosis“ - case report. V. Alpe-Adria neuroradiološki kongres; 2008., 23.10.-25.10., Supetar, Hrvatska.
- Kolic K, **Dolic K**, Jankovic S, Buca A, Lahman-Dorić M, Glavina G, Kuštera-Ćurković., „Our first experience with CT perfusion“. ECR 2010. Viene, Austria
- **Dolic K**, Buca A, Kolic K, Jankovic, Pavicic Ivelja M, Vulic M, Roje D. Posterior reversible encephalopathy syndrome in pregnant women with preeclampsia. 5th Congress of Croatian Society of Radiology with international participation, October 13-16. 2010 Opatija, Croatia.
- **Dolic K**, Marr K, Valnarov V, Dwyer MG, Carl E, Karmon Y, Kennedy C, Brooks C, Kilanowski C, Hunt K, Hojnacki D, Weinstock-Guttman B, Zivadinov R. Comparative study of MR venography and doppler sonography in depicting extracranial venous abnormalities in multiple sclerosis patients and healthy subjects. American Academy of Neurology Annual Meeting, Honolulu, SAD, April 2011.

- „40. Meeting of the Radiologists of the Alpe-Adria Region“, Graz, September 2011.
- Y. Karmon, R. Zivadinov, B. W-Guttman, K Marr, V.Valnarov, **K Dolic**, C. Kennedy E. Carl, L.N. Hopkins, E. I. Levy, A.H.Siddiqui. Multimodal diagnostic correlates between Doppler Sonography, Catheter Venography and Intravascular Ultrasound in detection of venous valve abnormalities during phase I PREMISE(Prospective Randomized Endovascular therapy in Multiple Sclerosis) study. American Academy of Neurology. Honolulu 2011.
- **Dolic K**, Buca A, Kolic K, Jankovic, Pavicic Ivelja M, Vulic M, Roje D. Posterior reversible encephalopathy syndrome in pregnant women with preeclampsia. Slovensko-hrvatsko-mađarski susret mladih radiologa, Maribor, Studeni 2011.
- **Dolic K**, Marr K, Valnarov V, Dwyer MG, Carl E, Karmon Y, Kennedy C, Brooks C, Kilanowski C, Hunt K, Hojnacki D, Weinstock-Guttman B, Zivadinov R. Comparative study of MR venography and doppler sonography in depicting extracranial venous abnormalities in multiple sclerosis patients and healthy subjects. European Congress of Radiology, Vienna, March 2012.
- Antulov R, **Dolic K**, Fruehwald-Pallamar J, Miletic D, Thurnher MM. Differentiation of Pyogenic and Fungal Brain Abscesses with Susceptibility-Weighted Imaging. ASNR 51st Annual Meeting, May 18-23,2013. San Diego, California. USA.

Izdavačka djelatnost (poglavlja u udžbenicima):

- Bešenski N, Jankovic S, Buča A. Klinička neuroradiologija mozga. Koautor poglavlja „Infektivne i upalne bolesti mozga“. Medicinska naklada Zagreb. 2011.

- Bešenski N, Jankovic S. „Neuroradiologija kralježnice i kralježnične moždine“. Autor poglavlja „Demijelinizacijske bolesti kralježnične moždine“ i „Infektivne bolesti kralježnice i kralježnične moždine“, te koautor poglavlja „Metaboličke bolesti kralježnice“. Medicinska naklada Zagreb. 2013. U tisku.

10. RADOVI OBJEDINJENI U DISERTACIJI

Sensitivity and specificity for screening of chronic cerebrospinal venous insufficiency using a multimodal non-invasive imaging approach in patients with multiple sclerosis

Kresimir Dolic, MD^a
Karen Marr, RVT, RDMS^a
Vesela Valnarov, MD^a
Michael G. Dwyer, BS, MS^a
Ellen Carl, BA, MS^a
Jesper Hagemeyer, MS^a
Cheryl Kennedy, LMSW, MPH^a
Christina Brooks, BA^a
Colleen Kilanowski, MS^a
Kristin Hunt, BA^a
David Hojnacki, MD^b
Bianca Weinstock-Guttman, MD^b
Robert Zivadinov, MD, PhD^{a,b}

^a Buffalo Neuroimaging Analysis Center, State University of New York, Buffalo, NY, USA

^b The Jacobs Neurological Institute, Department of Neurology, State University of New York, Buffalo, NY, USA

Corresponding author: Robert Zivadinov
Department of Neurology
School of Medicine and Biomedical Sciences
Buffalo Neuroimaging Analysis Center
100 High St, Buffalo, NY 14203, USA
E-mail: rzivadinov@bnac.net

Summary

The aim of this study was to investigate whether a combination of Doppler sonography (DS) and magnetic resonance venography (MRV) on 3T MRI increases specificity for detection of chronic cerebrospinal venous insufficiency (CCSVI) in 171 (113 relapsing-remitting, 47 secondary-progressive, 11 primary progressive) patients with multiple sclerosis (MS) and 79 age- and sex-matched healthy controls (HCs). One hundred ten (64.3%) MS patients and 30 (38%) HCs presented ≥ 2 venous hemodynamic CCSVI criteria ($p < .0001$). Both DS and MRV showed relatively high specificity but lower sensitivity for determining a CCSVI diagnosis in patients with MS vs HCs and between MS subgroups. In MS patients this diagnostic specificity increased to over 90% by combining internal jugular vein and vertebral vein abnormal DS and MRV findings, reflux in deep cerebral veins and MRV findings of >1 collateral veins. This study suggests that a multimodal non-invasive approach (DS and MRV) increases the specificity for a diagnosis of CCSVI in patients with MS.

KEY WORDS: CCSVI, Doppler sonography, healthy controls, MR venography, multiple sclerosis, reproducibility, specificity

Introduction

Recently, a condition called chronic cerebrospinal venous insufficiency (CCSVI) was described in multiple sclerosis (MS) patients with high frequency (1). It was postulated that MS is associated with impaired brain venous drainage due to outflow obstruction in the extracranial venous system, mostly related to anomalies in the internal jugular veins (IJVs) and azygos vein. Zamboni et al. (1), using extracranial and transcranial Doppler sonography (DS) of the neck, established five ultrasound venous hemodynamic (VH) criteria that were able to distinguish MS patients from controls with 100% sensitivity and specificity. Fulfillment of two or more VH criteria was required to establish a diagnosis of CCSVI (1).

Several recently published studies utilizing DS (2-6), magnetic resonance venography (MRV) (7-10) and catheter venography (CV) (11,12) aimed to reproduce these original findings. They gave variable results (as regards CCSVI diagnosis) between MS patients and controls, ranging from no difference to significant difference, but they all showed a substantially lower prevalence of CCSVI than originally reported (1).

One of the main criticisms of the current non-invasive CCSVI diagnostic approach is that DS is a highly operator-dependent imaging modality and not easy to blind in a clinical setting. Also, the assessment of the second VH criterion (reflux in deep cerebral veins) is controversial because the direction of the blood flow in veins connecting cortical with deep veins may vary considerably as a consequence of the physiological inter-individual variability of the cerebral venous anatomy (3). Moreover, the reproducibility of individual VH criteria used for CCSVI diagnosis is unknown at this time.

In addition, there are no standard protocols for defining venous pathology using different imaging techniques, which underlines the need for a multimodal approach to the assessment of CCSVI in a larger cohort of MS patients and controls. If different imaging techniques are found to show the same findings, this will not only establish the existence of a venous pathology that differentiates between MS patients and healthy controls (HCs), but also define its type. Moreover, the combination of different imaging techniques can influence the sensitivity and specificity of a multimodal approach to the diagnosis of CCSVI. Against this background, the purpose of our study was to investigate the frequency of CCSVI in MS patients and HCs using two non-invasive imaging techniques (DS and MRV) and to explore whether these techniques provide complementary information. We also aimed to identify whether combining the findings from DS and MRV can increase sensitivity and specificity for a diagnosis of CCSVI.

Materials and methods

Subjects and clinical assessments

This case-control study was approved by the local institutional review board (IRB) and informed consent was obtained from all subjects. The study included 171 consecutive MS patients and 79 age- and sex-matched HCs who participated in our recently published Combined Transcranial and Extracranial Venous Doppler (CTEVD) study (5) and fulfilled the following inclusion and exclusion criteria. Inclusion criteria for MS patients were: clinically definite MS (13), with a relapsing-remitting (RR), secondary-progressive (SP) or primary-progressive (PP) disease course (14); age 18-65 years; Expanded Disability Status Scale (EDSS) score of 0-6.5 (15), and a diagnostic evaluation using DS and MRV. Exclusion criteria were: a borderline finding on DS [borderline being defined as a case in which one VH criterion is fulfilled and another VH criterion is not determined for technical reasons, making a CCSVI diagnosis impossible (5) – 7 cases were excluded on this basis]; presence of relapse and steroid treatment in the 30 days preceding study entry; pre-existing medical conditions known to be associated with neck pathology; history of cerebral congenital vascular malformations, cerebral venous thrombosis, central venous catheter in the IJV; pregnancy; history of chronic obstructive pulmonary disease; and arthritic neck (the subject may not be able to lie flat).

Doppler sonography

Participants underwent extra- and transcranial DS of the head and neck performed using a color-coded DS scanner (My Lab 25, Esaote-Biosound, Bologna, Italy)

equipped with a 2.5 and 7.5-10 MHz transducer. All subjects were examined first in the supine and then in the sitting position (0° and 90° respectively) in accordance with the previously reported CCSVI protocol (1,5). The following 5 VH parameters indicative of CCSVI were investigated (Fig.s 1 and 2):

- 1) Reflux/bidirectional flow in the IJVs and/or in the vertebral veins (VVs) in sitting and in supine positions (90° and 0°), defined as flow directed toward the brain for a duration of >0.88 s;
- 2) Reflux/bidirectional flow in the deep cerebral veins (DCVs), defined as reverse flow for a duration of 0.5 s in one of the intracranial veins;
- 3) B-mode abnormalities or stenoses in IJVs, defined as cross-sectional areas (CSAs) of this vein $\leq 0.3 \text{ cm}^2$, with flaps, webs, septa, etc., in the lumen of IJVs, considered to be B-mode abnormalities significantly disturbing cerebral venous outflow;
- 4) Flow that is not Doppler-detectable in IJVs and/or VVs despite multiple deep breaths;
- 5) Reverted postural control of the main cerebral venous outflow pathway determined by measuring the difference between the CSA of the IJVs in the supine and in the upright positions. A subject was considered CCSVI-positive if ≥ 2 VH criteria were fulfilled, as previously proposed (1). The DS examination was performed by two trained technologists who were blinded to each subject's characteristics, as previously described (5). We considered using DS for visualizing collaterals; however, because of technical limits we were not able to evaluate these consistently.

In order to test the reproducibility of the CCSVI criteria, 27 subjects (20 MS patients and 7 HCs) were examined by two Doppler technologists who assessed all the subjects twice over a one-week period in a blinded manner.

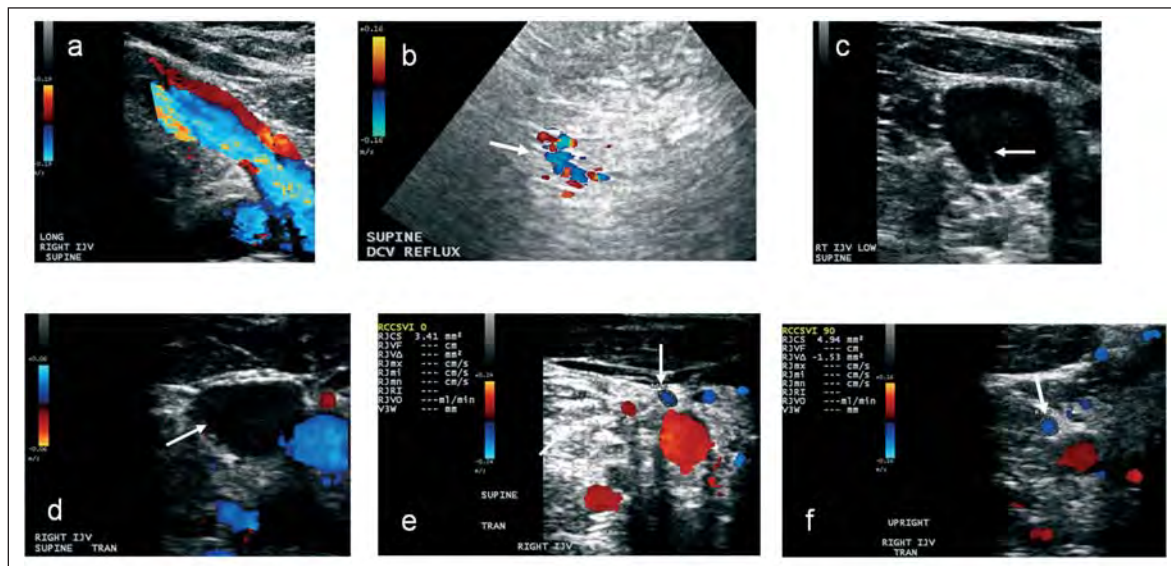


Figure 1 - Examples of positive Doppler sonography CCSVI criteria: (a) reflux/bidirectional flow directed toward the brain for a duration of >0.88 s in the supine position in the right internal jugular vein (RIJV); (b) reflux/bidirectional flow in one of the deep cerebral veins for a duration of 0.5 s; (c) septum intraluminal structural abnormality in the right internal jugular vein causing hemodynamic flow abnormality; (d) no visible flow in the RIJV in the supine position; (e and f) reverted postural control of the RIJV with negative ΔCSA .

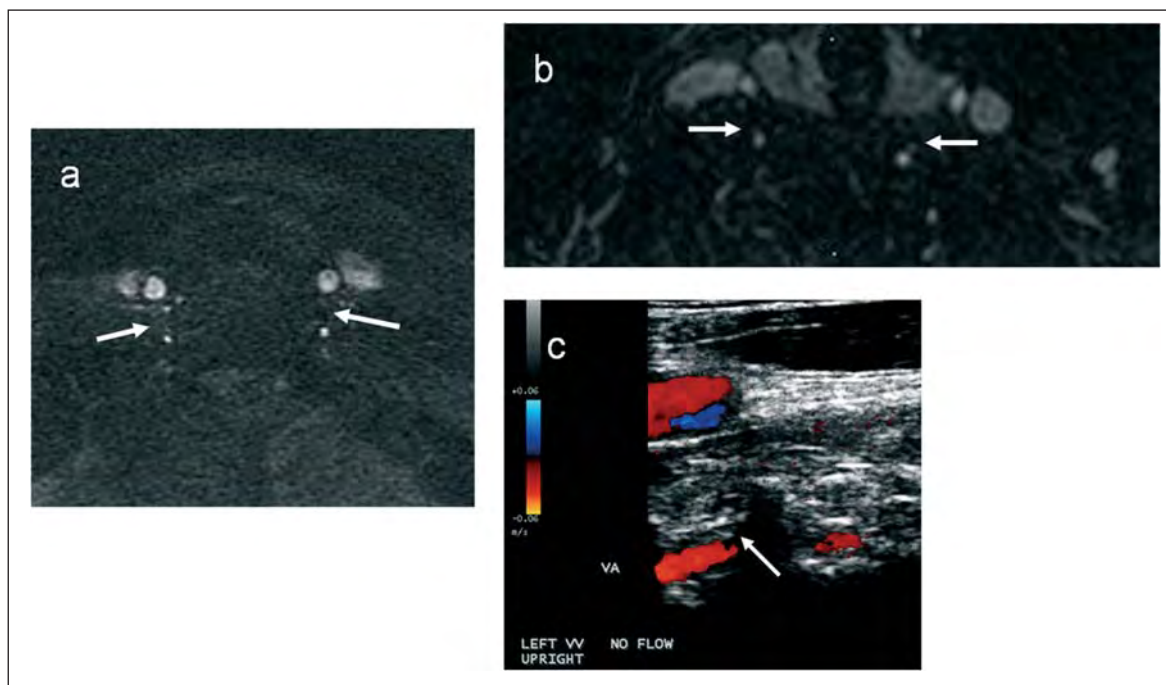


Figure 2 - Examples of vertebral vein (VV) flow abnormalities on Doppler sonography and MR venography: (a) no visible flow on axial 2D time-of-flight and (b) enhanced axial 3D time resolved imaging of contrast kinetics in both VVs; (c) no visible flow in the left VV in upright position on Doppler sonography.

Magnetic resonance venography

All the subjects were examined on a 3T GE Signa Excite HD 12.0 Twin Speed 8-channel scanner (General Electric, Milwaukee, WI). A multi-channel head and neck coil manufactured by GE was used to acquire unenhanced 2D time-of-flight (TOF) and enhanced 3D time-resolved imaging of contrast kinetics (TRICKS) sequences, as previously described (9). The parameters used for TOF were: TR/TE 17/4.3 ms (repetition/echo time), flip angle of 70 degrees, 1.5 mm slice thickness, field of view (FOV)=220 mm, acquisition matrix 320/192, phase FOV 75%, for an in-plane resolution (IPR) of 0.7 mm x 1.1 mm, and acquisition in axial scan plane. The parameters used for TRICKS were: TR/TE 4.2/1.6 ms, flip angle of 30 degrees, 2 mm slice thickness, FOV=340 mm, acquisition matrix 320/192, phase FOV 75%, IPR=1.1 mm x 1.8 mm, and acquisition in coronal scan plane. Intravenous gadolinium contrast (Omniscan®, GE Healthcare, Princeton, NJ) was injected at a rate of 2ml/s using a pressure injector followed by a 20 ml saline flush. The total volume of contrast was 20 ml. After acquisition of a 12-second mask (pre-contrast phase), the scanning of subsequent phases began simultaneously with the intravenous injection. The scan protocol consisted of 18 phases of acquisition, each of 5 seconds' duration.

Both MS patients and HCs underwent unenhanced TOF but TRICKS was performed only in the MS patients. The local IRB did not recommend participation by HCs in the contrast portion of the MRV study.

Two independent neuroradiologists (DH and KD) examined all MRI scans. Both readers had access only to the angiographic series but not to the structural MR images, and were blinded to the demographics (except date of

birth) and clinical information of all the study subjects. Scan-rescan MRV reproducibility data were previously reported (9).

The flow morphology of the IJVs was assessed on axial source TOF images, as well as on axial reconstructed TRICKS images, as previously described (9). We evaluated IJV flow on an ordinal scale ranging from absent (no visible flow) to ellipsoidal (patent lumen) and defined five qualitative flow categories: absent, pinpoint, flattened, crescentic and ellipsoidal. Only absent or pinpoint flow of the IJVs was considered to be abnormal flow (Fig. 3, over). Flow of the VVs was classified as absent/present (Fig. 2).

In this study we also assessed the prominence of the other more important veins in the neck visible on MRV, as previously described (9). These included the external jugular veins (EJVs), anterior jugular veins, facial veins, thyroid veins and deep cervical veins (Fig. 4, over). Veins were deemed prominent when their diameter was greater than 5 mm, or greater than 7 mm when considering the inferior segment of the EJVs (in accordance with the protocol used previously) (9,16). We evaluated the presence and number of collateral veins.

Multimodal imaging comparisons

In order to compare abnormal DS IJV and MRV IJV findings we considered only those VH criteria that are related to IJV pathology (positive VH criteria 1, 3, 4 and/or 5). Accordingly, the presence of at least one of the following IJV anomalies was taken to constitute an abnormal IJV exam: for DS, the presence of reflux/bidirectional flow in both sitting and supine positions, the presence of B-mode abnormalities (web, flap, membrane, mal-

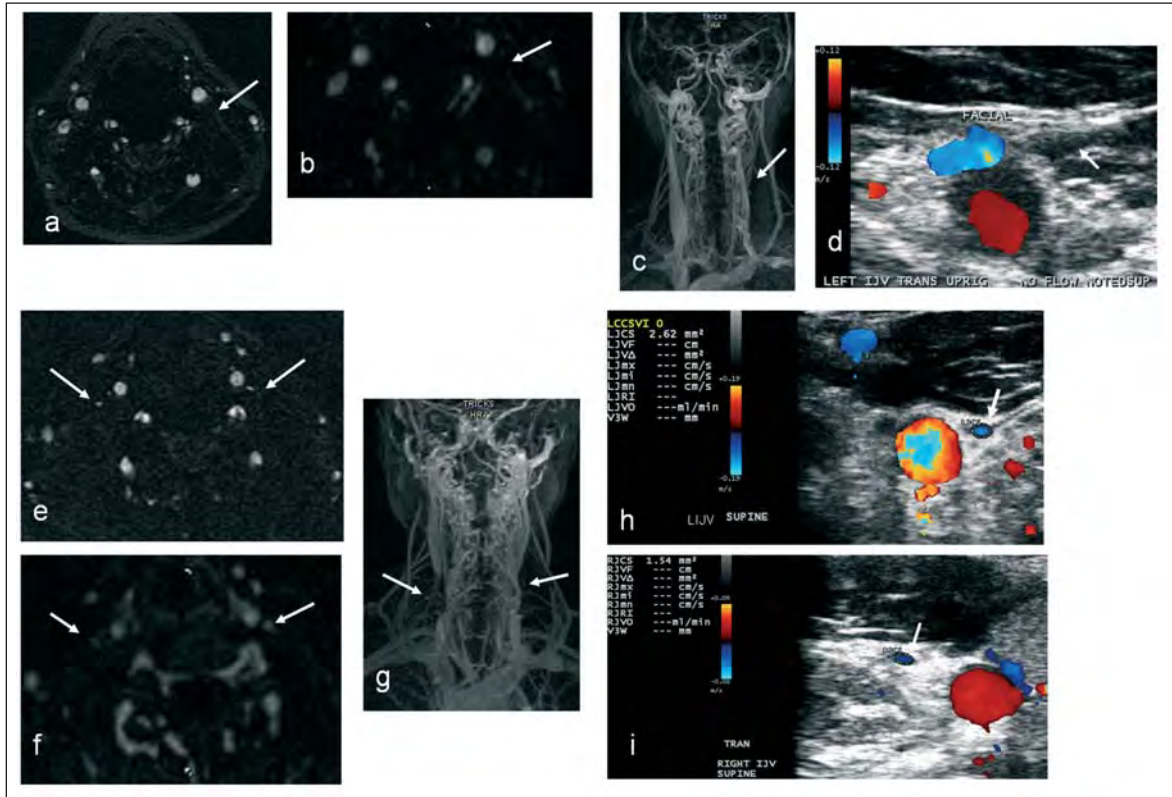


Figure 3 - Examples of abnormal internal jugular vein (IJV) flow morphology on MR venography and Doppler sonography: (a) absent flow in left IJV on axial 2D time-of-flight and (b and c) on enhanced 3D time resolved imaging of contrast kinetics, and (d) no flow in left IJV on Doppler sonography; (e) pinpoint flow morphology in both IJVs on axial 2D time-of-flight and (f and g) on enhanced 3D time resolved imaging of contrast kinetics images; (h) Doppler sonography shows reduction of lumen and flow in the left IJV and (i) right IJV.

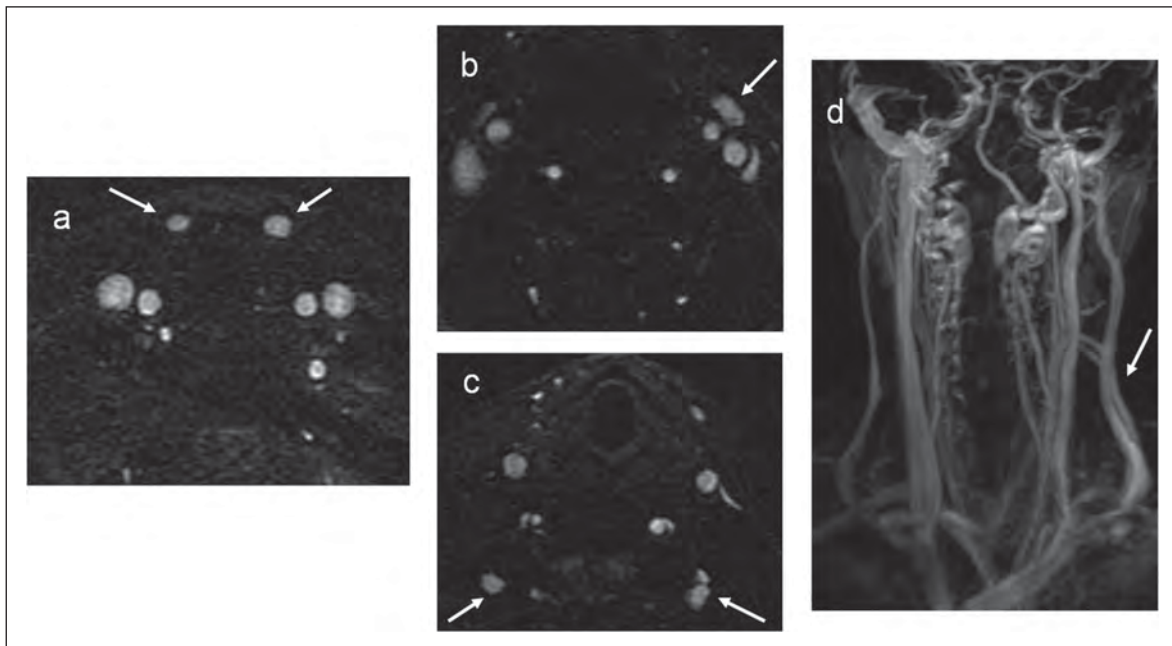


Figure 4 - Examples of prominent extracranial neck veins (collaterals) on MR venography: (a) prominent anterior jugular veins (both), (b) prominent left facial vein and (c) prominent deep cervical veins on axial 2D time-of-flight, (d) prominent left external jugular vein on enhanced 3D time resolved imaging of contrast kinetics sequence.

formed valve, septum), the presence of stenoses, the absence of detectable flow, and a negative cross-sectional area (Δ CSA); for MRV, absent or pinpoint flow.

Similar classification criteria were developed to compare abnormal DS VV and MRV VV findings. Positive VH criteria 1 and/or 4 (reflux/bidirectional flow and absence of detectable flow) were taken to constitute abnormal DS exams, while absence of flow denoted abnormal MRV (Fig. 2).

We also combined abnormal DS IJV and VV and abnormal MRV IJV and VV findings with reflux in the DCVs (positive VH criterion 2) and with the number of collateral veins to create the best combination of various imaging criteria that could potentially increase the specificity and sensitivity of the venous pathology findings in MS patients vs HCs.

Statistical analysis

Statistical analysis was performed using the Statistical Package for Social Sciences (SPSS, version 17.0). For statistics between the groups, the t-test, chi-square test and Mann-Whitney rank sum U-test were used. Prevalence rates for each of the five criteria, as well as for different CCSVI status groups, were calculated using the chi-square test. Reproducibility was calculated using Cohen's Kappa and inter-class correlation (ICC) tests. MS patients were further divided into two groups: MS non-progressive (RR) and MS progressive patients (SP and PP). Sensitivity and specificity were determined for CCSVI diagnosis, individual DS VH criteria, MRV flow findings and presence and number of collateral veins. Values were calculated separately for MS patients vs HCs, as well as progressive vs non-progressive MS patients. We determined the sensitivity and specificity between both HCs and MS patients, as well as between MS subgroups using crosstabs and direct computation from 2 x 2 contingency tables.

In order to avoid too many spurious findings due to multiple comparisons, a nominal p-value <.01 was considered as significant using two-tailed tests.

Results

Demographic and clinical characteristics

Table 1 shows the demographic, clinical and treatment characteristics of the study groups. The mean age of the MS patients was 44.5 years (SD 10.8), mean disease duration 12.7 years (SD 9.6) and median EDSS score 2.5. One hundred nineteen (69.6%) MS patients were females. HCs were age- and sex-matched to the MS patients. As expected, patients with progressive MS had significantly higher age and EDSS scores, and a longer disease duration than non-progressive MS patients (all $p < .001$).

CCSVI criteria: reproducibility results

Table 2 (over) shows the scan-rescan reproducibility data for CCSVI status and individual VH criteria. Positive CCSVI diagnostic assessment (≥ 2 fulfilled VH criteria) showed modest inter-operator agreement (Kappa 0.64). Assessments of individual VH criteria 2 and 5 showed low inter-operator agreement (Kappa 0.1 and 0.2, respectively). There was high inter-operator correlation (ICC, 0.75) for assessment of the number of VH criteria. The assessment of individual IJV and VV VH criteria also showed modest to high agreement.

CCSVI prevalence rates in the study groups

Table 3 (over) shows the prevalence rates of global and individual VH criteria indicative of CCSVI between MS patients and HCs. The prevalence of CCSVI was 64.3% for MS and 38% for HCs ($p < .001$), 58.4% for non-progressive MS patients and 75.9% for progressive MS patients ($p = .017$). The prevalence of VH criterion 3 was highest in progressive MS patients (79.3%), followed by non-progressive MS patients (63.7%) and HCs (45.6%) ($p < 0.001$). At least one positive criterion was found in 87.1% of MS patients and 72.7% of HCs.

The ≥ 1 DS VH IJV criteria prevalence rates were 78.2% for MS and 54.4% for HCs ($p < .001$), 74.3% for non progres-

Table 1 - Demographic and clinical characteristics in multiple sclerosis patients and healthy controls.

	MS (n=171)	HCs (n=79)	p	NPR-MS (n=113)	PR-MS (n=58)	p
Female gender, n (%)	119 (69.6)	48 (60.8)	NS	83 (73.5)	36 (62.1)	NS
Age in years, mean (SD)	44.5 (10.8)	43.9 (14.3)	NS	41.6 (10.3)	50.4 (9.3)	<.001
Age at onset, mean (SD)	31.6 (10.1)	–	–	32.2 (9.9)	30.6 (10.7)	NS
Disease duration, mean (SD)	12.7 (9.6)	–	–	9.7 (8.2)	18.8 (9.6)	<.001
Disease course, n (%)						
RR	113 (66.1)	–	–	113 (100)	–	–
SP	47 (27.5)	–	–	–	47 (81)	–
PP	11 (6.4)	–	–	–	11(19)	–
EDSS, mean (SD)	3.4 (2.3)	–	–	2.3 (1.5)	5.9 (1.7)	<.001
median	2.5	–	–	2.0	6.0	–

Abbreviations: MS=multiple sclerosis; HCs=healthy controls; RR=relapsing-remitting; PP=primary progressive; SP=secondary progressive; EDSS=Expanded Disability Status Scale; NS=not significant; NPR=non-progressive; PR=progressive.

Of the 171 MS patients, 121 (70.7%) were on disease-modifying therapy. These included 34 patients on glatiramer acetate, 33 on interferon-beta 1a I.M., 22 on natalizumab, 20 on interferon-beta 1a S.C. and 12 on combination therapy. The differences between the study groups were tested using the chi-square test, Student's t-test and Mann-Whitney rank sum test.

Table 2 - Intra- and inter-rater reproducibility of CCSVI criteria on Doppler sonography between two trained operators in 20 MS patients and 7 healthy controls.

Categoric variables	Operator 1		Operator 2		Operator 1 vs operator 2	
	Agreement (%)	Kappa	Agreement (%)	Kappa	Agreement (%)	Kappa
≥2 VH criteria	82.6	0.620	66.7	0.341	83.3	0.640
≥1 VH criteria	100	1	85.7	0.577	88.9	0.600
≥1 VH IJV criteria	95.6	0.893	63.6	0.170	78.9	0.513
≥1 VH VV criteria	95.6	0.862	95.2	0.889	88.9	0.753
VH criterion 1	100	1	100	1	100	N/A
VH criterion 2	86.95	0.732	81	0.538	50	0.110
VH criterion 3	100	0.911	66.7	0.310	77.8	0.538
VH criterion 4	91.3	0.744	85.7	0.690	83.3	0.649
VH criterion 5	78.3	0.493	76.2	0.146	77.8	0.200
Numeric variables		ICC		ICC		ICC
Number VH criteria	–	0.740	–	0.562	–	0.745
Number VH IJV criteria	–	0.803	–	0.447	–	0.541
Number VH VV criteria	–	0.867	–	0.894	–	0.764

Abbreviations: ICC=inter-class correlation; VH=venous hemodynamic; IJV=internal jugular vein; VV=vertebral vein.

Intra- and inter-rater reproducibility was calculated using Cohen's Kappa and inter-class correlation tests.

Table 3 - Prevalence, sensitivity and specificity of global and individual venous hemodynamic criteria in MS patients and healthy controls.

	HCs (n=79)	MS (n=171)	p ^a	Specificity	NPR-MS (n=113)	PR-MS (n=58)	p ^b	Specificity
VH criterion 1, n (%)	6 (7.6)	47 (27.5)	< .001	92.4%	32 (28.3)	15 (25.9)	.44	71.7%
VH criterion 2, n (%)	27 (34.2)	89 (52)	.006	65.8%	56 (49.6)	33 (56.9)	.23	50.1%
VH criterion 3, n (%)	36 (45.6)	118 (69)	< .001	54.4%	72 (63.7)	46 (79.3)	.026	36.3%
VH criterion 4, n (%)	15 (19)	37 (21.6)	.382	81%	21 (18.6)	16 (27.6)	.124	81.4%
VH criterion 5, n (%)	8 (10.1)	31 (18.1)	.073	89.9%	15 (13.3)	16 (27.6)	.02	86.7%
≥2 VH criteria, n (%)	30 (38)	110 (64.3)	< .001	86.8%	66 (58.4)	44 (75.9)	.017	61.1%
≥1 VH criteria, n (%)	57 (72.7)	149 (87.1)	.004	27.8%	94 (83.2)	55 (94.8)	.023	16.8%
≥1 VH IJV criteria, n (%)	43 (54.4)	133 (87.1)	< .001	45.6%	84 (74.3)	49 (84.5)	.06	25.7%
≥1 VH VV criteria, n (%)	12 (15.2)	24 (14.1)	.481	84.8%	16 (14.2)	8 (13.8)	.592	85.8%

Abbreviations: MS=multiple sclerosis patients; HCs=healthy controls; NPR=non-progressive; PR=progressive; VH=venous hemodynamic.

^a p-value for chi-square test represents comparison between HCs and MS; ^b p-value for chi-square test represents comparison between non-progressive and progressive MS patients. The sensitivity of MS vs HCs and NPR-MS vs PR-MS is represented in italics.

sive MS patients, and 84.5% for progressive MS patients (p=.06). There was no significant difference in the prevalence of ≥1 DS VH VV criteria between the study groups.

MRV findings in the internal jugular and vertebral veins

Table 4 shows MRV findings of IJV flow morphology in MS patients and HCs on TOF and TRICKS. No significant

differences were found on the IJV flow morphology scale between MS patients and HCs (p=.192), but there were significant differences between MS progressive and MS non-progressive patients on TOF (p=.01) and TRICKS (p=.003). IJV flow abnormalities were detected in 32.2% of MS patients and 24.1% of HCs on TOF (Table 5). Absent VV flow was found in 17.7% of HCs and in 13.5% of MS patients on TOF (p=.242); however, absent VV flow was found more in progressive MS patients

Table 4 - Flow morphology of internal jugular veins in multiple sclerosis patients and healthy controls on 2D time-of-flight venography and 3D time resolved imaging of contrast kinetics.

Morphology Score	TOF	TOF	TOF	TOF	TRICKS	TRICKS
	HCs (n=79)	MS (n=171)	NPR-MS (n=113)	PR-MS (n=58)	NPR-MS (n=113)	PR-MS (n=58)
Absent, n (%)	7 (8.9)	24 (14)	11 (9.7)	13 (22.4)	5 (4.4)	6 (10.7)
Pinpoint, n (%)	15 (19)	30 (17.5)	16 (14.2)	14 (24.1)	18 (15.9)	19 (33.9)
Flattened, n (%)	24 (30.4)	54 (31.6)	38 (33.6)	16 (27.6)	39 (34.5)	16 (28.6)
Crescentic, n (%)	3 (3.8)	2 (1.2)	2 (1.8)	0 (0)	2 (1.8)	2 (3.4)
Ellipsoidal, n (%)	30 (38)	61 (35.7)	46 (40.7)	15 (25.9)	45 (39.8)	15 (26.8)
	p=.192		p=.01		p=.003	

Abbreviations: MS=multiple sclerosis patients; HCs=healthy controls; NPR=non-progressive; PR=progressive; TOF=time-of-flight venography; TRICKS=time resolved imaging of contrast kinetics; n=number.

The differences on the ordinal morphological flow scale between the study groups were evaluated using the Mann-Whitney rank sum test.

Table 5 - Prevalence, sensitivity and specificity of extracranial vein flow abnormality in multiple sclerosis patients and healthy controls on 2D time-of-flight venography and 3D time resolved imaging of contrast kinetics.

	TOF	TOF	p	Speci- ficity	TOF	TOF	p	Speci- ficity	TRICKS	TRICKS	p	Speci- ficity
	HCs (n=79)	MS (n=171)			NPR-MS (n=113)	PR-MS (n=58)			NPR-MS (n=113)	PR-MS (n=58)		
Abnormal IJV flow, n (%)	19 (24.1)	55 (32.2)	.123	75.9%	29 (25.7)	26 (44.8)	.009	74.3%	23 (22.1)	25 (44.6)	.003	77.9%
Absent VV flow, n (%)	14 (17.7)	23 (13.5)	.242	82.3%	9 (8)	14 (24.1)	.004	92%	4 (3.8)	7 (12.1)	.044	96.2%
Presence of collaterals, n (%)	72 (91.1)	156 (91.2)	.576	8.9%	103 (91.2)	54 (93.1)	.602	8.8%	92 (88.5)	50 (89.3)	.55	11.5%
1 collateral	24 (30.4)	40 (23.4)		69.6%	27 (23.9)	13 (22.4)		76.1%	24 (21.2)	15 (25.9)		73.9%
2 collaterals	30 (38)	59 (34.5)		62%	40 (35.4)	19 (32.8)		32.8%	33 (29.2)	15 (25.9)		64.1%
3 collaterals	12 (15.2)	37 (21.6)		84.8%	19 (16.8)	18 (31)		83.2%	19 (16.8)	16 (27.6)		79.3%
≥4 collaterals	5 (6.3)	21 (12.3)		93.7%	17 (15)	4 (6.9)		85%	16 (14.2)	4 (6.9)		82.6%
Number of collaterals, mean (SD)	1.8 (1.1)	2.1 (1.2)	.05		2.1 (1.3)	2.1 (1.2)	.679		2.1 (1.4)	2.1 (1.3)	.783	

Abbreviations: MS=multiple sclerosis patients; HCs=healthy controls; NPR=non-progressive; PR=progressive; TOF=time-of-flight venography; TRICKS=time resolved imaging of contrast kinetics; n=number.

The frequency differences between the study groups were tested using the chi-square test, whereas the number of collaterals was tested using the Mann-Whitney rank sum test. Sensitivity of MS vs HCs and NPR-MS vs PR-MS is represented in italics.

(24.1%, $p=.004$ on TOF; and 12.1%, $p=.044$ on TRICKS) than in non-progressive patients (Table 5).

Collateral veins: MRV findings

Table 5 shows the presence and number of collateral veins in MS patients and HCs. No significant differences were found in the presence of collaterals between MS patients (91.8%) and HCs (89.8%) on TOF, or between MS non-progressive (91.2%) and progressive patients (93.1%). The TRICKS sequence also showed no difference in the presence of collaterals between MS subgroups. There was a trend toward a higher mean number of collateral veins in MS patients compared to HCs on TOF (2.1 vs 1.8, $p=.05$). There was also a trend toward a higher number of

collaterals on the right side in the MS patients than in the HCs ($p=.037$). No differences in number of collateral veins were found between progressive and non-progressive MS patients on TOF ($p=.679$) or TRICKS ($p=.886$).

Multimodal imaging findings

The presence of ≥ 2 positive DS VH criteria indicative of CCSVI showed acceptable sensitivity (64.3%) and high specificity (86.8%) for MS vs HCs, as well as between MS subgroups (sensitivity 75.9% and specificity 61.1%) (Table 3). Individual DS VH criteria 1 (92.4%), 4 (81%) and 5 (89.9%) and ≥ 1 DS VH VV criteria (84.8%) showed the highest specificity for distinguishing MS vs HCs, as well as progressive vs non-progressive MS pa-

tients. When the presence of ≥ 1 DS VH criteria was used to assess venous pathology in MS vs HCs, there emerged a high sensitivity for patients with MS (87.1%), but the specificity was low (27.8%). This pattern was also seen for progressive vs non-progressive MS patients (sensitivity of 94.8% vs specificity of 16.8%).

Although we did not find significant differences between MS patients and HCs regarding abnormal MRV IJV flow, MRV did show high diagnostic specificity in MS patients vs HCs on TOF (75.9%), as well as for distinguishing between progressive vs non-progressive MS patients on TOF (74.3%) and TRICKS (77.9%). The presence of abnormal MRV VV flow and the presence of collaterals showed even higher specificity. The presence of ≥ 4 collateral veins showed the highest diagnostic specificity for MS patients (Table 5).

When we combined ≥ 1 DS VH VV criteria and abnormal MRV VV flow, we found a high diagnostic specificity (92.4%) for MS patients vs HCs and for progressive vs non-progressive MS patients (92%) (Table 6). Specificity increased substantially when ≥ 1 DS VH IJV criteria were combined with abnormal MRV IJV flow criteria (84.8% for MS vs HCs and 76.1% for progressive vs non-progressive MS patients).

The combination of abnormal MRV IJV flow and DS VH criterion 2 and ≥ 1 collaterals also yielded high specificity for MS vs HCs (91.1%) and between MS subgroups (83.6%), while combining ≥ 1 DS VH VV criteria and DS VH criterion 2 and >1 collaterals gave even higher specificity. The highest sensitivity (38.6%) for MS was achieved by combining ≥ 1 DS VH IJV criteria and DS VH criterion 2 and >1 collaterals (Table 6).

Discussion

This study investigated the sensitivity and specificity of two non-invasive imaging techniques for the screening of CCSVI in a large cohort of MS patients and HCs. We found that ≥ 2 DS VH criteria showed high specificity, but lower sensitivity, for determining a CCSVI diagnosis in MS patients vs HCs and between MS subgroups. Indi-

vidual VH criteria 1, 4 and 5 showed high specificity for distinguishing MS patients from HCs, but also lower sensitivity. Although MRV did not show significant differences on the flow morphology scale between MS patients and HCs, it showed high specificity, but low sensitivity, for distinguishing MS patients from HCs and progressive from non-progressive MS patients, based on abnormal venous flow. Nevertheless, MRV was complementary to DS in differentiating progressive from non-progressive MS patients and in showing collaterals. Abnormal VV findings on DS and MRV showed very high specificity for distinguishing MS patients vs HCs, as did the presence of >1 collaterals on MRV, but again with low sensitivity. Most importantly, diagnostic specificity for MS patients increased to over 90% when we combined IJV and VV abnormal DS and MRV findings with positive VH criterion 2 and >1 collaterals on MRV.

From a diagnostic standpoint, one of the main criticisms of the DS criteria for CCSVI diagnosis is that these criteria are operator-dependent (5, 17, 18). A previous study showed that reproducibility of the CCSVI diagnostic criteria depends on training level (17). We recently showed modest to high intrarater agreement for establishing a CCSVI diagnosis (5). In order to provide more evidence for reproducibility of individual IJV/VV VH criteria, 20 MS patients and 7 HCs were examined one week apart by two blinded and previously trained Doppler technologists. We showed modest to high inter-rater agreement for determining a CCSVI diagnosis, as well as for the fulfillment of ≥ 1 individual DS IJV/VV VH criteria. Of the individual DS VH criteria, the most reproducible were criteria 1, 3 and 4, while criteria 2 and 5 were less reproducible. These findings suggest that global DS VH criteria for determining CCSVI diagnosis are more reproducible than individual VH criteria. Therefore, although the DS CCSVI protocol requires appropriate training before it can be applied (5, 17, 19), the inter-rater reproducibility data from the present study support its use in multi-center studies and for possible diagnostic purposes. In the present study, 64.3% of MS patients and 38% of HCs presented with ≥ 2 VH criteria and were classified as having CCSVI. CCSVI prevalence in MS patients and

Table 6 - Prevalence, sensitivity and specificity of multimodal venous hemodynamic criteria in MS patients and healthy controls that showed the highest specificity values.

Multimodal combination of criteria	Sensitivity MS vs HCs	Specificity MS vs HCs	Sensitivity NPR-MS vs PR-MS	Specificity NPR-MS vs PR-MS
≥ 1 DS VH IJV criteria and abnormal MRV IJV flow	28.7%	84.8%	37.9%	76.1%
≥ 1 DS VH VV criteria and abnormal MRV VV flow	29%	92.4%	24.1%	92%
≥ 1 DS VH IJV criteria and DS VH criterion 2 and > 1 collaterals	38.6%	81%	43.1%	63.7%
Abnormal MRV IJV flow and DS VH criterion 2 and > 1 collaterals	16.4%	91.1%	16.4%	83.6%
≥ 1 DS VH VV criteria and DS VH criterion 2 and > 1 collaterals	6.4%	94.9%	5.2%	92.9%
Abnormal MRV VV flow and DS VH criterion 2 and > 1 collaterals	5.2%	94.8%	12.1%	99.1%

Abbreviations: MS=multiple sclerosis patients; HCs=healthy controls; NPR=non-progressive; PR=progressive; VH=venous hemodynamic.

HCs was somewhat higher than reported in our recently published CTEVD study (5), but substantially lower than originally reported (for MS patients) (1). One of the exclusion criteria in the present study was a borderline finding on DS, which could have contributed to higher prevalence in the study groups. The main reason for exclusion of the 7 cases that were originally part of the CTEVD study (5) and presented with a borderline DS exam was comparison with MRV (we did not have a borderline category for MRV). The most common VH criterion in both MS patients and HCs was VH criterion 3, as in our previous study (5), which represents proximal IJV stenosis due to intraluminal abnormalities (9,10). This is also in line with our previous work where we found that the most frequent venous abnormalities in the IJVs, indicative of CCSVI, are of intraluminal origin (19). In addition, we found more MS patients fulfilling ≥ 1 DS IJV VH criteria, compared with HCs. This finding suggests that most of the venous abnormalities are localized at the IJV level. Without recourse to invasive CV exams, it is difficult to establish how much azygos vein pathology contributes to the CCSVI diagnosis (1,20). However, our VH findings in the VVs did not show a difference between the study groups.

Sensitivity and specificity data for diagnosing CCSVI with DS were substantially lower compared to the initial CCSVI study (1), but in line with our previous study (5). Although DS showed lower sensitivity, the specificity for distinguishing MS patients vs HCs was rather high when considering ≥ 2 positive VH criteria, and individual VH criteria 1, 4 and 5. The most common VH criterion both in MS patients and in HCs, as well as in the MS subgroups, was VH criterion 3, but it showed the lowest specificity in all groups. We did not use Quality Doppler Profile technology for detection of DS VH criterion 2 due to the inability of our DS scanner. This could have influenced the sensitivity and specificity results in relation to DS VH criterion 2 found in the present study. Specificity and sensitivity for differentiating progressive vs non-progressive MS patients based on individual DS VH criteria and CCSVI diagnosis were lower than the values for MS vs HCs.

In contrast to DS, MRV showed abnormal IJV flow morphology in only 32.2% of the MS subjects and 24.1% of the HCs, which is in line with several recently published small-scale MRV venous flow studies (7-9). In our previous study (9), we investigated the potential value of MRV for assessing morphology of the extracranial venous system in 57 patients with MS and 21 HCs, and found no difference between the study groups. Wattjes et al., in a group of 20 patients with definite MS and 20 age- and sex-matched HCs, analyzed intracranial and extracranial neck veins for stenosis/occlusion and alternative venous drainage patterns, and found no difference in the prevalence of venous stenoses between the MS patients and HCs (8). In another study, IJV outflow and reflux were studied in 21 MS patients and 20 HCs, and no differences between the study groups were found (7). Similarly, in our recent work that included 150 MS patients and 63 age- and sex-matched HCs, we did not find significant differences on the morphological flow MRV scale between MS patients and HCs (19). Despite the fact that head and neck veins are clearly shown using MRV, this technique does not have the resolution to visualize intraluminal abnormalities and it lacks dynamism in real time. These are the main limitations

when comparing MRV with DS, as discussed in a recent multimodal diagnostic study (10). Given that intraluminal abnormalities are the most frequent type of venous abnormality in the CCSVI criteria (1,5,6,10,19), this may further explain the discrepant results between DS (1,10) and MRV studies. However, MRV can detect the extraluminal abnormalities represented by stenoses, as shown in our recent work (19).

In the present study, significantly more progressive than non-progressive MS patients presented with MRV flow morphology abnormalities on both TOF and TRICKS. There also emerged a trend toward higher CCSVI prevalence on DS in progressive vs non-progressive MS patients, and toward higher prevalence of ≥ 1 DS VH IJV criteria in progressive MS patients. These findings suggest that progressive MS patients present with more MRV and DS venous abnormalities in their IJVs than non-progressive MS patients. This is also in line with a recent study that found significantly more extraluminal DS abnormalities and more flow abnormalities on MRV in progressive than in non-progressive MS patients (19). Further studies need to investigate whether age (progressive MS patients are generally older) or disease duration can influence the prevalence of IJV abnormalities in MS patients, as has been recently shown in elderly HCs (21,22).

Regarding sensitivity and specificity, MRV data showed high specificity for diagnosis of MS based on MRV abnormal IJV flow on TOF, as well between MS subgroups on TOF and TRICKS sequences. These findings suggest that MRV should be used as a complementary non-invasive screening tool to DS for diagnosing CCSVI, despite its lower sensitivity.

Zamboni et al. (23) proposed that extracranial venous collateral circulation in MS patients is a compensatory mechanism for impaired venous outflow, because it bypasses blocked veins and thereby reduces resistance to drainage. The present study established that MRV is more accurate than DS for obtaining a global view of the extracranial venous system. Using the TOF technique or administering intravenous contrast in the cubital vein, the global intra- and extracranial venous system can be shown non-invasively, which is not possible with CV (invasive technique) or DS (technical inability to follow the complete course of the collateral vein) (8,9). On MRV, we found that MS subjects, compared with HCs, showed a trend toward more collaterals, but collaterals were also very frequent in subjects with normal DS or MRV findings. In addition, we did not find a significant difference in the number of collaterals between non-progressive and progressive MS patients, either on the TOF or the TRICKS images, which is in line with our recent study (19). However, we found high specificity for distinguishing MS vs HCs and MS subgroups based on the number of collaterals (especially >1 collaterals) on TOF and TRICKS. Therefore, collateral veins probably represent physiological variations of the venous system that may play a compensatory role when there are more venous extracranial stenoses present.

One of the main study aims was to investigate whether the sensitivity and specificity for MS would increase by combining the DS and MRV IJV and VV abnormal findings with the presence of DS VH criterion 2 (DCV reflux) and number of collaterals. Overall, our findings show that combination of all 4 criteria (DS VH IJV, MRV IJV, DS VH criterion 2 and number of collaterals) yielded

specificity of over 85% while the sensitivity still remained between 20% and 30%. On the other hand, when we used a different combination of 4 criteria (DS VH VV, MRV VV, DS VH criterion 2 and number of collaterals) specificity was over 90% but the sensitivity dropped to less than 10%. Low sensitivity indicates that only a subpopulation of MS patients presents with a severe venous pathology. In addition, more quantitative measures for definition of venous abnormalities, such as blood flow velocity and blood volume flow on DS as well as on phase-contrast MRV could probably increase the sensitivity for assessing the degree of venous outflow obstruction in the IJVs and VVs. Future studies should also investigate whether impairment on cerebrospinal fluid hemodynamic MRI measures may increase the sensitivity and specificity of the CCSVI criteria (24).

In conclusion, despite the limitations in comparing different imaging techniques and the use of different imaging criteria, this study suggests that conventional MRV has complementary value for detection of extracranial venous anomalies, although DS is more sensitive in identifying venous abnormalities related to CCSVI in MS patients vs HCs. The study showed that use of a multimodal approach for determining the degree of extracranial venous impairment may substantially increase specificity in distinguishing MS patients from HCs, as well as between progressive vs non-progressive MS subgroups.

Acknowledgements

We thank all study subjects for their participation. We thank Eve Salczynski for technical assistance in the preparation of this manuscript.

This study was funded with internal resources of the Buffalo Neuroimaging Analysis Center and Baird MS Center, the Jacobs Neurological Institute, University of Buffalo. In addition, we received support from the Direct MS Foundation, the Jacquemin Foundation, the Bronfman Foundation and from smaller donors.

References

1. Zamboni P, Galeotti R, Menegatti E et al. Chronic cerebrospinal venous insufficiency in patients with multiple sclerosis. *J Neurol Neurosurg Psychiatry* 2009;80:392-399
2. Baracchini C, Perini P, Calabrese M, Causin F, Rinaldi F, Gallo P. No evidence of chronic cerebrospinal venous insufficiency at multiple sclerosis onset. *Ann Neurol* 2011;69:90-99
3. Doepp F, Paul F, Valdueza JM, Schmierer K, Schreiber SJ. No cerebrocervical venous congestion in patients with multiple sclerosis. *Ann Neurol* 2010;68:173-183
4. Krogias C, Schröder A, Wiendl H, Hohlfeld R, Gold R. "Chronic cerebrospinal venous insufficiency" and multiple sclerosis: critical analysis and first observation in an unselected cohort of MS patients. *Nervenarzt* 2010;81:740-746 [German]
5. Zivadinov R, Marr K, Cutter G et al. Prevalence, sensitivity, and specificity of chronic cerebrospinal venous insufficiency in MS. *Neurology* 2011;77:139-144
6. Mayer CA, Pfeilschifter W, Lorenz MW et al. The perfect crime? CCSVI not leaving a trace in MS. *J Neurol Neurosurg Psychiatry* 2011;82:436-440
7. Sundström P, Wählin A, Ambarki K et al. Venous and cere-

- brospinal fluid flow in multiple sclerosis: a case-control study. *Ann Neurol* 2010;68:255-259
8. Wattjes MP, van Oosten BW, de Graaf WL et al. No association of abnormal cranial venous drainage with multiple sclerosis: a magnetic resonance venography and flow-quantification study. *J Neurol Neurosurg Psychiatry* 2011;82:429-435
9. Zivadinov R, Lopez-Soriano A, Weinstock-Guttman B et al. Use of MR venography for characterization of the extracranial venous system in patients with multiple sclerosis and healthy control subjects. *Radiology* 2011;258:562-570
10. Zivadinov R, Galeotti R, Hojnacki D et al. Value of MR Venography for detection of internal jugular vein anomalies in multiple sclerosis: a pilot longitudinal study. *AJNR Am J Neuroradiol* 2011;32:938-946
11. Ludyga T, Kazibudski M, Simka M et al. Endovascular treatment for chronic cerebrospinal venous insufficiency: is the procedure safe? *Phlebology* 2010;25:286-295
12. Yamout B, Herlopian A, Issa Z et al. Extracranial venous stenosis is an unlikely cause of multiple sclerosis. *Mult Scler* 2010;16:1341-1348
13. Polman CH, Reingold SC, Edan G et al. Diagnostic criteria for multiple sclerosis: 2005 revisions to the "McDonald Criteria". *Ann Neurol* 2005;58:840-846
14. Lublin FD, Reingold SC. Defining the clinical course of multiple sclerosis: results of an international survey. National Multiple Sclerosis Society (USA) Advisory Committee on Clinical Trials of New Agents in Multiple Sclerosis. *Neurology* 1996;46:907-911
15. Kurtzke JF. Rating neurologic impairment in multiple sclerosis: an expanded disability status scale (EDSS). *Neurology* 1983;33:1444-1452
16. Hojnacki D, Zamboni P, Lopez-Soriano A et al. Use of neck magnetic resonance venography, Doppler sonography and selective venography for diagnosis of chronic cerebrospinal venous insufficiency: a pilot study in multiple sclerosis patients and healthy controls. *Int Angiol* 2010;29:127-139
17. Menegatti E, Genova V, Tessari M et al. The reproducibility of colour Doppler in chronic cerebrospinal venous insufficiency associated with multiple sclerosis. *Int Angiol* 2010;29:121-126
18. Simka M, Kostecki J, Zaniewski M, Hartel M. Extracranial Doppler sonographic criteria of chronic cerebrospinal venous insufficiency in the patients with multiple sclerosis. *Int Angiol* 2010;29:109-114
19. Dolic K, Marr K, Valnarov V et al. Intra- and extraluminal structural and functional venous anomalies in multiple sclerosis, as evidenced by 2 noninvasive imaging techniques. *AJNR Am J Neuroradiol* 2012;33:16-23
20. Zamboni P, Galeotti R, Menegatti E et al. A prospective open-label study of endovascular treatment of chronic cerebrospinal venous insufficiency. *J Vasc Surg* 2009;50:1348-1358.e1-3
21. Chung CP, Lin Y J, Chao AC et al. Jugular venous hemodynamic changes with aging. *Ultrasound Med Biol* 2010;36:1776-1782
22. Chung CP, Wang PN, Wu YH et al. More severe white matter changes in the elderly with jugular venous reflux. *Ann Neurol* 2011;69:553-559
23. Zamboni P, Consorti G, Galeotti R et al. Venous collateral circulation of the extracranial cerebrospinal outflow routes. *Curr Neurovasc Res* 2009;6:204-212
24. Zamboni P, Menegatti E, Weinstock-Guttman B et al. The severity of chronic cerebrospinal venous insufficiency in patients with multiple sclerosis is related to altered cerebrospinal fluid dynamics. *Funct Neurol* 2009;24:133-138

ORIGINAL
RESEARCH

K. Dolic
K. Marr
V. Valnarov
M.G. Dwyer
E. Carl
Y. Karmon
C. Kennedy
C. Brooks
C. Kilanowski
K. Hunt
A.H. Siddiqui
D. Hojnacki
B. Weinstock-Guttman
R. Zivadinov



Intra- and Extraluminal Structural and Functional Venous Anomalies in Multiple Sclerosis, as Evidenced by 2 Noninvasive Imaging Techniques

BACKGROUND AND PURPOSE: Chronic cerebrospinal venous insufficiency (CCSVI) is a vascular condition characterized by anomalies of the main extracranial cerebrospinal venous routes that interfere with normal venous outflow. Research into CCSVI will determine its sensitivity and specificity for a diagnosis of MS, its prevalence in MS patients, and its clinical, MRI, and genetic correlates. Our aim was to investigate the prevalence and number of intra- and extraluminal structural and functional extracranial venous abnormalities by using DS and MRV, in patients with MS and HCs.

MATERIALS AND METHODS: One hundred fifty patients with MS, 104 (69.3%) with RR and 46 (30.7%) with a progressive MS course, and 63 age- and sex-matched HCs were scanned with 3T MR imaging by using TOF and TRICKS sequences (only patients with MS). All subjects underwent DS examination for intra- and extraluminal structural and functional abnormalities of the IJVs. Absent/pinpoint IJV flow morphology on MRV was considered an abnormal finding. Prominence of collateral extracranial veins was assessed with MRV.

RESULTS: Patients with MS had a significantly higher number of functional ($P < .0001$), total ($P = .001$), and intraluminal ($P = .005$) structural IJV DS abnormalities than HCs. There was a trend for more patients with MS with extraluminal IJV DS abnormalities ($P = .023$). No significant differences were found on the MRV IJV flow morphology scale between patients with MS and HCs. Patients with progressive MS showed more extraluminal IJV DS abnormalities ($P = .01$) and more MRV flow abnormalities on TOF ($P = .006$) and TRICKS ($P = .01$) than patients with nonprogressive MS. There was a trend for a higher number of collateral veins in patients with MS than in HCs ($P = .016$).

CONCLUSIONS: DS is more sensitive than MRV in detecting intraluminal structural and functional venous abnormalities in patients with MS compared with HCs, whereas MRV is more sensitive in showing collaterals.

ABBREVIATIONS: CCSVI = chronic cerebrospinal venous insufficiency; CV = catheter venography; DS = Doppler sonography; EDSS = Expanded Disability Status Scale; Gd = gadolinium; HC = healthy control; ICC = interclass correlation coefficient; IJV = internal jugular vein; MRV = MR venography; PP = primary-progressive; RR = relapsing-remitting; SP = secondary-progressive; TOF = time-of-flight; TRICKS = time-resolved imaging of contrast kinetics; VV = vertebral veins

MS is an autoimmune disease of the CNS that is a result of interaction between genetic, environmental, and infectious factors.¹⁻⁴ Recently, a condition called CCSVI was found with high frequency in patients with MS.⁵ CCSVI presupposes that MS is associated with impaired venous drainage from the brain to the periphery due to venous anomalies in major extracranial neck and azygos veins.⁵

Recent studies by using extra- and transcranial DS,⁶⁻¹⁰

phase-contrast and contrast-enhanced MRV,¹¹⁻¹³ or CV^{14,15} failed to confirm the high frequency of abnormal cerebral venous outflow in patients with MS versus HCs, as originally reported.⁵

Previous CV studies in MS^{5,14-16} proposed that the extracranial venous anomalies are likely to be truncular venous malformations characterized by intraluminal defects (such as flaps, webs, septa, membranes, and malformed valves) or by extraluminal abnormalities represented by stenoses of the venous wall.

Therefore, in this study, we aimed to define the frequency of those venous abnormalities in patients with MS and HCs by using 2 noninvasive imaging techniques (DS and MRV).

Materials and Methods

Subjects and Clinical Assessments

The case-control prospective study included 150 consecutive patients with MS and 63 age- and sex-matched HCs who participated in the combined transcranial and extracranial venous Doppler study and fulfilled inclusion and exclusion criteria.⁶ The study started in April 2009 and is still enrolling subjects. Inclusion criteria for patients with

Received June 27, 2011; accepted after revision July 25.

From the Buffalo Neuroimaging Analysis Center (K.D., K.M., V.V., M.G.D., E.C., C.K., C.B., C.K., K.H., R.Z.), State University of New York, Buffalo, New York; and The Jacobs Neurological Institute (Y.K., D.H., B.W.-G., R.Z.), Department of Neurology, and Department of Neurosurgery (Y.K., A.H.S.), School of Medicine and Biomedical Sciences, Millard Fillmore Gates Hospital, Kaleida Health, University at Buffalo, State University of New York, Buffalo, New York.

Please address correspondence to Robert Zivadinov, MD, PhD, FAAN, Department of Neurology, School of Medicine and Biomedical Sciences, Buffalo Neuroimaging Analysis Center, 100 High St, Buffalo, NY 14203; e-mail: zivadinov@hotmail.com



Indicates open access to non-subscribers at www.ajnr.org



Indicates article with supplemental on-line tables.

<http://dx.doi.org/10.3174/ajnr.A2877>

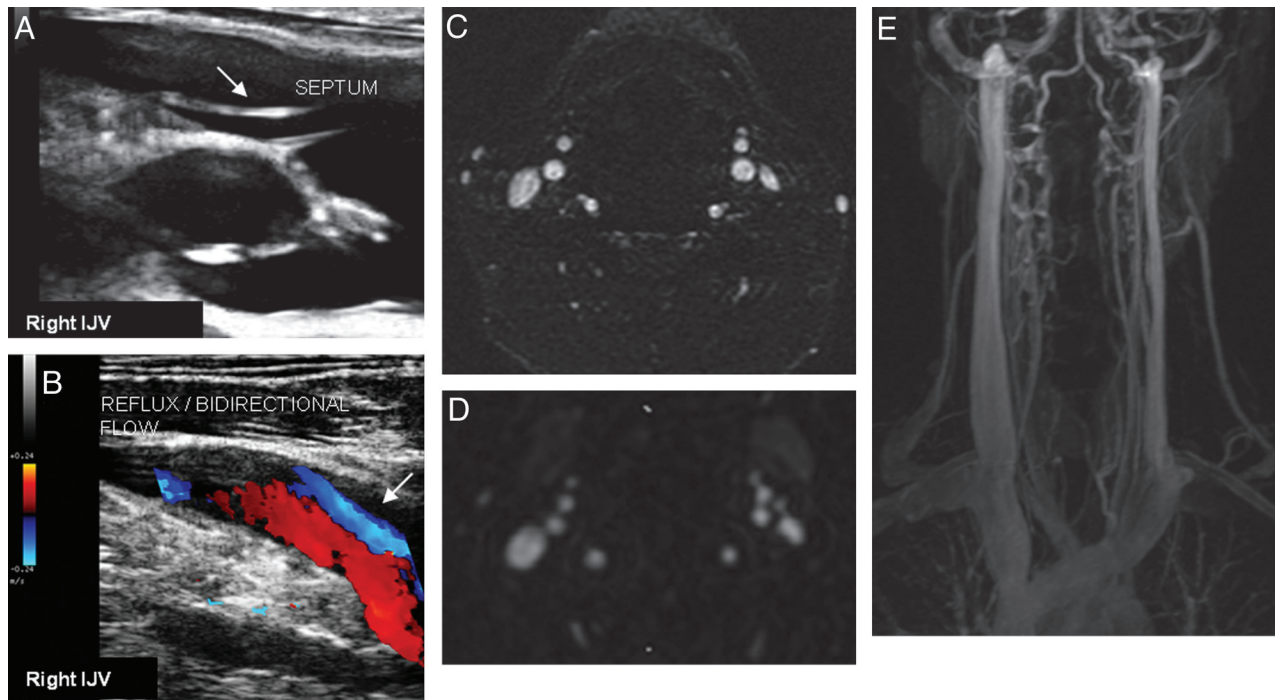


Fig 1. Intraluminal (septum, *A*) structural abnormality in the right IJV causing significant reflux/bidirectional flow directed toward the brain for a duration of >0.88 seconds in both the supine and sitting positions (*B*), as detected by using DS, in a 33-year-old woman with RRMS with 2 years of disease duration and minimal disability (EDSS score, 1.0). 2D TOF (*C*) and enhanced 3D TRICKS (*D* and *E*) sequences show normal flow morphology.

MS were clinically definite MS,¹⁷ RR-, SP-, and PPMS disease course¹⁸; 18–65 years of age; an EDSS score from 0 to 6.5¹⁹; and diagnostic evaluation for extracranial venous anomalies by using DS and MRV examinations. Exclusion criteria were occurrence of relapse and steroid treatment in the 30 days preceding study entry, pre-existing medical conditions known to be associated with neck pathology, history of cerebral congenital vascular malformations, pregnancy, contraindication for receiving Gd-based contrast agents in patients with MS, history of chronic obstructive pulmonary disease, and arthritic necks (may not be able to lie flat).⁶ The study was approved by the local institutional review board, and informed consent was obtained from all subjects.

DS

Participants underwent extracranial DS of the neck. A color-coded DS scanner (MyLab 25; Esaote-Biosound, Irvine, California) equipped with a 7.5- to 10-Mhz transducer was used to examine venous return in the IJVs and VVs. All subjects were examined first in the supine and then in the sitting position (0° and 90°). The DS examination was performed by 2 trained technologists who were blinded to subjects' characteristics, as previously described.⁶

The IJV abnormalities were divided into 3 subcategories (Figs 1–3): intraluminal structural (web, flap, septa, membrane, and malformed valve), extraluminal structural (stenosis and annulus), and functional abnormalities (presence of reflux/bidirectional flow, paradox, and no flow). The proposed classification and description of these abnormalities are given in Table 1.

Absence of detectable flow in VVs was considered abnormal and was compared with abnormal findings of VV on MRV.

To test the intra- and inter-rater reproducibility of the intra-, extraluminal, and functional venous abnormalities, 32 subjects (20 patients with MS, 7 HCs, and 5 controls with other neurologic dis-

eases) were examined by 2 Doppler technicians who assessed all subjects twice during a 1-week period in a blinded manner.⁶

All DS examinations were double-checked and confirmed by 2 independent neuroradiologists in a blinded manner (D.H. and K.D.).

MRV

All patients with MS and HCs underwent unenhanced 2D-TOF and enhanced 3D-TRICKS sequences (in patients with MS) on 3T MR imaging (Figs 1 and 3). The participation of the HCs in the contrast portion of the MRV protocol was not recommended by our institutional review board.

MRV Acquisition Protocol

All subjects were examined on a 3T Signa Excite HD 12.0 TwinSpeed 8-channel scanner (GE Healthcare, Milwaukee, Wisconsin), with a maximum slew rate of 150T/m/s and a maximum gradient amplitude in each orthogonal plane of 50 mT/m (zoom mode). A multichannel head and neck coil manufactured by GE Healthcare was used to acquire the following sequences: TOF and TRICKS MRV. The parameters used for TOF were the following: TR/TE, 17/4.3 ms; flip angle, 70°; 1.5-mm section thickness; acquisition matrix, 320/192; and acquisition in the axial scan plane. The parameters used for TRICKS were the following: TR/TE, 4.2/1.6 ms; flip angle, 30°; 2-mm section thickness; acquisition matrix, 320/192; and acquisition in the coronal scan plane. Intravenous Gd contrast was injected at a rate of 2 mL/s by using a pressure injector. The total volume of contrast was 20 mL. The scan protocol consisted of 18 phases of acquisition, each of 5 seconds' duration. The MR images were obtained from the level of the confluens sinuum to the level of the aortic arch.

The MRV analysis protocol has been previously described in detail.¹³ Briefly, the flow morphology of the IJVs was assessed on axial source TOF

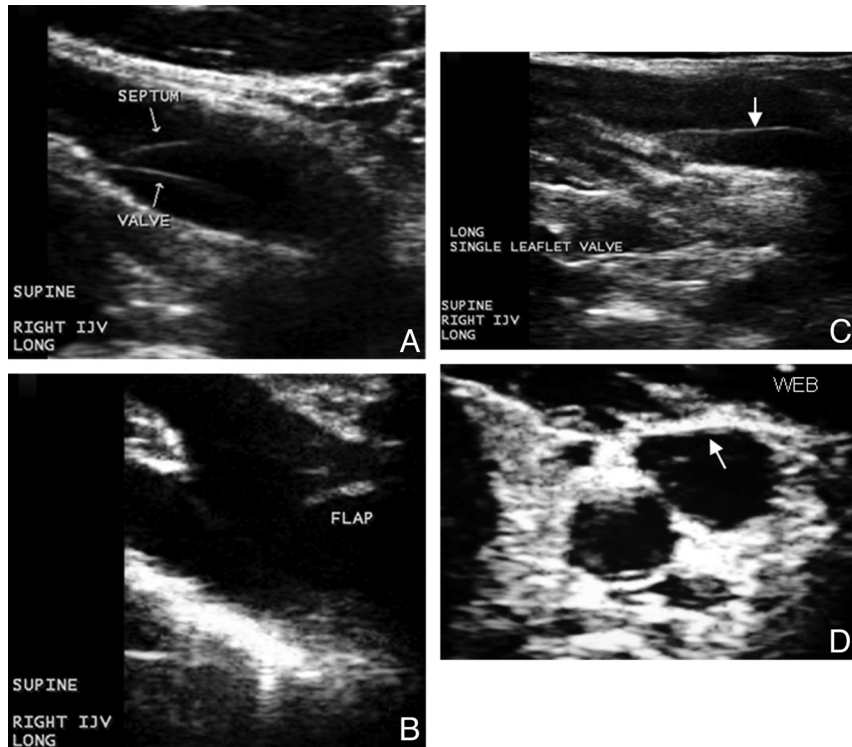


Fig 2. Examples of intraluminal structural abnormalities in the IJVs causing hemodynamic abnormality in HCs and patients with MS, 22 and 47 years of age. *A*, septum. *B*, Flap. *C*, Single leaflet valve. *D*, Web.

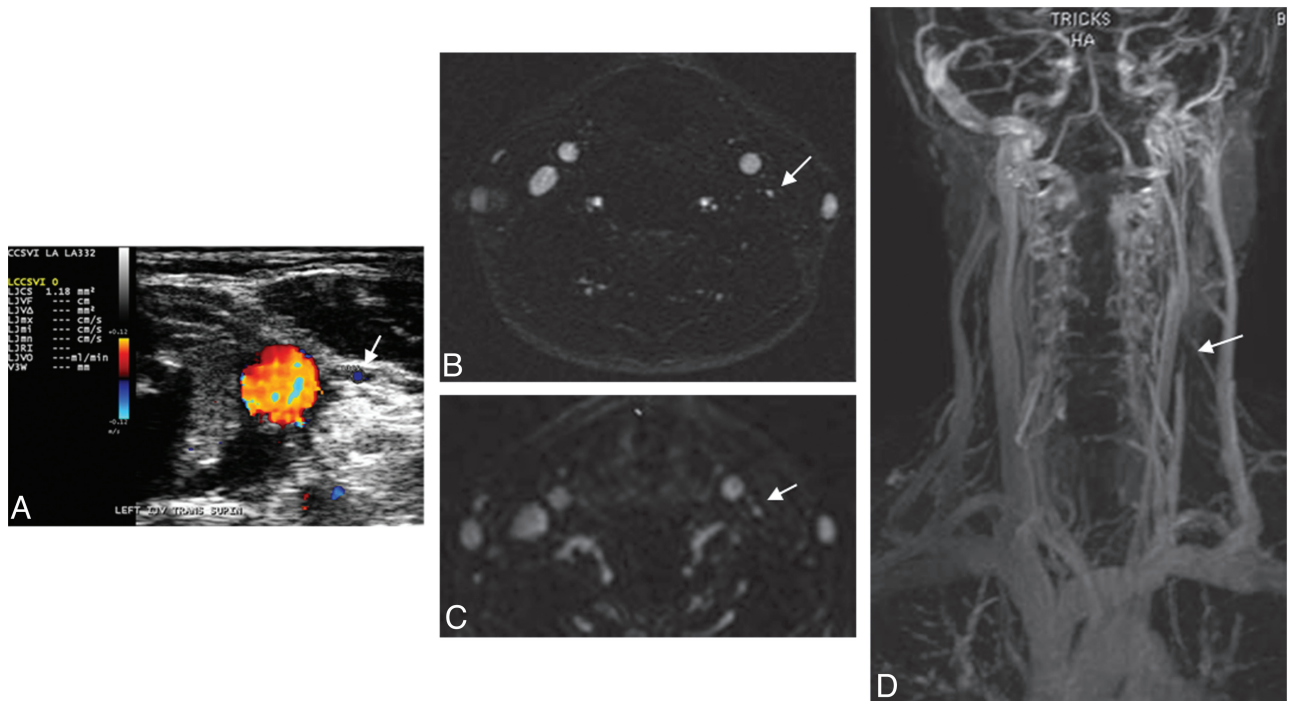


Fig 3. Extraluminal structural abnormality in the left IJV causing significantly reduced flow in both the supine and sitting positions, as detected by using DS (*A*) and MRV (*B–D*) in a 46-year-old woman with SPMS with 20 years of disease duration and advanced disability (EDSS score, 5.0). 2D TOF (*B*) and enhanced 3D TRICKS (*C* and *D*) sequences show pinpoint flow morphology.

images as well as on axial reconstructed TRICKS sections. The flow was evaluated on an ordinal scale ranging from absent (no visible flow) to ellipsoidal (patent lumen). We assigned 5 qualitative flow-morphology categories: absent, pinpoint, flattened, crescentic, and ellipsoidal.¹³ We considered only absent and pinpoint flow in the IJVs as abnormal. VV flow was classified as absent (abnormal)/present (normal).

We also assessed the left and right prominence of the other most important veins in the neck visible on MRV: external jugular veins, anterior jugular veins, facial veins, thyroid veins, and deep cervical veins, as previously reported.¹³ The prominence was graded as absent/present, and the number of collateral veins for the right and left side of the neck was also counted.

Table 1: Proposed classification of IJV abnormalities on DS

DS Classification	Types/Examples
Intraluminal structural venous abnormality; this is an echogenic structure extending from the endothelial lining of the vein wall with/without presence of functional abnormality; these abnormalities include web, flap, septum, membrane, and malformed valve	Web: multiple septa and/or flaps located in a cluster Flap: thin linear echogenic structure extending from endothelial lining of vein wall Septum: thin linear echogenic structure extending from endothelial lining of vein wall, and attached to it at both ends; septum may extend across a vein to attach on opposing sides or attach on same side Membrane: membranous structure almost occluding the entire diameter of the vein Malformed valve: dysdynamic or fibrous valve Stenosis: CSA measurement of ≤ 3 mm ² Annulus: circumferential thickened vein wall that is restricting the vein from fully expanding with respiratory or positional changes
Extraluminal structural venous abnormality; this is a restriction of the venous wall or stenosis; these abnormalities include stenosis and annulus	Reflux/bidirectional flow: present in the IJV for >0.88 seconds with the head at 90° and 0° Paradox: vein wall not reacting to respiratory phase; noncompliant No flow: no color flow noted in vein, despite deep breaths
Functional venous abnormality; this is an abnormal cerebral venous outflow in the presence of a structural venous anomaly; these abnormalities include reflux/bidirectional flow, paradox, and no flow	

Note:—CSA indicates cross-sectional area.

Table 2: Demographic and clinical characteristics in patients with MS and HCs^a

	MS (n = 150)	HC (n = 63)	P	NPRMS (n = 104)	PRMS (n = 46)	P
Female sex (No.) (%)	102 (68)	36 (57.1)	NS	73 (70.2)	29 (63)	NS
Age (yr) (mean) (SD)	43.2 (10.6)	42 (15)	NS	40.7 (10.7)	48.6 (8.2)	<.001
Age at onset, mean (SD)	31.3 (10)	—	—	31.9 (9.9)	30 (10.3)	NS
Disease duration (mean) (SD)	12.1 (9.1)	—	—	9.2 (7)	18.6 (9.9)	<.001
Disease course (No.) (%)		—				
RR	104 (70.4)			104 (100)		
SP	38 (25.3)				38 (82.6)	
PP	8 (5.3)				8 (17.4)	
EDSS (mean) (SD) (median)	3.4 (9.1) 2.5	—	—	2.5 (1.4) 2.0	5.8 (1.7) 6.0	<.001

Note:—NS indicates nonsignificant; NPR, nonprogressive; PR, progressive; —, not available.

^a The differences between the study groups were tested using the χ^2 test, Student's *t* test, and Mann-Whitney U test.

All MRV scans were examined by 2 independent neuroradiologists in a blinded manner (D.H. and K.D.). The reproducibility results were previously reported.¹³

Statistical Analyses

Statistical analysis was performed by using the Statistical Package for the Social Sciences (Version 16.0; SPS, Chicago, Illinois). For descriptive statistics and estimates of prevalence and number of venous abnormalities, *t* tests, Fisher exact tests, and the Mann-Whitney *U* tests were used. Reproducibility was calculated by using the Cohen κ and ICC tests. The relationship between different DS and MRV venous characteristics was assessed by using the Spearman rank correlation. Patients with MS were further divided into 2 groups: MS nonprogressive (RR) and MS progressive (SP and PP).

To correct for multiple comparisons, the nominal *P* value $<.01$ was considered as significant by using 2-tailed tests.

Results

Demographic and Clinical Characteristics

Table 2 shows demographic and clinical characteristics of patients with MS and HCs. As expected, patients with progressive MS had significantly higher age and EDSS scores and longer disease duration than patients with nonprogressive MS (all $P < .001$). Of the 150 patients with MS, 95 (63.3%) were on disease-modifying therapy.

Reproducibility Results

On-line Tables 1 and 2 show the intra- and inter-rater reproducibility for DS parameters. There was modest-to-high intrarater agreement for depicting total intra- and extraluminal structural and functional venous abnormalities. However, there was low-to-moderate inter-rater agreement for the assessment of intraluminal and functional venous abnormalities and modest-to-high inter-rater agreement for the assessment of the extraluminal abnormalities.

Intraluminal and Extraluminal Structural and Functional Venous Abnormalities in IJVs, as Evidenced by Doppler Sonography

Table 3 shows the individual frequency and number of intra- and extraluminal structural and functional IJV abnormalities, as evidenced by DS. Significantly more patients with MS presented with total ($P = .004$) and intraluminal ($P = .008$) structural and functional ($P = .003$) abnormalities, with a trend toward more extraluminal abnormalities compared with HCs ($P = .044$). There was a significantly higher number of total ($P = .001$) and intraluminal structural ($P = .005$) and functional abnormalities ($P < .0001$), with a trend for a higher number of extraluminal structural ($P = .023$) abnormalities in patients with MS compared with HCs. In patients with MS, there was a significant relationship between the higher number of intraluminal and functional abnormalities ($r = 0.36$,

Table 3: Intraluminal and extraluminal structural and functional venous abnormalities in IJVs in patients with MS and HCs on DS^a

Individual Frequency of Venous Abnormalities	HC	MS	P Value ^b	NPRMS	PRMS	P Value ^c
	(n = 63)	(n = 150)		(n = 104)	(n = 46)	
Total structural (No.) (%)	34 (54)	111 (74)	.004	72 (69.2)	39 (84.8)	.033
Intraluminal structural (No.) (%)	31 (49.2)	102 (68)	.008	67 (64.4)	35 (76.1)	.110
Web	0	6 (4)		5 (4.8)	1 (2.2)	
Flap	17 (27)	51 (34)		36 (34.6)	15 (32.6)	
Septum	9 (14.3)	43 (28.7)		34 (32.7)	9 (19.6)	
Membrane	0	0		0	0	
Malformed valve	18 (28.6)	40 (26.7)		25 (24)	15 (32.6)	
Extraluminal structural (No.) (%)	7 (11.1)	33 (22)	.044	17 (16.3)	16 (34.8)	.01
Stenosis	7 (11.1)	33 (22)		17 (16.3)	16 (34.8)	
Annulus	0	0		0	0	
Total functional (No.) (%)	21 (33.3)	82 (54.7)	.003	55 (52.9)	27 (58.7)	.316
Reflux	20 (31.7)	74 (49.3)		49 (47.1)	25 (54.3)	
Paradox	0	2 (1.3)		1 (1)	1 (2.2)	
No flow	2 (3.2)	16 (10.7)		8 (7.7)	8 (17.4)	
No. of venous abnormalities						
Total structural (mean) (SD)	1.05 (1.3)	1.85 (1.8)	.001	1.75 (1.7)	2.04 (1)	.384
Intraluminal structural (mean) (SD)	0.9 (1.2)	1.53 (1.7)	.005	1.5 (1.6)	1.61 (1.9)	.805
Web	0	0.07 (0.4)		0.07 (0.3)	0.09 (0.6)	
Flap	0.33 (0.6)	0.56 (1)		0.56 (1)	0.57 (1)	
Septum	0.24 (0.7)	0.55 (1)		0.57 (1)	0.5 (1.2)	
Membrane	0	0		0	0	
Malformed valve	0.35 (0.6)	0.37 (0.7)		0.33 (0.6)	0.5 (0.8)	
Extraluminal structural, (mean) (SD)	0.13 (0.5)	0.31 (0.7)	.023	0.25 (0.7)	0.43 (0.7)	.01
Stenosis	0.13 (0.5)	0.31 (0.7)		0.25 (0.7)	0.43 (0.7)	
Annulus	0	0		0	0	
Total functional (mean) (SD)	0.51 (0.9)	1.13 (1.2)	<.0001	1.02 (1.2)	1.4 (1.3)	.096
Reflux	0.44 (0.8)	0.88 (1.1)		0.85 (1.1)	0.96 (1.2)	
Paradox	0	0.02 (0.2)		0.02 (0.2)	0.02 (0.1)	
No flow	0.06 (0.6)	0.17 (0.5)		0.13 (0.5)	0.26 (0.6)	

Note:—NPR indicates nonprogressive; PR, progressive.

^a The frequency differences of the structural and functional venous abnormalities between the study groups were tested using the Fisher exact test, whereas the number of venous abnormalities differences was tested using Mann-Whitney U test.

^b P value represents comparison between HC and MS.

^c P value represents comparison between patients with NPR- and PRMS.

Table 4: Flow morphology of IJVs in patients with MS and HCs 2D-TOF using venography and 3D-TRICKS^a

Morphology Score	TOF				TRICKS	
	HC (n = 63)	MS (n = 150)	NPRMS (n = 104)	PRMS (n = 46)	NPRMS (n = 96)	PRMS (n = 44)
Absent (No.) (%)	5 (7.9)	23 (15.3)	14 (13.5)	9 (19.6)	7 (6.7)	2 (4.3)
Pinpoint (No.) (%)	12 (19)	23 (15.3)	12 (11.5)	11 (23.9)	18 (17.3)	17 (37)
Flattened (No.) (%)	18 (28.6)	50 (33.3)	33 (31.7)	17 (37)	43 (41.3)	30 (65.2)
Crescentic (No.) (%)	2 (3.2)	2 (1.3)	2 (1.9)	0 (0)	3 (2.9)	1 (2.2)
Ellipsoidal (No.) (%)	26 (41.3)	52 (34.7)	43 (41.3)	9 (19.6)	93 (89.4)	41 (89.1)
P value		.259		.006		.01

Note:—NPR indicates nonprogressive; PR, progressive.

^a The differences on the ordinal morphologic flow scale between the study groups were evaluated using the Mann-Whitney U test. Only absent and pinpoint flows in the IJVs were considered abnormal.

$P = <.0001$), extraluminal and functional abnormalities ($r = 0.29$, $P = .008$), and intraluminal and extraluminal abnormalities ($r = 0.23$, $P = .006$).

There were significantly more patients with extraluminal structural abnormalities ($P = .01$) and a higher number of extraluminal abnormalities ($P = .01$) in patients with progressive MS compared with those with nonprogressive MS. There was also a trend toward more patients with total structural abnormalities ($P = .033$). No significant differences were observed between patients with progressive and nonprogressive MS for intraluminal structural and functional abnormalities.

No significant relationship was found in patients with MS or HCs between age and sex, and the frequency and number of structural and functional IJV abnormalities, except a trend

toward greater age and a higher number of functional IJV abnormalities in patients with progressive MS ($r = 0.33$, $P = .026$).

MRV Findings in IJVs

Table 4 shows MRV findings in patients with MS and HCs on TOF and in progressive and nonprogressive MS subgroups on TOF and TRICKS MR imaging sequences. No significant differences were found on the flow-morphologic scale between patients with MS and HCs. Abnormal TOF findings (absent/pinpoint flow morphology) were found in 46 (30.7%) of the patients with MS and 17 (27%) HCs.

Significantly more abnormalities were observed on the flow-morphologic scale in patients with progressive compared

with nonprogressive MS on TOF ($P = .006$) and TRICKS ($P = .01$). In total, 20 (43.5%) patients with progressive MS had abnormal findings on TOF, and 19 (43.2%), on TRICKS. The figures were 26 (25%) in patients with nonprogressive MS for TOF and 25 (26%) for TRICKS. The relationship between TOF and TRICKS findings was highly related ($r = 0.95$, $P < .001$).

Collateral Vein Findings

There was a trend toward a higher mean number of collateral veins in patients with MS compared with HCs on TOF (2.56 versus 2.1, $P = .016$). No significant differences were observed in the number of collateral veins between patients with progressive and nonprogressive MS on TOF (2.65 versus 2.52, $P = .715$) or on TRICKS (2.57 versus 2.62, $P = .756$).

Patients with MS with a higher number of functional and intraluminal IJV DS abnormalities showed a significantly higher number of collateral veins on TRICKS ($r = 0.27$, $P = .009$ and $r = 0.23$, $P = .01$, respectively) and on TOF ($r = 0.27$, $P = .006$ and $r = 0.22$, $P = .01$, respectively).

VV Findings

There was absent flow in the VVs of 6 (9.5%) HCs and of 16 (10.7%) patients with MS on DS ($P = .932$). No significant differences were observed between patients with progressive and nonprogressive MS in VV flow on DS and MRV.

Discussion

This study investigated the intra- and extraluminal structural and functional extracranial venous abnormalities and the potential value of MRV and DS in depicting those abnormalities. Patients with MS showed a significantly higher number of total and intraluminal structural and functional abnormalities on DS compared with HCs. No differences on the morphologic MRV flow scale were found between patients with MS and HCs. Patients with progressive MS presented with significantly more extraluminal DS abnormalities and more flow abnormalities on MRV than those with nonprogressive MS.

From the time it was first mentioned, the CCSVI theory has not ceased to provoke controversy and attention in the scientific community²⁰⁻²³ and the media. The originally reported sensitivity and specificity of the CCSVI criteria for MS diagnosis⁵ were not reproduced by recent DS,⁶⁻¹⁰ MRV,¹¹⁻¹³ or CV^{14,15} studies. A major point that can explain different findings between the original and subsequent studies is that the CCSVI diagnosis is mainly based on extra- and transcranial echo-color DS criteria, which are operator-dependent and not easy to blind in a clinical setting. Moreover, the value of the CCSVI criteria is controversial because they combine functional and structural intra- and extracranial venous abnormalities in a single binary composite.²⁴ The assessment of the second CCSVI criterion (reflux in deep cerebral veins) is particularly controversial because the direction of the blood flow in veins connecting cortical with deep veins may vary considerably as a consequence of the physiologic interindividual variation of the cerebral venous anatomy.^{6,7,9,24} In addition, the value of MRV-based techniques for a diagnosis of CCSVI has not yet been completely elucidated.^{13,25} To provide better evidence on the types of venous anomalies, we focused, in this study, on the assessment of extracranial neck veins by

2 different noninvasive imaging techniques. Furthermore, we divided venous abnormalities into structural (intra- and extraluminal) and functional, to better understand their contribution to the CCSVI concept.

The DS examination showed that a substantial number of patients with MS and HCs presented with at least 1 structural venous abnormality in their IJVs. Similar results were found for the number of intraluminal abnormalities in the IJVs. More patients with MS and HCs presented with intraluminal abnormalities compared with the extraluminal ones. Of all the intraluminal abnormalities examined, the septum and flap occurred most frequently in patients with MS as well as in HCs, while no difference between the groups was found for the malformed valve (impaired mobility or thickened fibrotic valve), in line with a recent report.⁹ No membrane abnormalities were found in patients with MS and HCs.

All in all, these results suggest that the most frequent venous abnormalities in the IJVs, indicative of CCSVI, are of intraluminal origin. Although head and neck veins are clearly shown by using MRV, this technique does not have the resolution to visualize intraluminal abnormalities. This is 1 of the main limitations when comparing MRV with DS, as discussed in a recent multimodal diagnostic study.²⁵ The fact that intraluminal abnormalities present the most frequent type of venous abnormality in the CCSVI criteria^{5,6,10} can further explain the discrepant results between DS^{5,6} and MRV studies.¹¹⁻¹³ Although our intrarater reproducibility results showed modest-to-high agreement for the detection of the type and number of intraluminal abnormalities, the inter-rater agreement for these abnormalities showed low reproducibility for the detection of type and modest reproducibility for the detection of number. In the present study, the presence of intraluminal abnormalities did not imply the presence of functional abnormality or significant IJV stenosis (cross-sectional area, $\leq 0.3 \text{ cm}^2$). Therefore, the results from this study suggest that HCs also present frequently with intraluminal abnormalities, as recently reported.^{6,10} The possible origin of these abnormalities could be congenital,²⁶ aging-dependent, or a possible consequence of an inflammatory process.⁶ Therefore, further research is needed to determine whether these anomalies represent a pathologic condition or a physiologic variation.

No significant intraluminal differences were seen in patients with progressive versus nonprogressive MS, which could indicate that intraluminal abnormalities may appear earlier in the disease process. However, we found that age in patients with progressive MS correlated with the presence of DS intraluminal abnormalities. Although we did not find a relationship between age and the number of intraluminal abnormalities either in HCs or in the entire MS group, it cannot be excluded that the prevalence of these abnormalities is aging-dependent. A recent study that investigated IJV changes with aging in HCs found a decreased proportion of venous drainage and increased IJV reflux prevalence in older subjects.²⁷

In the present study, a trend toward a higher prevalence and number of extraluminal abnormalities was found in patients with MS compared with HCs on DS, whereas more patients with progressive-versus-nonprogressive MS presented with those anomalies. The presence of an annulus was not detected, contrary to previously reported results.^{5,16} Both

intra- and inter-rater reproducibility showed modest-to-high agreement for the presence and number of extraluminal abnormalities. Therefore, our reproducibility data suggest that DS evaluation of extraluminal abnormalities is less operator-dependent and could be more reliable in the evaluation of the venous anomalies in the IJVs.

On DS, patients with MS showed a significantly higher prevalence and number of functional abnormalities in the IJVs than HCs. No differences were seen between patients with progressive and nonprogressive MS. The most prevalent abnormality was reflux in patients with MS and in HCs, followed by no flow. A recent study found a strong correlation between jugular venous reflux and age-related white matter changes in elderly healthy subjects.²⁸ Although a significant relationship was found between the number of functional and the number of intra- and extraluminal abnormalities, this relationship could explain, at best, only 20% of the variance. In addition, modest-to-high intrarater agreement for the detection of type and number of functional abnormalities was not observed for inter-rater agreement. More quantitative measures for the definition of functional abnormalities such as blood flow velocity and blood volume flow could be potentially more reliable in assessing the degree of venous outflow obstruction in the IJVs.⁷

An attempt was made to distinguish intra- versus extraluminal structural and functional abnormalities in the IJVs with both MRV techniques used in this study, but ultimately, this distinction was not possible.^{13,25} Consequently, all MRV abnormalities were classified as flow abnormalities due to possible intra- or extraluminal origin. No significant differences on the morphologic flow MRV scale were found between patients with MS and HCs, in line with 3 recently published smaller scale MRV venous flow studies.¹¹⁻¹³ In a recent study,¹³ modest-to-low scan-rescan reproducibility agreement between baseline and follow-up MRV was detected. Nevertheless, we found significantly more flow abnormalities in patients with progressive versus nonprogressive MS both on TOF and TRICKS, confirming the DS extraluminal results. One of the limitations in the present study is the use of conventional MRV techniques, which are more prone to artifacts compared with other more advanced approaches.^{12,29} Although we did not perform contrast MRV sequences in HCs as recommended by our institutional review board, we showed high correlation between TOF and TRICKS in the present and previous studies.^{25,30}

In the present study, there was a trend toward a higher number of collateral veins in patients with MS compared with HCs, contrary to our previous study.¹³ Patients with MS with a higher number of DS intraluminal IJV flow abnormalities showed a significantly higher number of collateral veins on both MRV sequences. No significant difference in the number of collaterals between patients with nonprogressive versus progressive MS was found. These results indeed provide an important finding, because they support the existence of collateral circulation as a possible compensatory mechanism for the higher number of functional and intraluminal abnormalities in the IJVs, as previously proposed.^{5,16} It could be hypothesized that collaterals develop as a compensatory mechanism for the presence of intraluminal structural flow abnormalities; and when their compensatory ability is overcome, extralumi-

nal abnormalities begin to develop. This theory is supported by recent work of Yamout et al,¹⁴ who performed CV on 42 patients with MS in various phases of the disease (at onset and after 5 and 10 years) and found that extracranial venous stenosis was very rare at onset but became more frequent in subjects with longer MS duration. We considered the use of DS for visualizing collaterals; however, due to Doppler inability to follow the complete course of the collateral vein, we were unable to identify the vein with 100% accuracy. Therefore, MRV is more accurate than DS for following and labeling collaterals of the extracranial venous system. In a majority of cases, there was also a correlation between the size of the ipsilateral IJV and collateral veins, meaning that prominent collaterals followed stenotic IJVs with no visible flow. However, there were cases with normal patent IJV lumens and prominent collaterals. If the IJVs are developmentally smaller, then the other veins would likely be more prominent. Longitudinal studies should investigate the evolution of collaterals in stenotic or developmentally smaller IJVs.

We did not find VV flow differences on MRV and DS between patients with MS and HCs or between MS subgroups, which is in line with recent studies.^{13,25}

The value of DS and MRV for screening of CCSVI was tested against CV with promising results in 2 recent pilot studies that included patients with MS and HCs.^{25,30} In 1 of these studies, DS showed 82% sensitivity, 100% specificity, and 99% positive and 95% negative predictive values compared with CV in 10 patients with MS.²⁵ However, another recent study found no overlap between CV and DS in 7 of the 8 patients who presented with a sonographic finding of CCSVI.⁹ A multimodal approach by using noninvasive and invasive diagnostic techniques is recommended to determine the degree of extracranial venous structural and functional impairment in patients with MS and HCs.

One of the limits of this study is that we did not use invasive CV to confirm the DS and MRV findings. Although CV is considered the criterion standard for assessing and grading endovascular stenoses, CV is merely lumenography, providing little or no data on the wall of the vessel or its intraluminal structures. Malformed and/or reversed valve cusps can be crossed by the catheter and kept open artificially, thereby preventing documentation of stenosis.²⁴ No established criteria or guidelines currently exist on CV for the detection of venous anomalies indicative of CCSVI.²⁴ Any venous lumen reduction >50% on CV is considered a sign of significant stenosis, which is somewhat arbitrary.^{5,16} More sophisticated CV categorical criteria (ranging from grade 1 to grade 4) were recently proposed.¹⁵ Our preliminary experience with CV^{25,30} indicates that proper training is needed for recognition of pathologic intraluminal anomalies indicative of CCSVI and that more sophisticated criteria for detection of these anomalies, such as time to empty contrast from veins or waisting of the balloon, need to be tested and validated.²⁴ In addition, CV is an invasive method that requires radiation exposure, and there are ethical concerns in applying this technique to a large group of HCs.

Another limitation of our study is that we did not measure directly the venous pressures and flow patterns in the dural venous sinuses (the common pathway out of the brain before the cervical veins) to demonstrate any evidence of increased

pressure or abnormal flow patterns, such as reflux or bidirectional flow. Additionally, because there are no indications that patients with sinus thrombosis and elevated intracranial pressures or those with jugular occlusions or resections (eg, with radical neck dissections) ever develop demyelinating lesions,²⁰ our DS and MRV findings need further evaluation.

Conclusions

Despite the limitations in comparing different imaging techniques and the use of different imaging criteria, we found that conventional MRV has limited value for detection of extracranial venous anomalies compared with DS because it cannot distinguish intraluminal structural and functional venous abnormalities. However, MRV is more sensitive for showing collaterals.

Acknowledgments

We thank Eve Salczynski for technical assistance in the preparation of this manuscript.

Disclosures: Robert Zivadinov—*Related: Grant*. Direct MS Foundation,* *Unrelated: Consultancy*. Teva Neuroscience, Biogen Idec, *Grants/Grants Pending*. Teva Neuroscience, Biogen Idec, EMD Serono, Greatbatch, *Payment for Lectures (including service on Speakers Bureaus)*: Teva Neuroscience, Biogen Idec. Adnan H. Siddiqui—*Related: Grant*. National Institutes of Health (coinvestigator: National Institute of Neurological Disorders and Stroke 1R01NS064592-01A1, hemodynamic induction of pathologic remodeling leading to intracranial aneurysms), University at Buffalo (Research Development Award), *Consulting Fee or Honorarium*: Codman & Shurtleff Inc, Concentric Medical, ev3/Covidien Vascular Therapies, GuidePoint Global consulting, Penumbra, Abbott Vascular, courses for American Association of Neurological Surgeons, Genentech, Neocure Group LLC, an Emergency Medicine Conference, Abbott Vascular and Codman & Shurtleff Inc for training other neurointerventionists in carotid stenting and for training physicians in endovascular stenting for aneurysms, University of Iowa Endovascular Course, *Unrelated: Board Membership*: Codman & Shurtleff, Comments: Advisory Board; *Payment for Lectures (including service on Speakers Bureaus)*: Codman & Shurtleff Inc, Genentech; *Stock/Stock Options*: Hotspur, Intratech Medical, StimSox, Valor Medical. Bianca Weinstock-Guttman—*Unrelated: Consultancy*: Biogen Idec, Teva Neuroscience, EMD Serono, Pfizer, Acorda, *Grants/Grants Pending*: Biogen Idec,* EMD Serono,* Acorda,* Novartis,* Shire,* Teva Neuroscience,* *Payments for Lectures (including service on Speakers Bureaus)*: Biogen Idec, EMD Serono, Teva Neuroscience, Pfizer, Acorda, Novartis. *Money paid to the institution.

References

- Compston A, Coles A. Multiple sclerosis. *Lancet* 2008;372:1502–17
- Frohman EM, Racke MK, Raine CS. Multiple sclerosis: the plaque and its pathogenesis. *N Engl J Med* 2006;354:942–55
- Weinshenker BG, Bass B, Rice GP, et al. The natural history of multiple sclerosis: a geographically based study. I. Clinical course and disability. *Brain* 1989;112(pt 1):133–46
- Ascherio A, Munger KL. Environmental risk factors for multiple sclerosis. Part II. Noninfectious factors. *Ann Neurol* 2007;61:504–13
- Zamboni P, Galeotti R, Menegatti E, et al. Chronic cerebrospinal venous insufficiency in patients with multiple sclerosis. *J Neurol Neurosurg Psychiatry* 2009;80:392–99
- Zivadinov R, Marr K, Cutter G, et al. Prevalence, sensitivity, and specificity of chronic cerebrospinal venous insufficiency in MS. *Neurology* 2011;77:138–44
- Doepp F, Paul F, Valdueza JM, et al. No cerebrocervical venous congestion in patients with multiple sclerosis. *Ann Neurol* 2010;68:173–83
- Krogias C, Schroder A, Wiendl H, et al. “Chronic cerebrospinal venous insufficiency” and multiple sclerosis: critical analysis and first observation in an unselected cohort of MS patients [in German]. *Nervenarzt* 2010;81:740–46
- Baracchini C, Perini P, Calabrese M, et al. No evidence of chronic cerebrospinal venous insufficiency at multiple sclerosis onset. *Ann Neurol* 2011;69:90–99
- Mayer CA, Pfeilschifter W, Lorenz MW, et al. The perfect crime? CCSVI not leaving a trace in MS. *J Neurol Neurosurg Psychiatry* 2011;82:436–40
- Sundstrom P, Wahlin A, Ambarki K, et al. Venous and cerebrospinal fluid flow in multiple sclerosis: a case-control study. *Ann Neurol* 2010;68:255–59
- Wattjes MP, van Oosten BW, de Graaf WL, et al. No association of abnormal cranial venous drainage with multiple sclerosis: a magnetic resonance venography and flow-quantification study. *J Neurol Neurosurg Psychiatry* 2011;82:429–35
- Zivadinov R, Lopez-Soriano A, Weinstock-Guttman B, et al. Use of MR venography for characterization of the extracranial venous system in patients with multiple sclerosis and healthy control subjects. *Radiology* 2011;258:562–70
- Yamout B, Herlopian A, Issa Z, et al. Extracranial venous stenosis is an unlikely cause of multiple sclerosis. *Mult Scler* 2010;16:1341–48
- Ludyga T, Kazibudzi M, Simka M, et al. Endovascular treatment for chronic cerebrospinal venous insufficiency: is the procedure safe? *Phlebology* 2010;25:286–95
- Zamboni P, Galeotti R, Menegatti E, et al. A prospective open-label study of endovascular treatment of chronic cerebrospinal venous insufficiency. *J Vasc Surg* 2009;50:1348–58, e1–3
- Polman CH, Reingold SC, Edan G, et al. Diagnostic criteria for multiple sclerosis: 2005 revisions to the “McDonald Criteria.” *Ann Neurol* 2005;58:840–46
- Lublin FD, Reingold SC. Defining the clinical course of multiple sclerosis: results of an international survey—National Multiple Sclerosis Society (USA) Advisory Committee on Clinical Trials of New Agents in Multiple Sclerosis. *Neurology* 1996;46:907–11
- Kurtzke JF. Rating neurologic impairment in multiple sclerosis: an Expanded Disability Status Scale (EDSS). *Neurology* 1983;33:1444–52
- Khan O, Filippi M, Freedman MS, et al. Chronic cerebrospinal venous insufficiency and multiple sclerosis. *Ann Neurol* 2010;67:286–90
- Rudick RA. Multiple sclerosis: is multiple sclerosis caused by venous insufficiency? *Nat Rev Neurol* 2010;6:472–74
- Filippi M, Rocca MA, Barkhof F, et al. Multiple sclerosis and chronic cerebrospinal venous insufficiency: the neuroimaging perspective. *AJNR Am J Neuroradiol* 2011;32:424–47
- D’Haeseleer M, Cambron M, Vanopdenbosch L, et al. Vascular aspects of multiple sclerosis. *Lancet Neurol* 2011;10:657–66
- Zivadinov R, Ramanathan M, Dolic K, et al. Chronic cerebrospinal venous insufficiency in multiple sclerosis: diagnostic, pathogenetic, clinical and treatment perspectives. *Expert Rev Neurother* 2011;11:1277–94
- Zivadinov R, Galeotti R, Hojnacki D, et al. Value of MR venography for detection of internal jugular vein anomalies in multiple sclerosis: a pilot longitudinal study. *AJNR Am J Neuroradiol* 2011;32:938–46
- Lee AB, Laredo J, Neville R. Embryological background of transcranial venous malformation in the extracranial venous pathways as the cause of chronic cerebrospinal venous insufficiency. *Int Angiol* 2010;29:95–108
- Chung C, Lin Y, Chao A, et al. Jugular venous hemodynamic changes with aging. *Ultrasound Med Biol* 2010;36:1776–82
- Chung CP, Wang PN, Wu YH, et al. More severe white matter changes in the elderly with jugular venous reflux. *Ann Neurol* 2011;69:553–59
- van Amerom JF, Vidarsson L, Wu S, et al. Regional pulmonary blood flow: comparison of dynamic contrast-enhanced MR perfusion and phase-contrast MR. *Magn Reson Med* 2009;61:1249–54
- Hojnacki D, Zamboni P, Lopez-Soriano A, et al. Use of neck magnetic resonance venography, Doppler sonography and selective venography for diagnosis of chronic cerebrospinal venous insufficiency: a pilot study in multiple sclerosis patients and healthy controls. *Int Angiol* 2010;29:127–39

Heart disease, overweight, and cigarette smoking are associated with increased prevalence of extra-cranial venous abnormalities

Kresimir Dolic¹, Bianca Weinstock-Guttman², Karen Marr¹, Vesela Valnarov¹, Ellen Carl¹, Jesper Hagemeyer¹, Cheryl Kennedy¹, Colleen Kilanowski¹, David Hojnacki², Murali Ramanathan¹, Robert Zivadinov¹

¹Buffalo Neuroimaging Analysis Center, State University of New York, USA, ²The Jacobs Neurological Institute, Department of Neurology, Kaleida Health, University at Buffalo, State University of New York, USA, ³Department of Pharmaceutical Sciences, State University of New York, USA

Objectives: Most of the extra-cranial venous abnormalities have been previously described as truncular venous malformations. In this hypothesis-driven study, we evaluated possible association of risk/protective factors with the presence of truncular and functional venous abnormalities in internal jugular veins (IJVs) in a large cohort of volunteers without known central nervous system (CNS) pathology.

Methods: The study included 240 controls who underwent physical and Doppler sonography (DS) examinations for the presence of intra- and extra-luminal structural and functional abnormalities of the IJVs, and were assessed with a physical examination and structured environmental questionnaire for demographic characteristics, presence of autoimmune and other concomitant diseases, vascular risk factors, environmental factors, and habits. Logistic regression analysis was used to test which risk/protective factors were associated with the presence and number of extra-cranial venous abnormalities.

Results: Subjects with heart disease ($P < 0.001$), overweight ($P = 0.005$), and smoking ($P = 0.016$) had a significantly increased number of intra-luminal structural venous abnormalities. Presence of heart disease increased the risk of a malformed valve 12.9 times (95% CI: 5.4–31.3, $P < 0.001$), while smoking increased it 2.21 times (95% CI: 1–4.9, $P = 0.033$). Being overweight ($P = 0.003$), a history of mononucleosis ($P = 0.012$) and smoking ($P = 0.042$) increased risk for presence of a flap. No association was found between the investigated risk factors and extra-luminal or functional venous abnormalities. However, use of dietary and herbal supplements had a protective role for the presence of functional venous abnormalities.

Conclusions: There is a close association between intra-luminal, structural, extra-cranial, venous system pathology and the presence of heart disease, overweight, and smoking.

Keywords: Risk factors, Protective factors, Doppler sonography, Controls, Intra-luminal, Extra-luminal, Structural, Functional, Heart disease, Smoking, Overweight

Introduction

The main function of the venous system is to return blood to the heart from the periphery and to serve as a store of blood to maintain filling of the heart.¹ The anatomy and physiology of the peripheral venous system is well known, as well as the risk factors for developing peripheral vein disease.^{2,3} However, there is still little knowledge concerning the role of

intra- and extra-cranial venous system impairment and its complex anatomical variations.

Several studies have found a relationship between internal jugular vein (IJV) drainage abnormalities and specific neurological diseases of undetermined etiology, as well as in aging.^{4–8} However, impaired venous drainage of the central nervous system (CNS) caused by venous abnormalities that can affect functionality of extra-cranial veins has not been a subject of intense interest until recently, when condition called chronic cerebrospinal venous insufficiency (CCSVI) was described in patients with multiple sclerosis (MS).^{9,10} CCSVI is a vascular

Correspondence to: R Zivadinov, Department of Neurology, School of Medicine and Biomedical Sciences, Buffalo Neuroimaging Analysis Center, 100 High St., Buffalo, NY 14203, USA. Email: rzivadinov@bnac.net

condition characterized by impaired blood outflow from the CNS to the periphery, secondary to anatomical and functional abnormalities of the major intra- and extra-cranial veins.^{9–14}

The risk factors for increased susceptibility of venous pathology in the intra- and extra-cranial veins were unknown until our group described an association between the presence of CCSVI and risk/protective factors in a large control group of volunteers without known CNS pathology. We found that the presence of heart disease (especially heart murmurs), a history of infectious mononucleosis, and inflammatory bowel disease (IBS) were significantly associated with the presence of CCSVI, while use of dietary supplements in general, as well as ginkgo by itself, was a protective factor for this vascular condition.¹⁵

The origin of CCSVI-related venous abnormalities is a subject of intense research and debate.¹⁶ The origin of these abnormalities could be physiological, aging-dependent, congenital, a possible consequence of an inflammatory process or viral attack, immobility, and lack of exercise frequently occurring in chronic disease conditions and with aging, related to chronic pulmonary pathology such as chronic obstructive pulmonary disease and pulmonary hypertension, or related to environmental factors.^{15,16} Most of these extra-cranial venous abnormalities were described as truncular venous malformations.^{9,17–19} In a recent study, the frequency of these intra- and extra-luminal structural and functional venous abnormalities in patients with MS and healthy individuals was investigated using two non-invasive imaging techniques.¹² Doppler sonography (DS) and magnetic resonance venography revealed an increased number of intra- and extra-luminal structural and functional abnormalities in MS compared to healthy individuals.¹² That and other studies demonstrated that venous-related abnormalities are not exclusive to MS patients, and that healthy individuals or patients with other neurological diseases can also present with these anomalies of unknown origin.^{12–14,20}

Therefore, in this hypothesis-driven study, we aimed to evaluate the possible association of risk/protective factors with the presence of truncular and functional IJV abnormalities in a large cohort of volunteers without known CNS pathology. The null hypothesis was that risk factors for extra-cranial venous disease differ in subjects both with and without the presence of those venous abnormalities.

Methods

Subjects and clinical assessments

This study was approved by the local Health Sciences Institutional Review Board and was part of the prospective Combined Trans-cranial and Extra-cranial Venous Doppler study.¹³ Written informed consent was obtained from all subjects.

The study participants were 240 controls without known CNS pathology, who were selected according to the inclusion and exclusion criteria from 252 subjects who participated in a study of risk factors for CCSVI diagnosis.¹⁵ The subjects were recruited from among hospital personnel, respondents to a local newspaper advertisement, and spouses or relatives of the MS patients.¹⁵ In the previous study, no difference in prevalence of CCSVI was found between the different sources of recruitment.¹⁵

Inclusion criteria for this study were: fulfilling health screen questionnaire requirements containing information about medical history (illnesses, surgeries, medications, etc.), fulfilling the health screen requirements on physical examination, being capable of undergoing diagnostic evaluation for intra- and extra-cranial venous system using DS, and being able to respond on a structured environmental questionnaire. Exclusion criteria were: no availability of data regarding the assessment of intra- and extra-luminal venous and functional venous abnormalities, pre-existing medical conditions known to be associated with brain pathology (e.g. neurodegenerative disorder, cerebrovascular disease, cognitive impairment, history of psychiatric disorders, seizures, trauma, etc.), neck pathology, history of cerebral congenital vascular malformations, venous thrombosis, genetic thrombophilia, and presence of arthritic necks (as these subjects may not be able to lie flat).

All participants underwent physical and DS examinations, and were assessed with a structured environmental questionnaire (information related to demographic characteristics, presence of autoimmune and other concomitant diseases, vascular risk factors and environmental factors, as well as information about habits) administered in-person by a trained interviewer unaware of subjects' disease status, as previously described.¹⁵ Race/ethnicity was determined according to US Census Bureau definitions. Body mass index (BMI) was calculated and divided into four categories: underweight <18.5, normal weight 18.5–24.9, overweight 25–29.9, and obesity BMI >30 or greater.²¹

Doppler sonography

Extra-cranial DS of the neck was performed on all participants. A color-coded DS scanner (MyLab 25; Esaote-Biosound, Irvine, CA, USA) equipped with a 5.0- to 10-MHz transducer was used to examine IJV morphology and hemodynamics. The DS examination was performed by two trained technologists (KM and VV) who were blinded to subjects' characteristics, as reported.¹³ IJV abnormalities were divided into three subcategories, as recently defined¹²: (1) intra-luminal structural (web, flap, septa, membrane, and malformed valve); (2) extra-luminal structural (stenosis

and annulus); and (3) functional abnormalities (presence of reflux/bidirectional flow, non-compliant flow, and no flow). Two independent neuroradiologists double-read all DS examinations in a blinded manner (DH and KD).

Statistical analyses

Statistical analysis was performed by using the Statistical Package for the Social Sciences (Version 17.0; SPSS, Inc., Chicago, IL, USA). For descriptive statistics and estimates of prevalence and number of venous abnormalities, *t*-tests, Fisher exact tests, and the Mann–Whitney *U* tests were used.

To increase sensitivity and specificity of the study results, we took into account only those variables on a structured environmental questionnaire which had a response rate of at least 80%.

Logistic regression analysis was used to test which risk (higher frequency of association) or protective (lower frequency of association) factors were associated with the presence of venous abnormalities. The odds ratio (OR) and a 95% confidence interval (CI) were calculated. Nominal *P* value of <0.05 was considered significant using two-tailed tests.

Results

Demographic and clinical characteristics

Table 1 shows demographic and clinical characteristics of the study subjects. Twelve subjects who participated in a study of risk factors for CCSVI diagnosis¹⁵ were excluded, due to a lack of full availability of data regarding the assessment of intra- and extra-luminal structural and functional venous abnormalities. Therefore, 240 subjects were examined. The mean age of subjects was 42.5 years. One hundred and forty-four subjects were females (57.1%). The majority of participants (204) were Caucasian (88.7%), 16 (7%) were African-Americans, 10 (4.2%) were others (Asian, Hispanic/Latino), and data for 10 subjects were missing (4.2%).

Vascular risk factors (heart disease, hypertension, diabetes, obesity, smoking, and high jugular venous pressure) were present in one-third of the subjects (ranging from 31.4% to 67%), while 62% of the subjects took dietary supplements. Allergy was present in 38.5% of participants and migraine in 16.9%. More than two-thirds of subjects performed regular physical activity (ranging from daily to weekly). Only 19 subjects reported an autoimmune

Table 1 Demographic and clinical characteristics in study subjects

	Subjects, <i>n</i> (%)	Female, <i>n</i> (%)	Age (years), mean (SD)
Population	240	144 (57.1)	42.5 (15.5)
Race/ethnicity			
Caucasian	204 (88.7)	111 (86.7)	43.2 (15.7)
African-American	16 (7)	11 (8.6)	38.4 (11.3)
Other/missing	20 (8.3)	14 (9.7)	36.4 (11.5)
Vascular risk factors			
Heart disease	80 (35.9)	45 (36.9)	43.3 (15.2)
Smoking	146 (67)	81 (64.8)	43.7 (14.6)
Hypertension	64 (31.4)	29 (25.7)	48.5 (14.9)
BMI <18.5	5 (2.1)	4 (2.9)	22.8 (20.8)
BMI 18.5–24.9	74 (30.8)	45 (33.1)	39.5 (16.9)
BMI 25–29.9	84 (35)	40 (29.4)	43.5 (14.5)
BMI >30	55 (22.9)	32 (23.5)	46.3 (13.4)
Habits			
Alcohol	201 (88.2)	112 (54.9)	29.5 (21.1)
Dietary supplements	142 (62)	88 (68.2)	39 (15.4)
Herbal supplements	39 (17)	26 (20.2)	42.4 (15.9)
Physical activity	165 (72.7)	85 (67.5)	40.5 (15.9)
Autoimmune diseases			
Rheumatoid disorders	8 (3.5)	4 (3.1)	52.1 (7.1)
Psoriasis	6 (2.6)	4 (3.1)	49.2 (17.3)
Diabetes mellitus type 1	5 (2.2)	3 (2.3)	51.5 (5.2)
Other diseases			
Asthma	32 (13.9)	22 (17.1)	43.7 (16.6)
Allergy	89 (38.5)	62 (48.1)	42.5 (15.7)
Cancer	13 (5.6)	6 (4.4)	54.2 (6.4)
COPD	9 (3.9)	7 (5.4)	52 (11.9)
Irritable bowel syndrome	18 (7.8)	11 (8.5)	45.5 (12.2)
Migraine	39 (16.9)	28 (21.7)	42.08 (13.5)

Note: COPD: chronic obstructive pulmonary disease; BMI: body mass index.

BMI <18.5 represents underweight, BMI 18.5–24.9 represents normal weight, BMI 25–29.9 represents overweight, and BMI >30 represents obesity.

The various environmental factor frequencies were calculated on the total population of 240 subjects. Data for missing cases were conservatively categorized as negative.

disease. Consumption of alcohol (ranging from occasional to daily) was very frequent among participants (88.2%).

Prevalence of intra- and extra-luminal structural and functional venous abnormalities

Table 2 shows the individual frequency and number of intra- and extra-luminal structural and functional IJV abnormalities, as evidenced by DS. The most common venous abnormalities were represented by intra-luminal structural and functional abnormalities with no significant difference between gender or varied age groups. Flap, malformed valve, and septum were the most common intra-luminal structural abnormalities while reflux was found in more than one-third of the study subjects. Absent flow in the IJVs was found in only 5% of subjects. No annulus was found in any of the subjects. IJV extra-luminal stenosis was found in 12.5% of males and in 19.9% of females.

No difference in prevalence of intra- and extra-luminal structural and functional IJV abnormalities was found between different sources of recruitment. Therefore, the analyses for risk/protective factors included all participants in one group.

There was no significant relationship between age and sex, and frequency and number of any venous abnormalities.

Risk/protective factors and frequency of intra- and extra-luminal and functional venous abnormalities in the IJVs

Table 3 shows risk and protective factors that were significantly associated with the presence of intra- and extra-luminal structural and functional IJV venous abnormalities.

We did not find any risk factors associated with the presence of extra-luminal and functional venous abnormalities, while use of dietary and herbal supplements showed a lower frequency of association with functional abnormalities, suggesting a possible protective role.

Increased frequency of intra-luminal structural abnormalities was associated with presence of heart disease (OR: 3.01, 95% CI: 1.7–5.4, $P < 0.001$) and smoking (OR: 2.34, 95% CI: 1.2–4.4, $P = 0.005$). Among the intra-luminal structural venous abnormalities, the most significant associations of risk factors were found with a malformed valve. With the presence of heart disease, the risk of a malformed valve increased 12.9 times (95% CI: 5.4–31.3,

Table 2 Intra-luminal and extra-luminal structural and functional venous abnormalities in internal jugular veins in study subjects on Doppler sonography

Frequency of venous abnormalities, <i>n</i> (%)	Subjects (<i>n</i> =240)	Males (<i>n</i> =104)	Females (<i>n</i> =136)	<i>P</i> value
Total structural	103 (42.9)	47 (45.2)	56 (41.2)	0.6
Intra-luminal structural	87 (36.3)	41 (39.4)	46 (33.8)	0.41
Web	2 (0.8)	0	2 (1.5)	
Flap	46 (19.2)	25 (24)	21 (15.4)	
Septum	22 (9.2)	13 (12.5)	9 (6.6)	
Membrane	0	0	0	
Malformed valve	45 (18.8)	16 (15.4)	29 (21.3)	
Extra-luminal structural	39 (16.3)	13 (12.5)	27 (19.9)	0.16
Stenosis	39 (16.3)	13 (12.5)	27 (19.9)	
Annulus	0	0	0	
Total functional	102 (42.5)	46 (44.2)	56 (41.2)	0.73
Reflux	99 (41.3)	45 (43.3)	54 (39.7)	
Paradox	0	0	0	
No flow	11 (4.6)	5 (4.8)	6 (4.4)	
Number of venous abnormalities, mean (SD)				
Total structural	0.9 (1.2)	0.9 (1.3)	0.8 (1.1)	0.9
Intra-luminal structural	0.7 (1.08)	0.75 (1.2)	0.6 (1.01)	0.4
Web	0.01 (0.14)	0	0.02 (0.2)	
Flap	0.3 (0.6)	0.4 (0.8)	0.22 (0.5)	
Septum	0.15 (0.5)	0.22 (0.6)	0.1 (0.4)	
Membrane	0	0	0	
Malformed valve	0.24 (0.5)	0.2 (0.43)	0.3 (0.6)	
Extra-luminal structural	0.2 (0.5)	0.15 (0.5)	0.2 (0.4)	0.13
Stenosis	0.2 (0.5)	0.15 (0.5)	0.2 (0.4)	
Annulus	0	0	0	
Total functional	0.7 (1)	0.8 (1.01)	0.71 (1)	0.5
Reflux	0.7 (0.9)	0.73 (0.97)	0.65 (0.9)	
Non-compliant flow	0	0	0	
No flow	0.06 (0.3)	0.07 (0.32)	0.06 (0.3)	

Note: *n*: number.

The frequency differences of the structural and functional venous abnormalities between the gender groups were tested using the Chi-square test, whereas the number of venous abnormalities differences was tested using the Mann-Whitney rank sum test.

Table 3 Risk factors significantly associated with the presence of intra- and extra-luminal structural and functional venous abnormalities in internal jugular veins in logistic regression analysis

Venous abnormalities		Risk/protective factors	Subjects				
			n=240				
			totR/totA/tot venous abnormality	OR	95% CI	R	P
Total intra-luminal structural abnormalities	Risk factors	Heart problems	223/80/41	3.01	1.7–5.4	1.1	<.001
		Smoking	218/146/64	2.34	1.2–4.4	0.85	0.005
Malformed valve	Protective factors
	Risk factors	Heart problems	223/80/32	12.9	5.4–31.3	2.6	<0.001
Flap		Smoking	218/146/35	2.21	1–4.9	0.8	0.033
	Protective factors
Total extra-luminal abnormalities	Risk factors	Mononucleosis	225/34/12	2.8	1.3–6.3	1.03	0.012
		Smoking	218/146/34	2.1	0.9–4.7	0.75	0.042
Total functional abnormalities		BMI 25–29.9	218/84/25	2.8	1.4–5.5	1.03	0.003
	Protective factors
	Risk factors
	Protective factors
	Risk factors
	Protective factors	Dietary supplements	229/142/69	0.6	0.34–1.01	–0.53	0.037
		Herbal supplements	229/39/23	0.5	0.2–0.9	–0.7	0.027

Note: totR: total respondents on the environmental questionnaire; totA: total affected for certain condition; total venous abnormality; OR: odds ratio; CI: confidence interval; R: regression coefficient; BMI: body mass index. BMI 25–29.9 represents overweight.

$P < 0.001$), and there was also increased risk of a malformed valve with smoking (OR: 2.21, 95% CI: 1–4.9, $P = 0.033$). Further sub-analysis showed that 35.6% of subjects with a malformed valve had reflux, and 41.3% of subjects had heart problems. Smoking was the risk factor in 71.3% of controls with heart disease. Increased frequency of a flap was associated with overweight (OR: 2.8, 95% CI: 1.4–5.5, $P = 0.003$), a history of mononucleosis (OR: 2.8, 95% CI: 1.3–6.3, $P = 0.012$), and smoking (OR: 2.1, 95% CI: 1–4.9, $P = 0.042$).

Other vascular risk factors and habits, autoimmune, and other diseases, as well as aging, were not associated with increased or decreased risk for intra- and extra-luminal structural and functional venous abnormalities.

Risk/protective factors and number of intra- and extra-luminal and functional venous abnormalities in the IJVs

Table 4 shows the differences in the number of venous abnormalities and presence of risk factors. Presence of heart disease was related with an increased number of intra-luminal structural venous abnormalities ($P < 0.001$) and, in particular, a malformed valve ($P < 0.001$). Subjects who smoked had a significantly higher number of intra-luminal structural venous abnormalities ($P = 0.016$), especially a malformed valve ($P = 0.05$). There was a trend for an increased number of flaps in subjects who smoked ($P = 0.06$). Overweight was related with an increased number of flaps ($P = 0.004$) and the total number of intra-luminal structural abnormalities ($P = 0.005$).

Table 4 Risk factors significantly different with respect to the number of intra-luminal and extra-luminal structural and functional venous abnormalities in internal jugular veins

Subjects (n=240)			
Risk factors	totR/totA/tot venous abnormality	Number of abnormalities	P
Heart problems	223/80/41	Total intra-luminal structural abnormalities	<0.001
	223/80/32	Malformed valvae	<0.001
Smoking	218/146/64	Total intra-luminal structural abnormalities	0.016
	218/146/35	Malformed valvae	0.05
BMI 25–29.9	218/84/25	Flap	0.004
	218/84/38	Total intra-luminal structural abnormalities	0.005

Note: totR: total respondents on the environmental questionnaire; totA: total affected for certain condition; total venous abnormality; OR: odds ratio; CI: confidence interval; R: regression coefficient; BMI: body mass index. BMI 25–29.9 represents overweight.

Differences in the number of venous abnormalities were tested using the Mann–Whitney rank sum test.

Discussion

In this study, we investigated the relationship of demographic, clinical, and environmental risk factors and the presence of intra- and extra-luminal structural and functional IJV abnormalities in a large cohort of control subjects without known CNS pathology. Our findings showed that heart disease, being overweight, and smoking are the most common risk factors responsible for the presence of intra-luminal structural venous abnormalities, most often represented by a malformed valve and flap. We did not find any correlation between the presence of extra-luminal and functional venous abnormalities and the investigated risk factors, but we found that use of dietary and herbal supplements was a protective factor for the presence of functional venous abnormalities.

The IJVs, which are easily assessed by color-coded DS, are one of the main cerebral venous drainage pathways.^{22,23} Abnormal flow patterns in the IJVs with consequent cerebral venous outflow impairment were recently described in several neurologic disorders, including transient global amnesia,⁵ transient monocular blindness,⁶ cough headache,⁷ and primary exertional headache.⁸ From its initial discovery,^{9,10} CCSVI provoked substantial interest that led toward better understanding of the anatomy and pathology of the intra- and extra-cranial venous system.^{8,9,14,24–27}

While the etiology of peripheral chronic venous disease is relatively well known,^{28–30} there is still a lack of information about the etiology of extra-cranial venous disease. Recently published studies have proposed that extra-cranial venous anomalies are likely to be truncular venous malformations characterized by intra-luminal defects (such as flaps, webs, septa, membranes, and malformed valves) or by extra-luminal abnormalities represented by stenoses of the venous wall,^{9,18} although other hypotheses have also been proposed.^{13,15,16} Because, in a recently published study, we found that more than half of controls presented structural and more than one-third presented functional IJV abnormalities,¹² we aimed to investigate which risk factors are associated with the presence of these truncular and functional venous abnormalities in IJVs in a large cohort of controls without known CNS disease.

Increased age, female sex, and Caucasian ethnicity^{31–33} are considered the most important risk factors for venous disease.^{30,34} In the present study, we did not find any correlation between different age- and sex-, and ethnic groups regarding the presence of intra- and extra-luminal structural venous abnormalities, which is also in line with our recently published study on CCSVI risk factors.¹⁵ In addition, no relationship was found between the presence of functional venous abnormalities and investigated risk

factors, although more than one-third of subjects were positive for the presence of those abnormalities. In particular, 41.3% of the investigated cohort showed reflux in IJVs, which is in line with previously published studies that found reflux in IJVs in 20–40% of healthy individuals.^{6,23,35,36} In a study with a large sample of healthy individuals, IJV reflux was found more frequently in older subjects and in men, which was not the case in our study.³⁵

One of the most important findings of the present study is the identification of heart disease as a significant risk factor for the presence and higher number of intra-luminal structural venous abnormalities. As previously described,¹⁵ the presence of heart disease included, for this study, congestive heart failure, heart attack, arrhythmia, valvular disease, heart murmurs, enlarged heart, heart surgery, rheumatic fever, constrictive pericarditis, pulmonary hypertension, mediastinal tumor, and other. The extracellular matrix is a complex structure of collagens, elastins, laminins, fibronectins, and proteoglycans which support the cellular components of blood vessels. Matrix metalloproteinases, which are enzymes that remodel an extracellular matrix, are important in many physiological and pathological vascular processes. Dysregulation of matrix metalloproteinase activity and extracellular matrix remodeling of the vascular wall have been associated with atherosclerosis and arterial disease and, recently, also with venous disease and varicose veins.^{37–39} Hemodynamic forces, such as shear stress and increased intravascular blood pressure, strongly influence collagen metabolism through matrix metalloproteinases, which may cause vascular wall remodeling in both veins and arteries.⁴⁰ Therefore, tissue matrix alteration that is a common abnormality for heart disease and vessel structures, cannot fully be ruled out in relation to the type of venous abnormalities observed in the present study. Recent studies have also suggested that there is probably an association between venous thromboembolism of unknown origin and atherosclerosis.⁴¹ Patients with previous venous thromboembolism had an increased risk of subsequent symptomatic atherosclerosis and arterial cardiovascular events. It is assumed that this association could be due to the activation of coagulation and inflammatory pathways in both the venous and arterial systems.⁴²

One of the most striking findings in the present study was the 12.9 times increased risk for malformed valve in those who presented with heart disease. A malformed valve was the most frequent intra-luminal abnormality in the present study, which is in line with recent studies.^{9,17,35,43–45} In constrictive pericarditis and related states,⁴⁶ as well as in congestive heart disease,^{47,48} tricuspid valve regurgitation,^{47,48} and

primary pulmonary hypertension,⁴⁹ there is elevated central venous pressure which leads to IJV valve incompetency. These findings support the hypothesis that venous valve incompetence is acquired and linked to venous hypertension.⁴⁴

In the present study, we found that subjects who were smokers, either former or current, have significantly higher prevalence of intra-luminal IJV abnormalities in comparison with non-smokers. Smoking is significantly associated with lower limb venous insufficiency, in accordance with biologic data and physiopathological mechanisms.^{50,51} It is accepted that smoking is a major factor in oxidative stress,⁵² hypoxia through carbon monoxide and nitric oxide fixation to hemoglobin,⁵³ and endothelial damage. Women who smoke are at increased risk for deep vein thrombosis and the potentially deadly complication pulmonary embolism.^{50,54} In particular, smoking was related to increased frequency risk of both a malformed valve and a flap in this study. Further studies are needed to elucidate the exact mechanism responsible for the harmful effects of tobacco on the venous system.

Many risk factors for cardiovascular and thrombotic diseases are profoundly affected by diet and thus can be managed or prevented with a nutritional approach.⁵⁵ Macronutrients and other bioactive food components alter the predisposition to thrombosis and hemostasis pathways through a variety of mechanisms.⁵⁵ In the current study, we found that everyday use of dietary supplements decreases the frequency of functional IJV abnormalities. Dietary intervention has proven effective in lowering serum lipid levels, which are otherwise essential elements in the pathogenesis of cardiovascular disease. They have anti-inflammatory, anti-edema, and venotonic functions.⁵⁵⁻⁵⁸ Herbal supplements are also widely used for conservative treatment of chronic venous insufficiency because of their ability to increase the elasticity of the veins and reduce their fragility and permeability.^{58,59}

In the present study, a positive history of infective mononucleosis caused by the Epstein-Barr virus (EBV) showed significant correlation with the presence of flap abnormalities. This is in line with our previous study on risk factors of CCSVI where we found a significant association between CCSVI diagnosis and a history of mononucleosis.¹⁵ It was reported that persistent EBV infection in the vein wall may damage the venous endothelium by promoting a pro-inflammatory, pro-coagulant, and pro-atherogenic environment.^{60,61} However, further studies are needed to investigate the real mechanism by which EBV might trigger vein thrombosis.

We also found intra-luminal structural abnormalities in 42.6% of subjects who had functional IJV abnormalities, but no association was found between

the investigated risk factors and the presence of extra-luminal or functional venous abnormalities. Those results might lead to the hypothesis that functional and extra-luminal abnormalities are a secondary effect of intra-luminal structural abnormalities.¹²

We found significant association between overweight and the presence and number and of intra-luminal abnormalities in the IJVs. Obesity and overweight increase the likelihood of various diseases, particularly heart disease, type II diabetes, obstructive sleep apnea, certain types of cancer, and osteoarthritis.⁶² Various abnormalities of hemostasis have been described in obesity, mainly concerning increased levels of plasminogen activator inhibitor-1 and abnormalities of coagulation and platelet activation. Circulating microparticles have also been observed in obese patients; this suggests that obesity increases the risk for venous thromboembolism.⁶³ However, further research is necessary to fully elucidate the relationship between extra-cranial structural abnormalities and overweight, including the physical effects of body fat on limiting venous return, and promoting a pro-inflammatory, pro-thrombotic, and hypofibrinolytic milieu.

In a previous work, Lee *et al.*¹⁸ reported that extra-cranial venous abnormalities are mostly truncular (intra-luminal), which represents embryologically defective veins with no tendency for further progression. Our findings in this study firmly argue against this theory, showing that intra-luminal vein pathology is probably an acquired condition, mostly as a result of lifestyle factors and cardiovascular disease, and emphasize the role of early prevention of extra-cranial vein risk factors and possible disease-related states.

In conclusion, our study showed that there is a close association between intra-luminal, structural, extra-cranial, venous system pathology and the presence of heart disease, overweight, and smoking.

Acknowledgements

The authors thank Eve Salczynski for technical assistance in the preparation of this manuscript.

References

- Gelman S. Venous function and central venous pressure: a physiologic story. *Anesthesiology*. 2008;108(4):735-48.
- Anderson FA, Jr, Spencer FA. Risk factors for venous thromboembolism. *Circulation*. 2003;107(23 Suppl 1):I9-16.
- Antel J, Thompson A, Carroll W. Chronic cerebrospinal venous insufficiency. *Mult Scler*. 2010;16(7):770.
- Chung CP, Hsu HY, Chao AC, Chang FC, Sheng WY, Hu HH, *et al.* Detection of intracranial venous reflux in patients of transient global amnesia. *Neurology*. 2006;66(12):1873-7.
- Chung CP, Hsu HY, Chao AC, Sheng WY, Soong BW, Hu HH, *et al.* Transient global amnesia: cerebral venous outflow impairment-insight from the abnormal flow patterns of the internal jugular vein. *Ultrasound Med Biol*. 2007;33(11):1727-35.

- 6 Hsu HY, Chao AC, Chen YY, Yang FY, Chung CP, Sheng WY, *et al.* Reflux of jugular and retrobulbar venous flow in transient monocular blindness. *Ann Neurol.* 2008;63(2):247–53.
- 7 Chuang YM, Hu HH. Cough headache and thoracic inlet valvular competence in uremia. *Eur Neurol.* 2005;53(2):78–80.
- 8 Doepp F, Valdueza JM, Schreiber SJ. Incompetence of internal jugular valve in patients with primary exertional headache: a risk factor? *Cephalalgia.* 2008;28(2):182–5.
- 9 Zamboni P, Galeotti R, Menegatti E, Malagoni AM, Tacconi G, Dall'Ara S, *et al.* Chronic cerebrospinal venous insufficiency in patients with multiple sclerosis. *J Neurol Neurosurg Psychiatry.* 2009;80(4):392–9.
- 10 Zamboni P, Galeotti R, Menegatti E, Malagoni AM, Tacconi G, Dall'Ara S, *et al.* The value of cerebral Doppler venous haemodynamics in the assessment of multiple sclerosis. *J Neurol Sci.* 2009;282(1–2):21–7.
- 11 Zamboni P, Galeotti R, Menegatti E, Malagoni AM, Giancesini S, Bartolomei I, *et al.* A prospective open-label study of endovascular treatment of chronic cerebrospinal venous insufficiency. *J Vasc Surg.* 2009;50(6):1348–58.e1–3.
- 12 Dolic K, Marr K, Valnarov V, Dwyer MG, Carl E, Karmon Y, *et al.* Intra- and extraluminal structural and functional venous anomalies in multiple sclerosis, as evidenced by 2 noninvasive imaging techniques. *AJNR Am J Neuroradiol.* 2012;33(1):16–23.
- 13 Zivadinov R, Marr K, Cutter G, Ramanathan M, Benedict RH, Kennedy C, *et al.* Prevalence, sensitivity, and specificity of chronic cerebrospinal venous insufficiency in MS. *Neurology.* 2011;77(2):138–44.
- 14 Mancini M, Morra VB, Di Donato O, Maglio V, Lanzillo R, Liuzzi R, *et al.* Multiple sclerosis: cerebral circulation time. *Radiology.* 2012;262(3):947–55.
- 15 Dolic K, Weinstock-Guttman BB, Marr KK, Valnarov WV, Carl EE, Hagemeyer JJ, *et al.* Risk factors for chronic cerebrospinal venous insufficiency (CCSVI) in a large cohort of volunteers. *CORD Conf Proc.* 2011;6(11):e28062.
- 16 Zivadinov R, Ramanathan M, Dolic K, Marr K, Karmon Y, Siddiqui AH, *et al.* Chronic cerebrospinal venous insufficiency in multiple sclerosis: diagnostic, pathogenetic, clinical and treatment perspectives. *Expert Rev Neurother.* 2011;11(9):1277–94.
- 17 Al-Omari MH, Al-Bashir A. Internal jugular vein valve morphology in the patients with chronic cerebrospinal venous insufficiency (CCSVI): angiographic findings and schematic demonstrations. *Rev Recent Clin Trials.* 2012;7(2):83–7.
- 18 Lee AB, Laredo J, Neville R. Embryological background of truncular venous malformation in the extracranial venous pathways as the cause of chronic cerebro spinal venous insufficiency. *Int Angiol.* 2010;29(2):95–108.
- 19 Ludyga T, Kazibudzi M, Simka M, Hartel M, Swierad M, Piegza J, *et al.* Endovascular treatment for chronic cerebrospinal venous insufficiency: is the procedure safe? *Phlebology.* 2010;25(6):286–95.
- 20 Monti L, Menci E, Olivelli M, Cerase A, Bartalini S, Piu P, *et al.* Quantitative colour doppler sonography evaluation of cerebral venous outflow: a comparative study between patients with multiple sclerosis and controls. *PLoS ONE.* 2011;6(9):e25012.
- 21 WHO. Technical report series 894: obesity: preventing and managing the global epidemic. Geneva: World Health Organization; 2000.
- 22 Ayanzen RH, Bird CR, Keller PJ, McCully FJ, Theobald MR, Heiserman JE. Cerebral MR venography: normal anatomy and potential diagnostic pitfalls. *AJNR Am J Neuroradiol.* 2000;21(1):74–8.
- 23 Chung CP, Hsu HY, Chao AC, Cheng CY, Hu HH. Jugular venous hemodynamic changes with aging. *Ultrasound Med Biol.* 2010;36(11):1776–82.
- 24 Qiu J. Venous abnormalities and multiple sclerosis: another breakthrough claim? *Lancet Neurol.* 2010;9(5):464–5.
- 25 Wattjes MP, van Oosten BW, de Graaf WL, Seewann A, Bot JC, van den Berg R, *et al.* No association of abnormal cranial venous drainage with multiple sclerosis: a magnetic resonance venography and flow-quantification study. *J Neurol Neurosurg Psychiatry.* 2010;82:429–35.
- 26 Yamout B, Herlopian A, Issa Z, Habib RH, Fawaz A, Salame J, *et al.* Extracranial venous stenosis is an unlikely cause of multiple sclerosis. *Mult Scler.* 2010;16(11):1341–8.
- 27 Zivadinov R, Lopez-Soriano A, Weinstock-Guttman B, Schirda CV, Magnano CR, Dolic K, *et al.* Use of MR venography for characterization of the extracranial venous system in patients with multiple sclerosis and healthy control subjects. *Radiology.* 2011;258(2):562–70.
- 28 Criqui MH, Denenberg JO, Bergan J, Langer RD, Fronck A. Risk factors for chronic venous disease: the San Diego Population Study. *J Vasc Surg.* 2007;46(2):331–7.
- 29 Eberhardt RT, Raffetto JD. Chronic venous insufficiency. *Circulation.* 2005;111(18):2398–409.
- 30 Evans CJ, Fowkes FG, Ruckley CV, Lee AJ. Prevalence of varicose veins and chronic venous insufficiency in men and women in the general population: Edinburgh Vein Study. *J Epidemiol Community Health.* 1999;53(3):149–53.
- 31 White RH. The epidemiology of venous thromboembolism. *Circulation.* 2003;107(23 Suppl 1):14–8.
- 32 Dowling NF, Austin H, Dilley A, Whitsett C, Evatt BL, Hooper WC. The epidemiology of venous thromboembolism in Caucasians and African-Americans: the GATE Study. *J Thromb Haemost.* 2003;1(1):80–7.
- 33 White RH, Keenan CR. Effects of race and ethnicity on the incidence of venous thromboembolism. *Thromb Res.* 2009;123(Suppl 4):S11–7.
- 34 Fowkes FG, Evans CJ, Lee AJ. Prevalence and risk factors of chronic venous insufficiency. *Angiology.* 2001;52(Suppl 1):S5–15.
- 35 Akkawi NM, Agosti C, Borroni B, Rozzini L, Magoni M, Vignolo LA, *et al.* Jugular valve incompetence: a study using air contrast ultrasonography on a general population. *J Ultrasound Med.* 2002;21:747–51.
- 36 Silva MA, Deen KI, Fernando DJ, Sheriffdeen AH. The internal jugular vein valve may have a significant role in the prevention of venous reflux: evidence from live and cadaveric human subjects. *Clin Physiol Funct Imaging.* 2002;22(3):202–5.
- 37 Jacob MP, Badier-Commander C, Fontaine V, Benazzoug Y, Feldman L, Michel JB, *et al.* Extracellular matrix remodeling in the vascular wall. *Pathol Biol (Paris).* 2001;49(4):326–32.
- 38 Lijnen HR. Metalloproteinases in development and progression of vascular disease. *Pathophysiol Haemost Thromb.* 2003;33(5–6):275–81.
- 39 Makivaara LA, Ahti TM, Luukkaala T, Hakama M, Laurikka JO. Arterial disease but not hypertension predisposes to varicose veins. *Phlebology.* 2008;23(3):142–6.
- 40 Ishikawa Y, Asuwa N, Ishii T, Ito K, Akasaka Y, Masuda T, *et al.* Collagen alteration in vascular remodeling by hemodynamic factors. *Virchows Arch.* 2000;437(2):138–48.
- 41 Prandoni P. Links between arterial and venous disease. *J Intern Med.* 2007;262(3):341–50.
- 42 Prandoni P. Risk factors of recurrent venous thromboembolism: the role of residual vein thrombosis. *Pathophysiol Haemost Thromb.* 2003;33(5–6):351–3.
- 43 Lepori D, Papasso P, Fournier D, Genton CY, Schynder P. High-resolution ultrasound evaluation of internal jugular venous valves. *Eur Radiol.* 1999;9(6):1222–6.
- 44 Takase S, Pascarella L, Bergan JJ, Schmid-Schönbein GW. Hypertension-induced venous valve remodeling. *J Vasc Surg.* 2004;39(6):1329–34.
- 45 Chung CP, Hu HH. Jugular venous reflux. *J Med Ultrasound.* 2008;16:210–22.
- 46 Benchimol A, Tippit HC. The clinical value of the jugular and hepatic pulses. *Prog Cardiovasc Dis.* 1967;10(2):159–86.
- 47 Dresser LP, McKinney WM. Anatomic and pathophysiologic studies of the human internal jugular valve. *Am J Surg.* 1987;154(2):220–4.
- 48 Fisher J, Vaghaiwalla F, Tsitlik J, Levin H, Brinker J, Weisfeldt M, *et al.* Determinants and clinical significance of jugular venous valve competence. *Circulation.* 1982;65(1):188–96.
- 49 Doepp F, Würfel JT, Pfueller CF, Valdueza JM, Petersen D, Paul F, *et al.* Internal jugular vein valve incompetence in COPD and primary pulmonary hypertension. *J Clin Ultrasound.* 2008;36(8):480–4.
- 50 Lindqvist PG, Epstein E, Olsson H. The relationship between lifestyle factors and venous thromboembolism among women: a report from the MISS study. *Br J Haematol.* 2009;144(2):234–40.
- 51 Pomp ER, Rosendaal FR, Doggen CJ. Smoking increases the risk of venous thrombosis and acts synergistically with oral contraceptive use. *Am J Hematol.* 2008;83(2):97–102.
- 52 Morrow JD, Frei B, Longmire AW, Gaziano JM, Lynch SM, Shyr Y, *et al.* Increase in circulating products of lipid peroxidation (F2-isoprostanes) in smokers. Smoking as a cause of oxidative damage. *N Engl J Med.* 1995;332(18):1198–203.

- 53 Hickey RJ, Clelland RC, Boyce DE. Carbon monoxide: smoking, air pollution, cardiovascular disease, and physiological homeostasis. *Lancet*. 1973;2(7828):571–2.
- 54 Petitti DB, Wingerd J, Pellegrin F, Ramcharan S. Risk of vascular disease in women. Smoking, oral contraceptives, noncontraceptive estrogens, and other factors. *JAMA*. 1979;242(11):1150–4.
- 55 Phang SL, Wood LG, Garg M. Diet and thrombosis risk: nutrients for prevention of thrombotic disease. *Semin Thromb Hemost*. 2011;37(3):199–208.
- 56 Clarke R, Armitage J. Vitamin supplements and cardiovascular risk: review of the randomized trials of homocysteine-lowering vitamin supplements. *Semin Thromb Hemost*. 2000;26(3):341–8.
- 57 Jones W, Li X, Qu ZC, Perriott L, Whitesell RR, May JM. Uptake, recycling, and antioxidant actions of alpha-lipoic acid in endothelial cells. *Free Radic Biol Med*. 2002;33(1):83–93.
- 58 Pittler MH, Ernst E. Horse-chestnut seed extract for chronic venous insufficiency. A criteria-based systematic review. *Arch Dermatol*. 1998;134(11):1356–60.
- 59 Tsuruda T. Herbal dietary supplement: continuing to explore cardiovascular protection. *Cardiovasc Res*. 2010;88(3):387–8.
- 60 Mashav N, Mashav N, Saar N, Chundadze T, Steinvil A, Justo D. Epstein–Barr virus-associated venous thromboembolism: a case report and review of the literature. *Thromb Res*. 2008;122(4):570–1.
- 61 Dalpke AH, Thomssen R, Ritter K. Oxidative injury to endothelial cells due to Epstein–Barr virus-induced autoantibodies against manganese superoxide dismutase. *J Med Virol*. 2003;71(3):408–16.
- 62 Marinou K, Tousoulis D, Antonopoulos AS, Stefanadi E, Stefanadis C. Obesity and cardiovascular disease: from pathophysiology to risk stratification. *Int J Cardiol*. 2010;138(1):3–8.
- 63 Allman-Farinelli MA. Obesity and venous thrombosis: a review. *Semin Thromb Hemost*. 2011;37(8):903–7.

1

Authors Queries

Journal: **Neurological Research**

Paper: **2901**

Title: **Heart disease, overweight, and cigarette smoking are associated with increased prevalence of extra-cranial venous abnormalities**

Dear Author

During the preparation of your manuscript for publication, the questions listed below have arisen. Please attend to these matters and return this form with your proof. Many thanks for your assistance

Query Reference	Query	Remarks
1	Ref. 56 is the same as Ref. 55, so it is removed and Refs. 57–64 are renumbered accordingly, please confirm the changes are correct.	