

# Utjecaj načina zatvaranja operacijske rane pri dekompresiji karpalnog tunela na funkcionalne, neurološke i estetske ishode te na kvalitetu života: prospektivno randomizirano kliničko istraživanje

---

Šunjić Roguljić, Veridijana

Doctoral thesis / Disertacija

2025

Degree Grantor / Ustanova koja je dodijelila akademski / stručni stupanj: **University of Split, School of Medicine / Sveučilište u Splitu, Medicinski fakultet**

Permanent link / Trajna poveznica: <https://urn.nsk.hr/urn:nbn:hr:171:937285>

Rights / Prava: [In copyright](#)/[Zaštićeno autorskim pravom.](#)

Download date / Datum preuzimanja: **2025-02-21**



Repository / Repozitorij:

[MEFST Repository](#)



**SVEUČILIŠTE U SPLITU  
MEDICINSKI FAKULTET**

**VERIDIJANA ŠUNJIĆ ROGULJIĆ**

**UTJECAJ NAČINA ZATVARANJA OPERACIJSKE RANE PRI  
DEKOMPRESIJI KARPALNOG TUNELA NA FUNKCIONALNE,  
NEUROLOŠKE I ESTETSKE ISHODE TE NA KVALITETU  
ŽIVOTA: PROSPEKTIVNO RANDOMIZIRANO  
KLINIČKO ISPITIVANJE**

**DOKTORSKI RAD**

**Mentor: prof. dr. sc. prim. Vedran Kovačić, dr. med.**

**Split, 2025.**

## ZAHVALA

Zahvaljujem se mojem mentoru i uzoru u znanosti, prof. dr. sc. prim. Vedranu Kovačiću, na svesrdnoj pomoći bez koje ovaj doktorat ne bi bio moguć.

Neizmjereno zahvaljujem prijateljici, doc. dr. sc. prim. Ivani Jukić na potpori, razumijevanju i strpljenju tijekom pripremanja, izrade i pisanja ove doktorske radnje.

Zahvaljujem kolegama i medicinskim sestrama sa Zavoda za plastičnu, estetsku, rekonstrukcijsku kirurgiju i opeklina Klinike za kirurgiju i Klinike za neurologiju na pomoći prilikom izrade doktorske dizertacije, a posebno izv. prof. dr. sc. prim. Ivici Biliću na potpori i prijateljstvu tijekom stvaranja ove doktorske disertacije.

Posebno zahvaljujem suprugu Luki na ideji, kao i kćerkama Petri i Amneris na motivaciji, lijepim riječima i potpori u pisanju doktorata.

Ovaj rad posvećujem uspomeni na moju baku Ljubicu Čatipović.

## SADRŽAJ

|  |           |
|--|-----------|
| <b>1. UVOD</b> .....   | 1         |
| 1.1. Sindrom karpalnog tunela .....  | 2         |
| 1.2. Sindrom karpalnog tunela tijekom povijesti .....  | 3         |
| 1.3. Anatomija i anatomske odnose karpalnog tunela .....   | 3         |
| 1.4. Epidemiologija sindroma karpalnog tunela.....   | 6         |
| 1.5. Etiologija i čimbenici rizika za razvoj sindroma karpalnog tunela .....   | 7         |
| 1.6. Patogeneza sindroma karpalnog tunela .....  | 9         |
| 1.7. Dijagnostika sindroma karpalnog tunela i procjena težine stanja .....   | 10        |
| 1.8. Klinički oblici sindroma karpalnog tunela .....   | 12        |
| 1.9. Liječenje sindroma karpalnog tunela .....   | 14        |
| 1.10. Cijeljenje rane i ožiljak poslije kirurškog liječenja .....  | 15        |
| <b>2. CILJEVI ISTRAŽIVANJA.....</b>  | <b>18</b> |
| <b>3. PREGLED METODOLOGIJE ISTRAŽIVANJA .....</b>  | <b>22</b> |
| 3.1. Ispitanici i postupci .....   | 23        |
| 3.2. Statistička obrada podataka .....   | 31        |
| 3.3. Etička načela .....   | 32        |
| <b>4. SAŽETI PREGLED REZULTATA OBJEDINJENIH RADOVA.....</b>  | <b>33</b> |
| 4.1. Prvi znanstveni članak: analiza ranih kliničkih ishoda: estetski učinci, postoperacijska bol i postoperacijske komplikacije ..... | 34        |
| 4.2. Drugi znanstveni članak: analiza provodljivosti živca medijanusa i funkcije šake .....  | 37        |
| 4.3. Treći znanstveni članak: analiza ukupne kvalitete sna i globalne kvalitete života .....   | 41        |
| <b>5. RASPRAVA.....</b>  | <b>44</b> |
| 5.1. Ograničenja istraživanja .....  | 56        |
| <b>6. ZNANSTVENI DOPRINOS OBJEDINJENIH RADOVA .....</b>  | <b>57</b> |
| <b>7. ZAKLJUČCI .....</b>  | <b>60</b> |
| <b>8. SAŽETAK.....</b>   | <b>63</b> |
| <b>9. SUMMARY.....</b>   | <b>66</b> |
| <b>10. ŽIVOTOPIS.....</b>  | <b>69</b> |
| <b>11. LITERATURA .....</b>  | <b>73</b> |
| <b>12. RADOVI OBJEDINJENI U DOKTORSKOM RADU .....</b>  | <b>88</b> |
| 12.1. Prvi rad .....   | 89        |

|  |            |
|--|------------|
| 12.2. Drugi rad .....  | 101        |
| 12.3. Treći rad .....  | 115        |
| <b>13. PRILOZI .....</b>                                       | <b>125</b> |
| 13.1. Anketni obrasci i upitnici korišteni u istraživanju..... | 126        |

## POPIS OZNAKA I KRATICA

|         |   |
|---------|---|
| AAN     | Američka neurološka asocijacija (engl. <i>American Neurological Association</i> ) |
| BCTQ    | engl. <i>Boston Carpal Tunnel Syndrome Questionnaire</i>                          |
| BMI     | indeks tjelesne mase (engl. <i>Body Mass Index</i> )                              |
| CONSORT | engl. <i>Consolidated Standards of Reporting Trials</i>                           |
| EMNG    | elektromioneurografija  |
| ENG     | elektroneurografija   |
| FSS     | engl. <i>Functional Status Scale</i>  |
| HGS     | engl. <i>Hand Grip Strength</i>   |
| Hi-Ob   | engl. <i>Historical-Objective Scale</i>   |
| ISI     | skala težine nesanice (engl. <i>Insomnia Severity Scale</i> )                     |
| KBC     | klinički bolnički centar  |
| KT      | karpalni tunel  |
| MSS     | engl. <i>Manchester Scar Scale</i>  |
| NBCA    | n-butil 2 cijanoakrilat   |
| NM      | lat. <i>nervus medianus</i>   |
| OCA     | 2-oktil cijanoakrilat   |
| POSAS   | engl. <i>Patient and Observer Scar Assessment Scale</i>                           |
| PQSI    | Pittsburški indeks kvalitete sna (engl. <i>Pittsburgh Sleep Quality Index</i> )   |
| RF      | lat. <i>retinaculum flexorum seu ligamentum carpi transversum</i>                 |
| SAD     | Sjedinjene Američke Države  |
| SF-36   | ukupni indeks kvalitete života (engl. <i>36-Item Short Form Survey</i> )          |
| SBSSES  | engl. <i>Stony Brook Scar Evaluation Scale</i>                                    |
| SKT     | sindrom karpalnog tunela  |
| SSS     | engl. <i>Symptom Severity Scale</i>   |
| VAS     | vizualno-analognu ljestvicu (engl. <i>Visual Analogue Scale</i> )                 |
| VNRS    | vizualna numerička ljestvica boli (engl. <i>Verbal Number Rating Scale</i> )      |
| VSS     | engl. <i>Vancouver Scar Scale</i>   |
| WALANT  | engl. <i>wide-awake, local anesthesia, no tourniquet</i>                          |

## POPIS RADOVA NA KOJIMA SE TEMELJI DOKTORSKI RAD

Ovaj doktorski rad temelji se na prospektivnom randomiziranom ispitivanju iz kojega su proistekla tri rada objavljena u međunarodnim medicinskim časopisima u razdoblju od travnja 2023. do ožujka 2024. godine. Na sva tri članka pristupnica je prvi autor.

1. „*A Comparison of Tissue Adhesive Material and Suture as Wound-Closure Techniques following Carpal Tunnel Decompression: A Single-Center Randomized Control Trial.*“ objavljen u travnju 2023. godine u *Journal of Clinical Medicine* (2023 IF 4,964, WoS).
2. „*The Influence of the Tissue Adhesive Material as a Surgical Wound-Closure Technique Following Carpal Tunnel Decompression on Neurological and Functional Outcomes: A Single-Center Randomized Controlled Trial.*“ objavljen u siječnju 2024. godine u *Cureus* (2024 IF 1,2, WoS).
3. „*The Influence of Wound Closure Techniques after Surgical Decompression in Patients with Carpal Tunnel Syndrome on Sleep Disturbance and Life Quality: A Prospective Comparison of Surgical Techniques.*“ objavljen u ožujku 2024. godine u *Clinics and Practice* (2024 IF 2,3, WoS).

## **1. UVOD**



## 1.1. Sindrom karpalnog tunela

Sindrom karpalnog tunela (SKT) je najučestalija kompresivna fokalna neuropatija od koje boluje 3,8% svjetskog stanovništva i jedan je od najčešćih kanalikularnih sindroma.<sup>1</sup> SKT se razvija uslijed kompresije medijalnog živca (lat. *nervus medianus*) u području karpalnog tunela (KT) na palmarnoj strani korijena šake.<sup>2</sup> Kroz KT prolazi devet tetiva mišića koji savijaju prste i živac medianus.<sup>3</sup> KT je tunel omeđen kostima pešća i širokim četvrtastim poprečnim karpalnim ligamentom (lat. *ligamentum carpi transversum* ili *retinaculum flexorum*; RF).<sup>4</sup> Dugotrajna kompresija živca medianusa dovodi prvo do procesa demijelinizacije, a potom i oštećenja aksona samog živca što usporava kondukciju živčanih impulsa te u konačnici dovodi do tipičnih simptoma i znakova. Prema tome, SKT nastaje uslijed pritiska na živac medianus koji nema zaštitnu ovojniciu i prolazi površno tijekom KT ispod neelastičnog RF-a, a nasuprot tetive *m. flexor digitorum superficialis* za 2. i 3. prst. U kliničkoj slici dominiraju bol u području šake te parestezije šake u distalnom području inervacije medijalnog živca (radijalna polovica četvrtog prsta, palac, drugi i treći prst, s mogućnošću širenja u podlakticu i nadlakticu).<sup>5</sup> Ovi simptomi, kao i trajna utrnulost, intenzivni su noću i mogu probuditi bolesnike iz sna. Slabost uz motoričke ispade, hipotrofija i atrofija tenarnih mišića se naknadno događaju uslijed dugotrajne kompresije.<sup>6</sup> Svjetska zdravstvena organizacija definirala je SKT kao neurološku bolest te naglasila poteškoće povezane s njenim kasnim dijagnosticiranjem, neadekvatnim liječenjem i invalidnosti. Naime, SKT dovodi do značajnog psihosocijalnog invaliditeta te ima velik utjecaj na kvalitetu života bolesnika.<sup>7</sup>

## 1.2. Sindrom karpalnog tunela tijekom povijesti

Najraniji opis SKT-a bilježi se 1854. godine kada je James Paget nakon otvorenog prijeloma palčane kosti opisao dva slučaja kompresivne mononeuropatije NM.<sup>8</sup> Putam 1880. godine opisuje kod 37 trudnica noćne parestezije šake uz pojavu akroparestezija u inervacijskom području NM za koje pretpostavlja da su ishemijskog podrijetla.<sup>9</sup> Buzzard je 1906. godine preporučio resekciju vratnog rebra kao moguću metodu liječenja SKT-a povezujući pojavu akroparestezija šake sa postojanjem rudimentarnog vratnog rebra koje komprimira brahijalni pleksus.<sup>10,11</sup> Tek je Sir James Learmonth 1933. godine prvi obavio dekompresiju medijalnog živca u KT-u tako da je presjekao RF kod dvoje bolesnika.<sup>12</sup> George Phalen je 50-ih godina 20. stoljeća objavio niz radova u kojima je opisao osobna iskustava u kirurškom liječenju bolesnika sa SKT-om i dao značajan doprinos shvaćanju SKT-a kao velikog javno-zdravstvenog problema.<sup>13</sup> Termin SKT uveo je u uporabu Kremer 1953. godine navodeći da njegovu pojavu uzrokuje i retencija tekućine u trudnoći.<sup>14</sup> Prema Chammasu, SKT je klasificiran u idiopatski i sekundarni oblik.<sup>5</sup>

## 1.3. Anatomija i anatomske odnose karpalnog tunela

Živac medianus se formira od medijalnog i lateralnog snopa brahijalnog pleksusa (dva korijena) koji potječu od 6. - 8. vratnog kao i 1. torakalnog živca. Živac prolazi niz nadlakticu do lakatne jame te dolazi na prednju ložu podlaktice između površinskog i dubokog sloja fleksora prstiju. Živac medianus pruža ogranke na podlaktici gdje daje motoričke niti za četiri mišića (*mm. flexor digitorum superficialis, flexor carpi radialis, pronator teres, palmaris longus,*), a posjeduje i periferni ogranak (*n. interosseus anterior*) za inervaciju *m. pronator quadratus, flexor pollicis longus* i medijalni dio *m. flexor digiti profundus*. U donjem dijelu

podlaktice NM prolazi pored tetive *m. flexor carpi radialis*, a ispod tetive *m. palmaris longus*, iznad ručnoga zgloba ulazi u karpalni tunel i dolazi u proksimalni dio dlana. Pred sam ulazak u karpalni tunel, NM daje granu (*n. cutaneous palmaris*) za senzornu inervaciju vanjske polovice dlana.<sup>15</sup> N. medianus motorički i osjetno inervira strukture nadlaktice, podlaktice i šake. Živac inervira tenarne mišiće, kožu palmarnog dijela srednjeg prsta, kažiprsta i palca, te radijalnu polovicu prstenjaka.<sup>16</sup>

Karpalni tunel (KT) je usko koštano vezivno suženje (tjesnac, prolaz, kanal) koje se nalazi na palmarnom dijelu korijena šake. Omeđen je s tri strane karpalnim kostima pešća (lat. *ossa carpi: os trapezoideum, os capitatum, os trapezium i os hamatum*) u obliku karpalnog luka. Izraštaji krajnjih kostiju na krajevima pešća tvore ulnarnu i radijalnu izbočinu. Žlijeb (lat. *sulcus carpi*) se pruža između opisanih izbočina kojeg četvrtasta sveza (lat. *retinaculum flexorum*) i transverzalni karpalni ligament (lat. *ligamentum carpi transversum*) kao krov pretvara u tunel. *Retinaculum flexorum* predstavlja vrlo čvrstu vezivnu ploču razapetu između koštanih izbočina karpusa. Široka je oko 4-5 cm, a debljine je oko 5 mm. S vanjske strane *retinaculum flexorum* pokriven je kožom koja na njega čvrsto prianja. Kada se pogleda poprečni presjek onda se uočava kako karpalni tunel nije posvuda jednako širok, te se sužuje od proksimalnog prema distalnom dijelu s najužim dijelom na oko 2 cm od proksimalnog ulaza. Kroz karpalni tunel prolazi medijalni živac (lat. *nervus medianus*), sinovija i 9 fleksornih tetiva prstiju šake: četiri mišićne tetive površinskih pregibača drugog do petog prsta (lat. *tendines m. flexor diggitorum II-V superficialis*), zatim četiri mišićne tetive dubokih pregibača prstiju (lat. *tendines m. flexor diggitorum II-V profundus*), i tetiva mišića dugačkog pregibača palca (lat. *tendo m. flexor pollicis longus*). Tetiva mišića *flexor pollicis longus* posjeduje vlastitu sinovijsku ovojniciu, a tetive mišića *flexor digitorum superficialis* i *profundus* imaju zajedničke sinovijske ovojnice. Tetive mišića *flexor carpi radialis, flexor carpi ulnaris* i *palmaris longus* su u bliskom odnosu s karpalnim tunelom iako su smještene izvan njega.<sup>17</sup> U KT-u velik udio

volumena zauzima sinovijska ovojnica koja omata mišićne tetive poput vreće, izuzev medijalnog živca koji nema zaštitni omotač. Medijalni je živac u karpalnom tunelu najpovršnija struktura, smješten je između čvrstog RF-a i prednje strane tetiva površinskog fleksora prstiju, pri čemu ekspanzija volumena unutar KT-a može prouzrokovati pritisak na NM. Makroskopske promjene vidljive tijekom kirurškog liječenja SKT-a sastoje se od zadebljanja RF-a, a nakon njegovog presijecanja uočava se „fenomen pješčanog sata“, odnosno suženje medijalnog živca upravo na mjestu pritiska RF-a uz zadebljanje živca distalno i proksimalno od mjesta pritiska RF-a.<sup>18</sup> Središnji živac ulazi u karpalni tunel po sredini i račva se na ularnu i radijalnu granu. Ulnarni krajnji ogranak *n. medianusa* pruža dvije senzorne grane za inervaciju palmarnog dijela 2. i 3. prsta i radijalne polovice 4. prsta (lat. *n. digitalis palmaris communis secundus* i *n. digitalis palmaris communis tertius*), a zahvaća i dorzalnu stranu 3. i radijalne polovice 4. prsta distalno od baze srednje falange, što se klinički prezentira osjetnim smetnjama kao trnci, parestezije, bol i grčevi. Mogu nastati spontano ili provocirano ispitivanjem Tinelovog znaka ili kod hiperfleksije ili hiperekstenzije šake.<sup>19</sup> Medijalni živac inervira većinu mišića fleksora na podlaktici, a na dlanu podražuje tenarske mišiće (lat. *m. flexor carpi radialis, mm. pronator teres et quadratus, mm. flexor digitorum superficialis et profundus, mm. flexor pollicis longus et brevis, m. abductor pollicis brevis, m. opponens pollicis, mm. lumbricales*). Radijalni krajnji ogranak pruža dvije senzorne grane za inervaciju palmarne strane 1. i 2. prsta i motoričku granu za *m. abductor pollicis brevis, m. opponens pollicis i caput superficiale m. flexoris pollicis brevis*.<sup>20</sup> U slučaju pritiska na NM proksimalno od polazišta ramus muscularis razvija se slabost tenarskih mišića. To se klinički manifestira onemogućenim pokretima palca poput opozicije i abdukcije, te hipotrofijom ili atrofijom tenarnih mišića. U najtežim slučajevima uzrokuje nastanak „majmunske šake“, pri čemu su prva metakarpalna kost i palac izjednačeni sa ravninom ostalih prstiju. Klinička slika „ruke propovjednika“ javlja se kod jačeg oštećenja *n. medianusa* na nivou lakta jer se može manifestirati potpunim gubitkom osjeta i atrofijom

tenarskih mišića uz nemogućnost opozicije palca i savijanja prva tri prsta. Proksimalno od distalne poprečne fleksijske kožne brazde razdvaja se palmarna kutana grana medijalnog živca iz njegova radijalnog ruba te inervira tenar i središnji dio dlana. Poznavanje anatomije navedenog senzornog ogranka je klinički značajno jer ne dolazi do poremećaja osjeta u području dlana pri kompresiji NM-a u području KT-a, a ako je pritisak NM-a proksimalno od grananja palmarnog kožnog ogranka, prisutan je osjetni poremećaj u području korijena dlana.

Ključno je poznavanje anatomskih varijacija u tijeku živca i anatomije samog karpalnog tunela tijekom kirurške dekompresije živca medianusa u karpalnom tunelu.<sup>21</sup> Anatomska odstupanja mogu dovesti do jatrogene ozljede tijekom operacije SKT-a. Tijek tenarne motorne grane je varijabilan. Otkrivanje anatomskih odstupanja je značajno zbog moguće lezije senzorne inervacije šake kod operacijskih zahvata uz kasniji razvoja neuroma.<sup>22</sup>

Različitim putevima inervacije može se razviti nespecifična povezanost živčanih vlakana NM-a i *n. ulnaris* u podlaktici. Zato ponekad u sindromu karpalnog tunela nemamo uobičajnu kliničku sliku zahvaćenog inervacijskog područja klasičnim simptomima ove bolesti. EMNG analizom moguće je otkriti Martin-Gruber anastomozu, pri čemu se živčana vlakna nervusa medianusa pridružuju ulnarnom živcu. Manje učestala je Marinacci anastomoza, poznata kao reverzna Martin-Gruberova anastomoza kod koje se medijalnom živcu pridružuju živčana vlakna ulnarnog živca.<sup>23</sup>

#### **1.4. Epidemiologija sindroma karpalnog tunela**

Procijenjena godišnja učestalost sindroma karpalnog tunela (SKT) je 324 do 542 na 100.000 žena, odnosno 125 do 303 na 100.000 muškaraca.<sup>24</sup> Smatra se kako SKT zahvaća 0,1% adultne populacije, s ukupnim rizikom incidencije tijekom života od 10%.<sup>25</sup> Bolest je češća u žena; naime, na oko tri oboljele žene dolazi jedan muškarac u dobi od 45-60 godina.<sup>26</sup> U radno aktivnom stanovništvu godišnja incidencija u muškaraca je 0,6%, a u žena 5,8%.<sup>27</sup> Bolest je

češća na dominantnoj ruci.<sup>28</sup> Na pojavnost i pogoršanje bolesti utječu mnogi čimbenici rizika: ženski spol, srednja i starija dob, bijela rasa, stres, pretilost, konzumacija alkohola, pušenje, genetski i antropometrijski čimbenici, okolišni čimbenici, profesionalne bolesti u proizvodnim i uslužnim djelatnostima u kojima se koristi snaga šake, ponavljajuća uporaba šaka i zglobova, neprimjeren položaj ruke (dugotrajna fleksija ručnog zgloba) i vibracije.<sup>3</sup> SKT često zahvaća obje ruke, a obično prvo biva zahvaćena dominantna ruka. Ova bolest spada u poremećaje nastale zbog kumulativne mikrotraume jer se češće pojavljuje kod manualnih radnika i populacije koja obavlja ponavljajuće pokrete šake (učestalost je do čak 5% radnika u industriji).<sup>29,30</sup> Bolest je češća kod dijabetične polineuropatije i u posljednjem tromjesečju trudnoće.<sup>31</sup> Sekundarni SKT može nastati zbog stanja koja mijenjaju volumen KT-a: oticanje ruku nakon kardiokirurških zahvata, nakon mastektomije, nakon uboda insekta, nakon traume karpalnih kostiju ili palčane kosti, zbog osteoartritisa, reumatoidnog artritisa, akromegalije, upalnog tenosinovitisa, dijabetesa, metaboličkog sindroma, dislipidemije, kronične bubrežne bolesti, vaskularnih poremećaja, poremećaja koagulacije itd.<sup>32-35</sup>

### **1.5. Etiologija i čimbenici rizika za razvoj sindroma karpalnog tunela**

Uzroci SKT-a nisu u potpunosti razjašnjeni, ali danas se zna kako brojni čimbenici rizika utječu na pojavnost bolesti.<sup>36</sup> Osim već poznate uloge koju ima genetska predispozicija,<sup>37</sup> danas se zna kako važnu ulogu u nastanku bolesti imaju ženski spol, srednja životna dob, bijela rasa, antropometrički čimbenici (npr. veličina karpalnog tunela) itd.<sup>38,39</sup> Određenu ulogu u nastanku SKT-a imaju i vanjski fizički čimbenici: snažne repetitivne manualne aktivnosti jakog stiska šake,<sup>40</sup> izloženost vibrirajućim alatima<sup>41</sup> i hladni radni okoliš.<sup>42</sup> Iako ponavljani pokreti u području zapešća predstavljaju rizik od pojave SKT-a, nije dokazano kako rad na računalu povećava učestalost nastanka sindroma karpalnog tunela.<sup>43</sup>

U patofiziološkom smislu, SKT nastaje kao rezultat mehaničke kompresije medijalnog živca u prostoru karpalnog tunela, uz mikrovaskularnu insuficijenciju. Pri tome je bitno povećanje intratunelarnog tlaka koji kod bolesnika sa SKT-om u neutralnom položaju iznosi 32 mmHg, kod fleksije 94 mmHg te kod ekstenzije oko 110 mmHg, kod zdravih ljudi tlak unutar karpalnog tunela u neutralnom položaju oko 2,5 mmHg, dok kod fleksijskih i ekstenzijskih pokreta šake intratunelarni tlak iznosi oko 30 mmHg.<sup>44</sup> Utjecaj intratunelarnog tlaka na tkivo karpalnog tunela uzrokuje proliferaciju subsinovijalnog vezivnog tkiva i poremećaj u mikrovaskularnoj cirkulaciji jer zbog nedovoljne opskrbe krvlju postupno dolazi do smanjenog provođenja živčanih impulsa.<sup>45</sup> Zbog toga kod *n. medianusa* dolazi do smanjenja akcijskih potencijala i demijelinizacije, te je posljedica gubitak aksona.<sup>46</sup> Ishemija živca je vrlo važna u patogenezi ovoga sindroma jer ishemija pojačano stvara ožiljno i vezivno tkivo.<sup>47</sup> Pri tome se razlikuju tri faze živčane kompresije: 1. faza kada dolazi do fizioloških promjena bez promjena u histologiji, 2. faza kada dolazi do staze u venskom protoku sa posljedičnom hiperemijom i otokom živca, te 3. faza kada dolazi do stanjenja živca na mjestu kompresije.<sup>48</sup>

Postoji idiopatski i sekundarni oblik SKT-a. Idiopatski oblik SKT-a postoji u oko 50 % slučajeva, nepoznatog je uzroka, učestaliji je kod žena jer one imaju manje dimenzije KT-a uz često prisutnu kongenitalnu stenozu.<sup>49</sup> Simptomi se pojavljuju u starijoj i srednjoj životnoj dobi zbog degeneracijskih promjena koje dodatno smanjuju volumen KT-a.

Etiologiju sekundarnog SKT-a možemo razvrstati na:

1. Uzroke koji smanjuju volumena KT-a: trauma, tendinitis, abnormalnosti fleksornih tetiva, sinovitis, artritis, poremećaji tetiva i mišića, aberantne krvne žile, giht, lezije ili tumori koji zauzimaju prostor karpalnog tunela, aneurizme, arteriovenske malformacije, poremećaji mišića i tetiva, hemoragija, gangliomi i lipomi.<sup>50</sup> Osobito su bitne traume, a osobito *fractura radii loco typico*, gdje se u oko trećine bolesnika razvije SKT.<sup>51</sup>

2. Uzroke koji povećavaju osjetljivost živca na mehanički pritisak, gdje spadaju razne polineuropatije: osobito su važna dijabetička ili uremička polineuropatija, a rijetko se radi o alkoholnoj polineuropatiji.<sup>52</sup> Rjeđe polineuropatije, gdje se može javiti SKT, su kongenitalne neuropatije sa sklonošću kompresivnim parezama ili poliradikuloneuritis.<sup>53</sup>
3. Ostali uzroci: profesionalne bolesti, hormonalne promjene izazvane trudnoćom ili menopauzom,<sup>54</sup> pretilost,<sup>55</sup> sistemske bolesti poput reumatoidnog artritisa, dijabetesa, hipotireoidizma, lupusa, dermatomiozitisa, skleroderme, zatajenja bubrega, akromegalije, multiplog mijeloma, leukemije, hemofilije, amiloidoze, sarkoidoze, mukopolisaharidoze i drugih bolesti nakupljanja, tuberkuloze, gihta itd.<sup>56-61</sup>

SKT osobito se često javlja kod amiloidoze povezane s dijalizom, koja nastaje nakupljanjem  $\beta_2$ - mikroglobulina u karpalnom tunelu, te je najčešća mononeuropatija u bolesnika s bubrežnim zatajenjem.<sup>62</sup>

SKT se pojavljuje kao akutni ili kronični oblik. Rijetko se javlja u akutnom obliku kao kompresivna neuropatija zbog brzog i intenzivnog povišenja tlaka u karpalnom tunelu koji traje najviše nekoliko sati, najčešće kod prijeloma distalnog radiusa, opekline, koagulopatije, lokalne infekcije i injekcije. Kronični oblik je češći, simptomi traju mjesecima i godinama, pritisak je slabiji ali dugotrajniji. Diferencijalno dijagnostički potrebno je razmotriti polineuropatije (osobito cervikalnu radikulopatiju), poremećaje središnjeg živčanog sustava i sustavne bolesti s neuropatijama.

## **1.6. Patogeneza sindroma karpalnog tunela**

Patogeneza SKT-a je složena i nedovoljno razjašnjena.<sup>63,64</sup> U SKT-u glavni patofiziološki proces je povišeni intratunelarni tlak koji uzrokuje mehaničko oštećenje živca i ishemiju, a pri tome nastaje oštećenje mikrocirkulacije medijalnog živca, odnosno ishemija *vasa nervorum* samog živca uz segmentnu demijelinizaciju.<sup>65,66</sup> Pri tome dolazi do lokaliziranih



intranuralnih krvožilnih promjena i povećane propusnost endoneuralnih vezikula, te nastaje otok u endoneuralnim prostorima.<sup>67</sup> Konačan rezultat tih procesa je intraneuralna ishemija NM-a. Dodatno, fleksija i ekstenzija u ručnom zglobu pri ponavljanim trakcijama oštećuju živac koji je ograničene pokretljivosti zbog kompresije i epineuralnih priraslica.<sup>68,69</sup> Kronično povećanje tlaka u KT-u može uzrokovati poremećaj u krvnom optoku kroz živac, koji može uzrokovati epineuralni edem, povećanje oksidativnog stresa, lokalnu demijelinizaciju, a potom i aksonalnu degeneraciju NM-a.<sup>70</sup> Pri tome, u konačnici, nastaje formiranje fibroznog ožiljka oko medijalnog živca koje dovodi do poremećaja u njegovoj provodljivosti.

### **1.7. Dijagnostika sindroma karpalnog tunela i procjena težine stanja**

Kriteriji za dijagnozu SKT-a se postavljaju na temelju anamnestičkih podataka (pojavnost parastezija i bolova u palmarnoj strani šake tijekom noći) i ciljanog kliničkog pregleda, te dijagnostičkih testova. Tijekom kliničkog pregleda koristimo se provokacijskim testovima. Dijagnoza SKT-a se postavlja kombinacijom elektromioneurografije (EMNG) i kliničkog nalaza.<sup>71</sup>

Klinički kriteriji za dijagnozu SKT-a su: poremećaj osjeta utrnulost i bockanje u inervacijskom području NM-a, bolne nokturalne akroparestezije, hipotrofija/atrofija tenara, poremećaj motorike (nemogućnost palčane opozicije i volarne abdukcije), pozitivan Tinelov znak i Phalenov test uz nesposobnost osjetne distinkcije u dvije točke. Kod pozitivnog Tinelovog znaka bolesnik se tuži na bol ili parestezije na šaci u inervacijskom području medijalnog živca tijekom manualne perkusije NM-a na korjenu ručnog zgloba.<sup>72</sup> Phalenov znak je pojava boli ili parestezija šake u inervacijskom području NM-a nakon fleksije šake u zapešću ekstenziranom laktom, čime se poveća intratunelni tlak kroz 60 sekundi.<sup>13</sup> Pri kliničkom pregledu provode se standardni provokativni manevri koji obično pojačavaju simptome, a osobito su bitni test elevacije ruke, Phalenov test, Tinelov test i test manualne karpalne kompresije.

Drugi klinički testovi su Paleyev, McMurphyev test, kompresivni test sa šakom u fleksiji, tourniquet test, „flick“ manevar, Wormserov test (obrnuti Phalenov test), Bilićev test, Okutsuov test, test stiska šake, Durkanov kompresijski test te van Freyov test (Semmes-Weinstein monofilamentni test).<sup>73-80</sup>

Neurofiziološkim testovima (elektromioneurografija, EMNG) utvrđuje se brzina provođenja živčanih signala središnjeg živca.<sup>81</sup> EMNG je zlatni standard za dokazivanje kliničke dijagnoze SKT-a jer pruža podatke o neurofiziološkom stanju n. medianusa u regiji karpalnog tunela, ali služi za dokazivanje dodatnih neuroloških poremećaja povezanih sa SKT-om, poput cervikalne radikulopatija, lezije perifernih živaca, pleksopatije i polineuropatije. EMNG je pretraga koja se sastoji od elektromiografske (EMG) i elektroneurografske analize (ENG). Elektromiografska analiza služi za dokazivanje mioelektričnih akcijskih potencijala mišićnih vlakana tijekom kontrakcije. Pregled se sastoji od ubadanja posebne elektrode u obliku igle u mišić tijekom kontrakcije mišića. Elektroneurografsko ispitivanje sastoji se u mjerenju brzine provodljivosti motoričkih i osjetnih vlakana živca koji se ispituje s pomoću površinskih elektroda. Dijagnostički ENG kriteriji SKT-a su produžena motorička distalna i senzorička latencija NM-a uz usporenje motoričke i senzoričke brzine NM-a. Senzorna vlakna imaju dosta velikih mijeliniziranih vlakana, što zahtijeva veće potrebe za energijom, što ih čini vulnerabilnim na ishemiju. Fokalni pritisak dovodi do ishemije uz mehaničko oštećenje živčanih vlakana. Oni zajedno dovode do smanjenja provodnosti živca. Naknadno dolazi do tenarne atrofije uz slabost šake što upućuje na dodatnu leziju aksona motornih vlakana. Bitno je istaknuti kako EMNG u ranoj fazi SKT-a može biti normalan jer EMNG verificira živčanu leziju, a ne njegov povremeni pritisak pri čemu nije došlo do strukturnog oštećenja.<sup>82</sup> Kod 13-27% bolesnika rezultati EMNG testova bit će normalni.<sup>83</sup>

Stoga se pri postavljanju dijagnoze povremeno koriste pregled ultrazvukom i magnetska rezonancija.<sup>84,85</sup> Ultrazvuk karpalnog tunela se koristi za prikazivanje mekih tkiva u KT-u

(poput tetiva, NM, RF, eventualno prisustvo ganglion, lipoma ili tenosinovitisa), ali ne i koštanih struktura.<sup>86</sup> Ultrazvukom se mogu mjeriti veličina poprečnog presjeka živca, vaskularnost i eventualna kompresija živca. Magnetska rezonancija omogućuje vizualizaciju karpalnog tunela s prikazom poremećaja srednjeg živca, fleksornih tetiva, krvožilnih struktura i *retinaculuma flexorum* unutar karpalnog tunela, kao i moguću kompresiju živaca, struktura i anatomskih odnosa unutar tunela, odnosno može dokazati promjenu promjera živca prilikom ulaska u tunel.

Zaključno, konačna dijagnoza SKT-a treba povezati kliničke simptome i klinički pregled uz pozitivne elektroneurofiziološke testove.

### **1.8. Klinički oblici sindroma karpalnog tunela**

Klinička prezentacija SKT-a ovisi o duljini i intenzitetu pritiska medijalnog živca, a mogu imati utjecaj na radnu sposobnost i život oboljelog.<sup>87</sup> Na temelju kliničkih kriterija Američke neurološke asocijacije (AAN) objavljene 1993. godine, vjerojatnost za dijagnozu SKT-a je veća ukoliko je više simptoma i provocirajućih faktora.<sup>88</sup> Procjena težine SKT-a može se procijeniti s pomoću Hi-Ob-Db (Historic and Objective) skale koja se koristi za objektivizaciju kliničkog pregleda.<sup>89</sup> Prema nalazu ENG dijagnostičke obrade, stupanj težine SKT-a može se klasificirati po Blandovoj skali.<sup>90</sup>

Budući da sindrom karpalnog tunela nastaje kompresijom n. medianusa, koji osjetno i motorno inervira šaku, u ranim fazama bolesti postoje osjetni simptomi, a u kasnijim fazama bolesti dolazi do zahvaćenosti i motoričkih vlakana pa se javljaju i motorički simptomi. Osjetni simptomi vezani su za dio dlana, prva tri prsta i radijalnu stranu četvrtoga prsta (parestezije i bolovi) koji se mogu širiti palmarom stranom prema ručnom zglobu i laktu. Vrlo često se javljaju noćna jaka bol uz parestezije u području inervacije živca, a to su regije palca, kažiprsta i srednjeg prsta uz radijalnu polovicu prstenjaka.<sup>87</sup> Povremeno se javi i autonomna disfunkcija

poput promjene temperature i boje kože, suha koža i oticanje šake, te poremećaj funkcije lučenja znoja.

Osjetna živčana vlakna su osjetljivija na pritisak u odnosu na motorička vlakana; zato se u ranoj fazi SKT-a prvo jave osjetni simptomi (uglavnom bol i parestezija šake).<sup>4</sup> Tijekom progresije bolesti javljaju se i motorički simptomi, poput slabosti abdukcije i opozicije palca (ispuštanje ili problem držanja predmeta), praćeni atrofijom eminencije tenara.<sup>91</sup>

Klinička simptomatologija SKT-a može se podijeliti u tri stadija. U prvom stadiju bolesnik se često budi noću i navodi osjećaj natečenosti i ukočenosti šake, te parestezije i bol u području prva tri prsta i radijalne polovica četvrtog prsta.<sup>92</sup> Bolovi se često šire proksimalno prema laktu, ponekad i do ramena. Trešnje ruke (engl. *flick*) uz promjenu položaja šake ublažavaju tegobe. U drugom stadiju parestezija i boli su prisutni tijekom dana kod ponavljanih kretnji šake i kada šaka dulje vrijeme ostane u istoj poziciji. Zbog smanjenog ili nedostatnog osjeta u prstima bolesniku ispadaju predmeti iz ruku. Javlja se osjećaj slabosti u zahvaćenoj ruci uz nespretnost prilikom rada prstima i palcem. Kod oko 40% bolesnika sa SKT-om dolazi do hipotrofija tenarnih mišića. Osim toga, bolesnici se često žale na sijevajuću bol koja iradira prema ramenu i laktu. U trećem stadiju se javlja atrofija tenara uz slabost mišića kratkog palčanog odmicača (lat. *m. abductor pollicis brevis*) te slabost mišića palčanog oponenta (lat. *m. opponens pollicis*), uz simptome iz prethodnih stadija.<sup>93</sup> Precizne radnje šakom (poput otkopčavanja dugmadi ili zatvaranja staklenki) teško su izvedive, uz otežano držanje stvari u rukama, jer su motorna vlakna NM-a oštećena.<sup>94</sup>

---

## 1.9. Liječenje sindroma karpalnog tunela

Liječenje SKT-a obuhvaća konzervativni i kirurški pristup. Konzervativnom terapijom može se liječiti umjereno teški sindrom karpalnog tunela. Na konzervativnu terapiju reagira do 82% takvih bolesnika. Konzervativno liječenje obuhvaća primjenu ergonomskih mjera, korištenje nesteroidnih protuupalnih lijekova ili kortikosteroida, kao i fizikalnu terapiju.<sup>95,96</sup> U sklopu fizikalne terapije SKT-a koristi se elektroterapija, terapijski ultrazvuk, magnetoterapija, terapija laserom, primjena analgetskih struja, kineziterapija i masaža.<sup>97</sup> Ukoliko ne dolazi do smanjenja simptoma nakon šest tjedana, potrebno je razmotriti i druge mogućnosti liječenja.

Djelotvornom se pokazala i primjena oralnih steroida, a još je bolja primjena kortikosteroida lokalno (intratunelarna aplikacija), pri čemu je primjena lokalne aplikacije kortikosteroida djelotvorna ako edem tunela ne traje duže od pet mjeseci.<sup>98</sup> Primjena kortikosteroida može dovesti do nuspojava na mjestu karpalnog tunela poput alergije, nekroze kosti, živčanog ili tetivnog oštećenja.

Kirurškim liječenjem SKT-a izravno se smanjuje pritisak na medijalni živac, jer se potpunim presijecanjem RF-a povećava prostor u karpalnom tunelu za oko 24%. Dekompresija medijalnog živca provodi se kod srednje teških i teških stupnjeva SKT-a. Atrofija tenara je glavna indikacija za kiruršku dekompresiju.<sup>99</sup> Uspješnost operacije je veća od 95% uz komplikacije manje od 3%, a do pogoršanja može doći u 8% operiranih slučajeva.<sup>6</sup> Postoje tri moguća pristupa kirurškog liječenja SKT-a: otvorena metoda, minimalno invazivni pristup tj. tehnika „manjeg otvora“ i endoskopski pristup.<sup>100</sup> Otvorena metoda dekompresije je standardni kirurški zahvat koji rezultira većim ožiljkom. Započinje incizijom proksimalnog dijela dlana, u liniji koja se poklapa s medijalnom linijom 4. prsta pristupa se potkožnom tkivu, površinskoj fasciji i presijecanjem transverzalnog karpalnog ligamenta pristupi se u KT.<sup>101</sup> U moguće rane komplikacije ove otvorene metode spadaju inkompletno presijecanje transverzalnog ligamenta,

ozljeda ulnarnog ili medijanog živca te ozljeda arterijskih struktura palmarnog luka ili ulnarne arterije.<sup>102</sup> Moguće kasne operacijske komplikacije su gubitak snage, tvrdoća i distrofija ožiljka i skraćenje fleksornih tetiva.<sup>103</sup> Modifikacija ove tehnike je ograničeni otvoreni pristup, odnosno minimalno invazivni pristup ili tehnika „manjeg otvora“ koji ima manje komplikacija.<sup>104,105</sup> Prednosti endoskopskog pristupa su ranija radna sposobnost, poboljšana snaga šake i smanjenje postoperativne boli, ali uz veći rizik od ozljede živca zbog slabije vidljivosti u usporedbi s otvorenim pristupom.<sup>106,107</sup> Naime, moguće komplikacije endoskopske tehnike su parestezija medijanog i ulnarnog živca, laceracije fleksornih tetiva, nekompletna dekompresija SKT-a, ozljeda površinskog palmarnog luka i refleksna simpatička distrofija.<sup>108,109</sup> U primjeni je i WALANT metoda (engl. *wide-awake, local anesthesia, no tourniquet*), koja povećava zadovoljstvo bolesnika, smanjuje troškove liječenja te smanjuje poslijeoperacijsku mučninu i povraćanje.<sup>110</sup>

### **1.10. Cijeljenje rane i ožiljak poslije kirurškog liječenja**

Proces primarnog cijeljenja rane započinje povredom integriteta kože i sastoji se od četiri stadija koja se isprepliću. To su: hemostaza i inflamatorna faza, proliferacija, maturacija i remodeliranje, te kontrakcija rane.<sup>111</sup> Početna i najkraća faza cijeljenja rane je hemostaza koja traje desetak minuta i u njoj intrizična i ekstrizična koagulacijska kaskada dovodi do stvaranja primarnog ugruška uz vazokonstrukciju lokalnih krvnih žila i stvaranja sekundarnog ugruška s fibrinskim nitima. U inflamatornoj fazi leukociti migriraju na mjesto ozljede. Tijekom 24 sata neutrofili dolaze na mjesto rane i počinju fagocitozu. Time se otpuštaju kisikovi radikali i enzimi proteaze koji rade debridman nekrotičnog tkiva uz otpuštanje upalnih citokina. Nakon 72 sata od ozljede aktiviraju se makrofazi koji nastavljaju fagocitozu te oslobađaju čimbenike cijeljenja poput interleukina, transformirajućeg čimbenika rasta i angiogenetskih faktora, primjerice vaskularni endotelni čimbenik rasta. U proliferacijskoj fazi, koja se javlja 3-10 dana

poslije ozljede, fibroblasti i endotelne stanice otpuštaju vaskularni endotelni, trombocitni i fibroblastni čimbenik rasta, koji u uvjetima lokalne hipoksije dovode do neovaskularizacije, koja se sastoji od angiogeneze i vaskulogeneze. Za vrijeme neovaskularizacije javlja se proces epitelizacije: keratinociti prelaze preko rubova rane dok se ne priljube. Fibroblasti tada ulaze u ranu i proizvode izvanstanični matriks sastavljen od fibronektina, kolagena tipa III i glikozaminoglikana. Nastaje novo granulacijsko tkivo izgrađeno od kolagena, kapilara, leukocita i fibroblasta. Remodelacija je zadnja faza cijeljenja rane u kojoj dolazi do maturacije rane. Ona se javlja tri tjedna nakon ozljede i traje i do jedne godine.<sup>112</sup> To je stadij sinteze i razgradnje novog tkiva te postupno dolazi do sazrijevanja rane. Dolazi do zamjene kolagena tipa III čvršćim kolagenom tipa I u krvnim žilama što omogućuje veću otpornost rane na tenziju; međutim, zbog različitog razmještaja kolagenskih vlakana ostaje vidljiv ožiljak na mjestu ozljede. Istovremeno, miofibroblasti uz proizvodnju izvanstaničnog matriksa postupno dovode do kontrakcije rane.

Kirurške rane imaju ravne i priljubljene rubove te primarno zacjeljuju za 6-10 dana, pri čemu nastaju svježe epitelizirani crveni ožiljci koji postupno blijede. Pravilan ožiljak nema viška kolagena, kontraktura ili širenja, te sazrijeva u odgovarajućem periodu. Infekcija i ishemija tkiva u blizini rane zbog prejakog šivanja mogu usporiti proces cijeljenja rane.

Rane čiji rubovi nisu priljubljeni zbog defekta ili infekcije zacjeljuju sekundarno sa stvaranjem nepravilnog ožiljka, pri čemu nastaje granulacijsko tkivo i rubna epitelizacija. Hipertrofični ožiljci i keloidi uočavaju se kod 5 do 15% zacijeljenih rana.<sup>113</sup>

Izgled ožiljka možemo mjeriti korištenjem ljestvica, i to subjektivnim metodama koje ovise o promatraču, te objektivnim metodama kojima se kvantitativno opisuje i mjeri veličina i izgled. Instrumenti i upitnici za mjerenja ožiljaka su jednostavni za uporabu, neinvazivni i precizni. Koriste se za mjerenje rastegljivosti, čvrstoće, debljine, perfuzije, boje i taktilne morfologije.<sup>114</sup>

Kvaliteta ožiljaka nakon kirurških rekonstrukcija procjenjuje se primjenom različitih bodovnih ljestvica. Najpoznatije su: POSAS (engl. *Patient and Observer Scar Assessment Scale*), VAS (engl. *Visual Analog Scale*), VSS (engl. *Vancouver Scar Scale*), SBSES (engl. *Stony Brook Scar Evaluation Scale*) i MSS (engl. *Manchester Scar Scale*).<sup>115,116</sup> POSAS bodovni sustav najčešće se upotrebljava u evaluaciji ožiljaka nakon operacije raka dojke.<sup>114</sup> Koristi se radi objektivizacije subjektivnih simptoma poput svrbeža i boli od strane bolesnika. Ispituju se čvrstoća, smanjenje boli, vaskularitet, pigmentacija, rastegljivost i površina ožiljka, i obvezan su dio kliničkog pregleda ispitanika. Ljestvice POSAS i VSS ocjenjuju pigmentaciju, vaskularnost i fleksibilnost. Uz navedeno, VSS još procjenjuje visinu ožiljka i u početku se koristio samo za procjenu ožiljaka od opekline. Kod obje ljestvice, izgledom bolji ožiljci su kategorizirani nižim brojem bodova.<sup>117</sup>



## **2. CILJEVI ISTRAŽIVANJA**

Bolesnici koji imaju teški oblik sindroma karpalnog tunela ili oni bolesnici gdje nije došlo do poboljšanja simptoma nakon četiri do šest mjeseci konzervativnog liječenja, mogu se razmotriti za kiruršku dekompresiju.<sup>87</sup> Iako su postoperativne komplikacije rijetke, najznačajnije kasne komplikacije uključuju trajne simptome, ožiljke, neurovaskularna oštećenja, bol i smanjenu snagu stiska.<sup>118</sup> Stoga, unatoč operacijskom liječenju karpalnog tunela, mogu zaostati funkcionalni i estetski deficit, neurovaskularna oštećenja, bol i smanjena snaga stiska šake, te poremećena kvaliteta života, osobito poremećaj kvalitete spavanja. S ciljem smanjenja učestalosti poslijekirurških komplikacija, predložene su različite modifikacije kirurških tehnika zatvaranja rana nakon oslobađanja karpalnog tunela.<sup>119</sup> Budući da osjetljivost postoperativnog ožiljka može biti izazvana inverzijom rubova rane, dobro izvedeno zatvaranje rane rezultirat će smanjenom osjetljivošću postoperativnog ožiljka.<sup>120</sup> Šavovi, spajalice i ljepljive trake su se godinama koristili za zatvaranje postoperativnih rana.

Tkivna ljepljiva su nedavno počela biti korištena u kliničkoj praksi za ove namjene. Zbog svoje jake vlačne čvrstoće, bakteriostatskih svojstava i spontanog ljuštenja, ljepljiva za tkivo, poput 2-oktilcianoakrilata, sve se češće koriste za zatvaranje operacijskih rana.<sup>121</sup> Kod kirurških bolesnika općenito nije utvrđeno da postoje značajne razlike između tkivnih adheziva i klasičnih metoda zatvaranja rana kada se radi o dehiscenciji, infekcijama, estetskom izgledu ili zadovoljstvu kirurga i bolesnika.<sup>122</sup>

Unatoč mnogim predloženim tehnikama zatvaranja rana, nedostaju istraživanja o mogućoj ulozi ljepljiva za tkivo kod zatvaranje rane nakon otvorene operacije dekompresije karpalnog tunela kod bolesnika sa sindromom karpalnog tunela. Pregledom dostupne literature vidljivo je da je zatvaranje kirurške rane s pomoću tkivnog ljepljiva proučavano u raznim kirurškim zahvatima, ali nedostaju studije koje bi sveobuhvatno procjenjivale učinkovitosti tkivnog ljepljiva nakon dekompresije karpalnog tunela. Nedavno je provedena prospektivna randomizirana kontrolirana studija s ciljem usporedbe ljepljive trake (Steri Strips) i ljepljiva za

tkivo (2-octylcyanoacrylate) koje je naneseo nakon primarnog zatvaranja na različite polovice istog kirurškog reza, pri čemu je većina ispitanika imala operaciju karpalnog tunela.<sup>123</sup> Konačno, prije našeg istraživanja postoji samo jedan članak koji opisuje prospektivnu randomiziranu studiju provedenu s ciljem usporedbe ishoda kirurških rana šake saniranih ljepilom za tkivo (n-butil 2-cijanoakrilatno ljepilo za tkivo) ili standardnim tehnikama zatvaranja rana (4-0 monofilamentni šav).<sup>124</sup> U toj studiji su 22 ispitanika (od ukupno 50) imali operaciju zbog dekompresije karpalnog tunela. Od kliničkih efekata u tom istraživanju promatran je isključivo estetski učinak (samo srednja kozmetička VAS ocjena). Dakle, postoji nedostatak ispitivanja utjecaja tehnike zatvaranja operacijske rane i na druge važne kliničke ishode poput neuroloških ishoda, funkcionalnih ishoda, smanjenja bolova, te ishoda vezanih uz kvalitetu života i sna, a upravo je poboljšanje tih ishoda smisao liječenja bolesnika sa sindromom karpalnog tunela. Do našeg istraživanja nije postojalo sveobuhvatno istraživanje koje bi usporedilo tehniku zatvaranja rane s pomoću ljepila za kožu i tehniku zatvaranja standardnim šavovima tijekom otvorene dekompresije karpalnog tunela, te utjecaj tih tehnika na više važnih ishoda: neurološke ishode (uključivši i pojavu boli), funkcionalne učinke, postoperacijske komplikacije, kvalitetu života te estetske učinke.

Polazeći od pretpostavke da klasično transkutano šivanje zahvaća veću površinu šivanog tkiva (kože i potkožnog tkiva) u odnosu na potkožne resorptivne šave i tkivno ljepilo, te da je s pomoću tkivnog ljepila napetost rane ravnomjernije raspoređena uz smanjeni pritisak na kožu gdje su smješteni nociceptori, te vjerojatno postoji smanjeni otok potkožnog tkiva, hipoteza našeg istraživanja bila je kako ćemo dokazati značajne razlike u ranim i kasnim kliničkim ishodima između bolesnika kojima je kirurška rana nakon operacije dekompresije karpalnog tunela zatvarana standardnim šavovima u odnosu na one kojima je rana zatvarana ljepilom za tkivo. Hipoteza istraživanja bila je da ćemo dokazati razlike u funkciji šake,

neurološkoj (motoričkoj i senzornoj) provodljivosti živca medijanusa, postoperacijskoj boli, učestalosti postproceduralnih komplikacija, estetskim ishodima i kvaliteti života.

Glavni ciljevi provedenog i publiciranog istraživanja bili su procijeniti rane i kasne ishode usporedbom dviju tehnika zatvaranja rana nakon elektivne operacije dekompresije karpalnog tunela kod ispitanika randomiziranih za primjenu ljepila za tkivo “Glubran Tiss 2” ili standardnih šavova.

Rani klinički ishodi bili su estetski učinak mjeren kozmetičkom vizualno-analognom skalom C-VAS (engl. *Cosmetic- Visual Analog Scale*), estetski učinak mjeren modificiranom skalom za procjenu ožiljka za bolesnika i promatrača (modificirani POSAS- engl. *Patient and Observer Scar Assessment Scale*), postoperativna bol mjerena vizualnom numeričkom ljestvicom boli (VNRS- engl. *Verbal Number Rating Scale*) te učestalost postproceduralnih komplikacija. Kasni klinički ishodi su promjena senzorne i motoričke provodljivost živca medijanusa mjerena s pomoću ENG (elektroneurografije), promjena funkcija šake mjerene dinamometrom i validiranim upitnikom. Pri tome su rani klinički ishodi mjereni unutar 12 tjedana od operacije, a kasni klinički ishodi mjereni su 6-12 mjeseci od operacije. Konačno, tijekom 12-mjesečnog postoperativnog praćenja promatrani su i ishodi globalne kvalitete života i kvalitete sna: Pittsburški indeks kvalitete sna PQSI (engl. *Pittsburgh Sleep Quality Index*), skala težine nesanice ISI (engl. *Insomnia Severity Scale*), te procjena kvalitete života kao ukupni indeks SF-36 (engl. *36-Item Short Form Survey*).

### **3. PREGLED METODOLOGIJE ISTRAŽIVANJA**

### 3.1. Ispitanici i postupci

Provedeno ispitivanje je bilo prospektivno kontrolirano intervencijsko jednocentrično randomizirano jednostruko slijepo (ocjenjivači svih ishoda ispitanika su bili zaslijepljeni za intervenciju). S obzirom na izvor podataka ispitivanje je bila primarna klinička studija na bolesnicima. Uključivanje ispitanika, randomizacija, intervencije (kirurška dekompresija karpalnog tunela i obje tehnike zatvaranje kirurške rane) i početna ulazna mjerenja provedene su na Zavodu za plastičnu, rekonstrukcijsku i estetsku kirurgiju i opekline Klinike za kirurgiju Medicinskog fakulteta Sveučilišta u Splitu i KBC-u Split. Uključivanje sudionika u ispitivanje započelo je 1. travnja 2022. godine.

Ispitanici su bili raspoređeni u jednu od dvije skupine, ovisno o načinu zatvaranja operacijskog reza tijekom dekompresije karpalnog tunela. U intervencijskoj skupini operacijska rana je zatvarana primjenom “Glubran Tiss 2” ljepila za kožu. U kontrolnoj skupini bolesnika primijenjeni su standardni transkutani kožni šavovi. Ispitivanje je provedeno u skladu s načelima Helsinške deklaracije i smjernicama Konsolidiranih standarda izvještavanja o ispitivanjima (CONSORT, engl. *Consolidated Standards of Reporting Trials*). Svaki sudionik u ispitivanju dao je informirani pristanak.

Kriterij uključenja: bolesnici stariji od 18 godina kod kojih je neuspjelo konzervativno liječenje sindroma karpalnog tunela nakon šest mjeseci od početka simptoma, bolesnici koji su imali atrofiju tenara ili slabost abdukcije palca pri prvom posjetu ili prema neurologu klasificirano ozbiljno ili teško oštećenje provođenja medijalnog živca (lat. *nervus medianus*) procijenjeno elektroneurografijom (ENG). Ispitanici su imali dokazanu najmanje jednu od navedenih težih motornih ili osjetnih oštećenja medijalnog živca: brzinu osjetne kondukcije > 45 m/s, vršnu distalnu osjetnu latenciju < 3,5 ms, osjetnu amplitudu akcijskog potencijala > 10 mV, distalnu motornu latenciju < 4,2 ms, distalnu motornu amplitudu > 5 mV ili brzinu motornog provođenja > 50 m/s. Svi ispitanici imali su pozitivan Tinellov znak i Phalenov test.

Kriteriji isključenja: djeca mlađa od 18 godina, trudnoća, bolesnici kojima je bio potreban i drugi kirurški zahvat u isto vrijeme s dekompresijom karpalnog tunela (npr. Dupuytrenova fasciektomija), bolesnici koji su prije kirurški liječeni zbog dekompresije karpalnog tunela, bolesnici s kožnim alergijama ili osjetljivost na lidokain, cijanoakrilat, formaldehid, trake ili ljepila; osobna ili obiteljska anamneza stvaranja kelodinih ili hipertrofičnih ožiljaka, trauma ručnog zgloba ili prethodne operacije zapešća.

Izračun veličine uzorka: Pomoću *on-line* kalkulatora je izračunata minimalna veličina uzorka.<sup>125</sup> Veličina uzorka izračunata je uzimajući u obzir očekivanu varijabilnost snage stiska ruke (engl. *Hand Grip Strength*, HGS) kao glavne mjere ishoda, a iz prethodnih studija<sup>126</sup> s alfa pogreškom od 0,05 za prepoznavanje značajne razlike i 90% snage testa (beta pogreška od 0,1). Za postizanje navedene snage ispitivanja procijenjen je najmanji broj ispitanika na 31 u svakoj pojedinoj skupini. Za izračun veličine uzorka analize kvalitete života i sna bolesnika korištena je očekivana varijabilnost u glavnoj mjeri ishoda SF-36 iz prethodnih studija, s alfa pogreškom od 0,05 kako bi se prepoznala značajna razlika i 80% snage testa (beta pogreška od 0,2). Za ovu navedenu snagu minimalni broj ispitanika u studiji procijenjen je na 37 u svakoj skupini.

Svakom ispitaniku koji je uključen u ispitivanje napravljen je operacijski zahvat dekompresije karpalnog tunela otvorenim metodom. Operacije dekompresije karpalnog tunela sa zatvaranjem rane obavilo je ukupno pet licenciranih plastičnih kirurga. Nakon pripreme operacijskog polja u uvjetima blijede staze i lokalne infiltracije 2% lidokaina u meko tkivo dlana i karpalnog tunela, izveden je kožni rez duljine 15-18 mm prateći radijalnu polovicu zrake prstenjaka, ali ne preko pregibača zgloba. Za otvaranje kože i transekciju karpalnog ligamenta u proksimalnom smjeru korišten je skalpel br. 15, dok su za rezanje karpalnog ligamenta u

distalnom smjeru upotrijebljene Metzenbaumove škare. Korištene su dvije različite tehnike zatvaranja, ovisno o randomizaciji ispitanika u skupinu:

1. Koža je zašivena transkutanim najlonskim šavovima (polipropilen-polietilenski monofilament, neresorptivni kirurški šavovi) 4-0. (Optilene® DSMP 19, igla 3/8, veličina konca 4/0, B. Braun Surgical, S.A., Barcelona, Spain Španjolska)

2. Nakon potkožnog ukopanog kontinuiranog šava s 4-0 Coated Vicryl™ Plus PS-2, 3/8 (Ethicon Inc., Bridgewater, MA, SAD) nanese je dvokomponentno ljepilo za kožu Glubran Tiss 2® (GEM S.r.l., Viareggio, Italija) koje se sastoji od NBCA (n-butil 2 cijanoakrilata) i OCA (2-oktil cijanoakrilata). Glubran Tiss 2® je sintetičko bioinertno kirurško ljepilo koje posjeduje hemostatska, adhezivna, brtvena i bakteriostatska svojstva. Kada se nanese na tkivo, odmah se polimerizira u tanki, elastični film. Svaki ispitanik je primio 0,35 mL Glubran Tiss® u otvorenu ranu, a zatim je bilo potrebno mirovanje od 20 sekundi. Nakon toga slijedilo je previjanje.

Postoperacijska skrb bila je ista za sve ispitanike. Postoperacijska njega sastojala se od primjene kompresijskog zavoja tijekom jednog dana uz uvođenje analgetika. Pojedini ispitanici s transkutanim najlonskim šavovima i nekoliko ispitanika s kožnim ljepilom trebali su drenažu uskom plastičnom cjevčicom u prva dva postoperativni dana. Redovne posjete kirurga i medicinske sestre, zajedno s previjanjem rana, obavljale su se u ambulantnim uvjetima.

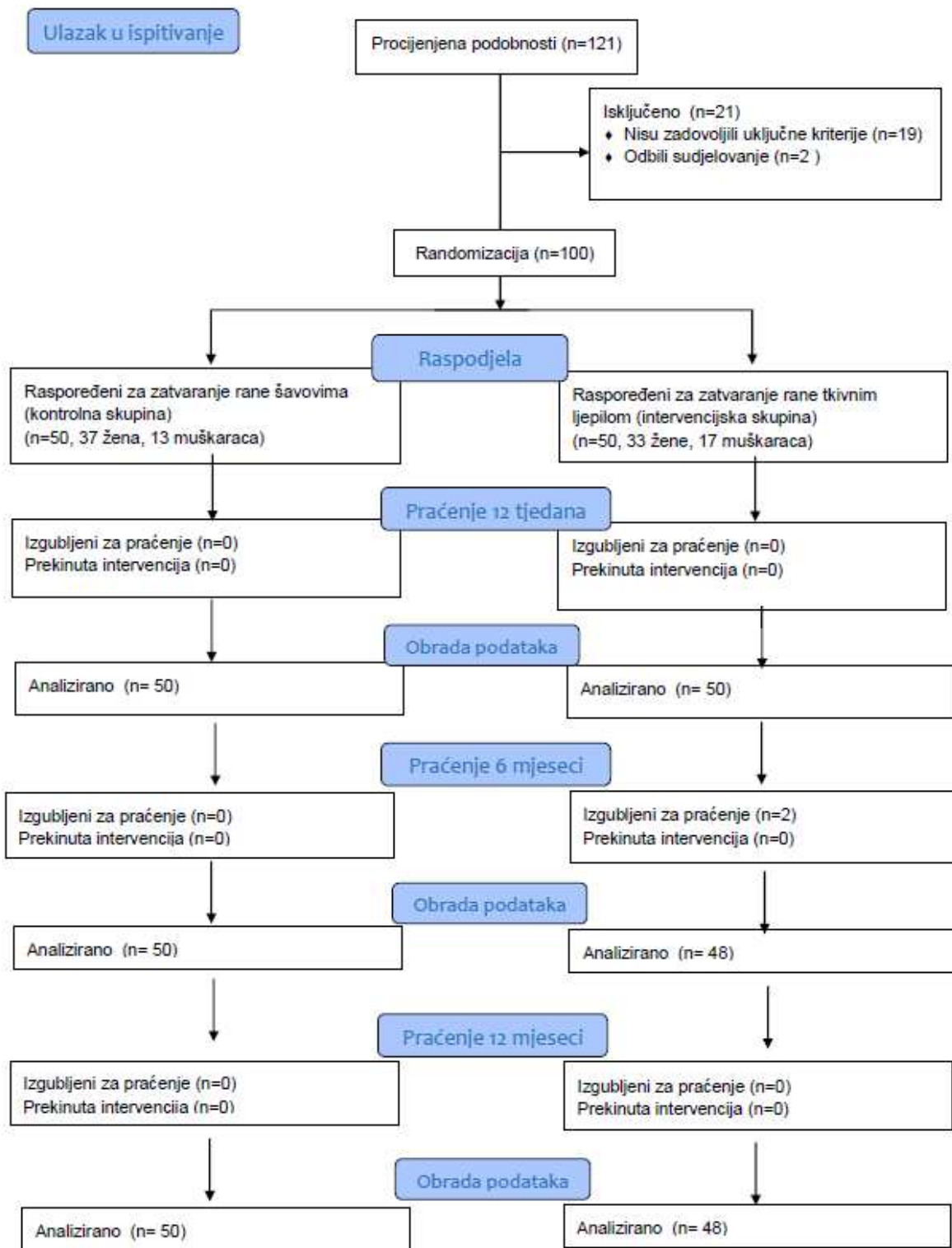
Svakom ispitaniku uključenom u studiju na početku ispitivanja (neposredno pred operaciju) zabilježili su se demografski podatci, spol, težina, visina, prethodne bolesti, laboratorijske dijagnostičke pretrage, duljina trajanja simptoma, te prethodno provođenje fizikalne terapije.



Na početku ispitivanja snaga šake procijenjena je dinamometrom, a funkcionalni status i ozbiljnost simptoma ocijenjena je upitnikom Bostonske procjene karpalnog tunela (BCTQ). Također je na početku ispitivanja prije operacije obavljen elektroneurografijski (ENG) pregled motoričkih i senzornih karakteristika živca medijanusa na ruci na kojoj je planirana operacija.

Odmah nakon operacije zabilježen je operacijski nalaz, uključujući duljinu postoperativne rane, vrijeme dekompresije živca, vrijeme šivanja i vrijeme previjanja. Tijekom prvih 12 tjedana zabilježene su postoperacijske komplikacije. Studija je osmišljena kao jednostruko slijepo ispitivanje jer su ocjenjivači svih ishoda ispitanika bili zaslijepljeni za način zatvaranja operacijske rane.

Tijekom razdoblja uključivanja bolesnika u ispitivanje (od travnja 2022. godine), ukupno je unovačen 121 bolesnik, a u ispitivanje je konačno uključeno 100 ispitanika nakon primjene kriterija isključenja na 19 bolesnika uz dva bolesnika koji su odbili sudjelovati. Ispitanici su nasumično raspoređeni na zatvaranje rana šavovima ili ljepilom za tkivo. Bez obzira na intervencijsku skupinu, postoperativna njega i kontrolni pregledi bili su isti za sve ispitanike. Računalo je generiralo randomizaciju kao slučajne brojeve u omjeru 1:1 u odnosu na vrstu intervencija. Dijagram tijeka ispitivanja CONSORT (engl. *flow chart*) može se vidjeti na Slici 1.



**Slika 1.** CONSORT dijagram tijeka (engl. *flow chart*) cijelog ispitivanja

U **prvom dijelu** ispitivanja ispitanici su pregledani ambulantno 2., 6. i 12. tjedan nakon operacije, te su ispunjeni upitnici (obraci) VAS, POSAS i VNRS. Zabilježen je i broj postoperacijskih komplikacija tijekom prvih 12 tjedana.

Procjena ožiljka provedena je korištenjem modificirane Skale za procjenu ožiljka ispitanika i promatrača (POSAS verzija 2.0, engl. *Patient and Observer Scar Assessment Scale*) od strane ispitanika i neovisnog promatrača - kirurga. Skala POSAS se u osnovi sastoji od dvije zasebne ljestvice: ljestvice promatrača i ljestvice bolesnika; brojčano se boduje svaka od šest komponenata na ljestvici od 1 do 10. Bodovi obje ljestvice se potom zbroje; najgori ožiljak ima ocjenu 60, a najbolji ožiljak ima ocjenu 6.<sup>127</sup> Ispitanici su popunili obrazac za standardiziranu procjenu ožiljka (POSAS), dok je neovisni promatrač (plastični kirurg ili specijalizant plastične kirurgije) ocijenio ožiljak radi bodovanja prema POSAS-u. Promatrači su bili zaslijepljeni i nisu sudjelovali u intervenciji niti u postoperacijskim pregledima. Za procjenu stupnja boli u ruci dan prije i dan nakon operacije, kao i u intervalima od 2, 6 i 12 tjedana nakon operacije tijekom perioda praćenja, korištena je verbalna brojčana skala za procjenu boli (VNRS, engl. *Verbal Number Rating Scale*). VNRS je verbalni instrument samoprocjene s numeričkom ljestvicom ocjenjivanja od 0-10, gdje 0 predstavlja odsustvo boli, a 10 predstavlja najjaču moguću bol.<sup>128</sup> Nadalje, ispitanici su ispunjavali kozmetički VAS (engl. *Visual Analog Scale*) obrazac za procjenu u intervalima od 2, 6 i 12 tjedana. Kozmetički VAS je ljestvica od 0 do 100 s "najgorim ožiljkom" napisanim na lijevom kraju (0) i "najboljim ožiljkom" napisanim na desnom kraju (100).<sup>129</sup> Ovaj prvi dio ispitivanja registriran je u najvećem javnom registru kliničkih istraživanja ClinicalTrials.gov pod identifikacijskim brojem NCT 05747989.

U **drugom dijelu** ispitivanja ispitanici su pregledani ambulantno 6-12 mjeseci nakon operacije. U ovom dijelu ispitivanja je ponovno ispitana je snaga šake dinamometrom te izmjerena snaga stiska ruke (HGS, engl. *Hand Grip Strength*), odnosno promjena HGS-a u odnosu na početni HGS. HGS test mjeri motoričku komponentu svih mišića uključenih u

formiranje stiska ruke te motoričku funkciju maksimalnog napora verbalnim poticanjem ispitanika da stisnu dinamometar što je moguće jače tri do pet sekundi. Dinamometrija je dobro dokumentirana metoda za objektivno kvantificiranje motoričkih ishoda i snage ruke, osobito za procjenu ishoda operacije oslobađanja karpalnog tunela.<sup>130</sup>

HGS je procijenjen s pomoću hidrauličkog ručnog dinamometra KERN MAP 130 K1 Version 1-2 (GB, Balingen, Njemačka). Tijekom mjerenja ispitanici su sjedili s aduktiranim ramenom i neutralno rotiranim laktom savijenim pod 90°, te podlakticom i zglobovom u neutralnom položaju bez oslonca, uz upute stiskanja ručke dinamometra što je jače moguće tri do pet sekunda.

Nakon toga, ispitanicima je ponovo provedena kontrolna elektroneurografija (ENG) kako bi se procijenila elektrofiziološka funkcija i provodljivost medijalnog živca kroz karpalni tunel (brzine, latencije i amplitude motoričkog i senzornog provođenja). ENG mjerenja obavljena su aparatom Medelec Synergy v.11, Nicolet EDX (Domestic Natus Neurology Incorporated, Middleton, WI, SAD) distalno preko zapešća. Ruke su bile dovoljno zagrijane za održavanje temperature kože od 32°C do 34°C, dok je bolesnik bio u udobnom ležećem položaju. Motoričke mjere ishoda su distalna motorička latencija (ms), motorna amplituda srednjeg živca (mV) i brzina motorne vodljivosti srednjeg živca (m/s). Senzorne mjere srednjeg živca su brzina senzorne vodljivosti srednjeg živca (m/s), senzorna amplituda srednjeg živca ( $\mu$ V) i brzina senzorne provodljivosti srednjeg živca (m/s). Sljedeće vrijednosti su smatrane normalnim vrijednostima za srednji živac: brzina senzorne provodljivosti >45 m/s, vršna distalna senzorna latencija <3,5 ms, amplituda akcijskog potencijala senzornog živca >10 mV, distalna motorna latencija <4,2 ms, distalna motorna amplituda >5 mV i brzina provođenja motora >50 m/s.<sup>131</sup> Nakon senzornih i motoričkih ENG mjerenja, ukupan ENG Bland rezultat je izračunat za svakog ispitanika.<sup>90</sup> Blandova ljestvica kreće se od 0 do 6, gdje 0 predstavlja

normalan nalaz, a 6 predstavlja najgori nalaz sa senzornim i motoričkim potencijalima koji se praktično ne mogu zabilježiti.

Potom je ponovno ispitan funkcionalni status i ozbiljnost simptoma pomoću upitnika Bostonske procjene karpalnog tunela - BCTQ (engl. *Boston Carpal Tunnel Syndrome Questionnaire*). BCTQ je upitnik koji se specifično fokusira na bolest i sastoji se od dvije ljestvice: ljestvice ozbiljnosti simptoma (SSS) i ljestvice funkcionalnog statusa (FSS). SSS obuhvaća 11 pitanja koja se odnose na težinu simptoma, dok FSS uključuje osam svakodnevnih aktivnosti koje se ocjenjuju prema stupnju težine. Obe ljestvice koriste petostepenu ocjenu. Rezultati SSS i FSS kreću se od 1 do 5, pri čemu viši rezultat ukazuje na veće oštećenje. Ukupan rezultat BCTQ izračunava se kao srednja vrijednost svih stavki. BCTQ je osjetljiv na klinički značajne promjene, što ga čini prikladnom mjerom za procjenu ishoda liječenja.<sup>132</sup>

Na početku studije, kvaliteta sna i kvaliteta života povezana sa zdravljem procijenjeni su ljestvicama samoprocjene. Nakon 2, 6 i 24 tjedna procijenjeni su parametri kvalitete sna. Za ocjenu kvalitete sna upotrijebljene su dvije validirane ljestvice: Pittsburgh Sleep Quality Index (PSQI) i Insomnia Severity Scale (ISS). PSQI je upitnik koji omogućava ispitanicima da samostalno ocijene ukupnu kvalitetu svog spavanja kroz 19 stavki, raspoređenih u jednu od sedam različitih potkategorija: subjektivna kvaliteta sna (latencija, trajanje spavanja, uobičajena učinkovitost spavanja, poremećaji spavanja, korištenje lijekova za spavanje i dnevna disfunkcija). Ljestvica pruža ukupni rezultat u rasponu od 0 do 21, pri čemu niži rezultati ukazuju na bolju kvalitetu sna.<sup>133</sup> ISI je razvijen za otkrivanje ispitanikove percepcije ozbiljnosti nesanice, kao i procjene njezinog utjecaja na dnevno funkcioniranje.<sup>134</sup> ISI upitnik za samoprocjenu sastoji se od sedam pitanja da bi se dobila ukupna ocjena: 0–7 = nema klinički značajne nesanice; 8–14 = subklinička nesanica; 15–21 = klinička nesanica (umjerena); 22–28 = klinička nesanica (teška).

PQSI i ISI su evaluirani na početku studije (neposredno pred kirurški zahvat) te tijekom kontrolnih pregleda nakon 2, 6 i 24 tjedna.

Kvaliteta života procijenjena je korištenjem upitnika SF-36 (36-Item Short-Form Survey), koji je razvijen u RAND Health Care kao dio studije o medicinskim ishodima. Ovaj upitnik se široko primjenjuje u kliničkim studijama i javnozdravstvenim analizama, a višestruko je validiran u raznim istraživanjima.<sup>135</sup> Upitnik se sastoji od 36 pitanja koja istražuju osam različitih dimenzija zdravlja, uključujući fizičke i psihičke aspekte. Ove dimenzije obuhvaćaju: ograničenja u tjelesnim aktivnostima uslijed zdravstvenih problema, ograničenja u društvenim aktivnostima zbog fizičkih ili emocionalnih poteškoća, ograničenja u svakodnevnim aktivnostima zbog tjelesnih zdravstvenih problema, tjelesnu bol, opće mentalno zdravlje, ograničenja u svakodnevnim aktivnostima zbog emocionalnog stresa, vitalnost te opću percepciju zdravlja. Rezultati se prikazuju na ljestvici koja se kreće od 0 (najgore stanje) do 100 (najbolje stanje). Ukupan rezultat SF-36 izračunat je na početku studije (neposredno prije operacije) i na posljednjem kontrolnom pregledu nakon 12 mjeseci.

Ovaj drugi dio ispitivanja registriran je također u najvećem javnom registru kliničkih istraživanja ClinicalTrials.gov pod identifikacijskim brojem NCT 05808855.

### **3.2. Statistička obrada podataka**

Opisni podaci prikazani su kao aritmetička sredina  $\pm$  standardna devijacija, ako je distribucija podataka bila normalna, ili kao medijan (sa interkvartilnim rasponom), ako podatci nisu normalno distribuirani. Kvantitativni podatci izraženi su kao broj (n) i postotak. Za procjenu normalnosti distribucije kvantitativnih varijabli korišten je Kolmogorov-Smirnovljevi test. Kvalitativni podatci između skupina ispitanika uspoređivani su hi-kvadrat testom ili Fisherovim egzaktnim testom. Kvantitativni podaci su uspoređeni korištenjem Studentovog t-testa za neovisne i ovisne uzorke. Za analizu i usporedbu kvantitativnih varijabli s distribucijom

koja nije bila normalna korišten je Mann-Whitneyev test za neuparene i Wilcoxonov test rangiranja za uparene varijable. Korelacije između kvantitativnih podataka izračunate su korištenjem Pearsonovog koeficijenta korelacije za normalno distribuirane varijable, dok je za varijable s nenormalnom distribucijom primijenjen Spearmanov koeficijent. Za neke korelacije konstruiran je graf linearne regresije s pripadajućom regresijskom jednadžbom. Statistička analiza izvršena je uz pomoć softvera SPSS (*IBM SPSS Statistics for Windows*, verzija 26.0, Armonk, NY, SAD). *P* vrijednosti manje od 0,05 su smatrane statistički značajnima.

### **3.3. Etička načela**

Ispitivanje je odobreno od Etičkog povjerenstva KBC-a Split (broj odobrenja 500-03/22-01; datum odobrenja 31. ožujka 2022. godine). Ispitivanje je provedeno u skladu s Helsinškom deklaracijom. Svi sudionici su prije uključivanja u studiju potpisali informirani pristanak za sudjelovanje u ispitivanju prije nego što je ispitivanje započelo. Svaki pojedinačni postupak i mogući rizik je detaljno pojašnjen ispitanicima.

Prvi dio ispitivanja registriran je u najvećem javnom registru kliničkih istraživanja ClinicalTrials.gov pod identifikacijskim brojem NCT 05747989, a drugi dio ispitivanja registriran je u istom registru pod identifikacijskim brojem NCT 05808855.

Plan ispitivanja usklađen je s odredbama o zaštiti prava i osobnih podataka ispitanika iz Zakona o zaštiti prava pacijenata (NN169/04, 37/08) i Zakona o provedbi Opće uredbe o zaštiti podataka (NN 42/18), te odredbama Kodeksa liječničke etike i deontologije (NN 55/08, 139/15) i pravilima Helsinške deklaracije WMA 1964-2013 na koje upućuje Kodeks.

#### **4. SAŽETI PREGLED REZULTATA OBJEDINJENIH RADOVA**

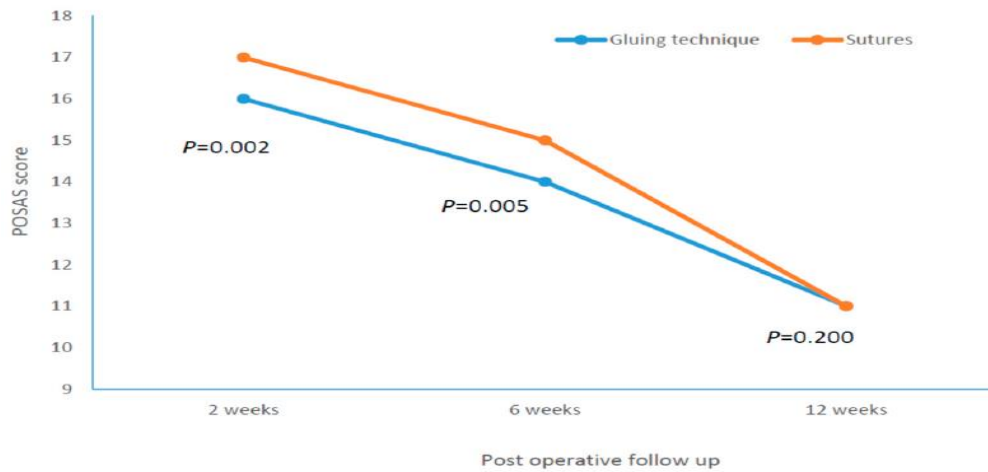


U ispitivanje je konačno uključeno 100 ispitanika (30 muškaraca i 70 žena) u dobi  $61,56 \pm 12,03$  godine, nasumično raspoređeno u omjeru 1:1 za zatvaranje rane šavovima ( $n = 50$ ) ili tkivnim ljepilom ( $n = 50$ ). Operacija desne strane izvedena je kod 57 ispitanika, dok je lijeva strana operirana kod 43 ispitanika. Srednje vrijeme kirurške dekompresije bilo je  $8,71 \pm 0,57$  minute. Nismo mogli dokazati razlike između vremena operacijske dekompresije između skupine ispitanika kojima je rana lijepljena i skupine kojima je operacijska rana zatvarana transkutanom šavovima ( $8,74 \pm 0,57$  naspram  $8,67 \pm 0,57$  minuta,  $P = 0,264$ ).

#### **4.1. Prvi znanstveni članak: analiza ranih kliničkih ishoda: estetski učinci, postoperacijska bol i postoperacijske komplikacije**

U prvom publiciranom radu analizirali smo rane ishode ovog ispitivanja (NCT 05747989), gdje su ishodi procijenjeni postoperativno tijekom razdoblja praćenja u intervalima od 2, 6 i 12 tjedana.<sup>136</sup> Procjena ožiljaka provedena je s pomoću modificirane POSAS skale (Skala za procjenu ožiljaka bolesnika i promatrača, engl. *Patient and Observer Scar Assessment Scale*) i kozmetičke VAS skale (Vizualne analogne skale, engl. *Visual Analog Scale*). Za ocjenu boli korištena je VNRS skala (Verbalno-numerička skala, engl. *Verbal Number Rating Scale*). Dokazane su značajne razlike u POSAS (Slika 2) i kozmetičkom -VAS skoru između skupine kod koje je kirurška rana zatvarana ljepilom i skupine kod koje je kirurška rana zatvarana transkutanom šavovima, i to u intervalima od 2 tjedna i 6 tjedana nakon operacije, odnosno dokazan je bolji estetski učinak kod tehnike zatvaranja rane ljepilom uz potkožni šav, s manje postoperativne boli u istim intervalima (VNRS). Nakon 12 tjedana razlike u navedenim ishodima nisu bile statistički značajne. (Tablica 1) Zaključno, dokazali smo kako adhezijske smjese tkivnog ljepila na bazi cijanoakrilata mogu biti možda kratkoročno bolje u smislu kozmetičkog izgleda i postoperacijske boli, u usporedbi s konvencionalnim tehnikama šivanja

kože za zatvaranje kirurških rana nakon otvorene dekompresije sindroma karpalnog tunela, ali nakon 12 tjedana nije bilo razlike između oba postupka.



**Slika 2.** Razlike u rezultatima POSAS-a (ocijenjenim od ispitanika) tijekom razdoblja promatranja.

**Tablica 1.** Razlike između ispitanika kojima je rana zatvarana tkivnim ljepilom i onih kojima je rana zatvarana transkutanom šavovima (Mann-Whitneyev test za neparametrijske podatke), *P* za značajne razlike je podebljano. Podatci su prikazani kao medijan (interkvartilni raspon).

|  | Tkivno ljepilo<br>(n=50) |                  | Transkutani šavovi<br>(n=50) |                  | <i>P</i>         |
|--|--------------------------|------------------|------------------------------|------------------|------------------|
| VAS 2 tjedna nakon zahvata                 | 95,00                    | (90,00- 95,00)   | 90,00                        | (90,00- 95,00)   | <b>0,014</b>     |
| VAS 6 tjedna nakon zahvata                 | 100,00                   | (100,00- 100,00) | 100,00                       | (95,00- 100,00)  | <b>0,003</b>     |
| VAS 12 tjedna nakon zahvata                | 100,00                   | (100,00- 100,00) | 100,00                       | (100,00- 100,00) | 0,153            |
| POSAS 2 tjedna nakon zahvata (ispitanik)   | 16,00                    | (16,00- 17,00)   | 17,00                        | (17,00- 18,00)   | <b>0,002</b>     |
| POSAS 2 tjedna nakon zahvata (promatrač)   | 16,00                    | (16,00- 17,00)   | 17,00                        | (16,00- 18,00)   | <b>&lt;0,001</b> |
| POSAS 6 tjedna nakon zahvata (ispitanik)   | 14,00                    | (14,00- 15,00)   | 15,00                        | (14,00- 15,00)   | <b>0,005</b>     |
| POSAS 6 tjedna nakon zahvata (promatrač)   | 14,00                    | (13,00- 14,00)   | 14,00                        | (13,75- 15,00)   | <b>0,038</b>     |
| POSAS 12 tjedana nakon zahvata (ispitanik) | 11,00                    | (10,00- 12,00)   | 11,00                        | (10,00- 12,00)   | 0,200            |
| POSAS 12 tjedana nakon zahvata (promatrač) | 11,00                    | (10,00- 11,25)   | 11,00                        | (10,00- 12,00)   | 0,064            |
| VNRS prije zahvata                         | 5,00                     | (4,00- 6,00)     | 5,00                         | (4,00- 5,25)     | 0,387            |
| VNRS na dan zahvata                        | 5,00                     | (4,00- 6,00)     | 5,00                         | (4,00- 6,00)     | 0,134            |
| VNRS 2 tjedna nakon zahvata                | 3,00                     | (3,00- 4,00)     | 3,00                         | (3,00- 4,00)     | <b>0,027</b>     |
| VNRS 6 tjedna nakon zahvata                | 2,00                     | (1,00- 2,00)     | 2,00                         | (2,00- 3,00)     | <b>0,001</b>     |
| VNRS 12 tjedana nakon zahvata              | 0,00                     | (0,00- 0,00)     | 0,00                         | (0,00- 0,00)     | 0,232            |

Legenda: VAS: Visual Analogue Scale, POSAS: Patient and Observer Scar Assessment Scale, VNRS: Verbal Numerical Rating Scale.

Pronašli smo značajnu korelaciju između vremena operacije i duljine rane ( $r = 0,206$ ,  $P = 0,020$ ). Nakon šest tjedana, rezultat VNRS-a pokazao je slabu povezanost s vremenom previjanja rane tijekom operacije ( $\rho = -0,347$ ,  $P < 0,001$ ). Indeks tjelesne mase (engl. *Body Mass Index*, BMI) je bio u slaboj negativnoj korelaciji s POSAS rezultatom promatrača nakon 6 tjedana ( $\rho = -0,270$ ,  $P = 0,03$ ).

U cijeloj skupini, 12 ispitanika imalo je sljedeće rane postoperativne komplikacije (nakon 15 dana): crvenilo (pet slučajeva), dehiscencija (dva slučaja), krvarenje (dva slučaja), infekcija (jedan slučaj), alergijski dermatitis (jedan slučaj) i sekret (jedan slučaj). Nakon 12-tjednog postoperacijskog razdoblja, što je bilo vrijeme resorpcije konca u skupini s potkožnim kontinuiranim šavovima, osam ispitanika imalo je kasne komplikacije: pet je imalo granulome, dvoje sekret, a jedan infekciju. Nije bilo statistički značajne razlike u broju ranih ili kasnih

komplikacija između dvije skupine ( $\chi^2 < 0,001$ ,  $P = 0,620$ , odnosno  $\chi^2 = 0,54$ ,  $P = 0,375$ ). Zaključno, nije bilo razlike u intervencijskim skupinama u ranim ili kasnim postoperacijskim komplikacijama.

#### 4.2. Drugi znanstveni članak: analiza provodljivosti živca medijanusa i analiza funkcije šake

U drugom objavljenom članku prikazali smo rezultate drugog dijela istraživanja (NCT 05808855) koji su vezani za neurološke (elektroneurografske) i funkcionalne ishode.<sup>137</sup> Kada promatramo cijelu kohortu ispitanika, vidljivo je kako je šest mjeseci nakon operacije došlo do statistički značajnog poboljšanja svih ispitivanih varijabli (Tablica 2).

**Tablica 2.** Razlike u snazi stiska šake, kliničkim značajkama i elektroneurografskim parametrima provođenja medijalnog živca prije i nakon operacije dekompresije u cijeloj skupini (N=98) (Studentov t-test za ovisne uzorke ili Wilcoxonov test), podatci su prikazani kao aritmetička sredina ± standardna devijacija ili medijan (s interkvartilnim rasponom) za neparametarske podatke.

|                          | Prije operacije |             | 6 mjeseci nakon operacije |             | P      |
|--------------------------|-----------------|-------------|---------------------------|-------------|--------|
| snaga stiska ruke (kg)   | 18,52±          | 5,64        | 23,20±                    | 6,40        | <0,001 |
| senzorna latencija (ms)  | 3,55±           | 1,59        | 2,72±                     | 0,99        | <0,001 |
| senzorna amplituda (mV)  | 4,55±           | 3,76        | 8,78±                     | 5,58        | <0,001 |
| senzorna brzina (m/s)    | 29,33±          | 15,52       | 38,65±                    | 14,40       | <0,001 |
| motorička latencija (ms) | 5,54±           | 1,60        | 4,46±                     | 1,40        | <0,001 |
| motorička amplituda (mV) | 6,55±           | 4,17        | 7,70±                     | 3,81        | 0,015  |
| motorička brzina (m/s)   | 50,29±          | 12,61       | 55,14±                    | 8,10        | 0,001  |
| BCTQ-SSS                 | 41,95±          | 8,06        | 22,45±                    | 6,34        | <0,001 |
| BCTQ-FSS                 | 27,66±          | 9,17        | 14,46±                    | 5,09        | <0,001 |
| Bland skor               | 4,00            | (3,00-5,00) | 3,00                      | (3,00-3,00) | <0,001 |

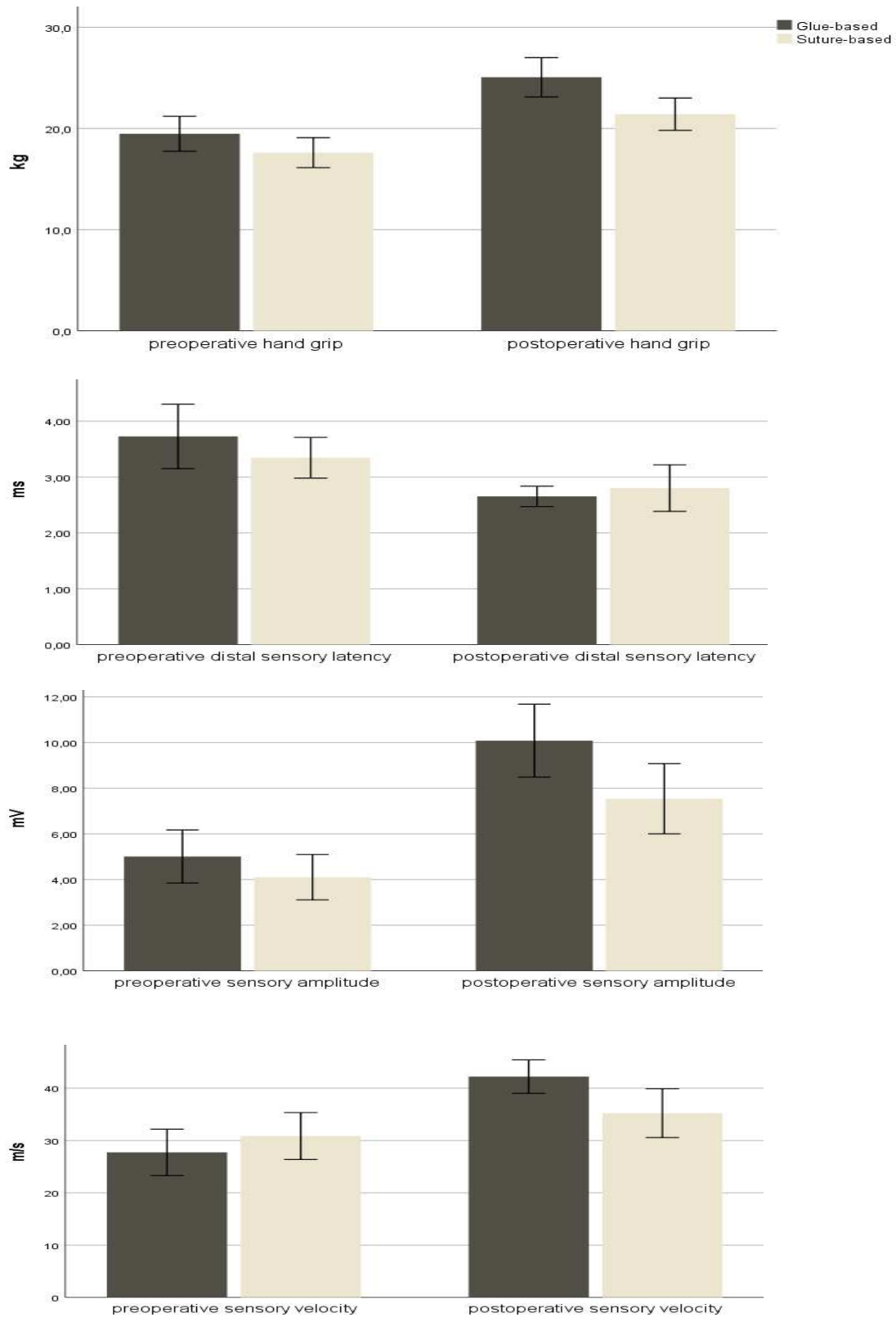
Legenda: BCTQ = Boston carpal tunnel questionnaire; SSS = symptom severity scale; FSS = functional status scale.

Dokazali smo značajne razlike između dvije intervencije (tehnike zatvaranja rane) i to u slijedećim varijablama: u postoperativnoj snazi stiska šake, postoperativnoj senzornoj latenciji, postoperativnoj senzornoj amplitudi i postoperativnoj senzornoj brzini; ovi rezultati favoriziraju zatvaranje rana s pomoću tkivnog ljepila. (Tablica 3, Slika 3)

**Tablica 3.** Razlike u snazi stiska šake i elektroneurografskim parametrima senzorne i motoričke vodljivosti medijalnog živca između skupina gdje je rana zatvarana tkivnim ljepljivom i zatvaranja rane šavovima (Studentov t-test za neovisne uzorke odnosno Mann-Whitneyev test za neparametrijske podatke), *P* za značajne razlike su podebljani. Podatci su prikazani kao aritmetička sredina± standardna devijacija ili medijan (s interkvartilnim rasponom) za neparametarske podatke.

|  | Tkivno ljepljivo |             | Transkutani šavovi |             | <i>P</i>         |
|--|------------------|-------------|--------------------|-------------|------------------|
|  | N=48             |             | N=50               |             |                  |
| snaga stiska ruke _preoperacijski (kg)     | 19,48±           | 5,95        | 17,61±             | 5,22        | 0,051            |
| snaga stiska ruke _6 mjeseci postop (kg)   | 25,06±           | 6,69        | 21,41±             | 5,62        | <b>0,002</b>     |
| delta_ snaga stiska ruke (post-pre) (kg)   | 5,58±            | 3,29        | 3,80±              | 2,50        | <b>0,002</b>     |
| senzorna latencija_ preoperacijski (ms)    | 3,73±            | 1,90        | 3,35±              | 1,14        | 0,137            |
| senzorna latencija _6 mjeseci postop (ms)  | 2,69±            | 0,60        | 3,14±              | 1,96        | 0,067            |
| delta_ senzorna latencija (pre-post) (ms)  | 1,07±            | 1,61        | 0,54±              | 1,25        | <b>0,049</b>     |
| senzorna amplituda _ preoperacijski (mV)   | 5,01±            | 4,00        | 4,10±              | 3,49        | 0,117            |
| senzorna amplituda _6 mjeseci postop (mV)  | 10,08±           | 5,50        | 7,54±              | 5,41        | <b>0,012</b>     |
| delta_ senzorna amplituda (post-pre) (mV)  | 5,07±            | 4,39        | 3,43±              | 3,95        | <b>0,028</b>     |
| senzorna brzina_ preoperacijski (m/s)      | 27,73±           | 15,24       | 30,86±             | 15,79       | 0,161            |
| senzorna brzina _6 mjeseci postop (m/s)    | 42,22±           | 11,04       | 35,23±             | 16,40       | <b>0,008</b>     |
| delta_ senzorna brzina (post-pre) (m/s)    | 14,48±           | 13,25       | 4,38±              | 12,33       | <b>&lt;0,001</b> |
| motorička latencija _ preoperacijski (ms)  | 5,44±            | 1,61        | 5,64±              | 1,60        | 0,273            |
| motorička latencija _6 mjeseci postop (ms) | 4,39±            | 1,82        | 4,53±              | 0,85        | 0,310            |
| delta_ motorička latencija (pre-post) (ms) | 1,06±            | 2,24        | 1,11±              | 1,69        | 0,446            |
| motorička amplituda_ preoperacijski (mV)   | 7,28±            | 3,91        | 5,86±              | 4,33        | <b>0,046</b>     |
| motorička amplituda_6 mjeseci postop (mV)  | 8,08±            | 3,80        | 7,34±              | 3,82        | 0,170            |
| delta_ motorička amplituda (post-pre) (mV) | 0,80±            | 4,69        | 1,48±              | 4,50        | 0,233            |
| motorička brzina _ preoperacijski (m/s)    | 51,62±           | 8,11        | 49,04±             | 15,70       | 0,158            |
| motorička brzina _6 mjeseci postop (m/s)   | 56,38±           | 5,04        | 53,98±             | 10,08       | 0,073            |
| delta_ motorička brzina (post-pre) (m/s)   | 4,76±            | 8,56        | 4,94±              | 17,77       | 0,474            |
| BCTQ-SSS_ preoperacijski                   | 42,65+           | 9,10        | 41,28±             | 6,95        | 0,202            |
| BCTQ-SSS_6 mjeseci postop                  | 23,19±           | 6,41        | 21,74±             | 6,27        | 0,130            |
| delta_ BCTQ-SSS (post-pre)                 | 19,46±           | 7,51        | 19,54±             | 6,03        | 0,476            |
| BCTQ-FSS_ preoperacijski                   | 26,81±           | 6,62        | 28,48±             | 11,09       | 0,185            |
| BCTQ-FSS_6 mjeseci postop                  | 14,08±           | 5,61        | 14,82±             | 4,57        | 0,238            |
| delta_ BCTQ-FSS (post-pre)                 | 12,73±           | 5,97        | 13,66±             | 9,50        | 0,282            |
| Bland skor_ preoperacijski                 | 3,00             | (3,00-4,75) | 4,00               | (3,00-5,00) | 0,142            |
| Bland skor _6 mjeseci postop               | 3,00             | (3,00-3,00) | 3,00               | (3,00-3,00) | 0,245            |
| delta_ Bland skor (pre-post)               | 0,00             | (0,00-1,00) | 0,50               | (0,00-1,00) | 0,224            |

Legenda: BCTQ = Boston carpal tunnel questionnaire; SSS = symptom severity scale; FSS = functional status scale.



**Slika 3.** Statistički značajne razlike između tehnika zatvaranja rana na temelju ljepila i šavova u preoperativnim i postoperativnim vrijednostima stiska šake, distalnoj senzornoj latenciji, amplitudi senzornog akcijskog potencijala i brzini senzorne vodljivosti medijalnog živca.

Nadalje, u skupini gdje je rana zatvarana tkivnim ljepilom, 23 (47,9%) bolesnika postiglo je veću postoperativnu senzornu brzinu od 45 m/s, dok je u skupini s transkutanom šavovima samo 11 (22,0%) bolesnika postiglo postoperativnu senzornu brzinu veću od 45 m/s. Razlika je bila statistički značajna ( $\chi^2 = 7,260$ ,  $P = 0,006$ ). Veći broj ispitanika u skupini gdje je rana zatvarana tkivnim ljepilom postigao je povećanje senzorne brzine nakon operacije u usporedbi sa šivanom skupinom (44 ili 91,8% prema 38 ili 76,0%), a razlika je bila statistički značajna ( $\chi^2 = 4,400$ ,  $P = 0,033$ ). Kod ispitanika gdje je rana zatvarana tkivnim ljepilom, 29 (60,42%) bolesnika postiglo je postoperativnu motoričku latenciju manju od 4,2 ms, u usporedbi sa samo 19 (38,0%) u šivanoj skupini. Razlika je bila statistički značajna ( $\chi^2 = 4,925$ ,  $P = 0,022$ ).

Ovo ispitivanje je tako dokazalo da adhezijski materijal na bazi cijanoakrilata, u kombinaciji s potkožnim kontinuiranim šavom za zatvaranje rana nakon otvorene dekompresije sindroma karpalnog tunela, ima prednost nad transkutanom šavovima u smislu poboljšanja funkcionalnih biljega mjerenih kao snaga stiska ruke i neuroloških ishoda mjerenih kao srednji parametri provođenja senzornih živaca. Zatvaranje rane nakon kirurške dekompresije karpalnog tunela može se učinkovito i sigurno izvesti s ljepilima za tkivo na bazi cijanoakrilata, uz očekivan povoljni utjecaj na oporavak medijalnog živca i poboljšanje snage ruke.

#### **4.3. Treći znanstveni članak: analiza ukupne kvalitete sna i globalne kvalitete života**

U trećem objavljenom radu analizirali smo razlike u kvaliteti života i kvaliteti sna između dvije skupine ispitanika randomizirane u odnosu na intervenciju.<sup>138</sup> Dokazali smo značajno poboljšanje sna i ukupne kvalitete života postoperacijski kod obje skupine ispitanika, uz dokazanu neinferiornost tkivnog ljepila, odnosno obje tehnike podjednako dovode do poboljšanja kvalitete sna i života, što znači da se tkivno ljepilo na bazi cijanoakrilata može

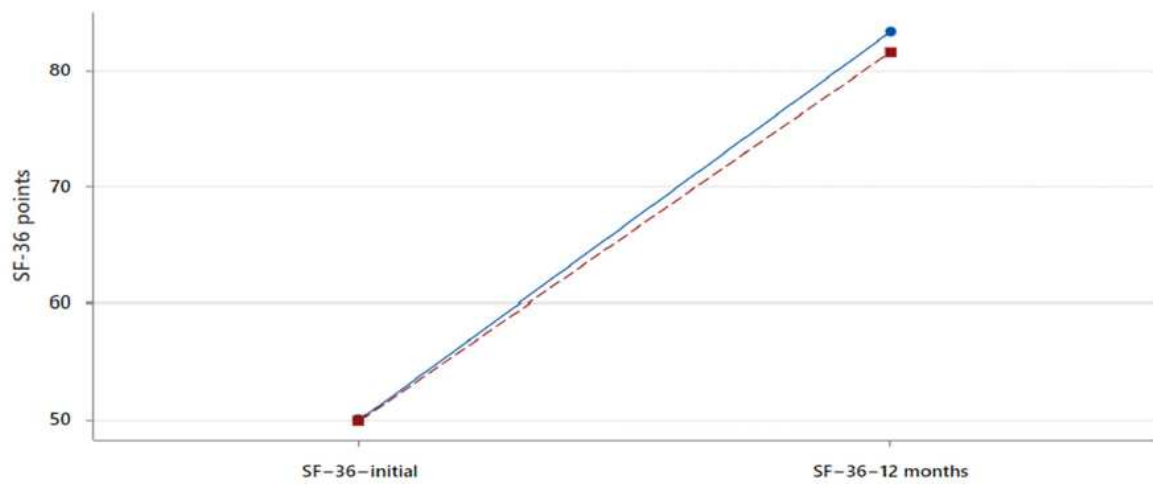


standardno koristiti kao adhezijski materijal za zatvaranje rana nakon otvorene dekompresije karpalnog tunela. Prikazali smo značajan napredak u kvaliteti života vezanoj uz spavanje i zdravlje tijekom svih intervala praćenja, što je rezultat kontinuiranog poboljšanja kvalitete života nakon operacije. Ukupni rezultat SF-36 porastao je 12 mjeseci nakon operacije ( $49,84 \pm 5,85$  naspram  $82,46 \pm 5,68$ ,  $p < 0,001$ ). Ovaj učinak je potvrđen za sve ispitanike, kao i za svaku pojedinačnu skupinu ispitanika. Pri tome je prednost tkivnog ljepljiva u odnosu na transkutani šav značajan utjecaj na brže poboljšanje kvalitete sna. (Tablica 4) Naime, dokazali smo statistički značajno smanjenje ISI skora (Skala ozbiljnosti nesanice) dva tjedna nakon operacije kod ispitanika čije su kirurške rane bile zatvarane ljepljivom za tkivo ( $9,40 \pm 1,18$  naspram  $9,96 \pm 1,09$  u skupini zatvaranoj šavovima,  $P = 0,008$ ). Isto tako, neke od drugih mjera kvalitete života povezane sa spavanjem i zdravljem bile su bolje u skupini u kojoj je kirurška rana bila zatvorena ljepljivom, ali nije postignuta statistička značajnost. (Tablica 4, Slika 4)

**Tablica 4.** Razlike u kvaliteti sna i globalnoj kvaliteti života između dvije skupine sudionika (zatvaranje rana na temelju ljepljiva i zatvaranje rana na temelju šavova), podatci su prikazani kao srednja vrijednost±standardna devijacija, Studentov t-test za neovisne uzorke, jednosmjerno,  $P$  za značajne razlike su podebljani.

|                                  | Tkivno ljepljivo |      | Transkutani šavovi |      | <i>P</i>     |
|----------------------------------|------------------|------|--------------------|------|--------------|
|                                  | N=48             |      | N=50               |      |              |
| ISI-2 tjedna postoperacijski     | 9,40±            | 1,18 | 9,96±              | 1,09 | <b>0,008</b> |
| ISI-6 tjedna postoperacijski     | 6,65±            | 1,25 | 6,64±              | 1,10 | 0,490        |
| ISI-24 tjedna postoperacijski    | 4,38±            | 1,16 | 4,24±              | 0,96 | 0,265        |
| PSQI-2 tjedna postoperacijski    | 8,08±            | 1,77 | 8,62±              | 1,59 | 0,059        |
| PSQI-6 tjedna postoperacijski    | 5,08±            | 1,01 | 5,26±              | 1,29 | 0,227        |
| PSQI- 24 tjedna postoperacijski  | 3,88±            | 1,04 | 3,90±              | 0,93 | 0,450        |
| SF-36-12 mjeseci postoperacijski | 83,35±           | 4,81 | 81,59±             | 6,36 | 0,064        |

Legenda: ISI: Insomnia Severity Scale, PSQI: Pittsburgh Sleep Quality Index, SF-36: Short Form Health Survey.



**Slika 4.** Dijagram intervalnih promjena srednjih vrijednosti procjene kvalitete života (SF-36) tijekom trajanja studije. Plava crta označava intervenciju na bazi tkivnog ljepila, a crvena crta označava kontrolu na bazi transkutanih šavova.

## **5. RASPRAVA**

Ovo ispitivanje, planirano i provedeno u nekoliko faza kao prospektivna randomizirana jednostruko slijepa klinička studija, odgovorilo je na važna pitanja o dugoročnim i kratkoročnim učincima različitih tehnika zatvaranja postoperacijske rane nakon otvorene dekompresije medijalnog živca. U kratkoročnim ishodima dokazali smo značajno poboljšanje estetskih ishoda i smanjenje postoperacijske boli, uz dugoročno poboljšanje elektroneurografskih pokazatelja medijalnog živca i snage stiska ruke, te brže poboljšanje kvalitete sna kod onih ispitanika gdje je operacijska rana zatvarana tkivnim ljepilom uz potkožni produljeni šav, u odnosu na zatvaranje rane standardnim transkutanom šavovima. Objedinjeni radovi proizašli iz ovog ispitivanja su sveobuhvatan prikaz svih razlika u ranim i kasnim kliničkim ishodima između standardne tehnike zatvaranja reza i zatvaranja reza tkivnim ljepilom na bazi n-butil 2 cijanoakrilata i 2-oktil cijanoakrilata kod bolesnika s otvorenom operacijom dekompresije karpalnog tunela.

U prvom dijelu ispitivanja, iz kojeg je proizašao prvi objavljeni rad, jasno je dokazano da je tehnika tkivne adhezije za zatvaranje rane značajno bolja nakon 2 i 6 tjedana u smislu estetskih učinaka i postoperacijske boli, od klasične tehnike transkutanog šava kod kirurški liječenih bolesnika sa SKT-om. Navedeni učinci nisu trajni, a nakon 12 tjedana dolazi do gubitka razlike u estetskim rezultatima i postoperativnoj boli, što smanjuje moguću praktičnu važnost izbora tehnike zatvaranja rane u kliničkoj praksi. Ipak, ne smije se zanemariti klinički značaj ožiljka ili postoperacijske boli. Naime, postoperacijski problemi nakon otvorene dekompresije SKT-a, kao što su produljena nelagoda ili funkcionalna oštećenja, ipak su značajni. Primjerice, Boya i sur.<sup>139</sup> su dokazali osjetljivosti ožiljka kod 7% i bol u 18% bolesnika podvrgnutih kirurškom liječenju SKT-a. Formiranje ožiljka nakon kirurške dekompresije otvorenog karpalnog tunela jedan je od najčešćih uzroka nelagode i funkcionalne nesposobnosti. Ovaj postupak može izazvati duboke ozljede kože i potkožnog tkiva, što može dovesti do hipertrofičnih ožiljaka i keloida koji značajno utječu na kvalitetu života.<sup>140,141</sup>

Upravo da bi se postigla manja postoperacijska bol i očuvala funkcionalna sposobnost, uz bolje estetske učinke, pokušane su razne modifikacije operacijskih tehnika dekompresije karpalnog tunela. Tako je, primjerice, u jednom istraživanju Donatijev šav rezultirao boljim estetskim učincima (mjenjenih kao POSAS skor) u usporedbi sa subkutanim produženim šavovima, unatoč činjenici da su obje tehnike općenito rezultirale niskim POSAS skorom i dobrim formiranjem ožiljka.<sup>142</sup> Ipak, u istoj studiji autori nisu mogli pronaći razlike između Donatijeva šava i produženog subkutanog šava u rezultatima postoperacijske boli nakon 2, 6 i 12 postoperativnih tjedana, mjerene kao VNRS skor. Ni druge slične modifikacije kirurškog postupka dekompresije nisu dokazale smanjenje učestalosti ili intenziteta postoperativne nelagode ili bolova.<sup>143,144</sup> Nasuprot tome, u našem ispitivanju dokazali smo jasne razlike u VNRS rezultatu za bol, i to već u 2. i 6. postoperativnom tjednu, dokazujući time prednost zatvaranje operacijske rane s pomoću tkivnog ljepila.

Isto tako, ni prethodna istraživanja raznih vrsta materijala konaca za šavove i njihov utjecaj na postoperativne komplikacije nakon dekompresije karpalnog tunela nisu pokazale razlike u kliničkim ishodima. U meta-analizi pet ispitivanja, Wade i sur.<sup>145</sup> zaključili su da nije jasno je li uporaba resorptivnih ili neresorptivnih šavova za zatvaranje kože nakon dekompresije karpalnog tunela uzrokovala bilo kakve razlike u nelagodima, boli (korištena je uglavnom VAS skala) ili estetskom učinku (korišten je uglavnom POSAS skor). Suprotno rezultatima tih studija, u našem ispitivanju je dokazana jasna prednost zatvaranja rane tkivnim ljepilom uz produženi potkožni resorptivni šav već nakon 2 i 6 tjedana u odnosu na transkutani šav, a vezano za bol i estetski učinak.

Posljednjih godina tkivno ljepilo na bazi cijanoakrilata postalo je često korišteno u mnogim granama kirurgije i u raznim kirurškim zahvatima, za osiguravanje i stabilizaciju zatvaranja postoperacijskih rana.<sup>146-148</sup> Unatoč njegovoj popularnosti, do sada nema dostatno uvjerljivih dokaza koji daju prednost ljepilima za kožu u odnosu na klasične šavove. Sustavna

analiza Cochrane nije otkrila razliku u estetskim rezultatima između ljepila za tkivo i standardnog zatvaranja rana kod traumatskih rana.<sup>149</sup> U sličnoj Cochrane sustavnoj analizi koja je obuhvatila 2 793 ispitanika, utvrđeno je da su šavovi čak bolji od ljepila za tkivo u sprječavanju dehiscencije rane, ali nisu pronađene razlike u infekciji rane kao ni estetske razlike mjerene kozmetičkim VAS skorom.<sup>122</sup> Za razliku od gore navedenih ispitivanja, u našem ispitivanju je dokazana značajna prednost zatvaranja rana ljepilom u estetskim postoperativnim učincima.

Iako je zatvaranje rana pomoću tkivnog ljepila za kožu proučavano u brojnim kirurškim zahvatima, nedostaju studije procjene učinkovitosti tkivnog ljepila nakon otvorene dekompresije karpalnog tunela. Nedavno je objavljeno prospektivno randomizirano kontrolirano ispitivanje koje je uspoređivalo ljepljivu traku i ljepilo za tkivo nanoseno nakon primarnog zatvaranja na različite dijelove istog kirurškog reza.<sup>123</sup> U tom istraživanju većina operacija obavljena je za dekompresiju karpalnog tunela (14 ispitanika) i karpometakarpalnu artroplastiku palca (14 ispitanika). Rane su inicijalno zatvorene 4-0 resorptivnim šavom, zatim su proksimalni i distalni dijelovi rane na kraju zatvoreni trakama (Steri Strips) ili 2-oktilcianoakrilatom (Dermabond). Autori su ocijenili ožiljke nakon otprilike tri mjeseca i došli do zaključka da su ljepljive trake donijele skromno, ali značajno poboljšanje u kozmetičkim rezultatima, u usporedbi s ljepilom za tkivo (rezultat POSAS) koji je procijenio kirurg. Ispitanici su uočili bolje kozmetičke rezultate s Steri-Strips nego s Dermabondom, iako razlike nisu bile statistički značajne. Sinha i sur.<sup>24</sup> proveli su prospektivnu randomiziranu studiju s ciljem usporedbe rezultata kirurških zahvata na šaci, koristeći zatvaranje tkivnim ljepilom (n-butil 2-cijanoakrilat) ili uobičajnu tehniku zatvaranja rana (4-0 monofilamentni šav). Od ukupno 50 ispitanika, njih 22 su imali operaciju SKT-a. Autori nisu mogli pronaći značajnu razliku u procjeni kozmetičkog ishoda procijenjenih 2 i 6 tjedana nakon operacije (srednji

kozmetički VAS rezultat u skupini s tkivnim ljepilom bio je 81, naspram 87 u skupini s šavovima).

Naše randomizirano kontrolirano ispitivanje pokazalo je da je primjena tkivnog ljepila uz produljeni transkutani šav nakon dekompresije karpalnog tunela dovela do boljeg estetskog učinka i poboljšanog zadovoljstva bolesnika, u usporedbi s kontrolnom skupinom koja je koristila klasične transkutane šavove kao postupak zatvaranja rana. Ti se učinci zadržavaju tijekom drugog i šestog tjedna, dok razlika postaje neznatna u dvanaestom tjednu. Vrijeme potrebno za zatvaranje rane bilo je kraće u skupini koja je primjenjivala tkivno ljepilo, naglašavajući jednostavnost upotrebe tog pripravka. Zanimljivo da je su u skupini s tkivnim ljepilom dokazana značajna negativna korelacija između indeksa tjelesne mase (engl. *body mass index*, BMI) i dobrih estetskih učinaka. Pretpostavili smo da su niže vrijednosti BMI-a povezane s pothranjenošću, što bi moglo imati utjecaj na suboptimalne estetske kirurške rezultate.

U drugom dijelu ove randomizirane kliničke studije dokazali smo, i u članku objavili, značajno šestomjesečno postoperativno povećanje stiska šake (što je važan funkcionalni pokazatelj), kao i povećanje parametara živčane vodljivosti medijalnog živca u skupini ispitanika čija je kirurška rana zatvorena tkivnim ljepilom i potkožnim šavovima, u usporedbi s skupini čija je kirurška rana zatvorena standardnim transkutanim šavovima. Nismo uspjeli dokazati razlike u BCTQ skor u između dvije kirurške tehnike zatvaranja rana.

Elektrofiziološki pokazatelji živčanog provođenja medijalnog živca važni su markeri težine kliničke slike i uznapređalosti SKT-a; utvrđeno je da su u korelaciji s razinama funkcionalne invalidnosti ruke. Na primjer, živčano provođenje mjereno kao srednja motorna latencija  $>4,2$  ms i srednja senzorna latencija  $>3,5$  ms smatraju se markerima ozbiljnog SKT-a.<sup>150</sup> U našem ispitivanju dokazali smo značajno postoperativno poboljšanje parametara senzorne provodljivosti srednjeg živca u skupini ispitanika čija je kirurška rana zatvorena

tkivnim ljepilom. Nadalje, u skupini zatvaranja rane ljepilom, značajno je više ispitanika postiglo postoperativnu senzornu brzinu  $>45$  m/s, postoperativnu vršnu distalnu senzornu latenciju  $<3,5$  ms i postoperativnu motoričku latenciju  $<4,2$  ms. Isto tako, pokazali smo značajno bolje rezultate postoperativnog stiska šake u skupini bolesnika kojima je rana zatvorena tkivnim ljepilom, što smatramo važnim rezultatom. Naime, dinamometrijsko mjerenje snage stiska predstavlja glavnu postoperativnu mjeru ishoda i ima utjecaj na dugoročne ishode bolesnika sa SKT-om.<sup>130</sup>

Rezultati našeg ispitivanja također su pokazali statistički značajno postoperativno poboljšanje elektroneurografskih, kliničkih i funkcionalnih parametara u svih bolesnika, kao i u pojedinim skupinama bolesnika. To naglašava učinkovitost kirurškog liječenja SKT-a u usporedbi s drugim modalitetima liječenja.

Pri tome mjerenje elektroneurografskih parametara medijalnog živca s ili bez mjerenja funkcionalnih sposobnosti ruke služi kao važan ishod za usporedbu učinkovitosti različitih modaliteta liječenja ili pak za usporedbu razlika između standardnih kirurških postupaka i kirurških modifikacija, kao što su mini-invazivne tehnike poput endoskopskih i mini-otvorenih pristupa karpalnom tunelu.<sup>151</sup> Primjerice, jedno prethodno randomizirano kliničko ispitivanje, koje je uspoređivalo lokalnu injekciju kortikosteroida i dekompresivnu kirurgiju za CTS, pronašlo je značajna poboljšanja u distalnoj motoričkoj latenciji, brzini senzorne provodljivosti i senzornoj amplitudi u kirurškoj skupini 12 mjeseci nakon liječenja.<sup>152</sup> U jednom istraživanju je dokazano da nema značajnih razlika između otvorenog ili endoskopskog oslobađanja karpalnog tunela u postoperativnim poboljšanjima kliničkih i elektromiografskih parametara testiranih prije operacije i tri mjeseca nakon operacije.<sup>153</sup> U sličnoj studiji, postoperativna latencija distalnog motora srednjeg živca, brzina prijenosa motora i akcijski potencijal osjetnog živca mjereni su tri, šest i 12 mjeseci nakon operacije i nisu se razlikovali između skupina nakon operacije SKT-a. Kontrolna skupina podvrgnuta je standardnoj kirurškoj dekompresiji, a



intervencijska skupina podvrgnuta je kirurškoj dekompresiji s jednom injekcijom plazme bogate trombocitima uvedene kroz mini-vakuumski dren.<sup>154</sup> Jedna retrospektivna studija, koja je uspoređivala endoskopsku s otvorenom dekompresijom karpalnog tunela, nije pronašla nikakve razlike u ishodima, uključujući elektromiografske indekse.<sup>155</sup> Slična prospektivna studija uspoređivala je endoskopsku dekompresiju karpalnog tunela s otvorenom dekompresijom karpalnog tunela i nije pronašla razlike između dviju tehnika u funkcionalnim i elektromiografskim rezultatima, unatoč značajnom skraćivanju distalne latencije srednjeg živčanog motora i povećanju brzine senzornih provođenja u oba skupine.<sup>156</sup> Jedno prospektivno randomizirano ispitivanje uspoređivalo je longitudinalnu epineurotomiju medijalnog živca s jednostavnom disekcijom karpalnog ligamenta i nije pronašlo razlike u distalnoj motoričkoj latenciji, distalnoj senzornoj latenciji ili snazi stiska nakon 180 dana praćenja.<sup>157</sup> Boumediene i sur. uspoređivali su dvije modifikacije kirurškog liječenja, uključujući primjenu gela karboksimetilceluloze/polietilen oksida i nisu mogli dokazati postoperativne razlike u distalnoj motoričkoj latenciji i brzini provođenja senzornih živaca između skupina.<sup>158</sup> Zaključno, većina prethodnih studija koje su uspoređivale različite kirurške tehnike nisu pronašle značajne razlike u funkcionalnim i/ili neurološkim ishodima između kirurških modaliteta liječenja SKT-a.

Iako su ljepila za kožu opsežno istražena za zatvaranje rana u raznim kirurškim zahvatima, do našeg ispitivanja samo je nekoliko studija procijenilo ljepila za kožu nakon dekompresije karpalnog tunela i izvijestilo samo o estetskim rezultatima. Ovo randomizirano kliničko ispitivanje prvo je koje pokazuje razlike između zatvaranja rana ljepilima za tkivo i klasičnog zatvaranja rana šavovima u bolesnika s SKT-a u pogledu neuroloških i funkcionalnih ishoda. Treba naglasiti da su ove značajne postoperativne razlike između skupina isključivo rezultat razlika u dvjema kirurškim tehnikama zatvaranja kirurške rane, tj. onoj koja koristi ljepilo u kombinaciji s produljenim potkožnim šavom i onoj koji koristi transkutane šavove. Naime, istiiskusni operateri operirali su obje skupine ispitanika bez statistički razlike u trajanju

zahvata između dviju skupina. Isto tako, nije dokazana značajna razlika između ranih i kasnih postoperativnih komplikacija u dvije skupine, pa se prema tome mogući utjecaj postoperacijskih komplikacija ne može pripisati razlikama u rezultatima. Konačno, dobivene značajne postoperativne razlike u mjerama ishoda ne mogu se pripisati isključivo upotrebi tkivnog ljepljiva, već i razlici između potkožnih i transkutanih šavova. Naime, ispitanici s potkožnim šavovima pošteđeni su neugode i boli skidanja šavova. Nadalje, klasično transkutano šivanje uključuje veću površinu šivanog tkiva (kože i potkožnog tkiva). Nasuprot tome, kod potkožnog šava tkivnim ljepljivom napetost rane je ravnomjerno raspoređena uz smanjeni pritisak konaca na kožu gdje se nalaze nociceptori, pa stoga ova skupina može ranije početi koristiti operiranu ruku.

U završnom dijelu ovog ispitivanja po prvi put je ispitivan utjecaj upotrebe ljepljiva za tkivo u zatvaranju postoperativnih rana nakon dekompresije karpalnog tunela na poremećaje spavanja i pokazatelje kvalitete života, a rezultati su objavljeni kao recenzirana međunarodna publikacija. Pri tome je dokazano da obje tehnike zatvaranja rana nakon operacije karpalnog tunela podjednako značajno utječu na poboljšanje poremećaja spavanja i kvalitete života. Ovaj povoljan učinak bio je značajan i dugotrajan, s tendencijom kontinuiranog poboljšanja tijekom razdoblja praćenja.

Naime, poboljšanje kvalitete sna vrlo je važan ishod liječenja bolesnika s SKT-om budući da poremećaji spavanja uvelike utječu na kvalitetu života bolesnika. Poboljšanje kvalitete sna obično se odvija vrlo brzo nakon operacije. Oko 80% bolesnika s SKT-om ima klinički značajne poremećaje spavanja (izražene kao Pittsburgh Sleep Quality Indexa -PSQI skor > 5).<sup>159</sup> Do našeg ispitivanja nije bilo dovoljno studija koje su uspoređivale različite tehnike liječenja SKT-a i njihov utjecaj na kvalitetu sna i kvalitetu života. Iako je dokazano da se kvaliteta sna i kvaliteta života značajno poboljšavaju nakon same kirurške dekompresije karpalnog tunela,<sup>160</sup> prije našeg ispitivanja postojao je tek vrlo mali broj studija provedenih

kao usporedna ispitivanja između kirurške dekompresije i drugih metoda liječenja u vezi s poremećajem spavanja i utjecaja na kvalitetu života. Primjerice, jedna analiza uspoređivala je otvorenu i endoskopsku dekompresiju karpalnog tunela, a pokazalo se da endoskopska metoda dovodi do bržeg rješavanja problema spavanja u usporedbi s otvorenom tehnikom.<sup>161</sup> Niedermeier i sur.<sup>162</sup> izvijestili su o poboljšanju poremećaja spavanja, pri čemu su rezultati mjerili pomoću PSQI ljestvice, koja se smanjila s 10,4 boda prije operacije na 7,8 bodova dva tjedna nakon operacije, te na 6,4 boda šest tjedana nakon operacije. Nasuprot tome, u jednoj prospektivnoj studiji, kvaliteta sna, mjerena ISI skorom, nije se povećala unutar sedam dana nakon otvorene dekompresije karpalnog tunela, niti u razdoblju praćenja između dva tjedna i tri mjeseca.<sup>163</sup> Nasuprot tome, u našem ispitivanju smo prikazali značajno poboljšanje kvalitete sna tijekom svih 24 tjedna praćenja u obje grupe ispitanika. Ako postoje, povoljni učinci operacije karpalnog tunela na parametre spavanja su dugotrajni; na primjer, Okkesim i sur. dokazali su u trećem do šestom mjesecu nakon operativne dekompresije karpalnog tunela bolju kvalitetu sna.<sup>164</sup> U našem ispitivanju smo također dokazali da poboljšanje kvalitete sna ima dugotrajni učinak, uz značajno i postepeno unapređenje tijekom dugog razdoblja praćenja. Postignut je isti učinak primjenom obje kirurške tehnike, no zabilježeno je značajno različito poboljšanje ISI rezultata dva tjedna nakon operacije kod ispitanika čije su rane zatvarane tkivnim ljepilom, u usporedbi sa skupinom gdje su rane zatvarane transkutanim šavovima. Time je dokazana prednost u brzini postizanja poboljšanja kvalitete sna u skupini kod koje je primjenjivano tkivno ljepilo s potkožnim produljenim šavom u odnosu transkutane šavove.

Primijećene su značajne razlike u ishodima nakon operacije, koje se mogu pripisati ne samo korištenju ljepila za tkivo, već i razlici između potkožnih i transkutanih šavova. Dakle, transkutano šivanje obuhvaća veću površinu zašivenog tkiva, uključujući kožu i potkožno tkivo. S druge strane, kod potkožnog šava uz upotrebu tkivnog ljepila, napetost rane se ravnomjerno raspoređuje, što rezultira manjim pritiskom šavova na koži, gdje se nalaze nociceptori. Kao

posljedica toga, bol i nelagoda su smanjeni, što rezultira kvalitetnijim snom. Ova brzina postizanja kvalitete sna može biti klinički značajna kod onih bolesnika koji imaju jako izražene poremećaje spavanja jer, prema nekim autorima, kod klasičnog zatvaranja rane ponekad dolazi tek jako kasno do poboljšanja kvalitete sna, kao što je pokazano u jednoj studiji gdje je nakon kirurške dekompresije karpalnog tunela došlo do mjerljivog poboljšanja sna (PSQI skora) tek nakon 12 do 24 mjeseca.<sup>165</sup>

U mnogim kirurškim studijama često korišteni alat koji ispituje globalnu kvalitetu života je Anketa o zdravlju u kratkom obliku - SF-36 (36-Item Short-Form Survey), koji je višestruko validiran instrument za procjenu kvalitete života povezane sa zdravljem.<sup>166</sup> Kod bolesnika sa SKT-om, upitnik SF-36 se vrlo malo koristio, a u malobrojnim istraživanjima je dokazano kako bolesnici sa SKT-om imaju niži rezultat SF-36 u usporedbi s općom populacijom, odnosno imaju značajno povećanje rezultata SF-36 nakon operacijske dekompresije karpalnog tunela.<sup>167</sup> Slično tome, naše je ispitivanje jasno pokazalo značajno poboljšanje ukupnog SF-36 rezultata od  $49,84 \pm 5,85$  na početku istraživanja, do  $82,46 \pm 5,68$  na kraju studije, odnosno 12 mjeseci nakon kirurške dekompresije. Zabilježeno je značajno unapređenje SF-36 rezultata u obje skupine ispitanika, i to u većoj mjeri nego u prethodnim istraživanjima. Na primjer, Galasso i sur. su u kod bolesnika sa SKT-om zabilježili značajno poboljšanje prosječnog ukupnog rezultata SF-36, koji je porastao s 38,7 na 44,3 šest mjeseci nakon operacijske dekompresije.<sup>168</sup> Do sada nije bilo usporednih studija koje su proučavale različite tehnike operacije ili tehnike zatvaranja kirurške rane na globalni skor kvalitete života. Iako smo u našem ispitivanju dokazali poboljšanje ukupnog SF-36 rezultata u skupini kojoj je rana zatvarana tkivnim ljepilom, u odnosu na skupinu kojoj je rana zatvarana transkutanim šavovima godinu dana nakon operacije ( $83.35 \pm 4.81$  naspram  $81.59 \pm 6.36$ ), navedena razlika nije dosegla statističku značajnost.

Zaključno, tehnika zatvaranja rane potkožnim šavom i tkivnim ljepilom dovela je do bržeg poboljšanja ozbiljnosti nesаницe dva tjedna nakon operacije, u odnosu na skupinu čija je

rana zatvarana transkutanim šavovima. Također, u ostalim mjerama ishoda tijekom postoperativnog praćenja, primijećena je tendencija boljim rezultatima u skupini čije su kirurške rane zatvorene ljepilom za tkivo, iako te razlike nisu postigle razinu statističke značajnosti. Ipak, ovo može sugerirati određene prednosti ljepila za tkivo u zatvaranju kirurških rana tijekom otvorene dekompresije karpalnog tunela. Ovo je prvo ispitivanje koje potvrđuje učinkovitost i neinferiornost korištenja ljepila za tkivo u zatvaranju kirurških rana tijekom operacije otvorenog karpalnog tunela s ciljem poboljšanja kvalitete sna i kvalitete života.

Ova tri rada predstavljaju sveobuhvatno i jedinstveno ispitivanje kojim smo dokazali značajne razlike u promjeni živčane provodljivosti i funkciji šake, postoperativnoj boli, estetskom rezultatu, te brzini poboljšanja kvalitete sna, ovisno o načinu zatvaranje rane u bolesnika koji su operirani otvorenom dekompresijom karpalnog tunela. Ipak, objašnjenje ovako dobivenih rezultata nije jednostavno i može se dijelom temeljiti na dosadašnjim istraživanjima cijeljenja rane, no takvih istraživanja nije puno i uglavnom se temelje na životinjskim modelima ili *in vitro* istraživanjima. Neki od tih životinjskih modela ispitivali su način anastomoziranja presječenih živaca tehnikom šivanja i tehnikom lijepljenja te su dokazali moguću prednost tehnike anastomoze živca tkivnim ljepilom na bazi cijanoakrilata u smislu poboljšanja funkcije živca.<sup>169</sup> U sličnim istraživanjima histološkim analizama nije pokazana razliku u promjeru, gustoći vlakana ili broju regeneriranih mijeliniziranih motornih i senzornih aksona distalno od mjesta popravka između skupina presječenih živaca lijepljenih cijanoakrilatnim ljepilom i konvencionalnim epineuralnim šavovima.<sup>170</sup> U jednom životinjskom modelu pokazano je da cijanoakrilat, korišten kao tkivno ljepilo za rekonstrukciju perifernih živaca, izaziva povećanu upalnu reakciju (više imunoreaktivnih makrofaga), što čak može imati prednosti u odnosu na konvencionalne šavove jer izaziva wallerijansku degeneraciju živca koja može povećati sposobnost regeneracije živca.<sup>171</sup> Stoga je jedno od

moćuĉih objašnjenja rezultata nařeg ispitivanja upravo lokalno povećanje upale izazvano tkivnim ljepilom na bazi cijanoakrilata koje povoljno djeluje na regeneraciju medijalnog ųivca koji se anatomske nalazi udaljen samo nekoliko milimetara od mjesta aplikacije tkivnog adheziva.

Kao ųto je već prije naglašeno, značajne postoperativne razlike u mjerama ishoda posljedica su isključivo razlika u naćinu zatvaranja kirurške rane. Pri tome se ne radi isključivo o utjecaju ovdje istraųivanog tkivnog ljepila. Naime, intervencijski postupak sastojao se u primjeni tkivnog ljepila (n-butil 2 cijanoakrilata i 2-oktil cijanoakrilata) uz kontinuirani potkoųni řav, dok je kontrolnoj skupini kirurška rana zatvarana transkutanim řavovima. U tom kontekstu potrebno je tumaćiti neke od dobivenih rezultata. Primjerice, ispitanici u intervencijskoj skupini pořtećeni su boli skidanja transkutanih řavova, jer su imali potkoųni resorptivni konac. Nadalje, klasićno transkutano řivanje u kontrolnoj skupini ukljućuje veću povrřinu řivanog tkiva (koųe i potkoųnog tkiva) te su zahvaćeni receptori za bol u koųi. Nasuprot tome, kod potkoųnog řava, uz tkivno ljepilo napetost rane je ravnomjerno rasporećena uz smanjeni pritisak konaca na koųu gdje se nalaze nociceptori, pa stoga ova skupina moųe ranije poćeti koristiti operiranu ruku, ćime poboljšava funkcionalnost i oporavak ųivca, a postoperativna bol je bila manja. Ravnomjernija rasporećenost napetosti rane moguće je objašnjenje boljih estetskih ućinaka u ranoj postoperacijskoj fazi. I konaćno, u intervencijskoj skupini koriřten je uz tkivno ljepilo produųni subkutani řav poliglaktin 910 (*Vicryl*), koji je apsorpcijski sintetski konac. Dobro je poznata ćinjenica kako dugotrajan proces resorpcije konca dovodi do lokalne mikroinflamacije.<sup>172</sup> Naša je hipoteza da je pojaćana produljena lokalna upala niskog intenziteta u blizini medijalnog ųivca poboljšala proces oporavka medijalnog ųivca i time dovela do izmjerenih kliniķkih poboljšanja, ųto u nařem hipotetskom modelu djeluje sinergistiķki s lokalnim povećanjem mikroinflamacije izazvanim tkivnim ljepilom.

## **5.1. Ograničenja istraživanja**

Ovo prospektivno randomizirano jednostruko slijepo kontrolirano intervencijsko ispitivanje ipak ima nekih ograničenja. Prvenstveno, ispitivanje je bilo ograničeno na jedan klinički centar. Nadalje, razdoblje praćenja možda nije dovoljno dugo da bi se izvukao zaključak o dugoročnim učincima intervencije, kao što su dugotrajni razvoj ožiljka, dugotrajni neurološki i funkcionalni ishodi ili parametri globalne kvalitete života. Konačno, za potpuno razumijevanje utjecaja intervencije bilo bi potrebno pratiti dodatne kliničke, histološke i biomehaničke parametre, čime bi se možda detaljnije etiološki objasnile dobivene značajne razlike u kliničkim ishodima koje su utvrđene ovim kliničkim ispitivanjima, a koje se za sada mogu tumačiti samo na temelju teorijskih rasprava ili na temelju rezultata nekih dosadašnjih istraživanja, prvenstveno histoloških studija. Stoga su za potpuno razumijevanje utjecaja opisane intervencije na promatrane kliničke ishode potrebna daljnja istraživanja.

## **6. ZNANSTVENI DOPRINOS OBJEDINJENIH RADOVA**



Znanstveni doprinos i klinički značaj ovog ispitivanja i proizašlih publiciranih radova sastoji se u razumijevanju učinaka primjene tkivnog ljepila pri zatvaranju rane nakon dekompresije karpalnog tunela. Naime, u ovom opsežnom ispitivanju dokazali smo da način zatvaranje rane može utjecati na promjene u živčanoj provodljivosti i funkciji šake, na postoperativnu bol i na estetski rezultat, te na brzinu poboljšanja kvalitete sna u bolesnika koji su operirani otvorenom dekompresijom karpalnog tunela. Do ovog ispitivanja nije bilo poznato postoje li razlike u kliničkim ishodima ovisno o načinu zatvaranja postopracijske rane nakon otvorene dekompresije karpalnog tunela, odnosno do sada nije provedeno istraživanje koje uključuje dugoročno praćenje ispitanika uz veliki broj važnih kliničkih varijabli. Stoga ovo ispitivanja i iz njega proizašli doktorski rad, temeljen na objedinjenim publikacijama, predstavlja važnu znanstvenu i kliničku spoznaju te je bitan doprinos i novina u razumijevanju primjene novog adhezijskog materijala na bazi cijanoakrilata, točnije kombinacije NBCA (n-butil 2 cijanoakrilata) i OCA (2-oktil cijanoakrilata) pri zatvaranju rane nakon dekompresije karpalnog tunela, što, u konačnici, može doprinijeti razvoju novih terapijskih pristupa liječenju sindroma karpalnog tunela, kao i razvoju primjene ovog materijala za druge kirurške discipline ili općenito medicinske svrhe.<sup>173</sup>

Naime, ovo ispitivanja doprinos je novim spoznajama u primjeni tkivnih adheziva, što je u znanstvenoj literaturi općenito nedovoljno istražena problematika, a gotovo potpuno je neistražena kod otvorene dekompresije karpalnog tunela. Smatramo da će rezultati našeg rada, u konačnici, potaknuti daljnja istraživanja tkivnih ljepila u mnogim poljima, a osobito istraživanja ovog inovativnog tkivnog adheziva koji se sastoji se od n-butil 2 cijanoakrilata i 2-oktil cijanoakrilata.

Nadalje, vjerujemo da će ovo ispitivanje potaknuti dodatna istraživanja koja doprinose boljem razumijevanju utjecaja cijeljenja rane promatrane kroz tehniku šivanja na kliničke ishode operacijskog liječenja. Potrebna su naime dodatna istraživanja koja bi objasnila naše

rezultate, odnosno kliničko poboljšanje neuroloških i funkcionalnih ishoda vezanih za korištenje tkivnog ljepila u kombinaciji s produljenim potkožnim šavom. Dodatnim istraživanjima mogli bi se objasniti povoljni učinci ovdje opisane tehnike zatvaranja kirurške rane, primjerice histološkim, citološkim i biokemijskim analizama rane i ožiljnog tkiva.

## **7. ZAKLJUČCI**

Ovo randomizirano kontrolirano ispitivanje pokazalo je značajne razlike u promatranim kliničkim učincima između dva načina zatvaranja kirurške rane nakon otvorene kirurške dekompresije SKT-a: tkivnim ljepilom na bazi cijanoakrilata uz produljeni potkožni šav, što je bila intervencija koja je uspoređivana sa standardnom tehnikom zatvaranje rane transkutanim šavovima.

Dokazano je da korištenje adhezijskog materijala na bazi cijanoakrilata ima prednost u odnosu na transkutane šavove u smislu boljih estetskih ishoda i manje postoperacijske boli, i to 2 i 6 tjedana nakon operacije. Međutim, nakon 12 tjedana nije bilo značajne razlike u navedenim ishodima. Nisu nađene razlike u ranim (15 dana nakon operacije) i kasnim (12 tjedana nakon operacije) poslijeoperacijskim komplikacijama između dviju tehnika zatvaranja kirurške rane.

Nadalje, adhezijski materijal na bazi cijanoakrilata, u kombinaciji s potkožnim kontinuiranim šavom za zatvaranje rana nakon otvorene dekompresije karpalnog tunela, ima značajnu prednost u odnosu na transkutane šavove u smislu poboljšanja funkcionalnosti šake mjerene kao snaga stiska ruke, uz značajno poboljšanje elektrofiziološke vodljivosti medijalnog živca, prvenstveno njegove senzorne, a manje motoričke komponente, i to šest mjeseci nakon operacije.

Obje tehnike zatvaranja kirurške rane nakon otvorene dekompresije karpalnog tunela dovode dugoročno do značajnog poboljšanja kvalitete sna i kvalitete života vezane uz zdravlje. Moguće prednosti tkivnog ljepila u odnosu na šavove uključuju brže smanjenje težine ozbiljnosti nesanice, odnosno značajno smanjenje nesanice već dva tjedna nakon operacije.

Kao zaključak, ovo ispitivanje je pokazalo da bi adhezijske smjese na bazi cijanoakrilata mogle imati prednost u usporedbi s konvencionalnim tehnikama šivanja kože za zatvaranje kirurških rana nakon otvorene dekompresije karpalnog tunela u pogledu bržeg poboljšanja estetskih učinaka i postoperacijske boli s očekivanim boljim učincima na oporavak medijalnog

živca i poboljšanje snage ruke, što u konačnici dovodi do poboljšanja kvalitete sna, smanjenja težine nesanice i poboljšanja ukupne kvalitete života.

Ovo ispitivanje je jasno pokazalo da se zatvaranje rane nakon operacije dekompresije karpalnog tunela može učinkovito i sigurno realizirati ljepilima za tkivo na bazi cijanoakrilata, pri čemu ne samo da nema inferiornosti tkivnih ljepila u odnosu na standardnu tehniku zatvaranja rane, nego su, naprotiv, dokazane i mnoge kliničke prednosti tkivnog ljepila.

## **8. SAŽETAK**

**Ciljevi:** Sindrom karpalnog tunela predstavlja najčešću perifernu neuropatiju koja se javlja uslijed pritiska na medijalni živac unutar karpalnog tunela. Učinak tkivnih adheziva kao materijala za zatvaranje rana nakon otvorene operacije dekompresije karpalnog tunela nije do sada istraživan. Cilj ovog ispitivanja bio je procijeniti rane i kasne kliničke ishode usporedbom dvaju metoda zatvaranja postoperacijske rane nakon otvorene operacije karpalnog tunela kod ispitanika koji su randomizirani za korištenje ljepila za tkivo ili šavova.

**Metodologija:** Ova randomizirana jednocentrična jednostruko slijepa kontrolirana prospektivna studija započeta u travnju 2022. godine obuhvatila je 100 ispitanika (70 žena) u dobi od  $61,56 \pm 12,03$  godina, nasumično raspoređenih na zatvaranje rane šavovima ( $n = 50$ ) ili za zatvaranje rana tkivnim ljepilom ( $n = 50$ ) Glubran Tiss 2®. Ishodi su procijenjeni postoperativno tijekom perioda praćenja u intervalima od 2, 6 i 12 tjedana. Procjena ožiljka provedena je korištenjem ljestvice za procjenu ožiljaka bolesnika i promatrača (POSAS) i kozmetičke vizualne analogne ljestvice (VAS). Za ocjenu boli upotrijebljena je verbalna numerička skala (VNRS). Zabilježene su rane i kasne postoperacijske komplikacije. Prije operacije i šest mjeseci nakon operacije procijenjeni su snaga ruke, elektroneurografske karakteristike medijalnog živca i Bostonski upitnik karpalnog tunela. Ishodi kvalitete života i kvalitete sna su procijenjeni tijekom 12-mjesečnog postoperativnog praćenja. Za procjenu poremećaja spavanja korišteni su Pittsburgh Sleep Quality Index (PQSI) i Insomnia Severity Scale (ISI), a za procjenu kvalitete života povezane sa zdravljem ukupni SF-36 (36-Item Short Form Survey).

**Rezultati:** Postojale su značajne razlike između zatvaranja rane ljepilom i zatvaranja rane šavom u intervalima od dva tjedna i šest tjedana nakon operacije na ljestvicama POSAS i kozmetički VAS (bolji estetski učinak tehnikom zatvaranja rane ljepilom), s manje postoperativne boli u istim intervalima. S intervalom od 12 tjedana, razlike u rezultatima nisu bile statistički značajne. Nije bilo značajnih razlika u ranim ili kasnim postoperacijskim

komplikacijama. Značajne razlike između tehnika zatvaranja rana na temelju ljepila i šavova utvrđene su u šestomjesečnoj postoperativnoj snazi stiska šake ( $25,06 \pm 6,69$  naspram  $21,41 \pm 5,62$  kg,  $P = 0,002$ ), postoperativnoj senzornoj amplitudi ( $10,08 \pm 5,50$  naspram  $7,54 \pm 5,41$  mV,  $P = 0,012$ ) i postoperativnoj senzornoj brzini medijalnog živca ( $42,22 \pm 11,04$  naspram  $35,23 \pm 16,40$  m/s,  $P = 0,008$ ). U skupini s tkivnim ljepilom, značajno je više ispitanika postiglo postoperativnu senzornu brzinu veću od 45 m/s (47,9% naspram 22,0%,  $P = 0,006$ ), postoperativnu distalnu senzornu latenciju manju od 3,5 ms (89,6% naspram 84,0%,  $P = 0,304$ ) i postoperativnu motoričku latenciju manju od 4,2 ms (60,42% prema 38,00%,  $P = 0,022$ ). Ljestvice PQSI, ISI i SF-36 nisu pokazale statistički značajne razlike među skupinama tijekom praćenja, osim u rezultatu ISI dva tjedna nakon operacije ( $9,40 \pm 1,18$  u skupini koja je koristila tkivno ljepilo naspram  $9,96 \pm 1,09$  u skupini sa šavovima,  $P = 0,008$ ). Rezultati PQSI, ISI i SF-36 za sve ispitanike i skupine kontinuirano su se poboljšavali u svim vremenskim intervalima praćenja nakon operacije. Ukupan rezultat SF-36 povećao se 12 mjeseci nakon operacije ( $49,84 \pm 5,85$  naspram  $82,46 \pm 5,68$ ,  $P < 0,001$ ).

**Zaključak:** Tkivna ljepila na bazi cijanoakrilata mogu imati prednost u usporedbi s konvencionalnim tehnikama šivanja kože za zatvaranje kirurških rana nakon otvorene dekompresije karpalnog tunela u pogledu bržeg poboljšanja estetskih učinaka i postoperacijske boli, s očekivanim boljim učincima na oporavak srednjeg živca i poboljšanje snage ruke, što u konačnici dovodi do poboljšanja kvalitete sna, smanjenja težine nesanice i poboljšanja ukupne kvalitete života. Zatvaranje rane nakon operacije dekompresije karpalnog tunela može se učinkovito i sigurno izvršiti tkivnim ljepilom na bazi cijanoakrilata, uz očekivano poboljšanje ranih i kasnih kliničkih ishoda.

**Registracija istraživanja:** [Clinicaltrial.gov NCT 05747989](https://clinicaltrials.gov/ct2/show/study/NCT05747989), [NCT 05808855](https://clinicaltrials.gov/ct2/show/study/NCT05808855).



## **9. SUMMARY**

## THE INFLUENCE OF SURGICAL WOUND CLOSURE TECHNIQUES FOLLOWING CARPAL TUNNEL DECOMPRESSION ON FUNCTIONAL, NEUROLOGICAL AND AESTHETIC OUTCOMES AND ON LIFE QUALITY: A PROSPECTIVE RANDOMIZED CLINICAL TRIAL

**Aims:** Compression of the medial nerve in the carpal tunnel results in the most prevalent peripheral neuropathy, known as carpal tunnel syndrome. The effect of tissue adhesives as a wound closure material after open carpal tunnel decompression surgery has not been investigated. The aim of the study was to evaluate early and late clinical outcomes by comparing two modalities of postoperative wound closure after open carpal tunnel surgery in subjects randomized to either tissue adhesive or sutures.

**Methods:** A randomized, single-center, single-blind, controlled prospective study started in April 2022 included 100 subjects (70 women) aged  $61.56 \pm 12.03$  years, randomly assigned to wound closure with sutures ( $n = 50$ ) or to closure wound with tissue glue ( $n = 50$ ) Glubran Tiss 2®. During the follow-up phase, postoperative outcomes were assessed at 2, 6, and 12 week intervals. Cosmetic VAS (Visual Analog Scale) and POSAS (Patient and Observer Scar Evaluation Scale) were used for scar assessment. Pain was measured using the VNRS (Verbal Number Rating Scale). Early and late postoperative complications were recorded. Hand strength, electroneurographic characteristics of the median nerve and the Boston Carpal Tunnel Questionnaire were assessed before surgery and six months after surgery. Quality of life and sleep quality outcomes were assessed during the 12-month postoperative follow-up. The Pittsburgh Sleep Quality Index (PQSI) and Insomnia Severity Scale (ISI) were used to assess sleep disorders, and the overall SF-36 (36-Item Short Form Survey) was used to assess health-related quality of life.

**Results:** There were significant differences between wound closure with glue and wound closure with suture at 2-week and 6-week postoperative intervals on the POSAS and cosmetic VAS scales (better aesthetic effect with the technique of wound closure with glue), with less


postoperative pain at the same intervals. After 12 weeks, the differences were not statistically significant. There were no significant differences in early or late postoperative complications. Significant differences between wound closure techniques based on glue and sutures were found in 6-month postoperative hand grip strength ( $25.06 \pm 6.69$  vs.  $21.41 \pm 5.62$  kg,  $P = 0.002$ ), postoperative sensory amplitude ( $10.08 \pm 5.50$  vs.  $7.54 \pm 5.41$  mV,  $P = 0.012$ ) and postoperative sensory velocity of the median nerve ( $42.22 \pm 11.04$  vs.  $35.23 \pm 16.40$  m/s,  $P = 0.008$ ). In the tissue adhesive group, significantly more subjects achieved postoperative sensory velocity greater than 45 m/s (47.9% vs. 22.0%,  $P = 0.006$ ), postoperative distal sensory latency less than 3.5 ms (89.6 % vs. 84.0%,  $P = 0.304$ ) and postoperative motor latency less than 4.2 ms (60.42% vs. 38.00%,  $P = 0.022$ ). With the exception of the ISI score two weeks following surgery ( $9.40 \pm 1.18$  in the tissue adhesive group vs.  $9.96 \pm 1.09$  in the with sutures,  $P = 0.008$ ), there was no statistically significant difference in the PQSI, ISI, or SF-36 scores across groups during follow-up. At every postoperative follow-up interval, the PQSI, ISI, and SF-36 scores for every subject and group showed steady improvement. A year following surgery, the SF-36 total score increased ( $49.84 \pm 5.85$  vs.  $82.46 \pm 5.68$ ,  $P < 0.001$ ).

**Conclusion:** Cyanoacrylate-based tissue adhesives may have an advantage compared to conventional skin suturing techniques for surgical wound closure after open carpal tunnel decompression in better of aesthetic effects and less postoperative pain with expected better effects on median nerve recovery and improvement of hand strength, with consecutively improvement in the quality of sleep, reduction of insomnia severity and improvement in the overall quality of life. Wound closure after carpal tunnel decompression surgery can be effectively and safely performed with cyanoacrylate-based tissue adhesive with expected improvement in early and late clinical outcomes.

**Study registration:** Clinicaltrial.gov NCT 05747989, NCT 05808855.

## **10. ŽIVOTOPIS**

Ime: **Veridijana Šunjić Roguljić**



**OBRAZOVANJE I OSPOSOBLJAVANJE:**

2021. položen subspecijalistički ispit iz uže specijalnosti opće kirurgije-plastične kirurgije

2018.- 2019. položen tečaj stalnog sudskog vještaka za opću kirurgiju, od 2021. i za plastičnu kirurgiju

2016.- polaznik poslijediplomskog doktorskog studija „Klinička medicina utemeljena na dokazima“, Medicinski fakultet Sveučilišta u Splitu

2013. položen specijalistički ispit iz opće kirurgije na Klinici za kirurgiju u KBC-u Split

2006. položen državni ispit za doktore medicine u Ministarstvu zdravstva i socijalne skrbi u Zagrebu

2003.-2005. Poslijediplomski znanstveni studij “Biomedicina” na Medicinskom fakultetu u Splitu

1994.-2003. Medicinski fakultet, Sveučilište u Rijeci

1989.-1994. I. jezična gimnazija “Natko Nodilo”, Split

1982.-1989. Osnovna škola“ Sućidar“, Split

**RADNO ISKUSTVO:**

Od 2021. zaposlena na radno mjesto subspecijaliste plastične kirurgije u KBC-u Split

2014.-2021. zaposlena na radno mjesto specijaliste opće kirurgije u KBC-u Split

2013.-2014. zaposlena na radnom mjestu specijaliste opće kirurgije u Poliklinici „Analiza“ u Dugopolju

2008.-2013. specijalizacija iz opće kirurgije za potrebe Specijalne bolnice za ortopediju, plastičnu kirurgiju i urologiju «Salus ST» obavljena u KBC-u Split.

2006.-2007. doktor medicine u Ustanovi za stariju dob i kućnu njegu «Vita» u Podstrani

2004.-2005. pripravnički staž za doktore medicine u Kliničkom bolničkom centru u Splitu

### **ISTRAŽIVAČKI RAD:**

2004.-2007.: Study Site Coordinator u zdravstvenim istraživanjima na Klinici za kirurgiju, Odjelu torakalne kirurgije u Splitu pri istraživanju primjene imunološkog cjepiva kod operiranih pacijenata od karcinoma pluća.

### **Publicirani radovi:**

1. **Sunjic Roguljic V**, Roguljic L, Kovacic V, Jukic I. A Comparison of Tissue Adhesive Material and Suture as Wound-Closure Techniques following Carpal Tunnel Decompression: A Single-Center Randomized Control Trial. *J Clin Med.* 2023 14;12:2864. doi:10.3390/jcm12082864.
2. **Sunjic Roguljic V**, Roguljic L, Kovacic V, Bilic I, Jukic I. The Influence of the Tissue Adhesive Material as a Surgical Wound-Closure Technique Following Carpal Tunnel Decompression on Neurological and Functional Outcomes: A Single-Center Randomized Controlled Trial. *Cureus.* 2024;16:e53312. doi: 10.7759/cureus.53312.
3. **Sunjic Roguljic V**, Roguljic L, Jukic I, **Kovacic V**. The Influence of Wound Closure Techniques after Surgical Decompression in Patients with Carpal Tunnel Syndrome on Sleep Disturbance and Life Quality: A Prospective Comparison of Surgical Techniques. *Clin Pract.* 2024; 14:546-555. doi.org/10.3390/clinpract14020042.
4. Dobrila-Dintinjana R, **Sunjic V**, Dintinjana M. Pain relief in patients with gastrointestinal cancers *The American Journal of Gastroenterology Elsevier* September 2001; 96 (9) DOI:10.1016/S0002-9270(01)03386-X
5. Dobrila-Dintinjana R, **Sunjic V**, Dintinjana M, Kovač D. Complete remission in patients with unresectable pancreatic cancer: dream or achievable event *The American Journal of Gastroenterology* September 2001; 96 (9) DOI: 10.1016/S0002-9270(01)03005-2

## **JEZIČNE VJEŠTINE:**

**Materinski jezik: hrvatski**

**Drugi jezici: engleski**, slušanje C2, čitanje C2, pisanje C2, govorna produkcija C2, govorna interakcija C2, **njemački**, slušanje B1, čitanje B1, pisanje B1, govorna produkcija B1, govorna interakcija B1.

## **DIGITALNE VJEŠTINE:**

MS Office (Word Excel PowerPoint) | Komunikacijski programi (Skype Zoom TeamViewer)  
| Internet | Informacije i komunikacija (pretraživanje interneta)

## **11. LITERATURA**



- 
1. Brinar V. Neurologija za medicinare. 2. izdanje. Zagreb: Medicinska naklada; 2009.
  2. Aroori S, Spence RA. Carpal tunnel syndrome. *Ulster Med J.* 2008;77:6-17.
  3. Ibrahim I, Khan W, Goddard N, Smitham P. Carpal tunnel syndrome: A review of the recent literature. *Open Orthop J.* 2012;6:69-76.
  4. Ghasemi-Rad M, Nosair E, Vegh A, Mohammadi A, Akkad A, Lesha E i sur. A handy review of carpal tunnel syndrome: From anatomy to diagnosis and treatment. *World J Radiol.* 2014 28;6:284-300.
  5. Chammas M. Carpal tunnel syndrome. *Chir Main.* 2014; 33:75-94.
  6. Bland JDP. Carpal tunnel syndrome. *BMJ.* 2007;335:343-6.
  7. Simovic D, Weinberg DH. Carpal tunnel syndrome. *Arch Neurol.* 2000;57:754-5.
  8. Paget J. Lectures on surgical pathology: delivered at the Royal College of Surgeons of England. 2. izdanje. Philadelphia: Lindsay and Blakiston; 1854, str. 42.
  9. Putnam JJ. A series of cases of paraesthesia, mainly of the hand, of periodic occurrence, and possibly of vaso-motor origin. *Archives of Medicine (NewYork).* 1880;4:147-62.
  10. Keen WW. The symptomatology, diagnosis and surgical treatment of cervical ribs. *Am J Med Sci.* 1907;133:173-218.
  11. Pfeffer GB, Gelberman RH, Boyes JH, Rydevik B. The history of carpal tunnel syndrome. *J Hand Surg Br.* 1988;13:28-34.
  12. Learmonth JR. The principle of decompression in the treatment of certain diseases of peripheral nerves. *Surg Clin North Am.* 1933;13:905-13.
  13. Phalen GS. The carpal-tunnel syndrome. Seventeen years' experience in diagnosis and treatment of six hundred fifty-four hands. *J Bone Joint Surg Am.* 1966;48:211-28.
  14. Kremer M, Gilliatt RW, Golding JS, Wilson TG. Acroparaesthesiae in the carpal-tunnel syndrome. *Lancet.* 1953;265:590-5.
  15. Marušić A. Anatomija čovjeka. 2. izdanje. Zagreb: Medicinska naklada; 2002.
  16. Moore KL, Dalley II FA, Agur AMR. Clinically Oriented Anatomy. 7. izdanje. Philadelphia: Lippincott Williams & Wilkins; 2005.
  17. Presazzi A, Bortolotto C, Zacchino M, Madonia L, Draghi F. Carpal tunnel: Normal anatomy, anatomical variants and ultrasound technique. *J Ultrasound.* 2011;14:40-6.
  18. Henry BM, Zwinczewska H, Roy J, Vikse J, Ramakrishnan PK, Walocha JA i sur. The prevalence of anatomical variations of the median nerve in the carpal tunnel: A systematic review and meta-analysis. *PLoS One.* 2015;25:e0136477

- 
19. Pećina M, Krmpotić-Nemanić J. Kanalikularni sindromi. Zagreb: Medicinski fakultet Sveučilišta u Zagrebu; 1987.
  20. Kahle W, Leonhardt H, Platzer W, Priručni anatomski atlas – Sustav organa za pokretanje. 4. izdanje. Zagreb: Jumena; 1989.
  21. MacDermid JC, Doherty T. Clinical and electrodiagnostic testing of carpal tunnel syndrome: a narrative review. *J Orthop Sports Phys Ther.* 2004;34:565-88.
  22. Unver Dogan N, Uysal II, Karabulut AK, Seker M, Ziylan T. Communications between the palmar digital branches of the median and ulnar nerves: A study in human fetuses and a review of the literature. *Clin Anat.* 2010;23:234-41.
  23. Basiri K, Katirji B. Practical approach to electrodiagnosis of the carpal tunnel syndrome: A review. *Adv Biomed Res.* 2015;4:50.
  24. Gelfman R, Melton LJ, Yawn BP, Wollan PC, Amadio PC, Stevens JC. Long-term trends in carpal tunnel syndrome. *Neurology.* 2009;72:33–41.
  25. Atroshi I, Englund M, Turkiewicz A, Tägil M, Petersson IF. Incidence of physician-diagnosed carpal tunnel syndrome in the general population. *Arch Intern Med.* 2011;171:943–4.
  26. Atroshi I, Gummesson C, Johnsson R, Onsteinn E, Ranstam J, Rosen I. Prevalence of carpal tunnel syndrome in a general population. *JAMA.* 1999;282:153–8.
  27. Stevens JC, Sun S, Beard CM, O'Fallon WM, Kurland LT. Carpal tunnel syndrome in Rochester, Minnesota, 1961 to 1980. *Mayo Clin Proc.* 1988;38:134-8.
  28. Mackinnon SE, Novak CB. Repetitive strain in the workplace. *J Hand Surg Am.* 1997;22:2-18.
  29. Kozak A, Schedlbauer G, Wirth T, Euler U, Westermann C, Nienhaus A. Association between work-related biomechanical risk factors and the occurrence of carpal tunnel syndrome: an overview of systematic reviews and a meta-analysis of current research. *BMC Musculoskelet Disord.* 2015;16:231.
  30. Cheadle A, Franklin G, Wolfhagen C, Savarino J, Liu PY, Salley C i sur. Factors influencing the duration of work-related disability: a population-based study of Washington State workers' compensation. *Am J Public Health.* 1994;84:190-6.
  31. Meems M, Truijens SEM, Speak V, Visser LH, Pop VJM. Prevalence, course and determinants of carpal tunnel syndrome symptoms during pregnancy: a prospective study. *BJOG.* 2015;122:1112-8.

- 
32. Oktayoglu P, Nas K, Kiliç F, Tasdemir N, Bozkurt M, Yildiz I. Assessment of the Presence of Carpal Tunnel Syndrome in Patients with Diabetes Mellitus, Hypothyroidism and Acromegaly. *J Clin Diagn Res.* 2015;9:OC14-8.
  33. Gunnoo N, Ebelin M, Arrault M, Vignes S. Impact of carpal tunnel syndrome surgery on women with breast cancer-related lymphedema. *Breast Cancer Res Treat.* 2015;152:683-6.
  34. Yurdakul FG, Bodur H, Cakmak OO, Ates C, Sivas F, Eser F i sur. On the Severity of Carpal Tunnel Syndrome: Diabetes or metabolic Syndrome. *J Clinic Neurol.* 2015;11: 234-40.
  35. Pourmemari MH, Shiri R. Diabetes as a risk factor for carpal tunnel syndrome: a systematic review and metaanalysis. *Diabet Med.* 2015;33:10-6.
  36. Solomon DH, Katz JN, Bohn R, Mogun H, Avorn J. Nonoccupational risk factors for carpal tunnel syndrome. *J Gen Intern Med.* 1999;14:310-4.
  37. Hakim AJ, Cherkas L, El Zayat S, MacGregor AJ, Spector TD. The genetic contribution to carpal tunnel syndrome in women: a twin study. *Arthritis Rheum.* 2002;47:275-9.
  38. Falkiner S, Myers S. When exactly can carpal tunnel syndrome be considered work-related? *ANZ J Surg.* 2002;72:204-9.
  39. Lozano-Calderón S, Anthony S, Ring D. The quality and strength of evidence for etiology: example of carpal tunnel syndrome. *J Hand Surg Am.* 2008;33:525-38.
  40. Chammas M, Boretto J, Burmann LM, Ramos RM, Dos Santos Neto FC, Silva JB. Carpal tunnel syndrome - Part I (anatomy, physiology, etiology and diagnosis). *Rev Bras Ortop.* 2014;49:429-36.
  41. van Rijn RM, Huisstede BM, Koes BW, Burdorf A. Associations between work-related factors and the carpal tunnel syndrome--a systematic review. *Scand J Work Environ Health.* 2009;35:19-36.
  42. Barcenilla A, March LM, Chen JS, Sambrook PN. Carpal tunnel syndrome and its relationship to occupation: a meta-analysis. *Rheumatology (Oxford).* 2012;51:250-61.
  43. Mediouni Z, Bodin J, Dale AM, Herquelot E, Carton M, Leclerc A i sur. Carpal tunnel syndrome and computer exposure at work in two large complementary cohorts. *BMJ Open.* 2015;5:e008156.
  44. Mackinnon SE. Pathophysiology of nerve compression. *Hand Clin.* 2002;18:231-41.

- 
45. Gelberman RH, Hergenroeder PT, Hargens AR, Lundborg GN, Akeson WH. The carpal tunnel syndrome. A study of carpal canal pressures. *J Bone Joint Surg Am.* 1981;63:380-3.
  46. Tucci MA, Barbieri RA, Freeland AE. Biochemical and histological analysis of the flexor tenosynovium in patients with carpal tunnel syndrome. *Biomed Sci Instrum.* 1997;33:246-51.
  47. Seiler JG 3rd, Milek MA, Carpenter GK, Swiontkowski MF. Intraoperative assessment of median nerve blood flow during carpal tunnel release with laser Doppler flowmetry. *J Hand Surg Am.* 1989;14:986-91.
  48. Uchiyama S, Itsubo T, Nakamura K, Kato H, Yasutomi T, Momose T. Current concepts of carpal tunnel syndrome: pathophysiology, treatment, and evaluation. *J Orthop Sci.* 2010;15:1-13.
  49. Dekel S, Papaioannou T, Rushworth G, Coates R. Idiopathic carpal tunnel syndrome caused by carpal stenosis. *Br Med J.* 1980;280:1297-9.
  50. Crnković, T., Bilić, R., Kolundžić, R. Sindrom karpalnog tunela – suvremena dijagnostika i liječenje. *Medica Jadertina.* 2014;38:77–84.
  51. Altissimi M, Antenucci R, Fiacca C, Mancini GB. Long-term results of conservative treatment of fractures of the distal radius. *Clin Orthop Relat Res.* 1986;206:202-10.
  52. Potts F, Shahani BT, Young RR. Study of the coincidence of carpal tunnel syndrome and generalized peripheral neuropathy. *Muscle Nerve.* 1980;3:440.
  53. Wiederholt WC, Mulder DW, Lambert EH. The Landry-Guillain-Barre-Strohl syndrome or polyradiculoneuropathy: historical review, report on 97 patients, and present concepts. *Mayo Clin Proc.* 1964;39:427-51.
  54. Wand JS. Carpal tunnel syndrome in pregnancy and lactation. *J Hand Surg Br.* 1990;15:93-5.
  55. Nathan PA, Keniston RC, Myers LD, Meadows KD. Obesity as a risk factor for slowing of sensory conduction of the median nerve in industry. A cross-sectional and longitudinal study involving 429 workers. *J Occup Med.* 1992;34:379-83.
  56. Plante-Bordeneuve V, Said G. Familial amyloid polyneuropathy. *Lancet Neurol.* 2011;10:1086-97.
  57. Martić V, Perić P. Neurofiziološki i klinički aspekt bolesnika sa karpal tunel sindromom [Neurophysiological and clinical aspect of patients with carpal tunnel syndrome]. *Acta Chir Iugosl.* 2004;51:87-91.

- 
58. Mayers LB. Carpal tunnel syndrome secondary to tuberculosis. *Arch Neurol.* 1964;10:426-9.
  59. Shambaugh GE, Cirksena WJ, Newcomer KL. Carpal tunnel syndrome as manifestation of sarcoidosis. *Arch Intern Med.* 1964;114:830-3.
  60. Purnell DC, Daly DD, Lipscomb PR. Carpal-tunnel syndrome associated with myxedema. *Arch Intern Med.* 1961;108:751-6.
  61. Schiller F, Kolb FO. Carpal tunnel syndrome in acromegaly. *Neurology.* 1954;4:271-82.
  62. Kuharić M, Zibar L. Screening for Carpal Tunnel Syndrome in Patients on Chronic Hemodialysis. *Acta Med Acad.* 2019;48:167-176.
  63. Aboonq MS. Pathophysiology of carpal tunnel syndrome. *Neurosciences (Riyadh).* 2015;20:4-9.
  64. Dahlin LB. Aspects on pathophysiology of nerve entrapments and nerve compression injuries. *Neurosurg Clin N Am.* 1999;2:21-9.
  65. Alfonso C, Jann S, Massa R, Torreggiani A. Diagnosis, treatment and follow-up of the carpal tunnel syndrome: a review. *Neurol Sci.* 2010;31:243-52.
  66. Viikari-Juntura E, Silverstein B. Role of physical load factors in carpal tunnel syndrome. *Scand J Work Environ Health.* 1999;25:163-85.
  67. Sami A, Unger J, Lange W. Vascular endothelial growth factor expression in peripheral nerves and dorsal root ganglia in diabetic neuropathy in rats. *Neurosci Lett.* 1999;262:159-62.
  68. Filius A, Thoreson AR, Wang Y, Passe SM, Zhao C, An KN i sur. The effect of tendon excursion velocity on longitudinal median nerve displacement: differences between carpal tunnel syndrome patients and controls. *J Orthop Res.* 2015;33:483-7.
  69. Ellis R, Blyth R, Arnold N, Miner-Williams W. Is there a relationship between impaired median nerve excursion and carpal tunnel syndrome? A systematic review. *J Hand Ther.* 2017;30:3-12.
  70. Lundborg G, Dahlin LB. The pathophysiology of nerve compression. *Hand clinics.* 1992;8:215-27.
  71. Wit JC, Hentz JG, Stevens JC. Carpal tunnel syndrome with normal nerve conduction studies. *Muscle Nerve.* 2004;29:515-22.
  72. Tinel J. Le signe du “fourmillement” dans les lésions des nerfs périphériques. *Press Méd.* 1915;47:388-9.

- 
73. Hansen PA, Micklesen P, Robinson LR. Clinical utility of the flick maneuver in diagnosing carpal tunnel syndrome. *Am J Phys Med Rehabil.* 2004;83:363-7
  74. Gilliat RW, Wilson TG. A pneumatic-tourniquet test in the carpal-tunnel syndrome. *Lancet.* 1953;265:595-7.
  75. Ahn DS. Hand elevation: a new test for carpal tunnel syndrome. *Ann Plast Surg.* 2001;46:120-4.
  76. Bilić R, Pećina M. Sindrom karpalnog tunela u reumatoidnih bolesnika. *Acta Orthop Jugosl.* 1986;17:191-200.
  77. Yoshida A, Okutsu I, Hamanaka I. A new diagnostic provocation test for carpal tunnel syndrome: Okutsu test. *Hand Surg.* 2010;15:65-9.
  78. Cobb TK, An KN, Cooney WP, Berger RA. Lumbrical muscle incursion into the carpal tunnel during finger flexion. *J Hand Surg Br.* 1994;19:434-8.
  79. Durkan JA. A new diagnostic test for carpal tunnel syndrome. *J Bone Joint Surg Am.* 1991;73:535-8.
  80. Pagel KJ, Kaul MP, Dryden JD. Lack of utility of Semmes-Weinstein testing in suspected carpal tunnel syndrome. *Am J Phys Med Rehabil.* 2002;81:597-600.
  81. Graham B. The value added by electrodiagnostic testing in the diagnosis of carpal tunnel syndrome. *J Bone Joint Surg Am.* 2008;90:2587-93.
  82. Billakota S, Hobson-Webb LD. Standard median nerve ultrasound in carpal tunnel syndrome: A retrospective review of 1,021 cases. *Clin Neurophysiol Pract.* 2017;2:188-191.
  83. Bodofsky EB, Wu KD, Campellone JV, Greenberg WM, Tomaio AC. A sensitive new median-ulnar technique for diagnosing mild Carpal Tunnel Syndrome. *Electromyogr Clin Neurophysiol.* 2005;45:139-44.
  84. Lin TY, Chang KV, Wu WT, Özçakar L. Ultrasonography for the diagnosis of carpal tunnel syndrome: an umbrella review. *J Neurol.* 2022;269:4663-75.
  85. Klauser AS, Faschingbauer R, Bauer T, Wick MC, Gabl M, Arora R i sur. Entrapment neuropathies II: carpal tunnel syndrome. *Semin Musculoskelet Radiol.* 2010;14:487-500.
  86. Cantatore FP, Del`Accio F, Lapadula G. Carpal tunnel syndrome: a review. *Clin Rheumatol.* 1997;16:596- 603.
  87. Wipperman J, Goerl K. Carpal Tunnel Syndrome: Diagnosis and Management. *Am Fam Physician.* 2016;94:993-9.

- 
88. American Academy of Neurology Quality Standards Subcommittee. Practice parameter for carpal tunnel syndrome (Summary statement). *Neurology*. 1993;43:2406–9.
  89. Giannini F, Cioni R, Mondelli M, Padua R, Gregori B, D'Amico P i sur. A new clinical scale of carpal tunnel syndrome: validation of the measurement and clinical-neurophysiological assessment. *Clin Neurophysiol*. 2002;113:71-7.
  90. Bland JD. A neurophysiological grading scale for carpal tunnel syndrome. *Muscle Nerve* 2000;23:1280-3.
  91. Gupta SK, Benstead TJ. Symptoms experienced by patients with carpal tunnel syndrome. *Can J Neurol Sci*. 1997;24:338-42.
  92. Szabo RM, Slater RR Jr, Farver TB, Stanton DB, Sharman WK. The value of diagnostic testing in carpal tunnel syndrome. *J Hand Surg Am*. 1999;24:704-14.
  93. Alfonso C, Jann S, Massa R, Torreggiani A. Diagnosis treatment and follow-up of the carpal tunnel syndrome: a review. *Neurol Sci*. 2010;31:243-52.
  94. LeBlanc KE, Cestia W. Carpal Tunnel Syndrome. *Am Fam Physician*. 2011;83:952-8.
  95. Oztas O, Turan B, Bora I, Karakaya MK. Ultrasound therapy effect in carpal tunnel syndrome. *Arch Phys Med Rehabil*. 1998;79:1540-4.
  96. Lehmann JF, Warren CG, Scham SM. Therapeutic heat and cold. *Clin Orthop Relat Res*. 1974;99:207-45.
  97. Burke FD, Ellis J, McKenna H, Bradley MJ. Primary care management of carpal tunnel syndrome. *Postgrad Med J*. 2003;79:433-7.
  98. Racasan O, Dubert T. The safest location for steroid injection in the treatment of carpal tunnel syndrome. *J Hand Surg Br*. 2005;30:412-4.
  99. Yucetas SC, Yildirim A. Comparative results of standard open and mini open, KnifeLight instrumental-assisted carpal tunnel release. *J Neurol Surg A Cent Eur Neurosurg*. 2013;74:393-9.
  100. Teoh LC, Tan PL. Endoscopic carpal tunnel release for recurrent carpal tunnel syndrome after previous open release. *Hand Surg*. 2004;9:235-9.
  101. Taleisnik J. The palmar cutaneous branch of the median nerve and the approach to the carpal tunnel. An anatomical study. *J Bone Joint Surg Am*. 1973;55:1212-7.
  102. Seiler JG 3rd, Barnes K, Gelberman RH, Chalidapong P. Endoscopic carpal tunnel release: an anatomic study of the two-incision method in human cadavers. *J Hand Surg Am*. 1992;17:996-1002.

- 
103. Katz JN, Fossel KK, Simmons BP, Swartz RA, Fossel AH, Koris MJ. Symptoms, functional status, and neuromuscular impairment following carpal tunnel release. *J Hand Surg Am.* 1995;20:549-55.
  104. Aslani HR, Alizadeh K, Eajazi A, Karimi A, Karimi MH, Zaferani Z i sur. Comparison of carpal tunnel release with three different techniques. *Clin Neurol Neurosurg.* 2012;114:965-8.
  105. Tarallo M, Fino P, Sorvillo V, Parisi P, Scuderi N. Comparative analysis between minimal access versus traditional accesses in carpal tunnel syndrome: a perspective randomised study. *J Plast Reconstr Aesthet Surg.* 2014;67:237–43.
  106. Sayegh ET, Strauch RJ. Open versus endoscopic carpal tunnel release: a meta-analysis of randomized controlled trials. *Clin Orthop Relat Res.* 2015;473:1120–32.
  107. Michelotti B, Romanowsky D, Hauck RM. Prospective, randomized evaluation of endoscopic versus open carpal tunnel release in bilateral carpal tunnel syndrome: an interim analysis. *Ann Plast Surg.* 2014;73: S157–60.
  108. Bande S, De Smet L, Fabry G. The results of carpal tunnel release: open versus endoscopic technique. *J Hand Surg Br.* 1994;19:14-7.
  109. Brown RA, Gelberman RH, Seiler JG 3rd, Abrahamsson SO, Weiland AJ, Urbaniak JR i sur. Carpal tunnel release. A prospective, randomized assessment of open and endoscopic methods. *J Bone Joint Surg Am.* 1993;75:1265-75.
  110. Pederiva D, Pilla F, Chiaramonte I, Rinaldi A, Rossomando V, Brunello M i sur. Under 2\$ hand anesthesia? Our first 800 cases with Wide-Awake Local Anesthesia No Tourniquet (WALANT) in hand surgery. *Musculoskelet Surg.* 2024. doi: 10.1007/s12306-024-00835-z.
  111. Huljev D. Debridement- krucijalni postupak u liječenju kroničnih rana [Debridement-crucial procedure in the treatment of chronic wounds]. *Acta Med Croatica.* 2013;67 Suppl 1:63-9.
  112. Velnar T, Bailey T, Smrkolj V. The wound healing process: an overview of the cellular and molecular mechanisms. *J Int Med Res.* 2009;37:1528-42.
  113. Šoša T, Sutlić Ž, Stanec Z, Tonković I i sur. *Kirurgija.* Zagreb: Naklada Ljevak;2007.
  114. Fearmonti R, Bond J, Erdmann D, Levinson H. A review of scar scales and scar measuring devices. *Eplasty.* 2010;10:e43.
  115. Truong PT, Lee JC, Soer B, Gaul CA, Olivotto IA. Reliability and validity testing of the patient and observer scar assessment scale in evaluating linear scars after breast cancer surgery. *Plast Reconstr Surg.* 2007;119:487-94.



- 
116. Nedelec B, Shankowsky HA, Tredget EE. Rating the resolving hypertrophic scar: comparison of the Vancouver scar scale and scar volume. *J Burn Care Rehabil.* 2000;21:205-12.
  117. Vercelli S, Ferriero G, Sartorio F, Stissi V, Franchignoni F. How to assess postsurgical scars: a review of outcome measures. *Disabil Rehabil.* 2009;31:2055-63.
  118. Kluge W, Simpson RG, Nicol AC. Late complications after open carpal tunnel decompression. *J Hand Surg Br.* 1996;21:205-7.
  119. Bolster M, Schipper C, Van Sterkenburg S, Ruettermann M, Reijnen M. Single interrupted sutures compared with Donati sutures after open carpal tunnel release: a prospective randomised trial. *J Plast Surg Hand Surg.* 2013;47:289–91.
  120. Dietz UA, Kuhfuss I, Debus E-S, Thiede A. Mario Donati and the vertical mattress suture of the skin. *World J Surg.* 2006;30:141–8.
  121. Coulthard P, Esposito M, Worthington HV, van der Elst M, van Waes OJ, Darcey J. Tissue adhesives for closure of surgical incisions. *Cochrane Database Syst Rev.* 2010 12;:CD004287.
  122. Dumville JC, Coulthard P, Worthington HV, Riley P, Patel N, Darcey J i sur. Tissue adhesives for closure of surgical incisions. *Cochrane Database Syst Rev.* 2014;28:CD004287.
  123. McQuillan TJ, Vora M, Hawkins J, Kenney D, Diaz R, Ladd AL. Adhesive Taping Shows Better Cosmetic Outcomes Than Tissue Adhesives for Sutured Upper Extremity Incisions: A Single-Blind Prospective Randomized Controlled Trial. *Orthopedics.* 2022;45:e42-e46.
  124. Sinha S, Naik M, Wright V, Timmons J, Campbell AC. A single blind, prospective, randomized trial comparing n-butyl 2-cyanoacrylate tissue adhesive (Indermil) and sutures for skin closure in hand surgery. *J Hand Surg Br.* 2001;26:264-5.
  125. Sample size calculator. Dostupno na adresi <https://www.stat.ubc.ca/~rollin/stats/ssize/>. Zadnji put pristupljeno 16 rujna 2023. godine.
  126. Fernandes CH, Meirelles LM, Santos JBGD, Fernandes M, Nakachima LR, Faloppa F. An Intraindividual Comparison of Open versus Paine Retinaculotome Release for Bilateral Carpal Tunnel Syndrome. *Rev Bras Ortop (Sao Paulo).* 2022;58:295-302.
  127. Stavrou D, Haik J, Weissman O, Goldan O, Tessone A, Winkler E. Patient and observer scar assessment scale: how good is it? *J Wound Care.* 2009;18:171-6.

- 
128. Ismail AK, Abdul Ghafar MA, Shamsuddin NS, Roslan NA, Kaharuddin H, Nik Muhamad NA. The Assessment of Acute Pain in Pre-Hospital Care Using Verbal Numerical Rating and Visual Analogue Scales. *J Emerg Med.* 2015;49:287-93.
  129. Pawar AA, Joshi MA, Gadhire M, Shotriya R, Phad B, Singh, J. Prospective randomized comparative study of skin adhesive glue (2- methyl -2- cyanopropionate or cyanoacrylate) versus conventional skin suturing by suture material/skin stapler in clean surgical cases. *Int J Surg.* 2017;5,168.
  130. Fernandes CH, Meirelles LM, Raduan Neto J, Nakachima LR, Dos Santos JB, Faloppa F. Carpal tunnel syndrome with thenar atrophy: evaluation of the pinch and grip strength in patients undergoing surgical treatment. *Hand (N Y).* 2013;8:60-3.
  131. Faour-Martín O, Martín-Ferrero MA, Almaraz-Gómez A, Vega-Castrillo A. The long-term post-operative electromyographic evaluation of patients who have undergone carpal tunnel decompression. *J Bone Joint Surg Br.* 2012;94:941-5.
  132. Leite JC, Jerosch-Herold C, Song F. A systematic review of the psychometric properties of the Boston Carpal Tunnel Questionnaire. *BMC Musculoskelet Disord.* 2006;7:78.
  133. Buysse DJ, Reynolds CF 3rd, Monk TH, Berman SR, Kupfer DJ. The Pittsburgh Sleep Quality Index: a new instrument for psychiatric practice and research. *Psychiatry Res.* 1989;28:193-213.
  134. Morin CM, Belleville G, Bélanger L, Ivers H. The Insomnia Severity Index: psychometric indicators to detect insomnia cases and evaluate treatment response. *Sleep.* 2011;34:601-8.
  135. Ware JE Jr, Gandek B. Overview of the SF-36 Health Survey and the International Quality of Life Assessment (IQOLA) Project. *J Clin Epidemiol.* 1998;51:903-12.
  136. Sunjic Roguljic V, Roguljic L, Kovacic V, Jukic I. A Comparison of Tissue Adhesive Material and Suture as Wound-Closure Techniques following Carpal Tunnel Decompression: A Single-Center Randomized Control Trial. *J Clin Med.* 2023 14;12:2864.
  137. Sunjic Roguljic V, Roguljic L, Kovacic V, Bilic I, Jukic I. The Influence of the Tissue Adhesive Material as a Surgical Wound-Closure Technique Following Carpal Tunnel Decompression on Neurological and Functional Outcomes: A Single-Center Randomized Controlled Trial. *Cureus.* 2024;16:e53312.
  138. Sunjic Roguljic V, Roguljic L, Jukic I, Kovacic V. The Influence of Wound Closure Techniques after Surgical Decompression in Patients with Carpal Tunnel Syndrome

- 
- on Sleep Disturbance and Life Quality: A Prospective Comparison of Surgical Techniques. *Clin Pract.* 2024; 14:546-555.
139. Boya H., Özcan Ö., Özteki N.H.H. Long-term complications of open carpal tunnel release. *Muscle Nerve.* 2008;38:1443–6.
140. Ogawa R, Akaishi S. Endothelial dysfunction may play a key role in keloid and hypertrophic scar pathogenesis—Keloids and hypertrophic scars may be vascular disorders. *Med. Hypotheses.* 2016;96:51–60.
141. Finnerty CC, Jeschke MG, Branski LK, Barret JP, Dziewulski P, Herndon DN. Hypertrophic scarring: the greatest unmet challenge after burn injury. *Lancet.* 2016;388:1427-36.
142. Suwannaphisit S, Aonsong W, Suwanno P, Yuenyongviwat V. Comparing the running subcuticular technique versus the Donati technique in open carpal tunnel release: a randomized controlled trial. *J Orthop Surg Res.* 2021;16:565.
143. Siegmeth AW, Hopkinson-Woolley JA. Standard open decompression in carpal tunnel syndrome compared with a modified open technique preserving the superficial skin nerves: a prospective randomized study. *J Hand Surg Am.* 2006;31:1483-9.
144. Ahcan U, Arnez ZM, Bajrović F, Zorman P. Surgical technique to reduce scar discomfort after carpal tunnel surgery. *J Hand Surg Am.* 2002;27:821-7.
145. Wade RG, Wormald JC, Figus A. Absorbable versus non-absorbable sutures for skin closure after carpal tunnel decompression surgery. *Cochrane Database Syst Rev.* 2018;2:CD011757.
146. Grimaldi L, Cuomo R, Brandi C, Botteri G, Nisi G, D'Aniello C. Octyl-2-cyanoacrylate adhesive for skin closure: eight years experience. *In Vivo.* 2015;29:145-8.
147. Martin JG, Hollenbeck ST, Janas G, Makar RA, Pabon-Ramos WM, Suhocki PV i sur. Randomized Controlled Trial of Octyl Cyanoacrylate Skin Adhesive versus Subcuticular Suture for Skin Closure after Implantable Venous Port Placement. *J Vasc Interv Radiol.* 2017;28:111-6.
148. Lee CS, Han SR, Kye BH, Bae JH, Koh W, Lee IK i sur. Surgical skin adhesive bond is safe and feasible wound closure method to reduce surgical site infection following minimally invasive colorectal cancer surgery. *Ann Surg Treat Res.* 2020;99:146-52.
149. Farion K, Osmond MH, Hartling L, Russell K, Klassen T, Crumley E i sur. Tissue adhesives for traumatic lacerations in children and adults. *Cochrane Database Syst Rev.* 2002;2002:CD003326.

- 
150. Daliri BOM, Azhari A, Khaki S, Hajebi Khaniki S, Moradi A. Which Psychological and Electrodiagnostic Factors Are Associated With Limb Disability in Patients With Carpal Tunnel Syndrome? *Clin Orthop Relat Res.* 2022;480:960-8.
  151. Deng X, Chau LP, Chiu SY, Leung KP, Hu Y, Ip WY. Screening of Axonal Degeneration in Carpal Tunnel Syndrome Using Ultrasonography and Nerve Conduction Studies. *J Vis Exp.* 2019;143.
  152. Andreu JL, Ly-Pen D, Millán I, de Blas G, Sánchez-Olaso A. Local injection versus surgery in carpal tunnel syndrome: neurophysiologic outcomes of a randomized clinical trial. *Clin Neurophysiol.* 2014;125:1479-84.
  153. Tian Y, Zhao H, Wang T. Prospective comparison of endoscopic and open surgical methods for carpal tunnel syndrome. *Chin Med Sci J.* 2007;22:104-7.
  154. Yasak T, Özkaya Ö, Ergan Şahin A, Çolak Ö. Electromyographic and Clinical Investigation of the Effect of Platelet-Rich Plasma on Peripheral Nerve Regeneration in Patients with Diabetes after Surgery for Carpal Tunnel Syndrome. *Arch Plast Surg.* 2022 6;49:200-6.
  155. Calotta NA, Lopez J, Deune EG. Improved Surgical Outcomes With Endoscopic Carpal Tunnel Release in Patients With Severe Median Neuropathy. *Hand (N Y).* 2017;12:252-7.
  156. Gümüştaş SA, Ekmekçi B, Tosun HB, Orak MM, Bekler Hİ. Similar effectiveness of the open versus endoscopic technique for carpal tunnel syndrome: a prospective randomized trial. *Eur J Orthop Surg Traumatol.* 2015;25:1253-60.
  157. Crnković T, Bilić R, Trkulja V, Cesarik M, Gotovac N, Kolundžić R. The effect of epineurotomy on the median nerve volume after the carpal tunnel release: a prospective randomised double-blind controlled trial. *Int Orthop.* 2012;36:1885–92.
  158. Boumediane M, Meyer N, Facca S, Pizza C, Liverneaux P. Revision surgery for carpal tunnel syndrome: a retrospective study comparing the combination of Canaletto® and Dynavisc® gel versus Dynavisc® gel alone. *Hand Surg Rehabil.* 2021;40:57–63.
  159. Patel A, Culbertson MD, Patel A, Hashem J, Jacob J, Edelstein D i sur. The negative effect of carpal tunnel syndrome on sleep quality. *Sleep Disord.* 2014;2014:962746.
  160. Erickson J, Polatsch D, Beldner S, Melamed E. An Assessment of Sleep Disturbance in Patients before and after Carpal Tunnel Release. *J Hand Surg Asian Pac Vol.* 2019;24:144-6.
  161. Gaspar MP, Osterman MN, Shin EK, Osterman AL, Kane PM. Sleep disturbance and response to surgical decompression in patients with carpal tunnel syndrome: a

- 
- prospective randomized pilot comparison of open versus endoscopic release. *Acta Biomed.* 2019;90:92-96.
162. Niedermeier SR, Pettit RJ, Frantz TL, Colvell K, Mawan H. Early Postoperative Improvement in Sleep and Pain After Carpal Tunnel Release. *Hand.* 2020;15:311–4.
163. Tulipan JE, Kim N, Abboudi J, Jones C, Liss F, Kirkpatrick W i sur. Prospective Evaluation of Sleep Improvement Following Carpal Tunnel Release Surgery. *J Hand Surg Am.* 2017;42:390.e1-390.e6.
164. Okkesim CE, Serbest S, Tiftikçi U, Çirpar M. Prospective evaluation of preoperative and postoperative sleep quality in carpal tunnel release. *J Hand Surg Eur Vol.* 2019;44:278-82.
165. Trouw AG, Patel A, Yang A, Jauregui J, Caligiuri D, Choueka J. Improvement in Sleep Quality after Carpal Tunnel Release. *J Long Term Eff Med Implants.* 2018;28:55-61.
166. Lins L, Carvalho FM. SF-36 total score as a single measure of health-related quality of life: Scoping review. *SAGE Open Med.* 2016;4:2050312116671725.
167. Atroshi I, Gummesson C, Johnsson R, Sprinchorn A. Symptoms, disability, and quality of life in patients with carpal tunnel syndrome. *J Hand Surg Am.* 1999;24:398–404.
168. Galasso O, Mariconda M, Donato G, Di Mizio G, Padua L, Brando A i sur. Histopathological, clinical, and electrophysiological features influencing postoperative outcomes in carpal tunnel syndrome. *J Orthop Res.* 2011;29:1298-304.
169. Roth J, Shtokman J, Shamir MH, Nissan M, Shchetinkov L, Trejo LL, Rochkind S. Regeneration of the transected rat sciatic nerve after suturing or adhesion with cyanoacrylate glue. *J Neurosurg.* 2011;114:245-52.
170. Landegren T, Risling M, Brage A, Persson JK. Long-term results of peripheral nerve repair: a comparison of nerve anastomosis with ethyl-cyanoacrylate and epineural sutures. *Scand J Plast Reconstr Surg Hand Surg.* 2006;40:65-72.
171. Landegren T, Risling M, Persson JK. Local tissue reactions after nerve repair with ethyl-cyanoacrylate compared with epineural sutures. *Scand J Plast Reconstr Surg Hand Surg.* 2007;41:217-27.
172. Cartmill BT, Parham DM, Strike PW, Griffiths L, Parkin B. How do absorbable sutures absorb? A prospective double-blind randomized clinical study of tissue reaction to polyglactin 910 sutures in human skin. *Orbit.* 2014;33:437-4.

- 
173. Subwongcharoen S, Ruksakul K. A randomized controlled trial of staple fixation versus N-butyl-2-cyanoacrylate fixation in laparoscopic inguinal hernia repair. *J Med Assoc Thai.* 2013;96:S8-13.



## **12. RADOVI OBJEDINJENI U DOKTORSKOM RADU**

## 12.1. Prvi rad

Article

# A Comparison of Tissue Adhesive Material and Suture as Wound-Closure Techniques following Carpal Tunnel Decompression: A Single-Center Randomized Control Trial

Veridijana Sunjic Roguljic <sup>1</sup>, Luka Roguljic <sup>2</sup>, Vedran Kovacic <sup>3,4,\*</sup>  and Ivana Jukic <sup>5</sup>

<sup>1</sup> Surgery Department, Plastic, Reconstructive and Aesthetic Surgery with Burn Care Division, University Hospital of Split, 21000 Split, Croatia

<sup>2</sup> Surgery Department, Orthopaedics and Traumatology Division, University Hospital of Split, 21000 Split, Croatia

<sup>3</sup> Internal Medicine Department, Division of Emergency and Intensive Medicine with Clinical Pharmacology and Toxicology, University Hospital of Split, 21000 Split, Croatia

<sup>4</sup> School of Medicine, University of Split, 21000 Split, Croatia

<sup>5</sup> Internal Medicine Department, Gastroenterology Division, University Hospital of Split, 21000 Split, Croatia

\* Correspondence: vedran.kovacic.split@gmail.com; Tel.: +38-52-155-7456

**Abstract:** Background: Carpal tunnel syndrome (CTS) is the most common peripheral neuropathy caused by compression of the median nerve in the carpal tunnel. The presented study aimed to evaluate clinical outcomes by comparing two techniques of wound closure following carpal tunnel surgery in subjects randomized to the application of tissue adhesive or sutures. Methods: From April 2022 to December 2022, a single-center randomized prospective trial was conducted at the University Hospital of Split in Croatia. The study participants consisted of 100 patients (70 females) aged  $61.56 \pm 12.03$  years, randomly assigned to suture-based wound closure ( $n = 50$ ) or tissue adhesive-based wound closure ( $n = 50$ ) with two-component skin adhesive Glubran Tiss 2<sup>®</sup>. The outcomes were assessed postoperatively during the follow-up period at intervals of 2, 6, and 12 weeks. A scar assessment was performed using the POSAS (Patient and Observer Scar Assessment Scale) and cosmetic VAS (Visual Analog Scale). The VNRS (Verbal Number Rating Scale) was used to assess pain. Results: There were significant differences between glue-based wound closure and suture-based wound closure at 2-week and 6-week intervals after the surgery on the POSAS and cosmetic-VAS scales (better aesthetic effect with glue-based wound closure technique where noticed), with less postoperative pain at the same intervals. With the 12-week interval, differences in outcomes were insignificant. Conclusions: This trial demonstrated that cyanoacrylate-based adhesion mixtures might be possibly superior in the short term in terms of cosmetic appearance and discomfort compared to conventional skin suturing techniques for the closing of surgical wounds following open CTS decompression, but there was no difference between both procedures in the long term.

**Keywords:** carpal tunnel; skin adhesive; cyanoacrylate; skin suture



**Citation:** Sunjic Roguljic, V.; Roguljic, L.; Kovacic, V.; Jukic, I. A Comparison of Tissue Adhesive Material and Suture as Wound-Closure Techniques following Carpal Tunnel Decompression: A Single-Center Randomized Control Trial. *J. Clin. Med.* **2023**, *12*, 2864. <https://doi.org/10.3390/jcm12082864>

Academic Editor: Christian Carulli

Received: 7 March 2023

Revised: 12 April 2023

Accepted: 13 April 2023

Published: 14 April 2023



**Copyright:** © 2023 by the authors. Licensee MDPI, Basel, Switzerland. This article is an open access article distributed under the terms and conditions of the Creative Commons Attribution (CC BY) license (<https://creativecommons.org/licenses/by/4.0/>).

## 1. Introduction

Carpal tunnel syndrome (CTS) is the most common peripheral neuropathy caused by compression of the median nerve in the carpal tunnel. From the start, CTS is a potentially debilitating syndrome. In mild to moderate cases, conservative therapy is suggested, while severe cases are treated surgically [1,2]. Patients who have severe carpal tunnel syndrome or whose symptoms have not improved after four to six months of conservative treatment may be considered for surgical decompression [3].

Despite the fact that postoperative complications are uncommon, potential sequelae have a significant impact on patients' impairment. The most important late complications include persistent symptoms, scars, neurovascular damage, pillar pain, and decreased grip strength [4].



In order to reduce the frequency of late postsurgical complications, various modifications of postsurgical wound closure techniques following carpal tunnel release have been proposed [5]. As postoperative scar tenderness can be induced by inversion of the wound edges, well-performed wound closure will result in reduced postoperative scar tenderness [6]. Sutures, staples, and sticky tapes have been used for many years to seal postoperative wounds.

Tissue adhesives have recently entered clinical practice for these purposes. Due to their strong tensile strength, bacteriostatic characteristics and spontaneous peeling, tissue adhesives such as 2-octylcyanoacrylate are becoming increasingly popular for reinforcing wound closures [7]. However, it has not been proven that there are clear differences between tissue adhesives and classical wound closure techniques in terms of dehiscence, infection, cosmetic appearance, or surgeon and patient satisfaction [8].

Despite many proposed wound-closure techniques following open carpal tunnel decompression surgery, there is a lack of information on the possible role of tissue adhesives in this clinical setting. The presented study aimed to evaluate clinical outcomes by comparing two techniques of wound closure following carpal surgery in subjects randomized to the application of tissue adhesive or sutures. The primary endpoint of the study was aesthetic outcomes, with postoperative pain and the frequency of postprocedural complications as secondary outcomes.

## 2. Materials and Methods

A single-center randomized prospective controlled interventional follow-up study was conducted from 1 April 2022, to 31 December 2022, at the Surgery Department, Plastic, Reconstructive and Aesthetic Surgery with Burn Care Division of the University Hospital of Split in Croatia. The study was designed as a single-blind trial because the outcome evaluators were blinded.

The study protocol was approved by the Ethics Committee at the University Hospital of Split with an ethics code of 500-03/22-01/41; date of approval, 31 March 2022. The study was conducted according to the principles of the Declaration of Helsinki and the Consolidated Standards of Reporting Trials (CONSORT) guidelines. Informed consent was obtained from all subjects involved in the study. This clinical trial was registered with [www.clinicaltrials.gov](http://www.clinicaltrials.gov) (accessed on 1 March 2023) (NCT05747989).

### 2.1. Study Population

The study population consisted of adult patients (age > 18 years) who had previously been diagnosed with carpal tunnel syndrome and were scheduled for decompression surgery in our department. The diagnosis was based on history, physical examination (weakness of thumb abduction with atrophy of the thenar), and neurological examination with measurement of nerve conduction velocity. The surgery inclusion criteria were the complete failure of conservative treatment for more than 6 months with significant disabilities, such as thenar atrophy, thumb abduction weakness, or severe median nerve conduction impairment estimated by electromyography. The indication for surgery was made by the attending plastic surgeon during the visit, and the patient was scheduled for surgery the following month. Exclusion criteria were threatening hemorrhagic complications (patients with peroral anticoagulation and/or antithrombotic therapy), previous wrist trauma or surgery on the wrist region, another etiology of neuropathy, previous allergic reactions (with lidocaine, cyanoacrylate, formaldehyde, tapes, or adhesives), personal or family history of keloids or hypertrophic scars, and severe general illness with cachexia.

### 2.2. Study Flow

During the study period, 121 patients were recruited, and finally 100 patients were enrolled in the trial after applying exclusion criteria to 19 patients and 2 patients declining to participate. During the 12-week postoperative period, no subjects dropped out or were lost to follow-up. (Figure 1). The size of the sample was calculated considering the anticipated

main outcome measure (cosmetic VAS) from previous reports with an alpha error of 0.05 to recognize a significant difference and 90% test power (beta error of 0.1). For this study power, the minimum number of subjects was estimated at 47 in each study group.

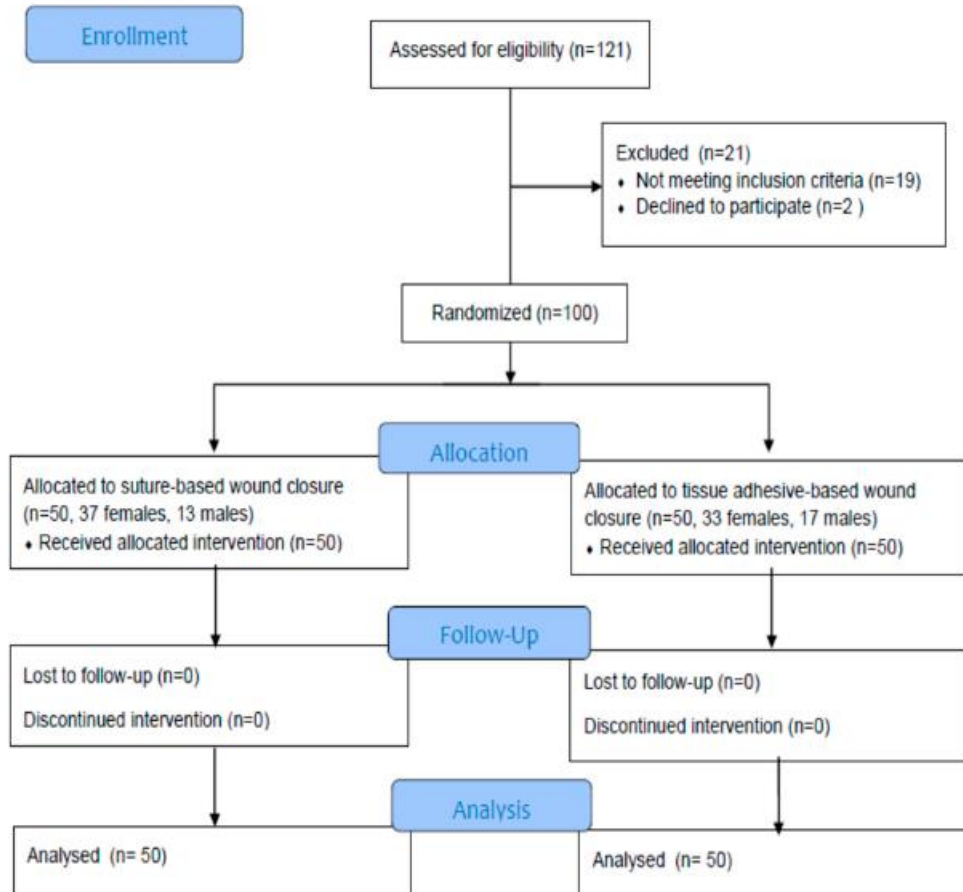


Figure 1. CONSORT flow diagram of the study.

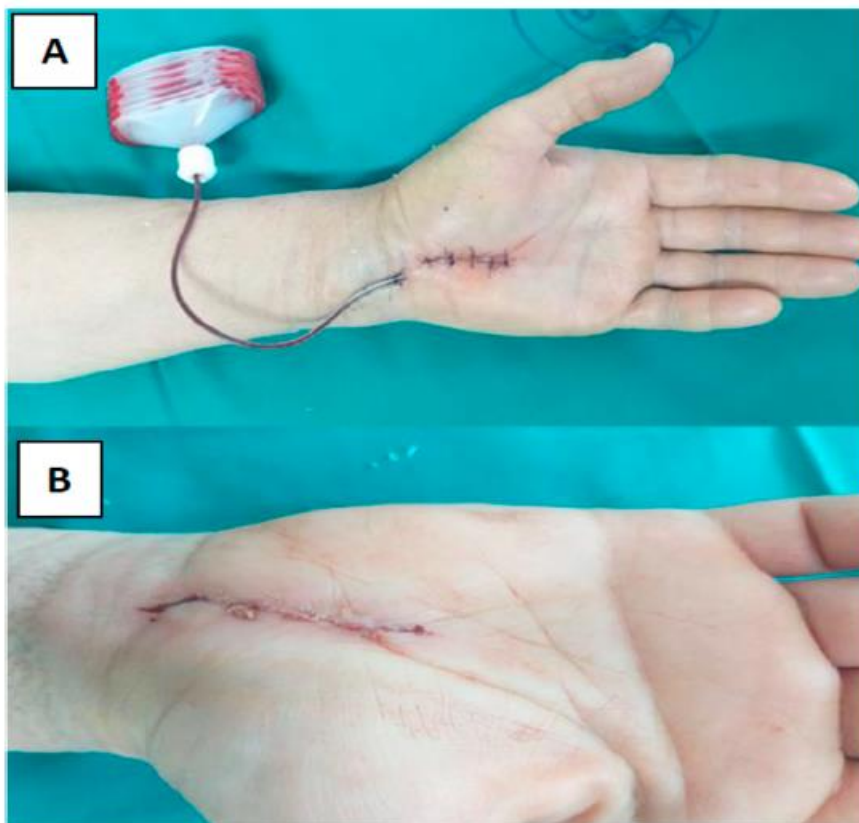
The patients were randomly assigned to suture-based wound closure or tissue adhesive-based wound closure. The randomization was generated by a computer as random numbers in a 1:1 ratio between the two interventions. Participants and plastic surgeons were blinded to the intervention until they entered the operating room. Postoperative care and follow-up visits were the same regardless of the intervention group. None of the subjects experienced any side effects from the medication.

### 2.3. Intervention Protocols

All surgical procedures were performed with a tourniquet and local anesthesia using 2% lidocaine in the palmar soft tissues and carpal tunnel. For all subjects, the standard carpal canal decompression procedure began with a 15–18 mm skin incision in the radial half of the palm, followed by carpal ligament transection and cutting [9]. Fol-

lowing primary closure, two different techniques were used depending on the subject's randomization group:

1. The skin is stitched with transcutaneous nylon sutures (polypropylene-polyethylene monofilament, non-absorbable surgical suture) 4-0. (Optilene<sup>®</sup> DSMP 19, 3/8 needle, thread size 4/0, B. Braun Surgical, S.A. Carretera de Terrassa, Spain) (Figure 2A).
2. After subcutaneous buried running continuous stitch with 4-0 Coated Vicryl<sup>™</sup> Plus PS-2, 3/8 (Ethicon Inc., Cincinnati, OH, USA), a two-component skin adhesive, Glubran Tiss 2<sup>®</sup> (GEM S.r.l., Viareggio, Italy), was applied. Glubran Tiss 2<sup>®</sup> is composed of NBCA (n-butyl 2 cyanoacrylate) and OCA (2-octyl cyanoacrylate) as a synthetic surgical glue with hemostatic, adhesive, sealing, and bacteriostatic properties [10]. When applied to wet tissue, it immediately polymerizes into a thin, elastic film with a great tensile strength that clings securely to the architecture of the tissue. Polymerized glue is a bioinert material. Each subject received 0.35 mL of Glubran Tiss<sup>®</sup> on the open wound, and before bandaging, subjects rested for 20 s for a polymerization process (Figure 2B).



**Figure 2.** Photographs of a patient demonstrating suture wound closure (A) and a patient demonstrating wound closure with Glubran Tiss<sup>®</sup> (B).

Postoperative care consisted of the application of a compressive bandage for 1 day and the introduction of analgesics. Drainage with a narrow plastic tube has been placed if

necessary in the first two postoperative days. Regular visits by the attending surgeon and the nurse with wound dressings were done on a daily basis.

#### 2.4. Estimation of Outcomes

We assessed the outcomes during the follow-up period at intervals of 2, 6, and 12 weeks postoperatively. During the follow-up, all patients were photographed, completed the VAS and POSAS questionnaires, and completed the VNRS form, while an examiner completed the POSAS questionnaires.

A scar assessment was performed using the Patient and Observer Scar Assessment Scale (POSAS) from both the patient's and the surgeon's perspectives. The POSAS is made up of two scales: the patient scale and the observer scale; each of the six components is scored numerically on a scale of 1 to 10. The component scores are then added together; the worst scar would receive a score of 60, while the best scar would receive a score of 6 [11]. Subjects filled out a standardized scar assessment form (POSAS), and blinded photos were collected so that an independent observer (a surgeon) could evaluate the scar as a POSAS score. Independent observers were blinded and did not participate in the intervention or follow-up examinations.

A Verbal Number Rating Scale (VNRS) was used to assess the degree of pain in the hand before and the day after surgery, as well as at 2, 6, and 12-week intervals during the follow-up period. The VNRS is a verbal self-report instrument with a 0–10 numeric rating scale, where 0 represents no pain and 10 represents the most severe pain possible [12]. Additionally, a cosmetic VAS (Visual Analog Scale) assessment form was filled out by the patient at the 2, 6, and 12-week intervals. The cosmetic-VAS is a 0–100 scale with “worst scar” written at the left end (0) and “best scar” written at the right end (100) [13].

Gender, weight, height, previous illnesses, length of postoperative wound, nerve decompression time, stitching time, and bandage time were recorded for each subject.

#### 2.5. Statistical Analysis

Descriptive statistics calculations and data were expressed as the arithmetic mean  $\pm$  standard deviation if normally distributed, or as the median (interquartile range) if not normally distributed. The Kolmogorov–Smirnov test was used for the estimation of the normality of quantitative variables' distributions. Qualitative data between groups were compared with Fisher's exact tests. Quantitative data were compared using an unpaired Student's *t*-test. The Mann–Whitney test was employed to analyze and compare quantitative variables with non-normal distribution. Correlations between quantitative data were calculated as the significance of the Pearson's correlation coefficient for normally distributed variables or of the Spearman's rho coefficient for variables with a non-normal distribution. Statistical analysis was performed with SPSS software for Windows (IBM SPSS Statistics for Windows, version 26.0, Armonk, NY, USA). *p* values < 0.05 were considered significant.

### 3. Results

The study participants consisted of 100 patients (30 males and 70 females) randomly assigned in a 1:1 ratio for wound closure with glue ( $n = 50$ ) and wound closure with sutures ( $n = 50$ ). The age of the entire cohort was  $61.56 \pm 12.03$  years. The right-side surgery was performed on 57 subjects, while the left-side surgery was performed on 43. The mean surgery decompression time for CTS resolution was  $8.71 \pm 0.57$  min. Subjects' clinical presentation with surgical times and outcomes, along with gender differences, is demonstrated in Table 1. The differences between patients whose wounds were closed with glue and those whose wounds were closed with sutures are presented in Table 2.

**Table 1.** Subjects' clinical presentations with surgical times and outcomes. Data are shown for the entire patient population as well as for the two subgroups; sex differences are calculated (Student's *t*-test for independent samples or Mann–Whitney test for non-parametric data), and *p*-values for significant differences are bolded. Data are presented as the arithmetic mean ± standard deviation, or median (interquartile range) for non-parametric variables.

|                              | All (n = 100) |                 | Males (n = 30) |                 | Females (n = 70) |                 | <i>p</i>         |
|------------------------------|---------------|-----------------|----------------|-----------------|------------------|-----------------|------------------|
| Age (years)                  | 61.56 ± 12.03 |                 | 66.30 ± 10.88  |                 | 59.53 ± 12.00    |                 | <b>0.005</b>     |
| BMI (kg/m <sup>2</sup> )     | 24.92 ± 2.74  |                 | 26.44 ± 2.12   |                 | 24.26 ± 2.73     |                 | <b>&lt;0.001</b> |
| Time_stitching (min)         | 3.25 ± 0.31   |                 | 3.29 ± 0.27    |                 | 3.23 ± 0.32      |                 | 0.198            |
| Time_bandage (min)           | 12.87 ± 1.01  |                 | 12.70 ± 0.99   |                 | 12.94 ± 1.02     |                 | 0.131            |
| Surgical_decompression (min) | 8.71 ± 0.57   |                 | 8.60 ± 0.53    |                 | 8.75 ± 0.58      |                 | 0.115            |
| cosmetic-VAS 2 weeks         | 95.00         | (90.00–95.00)   | 90.00          | (90.00–95.00)   | 95.00            | (90.00–95.00)   | 0.270            |
| cosmetic-VAS 6 weeks         | 100.00        | (95.00–100.00)  | 100.00         | (95.00–100.00)  | 100.00           | (95.00–100.00)  | 0.159            |
| cosmetic-VAS 12 weeks        | 100.00        | (100.00–100.00) | 100.00         | (100.00–100.00) | 100.00           | (100.00–100.00) | 0.092            |
| POSAS 2 weeks pt             | 17.00         | (16.00–17.00)   | 17.00          | (16.00–17.00)   | 17.00            | (16.00–17.25)   | 0.117            |
| POSAS 2 weeks observer       | 17.00         | (16.00–17.00)   | 16.00          | (16.00–17.00)   | 17.00            | (16.00–17.00)   | <b>0.006</b>     |
| POSAS 6 weeks pt             | 15.00         | (14.00–15.00)   | 14.00          | (13.00–15.00)   | 15.00            | (14.00–15.00)   | 0.143            |
| POSAS 6 weeks observer       | 14.00         | (13.00–15.00)   | 14.00          | (13.00–14.00)   | 14.00            | (13.75–15.00)   | 0.060            |
| POSAS 12 weeks pt            | 11.00         | (10.00–12.00)   | 11.00          | (11.00–12.00)   | 11.00            | (10.00–12.00)   | 0.145            |
| POSAS 12 weeks observer      | 11.00         | (10.00–12.00)   | 11.00          | (10.00–12.00)   | 11.00            | (10.00–12.00)   | 0.180            |
| VNRS prior surgery           | 5.00          | (4.00–6.00)     | 5.00           | (4.00–6.00)     | 5.00             | (4.00–5.25)     | 0.403            |
| VNRS on surgery day          | 5.00          | (4.00–6.00)     | 4.50           | (4.00–6.00)     | 5.00             | (4.00–6.00)     | 0.084            |
| VNRS 2 weeks post surgery    | 3.00          | (3.00–4.00)     | 3.00           | (2.00–4.00)     | 3.00             | (3.00–4.00)     | <b>0.023</b>     |
| VNRS 6 weeks post surgery    | 2.00          | (1.00–2.00)     | 2.00           | (1.00–2.00)     | 2.00             | (1.75–2.00)     | 0.087            |
| VNRS 12 weeks post surgery   | 0.00          | (0.00–0.00)     | 0.00           | (0.00–0.00)     | 0.00             | (0.00–0.00)     | 0.374            |
| wound length (mm)            | 17.00         | (17.00–18.00)   | 17.00          | (17.00–18.00)   | 18.00            | (17.00–18.00)   | <b>0.045</b>     |

Legend: BMI: Body Mass Index, pt.: patient, VAS: Visual Analogue Scale, POSAS: Patient and Observer Scar Assessment Scale, VNRS: Verbal Numerical Rating Scale.

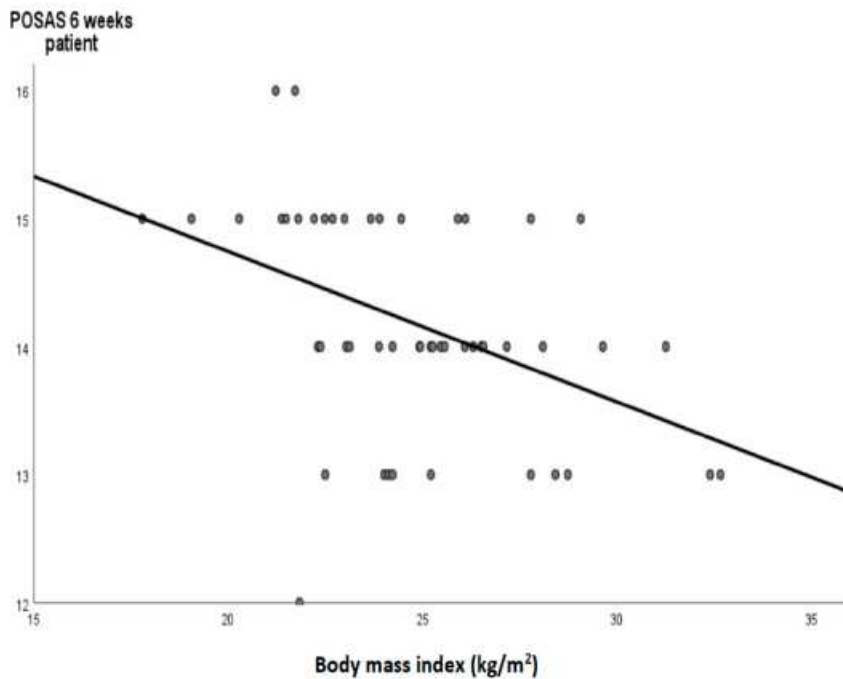
**Table 2.** Differences between glue-based wound closure and suture-based wound closure patients (Student's *t*-test for independent samples or Mann–Whitney test for non-parametric data), and *p*-values for significant differences are bolded. Data are presented as the arithmetic mean ± standard deviation, or median (interquartile range) for non-parametric data.

|                              | Glue-Based Technique (n = 50) |                 | Suture-Based Technique (n = 50) |                 | <i>p</i>         |
|------------------------------|-------------------------------|-----------------|---------------------------------|-----------------|------------------|
| Age (years)                  | 63.02 ± 12.97                 |                 | 60.10 ± 10.95                   |                 | 0.113            |
| BMI (kg/m <sup>2</sup> )     | 24.79 ± 3.17                  |                 | 25.04 ± 2.25                    |                 | 0.325            |
| Time_stitching (min)         | 3.19 ± 0.27                   |                 | 3.31 ± 0.33                     |                 | <b>0.021</b>     |
| Time_bandage (min)           | 12.93 ± 1.00                  |                 | 12.81 ± 1.03                    |                 | 0.291            |
| Surgical_decompression (min) | 8.74 ± 0.57                   |                 | 8.67 ± 0.57                     |                 | 0.264            |
| cosmetic-VAS 2 weeks         | 95.00                         | (90.00–95.00)   | 90.00                           | (90.00–95.00)   | <b>0.014</b>     |
| cosmetic-VAS 6 weeks         | 100.00                        | (100.00–100.00) | 100.00                          | (95.00–100.00)  | <b>0.003</b>     |
| cosmetic-VAS 12 weeks        | 100.00                        | (100.00–100.00) | 100.00                          | (100.00–100.00) | 0.153            |
| POSAS 2 weeks pt             | 16.00                         | (16.00–17.00)   | 17.00                           | (17.00–18.00)   | <b>0.002</b>     |
| POSAS 2 weeks observer       | 16.00                         | (16.00–17.00)   | 17.00                           | (16.00–18.00)   | <b>&lt;0.001</b> |
| POSAS 6 weeks pt             | 14.00                         | (14.00–15.00)   | 15.00                           | (14.00–15.00)   | <b>0.005</b>     |
| POSAS 6 weeks observer       | 14.00                         | (13.00–14.00)   | 14.00                           | (13.75–15.00)   | <b>0.038</b>     |
| POSAS 12 weeks pt            | 11.00                         | (10.00–12.00)   | 11.00                           | (10.00–12.00)   | 0.200            |
| POSAS 12 weeks observer      | 11.00                         | (10.00–11.25)   | 11.00                           | (10.00–12.00)   | 0.064            |
| VNRS prior surgery           | 5.00                          | (4.00–6.00)     | 5.00                            | (4.00–5.25)     | 0.387            |
| VNRS on surgery day          | 5.00                          | (4.00–6.00)     | 5.00                            | (4.00–6.00)     | 0.134            |
| VNRS 2 weeks post surgery    | 3.00                          | (3.00–4.00)     | 3.00                            | (3.00–4.00)     | <b>0.027</b>     |
| VNRS 6 weeks post surgery    | 2.00                          | (1.00–2.00)     | 2.00                            | (2.00–3.00)     | <b>0.001</b>     |
| VNRS 12 weeks post surgery   | 0.00                          | (0.00–0.00)     | 0.00                            | (0.00–0.00)     | 0.232            |
| wound length (mm)            | 17.00                         | (17.00–18.00)   | 17.00                           | (17.00–18.00)   | 0.355            |

Legend: BMI: Body Mass Index, pt.: patient, VAS: Visual Analogue Scale, POSAS: Patient and Observer Scar Assessment Scale, VNRS: Verbal Numerical Rating Scale.

Postoperative complications after 15 days in the entire cohort were observed in 12 participants: redness (5 cases), dehiscence (2), hematoma (2), infection (1), allergic dermatitis (1), and secretion (1 case). There were no statistically significant differences in the number of complications between the glue-based wound closure and the suture-based wound closure groups of the patients (Chi square < 0.001,  $p = 0.620$ ). After 12 weeks of surgery, we observed complications in 8 subjects, granuloma in 5 cases, secretion in 2, and infection in 1. There were no statistically significant differences in the number of complications between the glue-based wound closure and suture-based wound closure groups of the patients (Chi square = 0.54,  $p = 0.375$ ). We found a weak but significant correlation between surgery time and wound length ( $r = 0.206$ ,  $p = 0.020$ ). At 6 weeks, the VNRS score was weakly correlated with the bandaging time ( $\rho = -0.347$ ,  $p < 0.001$ ). BMI was weakly negatively correlated with the observer's POSAS score at 6 weeks ( $\rho = -0.270$ ,  $p = 0.03$ ).

A correlation analysis between BMI and outcome scores in the subgroup of glue wound closure subjects is demonstrated in Table 3. Moderate significant correlations were found between the BMI and POSAS scores of the patient and the observer in the 6th week. Figure 3 shows a regression graph with regression equation between the BMI and the POSAS score of the patient in the 6th week in the subgroup of glue wound closure subjects. Figure 4 demonstrated the time changes in the POSAS scores evaluated by the patient during the postoperative follow-up period.



**Figure 3.** A regression graph (black line) and circles as a cases with the regression equation demonstrated a moderate correlation between the body mass index and POSAS score of the patient in the 6th week in the subgroup of glue wound closure subjects ( $Y = -0.118X + 17.09$ ).

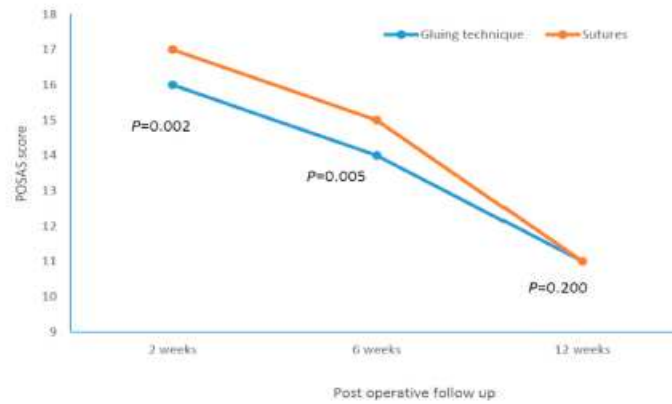


Figure 4. POSAS scores evaluated by the patient during the follow-up period after surgery.

Table 3. Correlation analysis between body mass index (BMI) and outcome scores in a subgroup of subjects with glue wound closure (n = 50); Spearman’s correlation, one-tailed, significant correlations are bolded.

|                            | Spearman’s Rho | p                |
|----------------------------|----------------|------------------|
| wound length               | −0.088         | 0.273            |
| Time_stitching             | 0.085          | 0.279            |
| Time_bandage               | 0.016          | 0.456            |
| Surgical_decompression     | <b>0.239</b>   | <b>0.048</b>     |
| cosmetic-VAS 2 weeks       | −0.183         | 0.101            |
| cosmetic-VAS 6 weeks       | <b>−0.290</b>  | <b>0.021</b>     |
| cosmetic-VAS 12 weeks      | −0.064         | 0.329            |
| POSAS 2 weeks pt           | <b>−0.252</b>  | <b>0.039</b>     |
| POSAS 2 weeks observer     | <b>−0.294</b>  | <b>0.019</b>     |
| POSAS 6 weeks pt           | <b>−0.460</b>  | <b>&lt;0.001</b> |
| POSAS 6 weeks observer     | <b>−0.407</b>  | <b>0.002</b>     |
| POSAS 12 weeks pt          | −0.005         | 0.487            |
| POSAS 12 weeks observer    | 0.104          | 0.237            |
| VNRS prior surgery         | 0.062          | 0.335            |
| VNRS on surgery day        | −0.230         | 0.054            |
| VNRS 2 weeks post surgery  | <b>−0.355</b>  | <b>0.006</b>     |
| VNRS 6 weeks post surgery  | −0.208         | 0.074            |
| VNRS 12 weeks post surgery | 0.219          | 0.063            |

Legend: pt: patient, VAS: Visual Analogue Scale, POSAS: Patient and Observer Scar Assessment Scale, VNRS: Verbal Numerical Rating Scale.

4. Discussion

The results of this trial demonstrated that the tissue adhesion technique for wound closure is significantly better after 2 and 6 weeks in terms of aesthetic effects than the classic stitch technique in surgically treated patients with CTS. Furthermore, patients subjected to the tissue adhesion technique reported less postoperative pain in the 2nd and 6th weeks after the surgical procedure. Despite the fact that the mentioned differences in postoperative pain were statistically significant, the objectively measured differences are very small, and the clinical significance of such differences in the experience of postoperative pain has objectively little clinical significance. Additionally, although there are statistically significant differences between the two wound closure techniques in the 2nd and 6th weeks, these differences are still clinically insubstantial to have a major influence on the surgeon’s decision as to which technique to use. In addition, after 12 weeks, the mentioned difference

in aesthetic effects and postoperative pain is lost, which further diminishes the practical importance of choosing a wound closure technique in real-world clinical practice.

Surgical treatment of CTS is reserved for the subgroup of patients with an insufficient response to conservative therapy or for severe, debilitated cases of CTS with significant functional deficits. Although surgical decompression of the carpal tunnel is a relatively safe treatment, late postoperative problems, such as prolonged discomfort or functional impairments, are nevertheless considerable. Boya et al. [14], reported scar tenderness in 7% and pillar pain in 18% of patients subjected to surgical treatment of CTS.

Scar formation after open carpal tunnel release is one of the most common causes of discomfort and functional disability, as this procedure causes deep skin and subcutaneous injuries that can result in hypertrophic scars and keloids [15]. In addition, abnormal scars can decrease the quality of life and deteriorate the social and physical status of the patient [16]. It is not easy to assess the aesthetic effects of surgery. Many techniques have been used in the past to evaluate the aesthetic effects of surgical procedures. The methods and techniques of aesthetic effect evaluation are prone to the subjective evaluations of the observer. The greatest advance in the evaluation of the aesthetic effects of surgery was made in the aesthetic surgery of the face and the neck [17,18].

The aforementioned surgical complications triggered a considerable effort to find a better surgical technique to preserve functional capacity and diminish scar development after CTS surgery. Suwannaphisit et al. [19] demonstrated that the Donati suture resulted in higher POSAS scores compared to the subcuticular running sutures, despite the fact that both techniques generally resulted in low POSAS scores and good scar formation. In this study, the average POSAS score after 2 weeks was lower for the running subcuticular suture ( $15.3 \pm 4.8$ ) compared with the Donati suture ( $17 \pm 4.6$ ), but observer scores were not significantly different ( $15.6 \pm 5.8$  vs.  $16.7 \pm 5.2$ ) after 2, 6, or 12 weeks. These POSAS scores are similar to our results after 2 weeks (median 16 in glue-based group), but in contrast to the cited study, the difference in POSAS score was visible in our subjects even after 6 weeks in both assessment methods. In study by Suwannaphisit et al., the authors could not find differences between the Donati suture and the running subcuticular suture in VNRS pain scores at 2, 6, and 12 postsurgical weeks. The authors found that both suture methods are appropriate for wound closure following an open carpal tunnel surgery. In contrast, we found clear differences in the VNRS score in the 2nd and 6th postoperative weeks, demonstrating the favorability of glue-based tissue adhesion.

A study in CTS patients, although aiming at conserving superficial nerve branches at the incision site during open carpal tunnel decompression, did not diminish the incidence or intensity of postoperative discomfort [20]. At 6 weeks, 3 months, and 6 months, the authors found no proof that the two treatments differed in terms of scar pain. On the contrary, in our cohort, a significant difference in pain assessment was found at 2 and 6 weeks post surgery. In addition to the aforementioned studies, numerous additional efforts were made to advance surgical procedures in CTS patients; however, the findings were inconclusive and failed to demonstrate improvement during postprocedural follow-up [21].

In addition to comparisons of suture or surgery techniques, some studies examined types of suture materials and their impact on postoperative complications after carpal tunnel decompression. There is a lack of definitive conclusions in the comparison of absorbable sutures with non-absorbable sutures after carpal tunnel decompression. In a meta-analysis of five trials, Wade et al. [22] concluded that it was unclear if using absorbable or non-absorbable sutures for skin closure after carpal tunnel decompression caused any differences in discomfort or wound inflammation. In most of the included studies, the visual analogue scale (VAS) was used for pain assessment. In one of those studies [23], the authors compared the aesthetic outcome of scars after closure of open carpal tunnel with either absorbable 4-0 Vicryl Rapide or non-absorbable 4-0 Novafil at 6 weeks using a POSAS score and did not find differences between the two techniques. Contrary to the results of those studies, we showed that after 2 and 6 weeks, clear differences between the



two surgical wound closure techniques in relation to pain and aesthetic effect, although the possible practical significance of these differences might be clinically negligible.

In recent years, cyanoacrylate-based skin glue has become more popular in various surgical procedures for ensuring and stabilizing wound closure [24,25]. One of the recognized advantages of these glues is their ability to decrease the risk of surgical site infection by physically isolating the surgical wound [26,27].

Despite its popularity, there is a scarcity of conclusive evidence favoring skin adhesives over sutures. A Cochrane systematic analysis found no difference in aesthetic outcomes between tissue adhesives and conventional wound closure or between different tissue adhesives [28]. Furthermore, a randomized study using a topical skin adhesive (2-octylcyanoacrylate) for wound closure in forefoot surgery found that skin adhesive use was related to higher inflammation and regions of wound separation than nylon sutures [29]. In a recent Cochrane systematic analysis of 33 studies involving 2793 participants, sutures were found to be superior to tissue adhesives in preventing wound dehiscence, and no differences were found in wound infection [8]. The same systematic analysis in a subanalysis of trials comparing the use of tissue adhesives with sutures found no evidence of a difference in the participants' and surgeons' assessments of cosmetic appearance measured by the cosmetic VAS score. In contrast to the aforementioned trials, a clear difference between the aesthetic postoperative effects measured as VAS scores of glue-based and suture-based wound closure was proven in our subjects.

Although wound closure using skin adhesives has been studied in numerous surgical procedures, the evaluation of skin adhesives following carpal tunnel decompression is still pending. A prospective randomized controlled trial was recently carried out to compare adhesive tape and tissue adhesive applied after primary closure to different halves of the same surgical incision [30]. Most of the incisions (50 in total) were for carpal tunnel decompression (14 subjects) and thumb carpometacarpal arthroplasty (14 subjects). Wounds were initially closed with 4-0 absorbable suture, then the proximal and distal parts of the wounds were finally closed with tapes (Steri Strips) or 2-octylcyanoacrylate (Dermabond). The authors evaluated the scars at approximately 3 months and concluded that the adhesive strips provided a modest but significant improvement in cosmetic outcomes compared to a tissue adhesive (POSAS score) observed by a surgeon. Patient observed better cosmetic outcomes with Steri-Strips than with Dermabond, although differences were not statistically significant.

Sinha et al. [31] conducted a prospective, randomized study with the aim of comparing the outcome of hand surgery wounds repaired with a tissue adhesive (n-butyl 2-cyanoacrylate tissue adhesive) or with standard wound closure techniques (4-0 monofilament suture). The 50 participants had hand surgery; 22 had CTS surgery. The authors could not find a significant difference in the cosmetic outcome assessment in the cohort of participants assessed at 2 and 6 weeks post surgery (mean cosmetic VAS score in the tissue adhesive group was 81 vs. 87 in the suture group).

In contrast to the previously mentioned studies, our randomized controlled trial found that the application of skin adhesion after carpal tunnel decompression brought about a better aesthetic effect and improved patient satisfaction compared to a control group that used sutures as a wound closure procedure. These effects are maintained throughout the second and sixth weeks, and the difference becomes insignificant in the twelfth week. Additionally, the cosmetic VAS score was significantly higher in both our groups than in the study by Sinha et al. The time required for wound closure was shorter in the skin adhesion application group, highlighting the ease of use of commercially available skin glue preparation. However, the results of our study are unlikely to have a significant impact on the surgeon's clinical decision about which technique to use in wound closure after CTS surgery. Interestingly, in the skin adhesion group, the results of our study have shown a moderate significant negative correlation between BMI and the good aesthetic effects estimated by the patient and the observer. We hypothesized that lower BMI values were associated with malnutrition, which might impact suboptimal aesthetic surgical outcomes.

However, the presented study had certain limitations. Firstly, the follow-up duration was insufficient to determine long-term problems and monitor long-lasting scar development following carpal tunnel release. Secondly, participants and data were restricted to a single center. Third, significant limitation of this study is that the possible effects of the compared wound closure technique on biomechanical and functional postoperative complications were not evaluated.

## 5. Conclusions

This randomized controlled trial found that wound closure following open CTS using cyanoacrylate-based adhesion material had a mild advantage over sutures in terms of aesthetic outcomes, discomfort, and patient compliance at 2 and 6 weeks postoperatively. However, the cosmetic results leveled off at 12 weeks postoperatively with no significant differences. As a conclusion, this trial demonstrated that cyanoacrylate-based adhesion mixtures might be possibly superior in the short term in terms of cosmetic appearance compared to conventional skin suturing techniques for the closing of surgical wounds following open CTS decompression. Larger multicentric studies with additional clinical and functional outcomes are needed to clarify the aforementioned conclusions.

**Author Contributions:** V.S.R.: investigation, draft preparation, writing; L.R.: draft preparation, writing; V.K.: conceptualization, methodology, validation, analysis; I.J.: methodology, draft preparation, writing. All authors contributed to the conception and design. All authors have read and agreed to the published version of the manuscript.

**Funding:** This research received no external funding.

**Institutional Review Board Statement:** The study was conducted in compliance with ethical standards. The study protocol was approved by the Ethics Committee at the University Hospital of Split with an ethics code of 500-03/22-01/41; date of approval, 31 March 2022. The study was conducted according to the principles of the Declaration of Helsinki.

**Informed Consent Statement:** Informed consent was obtained from all subjects involved in the study.

**Data Availability Statement:** The data presented in this study are available on request from the corresponding author.

**Conflicts of Interest:** The authors declare no conflict of interest.

## References

1. Jiménez Del Barrio, S.; Bueno Gracia, E.; Hidalgo García, C.; Estébanez de Miguel, E.; Tricás Moreno, J.M.; Rodríguez Marco, S.; Laita, L.C. Conservative treatment in patients with mild to moderate carpal tunnel syndrome: A systematic review. *Neurologia* **2018**, *33*, 590–601. [CrossRef] [PubMed]
2. Pace, V.; Marzano, F.; Placella, G. Update on surgical procedures for carpal tunnel syndrome: What is the current evidence and practice? What are the future research directions? *World J. Orthop.* **2023**, *14*, 6–12. [CrossRef]
3. Wipperfurth, J.; Goerl, K. Carpal Tunnel Syndrome: Diagnosis and Management. *Am. Fam. Physician* **2016**, *15*, 993–999.
4. Kluge, W.; Simpson, R.G.; Nicol, A.C. Late complications after open carpal tunnel decompression. *J. Hand Surg. Br.* **1996**, *21*, 205–207. [CrossRef] [PubMed]
5. Bolster, M.; Schipper, C.; Van Sterkenburg, S.; Ruettermann, M.; Reijnen, M. Single interrupted sutures compared with Donati sutures after open carpal tunnel release: A prospective randomised trial. *J. Plast. Surg. Hand Surg.* **2013**, *47*, 289–291. [CrossRef]
6. Dietz, U.A.; Kuhfuss, I.; Debus, E.-S.; Thiede, A. Mario Donati and the vertical mattress suture of the skin. *World J. Surg.* **2006**, *30*, 141–148. [CrossRef]
7. Coulthard, P.; Esposito, M.; Worthington, H.V.; van der Elst, M.; van Waes, O.J.; Darcey, J. Tissue adhesives for closure of surgical incisions. *Cochrane Database Syst. Rev.* **2010**, *12*, CD004287. [CrossRef]
8. Dumville, J.C.; Coulthard, P.; Worthington, H.V.; Riley, P.; Patel, N.; Darcey, J.; Esposito, M.; van der Elst, M.; van Waes, O.J.F. Tissue adhesives for closure of surgical incisions. *Cochrane Database Syst. Rev.* **2014**, *28*, CD004287. [CrossRef]
9. Steinberg, D.R. Surgical release of the carpal tunnel. *Hand Clin.* **2002**, *18*, 291–298. [CrossRef]
10. Kakaei, F.; Seyyed Sadeghi, M.S.; Sanei, B.; Hashemzadeh, S.; Habibzadeh, A. A randomized clinical trial comparing the effect of different haemostatic agents for haemostasis of the liver after hepatic resection. *HPB Surg.* **2013**, *2013*, 587608. [CrossRef]
11. Stavrou, D.; Haik, J.; Weissman, O.; Goldan, O.; Tessone, A.; Winkler, E. Patient and observer scar assessment scale: How good is it? *J. Wound Care.* **2009**, *18*, 171–176. [CrossRef] [PubMed]

12. Ismail, A.K.; Abdul Ghafar, M.A.; Shamsuddin, N.S.; Roslan, N.A.; Kaharuddin, H.; Nik Muhamad, N.A. The Assessment of Acute Pain in Pre-Hospital Care Using Verbal Numerical Rating and Visual Analogue Scales. *J. Emerg. Med.* **2015**, *49*, 287–293. [CrossRef] [PubMed]
13. Pawar, A.A.; Joshi, M.A.; Gadhire, M.; Shotriya, R.; Phad, B.; Singh, J. Prospective randomized comparative study of skin adhesive glue (2-methyl-2-cyanoacrylate or cyanoacrylate) versus conventional skin suturing by suture material/skin stapler in clean surgical cases. *Int. J. Surg.* **2017**, *5*, 168. [CrossRef]
14. Boya, H.; Özcan, Ö.; Özteki, N.H.H. Long-term complications of open carpal tunnel release. *Muscle Nerve* **2008**, *38*, 1443–1446. [CrossRef]
15. Ogawa, R.; Akaishi, S. Endothelial dysfunction may play a key role in keloid and hypertrophic scar pathogenesis—Keloids and hypertrophic scars may be vascular disorders. *Med. Hypotheses*. **2016**, *96*, 51–60. [CrossRef]
16. Finnerty, C.C.; Jeschke, M.G.; Branski, L.K.; Barret, J.P.; Dziewulski, P.; Herndon, D.N. Hypertrophic scarring: The greatest unmet challenge after burn injury. *Lancet*. **2016**, *388*, 1427–1436. [CrossRef]
17. Ruiz, R.; Hersant, B.; La Padula, S.; Meningaud, J.P. Facelifts: Improving the long-term outcomes of lower face and neck rejuvenation surgery: The lower face and neck rejuvenation combined method. *J. Cranio-Maxillofacial Surg.* **2018**, *46*, 697–704. [CrossRef]
18. La Padula, S.; Hersant, B.; Bompoy, L.; Meningaud, J.P. In search of a universal and objective method to assess facial aging: The new face objective photo-numerical assessment scale. *J. Cranio-Maxillofacial Surg.* **2019**, *47*, 1209–1215. [CrossRef]
19. Suwannaphisit, S.; Aonsong, W.; Suwannong, P.; Yuenyongviwat, V. Comparing the running subcuticular technique versus the Donati technique in open carpal tunnel release: A randomized controlled trial. *J. Orthop. Surg. Res.* **2021**, *16*, 565. [CrossRef]
20. Siegmeth, A.W.; Hopkinson-Woolley, J.A. Standard open decompression in carpal tunnel syndrome compared with a modified open technique preserving the superficial skin nerves: A prospective randomized study. *J. Hand Surg. Am.* **2006**, *31*, 1483–1489. [CrossRef]
21. Ahcan, U.; Armez, Z.M.; Bajrović, F.; Zorman, P. Surgical technique to reduce scar discomfort after carpal tunnel surgery. *J. Hand Surg. Am.* **2002**, *27*, 821–827. [CrossRef] [PubMed]
22. Wade, R.G.; Wormald, J.C.; Figus, A. Absorbable versus non-absorbable sutures for skin closure after carpal tunnel decompression surgery. *Cochrane Database Syst. Rev.* **2018**, *2*, CD011757. [CrossRef] [PubMed]
23. Theopold, C.; Potter, S.; Dempsey, M.; O'Shaughnessy, M. A randomised controlled trial of absorbable versus non-absorbable sutures for skin closure after open carpal tunnel release. *J. Hand Surg. Eur. Vol.* **2012**, *37*, 350–353. [CrossRef]
24. Grimaldi, L.; Cuomo, R.; Brandi, C.; Botteri, G.; Nisi, G.; D'Aniello, C. Octyl-2-cyanoacrylate adhesive for skin closure: Eight years experience. *In Vivo* **2015**, *29*, 145–148. [PubMed]
25. Martin, J.G.; Hollenbeck, S.T.; Janas, G.; Makar, R.A.; Pabon-Ramos, W.M.; Suhocki, P.V.; Miller, M.J.; Sopko, D.R.; Smith, T.P.; Kim, C.Y. Randomized Controlled Trial of Octyl Cyanoacrylate Skin Adhesive versus Subcuticular Suture for Skin Closure after Implantable Venous Port Placement. *J. Vasc. Interv. Radiol.* **2017**, *28*, 111–116. [CrossRef]
26. Rushbrook, J.L.; White, G.; Kidger, L.; Marsh, P.; Taggart, T.F. The antibacterial effect of 2-octyl cyanoacrylate (Dermabond®) skin adhesive. *J. Infect. Prev.* **2014**, *15*, 236–239. [CrossRef]
27. Lee, C.S.; Han, S.R.; Kye, B.H.; Bae, J.H.; Koh, W.; Lee, I.K.; Lee, D.-S.; Lee, Y.S. Surgical skin adhesive bond is safe and feasible wound closure method to reduce surgical site infection following minimally invasive colorectal cancer surgery. *Ann. Surg. Treat. Res.* **2020**, *99*, 146–152. [CrossRef]
28. Farion, K.J.; Russell, K.F.; Osmond, M.H.; Hartling, L.; Klassen, T.P.; Durec, T.; Vandermeer, B. Tissue adhesives for traumatic lacerations in children and adults. *Cochrane Database Syst. Rev.* **2002**, *2002*, CD003326. [CrossRef]
29. Lewis, T.L.; Goff, T.A.J.; Ray, R.; Varrall, C.R.; Robinson, P.W.; Fogarty, K.; Chang, A.; Dhaliwal, J.; Dearden, P.M.C.; Wines, A. Randomized Controlled Trial of Topical Skin Adhesive vs Nylon Sutures for Incision Closure in Forefoot Surgery. *Foot Ankle Int.* **2021**, *42*, 1106–1114. [CrossRef]
30. McQuillan, T.J.; Vora, M.; Hawkins, J.; Kenney, D.; Diaz, R.; Ladd, A.L. Adhesive Taping Shows Better Cosmetic Outcomes Than Tissue Adhesives for Sutured Upper Extremity Incisions: A Single-Blind Prospective Randomized Controlled Trial. *Orthopedics* **2022**, *45*, e42–e46. [CrossRef]
31. Sinha, S.; Naik, M.; Wright, V.; Timmons, J.; Campbell, A.C. A single blind, prospective, randomized trial comparing n-butyl 2-cyanoacrylate tissue adhesive (Indermil) and sutures for skin closure in hand surgery. *J. Hand Surg. Br.* **2001**, *26*, 264–265. [CrossRef] [PubMed]

**Disclaimer/Publisher's Note:** The statements, opinions and data contained in all publications are solely those of the individual author(s) and contributor(s) and not of MDPI and/or the editor(s). MDPI and/or the editor(s) disclaim responsibility for any injury to people or property resulting from any ideas, methods, instructions or products referred to in the content.

## 12.2. Drugi rad

Cureus

Open Access Original  
Article

DOI: 10.7759/cureus.53312

Review began 01/16/2024  
Review ended 01/28/2024  
Published 01/31/2024

© Copyright 2024  
Sunjic Roguljic et al. This is an open access article distributed under the terms of the Creative Commons Attribution License CC-BY 4.0., which permits unrestricted use, distribution, and reproduction in any medium, provided the original author and source are credited.

# The Influence of the Tissue Adhesive Material as a Surgical Wound-Closure Technique Following Carpal Tunnel Decompression on Neurological and Functional Outcomes: A Single-Center Randomized Controlled Trial

Veridijana Sunjic Roguljic <sup>1</sup>, Luka Roguljic <sup>2</sup>, Vedran Kovacic <sup>3</sup>, Ivica Bilic <sup>4</sup>, Ivana Jukic <sup>5</sup>

<sup>1</sup>. Department of Surgery, Division of Plastic, Reconstructive and Aesthetic Surgery With Burn Care, University Hospital of Split, Split, HRV <sup>2</sup>. Department of Surgery, Division of Orthopaedics and Traumatology, University Hospital of Split, Split, HRV <sup>3</sup>. Department of Internal Medicine, Division of Emergency and Intensive Medicine With Clinical Pharmacology and Toxicology, University Hospital of Split, Split, HRV <sup>4</sup>. Department of Neurology, Division of Clinical Neurology, University Hospital of Split, Split, HRV <sup>5</sup>. Department of Internal Medicine, University Hospital of Split, Split, HRV

Corresponding author: Vedran Kovacic, vedran.kovacic.split@gmail.com

## Abstract

### Background

Carpal tunnel syndrome (CTS) is caused by compression of the median nerve in the carpal tunnel. The effect of tissue adhesives as a material for wound closure following CTS decompression has been insufficiently investigated. This study aimed to evaluate outcomes by comparing two modalities of wound closure following carpal surgery in patients randomly assigned to either tissue adhesives or sutures.

### Methodology

This randomized, prospective study was conducted in April 2022 at the University Hospital of Split in Croatia. Patients aged 61.56 ± 12.03 years were randomized to either tissue adhesive Glubran Tiss 2®-based (n = 50) or suture-based (n = 50) wound-closure techniques. The following outcomes were assessed before surgery and six months postoperatively: hand strength, electroneurographic characteristics of the median nerve, and the Boston Carpal Tunnel Questionnaire.

### Results

Significant differences between glue-based and suture-based wound-closure techniques were found in the six-month postoperative hand grip strength (25.06 ± 6.69 vs. 21.41 ± 5.62 kg; p = 0.002), postoperative sensory amplitude (10.08 ± 5.50 vs. 7.54 ± 5.41 mV; p = 0.012), and postoperative sensory velocity (42.22 ± 11.04 vs. 35.23 ± 16.40 m/s; p = 0.008). In the glue-based group, significantly more patients achieved a postoperative sensory velocity greater than 45 m/s (47.9% vs. 22.0%; p = 0.006), postoperative distal sensory latency less than 3.5 ms (89.6% vs. 84.0%; p = 0.304), and postoperative motor latency of less than 4.2 ms (60.42% vs. 38.00%; p = 0.022).

### Conclusions

This trial demonstrated that cyanoacrylate-based adhesion material for wound closure after open CTS decompression compared with sutures showed a significant six-month postoperative increment in hand grip strength and median nerve sensory conduction.

**Categories:** Plastic Surgery

**Keywords:** hand function, cyanoacrylate, skin suture, skin adhesive, carpal tunnel

## Introduction

Carpal tunnel syndrome (CTS) is the most prevalent peripheral neuropathy caused by compression of the median nerve in the carpal tunnel. Its prevalence in the general population is between 3.8% and 5.8% [1]. CTS is caused by an ischemic injury to the median nerve caused by increased carpal tunnel internal pressure [2]. The consequences of such injuries include sensorimotor neuropathy with demyelination and structural abnormalities in the nerve. These abnormalities can reduce the neural transmission speed and action potentials of the median nerve in individuals affected by CTS [3]. Therefore, CTS is a potentially disabling condition. Hence, treatment aims to prevent and treat neurological and functional abnormalities caused by median nerve injury [4].

### How to cite this article

Sunjic Roguljic V, Roguljic L, Kovacic V, et al. (January 31, 2024) The Influence of the Tissue Adhesive Material as a Surgical Wound-Closure Technique Following Carpal Tunnel Decompression on Neurological and Functional Outcomes: A Single-Center Randomized Controlled Trial. Cureus 16(1): e53312. DOI 10.7759/cureus.53312

For mild-to-moderate cases, conservative therapy is advocated; however, for severe cases, surgery is required [5]. Surgery may be recommended for patients with severe CTS or whose symptoms have not subsided after four to six months of conservative therapy [6].

Although postsurgical complications are infrequent, possible sequelae might have a major influence on patients' disability, with scars, neurovascular damage, pillar discomfort, and diminished grip strength being the most common late consequences [7].

To improve neurological, functional, and aesthetic outcomes and to reduce the number of postsurgical complications in patients after surgical decompression of the carpal tunnel, numerous surgical techniques and modifications have been proposed [8,9]. Most of these studies observed differences in aesthetic effects or scar discomfort when comparing operative techniques during carpal tunnel decompression [10]. Postoperative scar discomfort can be decreased with proper wound closure. Therefore, in addition to comparing surgical approaches, some researchers examined different types of suture materials and their effect on postoperative outcomes after carpal tunnel decompression. It is unclear if absorbable sutures produce better, poorer, or similar results as non-absorbable sutures after carpal tunnel decompression [11].

Tissue adhesives have recently been used in surgical clinical practice. Tissue adhesives, such as 2-octyl cyanoacrylate (OCA), are becoming increasingly popular for strengthening wound closures because of their high tensile strength, bacteriostatic properties, and spontaneous peeling [12]. Therefore, tissue adhesives have found widespread use in a variety of surgical procedures. However, no obvious differences in dehiscence, infection, aesthetic appearance, or surgeon and patient satisfaction have been demonstrated between tissue adhesives and traditional wound-closure procedures [13].

Despite several proposed wound-closure procedures, there is a remarkable paucity of data on the potential relevance of tissue adhesives in open carpal tunnel decompression surgery. In a few comparative studies that used tissue adhesives as a material for wound closure following carpal surgery, the observed postoperative outcomes were mainly aesthetic [14]. Similarly, in our previous report, we found that cyanoacrylate-based tissue adhesion was superior in cosmetic outcomes and patient discomfort compared to conventional skin sutures for the closing of surgical wounds after CTS [15].

However, the effect of tissue adhesives as a material for wound closure following CTS decompression on medial nerve electrodiagnostic and hand function has not been investigated, despite improvements in medial nerve motor/sensory conduction and hand ability present very important endpoints of surgical decompression.

This study aimed to evaluate neurological and functional outcomes by comparing two modalities of wound closure following carpal surgery in patients who were randomly assigned to either tissue adhesive or sutures.

## Materials And Methods

### Patients and methods

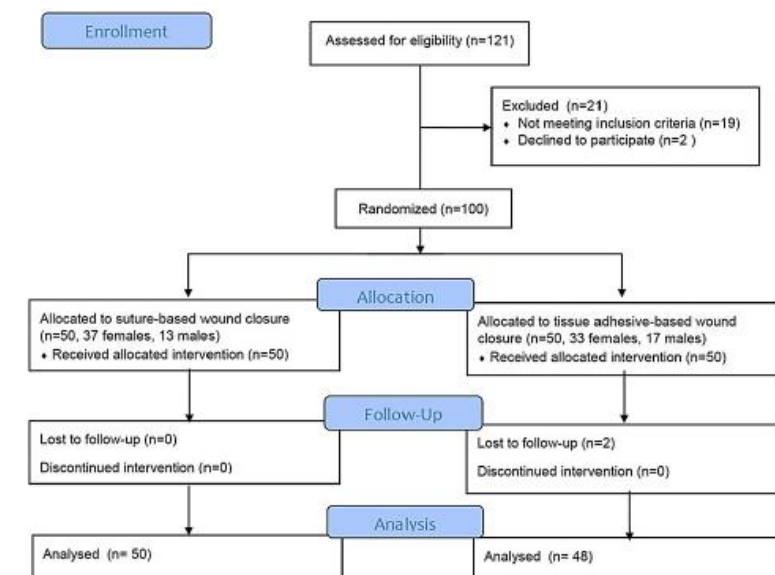
The Plastic, Reconstructive, and Aesthetic Surgery With Burn Care Division of the University Hospital of Split in Croatia conducted a single-center, randomized, controlled, prospective, interventional, follow-up trial. As the evaluators were blinded, the study was set up as a single-blind trial. The University Hospital of Split Ethics Committee authorized the study protocol (ethics code: 500-05/22-01/41 approved) on March 31, 2022. The Consolidated Standards of Reporting Trials (CONSORT) guidelines and the Declaration of Helsinki tenets were followed in the conduct of the study. Every participant in the study gave their informed consent. This study was registered at Clinicaltrials.gov as a clinical trial (NCT05808855).

### Study population

Adult patients (>18 years old) who had previously been diagnosed with CTS and were scheduled for decompression surgery in our department were included in the study. The diagnosis was based on history, physical examination (weakness of thumb abduction with thenar atrophy), and neurological examination with nerve conduction velocity assessment. The inclusion criteria for surgery included total failure of conservative therapy for more than six months and serious limitations such as thenar atrophy, thumb abduction weakness, or severe median nerve conduction impairment, as measured by electromyography. All patients had positive Tinel's sign and Phalen's test, which are sensitive and specific provocative tests used to diagnose CTS. During the appointment, the attending plastic surgeon made the recommendation for surgery, and the patient was booked for surgery the following month. Exclusion criteria included patients on peroral anticoagulation and/or antithrombotic therapy, previous wrist trauma or surgery on the wrist region, any other cause of neuropathy, previous allergic reactions (with lidocaine, cyanoacrylate, formaldehyde, tapes, or adhesives), a personal or family history of keloids or hypertrophic scars, and severe general illness with cachexia.

### Study flow

Recruitment of study participants began on April 1, 2022. During the study period, 121 participants were recruited, and after applying exclusion criteria to 19 patients and two patients rejecting to participate, 100 patients were included in the trial. During the six-month follow-up in the postoperative period, two participants dropped out of the study (Figure 1). The sample size was calculated taking into account the expected variability of hand grip strength from previous studies as the main outcome measure [16], considering an alpha error of 0.05 to recognize a significant difference and 90% test power. For this study power, the minimum number of participants was estimated at 31 in each group.



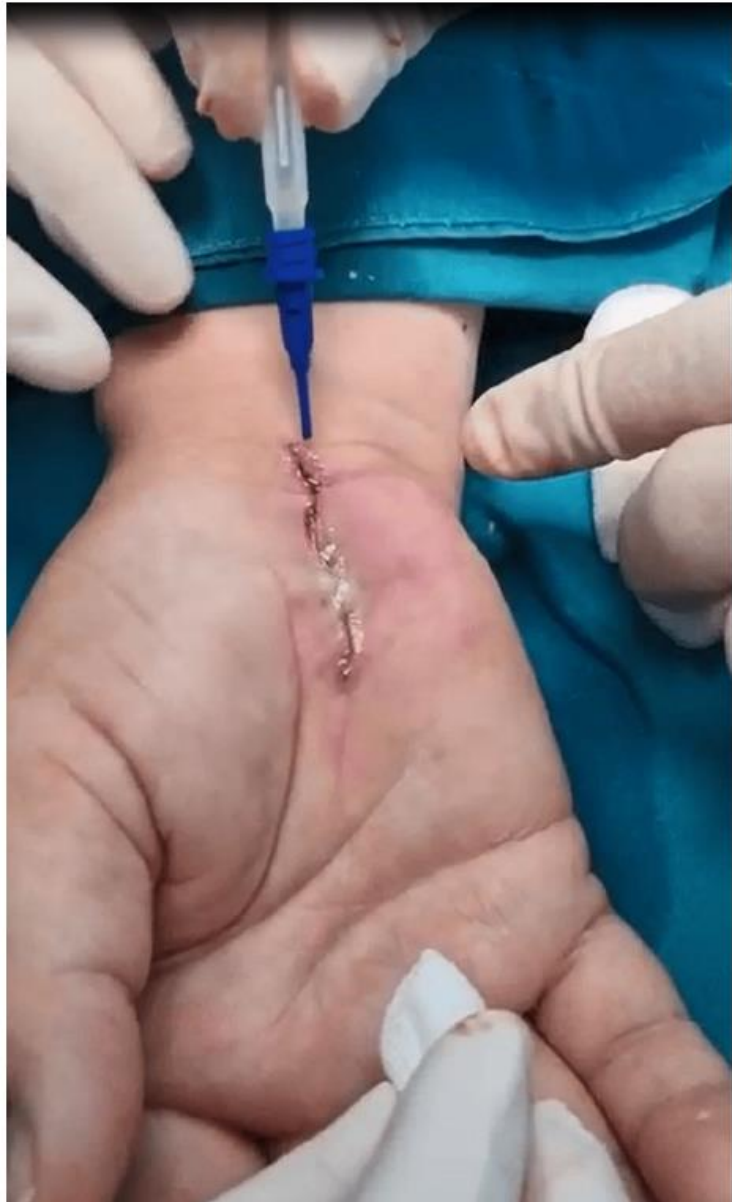**FIGURE 1: CONSORT flow diagram of the study.**

Patients were randomly assigned to suture-based wound closure or tissue adhesive-based wound closure. A computer created the randomization as random numbers in a 1:1 ratio between the two interventions. The intervention was hidden from participants and plastic surgeons until they entered the operating room. Regardless of the intervention group, postoperative treatment and follow-up visits were the same. None of the patients experienced any side effects from the medication.

### Procedures for interventions

Every surgical treatment was performed in the carpal tunnel and palmar soft tissues under local anesthesia with 2% lidocaine using a tourniquet. A pneumatic forearm tourniquet was used to achieve a blood-free operative field. The patients tolerated the tourniquet well, and the mean surgery decompression time was  $8.71 \pm 0.57$  minutes. The conventional carpal canal decompression treatment involved cutting and transection of the carpal ligaments after a 15-18 mm skin incision in the radial half of the palm for all individuals [17]. Carpal tunnel decompression operations and sutures were performed by five highly experienced plastic surgeons with more than 10 years of experience in plastic surgery after obtaining a license for plastic and reconstructive surgery.

Two wound-closure techniques were applied based on the randomization group of the patients. (1) Transcutaneous 4-0 nylon sutures (polypropylene-polyethylene monofilament, non-absorbable surgical sutures) were used to sew the skin (B. Braun Surgical, S.A. Carretera de Terrassa, Spain; Optilene® DSMP 19, 3/8 needle, thread size 4/0). (2) Following a subcutaneous buried running continuous stitch using 4-0 coated Vicryl™ Plus PS-2, 3/8 (Ethicon Inc., USA), Glubran Tiss 2® (GEM S.r.l., Viareggio, Italy), a two-component skin adhesive, was applied. Glubran Tiss 2® is a synthetic surgical glue with bacteriostatic, adhesion, hemostatic, and sealing qualities that is made up of n-butyl 2-cyanoacrylate (NBCA) and OCA [18]. It instantly polymerizes into a thin, elastic film with exceptional tensile strength when applied to wet tissue, adhering firmly to the tissue's structure. One type of bio-inert substance is polymerized glue. After each patient received 0.35 mL of Glubran Tiss® in the open wound, they relaxed for 20 seconds to allow the polymerization process to occur before bandaging (Figure 2).



**FIGURE 2: Image demonstrating wound closure with Glubran Tiss® composed of n-butyl 2 cyanoacrylate and 2-octyl cyanoacrylate.**

Postoperative treatment included the use of a compressive bandage for one day and the administration of analgesics. If necessary, a thin plastic tube was implanted for drainage in the first two postoperative days. Daily wound dressing visits were made by the attending surgeon and nurse.

Subcutaneous buried continuous stitch was a major component of wound closure in the glue-based group, and the possible effect of an inflammatory process secondary to thread resorption needed to be estimated. Therefore, to assess the possible effect of inflammation due to suture resorption, the number of postoperative complications was recorded in both groups.

#### **Estimation of outcome measures**

Demographic data, gender, weight, height, previous illnesses, laboratory diagnostic tests, duration of symptoms, and previous physical therapy were recorded for each patient included in the study at the beginning (immediately before surgery). At the beginning of the study, hand strength was assessed with a dynamometer, and nerve conduction studies with an electroneurographic examination of the motor and sensory characteristics of the median nerve were performed on the hand planned for the operation.

Hand strength was measured with a dynamometer, and the primary result was hand grip strength. Dynamometry is a well-documented method for objectively quantifying motor outcomes and hand strength, particularly for assessing the outcome of carpal tunnel release surgery [19]. The hand grip strength test measures the motor component of all muscles involved in a hand grip and measures the motor function of maximum effort by patients who squeezed the dynamometer as hard as possible for three to five seconds. The hand grip strength of the operated arm was assessed using a hydraulic hand dynamometer, KERN MAP 130 K1 Version 1-2 (GB, Balingen, Germany). During the measurement, patients were sitting with the shoulder adducted and neutrally rotated, the elbow bent at 90°, and the forearm and wrist in a neutral position without any support. The instruction was to squeeze the handle of the dynamometer as hard as possible for three to five seconds. Subsequently, patients were exposed to median nerve conduction studies with electroneurography (ENG) to assess the function and conduction of the median nerve through the carpal tunnel (speed, latency, and amplitude of motor and sensory conduction). ENG measurements were performed with a Medelec Synergy v.11, Nicolet EDX (Domestic Natus Neurology Incorporated, WI, USA) distally across the wrist. The hands were sufficiently warmed to maintain a skin temperature of 32°C to 34°C while the patient was in a comfortable supine position. Motor outcome measures included median nerve motor latency (ms), median nerve motor amplitude (mV), and median nerve motor conduction velocity (m/s). Sensory measures included median nerve sensory conduction velocity (m/s), median nerve sensory amplitude (mV), and median nerve sensory latency (ms). The following were considered normal values for the median nerve: sensory conduction velocity >45 m/s, peak distal sensory latency <3.5 ms, sensory nerve action potential amplitude >10 mV, distal motor latency <4.2 ms, distal motor amplitude >5 mV, and motor conduction velocity >50 m/s [20]. After sensory and motor ENG measurements, the total ENG Bland score was calculated for each subject [21]. The Bland scale ranges from 0 to 6, where 0 represents a normal finding, and 6 represents the worst finding with sensory and motor potentials effectively unrecordable.

At the beginning of the study, the Boston Carpal Tunnel Questionnaire (BCTQ) was administered to every participant. BCTQ [22] was completed by the patient and consists of two scales: the Boston Symptom Severity Scale (SSS) and the Functional Status Scale (FSS). The Boston SSS uses a five-point rating scale for 11 questions on pain, paresthesia, numbness, weakness, nocturnal symptoms, and difficulty grasping, with a final score ranging from 11 to 55. A higher score suggests a higher level of impairment. The FSS also uses a five-point rating scale for eight questions to estimate the degree of difficulty in typical daily activities (writing, buttoning clothes, holding a book while reading, gripping a telephone handle, opening jars, performing household chores, carrying grocery bags, bathing, and dressing). The final score ranges from 8 to 40. A higher score indicates a greater degree of disability. After six months, hand grip strength measurements, BCTQ scores, and measurements of sensory and motor neuroelectrical conduction properties of the median nerve with Bland scores were again determined for all included participants. Changes (delta) in all variables compared to the initial values were calculated.

### Statistical analysis

Calculations and data for descriptive statistics were expressed as the median with interquartile range if the data were non-normally distributed, or as the arithmetic mean  $\pm$  standard deviation if the data were normally distributed. The Kolmogorov-Smirnov test was employed to estimate the distributional normality of quantitative variables. To compare qualitative data between groups, Fisher's exact test and chi-square test were used. A paired and an unpaired Student's t-test were used to compare quantitative data. To analyze and compare quantitative variables with a non-normal distribution, the Mann-Whitney test for unpaired variables and the Wilcoxon signed ranks test for paired variables were used. The statistical analysis was performed using SPSS Statistics for Windows version 26.0 (IBM Corp., Armonk, NY, USA). Two-tailed p-values less than 0.05 were considered significant.

### Results

The study participants consisted of 100 patients (30 males and 70 females) randomly assigned in a 1:1 ratio for wound closure with glue (n = 50) and sutures (n = 50). After postoperative follow-up, 98 participants were assessed. The age of the entire cohort was  $61.56 \pm 12.03$  years. The mean surgery decompression time was  $8.71 \pm 0.57$  minutes. We could not find differences between surgery decompression time between the glue-based and suture-based groups ( $8.74 \pm 0.57$  vs.  $8.67 \pm 0.57$  minutes,  $p = 0.264$ ). The right-side surgery was performed on 57 patients, while the left-side surgery was performed on 45 patients.

To measure the possible effect of inflammation due to suture resorption in the glue plus subcutaneous suture-based wound closure group, early and late postoperative complications were compared between both groups. In the entire cohort, 12 individuals experienced the following early postoperative complications after 15 days: redness (five cases), dehiscence (two cases), hemorrhage (two cases), infection (one case), allergic dermatitis (one case), and secretion (one case). Following a 12-week surgical period, which is the



time after thread resorption in the group with subcutaneous continuous sutures, eight patients experienced late complications, five had granulomas, two had secretions, and one had an infection. There were no statistically significant differences in the number of early or late complications between the glue plus subcutaneous suture-based wound closure and the transcutaneous suture-based wound closure groups ( $\chi^2 < 0.001$ ,  $p = 0.620$ , and  $\chi^2 = 0.54$ ,  $p = 0.375$ , respectively).

Differences in functional, clinical, and electroneurographic parameters before and after decompression surgery for all participants and the groups are presented in Tables 1-3. From these data, it is evident that a vast majority of parameters significantly improved after surgical decompression of the carpal tunnel, with small exceptions between the groups. In the glue-based wound closure group, the difference in motor amplitude of the median nerve before and after decompression surgery did not reach a significant difference. The difference in motor velocity of the median nerve before and after decompression surgery was not significant in the suture-based wound closure group.

|                         | Before surgery   | 6 months after surgery | P-values         |
|-------------------------|------------------|------------------------|------------------|
|                         | Mean ± SD        | Mean ± SD              |                  |
| Hand grip strength (kg) | 18.52 ± 5.64     | 23.20 ± 6.40           | <b>&lt;0.001</b> |
| Sensory latency (ms)    | 3.55 ± 1.59      | 2.72 ± 0.99            | <b>&lt;0.001</b> |
| Sensory amplitude (mV)  | 4.55 ± 3.76      | 8.78 ± 5.58            | <b>&lt;0.001</b> |
| Sensory velocity (m/s)  | 29.33 ± 15.52    | 38.65 ± 14.40          | <b>&lt;0.001</b> |
| Motor latency (ms)      | 5.54 ± 1.60      | 4.46 ± 1.40            | <b>&lt;0.001</b> |
| Motor amplitude (mV)    | 6.55 ± 4.17      | 7.70 ± 3.81            | <b>0.015</b>     |
| Motor velocity (m/s)    | 50.29 ± 12.61    | 55.14 ± 8.10           | <b>0.001</b>     |
| BCTQ-SSS                | 41.95 ± 8.06     | 22.45 ± 6.34           | <b>&lt;0.001</b> |
| BCTQ-FSS                | 27.66 ± 9.17     | 14.46 ± 5.09           | <b>&lt;0.001</b> |
| Bland score             | 4.00 (3.00-5.00) | 3.00 (3.00-3.00)       | <b>&lt;0.001</b> |

**TABLE 1: Differences in hand grip strength, clinical features, and electroneurographic conduction parameters of the median nerve before and after decompression surgery for all participants (N = 98) (Student's t-test for dependent samples or Wilcoxon signed-rank test).**

P-values for significant differences (two-tailed) are bolded. Data are presented as the arithmetic mean ± standard deviation, or median (with interquartile range) for non-parametric data.

BCTQ = Boston Carpal Tunnel Questionnaire; SSS = symptom severity scale; FSS = functional status scale

|                         | Before surgery    | 6 months after surgery | P-values         |
|-------------------------|-------------------|------------------------|------------------|
|                         | Mean $\pm$ SD     | Mean $\pm$ SD          |                  |
| Hand grip strength (kg) | 19.48 $\pm$ 5.95  | 25.06 $\pm$ 6.69       | <b>&lt;0.001</b> |
| Sensory latency (ms)    | 3.73 $\pm$ 1.90   | 2.65 $\pm$ 0.60        | <b>&lt;0.001</b> |
| Sensory amplitude (mV)  | 5.01 $\pm$ 4.00   | 10.08 $\pm$ 5.50       | <b>&lt;0.001</b> |
| Sensory velocity (m/s)  | 27.73 $\pm$ 15.24 | 42.22 $\pm$ 11.04      | <b>&lt;0.001</b> |
| Motor latency (ms)      | 5.44 $\pm$ 1.61   | 4.39 $\pm$ 1.82        | <b>0.002</b>     |
| Motor amplitude (mV)    | 7.28 $\pm$ 3.91   | 8.08 $\pm$ 3.80        | 0.241            |
| Motor velocity (m/s)    | 51.62 $\pm$ 8.11  | 56.38 $\pm$ 5.04       | <b>&lt;0.001</b> |
| BCTQ-SSS                | 42.65 $\pm$ 9.10  | 23.19 $\pm$ 6.41       | <b>&lt;0.001</b> |
| BCTQ-FSS                | 26.81 $\pm$ 6.62  | 14.08 $\pm$ 5.61       | <b>&lt;0.001</b> |
| Bland score             | 3.00 (3.00-4.75)  | 3.00 (3.00-3.00)       | <b>0.002</b>     |

**TABLE 2: Differences in hand grip strength, clinical features, and electroneurographic conduction parameters of the median nerve before and after decompression surgery for glue-based wound closure participants (N = 48) (Student's t-test for dependent samples or Wilcoxon-signed rank test).**

P-values for significant differences (two-tailed) are bolded. Data are presented as the arithmetic mean  $\pm$  standard deviation, or median (with interquartile range) for non-parametric data.

BCTQ = Boston Carpal Tunnel Questionnaire; SSS = symptom severity scale; FSS = functional status scale

|                         | Before surgery   | 6 months after surgery | P-value          |
|-------------------------|------------------|------------------------|------------------|
|                         | Mean ± SD        | Mean ± SD              |                  |
| Hand grip strength (kg) | 17.61 ± 5.22     | 21.41 ± 5.62           | <b>&lt;0.001</b> |
| Sensory latency (ms)    | 3.35 ± 1.14      | 2.80 ± 1.30            | <b>0.009</b>     |
| Sensory amplitude (mV)  | 4.10 ± 3.49      | 7.54 ± 5.41            | <b>&lt;0.001</b> |
| Sensory velocity (m/s)  | 30.86 ± 15.79    | 35.23 ± 16.40          | <b>0.015</b>     |
| Motor latency (ms)      | 5.64 ± 1.60      | 4.53 ± 0.85            | <b>&lt;0.001</b> |
| Motor amplitude (mV)    | 5.86 ± 4.33      | 7.34 ± 3.82            | <b>0.024</b>     |
| Motor velocity (m/s)    | 49.04 ± 15.70    | 53.98 ± 10.08          | 0.055            |
| BCTQ-SSS                | 41.28 ± 6.95     | 21.74 ± 6.27           | <b>&lt;0.001</b> |
| BCTQ-FSS                | 28.48 ± 11.09    | 14.82 ± 4.57           | <b>&lt;0.001</b> |
| Bland score             | 4.00 (3.00-5.00) | 3.00 (3.00-3.00)       | <b>0.001</b>     |

**TABLE 3: Differences in hand grip strength, clinical features, and electroneurographic conduction parameters of the median nerve before and after decompression surgery for suture-based wound closure participants (N = 50) (Student's t-test for dependent samples or Wilcoxon signed-rank test).**

P-values for significant differences (two-tailed) are bolded. Data are presented as the arithmetic mean ± standard deviation, or median (with interquartile range) for non-parametric data.

BCTQ = Boston Carpal Tunnel Questionnaire; SSS = symptom severity scale; FSS = functional status scale

Differences in functional, clinical, and electroneurographic parameters between glue-based wound closure and suture-based wound closure patients are demonstrated in Table 4. Significant differences between the two wound-closure techniques were found in postoperative hand grip strength, delta pre- and postsurgical sensory latency, postoperative sensory amplitude, and postoperative sensory velocity; these results favored glue-based wound closure. These significant differences between glue-based and suture-based wound-closure techniques with preoperative and postoperative values are shown in Figure 3.

|   | Glue-based technique | Suture-based technique | P-value      |
|---|----------------------|------------------------|--------------|
|   | N = 48               | N = 50                 |              |
|   | Mean ± SD            | Mean ± SD              |              |
| Age (years)                               | 63.02 ± 12.967       | 60.10 ± 10.95          | 0.113        |
| Body mass index (kg/m <sup>2</sup> )      | 24.79 ± 3.172        | 25.04 ± 2.25           | 0.325        |
| Hand grip strength, preoperative (kg)     | 19.48 ± 5.95         | 17.61 ± 5.22           | 0.051        |
| Hand grip strength, 6 months (kg)         | 25.06 ± 6.69         | 21.41 ± 5.62           | <b>0.002</b> |
| Delta, hand grip strength (post-pre) (kg) | 5.58 ± 3.29          | 3.80 ± 2.50            | <b>0.002</b> |
| Sensory latency, preoperative (ms)        | 3.73 ± 1.90          | 3.35 ± 1.14            | 0.137        |
| Sensory latency, 6 months (ms)            | 2.69 ± 0.60          | 3.14 ± 1.96            | 0.067        |
| Delta, sensory latency (pre-post) (ms)    | 1.07 ± 1.61          | 0.54 ± 1.25            | <b>0.049</b> |
| Sensory amplitude, preoperative (mV)      | 5.01 ± 4.00          | 4.10 ± 3.49            | 0.117        |
| Sensory amplitude, 6 months (mV)          | 10.08 ± 5.50         | 7.54 ± 5.41            | <b>0.012</b> |
| Delta, sensory amplitude (post-pre) (mV)  | 5.07 ± 4.39          | 3.43 ± 3.95            | <b>0.028</b> |

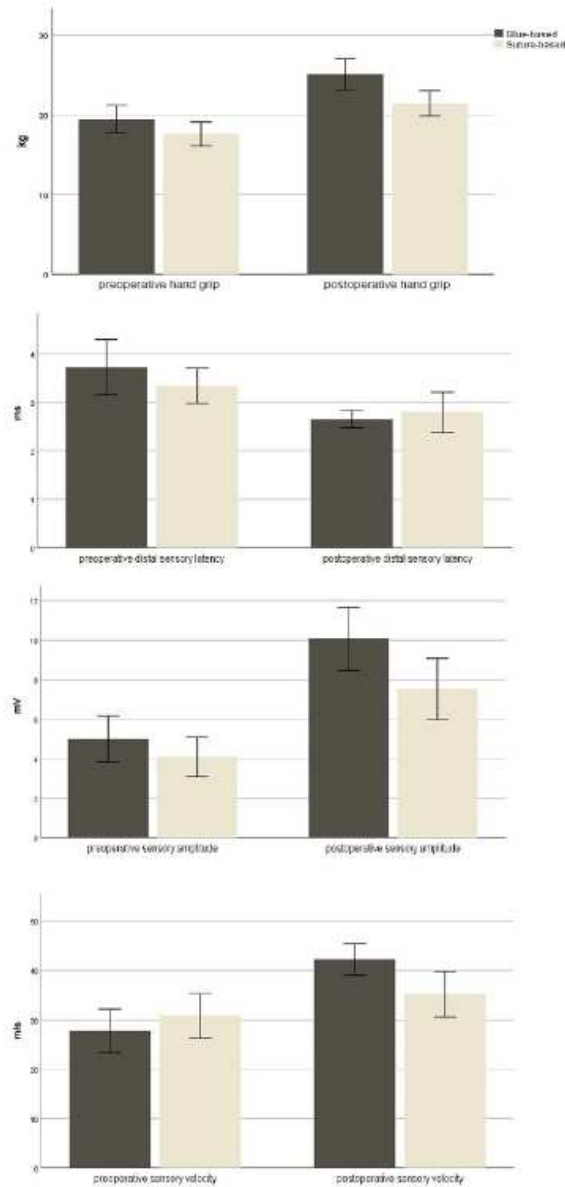
## Cureus

|  |                  |                  |                  |
|--|------------------|------------------|------------------|
| Sensory velocity, preoperative (m/s)     | 27.73 ± 15.24    | 30.86 ± 15.79    | 0.161            |
| Sensory velocity, 6 months (m/s)         | 42.22 ± 11.04    | 35.23 ± 16.40    | <b>0.008</b>     |
| Delta, sensory velocity (post-pre) (m/s) | 14.48 ± 13.25    | 4.38 ± 12.33     | <b>&lt;0.001</b> |
| Motor latency, preoperative (ms)         | 5.44 ± 1.61      | 5.64 ± 1.60      | 0.273            |
| Motor latency, 6 months (ms)             | 4.39 ± 1.82      | 4.53 ± 0.85      | 0.310            |
| Delta, motor latency (pre-post) (ms)     | 1.06 ± 2.24      | 1.11 ± 1.69      | 0.446            |
| Motor amplitude, preoperative (mV)       | 7.28 ± 3.91      | 5.86 ± 4.33      | <b>0.046</b>     |
| Motor amplitude, 6 months (mV)           | 8.08 ± 3.80      | 7.34 ± 3.82      | 0.170            |
| Delta, motor amplitude (post-pre) (mV)   | 0.80 ± 4.69      | 1.48 ± 4.50      | 0.233            |
| Motor velocity, preoperative (m/s)       | 51.62 ± 8.11     | 49.04 ± 15.70    | 0.158            |
| Motor velocity, 6 months (m/s)           | 56.38 ± 5.04     | 53.98 ± 10.08    | 0.073            |
| Delta, motor velocity (post-pre) (m/s)   | 4.76 ± 8.56      | 4.94 ± 17.77     | 0.474            |
| BCTQ-SSS, preoperative                   | 42.65 ± 9.10     | 41.28 ± 6.95     | 0.202            |
| BCTQ-SSS, 6 months                       | 23.19 ± 6.41     | 21.74 ± 6.27     | 0.130            |
| Delta, BCTQ-SSS (post-pre)               | 19.46 ± 7.51     | 19.54 ± 6.03     | 0.476            |
| BCTQ-FSS, preoperative                   | 26.81 ± 6.62     | 28.48 ± 11.09    | 0.185            |
| BCTQ-FSS, 6 months                       | 14.08 ± 5.61     | 14.82 ± 4.57     | 0.238            |
| Delta, BCTQ-FSS (post-pre)               | 12.73 ± 5.97     | 13.66 ± 9.50     | 0.282            |
| Bland score, preoperative                | 3.00 (3.00-4.75) | 4.00 (3.00-5.00) | 0.142            |
| Bland score, 6 months                    | 3.00 (3.00-3.00) | 3.00 (3.00-3.00) | 0.245            |
| Delta, Bland score (pre-post)            | 0.00 (0.00-1.00) | 0.50 (0.00-1.00) | 0.224            |

**TABLE 4: Differences in hand grip strength, clinical features, and electroneurographic conduction parameters of the median nerve between glue-based wound closure and suture-based wound closure (Student's t-test for independent samples or Mann-Whitney test for non-parametric data).**

P-values for significant differences are bolded. Data are presented as the arithmetic mean ± standard deviation or median (with interquartile range) for non-parametric data.

BCTQ = Boston Carpal Tunnel Questionnaire; SSS = symptom severity scale; FSS = functional status scale



**FIGURE 3: The differences between glue-based and suture-based wound-closure techniques in preoperative and postoperative values of hand grip, distal sensory latency, sensory action potential amplitude, and sensory conduction velocity of the median nerve.**

In the glue-based wound closure group, 25 (47.9%) patients achieved a postoperative sensory velocity greater than 45 m/s, while in the suture group, only 11 (22.0%) patients achieved a postoperative sensory velocity greater than 45 m/s. The difference was statistically significant ( $\chi^2 = 7.260$ ;  $p = 0.006$ ). A greater number of participants in the glue-based wound closure group achieved an increase in sensory velocity after surgery compared to the suture group (44 or 91.8% vs. 38 or 76.0%), and the difference was statistically significant ( $\chi^2 = 4.400$ ;  $p = 0.033$ ). In the glue-based wound closure group, 43 (89.6%) patients achieved postoperative peak distal sensory latency of less than 3.5 ms compared to 42 (84.0%) in the suture group. The difference did not reach significance ( $\chi^2 = 0.664$ ;  $p = 0.304$ ). In the glue-based wound closure group, 19 (39.6%) patients

reached a sensory nerve action potential amplitude higher than 10 mV compared to 14 (28.0%) in the suture group. The difference did not reach significance ( $\chi^2 = 1.471$ ;  $p = 0.159$ ). In the glue-based wound closure group, 29 (60.42%) patients achieved postoperative motor latency of less than 4.2 ms compared to only 19 (38.00%) in the suture group. The difference was statistically significant ( $\chi^2 = 4.925$ ;  $p = 0.022$ ). In the glue-based wound closure group, there were more patients with postoperative motor amplitude greater than 5 mV than in the suture group (40 patients, or 83.3%, vs. 37 patients, or 74.0%), but statistical significance was not reached ( $\chi^2 = 1.267$ ;  $p = 0.190$ ). The glue-based wound closure group had 44 (93.6%) patients with a postoperative motor velocity greater than 50 m/s compared to 42 (84.0%) in the suture group, and the difference was not significant ( $\chi^2 = 2.229$ ;  $p = 0.120$ ).

## Discussion

The results of this randomized clinical study demonstrated significant six-month postoperative augmentation of hand grip as an important functional indicator, as well as an increase in median nerve conduction parameters in the group of patients whose surgical wound was closed with tissue glue and subcutaneous sutures compared to the group whose surgical wound was closed with transcutaneous sutures. We were unable to demonstrate differences in the BCTQ between the two surgical wound-closure techniques. However, electrophysiologic indices estimated by median nerve conduction parameters are important markers of CTS severity and have been found to be correlated with hand functional disability levels. For example, nerve conduction measured as median motor latency  $>4.2$  ms and median sensory latency  $>5.5$  ms are considered markers of severe CTS [3]. In our study, we showed a significant postoperative improvement in sensory median nerve conduction parameters in the group of patients whose surgical wound was closed with tissue glue. Furthermore, in the glue-based wound closure group, significantly more patients achieved a postoperative sensory velocity  $>45$  m/s, a postoperative peak distal sensory latency  $<3.5$  ms, and a postoperative motor latency  $<4.2$  ms. Likewise, we showed significantly better postoperative hand grip results in the group of patients whose wound was closed with tissue glue, which we consider an important result. Hence, the dynamometric measurement of grip strength represents a major postoperative outcome measure and has an impact on the long-term outcomes of patients with CTS [19].

The results of our study also showed a statistically significant postoperative improvement in electroneurographic, clinical, and functional parameters in all patients, as well as in separate groups of patients. This is similar to the results of previous studies, which also showed a statistically significant improvement in the electrophysiological parameters of the median nerve, as well as an improvement in the clinical characteristics of the hand, including Boston questionnaire results, after decompression surgery for CTS [23,24]. This proves the effectiveness of surgical treatment for CTS compared to other treatment modalities. For example, in a study of 18 CTS patients, El-Hajj et al. [25] found an 82.3% improvement in nerve conduction parameters after surgery, which increased to 88.2% after nine months.

Therefore, the measurement of the electroneurographic parameters of the median nerve with or without measurement of hand functional capabilities serves as an important outcome to compare the effectiveness of various treatment modalities [26]. A randomized clinical trial comparing local corticosteroid injection and decompressive surgery for CTS found significant improvements in distal motor latency, sensory conduction velocity, and sensory amplitude in the surgery group 12 months after treatment [27].

Likewise, these electrophysiological neurological outcomes as well as functional outcomes serve to evaluate the success of a surgical CTS treatment [28]. Accordingly, these electrophysiological and/or functional outcomes were used to evaluate differences between standard surgical procedures and surgical modifications, such as mini-invasive techniques like endoscopic and mini-open approaches to the carpal tunnel [29]. In 62 patients with CTS, Tian et al. [30] reported no significant differences between open or endoscopic carpal tunnel release in postoperative improvements of clinical and electromyography parameters tested before the operation and three months after the operation. In one study, postoperative median nerve distal motor latency, motor transmission velocity, and sensory nerve action potential were measured three, six, and 12 months after surgery and did not differ between the groups following CTS surgery. The control group underwent standard surgical decompression, and the intervention group underwent surgical decompression with a single injection of platelet-rich plasma introduced through the mini-vacuum drain [31]. Similarly, modified Camitz opponensplasty did not correlate with neurologic and muscle recovery in a study of 21 participants with severe CTS [32]. A retrospective study that compared endoscopic carpal tunnel release with open carpal tunnel release did not find any differences in outcomes, including electromyographic abnormalities [33]. A similar prospective study compared endoscopic carpal tunnel decompression with open carpal tunnel decompression and did not find differences between the two techniques in functional and electromyography outcomes, despite a significant shortening in median nerve motor distal latency and an increase in the velocity of sensory conduction in both groups [34]. A retrospective analysis of 114 CTS patients compared two surgical procedures, namely, classical open neurolysis of the median nerve with flexor retinaculum lengthening according to the Simonetta technique, and demonstrated that ligamentoplasty according to the Simonetta technique led to better manual force in 10 years of follow-up [35]. A prospective, randomized, double-blind, controlled trial involving 50 CTS patients compared the longitudinal epineurotomy of the median nerve with the simple dissection of the

carpal ligament and found no differences in distal motor latency, distal sensory latency, or grip strength after 180 days of follow-up [36]. Boumediene et al. [37], in 31 patients with recurrent CTS, compared two modifications of surgical treatments, including the application of carboxymethylcellulose/polyethylene oxide gel added to the Canaletto® implant with such anti-adhesion gel alone. The study could not demonstrate postoperative differences in the distal motor latency and sensory nerve conduction speed between the groups. Bilge et al [38], compared 200 CTS patients divided after mini-incision open surgery into two groups, i.e., whether they received or did not receive local administration of anti-adhesion gel consisting of hyaluronic acid-carboxymethylcellulose. They could not demonstrate a significant difference between groups in the Boston questionnaire after the operation. In conclusion, the majority of previous studies comparing different surgical techniques found no significant differences in functional and/or neurological outcomes between surgical modalities.

In recent years, cyanoacrylate-based skin glue has grown in popularity in various surgical procedures for ensuring and maintaining wound closure due to the acknowledged benefits of these glues in their ability to physically isolate the surgical incision and reduce the risk of surgical site infection [39,40]. Although skin adhesives have been extensively explored for wound closure in various surgical procedures, only a few studies have assessed skin adhesives following carpal tunnel decompression and reported only aesthetic outcomes. A prospective randomized controlled trial compared adhesive tape and a tissue adhesive (OCA) applied after primary closure with a 4-0 absorbable suture to different halves of the same surgical incision after carpal tunnel decompression and reported that the adhesive strips provided significant improvement in cosmetic outcomes observed by a surgeon three months after the surgery [14]. In a prospective randomized study, Sinha et al. [41] compared the closure of hand surgery wounds (including 22 CTS patients) with a tissue adhesive (NBCA) or with the standard wound-closure technique (4-0 monofilament suture) and could not demonstrate significant differences in the cosmetic outcomes at two and six weeks after surgery. Finally, we previously reported in a randomized controlled trial that wound closure using cyanoacrylate-based adhesion material compared to a control group that used sutures as a wound-closure procedure following open CTS was significantly better in terms of aesthetic outcomes, discomfort, and patient compliance at two and six weeks postoperatively [15]. This randomized clinical trial is the first to demonstrate the differences between wound closure with tissue adhesives and classical wound closure with sutures in patients with CTS concerning neurological and functional outcomes. However, it should be emphasized that these significant postoperative differences between the groups in hand strength and median nerve electroneurographic parameters improvement are exclusively the result of the differences in the two surgical techniques for closing the surgical wound, i.e., the one that uses glue plus subcutaneous running continuous stitch and the one that uses transcutaneous sutures. The same experienced operators operated both groups of patients with no difference in the duration of the procedure. Likewise, the influence of inflammation secondary to thread resorption in the glue subcutaneous stitch group probably did not affect the outcome measures because no significant difference was shown between the postoperative complications in the two groups. Finally, the obtained significant postoperative differences in outcome measures can not only be attributed exclusively to the use of tissue glue but also to the difference between subcutaneous and transcutaneous sutures. Specifically, patients with transcutaneous sutures are spared the discomfort and pain of suture removal. Furthermore, classic transcutaneous suturing involves a larger area of the sutured tissue (skin and subcutaneous tissue). In contrast, with a subcutaneous suture using tissue glue, the tension of the wound is equally distributed with reduced pressure of the sutures on the skin where the nociceptors are located, and, therefore, this group can start using the operated hand earlier.

### Limitations

This study has certain limitations. First, this trial was restricted to a single center. Second, the six-month follow-up period is not long enough to conclude the long-term effects of the intervention. Third, to further understand the impact of the intervention, it is necessary to monitor additional clinical, histological, and biomechanical parameters. Fourth, the obtained differences in outcome measures are not exclusively a consequence of the application of tissue glue but also of the use of a continuous subcutaneous suture, which can significantly affect the strength and tension of the wound closure.

### Conclusions

This randomized controlled trial demonstrated that cyanoacrylate-based adhesion material in combination with a subcutaneous continuous stitch for wound closure after open CTS decompression has an advantage over transcutaneous sutures in terms of functional markers measured as hand grip strength and neurological indices measured as median sensory nerve conduction parameters. Wound closure after CTS decompression surgery can be efficiently and safely realized with cyanoacrylate-based tissue adhesives, with anticipated beneficial effects on median nerve recovery and the improvement of hand strength. Larger multicenter trials with longer follow-ups and additional outcomes are required to further strengthen the conclusions of this study.

### Additional Information

#### Author Contributions

All authors have reviewed the final version to be published and agreed to be accountable for all aspects of the

work.

**Concept and design:** Vedran Kovacic, Veridijana Sunjic Roguljic, Luka Roguljic, Ivica Bilic, Ivana Jukic

**Acquisition, analysis, or interpretation of data:** Vedran Kovacic, Veridijana Sunjic Roguljic, Luka Roguljic, Ivica Bilic, Ivana Jukic

**Drafting of the manuscript:** Vedran Kovacic, Veridijana Sunjic Roguljic, Luka Roguljic, Ivica Bilic, Ivana Jukic

**Critical review of the manuscript for important intellectual content:** Vedran Kovacic, Veridijana Sunjic Roguljic, Luka Roguljic, Ivica Bilic, Ivana Jukic

**Supervision:** Vedran Kovacic, Veridijana Sunjic Roguljic, Luka Roguljic, Ivica Bilic, Ivana Jukic

## Disclosures

**Human subjects:** Consent was obtained or waived by all participants in this study. Ethics Committee at the University Hospital of Split issued approval 500-03/22-01/41. The study protocol was approved by the Ethics Committee at the University Hospital of Split (500-03/22-01/41) on March 31, 2022. The study was conducted according to the principles of the Declaration of Helsinki and the Consolidated Standards of Reporting Trials (CONSORT) guidelines. Informed consent was obtained from all patients involved in the study. This clinical was trial registered with [www.clinicaltrials.gov](http://www.clinicaltrials.gov) (NCT05808855). **Animal subjects:** All authors have confirmed that this study did not involve animal subjects or tissue. **Conflicts of interest:** In compliance with the ICMJE uniform disclosure form, all authors declare the following: **Payment/services info:** All authors have declared that no financial support was received from any organization for the submitted work. **Financial relationships:** All authors have declared that they have no financial relationships at present or within the previous three years with any organizations that might have an interest in the submitted work. **Other relationships:** All authors have declared that there are no other relationships or activities that could appear to have influenced the submitted work.

## References

1. Tekin F, Sirmeli M, Şimşek H, Ceran C, Tezcan S, Taner ÖF, Şimşek G: Comparison of the histopathological findings of patients with diabetic and idiopathic carpal tunnel syndrome. *Int Orthop*. 2015, 39:2395-401. [10.1007/s00264-015-2790-y](https://doi.org/10.1007/s00264-015-2790-y)
2. de Krom MC, de Krom CJ, Spaans F: [Carpal tunnel syndrome: diagnosis, treatment, prevention and its relevance to dentistry]. *Ned Tijdschr Tandheelkd*. 2009, 116:97-101.
3. Daliri B O M, Azhari A, Khaki S, Hajebi Khaniki S, Moradi A: Which psychological and electrodiagnostic factors are associated with limb disability in patients with carpal tunnel syndrome? *Clin Orthop Relat Res*. 2022, 480:960-8. [10.1097/CORR.0000000000002057](https://doi.org/10.1097/CORR.0000000000002057)
4. Thomsen NO, Rosén I, Dahlin LB: Neurophysiologic recovery after carpal tunnel release in diabetic patients. *Clin Neurophysiol*. 2010, 121:1569-73. [10.1016/j.clinph.2010.03.014](https://doi.org/10.1016/j.clinph.2010.03.014)
5. Jiménez Del Barrio S, Bueno Gracia E, Hidalgo García C, Estébanez de Miguel E, Tricás Moreno JM, Rodríguez Marco S, Ceballos Laita L: Conservative treatment in patients with mild to moderate carpal tunnel syndrome: a systematic review. *Neurologia (Engl Ed)*. 2018, 33:590-601. [10.1016/j.nrl.2016.05.018](https://doi.org/10.1016/j.nrl.2016.05.018)
6. Wiperman J, Goerl K: Carpal tunnel syndrome: diagnosis and management. *Am Fam Physician*. 2016, 94:993-9.
7. Kluge W, Simpson RG, Nicol AC: Late complications after open carpal tunnel decompression. *J Hand Surg Br*. 1996, 21:205-7. [10.1016/s0266-7681\(96\)80098-2](https://doi.org/10.1016/s0266-7681(96)80098-2)
8. Bolster M, Schipper C, Van Sterkenburg S, Ruettermann M, Reijnen M: Single interrupted sutures compared with Donati sutures after open carpal tunnel release: a prospective randomised trial. *J Plast Surg Hand Surg*. 2013, 47:289-91. [10.3109/2000656X.2012.762006](https://doi.org/10.3109/2000656X.2012.762006)
9. Suwannaphisit S, Aonsong W, Suwann P, Yuenyongviwat V: Comparing the running subcuticular technique versus the Donati technique in open carpal tunnel release: a randomized controlled trial. *J Orthop Surg Res*. 2021, 16:565. [10.1186/s13018-021-02710-0](https://doi.org/10.1186/s13018-021-02710-0)
10. Ahcan U, Arnez ZM, Bajrović F, Zorman P: Surgical technique to reduce scar discomfort after carpal tunnel surgery. *J Hand Surg Am*. 2002, 27:821-7. [10.1053/jhsu.2002.35083](https://doi.org/10.1053/jhsu.2002.35083)
11. Wade RG, Wormald JC, Figus A: Absorbable versus non-absorbable sutures for skin closure after carpal tunnel decompression surgery. *Cochrane Database Syst Rev*. 2018, 2:CD011757. [10.1002/14651858.CD011757.pub2](https://doi.org/10.1002/14651858.CD011757.pub2)
12. Coulthard P, Esposito M, Worthington HV, van der Elst M, van Waas OJ, Darcey J: Tissue adhesives for closure of surgical incisions. *Cochrane Database Syst Rev*. 2010, CD004287. [10.1002/14651858.CD004287.pub3](https://doi.org/10.1002/14651858.CD004287.pub3)
13. Dumville JC, Coulthard P, Worthington HV, et al.: Tissue adhesives for closure of surgical incisions. *Cochrane Database Syst Rev*. 2014, 2014:CD004287. [10.1002/14651858.CD004287.pub4](https://doi.org/10.1002/14651858.CD004287.pub4)
14. McQuillan TJ, Vora M, Hawkins J, Kenney D, Diaz R, Ladd AL: Adhesive taping shows better cosmetic outcomes than tissue adhesives for sutured upper extremity incisions: a single-blind prospective randomized controlled trial. *Orthopedics*. 2022, 45:e42-6. [10.5928/01477447-20211101-08](https://doi.org/10.5928/01477447-20211101-08)
15. Sunjic Roguljic V, Roguljic L, Kovacic V, Jukic I: A comparison of tissue adhesive material and suture as wound-closure techniques following carpal tunnel decompression: a single-center randomized control trial.



- J Clin Med. 2023, 12:2864. [10.3390/jcm12082864](https://doi.org/10.3390/jcm12082864)
16. Fernandes CH, Meirelles LM, Santos JB, Fernandes M, Nakachima LR, Faloppa F: An intraindividual comparison of open versus Paine retinaculotomy release for bilateral carpal tunnel syndrome. *Rev Bras Ortop (Sao Paulo)*. 2023, 58:295-302. [10.1055/s-0042-1744497](https://doi.org/10.1055/s-0042-1744497)
  17. Steinberg DR: Surgical release of the carpal tunnel. *Hand Clin*. 2002, 18:291-8. [10.1016/s0749-0712\(01\)00011-7](https://doi.org/10.1016/s0749-0712(01)00011-7)
  18. Kakaei F, Seyyed Sadeghi MS, Sanei B, Hashemzadeh S, Habibzadeh A: A randomized clinical trial comparing the effect of different haemostatic agents for haemostasis of the liver after hepatic resection. *HPB Surg*. 2013, 2013:587608. [10.1155/2013/587608](https://doi.org/10.1155/2013/587608)
  19. Fernandes CH, Meirelles LM, Raduan Neto J, Nakachima LR, Dos Santos JB, Faloppa F: Carpal tunnel syndrome with thenar atrophy: evaluation of the pinch and grip strength in patients undergoing surgical treatment. *Hand (N Y)*. 2013, 8:60-3. [10.1007/s11552-012-9471-8](https://doi.org/10.1007/s11552-012-9471-8)
  20. Faour-Martin O, Martin-Ferrero MA, Almaraz-Gómez A, Vega-Castrillo A: The long-term post-operative electromyographic evaluation of patients who have undergone carpal tunnel decompression. *J Bone Joint Surg Br*. 2012, 94:941-5. [10.1302/0301-620X.94B7.28605](https://doi.org/10.1302/0301-620X.94B7.28605)
  21. Bland JD: A neurophysiological grading scale for carpal tunnel syndrome. *Muscle Nerve*. 2000, 23:1280-5. [10.1002/1097-4598\(200008\)23:8<1280::aid-mus20>3.0.co;2-y](https://doi.org/10.1002/1097-4598(200008)23:8<1280::aid-mus20>3.0.co;2-y)
  22. Levine DW, Simmons BP, Koris MJ, Daltroy LH, Hohl GG, Fossel AH, Katz JN: A self-administered questionnaire for the assessment of severity of symptoms and functional status in carpal tunnel syndrome. *J Bone Joint Surg Am*. 1993, 75:1585-92. [10.2106/00004623-199311000-00002](https://doi.org/10.2106/00004623-199311000-00002)
  23. Bulut T, Sener U, Yağdı S, Kazımoglu C, Sener M: Relationship between clinical and electrophysiological results in surgically treated carpal tunnel syndrome. *Eklemler Hastalıkları Cerrahisi*. 2011, 22:140-4.
  24. Yilmaz N, Akdemir G, Gezici AR, et al.: Electrophysiological and clinical assessment of response to surgery in carpal tunnel. *Int J Neurosci*. 2010, 120:261-4. [10.3109/00207451003615748](https://doi.org/10.3109/00207451003615748)
  25. El-Hajj T, Tohme R, Sawaya R: Changes in electrophysiological parameters after surgery for the carpal tunnel syndrome. *J Clin Neurophysiol*. 2010, 27:224-6. [10.1097/WNP.0b013e3181dd4ff0](https://doi.org/10.1097/WNP.0b013e3181dd4ff0)
  26. Deng X, Chau LP, Chiu SY, Leung KP, Hu Y, Ip WY: Screening of axonal degeneration in carpal tunnel syndrome using ultrasonography and nerve conduction studies. *J Vis Exp*. 2019, 11:e58681. [10.3791/58681](https://doi.org/10.3791/58681)
  27. Andreu JL, Ly-Pen D, Millán I, de Blas G, Sánchez-Olaso A: Local injection versus surgery in carpal tunnel syndrome: neurophysiologic outcomes of a randomized clinical trial. *Clin Neurophysiol*. 2014, 125:1479-84. [10.1016/j.clinph.2013.11.010](https://doi.org/10.1016/j.clinph.2013.11.010)
  28. Pourmohktari M, Mazrooyi M, Vosoughi AR: Conservative or surgical treatment of carpal tunnel syndrome based on the severity and patient risk factors. *Musculoskeletal Surg*. 2021, 105:315-9. [10.1007/s12306-020-00663-x](https://doi.org/10.1007/s12306-020-00663-x)
  29. Chammas M: Carpal tunnel syndrome. *Chir Main*. 2014, 33:75-94. [10.1016/j.main.2015.11.010](https://doi.org/10.1016/j.main.2015.11.010)
  30. Tian Y, Zhao H, Wang T: Prospective comparison of endoscopic and open surgical methods for carpal tunnel syndrome. *Chin Med Sci J*. 2007, 22:104-7.
  31. Yasak T, Özkaya Ö, Ergun Şahin A, Çolak Ö: Electromyographic and clinical investigation of the effect of platelet-rich plasma on peripheral nerve regeneration in patients with diabetes after surgery for carpal tunnel syndrome. *Arch Plast Surg*. 2022, 49:200-6. [10.1055/s-0042-1744410](https://doi.org/10.1055/s-0042-1744410)
  32. Durban CM, Antolin B, Sau CY, Li SW, Ip WY: Thumb function and electromyography result after modified Camitz tendon transfer. *J Hand Surg Asian Pac Vol*. 2017, 22:275-80. [10.1142/S0218810417500290](https://doi.org/10.1142/S0218810417500290)
  33. Calotta NA, Lopez J, Deune EG: Improved surgical outcomes with endoscopic carpal tunnel release in patients with severe median neuropathy. *Hand (N Y)*. 2017, 12:252-7. [10.1177/1558944716661995](https://doi.org/10.1177/1558944716661995)
  34. Gümüştaş SA, Ekmekçi B, Tosun HB, Orak MM, Bekler HI: Similar effectiveness of the open versus endoscopic technique for carpal tunnel syndrome: a prospective randomized trial. *Eur J Orthop Surg Traumatol*. 2015, 25:1253-60. [10.1007/s00590-015-1696-0](https://doi.org/10.1007/s00590-015-1696-0)
  35. Faour-Martin O, Martin-Ferrero MÁ, Vega Castrillo A, Almaraz-Gómez A, Valverde-García JA, Amigo Liñares L, Red-Gallego MÁ: Long-term effects of preserving or splitting the carpal ligament in carpal tunnel operation. *J Plast Surg Hand Surg*. 2013, 47:263-7. [10.3109/2000656X.2012.755928](https://doi.org/10.3109/2000656X.2012.755928)
  36. Crnković T, Bilić R, Trkulja V, Cesarik M, Gotovac N, Kolundžić R: The effect of epineurotomy on the median nerve volume after the carpal tunnel release: a prospective randomised double-blind controlled trial. *Int Orthop*. 2012, 36:1885-92. [10.1007/s00264-012-1565-y](https://doi.org/10.1007/s00264-012-1565-y)
  37. Boumediene M, Meyer N, Facca S, Pizzi C, Liverneaux P: Revision surgery for carpal tunnel syndrome: a retrospective study comparing the combination of Canaletto® and Dynavisc® gel versus Dynavisc® gel alone. *Hand Surg Rehabil*. 2021, 40:57-63. [10.1016/j.hansur.2020.10.005](https://doi.org/10.1016/j.hansur.2020.10.005)
  38. Bilge A, Ulusoy RG, Öztürk O, Öztürk IA, Aykut S: Carpal tunnel syndrome surgery anti-adhesion gel is effective?. *Acta Chir Orthop Traumatol Cech*. 2017, 84:591-5.
  39. Rushbrook JL, White G, Kidger L, Marsh P, Taggart TF: The antibacterial effect of 2-octyl cyanoacrylate (Dermabond®) skin adhesive. *J Infect Prev*. 2014, 15:236-9. [10.1177/1757177414551562](https://doi.org/10.1177/1757177414551562)
  40. Lee CS, Han SR, Kye BH, et al.: Surgical skin adhesive bond is safe and feasible wound closure method to reduce surgical site infection following minimally invasive colorectal cancer surgery. *Ann Surg Treat Res*. 2020, 99:146-52. [10.4174/ast.2020.99.3.146](https://doi.org/10.4174/ast.2020.99.3.146)
  41. Sinha S, Naik M, Wright V, Timmons J, Campbell AC: A single blind, prospective, randomized trial comparing n-butyl 2-cyanoacrylate tissue adhesive (Indermil) and sutures for skin closure in hand surgery. *J Hand Surg Br*. 2001, 26:264-5. [10.1054/jhsb.2000.0572](https://doi.org/10.1054/jhsb.2000.0572)



## Article

# The Influence of Wound Closure Techniques after Surgical Decompression in Patients with Carpal Tunnel Syndrome on Sleep Disturbance and Life Quality: A Prospective Comparison of Surgical Techniques

Veridijana Sunjic Roguljic <sup>1</sup>, Luka Roguljic <sup>2</sup>, Ivana Jukic <sup>3,4</sup> and Vedran Kovacic <sup>5,6,\*</sup>

- <sup>1</sup> Plastic, Reconstructive and Aesthetic Surgery with Burn Care Division, Surgery Department, University Hospital of Split, 21000 Split, Croatia; lroguljic@kbsplit.hr
  - <sup>2</sup> Orthopaedics and Traumatology Division, Surgery Department, University Hospital of Split, 21000 Split, Croatia
  - <sup>3</sup> Gastroenterology Division, Internal Medicine Department, University Hospital of Split, 21000 Split, Croatia
  - <sup>4</sup> University Department of Health Studies, University of Split, 21000 Split, Croatia
  - <sup>5</sup> Division of Emergency and Intensive Medicine with Clinical Pharmacology and Toxicology, Internal Medicine Department, University Hospital of Split, 21000 Split, Croatia
  - <sup>6</sup> School of Medicine, University of Split, 21000 Split, Croatia
- \* Correspondence: vkovacic@mefst.hr; Tel.: +385-21557456



**Citation:** Sunjic Roguljic, V.; Roguljic, L.; Jukic, I.; Kovacic, V. The Influence of Wound Closure Techniques after Surgical Decompression in Patients with Carpal Tunnel Syndrome on Sleep Disturbance and Life Quality: A Prospective Comparison of Surgical Techniques. *Clin. Pract.* **2024**, *14*, 546–555. <https://doi.org/10.3390/clinpract14020042>


Academic Editor: Roberto Cuomo

Received: 16 January 2024

Revised: 16 March 2024

Accepted: 19 March 2024

Published: 26 March 2024



**Copyright:** © 2024 by the authors. Licensee MDPI, Basel, Switzerland. This article is an open access article distributed under the terms and conditions of the Creative Commons Attribution (CC BY) license (<https://creativecommons.org/licenses/by/4.0/>).

**Abstract** Background: The compression of the median nerve within the carpal tunnel is the cause of carpal tunnel syndrome (CTS). Surgical decompression is successful in improving sleep and quality of life, but the effect of tissue adhesives as a material for wound closure has not been investigated. The objective of the study was to evaluate sleep disorders and health-related life quality by comparing two methods for wound closure after carpal surgery in participants who were randomized to receive tissue adhesives or transcutaneous sutures. Methods: The subjects, aged  $61.56 \pm 12.03$  years, were randomized to receive either tissue adhesives ( $n = 50$ ) or suture-based wound closure ( $n = 50$ ) using the Glubran Tiss 2<sup>®</sup> skin adhesive after subcutaneous running sutures. The outcomes were assessed during the 12-month postoperative follow-up. The Pittsburgh Sleep Quality Index (PQSI) and Insomnia Severity Scale (ISI) were used for the sleep disturbance assessment, and for the health-related quality of life assessment, the total SF-36 (36-Item Short Form Survey) was used. Results: The PQSI, ISI, and SF-36 were not statistically different between groups during the follow-up, except in the ISI score two weeks after surgery ( $9.40 \pm 1.18$  in the tissue adhesive group vs.  $9.96 \pm 1.09$  in the suture-based group,  $p = 0.008$ ). The PQSI, ISI, and SF-36 scores for all the subjects and groups were persistently improved at all the follow-up intervals after surgery. The total SF-36 score increased 12 months after surgery ( $49.84 \pm 5.85$  vs.  $82.46 \pm 5.68$ ,  $p < 0.001$ ). Conclusions: Cyanoacrylate-based adhesion material can be used for wound closure after open CTS decompression as a standard transcutaneous suture, and both techniques equally lead to improved sleep and life quality. The possible advantages of tissue adhesives include a faster reduction in the ISI.

**Keywords:** insomnia; sleep disturbance; life quality; carpal tunnel; skin adhesive; skin suture; cyanoacrylate

## 1. Introduction

The most prevalent entrapment neuropathy affecting the upper limb is carpal tunnel syndrome (CTS), which frequently requires carpal tunnel release (CTR) for decompression in cases where conservative treatment is ineffective [1]. In the distribution of the median nerve, patients with CTS frequently suffer with pain, tingling, and numbness. These symptoms frequently interfere with sleep, which can have a significant negative impact on a patient's quality of life [2].

It has been proven that surgical decompression of the carpal tunnel is successful in improving the sleep and quality of life of patients with CTS [3]. Even non-surgical methods such as steroid injection treatment or medicaments have a significant effect on sleep improvement in patients with CTS [4,5]. It is of the utmost importance for the patient to achieve relief of night paresthesia and improved quality of sleep by treating CTS, which then has an impact on their quality of life and ability to work [6].

Differences in the approach to CTS treatment and the advantages of one procedure over another have been analyzed in various clinical studies, while different clinical parameters have been used as the outcome measures, most often patient-reported questionnaires, physical examination of scars, medial nerve conduction testing, or the number of surgical complications [7].

Despite plenty of surgical procedures and adjustments that have been proposed to improve the neurological, functional, and aesthetic outcomes of CTS decompression [8], to date, there has been no comparison analysis of different surgical methods aimed at enhancing sleep and life quality in CTS patients.

Tissue adhesives, including 2-octylcyanoacrylate, have been recently used in clinical settings to seal wounds following surgery since they have a high tensile strength and bacteriostatic properties [9]. Despite several proposed wound closure procedures, there is a remarkable paucity of data on the potential relevance of tissue adhesives to open carpal tunnel decompression surgery. In the small number of studies comparing tissue adhesives and sutures for wound closure after carpal surgery, the observed outcomes were mostly aesthetic [10]. The effect of using tissue adhesives as the material for wound closure during CTS decompression on sleep disturbances and health-related life quality has not been studied.

The objective of the current study was to evaluate sleep disorders and health-related life quality by comparing two methods for wound closure after carpal surgery in participants who were randomized to receive tissue adhesives or transcutaneous sutures as the wound closure material. Therefore, this study is the first to aim to find the impact of different wound closure techniques after carpal tunnel decompression on sleep disorders (measured using the Insomnia Severity Scale and the Pittsburgh Sleep Quality Index) and health-related life quality (measured using the Short-Form Health Survey). We hypothesized that various wound closure techniques have a significantly different impact on life and sleep quality assessments.

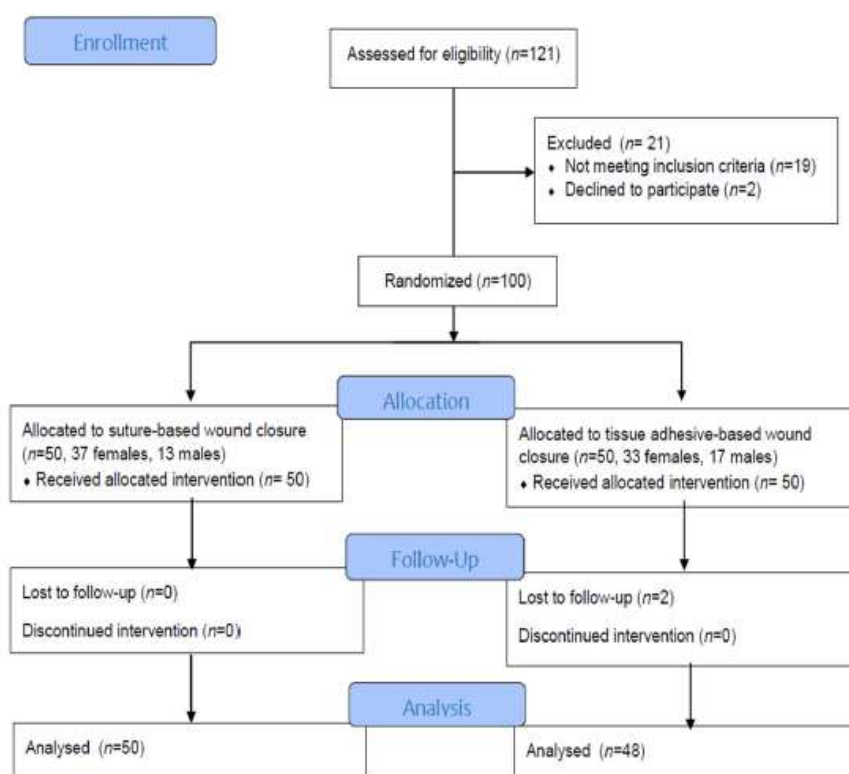
## 2. Materials and Methods

A randomized prospective follow-up single-center trial was carried out at the Surgery Department of the University Hospital of Split. The Ethics Committee at the hospital approved the study with an ethics code of 500-03/22-01/41 and a date of approval of 31 March 2022. The Helsinki Declaration's guiding principles were followed in the conduct of the study, as were the Consolidated Standards of Reporting Trials (CONSORT) guidelines. Informed consent was obtained from all the subjects involved in the study. This study was part of a clinical project registered with [www.clinicaltrials.gov](http://www.clinicaltrials.gov) (accessed on 12 April 2023) (NCT05808855). The participants in the study included adult patients (>18 years) with carpal tunnel syndrome who had failed conservative therapy for more than 6 months and had serious limitations, such as severe median nerve conduction impairment as determined using electromyography, thenar atrophy, or thumb abduction weakness. Median nerve conduction studies were performed in all the subjects to assess the conduction of the median nerve through the carpal tunnel (speed, latency, and amplitude of motor and sensory conduction). All the included subjects had at least one of the following motoric or sensory median nerve impairments: a sensory conduction velocity > 45 m/s, a peak distal sensory latency < 3.5 ms, a sensory nerve action potential amplitude > 10 mV, a distal motor latency < 4.2 ms, a distal motor amplitude > 5 mV, and a motor conduction velocity > 50 m/s. The exclusion criteria included a history of severe general illness with cachexia, a family history of keloids or hypertrophic scars, a history of previous wrist trauma or surgery,

another etiology of neuropathy, and threatening hemorrhagic complications (patients with peroral anticoagulation and/or antithrombotic therapy).

The sample size was calculated taking into account the expected variability in the main outcome measure (SF-36) from previous studies with an alpha error of 0.05 to detect a significant difference and an 80% test power (beta error of 0.2). For this power of the study, the minimum number of subjects was estimated to be 37 in each group.

After applying the inclusion criteria, 100 patients were included in the trial. During the 12-month postoperative follow-up period, two subjects dropped out. A total of 98 subjects were included (Figure 1). Subjects were randomized to receive either tissue-adhesive-based or suture-based wound closure. A computer created the randomization, which consisted of numbers at a 1:1 ratio between the two interventions.



**Figure 1.** Study flow diagram (CONSORT).

A total of 6 licensed plastic surgeons in the Plastic, Reconstructive and Aesthetic Surgery with Burn Care Division of the Surgery Department of the University Hospital of Split, Croatia, participated in the surgical procedures. All the surgical procedures were performed as standard open carpal canal decompression surgery [11]. After preparation of the operating field with a tourniquet and local infiltration of 2% lidocaine into the soft tissue of the palm and carpal tunnel, a 15–18 mm long skin incision was made following the radial half of the palm, not over the joint flexor. To open the skin and transect the carpal ligament in the proximal direction, scalpel no. 15 was used, and Metzenbaum scissors were used to cut the carpal ligament in the distal direction. Depending on the subject's randomization group, two different techniques were used for the primary wound closure:

(1) Transcutaneous nylon sutures (non-absorbable polypropylene/polyethylene monofilament, 3/8 needle, thread size 4/0) were used to stitch the skin (Optilene®, B. Braun Surgical, S.A., Barcelona, Spain)

(2) After a subcutaneous buried running continuous stitch (thread size 4-0 coated Vicryl™ Plus PS-2, 3/8, Ethicon Inc., Bridgewater, MA, USA), a synthetic two-component surgical glue, Glubran Tiss 2® (GEM S.r.l., Viareggio, Italy), was applied. For the wound closure, 0.35 mL of Glubran Tiss 2® was used and rested for 20 s in the open wound to allow the polymerization process to begin before bandaging. Glubran Tiss 2® is a synthetic bio-inert surgical glue composed of n-butyl 2-cyanoacrylate (NBCA) and 2-octyl cyanoacrylate (OCA) with hemostatic, bacteriostatic, and sealing properties. When applied to wet tissue, Glubran Tiss 2® rapidly polymerizes into a thin, elastic film with a remarkable tensile strength, clinging tightly to the structure of the tissue [12].

All the subjects had the same postoperative care. The postoperative care consisted of the application of a compression bandage for one day and the administration of analgesics. Some subjects needed drainage with a narrow plastic tube on the first two postoperative days. Regular visits by surgeons and nurses with wound dressings were performed on a daily basis. We did not use a splint to immobilize the limb after surgery, but all subjects had to rest strictly to prevent wound dehiscence.

For each subject included in the study, their gender, weight, height, and previous illnesses were recorded before surgery. Subjects were evaluated 2 weeks after surgery for a standard follow-up examination that included wound inspection and suture removal. The next evaluation was performed 6 weeks after surgery, the third evaluation was performed 24 weeks after surgery, and the final evaluation was performed 12 months after surgery.

At the beginning of the study, sleep quality and health-related quality of life were assessed on self-reported scales. For the sleep quality assessment, two validated scales were used: the Pittsburgh Sleep Quality Index (PQSI) and the Insomnia Severity Scale (ISI).

The PSQI is a self-reported questionnaire that assesses the overall sleep quality across 19 items belonging to one of seven different subcategories: subjective sleep quality, sleep latency, sleep duration, habitual sleep efficiency, sleep disturbances, use of sleeping medication, and daytime dysfunction. The scale provides an overall score ranging from 0 to 21, with lower scores indicating a better sleep quality [13].

The ISI was developed to detect and quantify patients' perception of the severity of insomnia, as well as to assess its impact on daytime functioning and track the treatment response [14]. The ISI self-reported questionnaire consists of seven questions that are added together to yield a total score: 0–7 = no clinically significant insomnia; 8–14 = subthreshold insomnia; 15–21 = clinical insomnia (moderate severity); 22–28 = clinical insomnia (severe).

The PQSI and ISI were evaluated at the beginning of the study (immediately before surgery) and during follow-up visits at 2, 6, and 24 weeks.

The TSF-36 (36-Item Short-Form Survey) is a self-reported measure of health-related quality of life. The SF-36 Health Survey was developed at RAND Health Care as part of the Medical Outcomes Study [15]. It comprises 36 questions that consider eight different dimensions of health (physical and mental components): limitations in physical activities due to health problems, limitations in social activities due to physical or emotional problems, limitations in usual role activities due to physical health problems, bodily pain, general mental health, limitations in usual activities due to emotional distress, vitality, and general health perceptions. The scores are converted into a scale with a minimum of 0 (the worst condition) and a maximum of 100 (the best condition).

The total SF-36 score was calculated at the beginning of the study (immediately before surgery) and at the last follow-up visit at 12 months.

The distributions of the quantitative variables were checked for normality using the Kolmogorov–Smirnov test. Fisher's exact chi-square test was used to compare the qualitative data between groups. A paired and an unpaired Student's t-test were used to compare the quantitative data. The statistical analysis was carried out using the Windows version of the SPSS program (IBM SPSS Statistics for Windows, version 26.0, Armonk, NY, USA). *p*-values less than 0.05 were regarded significant.

### 3. Results

The study population comprised 100 patients (30 males and 70 females) who were randomized 1:1 to receive either glue-based wound closure ( $n = 50$ ) or suture-based wound closure ( $n = 50$ ). Two participants dropped out after postoperative follow-up. A total of 98 subjects were evaluated. The age of the study population cohort was  $61.56 \pm 12.03$  years. Right-side surgery was performed on 57 subjects, while left-side surgery was performed on 43 subjects.

The initial parameters and output measures before surgery are demonstrated in Table 1. There were no statistical differences between the groups.

**Table 1.** The initial preoperative differences in characteristics and outcome measures between two groups of participants (glue-based wound closure and suture-based wound closure), mean  $\pm$  standard deviation or number of participants and percent, Student's *t*-test for independent samples, and Fisher's exact chi-square test, one-tailed.

|                                      | Glue-Based Technique | Suture-Based      | <i>p</i> |
|--------------------------------------|----------------------|-------------------|----------|
|                                      | <i>N</i> = 48        | <i>N</i> = 50     |          |
| Age (years)                          | 63.02 $\pm$ 12.97    | 60.10 $\pm$ 10.95 | 0.113    |
| Body mass index (kg/m <sup>2</sup> ) | 24.79 $\pm$ 3.17     | 25.04 $\pm$ 2.25  | 0.325    |
| Female sex ( <i>n</i> , %)           | 33 (68.75%)          | 37 (74.00%)       | 0.257    |
| ISI, initial                         | 16.77 $\pm$ 3.05     | 17.52 $\pm$ 3.08  | 0.115    |
| PSQI, initial                        | 12.15 $\pm$ 1.61     | 12.52 $\pm$ 1.67  | 0.131    |
| SF-36, initial                       | 49.96 $\pm$ 5.96     | 49.86 $\pm$ 5.83  | 0.467    |

Legend: ISI: Insomnia Severity Scale, PQSI: Pittsburgh Sleep Quality Index, SF-36: Short-Form Health Survey.

The differences between the two groups in the outcome measures during follow-up are demonstrated in Table 2. We demonstrated a statistically significant reduction in the ISI score (Insomnia Severity Scale) two weeks after surgery in patients whose surgical wounds were closed with tissue adhesives. Some of the other output measures of sleep- and health-related quality of life tended to be better in the group where the surgical wound was closed with glue, but statistical significance was not reached.

**Table 2.** The differences in postoperative outcome measures between two groups of participants (glue-based wound closure and suture-based wound closure), mean  $\pm$  standard deviation, Student's *t*-test for independent samples, one-tailed.

|                  | Glue-Based Technique | Suture-Based     | <i>p</i> |
|------------------|----------------------|------------------|----------|
|                  | <i>N</i> = 48        | <i>N</i> = 50    |          |
| ISI, 2 weeks     | 9.40 $\pm$ 1.18      | 9.96 $\pm$ 1.09  | 0.008 *  |
| ISI, 6 weeks     | 6.65 $\pm$ 1.25      | 6.64 $\pm$ 1.10  | 0.490    |
| ISI, 24 weeks    | 4.38 $\pm$ 1.16      | 4.24 $\pm$ 0.96  | 0.265    |
| PSQI, 2 weeks    | 8.08 $\pm$ 1.77      | 8.62 $\pm$ 1.59  | 0.059    |
| PSQI, 6 weeks    | 5.08 $\pm$ 1.01      | 5.26 $\pm$ 1.29  | 0.227    |
| PSQI, 24 weeks   | 3.88 $\pm$ 1.04      | 3.90 $\pm$ 0.93  | 0.450    |
| SF-36, 12 months | 83.35 $\pm$ 4.81     | 81.59 $\pm$ 6.36 | 0.064    |

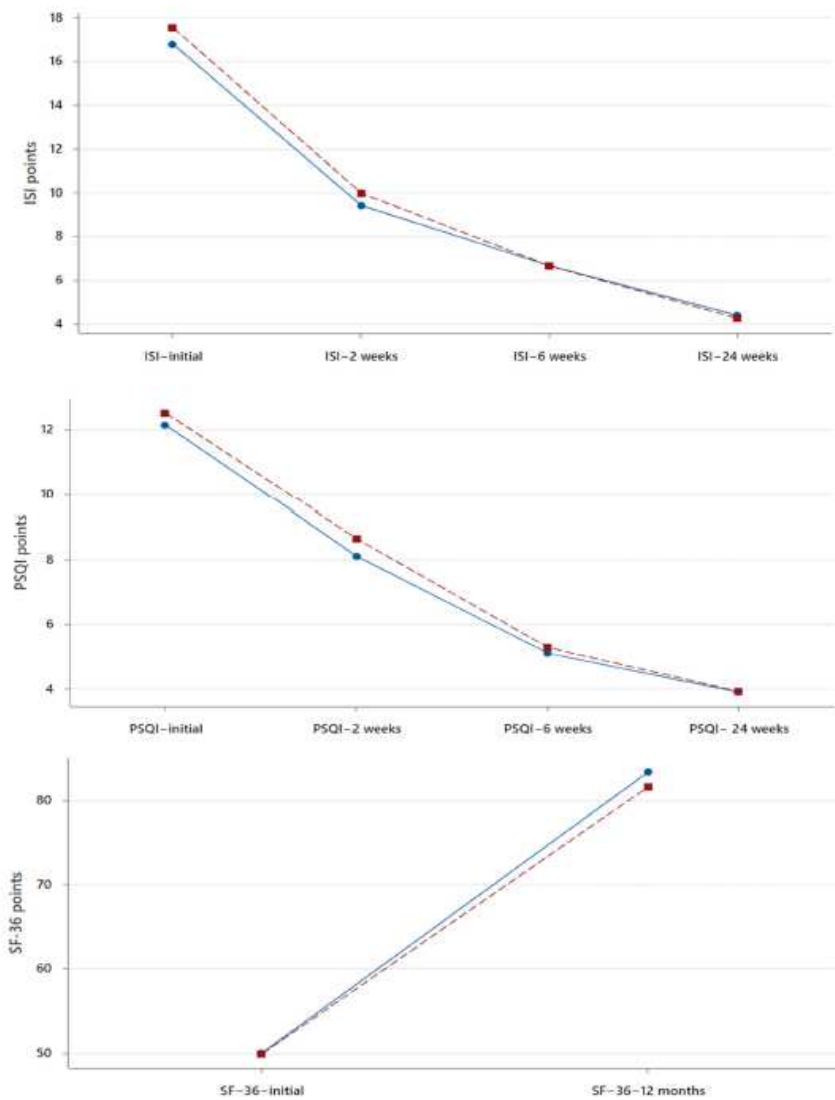
Legend: ISI: Insomnia Severity Scale, PQSI: Pittsburgh Sleep Quality Index, SF-36: Short-Form Health Survey, \*  $p < 0.05$ .

And finally, we demonstrated a significant improvement in the sleep- and health-related quality of life between all the follow-up intervals as a consequence of the continuous recovery of quality of life after surgery. This effect was proven for all subjects (Table 3) and for each group of subjects separately (Figure 2).

**Table 3.** The follow-up interval differences in outcome measures for all participants (N = 98), Student’s t-test for paired samples, one-tailed.

|                                     | Mean ± Std. Deviation | Mean ± Std. Deviation | p        |
|-------------------------------------|-----------------------|-----------------------|----------|
| ISI, initial vs. ISI, 2 weeks       | 17.15 ± 3.07          | 9.68 ± 1.16           | <0.001 * |
| ISI, 2 weeks vs. ISI, 6 weeks       | 9.68 ± 1.16           | 6.64 ± 1.17           | <0.001 * |
| ISI, 6 weeks vs. ISI, 24 weeks      | 6.64 ± 1.17           | 4.31 ± 1.06           | <0.001 * |
| PSQI, initial vs. PSQI, 2 weeks     | 12.34 ± 1.64          | 8.36 ± 1.69           | <0.001 * |
| PSQI, 2 weeks vs. PSQI, 6 weeks     | 8.36 ± 1.69           | 5.17 ± 1.16           | <0.001 * |
| PSQI, 2 weeks vs. PSQI, 24 weeks    | 5.17 ± 1.16           | 3.89 ± 0.98           | <0.001 * |
| SF-36, initial vs. SF-36, 12 months | 49.84 ± 5.85          | 82.46 ± 5.68          | <0.001 * |

Legend: ISI: Insomnia Severity Scale, PQSI: Pittsburgh Sleep Quality Index, SF-36: Short-Form Health Survey, \* p < 0.05.



**Figure 2.** Plots of interval changes in mean values of Insomnia Severity Scale (ISI), Pittsburgh Sleep Quality Index (PSQI), and Short-Form Health Survey (SF-36) over the study duration. The Blue line indicates glue based, and the Red line indicates suture based.

#### 4. Discussion

The results of this study demonstrated for the first time the impact of using tissue adhesive to close postoperative wounds after the decompression of the carpal tunnel on sleep disorders and quality of life indicators. The study compared standard transcutaneous sutures with 2-octylcyanoacrylate-based tissue adhesive and showed that both techniques of wound closure after carpal tunnel surgery have an equally significant effect on the improvement of sleep disturbances and quality of life. This beneficial effect was significant and long-lasting, with a tendency for constant improvement during follow-up.

A limited number of studies have been conducted to compare different treatment techniques for CTS and their impact on sleep quality and sleep-related quality of life. Although it has been proven that quality of sleep and quality of life improve significantly after surgical decompression of the carpal tunnel [16], there are only a small number of studies conducted as comparative trials between surgical decompression and other treatment methods regarding sleep disturbance and its impacts on life quality. For example, one analysis compared open and endoscopic carpal tunnel release for treating secondary sleep symptoms due to CTS, and it was shown that the endoscopic method leads to a faster resolution of sleep problems compared to the open technique [17].

Improving the quality of sleep is a very important outcome of the treatment of patients with CTS since a patient's quality of life is greatly impacted by sleep disturbances. About 80% of CTS patients demonstrated clinically significant sleep disturbances (a PSQI score > 5) [18]. The beneficial effect of surgical decompression of the carpal tunnel on sleep disorders has been proven in several studies, and this effect is considered a very important outcome of the surgical treatment of patients with CTS, as sleep improvements have an impact on patient satisfaction and quality of life. Similar to our results, Niedermeier et al. [19] reported an improvement in sleep disorders measured using the Pittsburgh Sleep Quality Index, from a mean of 10.4 points preoperatively to 7.8 points two weeks after surgery and 6.4 points six weeks after surgery. Sleep improvement typically occurs very quickly after surgery. Tulipan et al. [20], in a prospective study, showed an enhancement in the quality of sleep measured as an ISI score within 7 days after CTS open decompression. The authors reported that the ISI score did not further significantly improve in the follow-up period between 2 weeks and 3 months. On the contrary, in our study, we demonstrated a progressive and significant improvement in sleep quality during all 24 weeks of the monitoring period in both groups of subjects. Nevertheless, the favorable effects of carpal tunnel surgery on sleep parameters are long-lasting; for example, Okkesim et al. [21] showed that in the third to sixth month after operative median nerve decompression, individuals with carpal tunnel syndrome had better sleep metrics and a better quality of sleep. Our results are consistent with previous reports, and we demonstrated that an improvement in sleep has a long-term effect with a significant and progressive improvement during the follow-up period. The same effect was achieved in the application of both surgical techniques, with a significantly different improvement in the ISI score 2 weeks postoperatively in subjects with tissue-adhesive-based wound closure compared with the suture-based wound closure group. This may indicate that the sleep improvement effect was achieved faster in the tissue adhesive group. It should be noted that the two surgical approaches used to close the surgical wound—one using transcutaneous sutures and the other using glue plus a subcutaneous running continuous stitch—caused these notable postoperative differences in earlier sleep improvements. The observed notable variations in the outcome measures after surgery can be ascribed not only to the use of tissue glue but also to the distinction between subcutaneous and transcutaneous sutures. In particular, transcutaneous suturing covers a greater surface area of the sutured tissue (skin and subcutaneous tissue). In contrast, the tension of the wound is evenly distributed with less pressure from the sutures on the skin where the nociceptors are located when a subcutaneous suture using tissue glue is used. As a result, pain and discomfort are minimized, which leads to better sleep.

A rapid improvement in symptoms can be important in patients who have very pronounced sleep disorders. In contrast, some authors showed very late effects on improving



sleep after surgical decompression of the carpal tunnel; for example, Trouw et al. [22] reported a measurable and significant improvement in the PSQI score at the 12- to 24-month follow-up.

One frequently utilized tool in orthopedic studies is the 36-item Short-Form Health Survey (SF-36) because it is a valid instrument for evaluating health-related quality of life [23]. Nevertheless, the SF-36 has been sparingly used in CTS patients, where it was shown that patients with CTS have a lower SF-36 score compared to the general population, with a significant increase in the SF-36 score after operative decompression of the carpal tunnel [24]. Similarly, our research clearly showed a significant improvement in the total SF-36 score from  $49.84 \pm 5.85$  at the beginning to  $82.46 \pm 5.68$  at the end of the study, 12 months after the surgical decompression. A significant improvement in the SF-36 score was recorded in both groups of subjects. Chen et al. [25] reported a study conducted on 49 CTS subjects treated using nasal instruments and the mini-incision approach as a modification of the standard surgical procedure, which demonstrated a significant increment during the mean follow-up of 13 months in all the SF-36 subdivisions: the mean SF-36 scores for social functioning were 60.3 preoperatively vs. 79.8 postoperatively, and the mean SF-36 scores for mental health were 46.5 preoperatively vs. 65.8 postoperatively. Galasso et al. [26] demonstrated in 30 CTS subjects referred for standard surgery a significant improvement in the mean SF-36 total score from 38.7 to 44.3 points six months after surgery.

Although we hypothesized that different surgical wound closure techniques would have an impact on improvements in sleep and quality of life, we did not prove major differences, except for a short-term improvement in the Insomnia Severity Scale two weeks postoperatively in favor of the group of patients whose wound was closed with tissue glue. Furthermore, in the other outcome measures during the postoperative follow-up, there was a tendency towards better outcomes in the group whose surgical wounds were closed with tissue adhesive, but the statistical significance threshold was not met by those differences. The above may indicate, however, some advantages of tissue adhesives in closing post-surgical wounds during open decompression of the carpal tunnel; however, these differences are not significant from a clinical standpoint. The utility of tissue adhesives for wound closure after CTS decompression was insufficiently studied and was limited to aesthetic outcomes [27]. This is the first study to prove the effectiveness and non-inferiority of using a tissue adhesive to close surgical wounds during open carpal tunnel surgery to improve quality of sleep and life.

However, the study presented here has some limitations. First, this trial was restricted to a single center. Second, the follow-up period is insufficient to draw a conclusion about the intervention's long-term effects. Third, additional sleep and life quality parameters have to be monitored to better understand the impact of the intervention.

## 5. Conclusions

The study demonstrated that cyanoacrylate-based adhesion material can be used for wound closure after open CTS decompression to the same extent as standard surgical wound closure with transcutaneous sutures, and both techniques lead to a significantly improved sleep quality and health-related life quality. The possible advantages of tissue adhesive over sutures include a faster reduction in the Insomnia Severity Scale. To clarify the findings of this study, larger multicentric trials with a longer follow-up and additional outcomes are needed.

**Author Contributions:** Conceptualization, V.K.; Software, V.K.; Validation, V.K.; Investigation, V.S.R., I.J. and V.K.; Writing—original draft, V.S.R., L.R. and I.J.; Writing—review & editing, V.S.R., L.R. and I.J. All authors have read and agreed to the published version of the manuscript.

**Funding:** This research received no external funding.

**Institutional Review Board Statement:** The study protocol was approved by the Ethics Committee at the University Hospital of Split with an ethics code of 500-03/22-01/41, date of approval 31 March 2022.

**Informed Consent Statement:** Informed consent was obtained from all the subjects involved in the study.

**Data Availability Statement:** The data presented in this study are available on request from the corresponding author.

**Conflicts of Interest:** The authors declare no conflicts of interest.

## References

1. Fnais, N.; Gomes, T.; Mahoney, J.; Alissa, S.; Mamdani, M. Temporal trend of carpal tunnel release surgery: A population-based time series analysis. *PLoS ONE* **2014**, *9*, e97499. [[CrossRef](#)] [[PubMed](#)]
2. Lehtinen, I.; Kirjavainen, T.; Hurme, M.; Lauerma, H.; Martikainen, K.; Rauhala, E. Sleep-related disorders in carpal tunnel syndrome. *Acta Neurol. Scand.* **1996**, *93*, 360–365. [[CrossRef](#)] [[PubMed](#)]
3. Yalin, M.; Key, S.; Kazez, M.; Agar, A. Carpal tunnel decompression: A comparison of elderly and younger patients' sleep quality. *Acta Orthop. Belg.* **2023**, *89*, 253–256. [[CrossRef](#)] [[PubMed](#)]
4. Aşkın Turan, S.; Aydın, Ş. Karpal tünel sendromu tedavisinde steroid enjeksiyonun uyku hijyeni üzerindeki etkisi [The effect of steroid injection treatment with carpal tunnel syndrome on sleep hygiene]. *Agri/J. Turk. Soc. Algol.* **2021**, *33*, 96–102. (In Turkish) [[CrossRef](#)]
5. Aydın, M.; Argun, G.; Acar, B.; Arıkan, M.; Toğral, G.; Cinaroglu, S.; Mert, A.; Demi Rtas, M. Residual Symptoms After Carpal Tunnel Decompression and Treatment with Gabapentin: A Multicenter Study. *Cureus* **2021**, *13*, e17638. [[CrossRef](#)] [[PubMed](#)]
6. Shifflett, G.D.; Dy, C.J.; Daluiski, A. Carpal tunnel surgery: Patient preferences and predictors for satisfaction. *Patient Prefer. Adherence* **2012**, *6*, 685–689. [[CrossRef](#)] [[PubMed](#)]
7. Mertz, K.; Lindsay, S.E.; Morris, A.; Kamal, R.N. Outcome Metrics in the Treatment of Carpal Tunnel Syndrome: A Systematic Review. *Hand* **2022**, *17*, 659–667. [[CrossRef](#)]
8. Suwannaphisit, S.; Aonsong, W.; Suwanno, P.; Yuenyongviwat, V. Comparing the running subcuticular technique versus the Donati technique in open carpal tunnel release: A randomized controlled trial. *J. Orthop. Surg. Res.* **2021**, *16*, 565. [[CrossRef](#)]
9. Coulthard, P.; Esposito, M.; Worthington, H.V.; van der Elst, M.; van Waes, O.J.; Darcey, J. Tissue adhesives for closure of surgical incisions. *Cochrane Database Syst. Rev.* **2010**, *12*, CD004287. [[CrossRef](#)]
10. McQuillan, T.J.; Vora, M.; Hawkins, J.; Kenney, D.; Diaz, R.; Ladd, A.L. Adhesive Taping Shows Better Cosmetic Outcomes Than Tissue Adhesives for Sutured Upper Extremity Incisions: A Single-Blind Prospective Randomized Controlled Trial. *Orthopedics* **2022**, *45*, e42–e46. [[CrossRef](#)]
11. Steinberg, D.R. Surgical release of the carpal tunnel. *Hand Clin.* **2002**, *18*, 291–298. [[CrossRef](#)]
12. Haghpanah, S.; Vafafar, A.; Golzadeh, M.H.; Ardeshiri, R.; Karimi, M. Use of Glubran 2 and Glubran tissue skin adhesive in patients with hereditary bleeding disorders undergoing circumcision and dental extraction. *Ann. Hematol.* **2011**, *90*, 463–468. [[CrossRef](#)] [[PubMed](#)]
13. Buysse, D.J.; Reynolds, C.F., 3rd; Monk, T.H.; Berman, S.R.; Kupfer, D.J. The Pittsburgh Sleep Quality Index: A new instrument for psychiatric practice and research. *Psychiatry Res.* **1989**, *28*, 193–213. [[CrossRef](#)] [[PubMed](#)]
14. Morin, C.M.; Belleville, G.; Bélanger, L.; Ivers, H. The Insomnia Severity Index: Psychometric indicators to detect insomnia cases and evaluate treatment response. *Sleep* **2011**, *34*, 601–608. [[CrossRef](#)] [[PubMed](#)]
15. Ware, J.E., Jr.; Gandek, B. Overview of the SF-36 Health Survey and the International Quality of Life Assessment (IQOLA) Project. *J. Clin. Epidemiol.* **1998**, *51*, 903–912. [[CrossRef](#)] [[PubMed](#)]
16. Erickson, J.; Polatsch, D.; Beldner, S.; Melamed, E. An Assessment of Sleep Disturbance in Patients before and after Carpal Tunnel Release. *J. Hand Surg. Asian Pac. Vol.* **2019**, *24*, 144–146. [[CrossRef](#)]
17. Gaspar, M.P.; Osterman, M.N.; Shin, E.K.; Osterman, A.L.; Kane, P.M. Sleep disturbance and response to surgical decompression in patients with carpal tunnel syndrome: A prospective randomized pilot comparison of open versus endoscopic release. *Acta Biomed.* **2019**, *90*, 92–96. [[CrossRef](#)]
18. Patel, A.; Culbertson, M.D.; Patel, A.; Hashem, J.; Jacob, J.; Edelstein, D.; Choueka, J. The negative effect of carpal tunnel syndrome on sleep quality. *Sleep Disord.* **2014**, *2014*, 962746. [[CrossRef](#)]
19. Niedermeier, S.R.; Pettit, R.J.; Frantz, T.L.; Colvell, K.; Mawan, H. Early Postoperative Improvement in Sleep and Pain After Carpal Tunnel Release. *Hand* **2020**, *15*, 311–314. [[CrossRef](#)] [[PubMed](#)]
20. Tulipan, J.E.; Kim, N.; Abboudi, J.; Jones, C.; Liss, F.; Kirkpatrick, W.; Matzon, J.; Rivlin, M.; Wang, M.L.; Ilyas, A.M. Prospective Evaluation of Sleep Improvement Following Carpal Tunnel Release Surgery. *J. Hand Surg. Am.* **2017**, *42*, 390.e1–390.e6. [[CrossRef](#)] [[PubMed](#)]
21. Okkesim, C.E.; Serbest, S.; Tiftikçi, U.; Çirpar, M. Prospective evaluation of preoperative and postoperative sleep quality in carpal tunnel release. *J. Hand Surg. Eur. Vol.* **2019**, *44*, 278–282. [[CrossRef](#)]
22. Trouw, A.G.; Patel, A.; Yang, A.; Jauregui, J.; Caligiuri, D.; Choueka, J. Improvement in Sleep Quality after Carpal Tunnel Release. *J. Long Term Eff. Med. Implant.* **2018**, *28*, 55–61. [[CrossRef](#)]
23. Lins, L.; Carvalho, F.M. SF-36 total score as a single measure of health-related quality of life: Scoping review. *SAGE Open Med.* **2016**, *4*, 2050312116671725. [[CrossRef](#)]

24. Atroshi, I.; Gummesson, C.; Johnsson, R.; Sprinchorn, A. Symptoms, disability, and quality of life in patients with carpal tunnel syndrome. *J. Hand Surg. Am.* **1999**, *24*, 398–404. [[CrossRef](#)]
25. Chen, Y.; Ji, W.; Li, T.; Cong, X.; Chen, Z. The mini-incision technique for carpal tunnel release using nasal instruments in Chinese patients. *Medicine* **2017**, *96*, e7677. [[CrossRef](#)] [[PubMed](#)]
26. Galasso, O.; Mariconda, M.; Donato, G.; Di Mizio, G.; Padua, L.; Brando, A.; Conforti, F.; Valentino, P.; Gasparini, G. Histopathological, clinical, and electrophysiological features influencing postoperative outcomes in carpal tunnel syndrome. *J. Orthop. Res.* **2011**, *29*, 1298–1304. [[CrossRef](#)] [[PubMed](#)]
27. Sinha, S.; Naik, M.; Wright, V.; Timmons, J.; Campbell, A.C. A single blind, prospective, randomized trial comparing n-butyl 2-cyanoacrylate tissue adhesive (Indermil) and sutures for skin closure in hand surgery. *J. Hand Surg. Br.* **2001**, *26*, 264–265. [[CrossRef](#)] [[PubMed](#)]

**Disclaimer/Publisher's Note:** The statements, opinions and data contained in all publications are solely those of the individual author(s) and contributor(s) and not of MDPI and/or the editor(s). MDPI and/or the editor(s) disclaim responsibility for any injury to people or property resulting from any ideas, methods, instructions or products referred to in the content.



## 13.1. Anketni obrasci i upitnici korišteni u istraživanju

### POSAS ljestvica bolesnika: Skala za procjenu ožiljaka pacijenta i promatrača v 2.0 / EN

Ispiti

Datum ispitivanja:

Ime pacijenta:

Lokacija:

Datum rođenja:

Studija i matični broj:

Ispitivač:

Je li ožiljak bolan? Bez pritužbi 1 2 3 4 5 6 7 8 9 10 Najgore moguće

Svrbi li vas ožiljak? Bez pritužbi 1 2 3 4 5 6 7 8 9 10 Najgore moguće

Je li boja ožiljka drugačija? Bez pritužbi 1 2 3 4 5 6 7 8 9 10 Najgore moguće

Je li ožiljak krući? Bez pritužbi 1 2 3 4 5 6 7 8 9 10 Najgore moguće

Je li debljina ožiljka drugačija u odnosu na okolnu kožu?

Bez pritužbi 1 2 3 4 5 6 7 8 9 10 Najgore moguće

Je li ožiljak nepravilan? Bez pritužbi 1 2 3 4 5 6 7 8 9 10 Najgore moguće

Ukupan broj bodova:

Kakvo je vaše mišljenje o ožiljku u usporedbi s normalnom kožom? 1- normalna koža, 10-vrlo različita

1 2 3 4 5 6 7 8 9 10

### VIZUALNA NUMERIČKA LJESTVICA ZA PROCJENU BOLI VNRS:

Bez boli 0 1 2 3 4 5 6 7 8 9 10 Najgora moguća bol

### KOZMETIČKA VIZUALNA ANALOGNA LJESTVICA - VAS:

Datum: Najgori ožiljak 0 10 20 30 40 50 60 70 80 90 100 Najbolji ožiljak

-----

Datum: Najgori ožiljak 0 10 20 30 40 50 60 70 80 90 100 Najbolji ožiljak

-----

Datum: Najgori ožiljak 0 10 20 30 40 50 60 70 80 90 100 Najbolji ožiljak

-----

---

**POSAS ljestvica ispitivača:**

Skala za procjenu ožiljaka pacijenta i promatrača v 2.0 / EN

Datum ispitivanja:

Ime pacijenta:

Lokacija:

Datum rođenja:

Studija:

Matični broj

Ispitivač:

|                |   |   |   |   |   |   |   |   |   |    |                        |
|----------------|---|---|---|---|---|---|---|---|---|----|------------------------|
| Normalna koža  | 1 | 2 | 3 | 4 | 5 | 6 | 7 | 8 | 9 | 10 | Najgori mogući ožiljak |
| Vaskularitet   | 1 | 2 | 3 | 4 | 5 | 6 | 7 | 8 | 9 | 10 |                        |
| Pigmentacija   | 1 | 2 | 3 | 4 | 5 | 6 | 7 | 8 | 9 | 10 |                        |
| Debljina       | 1 | 2 | 3 | 4 | 5 | 6 | 7 | 8 | 9 | 10 |                        |
| Olakšanje boli | 1 | 2 | 3 | 4 | 5 | 6 | 7 | 8 | 9 | 10 |                        |
| Rastegljivost  | 1 | 2 | 3 | 4 | 5 | 6 | 7 | 8 | 9 | 10 |                        |
| Površina       | 1 | 2 | 3 | 4 | 5 | 6 | 7 | 8 | 9 | 10 |                        |

Ukupan broj bodova:

---

## **PITTSBURGH INDEKS KVALITETE SNA**

**(PITTSBURGH SLEEP QUALITY INDEX)**

### **UPUTA:**

Navedena pitanja odnose se na Vaše uobičajene postupke vezane za spavanje isključivo tijekom posljednjih mjesec dana. Vaš odgovor trebao bi predstavljati tvrdnju koja najtočnije opisuje većinu dana i noći u posljednjih mjesec dana. Molim vas odgovorite na sva navedena pitanja.

1. Tijekom posljednjih mjesec dana, u koje vrijeme ste obično išli na spavanje?

Vrijeme odlaska na spavanje:

2. Tijekom posljednjih mjesec dana, koliko Vam je vremena potrebno za usnuće (u minutama)?

Broj minuta:

3. Tijekom posljednjih mjesec dana, u koliko sati ste obično ustajali ujutro?

Vrijeme ustajanja:

4. Tijekom posljednjih mjesec dana koliko ste sati spavali tijekom noći? (Može se razlikovati od vremena provedenog u krevetu.)

Broj sati spavanja tijekom noći:

**Za svako slijedeće pitanje označite odgovor koji je za Vas najtočniji. Molim vas da odgovorite na sva navedena pitanja. Ponuđeni odgovori su sljedeći:**

**Ne u posljednjih mjesec dana (0)**

**Rjeđe od jednom tjedno (1)**

**Jednom ili dva puta tjedno (2)**

**Tri ili više puta tjedno (3)**

5. Tijekom posljednjih mjesec dana, koliko često ste imali ovakve poteškoće sa spavanjem:

|  |   |   |   |   |
|--|---|---|---|---|
| a) Niste mogli zaspati tijekom prvih 30 minuta | 0 | 1 | 2 | 3 |
| b) Budili ste se tijekom noći ili rano ujutro  | 0 | 1 | 2 | 3 |
| c) Morali ste ustati da odete u toalet         | 0 | 1 | 2 | 3 |
| d) Niste mogli normalno disati                 | 0 | 1 | 2 | 3 |
| e) Kašljali ste ili glasno hrkali              | 0 | 1 | 2 | 3 |
| f) Bilo Vam je hladno                          | 0 | 1 | 2 | 3 |
| g) Bilo Vam je vruće                           | 0 | 1 | 2 | 3 |
| h) Sanjali ste ružno                           | 0 | 1 | 2 | 3 |
| i) Osjećali ste bol                            | 0 | 1 | 2 | 3 |
| j) Iz drugih razloga, molim Vas navedite:      |   |   |   |   |

-----  
Koliko često ste u posljednjih mjesec dana imali poteškoća sa spavanjem zbog ovog razloga?

0      1      2      3

6. Kako biste ocijenili kvalitetu vašeg sna tijekom posljednjih mjesec dana?

---

Vrlo dobra -----  
Uglavnom dobra -----  
Uglavnom loša -----  
Vrlo loša -----

1. Tijekom posljednjih mjesec dana, koliko često ste uzeli lijek kako biste zaspali?  
Ne u posljednjih mjesec dana (0)  
Rjeđe od jednom tjedno (1)  
Jednom ili dva puta tjedno (2)  
Tri ili više puta puta tjedno (3)
  
2. U posljednjih mjesec dana, koliko često ste imali poteškoća ostati budni prilikom vožnje, druženja, obroka?  
Ne u posljednjih mjesec dana (0)  
Rjeđe od jednom tjedno (1)  
Jednom ili dva puta tjedno (2)  
Tri ili više puta puta tjedno (3)
  
3. Tijekom posljednjih mjesec dana, koliko ste poteškoća imali s nedostatkom elana za dovršenje započetih aktivnosti?  
  
Nije bilo poteškoća -----  
Vrlo malo poteškoća -----  
Bilo je određenih poteškoća -----  
Vrlo velike poteškoće -----
  
4. Spava li netko pokraj Vas u krevetu ili u istoj prostoriji?  
Ne -----  
Da u drugoj prostoriji -----  
U istoj prostoriji, ne u istom krevetu -----  
U istom krevetu -----

Ukoliko netko spava pokraj Vas u istom krevetu ili prostoriji, upitajte ga koliko često ste u posljednjih mjesec dana:

- |  |   |   |   |   |
|--|---|---|---|---|
| a) Hrkali glasno   | 0 | 1 | 2 | 3 |
| b) Imali duge pauze u disanju tijekom spavanja                       | 0 | 1 | 2 | 3 |
| c) Imali grčeve ili trzajeve noge tijekom spavanja                   | 0 | 1 | 2 | 3 |
| d) Imali trenutke dezorjentiranosti ili zbunjenosti tijekom spavanja | 0 | 1 | 2 | 3 |
| e) Druge vrste nemira tijekom spavanja, molim Vas opišite            | 0 | 1 | 2 | 3 |

---

1989 University of Pittsburgh. All Rights reserved. Developed by Buysse, D.J. Reynolds, C.F., Monk T.H., Berman S.R., and Kupfer D.J. of the University of Pittsburgh using national Institute of Mental Health Funding.

Buysse DJ, ReynoldsCF, Monk TH, Berman SR, Kupfer DJ: Psychiatry Research, 28: 193-213, 1989



---

**Upitnik za procjenu zdravstvenog statusa SF-36****UPITNIK SF – 36**

Ime i prezime: \_\_\_\_\_

1. Općenito, biste li rekli da je Vaše zdravlje : (zaokružite jedan odgovor)

|                 |   |
|-----------------|---|
| Izvršno         | 1 |
| vrlo dobro      | 2 |
| dobro           | 3 |
| zadovoljavajuće | 4 |
| loše            | 5 |

2. U usporedbi s prošlom godinom, kako biste sada ocijenili svoje zdravlje?
- 
- (zaokružite jedan odgovor)

|  |   |
|--|---|
| puno bolje nego prije godinu dana      | 1 |
| malo bolje nego prije godinu dana      | 2 |
| otprilike isto kao i prije godinu dana | 3 |
| malo lošije nego prije godinu dana     | 4 |
| puno lošije nego prije godinu dana     | 5 |

Sljedeća pitanja se odnose na aktivnosti kojima se možda bavite tijekom jednog tipičnog dana. Ograničava li Vas trenutno Vaše zdravlje u obavljanju tih aktivnosti?

Ako DA, u kojoj mjeri? (zaokružite jedan broj u svakom redu)

| AKTIVNOSTI   | DA puno | DA malo | NE nimalo |
|--|---------|---------|-----------|
| 3.fizički naporne aktivnosti, kao što su trčanje, podizanje teških predmeta, sudjelovanje u naporim sportovima | 1       | 2       | 3         |
| 4.umjeren naporne aktivnosti, kao što su pomicanjestola, vožnja biciklom, boćanje i sl.                        | 1       | 2       | 3         |
| 5. podizanje ili nošenje torbe s namirnicama   | 1       | 2       | 3         |
| 6. uspinjanje uz stepenice (nekoliko katova)   | 1       | 2       | 3         |
| 7. uspinjanje uz stepenice (jedan kat)   | 1       | 2       | 3         |
| 8. saginjanje, klečanje ili pregibanje   | 1       | 2       | 3         |
| 9. hodanje više od 1 kilometra   | 1       | 2       | 3         |
| 10.hodanje oko pola kilometra  | 1       | 2       | 3         |
| 11.hodanje 100 metara  | 1       | 2       | 3         |
| 12. kupanje ili oblačenje  | 1       | 2       | 3         |

Jeste li u protekla 4 tjedna u svom radu ili drugim redovitim dnevnim aktivnostima imali neki od slijedećih problema zbog svog fizičkog zdravlja?

(zaokružite jedan broj u svakom redu)

|   | DA | NE |
|---|----|----|
| 13. skratili ste vrijeme provedeno u radu i drugim aktivnostima   | 1  | 2  |
| 14. obavili ste manje nego što ste željeli  | 1  | 2  |
| 15. niste mogli obaviti neke poslove ili druge aktivnosti   | 1  | 2  |
| 16. imali ste poteškoća pri obavljanju posla ili nekih drugih aktivnosti (npr. morali ste uložiti dodatni trud) | 1  | 2  |

Jeste li u protekla 4 tjedna imali neke od dolje navedenih problema na poslu ili pri obavljanju nekih drugih svakodnevnih aktivnosti zbog bilo kakvih emocionalnih problema (npr. osjećaj potištenosti ili tjeskobe)?

(zaokružite jedan broj u svakom redu)

|  | DA | NE |
|--|----|----|
| 17. skratili ste vrijeme provedeno u radu ili drugim aktivnostima      | 1  | 2  |
| 18. obavili ste manje nego što ste željeli                             | 1  | 2  |
| 19. niste obavili posao ili druge aktivnosti onako pažljivo kao obično | 1  | 2  |

20. U kojoj su mjeri u protekla 4 tjedna Vaše fizičko zdravlje ili Vaši emocionalni problemi utjecali na Vaše uobičajene društvene aktivnosti u obitelji, s prijateljima, susjedima ili drugim ljudima?

(zaokružite jedan odgovor)

|                |   |
|----------------|---|
| uopće ne       | 1 |
| u manjoj mjeri | 2 |
| umjereno       | 3 |
| prilično       | 4 |
| izrazito       | 5 |

21. Kakve ste tjelesne bolove imali u protekla 4 tjedna?  
(zaokružite jedan odgovor)

|            |   |
|------------|---|
| Nikakve    | 1 |
| vrlo blage | 2 |
| blage      | 3 |
| umjerene   | 4 |
| teške      | 5 |
| vrlo teške | 6 |

22. U kojoj su Vas mjeri ti bolovi u protekla 4 tjedna ometali na Vašem uobičajenom radu  
(uključujući rad izvan kuće i kućne poslove)  
(zaokružite jedan odgovor)

|          |   |
|----------|---|
| uopće ne | 1 |
| malo     | 2 |
| umjereno | 3 |
| prilično | 4 |
| izrazito | 5 |

Sljedeća pitanja govore o tome kako se osjećate i kako ste se osjećali u protekla 4 tjedna.  
Molim Vas da za svako pitanje odaberete po jedan odgovor koji će najbliže odrediti kako ste se osjećali.

Koliko ste (se) vremena u protekla 4 tjedna:  
(zaokružite jedan odgovor u svakom redu)

|  | stalno | skoro uvijek | dobar dio vremena | povremeno | rijetko | nikada |
|--|--------|--------------|-------------------|-----------|---------|--------|
| 23. osjećali puni života?  | 1      | 2            | 3                 | 4         | 5       | 6      |
| 24. bili vrlo nervozni?  | 1      | 2            | 3                 | 4         | 5       | 6      |
| 25. osjećali tako potištenim da Vas ništa nije moglo razvedriti? | 1      | 2            | 3                 | 4         | 5       | 6      |
| 26. osjećali spokojnim i mirnim?                                 | 1      | 2            | 3                 | 4         | 5       | 6      |
| 27. bili puni energije?  | 1      | 2            | 3                 | 4         | 5       | 6      |

|                                   |   |   |   |   |   |   |
|-----------------------------------|---|---|---|---|---|---|
| 28. osjećali malodušnim i tužnim? | 1 | 2 | 3 | 4 | 5 | 6 |
| 29. osjećali iscrpljenim?         | 1 | 2 | 3 | 4 | 5 | 6 |
| 30. bili sretni?                  | 1 | 2 | 3 | 4 | 5 | 6 |
| 31. osjećali umornim?             | 1 | 2 | 3 | 4 | 5 | 6 |

32. Koliko su Vas vremena u protekla 4 tjedna Važe fizičko zdravlje ili emocionalni problemi ometali u društvenim aktivnostima (npr. posjete prijateljima, rodbini i sl.)

|              |   |
|--------------|---|
| stalno       | 1 |
| skoro uvijek | 2 |
| povremeno    | 3 |
| rijetko      | 4 |
| nikada       | 5 |

Koliko je u Vašem slučaju TOČNA ili NETOČNA svaka od dolje navedenih tvrdnji?

(zaokružite jedan odgovor u svakom redu)

|  | potpuno točno | uglavnom točno | ne znam | uglavnom netočno | potpuno netočno |
|--|---------------|----------------|---------|------------------|-----------------|
| 33. čini mi se da se razbolim lakše nego drugi ljudi | 1             | 2              | 3       | 4                | 5               |
| 34. zdrav sam kao i bilo tko drugi koga poznam       | 1             | 2              | 3       | 4                | 5               |
| 35. mislim da će mi se zdravlje pogoršati            | 1             | 2              | 3       | 4                | 5               |
| 36. zdravlje mi je odlično                           | 1             | 2              | 3       | 4                | 5               |