

Colles' fracture treatment and rehabilitation at University Hospital of Split : one-year retrospective study

Belcovska, Marina

Master's thesis / Diplomski rad

2018

Degree Grantor / Ustanova koja je dodijelila akademski / stručni stupanj: **University of Split, School of Medicine / Sveučilište u Splitu, Medicinski fakultet**

Permanent link / Trajna poveznica: <https://um.nsk.hr/um:nbn:hr:171:016156>

Rights / Prava: [In copyright](#)/[Zaštićeno autorskim pravom.](#)

Download date / Datum preuzimanja: **2024-07-26**



Repository / Repozitorij:

[MEFST Repository](#)



**UNIVERSITY OF SPLIT
SCHOOL OF MEDICINE**

MARINA BELCOVSKA

**COLLES' FRACTURE TREATMENT AND REHABILITATION
AT UNIVERSITY HOSPITAL OF SPLIT: ONE-YEAR
RETROSPECTIVE STUDY**

Diploma Thesis

Academic year:

2017/2018

Mentor:

Assist. Prof. Ana Poljičanin, MD, PhD

Split, July 2018

**UNIVERSITY OF SPLIT
SCHOOL OF MEDICINE**

MARINA BELCOVSKA

**COLLES' FRACTURE TREATMENT AND REHABILITATION
AT UNIVERSITY HOSPITAL OF SPLIT: ONE-YEAR
RETROSPECTIVE STUDY**

Diploma Thesis

**Academic year:
2017/2018**

**Mentor:
Assist. Prof. Ana Poljičanin, MD, PhD**

Split, July 2018

TABLE OF CONTENTS

1. INTRODUCTION.....	1
1.1. Distal radius fracture	2
1.1.1. History.....	2
1.1.2. Definition	2
1.2. Anatomy and Function of the Wrist joint in brief.....	3
1.2.1. The radial bone.....	3
1.2.2. The distal radioulnar joint	4
1.2.3. The column model.....	4
1.3. Epidemiology.....	4
1.3.1. Pediatric distal radius fractures	5
1.3.2. Adolescent distal radius fractures	5
1.3.3. Distal radius fractures in the elderly	5
1.3.4. Gender distribution	5
1.4. Mechanism of Injury.....	6
1.4.1. Pediatric fracture mechanisms	6
1.4.2. Adult fracture mechanisms	6
1.5. Clinical presentation	6
1.6. Diagnosis.....	7
1.6.1. Signs of distal radius fracture.....	7
1.6.2. Radiographic imaging	7
1.6.2.1. Radiographic evaluation.....	8
1.6.3. Ultrasound imaging.....	9
1.6.4. Computer tomography	9
1.6.5. Magnetic resonance imaging	10
1.7. Classifications	10
1.7.1. DRF eponyms	10
1.7.2. Frykman classification	10
1.7.3. Fernandez classification	11
1.7.4. AO classification.....	11
1.8. Associated injuries	11
1.8.1. Ulnar styloid fracture	11
1.8.2. Soft tissue injuries.....	12

1.8.3. Scaphoid bone fracture.....	12
1.8.4. Neurovascular injuries	12
1.9. Fracture healing basics.....	12
1.9.1. Primary bone healing	13
1.9.2. Secondary bone healing	13
1.9.2.1. Inflammatory response.....	13
1.9.2.2. Soft callus (cartilage) formation.....	13
1.9.2.3. Hard callus formation.....	14
1.9.2.4. Bone remodeling	14
1.10. Treatment of Colles' fractures.....	14
1.10.1. Acceptable alignment.....	14
1.10.2. Conservative treatment	15
1.10.3. Surgical treatment	15
1.10.3.1. Percutaneous fixation	16
1.10.3.2. External fixation.....	16
1.10.3.3. ORIF.....	17
1.11. Rehabilitation	17
1.11.1. Aims of DRF rehabilitation.....	18
1.11.2. Rehabilitation stages for distal radius fractures	18
1.11.2.1. Early stage	18
1.11.2.2. Intermediate stage	19
1.11.2.3. Late stage.....	19
1.11.3. Physical therapy modalities.....	19
1.11.3.1. Kinesiotherapy	19
1.11.3.1.1. Passive exercises	19
1.11.3.1.2. Active assisted exercises	21
1.11.3.1.3. Active exercises.....	21
1.11.4. Cryotherapy.....	23
1.11.5. Magnetotherapy.....	23
1.11.6. Education.....	23
1.12. Outcomes and Complications.....	24
1.12.1. Outcome measures	24
1.12.1.1. Manual Muscle Testing.....	26
1.12.2. Complications.....	26

1.12.2.1. Disrupted bone healing.....	26
1.12.2.2. Complex regional pain syndrome	27
2. OBJECTIVES	28
3. SUBJECTS AND METHODS.....	30
3.1. Data collection.....	31
3.1.1 Inclusion criteria.....	31
3.1.2 Exclusion criteria.....	32
3.3. Statistical analysis	32
4. RESULTS.....	33
4.1. Surgical Emergency Data.....	34
4.2. Rehabilitation Data.....	37
5. DISCUSSION	38
6. CONCLUSIONS	43
7. REFERENCES.....	45
8. SUMMARY	51
9. CROATIAN SUMMARY.....	53
10. CURRICULUM VITAE	56

ACKNOWLEDGMENTS

Foremost, I would like to thank my mentor, Ana Poljičanin, for the continuous guidance and encouragement that made this diploma thesis possible.

To my dear friends and colleagues, it's been a pleasure.

To Evin, thank you for walking this path alongside me. We started out as strangers, now we part as sisters.

To my sister and family, thank you for giving me the opportunity to make my dream a reality. You taught me to continue even when the going gets tough and proved that it's worth it.

To Victor, I didn't know what was missing until I met you. You complete me.

1. INTRODUCTION

Distal radius fractures (DRF) are one of the most common locomotor injuries, especially in the elderly (1). Despite recent medical developments, the incidence is increasing, and the functional outcomes remain diverse (1). There is no simple cause for the increasing incidence, but there are theories based on the increased life expectancy as well as urbanization, childhood obesity, and osteoporosis (1,2). None of the medical treatment methods available today have been scientifically proven superior.

Due to the impact of distal radius fractures on the function of the hand, and the increasing incidence, the area is widely researched, resulting in numerous techniques for repositioning and fixation (both conservative and surgical). An important aspect of treatment for long-term outcome after DRF is physical rehabilitation.

1.1. Distal radius fracture

1.1.1. History

Historically the distal radius fractures were thought to be dislocations (3). All from the times of Hippocrates and Galen, until the French surgeon Pouteau published a paper describing a variety of distal radius fractures in French literature in 1783. (3). This new description was however not accepted by the English-speaking world until the Irish surgeon Abraham Colles clinically described DRFs in 1814. (3). Dr. Colles described fractures of the distal radius without help of radiography which was discovered 81 years later (3,4).

Today, the term distal radius fracture covers all fractures of the distal articular and metaphyseal areas of the radial bone. DRFs are considered the most common type of fractures in adults (5,6). They account for nearly 20% of all fractures treated in emergency departments (7).

1.1.2. Definition

There are numerous classifications, sub-classification systems and eponyms describing DRFs. The most used eponyms are: Colles', Smith, Barton and Chauffer's fractures (Table 1).

The single most commonly used eponym is Colles' fracture (8,9). It is characterized by extra-articular metaphyseal injury (within 2–3 cm of articular surface) of the distal radius with characteristic dorsal angulation, dorsal shift, radial tilt, radial shift, supination and impaction (7,9,10). Colles' fracture is often referred to as *fractura radii loco typico*.

Smith's fracture is a DRF with palmar tilt of the distal fragment (reversed Colles') (7,9). A Barton's fracture is a displaced intra-articular fracture-dislocation of the dorsal rim of the distal radius with displacement of the carpus (7,9). Reversed Barton's fracture can occur with the wrist in palmar flexion, fracturing the volar rim. Chauffer's fracture describes an intra-articular avulsion fracture of the radial styloid (9).

Table 1. Eponym and fracture description

Colles' fracture	Dorsally angulated and displaced DRF
Smith's fracture (reversed Colles')	Volar angulation of distal fragment
Barton's fracture	Displaced intra-articular fracture/dislocation of the dorsal articular rim
Chauffer's fracture	Avulsion fracture of the radial styloid

1.2. Anatomy and Function of the Wrist joint in brief

The wrist is a complex joint, consisting of all the tissues between the proximal aspect of the distal radioulnar joint and the base of the metacarpals (11). This includes the distal radius and ulna, the eight carpal bones, the proximal metacarpals, their respective synovial compartments and all the soft tissues surrounding the bones (10,11). A clear understanding of the anatomy and function is necessary to treat any injuries in the wrist joint, as a fracture can involve several soft-tissue injuries that also warrant attention (3).

1.2.1. The radial bone

The radius is a typical long bone located laterally in the forearm (12,13). It has two facets on its distal articular surface for the scaphoid and lunate bones, on the right and left sides respectively, forming the wrist joint (3,11,13). Together with the ulna it forms the distal radioulnar joint (DRUJ), connected at the ulnar notch located on the medial side of the radius (10,13). Both the radial and the ulnar bones terminate with styloid processes distally (10). Normally the radial styloid process extends further distally than the ulnar styloid process, in Colles' fractures it is reversed due to the shortening of the radius (10). The ulnar variance is dependent on the position of the wrist, in supination the ulna is longer while in pronation the ulna is normally shorter (5).

1.2.2. The distal radioulnar joint

Normally the distal radial articular surface is tilted at approximately 20 to 25 degrees toward the ulna and 10 degrees toward the palm (11). The normal wrist alignment of the radial articular surface enables palmar tilt and ulnar inclination (11). Main functions of the DRUJ is to facilitate supination and pronation, by allowing the radius to pivot around the ulna (10,11,13). In order to maintain the mobility of the wrist without sacrificing stability, the bones are connected and supported by a complex structure of ligaments (14). The main stabilizers of the DRUJ are the triangular fibrocartilage complex (TFCC) and the palmar and dorsal radioulnar ligaments (9). Loss of radial height (5mm or more) can cause distortion of the TFCC, which may lead to loss of pronosupination (9).

1.2.3. The column model

A column-type model was described by Rikli and Regazzoni (9). The model divides the anatomy of the wrist into three distinct columns: 1. Radial column; 1. Intermediate column; 3. Ulnar column.

The radial column includes the radial styloid, scaphoid facet, and attachments of radiolunate ligament, radioscapocapitate ligament, and brachioradialis (9). It has little weight bearing function, but the pull from the brachioradialis can cause loss of radial height, inclination, and radial translation in the case of fractures (9).

The intermediate column is the primary load-bearing component formed by the lunate facet, sigmoid notch, and ligamentous attachments. Articular congruity and mechanical axis alignment is of greatest importance in this column.

The ulnar column is composed of the distal ulna and the TFCC, serving as the rotational axis of the wrist. This column is critical for DRUJ stability and forearm rotation (9).

1.3. Epidemiology

Colles' fractures are the most common fractures of the forearm in adults (5,10,15). Annually more than 600,000 distal radius fractures occur in the United States (9,16). In very small children the most common injuries are buckle/torus fractures of the distal radius (4,11). The incidence of DRFs in all age groups have increased in recent time. The exact cause for this rise is unknown, but some of the theories are increased life expectancy, urbanization, childhood obesity, and osteoporosis (1,2).

1.3.1. Pediatric distal radius fractures

The incidence and fracture patterns of Colles' fractures vary depending on age. In children 4–10 years of age most fractures of the distal radius and ulna are incomplete, leaving the cortex intact (buckle/torus) (11). Buckle/torus fractures are a result of compressive forces exerted onto the relatively soft metaphysis in young children, causing cortical bone buckling (4,17,18). These injuries are very stable, and even with some fracture angulation a simple wrist splint gives a satisfactory result (17,18). More force produces a greenstick fracture, or a complete fracture (18). Displaced or angulated DRFs are sufficiently reduced by closed reduction in children (18). Open reduction is reserved for irreducible or open fractures (18).

1.3.2. Adolescent distal radius fractures

Adolescent children (11–17 years) have stronger bones, resulting in Salter-Harris II injuries (physeal shear with marginal metaphyseal fracture) also known as juvenile Colles' fracture (11,15,18). Salter-Harris II fractures with dorsal displacement of the distal radius are managed non-operatively unless there is significant angulation/displacement (11,15,18).

1.3.3. Distal radius fractures in the elderly

The incidence of Colles' fractures increases significantly after the age of 40, with a peak in the elderly population above 65 years of age (1,8,11). Numerous factors contribute to this increase, especially metabolic bone disorders e.g. osteoporosis, and vitamin D deficiency. Fracture patterns in adults are more diverse in terms of displacement, comminution, and intra-articular extent (11). The recommended treatment is dependent on the clinical and diagnostic features.

1.3.4. Gender distribution

Gender affects the distribution of distal radius fractures across the different age groups. The peak incidence in the pediatric population differs between boys and girls. It corresponds to the adolescent growth spurt, age 12–14 in boys and 10–12 in girls (18). DRFs are more common in boys than in girls in the pediatric population (1,2).

In the elderly population it is reversed, these injuries are more commonly sustained by women than men (2). One attributing factor is the prevalence of post-menopausal osteoporosis (19). Colles' fractures are also more often extra-articular in women than in men (20).

1.4. Mechanism of injury

The distal radius is the most common site for injuries from a fall onto an outstretched hand (FOOSH) (4,11,15). Forced dorsiflexion of the hand causes the Colles' fracture, which is often accompanied by avulsion of the ulnar styloid (10). About 85% of DRF are a result of wrist hyperextension (5). Less often, the wrist is flexed during the injury (21). Injuries can also be the result of a direct blow to the wrist (8).

1.4.1. Pediatric fracture mechanisms

Children are most likely to sustain a Colles' fracture during the beginning of puberty, while their bone mineralization is relatively low (2). The most common mechanisms in adolescents are high energy injuries from sports activities, motor vehicle accidents, or falls from greater heights (2,8). High energy injuries may cause intra-articular fractures (20). Due to the high bone turnover and healing potential in children anatomic reduction is not required and the fractures usually have excellent outcomes with low complication rates (1,2).

1.4.2. Adult fracture mechanisms

In the elderly population Colles' fractures are usually sustained by a low energy injury, the most common mechanism being FOOSH from a standing height or lower (2,8). When weakness of the bone contributes to the cause of the fracture it is categorized as a "fragility fracture" (8).

1.5. Clinical presentation

Patients suffering from distal radius fractures complain of wrist pain, tenderness, and swelling (8). The pain is exacerbated by flexion of the wrist, and there is often visible bruising. All skin breaks over possible fracture warrant surgical evaluation, as possible open fractures.

Classically a "dinner fork" deformity can be seen (8,10,11,15,21). The deformity is a result of the dorsal angulation and dorsal displacement of the distal radius (Colles' fracture) (8,20). This produces a depression at the fracture site and a posterior bending of the forearm just proximal to the wrist and the normal anterior curvature of the relaxed hand (8,10). Less commonly, Smith fracture may present with volar displacement due to wrist flexion during injury (21).

Swelling and/or deformity may injure other structures in the wrist, producing neurological symptoms. The median nerve can be injured directly or by increased pressure on the nerve, resulting in numbness of the index finger and a weak thumb to little finger pinch (21).

1.6. Diagnosis

Key elements of diagnosis of DRFs are a thorough history taking of the injury and examination of the wrist. The history is important due to the possible mechanisms of injury that can increase the suspicion of fracture. History with a fall on an outstretched hand is suspicious for fracture in the elderly but not in adolescents. During the examination, there are certain diagnostic and unspecific signs of fracture that should be evaluated.

1.6.1. Signs of distal radius fracture

Diagnostic signs of DRF:	Unspecific signs of DRF:
<ul style="list-style-type: none">• Pathologic flexibility at injury site• Crepitation• Classic deformity at injury site	<ul style="list-style-type: none">• Swelling• Tender wrist• Pain when moving the wrist joint• Bruising of skin above wrist• Decreased or diminished function of hand

1.6.2. Radiographic imaging

A definite diagnosis of a wrist fracture should be supported by conventional radiographs. Any traumatized or painful wrist with a history or clinical suspicion of DRF should undergo radiological evaluation (4,11). The diagnosis can be made on posterior-anterior (PA) and lateral X-rays of the wrist (Figure 1) (5). Both views need to show the distal radio-ulnar articulation, so that the fracture line can be properly visualized and radio-ulnar misalignment may be observed or excluded (5).

The standard X-ray projections of the wrist are taken with the forearm in neutral position. This means 90° abduction of the shoulder and 90° flexion of the elbow with the wrist and hand flat on the table for the PA view (5). For the lateral view the forearm is in neutral position if the distal forearm, lunate, capitate, and third metacarpal are aligned (5,11). It is worth to note that the ulna is normally shorter than the radius in supination (ulnar minus variance) and longer in pronation (ulnar plus variance) (5). Incorrect positioning for the radiographs can lead to misdiagnosis.

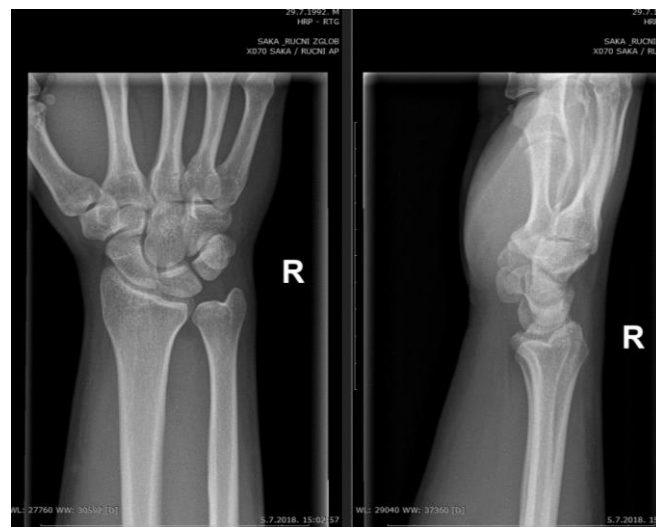


Figure 1. Conventional PA and lateral x-ray of unfractured wrist
(Pictures obtained with courtesy of Assist. Prof. Maja Marinović Guić, MD, PhD)

1.6.2.1. Radiographic evaluation

The five radiographic measurements that are used to evaluate distal radius fractures on x-rays are: 1. Radial height (impaction of the radius/loss of radial length); 2. Dorsal angulation (loss of normal 11° volar tilt); 3. Ulnar variance; 4. Radial inclination (displacement of the distal fragment); 5. Radial shift of the distal fragment (9,15).

A Colles' fracture is characterized by a fracture of the distal radius with apex volar angulation and dorsal impaction (Figure 2) (11).

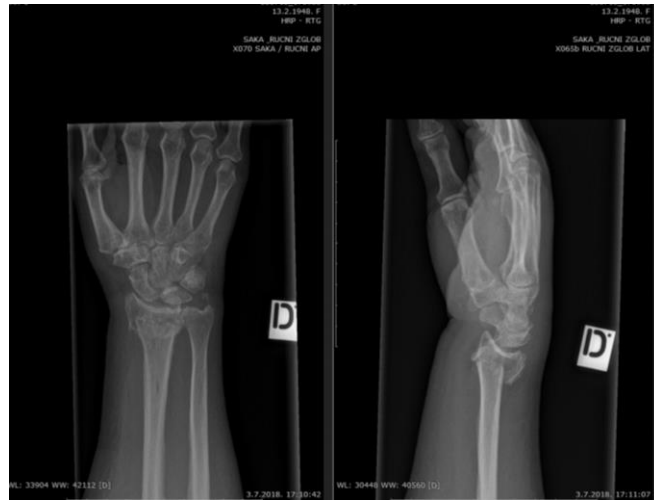

Figure 2. Conventional PA and lateral x-ray of fractured wrist

(Pictures obtained with courtesy of Assist. Prof. Maja Marinović Guić, MD, PhD)

Another sign of fracture is deformation/elevation of the pronator quadratus fat in palmar direction (4,15). The presence or absence of ulnar styloid fracture should be noted (9). If there is intra-articular extension, possible articular step-off should be measured (11). A defect of 2 mm or more is an indication for operative reduction (11).

Radiologically occult DRFs can be recognized by a hematoma in the palmar muscle compartment with a pronator quadratus sign (loss of the fat stripe of the pronator quadratus) (5).

1.6.3. Ultrasound examination

Ultrasound (US) can be used to assess for joint or tendon sheath effusion, or mass lesion in the carpal tunnel (11). In the pediatric population US is useful for diagnosis of cortical step deformities (5).

1.6.4. Computer tomography

Computer tomography (CT) is useful for recognizing occult or complex fractures, and articular involvement (5,9,21). Articular involvement is an important prognostic indicator, as any wrist incongruity will lead to post-traumatic arthrosis in 91% of patients (100% if >2mm) (9,11).

1.6.5. Magnetic resonance imaging

The most sensitive method for detection of fractures, avascular necrosis, tenosynovitis and mass lesions in the wrist is magnetic resonance imaging (MRI) (11). It is also useful to detect osteochondral injuries and stress fractures (5). All mentioned injuries can be detected by other radiological methods, however MRI is unique in its ability to assess associated carpal ligament and TFCC injuries (5,11).

Due to cost, availability, and diagnostic value only conventional radiography is used daily for DRF diagnosis.

1.7. Classifications

Distal radius fractures can be classified according to several classification systems that have been developed over the years to describe fracture patterns and better guide treatment (9). Currently, there are 15 described distal radius classification systems, describing the fractures according to fracture patterns, comminution, and displacement (22).

The four most commonly used classification systems are Frykman (1967), Universal (Cooney 1993), Fernández (2001), and AO (2007) (23). Neither of which is considered a golden standard.

1.7.1. DRF eponyms

The first classifications of distal radius fractures used eponyms (Table 1). The first was Colles, describing an extra-articular, dorsally displaced, metaphyseal fractures with radial shortening (22). At first it was based on clinical features only (23). Today the eponym is often used synonymously with distal radius fracture. Barton describes an intra-articular fracture with either volar or dorsal displacement of the distal radius (22). Smith fracture (also known as reversed Colles') describes a volarly displaced distal radius fracture (22).

1.7.2. Frykman classification

The Frykman classification system distinguishes between four types of DRFs, focusing on radiocarpal and/or radioulnar joint involvement, as well as the presence or absence of ulnar styloid fracture (22).

The Universal classification system (refined by Cooney in 1993) was made in the attempt to improve on the Frykman classification by differentiating between displaced and nondisplaced intra-articular fractures (22). This resulted in a simple system differentiating extra- from intra-articular fractures and displaced from non-displaced fractures (22).

1.7.3. Fernandez classification

Fernandez is a mechanism-based classification, aiming to provide a better assessment of potential soft-tissue damage. It includes five types of injuries: I. bending of the metaphysis; II. shearing fractures of the joint surface; III. compression of the joint surface; IV. avulsion or radiocarpal fracture dislocations; V. combined fractures with high velocity injuries (22). It has a separate group for distal radioulnar joint injuries, jointly providing information about the fracture line, stability, and soft-tissue injury (22).

1.7.4. AO classification

The most comprehensive classification system is the AO (by the Association for the Study of Osteosynthesis). It describes in total 27 fracture patterns of the distal radius (22). It divides DRFs into three categories dependent on articular involvement: extra-articular, partially articular or intra-articular (5,9). The categories are further divided into groups and subgroups by fracture pattern, propagation, and comminution (9). Due to its extensive subdivisions it is often omitted in favor of easier classifications like Colles' when applicable.

All the mentioned classification systems have their strengths and weaknesses. None have survived statistical scrutiny, proving either to be unreliable, irreproducible or simply too complicated (22).

1.8. Associated Injuries

There are several injuries that can occur in combination with Colles' fractures. All associated injuries affect treatment choices. A few of these are ulnar styloid fractures, soft tissue injuries, scaphoid fractures, and neural injury.

1.8.1. Ulnar styloid fracture

Isolated distal ulnar fractures are very rare in comparison to DRFs, hence DRFs are often viewed as an injury with or without involvement of the ulna (5). DRFs are most often associated with ulnar styloid fractures (4,10,15). This is clinically relevant due to its impact on wrist stability and therefore should prompt further investigation (9).

1.8.2. Soft tissue injuries

The most frequently associated injuries are soft tissue injuries, especially tear of the TFCC which is found in 39-84% of unstable distal radius fractures (9). TFCC tear should therefore always be suspected when there is DRUJ instability (9). Soft tissue injuries may complicate DRFs by decreasing functional outcomes, grip strength, or causing intractable pain (9).

1.8.3. Scaphoid bone fracture

Another important injury, that can cause severe complications if missed, is fracture of the scaphoid bone. The scaphoid bone plays a role in wrist mobility as well as carpal stability. A missed fracture can cause post-traumatic osteoarthritis of the carpus, or avascular necrosis of the scaphoid bone (20).

1.8.4. Neurovascular injuries

The proximity and course of the median nerve make it vulnerable to direct and indirect injury from DRFs. Also, the radial and ulnar arteries can be affected. Hence all patients with Colles' fractures should undergo a thorough neurovascular examination (9).

1.9. Fracture healing basics

When the distal radius fractures, the body immediately initiates the process of healing (24). This process is dependent on several factors, eventually resulting in the restoration of the anatomy and function of normal bone after injury (25). The degree of fracture comminution and displacement affect the time needed for healing and functional recovery (24,25).

Two conditions are vital for bone healing: anatomic repositioning and fracture immobilization. Anatomic repositioning or acceptable alignment is integral for good bone healing. Fracture displacement frequently results in malunion (25). Immobilization is necessary to prevent secondary fracture displacement.

The mechanical stability between the fracture fragments dictates whether primary or secondary healing will take place (31). Primary healing is the process of direct restoration of continuity across the fracture line through intracortical remodeling (25). Secondary (spontaneous) healing involves callus formation and endochondral ossification (25). Unstable or insufficiently fixated fractures may lead to pseudarthrosis (25).

1.9.1. Primary bone healing

Primary or “direct” bone healing is characterized by the absence of callus formation (26), and only takes place when there is minimal interfragmentary motion (24,25). It requires a fracture gap of 0.5 millimeters or less (26). This can be accomplished by rigid internal plate fixation. Rigid fixation diminishes motion between the fracture fragments (24). The periosteal reaction to the bone injury is inhibited by rigid fixation, allowing osteons to directly bridge the fracture gap and regenerate the bone (remodeling) (24,25).

Newer locking plate splints do not compress the fracture site, resulting in a more flexible elastic fixation and callus formation (24). Plate fixation allows for earlier fracture loading and rehabilitation than other treatment methods (24,27).

1.9.2. Secondary bone healing

Spontaneous bone healing is driven by the response of the periosteum and surrounding soft tissues at the fracture site (25). Callus formation takes place under unstable or flexible fixations, that allow for interfragmentary motion (24). Cast treatment, percutaneous pin fixation, and external fixation leads to fracture repair through cartilage formation.

Secondary bone repair can be divided into 4 stages: 1. Inflammation; 2. Soft callus (cartilage formation); 3. Hard callus (endochondral ossification); 4. Bone remodeling.

1.9.2.1. Inflammatory response

The inflammatory response begins immediately after a fracture, marked by hematoma formation and inflammatory exudate from ruptured vessels (24). During this phase the fracture fragments are freely moveable. The hematoma is resorbed by the end of the first week unless excessive motion, infection, or necrosis is persisting in the surrounding soft tissues (25). This phase persists until the formation of cartilage or bone is initiated (1-7 days) (25).

1.9.2.2. Soft callus (cartilage) formation

A few days after the injury the hematoma begins to transform into granulation tissue (25). The formation of granulation tissue causes a slight increase in stability and mechanical strength (24). As the maturation process advances collagen is deposited forming an internal cartilaginous callus, the periosteum surrounding the fracture site thickens producing an external callus (25). The soft callus formed during the first 3 weeks after injury has enough tensile strength to prevent shortening, but protection against excessive forces is needed to prevent shortening and angulation (24).

1.9.2.3. Hard callus formation

Mineralization (endochondral ossification) of the soft callus forms a hard callus that restricts the movement of the fracture fragments (24,25). Intramembranous bone formation fills in the fracture gap if there is sufficient vascularization and mechanical support from the callus (25). The repair ultimately leads to firm bone union, the time required to achieve union is dependent on fracture comminution and patient characteristics (25). The new bone has enough strength to allow low-impact exercise (24).

1.9.2.4. Bone remodeling

Remodeling and recovery of optimal function and strength begins when the fracture has solidly united (24,25). The average time needed for healing of Colles' fractures is 3-5 weeks (24).

1.10. Treatment of Colles' fractures

The aim of DRF treatment is to restore alignment, leading to a pain free and functional wrist (3,9,28). Proper alignment helps to prevent complications like distal radioulnar joint instability (29). Treatment method is chosen according to several factors, including but not limited to the mechanism of the injury, fracture pattern, instability, age and the condition of the patient (5,28).

Restoration of anatomic alignment can be attempted by conservative or surgical means. In a lot of cases it is not possible to restore the alignment perfectly, therefore certain radiographic criteria for acceptable alignment are agreed upon (9,30).

1.10.1. Acceptable alignment

Radiographic criteria of acceptable alignment are: 1. Less than 2 mm radial shortening; 2. A minimum of 10° radial inclination; 3. 10° dorsal to 20° volar tilt; 4. Less than 2 mm intra-articular step-off (9,30). It is good practice to offer surgical treatment if any of the abovementioned parameters are not met following conservative reduction (30).

Distal radius fracture treatment should always be selected in consultation with the patient. The treating doctor provides a professional recommendation based on an assessment of benefits and risks of conservative vs. surgical treatment. This should be in accordance with the patient's wishes and needs. Limitations of each procedure should also be explained. Even when surgery is indicated by radiological parameters, each patient is at liberty to decline surgical intervention.

1.10.2. Conservative treatment

Majority of DRFs are closed fractures with or without fragment displacement (28). The mainstay of treatment of stable fractures is closed reduction and immobilization (9). All displaced fractures in adults need to be reduced prior to immobilization to avoid development of long-term complications. Radiographs are taken prior to reduction, and then again after reduction and immobilization (31). At University Hospital of Split the standard procedure is reduction under local anesthesia, followed by plaster cast immobilization below the elbow. The anesthesia is introduced directly into the hematoma.

The typical Colles' fracture reduction involves placing a thumb over the fracture site as a lever, hyperextension of the fracture fragment to distract it from the radial metaphysis, longitudinal traction, and palmar flexion to lever the dorsally displaced fracture fragment into position (32,33).

The American Academy of Orthopedic Surgeons recommends weekly radiographs during the first 3 weeks following immobilization, and then again after cast removal (9). The duration of immobilization depends on several factors, therein fracture pattern, stability and status of the patient. The average duration of splinting or casting is 4-6 weeks (34). In the case of secondary displacement of the fracture, reduction can be attempted again or a surgical technique is recommended (31).

1.10.3. Surgical treatment

Surgical interventions of DRFs are often indicated when reduction is unsuccessful or not possible, or secondary displacement takes place. Secondary displacement is more common in elderly patients (32). Open, unstable, and comminuted fractures also warrant surgical intervention (34). Today there are several surgical methods in use for DRF treatment, ranging from minimally invasive to open surgery. The main surgical techniques used today include percutaneous fixation, external fixation, ORIF (open reduction internal fixation), or in certain cases combinations.

1.10.3.1. Percutaneous fixation

Percutaneous fixation is a minimally invasive technique used to fixate dorsally displaced extra-articular DRFs (Colles' fracture).

Kirschner wires are passed through the skin over the anatomic snuffbox or the dorsal aspect of the distal radius and into the bone to hold the fracture fragment in the correct anatomical position (24,35). For sufficient internal fixation cast or splint immobilization is necessary for 4 to 6 weeks (9,24).

A successful result requires good bone quality and limited comminution (36). In patients with more than two cortices comminuted, or older than age 55 there is a high likelihood of fracture collapse with K-wire fixation alone (24).

Functional outcomes in patients over 60 years with low functional demands do not differ between percutaneous fixation and cast treatment alone (37). Possible complications from k-wire fixation includes tendon injury/rupture, pin migration, vascular injury, and pin site infection (9).

1.10.3.2. External fixation

External fixation is not as popular as it once was, but it is still indicated as initial treatment of patients with polytrauma, and/or open DRFs with severe soft tissue loss (9). External fixation is a technique that maintains fracture fragment reduction by ligamentotaxis (9).

Pins are drilled into the radius proximal to the fracture and into the index finger metacarpal distal to the fracture and spanning the carpal joint. A mechanical frame is attached to the pins and used to apply traction in different directions. This technique is considered a flexible fixation, with the callus development providing the rigidity of the fixator-bone complex (24).

Fracture fragment stability can be significantly increased, and dependence of ligamentotaxis reduced by augmentation with percutaneous K-wires (24). An external fixator reduces the risk of secondary displacement relative to conservative treatment, but there is a higher risk of infection (pin sites) (9,37).

1.10.3.3. ORIF

Open reduction followed by internal fixation is a technique frequently used for DRF fixation. Depending on the fracture pattern and comminution, dorsal, volar or fragment-specific locking plates can be used. The volar locking plate (VLP) has become the mainstay in most DRF fixations, especially Colles' fractures (dorsally displaced) (38,39). Reduction is done under direct visualization of the joint surface, after which fragments are splinted with internal plates (24,32). A flexible elastic fixation is achieved by fixation of the fracture without compression, stimulating callus formation (24).

The approach to dorsally displaced fractures (Colles') is most commonly through an incision over the palmar aspect of the wrist (35). The fracture line is visualized, and fragments are released and reduced, a volar locking plate is then positioned and provisionally held in place with K-wires until positioning is confirmed by radiography. The plate is then fixed to the bone with angle-locking screws, normally under fluoroscopic assistance (35).

Volar locking plates (VLP) are currently popular, yet not without complications (24,32). Iatrogenic injuries as well as intra-articular screw penetration due to fracture collapse can occur (9,39). There is evidence that volar plating leads to better short-term functional outcomes than dorsal plate fixation, as improved function, grip strength and decreased pain (32,37). However, there is no conclusive evidence of volar plating leading to better long-term outcomes compared to other fixation techniques (37).

1.11. Rehabilitation

Colles' fractures often heal with some persisting decrease in motility despite proper therapy (11). To decrease the incidence of chronic pain and decreased function all patients should receive practical instructions regarding self-rehabilitation following DRF regardless of treatment method (30).

According to the Norwegian guideline from 2015. and the Danish guideline from 2016. on the treatment and rehabilitation of distal radius fractures, uncomplicated fractures in patients with good function do not need to be referred to physical rehabilitation after removal of immobilization (30,40). A satisfactory result can be achieved with a home program of exercises (24,37).

According to Croatian common practice every diagnosed distal radius fracture should receive physical therapy after cast removal and is referred to Physical and Rehabilitation medicine (31).

The physical rehabilitation is nearly uniform among different fracture patterns, provided it has been treated appropriately (34). The program is tailored to each patient's needs, according to fracture treatment and initial function (41). Therapy can be done individually with a physical therapist, or it can be supervised in small groups. The pace of therapy can be significantly influenced by patient factors such as age, bone density, pain tolerance, and systemic disease (24).

1.11.1. Aims of DRF rehabilitation:

- Decrease pain, inflammation and edema in the acute phase
- Restore full joint movement and functional ability
- Maintain and increase muscle strength
- Education

1.11.2. Rehabilitation stages for distal radius fractures

Rehabilitation after distal radius fractures can be divided into three stages: early, intermediate and late.

1.11.2.1. Early stage

The early phase is considered from the moment of injury until the 6th week post-injury (34). In this period it is critical to limit swelling and stiffness in the hand (34). Swelling is limited and reduced by encouraging elevation of the hand above the level of the heart and frequent active mobilization of the upper limb (34). Stiffness can be limited by active and passive digit ROM exercises (24,34).

This stage corresponds to the time until cast, pin or external fixators are removed (24). Proper treatment of the fracture should provide adequate stability to allow for light use of the hand, e.g. assist with daily activities such as dressing and feeding (34).

1.11.2.2. Intermediate stage

The intermediate phase begins once early fracture healing is established by radiography, commonly between 6 – 8 weeks after the injury or operation (34). Casts, pins and external fixators are removed (24). Active-assisted forearm and wrist motion is initiated in this phase to maximize mobility (24,34).

1.11.2.3. Late stage

In the late phase fracture healing is well established (8 – 12 weeks after injury) (34). After plate fixation early mobilization (starting at week 2) has not proven to provide long-term benefits compared with delayed mobilization (starting at week 6) (37).

1.11.3. Physical therapy modalities

Physiotherapists employ active and passive interventions to achieve the aims of physical therapy (41). These interventions can include splints, passive movements, mobilization and strengthening exercises, cryotherapy, magnetotherapy, electrotherapy, advice and education (42). The most commonly used modalities at University Hospital of Split are further explained.

1.11.3.1 Kinesiotherapy

Kinesiotherapy is a medical field of movement therapy with focus on exercise principles adapted to enhance strength, endurance, and mobility of patients. It is a keystone in post-fracture rehabilitation for the best possible functional outcome. Therapy can usually begin 4-6 weeks after injury or surgery, provided that hard callus formation is radiographically confirmed (27).

There are three types of ROM exercises that can be used during rehabilitation: passive, active assisted, and active (31). All exercises should initially only be conducted under supervision by a physiotherapist, until the patient can perform them confidently and correctly independently (31). The muscle contractions should optimally last 5-6 seconds, with a break of 10-12 seconds between every second contraction (31). Great care should be taken to not overdo the exercises, to avoid exhaustion and pain.

The duration of treatment depends on the initial muscle strength of the patient, it can consist of everything from one consultation to several visits over several months.

1.11.3.1.1. Passive exercises

Passive ROM exercises are conducted with help from a physiotherapist, the injured wrist exerts no effort (Figures 3-5). The joints are moved through their full range of motion (Figures 3-5). Passive exercises can be used to improve circulation and maintain the flexibility of the wrist (31). The application of passive exercises does not affect muscle strength or prevent muscle wasting, limiting their usefulness in Colles' rehabilitation (31).

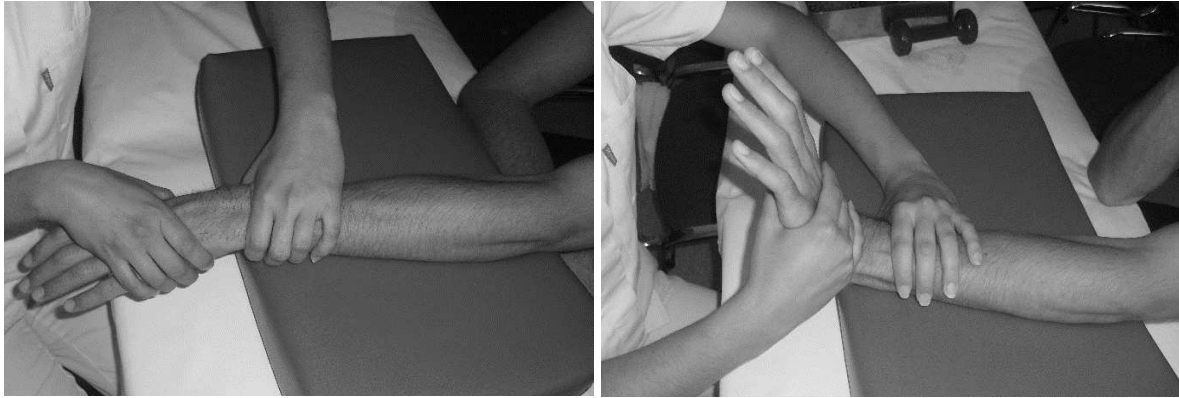

Figure 3. Passive exercises A. Starting position B. Passive extension of the wrist
(Pictures obtained with courtesy of Tihana Grgurević, Bacc. Physioth.)

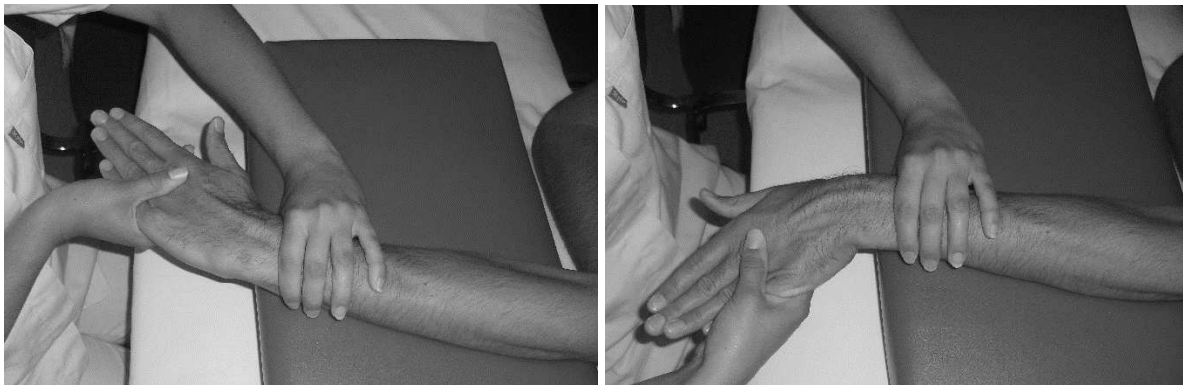

Figure 4. Passive exercises A. Passive radial deviation B. Passive ulnar deviation
(Pictures obtained with courtesy of Tihana Grgurević, Bacc. Physioth.)

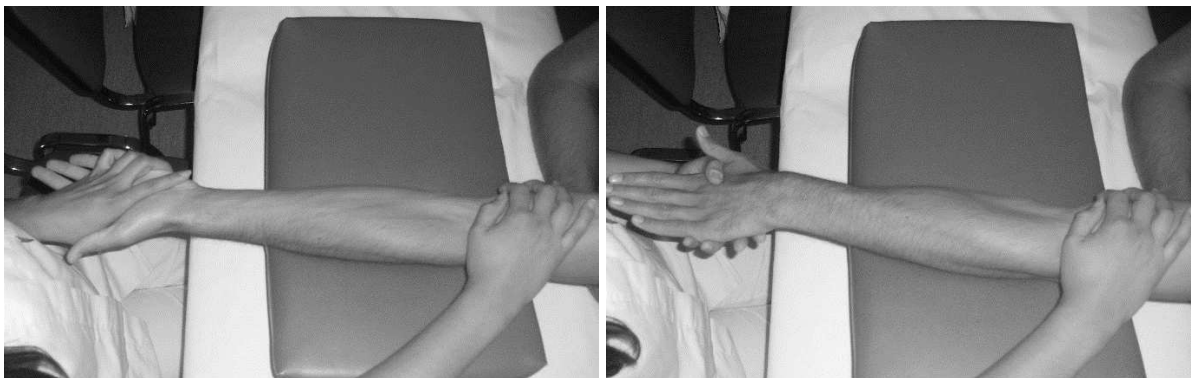

Figure 5. Passive exercises A. Passive supination B. Passive pronation
(Pictures obtained with courtesy of Tihana Grgurević, Bacc. Physioth.)

1.11.3.1.2. Active assisted exercises

Active assisted ROM exercises are performed by patients with decreased muscle strength, with the help from a physiotherapist or the healthy arm. The patient exerts maximum active contraction and performs as much of the motion as they can, the physiotherapist or the patient help complete the motion (Figure 6). The only way to increase muscle strength is by active contractions (31). These exercises are a good way to begin restoring enough strength for active exercises.

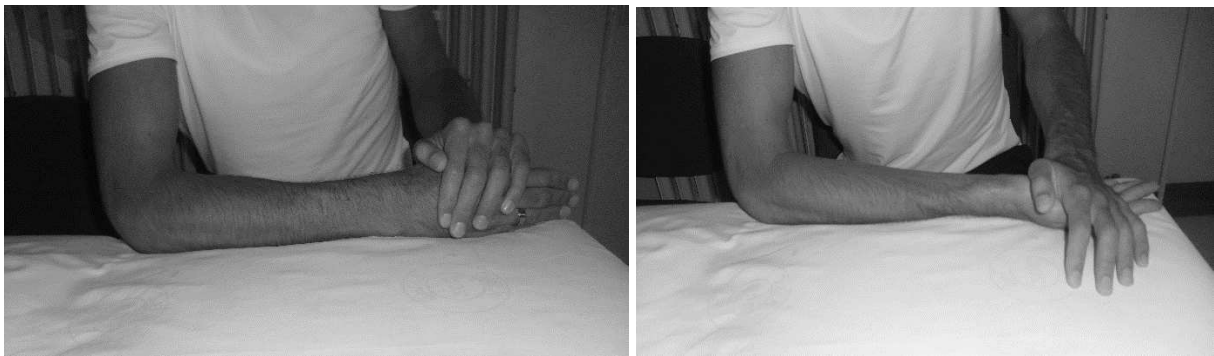


Figure 6. Active assisted supination.

(Pictures obtained with courtesy of Tihana Grgurević, Bacc. Physioth.)

1.11.3.1.3. Active exercises

Active ROM exercises can only be performed by patients with well-preserved or recovered muscle strength. The range of motion is performed by isotonic contractions against a constant resistance, while the muscle length continuously changes (43). Active exercises increase muscle strength and wrist flexibility (31).

When the wrist is healed, active exercises against resistance can help further increase the muscle strength (Figure 7-9). Resistance should not be applied too early in the rehabilitation, when it can cause harm.

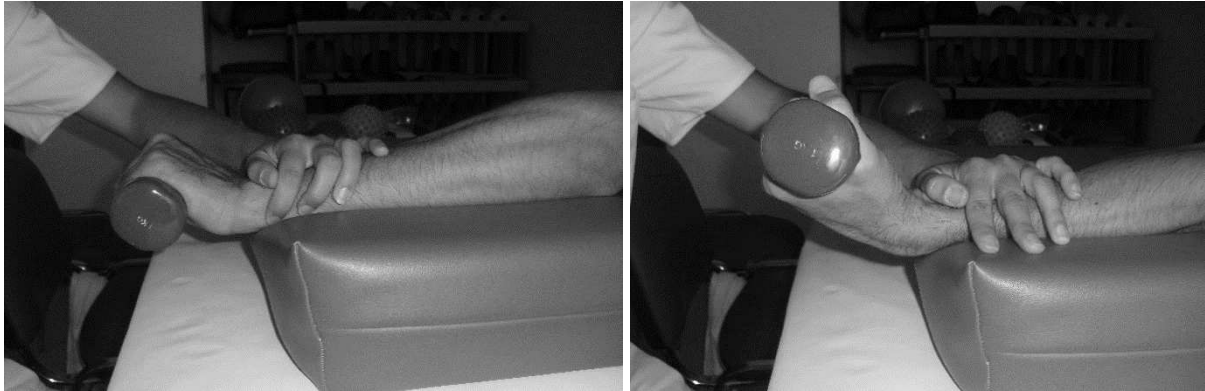


Figure 7. Active exercises against resistance A. Wrist extension B. Wrist flexion
(Pictures obtained with courtesy of Tihana Grgurević, Bacc. Physioth.)

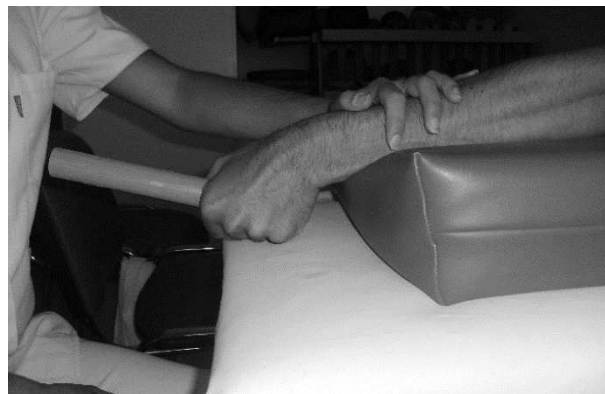

Figure 8. Active radial deviation against resistance
(Pictures obtained with courtesy of Tihana Grgurević, Bacc. Physioth.)

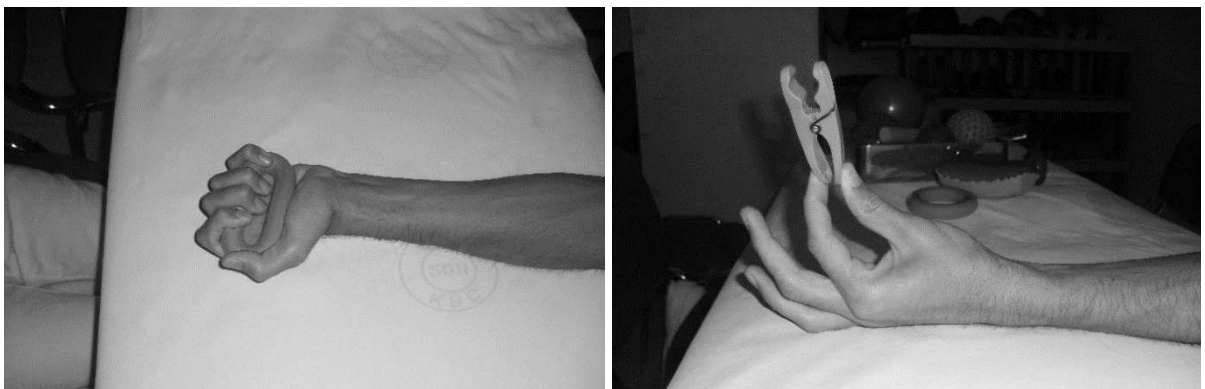

Figure 9. Strengthening exercises for finger flexors against resistance
(Pictures obtained with courtesy of Tihana Grgurević, Bacc. Physioth.)

1.11.4. Cryotherapy

Cryotherapy is the use of cold in rehabilitation of injuries. Coldness affects the local vessel and nerve endings, causing vasoconstriction, increased threshold of nociceptive excitability, and decreased muscular spasm and spasticity (43). Cold is usually applied during the first 24 to 48 hours following an injury to decrease inflammation and pain (43). Vasoconstriction can control bleeding and prevent or reduce edema from trauma and inflammation. Pain relief is accomplished by the increased threshold of nociceptive excitability and the decreased muscular spasticity. Cold can be applied by ice packs, ice whirlpool, ice massage, and vasocoolant sprays (43).

Ice massage is commonly used during rehabilitation. The injured area is massaged with an ice cube using circular motions for about 5 minutes or until analgesia is accomplished. The temperature stays above 15°C, so there is no danger of frostbite (31).

Cryotherapy can be used immediately after fracturing the distal radius, or to treat limitations of ROM secondary to pain (43).

1.11.5. Magnetotherapy

Magnetotherapy is the use of electromagnetic fields (EMFs) mainly for the management of pain, through effects on a cellular level (44). However, there is also clinical evidence that it can be used to stimulate bone and wound healing, and decrease edema (44). There are several EMF devices, the newest being the Super inductive system launched by BTL in 2017.

The Super inductive system is not yet in use in Split, but its implementation at the University Hospital is planned. The new system is based on high intensity electromagnetic fields, which are supposed to enhance blood circulation and subsequently callus formation and fracture healing. The system can also be used in the treatment of known possible complications of DRFs, such as compartment syndrome.

1.11.6. Education

Every patient that has sustained a Colles' fracture should be advised and educated about home exercises and rehabilitation techniques. Education involves the patient in the recovery process, increases awareness of what they can accomplish and clarifies the goals of the exercises. Patients should be educated about ice massage for pain management at home, and ROM exercises (Figure 10) to enable independent improvement of recovery (31).

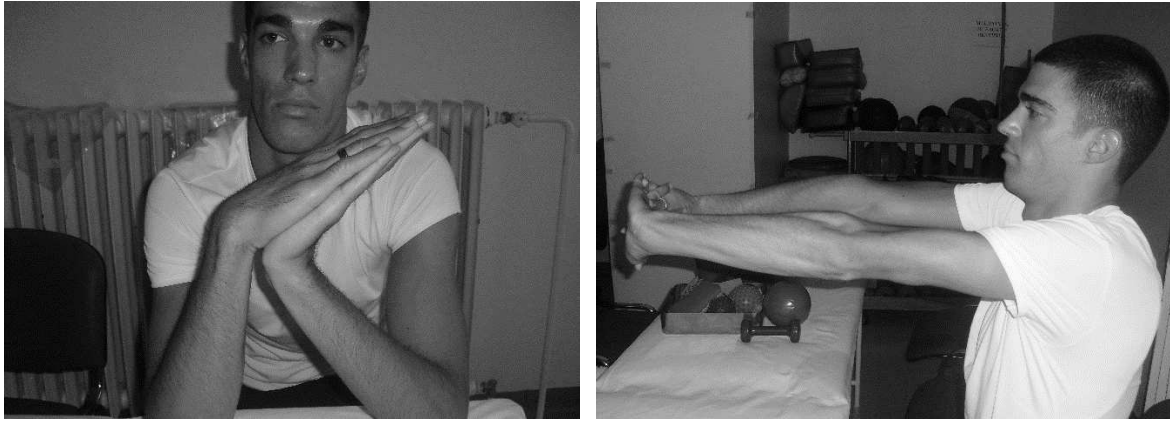

Figure 10. ROM exercises performed independently
(Pictures obtained with courtesy of Tihana Grgurević, Bacc. Physioth.)

1.12. Outcomes and Complications

Colles' fracture healing is not always predictable and can result in less than perfect recovery regardless of treatment method and rehabilitation. The overall incidence of DRF complications varies from 6% to as much as 80% depending on the definition of complication (45,46). Complications occur for many reasons, some are more associated with certain treatment methods and should be prevented or recognized early and managed on time. Patient factors affect the outcome and likelihood for complications. Patient's gender, age, comorbidities and previous functional status should therefore be taken into consideration when choosing treatment method and rehabilitation (46).

1.12.1. Outcome measures

The outcomes measured after DRF can be divided into different categories, the main ones being functional and clinical outcomes. Functional outcomes include impairment, ROM, pain, grip strength, and patient self-assessments (47). Clinical outcomes include soft tissue swelling and early and late complications (47). Other measures of outcomes worth mentioning are malunion, cosmetic appearance (deformity), and patient satisfaction.

The achieved outcomes that are less than 100% normal function but do not attribute to a specific diagnosis are not classified as complications (45).

Clinical and functional outcomes should be evaluated during every patient follow-up after a distal radius fracture, for early detection and management. Post-immobilization there is commonly a reduced grip strength, limited ROM, and pain (47). At the time of cast removal, and during the course of follow-up, patients should have standard radiologic imaging performed to evaluate bone healing and malalignment (48).

Wrist pain is assessed by a physician according to the Visual Analog Scale, while Self-assessment by patients is commonly done by the Quick-DASH (Disability of the Arm, Shoulder and Hand, Figure 11) and the Patient-Rated Wrist Evaluation questionnaires (48).

QuickDASH

Please rate your ability to do the following activities in the last week by circling the number below the appropriate response.

	NO DIFFICULTY	MILD DIFFICULTY	MODERATE DIFFICULTY	SEVERE DIFFICULTY	UNABLE
1. Open a tight or new jar.	1	2	3	4	5
2. Do heavy household chores (e.g., wash walls, floors).	1	2	3	4	5
3. Carry a shopping bag or briefcase.	1	2	3	4	5
4. Wash your back.	1	2	3	4	5
5. Use a knife to cut food.	1	2	3	4	5
6. Recreational activities in which you take some force or impact through your arm, shoulder or hand (e.g., golf, hammering, tennis, etc.).	1	2	3	4	5

	NOT AT ALL	SLIGHTLY	MODERATELY	QUITE A BIT	EXTREMELY
7. During the past week, <i>to what extent</i> has your arm, shoulder or hand problem interfered with your normal social activities with family, friends, neighbours or groups?	1	2	3	4	5

	NOT LIMITED AT ALL	SLIGHTLY LIMITED	MODERATELY LIMITED	VERY LIMITED	UNABLE
8. During the past week, were you limited in your work or other regular daily activities as a result of your arm, shoulder or hand problem?	1	2	3	4	5

Please rate the severity of the following symptoms in the last week. (*circle number*)

	NONE	MILD	MODERATE	SEVERE	EXTREME
9. Arm, shoulder or hand pain.	1	2	3	4	5
10. Tingling (pins and needles) in your arm, shoulder or hand.	1	2	3	4	5

	NO DIFFICULTY	MILD DIFFICULTY	MODERATE DIFFICULTY	SEVERE DIFFICULTY	SO MUCH DIFFICULTY THAT I CAN'T SLEEP
11. During the past week, how much difficulty have you had sleeping because of the pain in your arm, shoulder or hand? (<i>circle number</i>)	1	2	3	4	5

QuickDASH DISABILITY/SYMPTOM SCORE = $\left(\left[\frac{\text{sum of } n \text{ responses}}{n} \right] - 1 \right) \times 25$, where n is equal to the number of completed responses.

A QuickDASH score may not be calculated if there is greater than 1 missing item.

Figure 11. Quick-DASH questionnaire (49)

1.12.1.1. Manual muscle testing

Muscle testing is an important evaluation tool for objective assessment of impairments and deficits in muscle performance (strength and power) (50). It is a practical method to manually measure muscle strength and is used to guide rehabilitation (31). It is routinely done at the beginning of physical therapy (initial state), during treatment (transitional state), and at conclusion of treatment (final state) (31).

MMT can be graded 0 to 5 according to the Oxford scale: 0. No muscle contraction; 1. Flicker of movement; 2. Full ROM with gravity counterbalanced ; 3. Full ROM against gravity; 4. Full ROM against some resistance; 5. Full ROM against strong resistance (50).

1.12.2. Complications

Colles' fracture complications occur frequently (45). The reasons for the occurrence of these complications vary depending on the severity, comminution and treatment method of the fracture as well as patient characteristics like blood circulation and bone quality (46).

Complications can be divided into physician-reported and patient-reported. Patient-reported complications can be associated with surgical fracture treatment, resulting in non-diagnostic complaints of loose pins that require second surgery or pins cutting through skin (45). The most common complaints after conservative treatment are deformity, pain, or stiffness (45). The most common physician-reported complication is median nerve pathology (45).

Deformity can be a result of displacement that is inadequately repositioned or secondarily displaced. The resulting deformity will be characterized by dorsal angulation, limited supination, and a weak grip (8).

A common complication of long-term immobilization is muscle atrophy. Any prolonged inactivity leads to some degree of muscle and soft tissue atrophy. Rehabilitation, especially active exercises, is paramount for prevention and reversal of atrophy.

1.12.2.1. Disrupted bone healing

Healing is classified as delayed if the healing time exceeds twice the expected time (4 to 6 months) (26). The primary causes of delayed healing are inadequate immobilization, impaired fracture perfusion, and infection (26). Delayed fracture healing can lead to pseudarthrosis.

Pseudarthrosis refers to non-union at the fracture site after 6 to 8 weeks (26). Non-union can be caused by inadequate immobilization, soft tissues interposed in the fracture gap, extensive loss of bone, inadequate blood supply, and infection (26). There are three types of

pseudarthrosis: hypertrophic form, atrophic form, and defect with pseudarthrosis (26). The treatment depends on the cause and type of non-union, in most cases treatment is a long-lasting process.

The most common complication after a distal radius fracture is malunion (46). Malunion occurs when a fracture heals with improper alignment, articular incongruity, loss of length, or a combination of these factors (46). A common cause of malunion is conservative treatment (46). Surgical correction should be considered for all patients with confirmed malunions.

1.12.2.2. Complex regional pain syndrome

Complex regional pain syndrome (CRPS) is an autonomic dysfunction that can occur after both conservative and surgical treatments of Colles' fractures (46). There is no definitive cause nor treatment for the syndrome, however there are some associated factors. For conservatively treated fractures there was found a correlation between CRPS risk and pressure under the cast (46). For post-surgical fractures excessive distraction can increase the risk of CRPS development (46).

There are two types of CRPS, type 1 was formerly known as reflex sympathetic dystrophy (RSD), and type 2 (46). Type 1 CRPS is characterized by chronic pain without identifiable nerve injury, while type 2 CRPS is characterized by nerve involvement (46).

If diagnosed early and treated promptly the recovery rate of CRPS is good. However, diagnosis can be difficult due to the lack of standardized diagnostic criteria (46). A multimodal approach with combined psychiatric therapy, physical therapy, and pain management has proven most effective (46).

2. OBJECTIVES

There were three main aims of this study:

1. Determine the frequency of Colles' fractures treated at the University Hospital of Split through the duration of one calendar year (2016.);
2. Determine the prevalence of conservative and surgical treatment techniques of Colles' fracture;
3. Determine the prevalence of patients undergoing rehabilitation after Colles' fracture surgical treatment.

The frequency of Colles' fractures was assessed according to gender, dexterity, age groups and seasons.

3. SUBJECTS AND METHODS

3.1. Data collection

For this one-year retrospective study conducted at the University Hospital of Split, data for the whole calendar year of 2016. was collected from the Surgical Emergency Department's paper patient database. The data pertaining to the rehabilitation of the included patients was collected from the Institute of Physical Medicine and Rehabilitation with Rheumatology's electronic patient database.

3.1.1. Inclusion criteria

All distal radius fractures that were registered with the Emergency Surgical department were included, with name, date, age, gender, citizenship, first treatment and checkups if any. This includes diagnoses described as: *fractura radii in loco typico*, *fractura radii in zona typica*, *fractura radii partis distalis* and *fractura processus styloidei radii*.

For the purpose of statistical analysis, the patients were grouped by age in different categories, depending on gender. Women were grouped into four categories: 1. Below the age of 40 (idiopathic fractures); 2. 50 to 55 years (pre-menopausal fractures); 3. 56 to 70 years (post-menopausal fractures); 4. 71 years and above (senile fractures). Men were grouped into three categories: 1. Below 40 years (idiopathic fractures); 2. 40 to 60 years; 3. 61 years and above (senile fractures).

The seasonal fracture incidence was grouped according to the National Geographic Society's four seasons: 1. Winter (21.12 – 20.03); 2. Spring (21.03 – 20.06); 3. Summer (21.06 – 20.09); 4. Autumn (21.09 – 20.12) (51).

The patients were cross-referenced with the database from the Institute of Physical Medicine and Rehabilitation with Rheumatology at location Križine, Firule, and Toplice. The rehabilitation treatment records from both calendar years 2016. and 2017. were included. Data about first visit, type of therapy, as well as number of therapy sessions and checkups were noted.

In the electronic database type of therapy was coded according to the Croatian Health Insurance Fund, as individual therapy (FT006) lasting for 45 minutes, or small group therapy (FT007, FT008) lasting for 30 and 20 minutes respectively. All three codes include cryotherapy and electrotherapy modalities. The usual duration of one therapy cycle is 10 days at the University Hospital of Split. ROM evaluation codes (FT024, FT025) were also recorded.

3.1.2. Exclusion criteria

Patient entries not specifying dexterity of the Colles' fracture (right/left/bilateral) were disregarded. Patients with suspected fracture, without later confirmed fracture, were excluded. Foreign citizens were also disregarded, given the difficulty to ascertain their follow-up treatment in their respective countries. Also, those who attained their fractures before 01.01.16 but returned for checkups in 2016. were excluded. Patients under age 18 were not included in the study.

3.3. Statistical analysis

Statistical analyses were performed using the statistical software MedCalc for Windows, version 18.5 (MedCalc Software, Ostend, Belgium). Chi-square tests were performed with P value <0.05 as statistically significant.

4. RESULTS

4.1. Surgical Emergency Data

During the calendar year of 2016, a total of 888 adults visited the Surgical Emergency Department at University Hospital of Split with or due to suspicion of distal radius fracture. After applying the exclusion criteria, 717 patients remained relevant for this study.

Of the 171 patients that were excluded 19 patients had previously acquired DRFs (before 01.01.16), 13 were suspected fractures lacking confirmatory diagnosis, 5 lacked information about dexterity of the fracture, and 134 were foreign citizens from 26 different countries. The most common countries being Germany and UK with 27.6% (37/134) and 14.2% (19/134) of the foreigners respectively. Due to the low number of patients with bilateral fractures (5 female, 3 male), they were additionally disregarded (Figure 12).

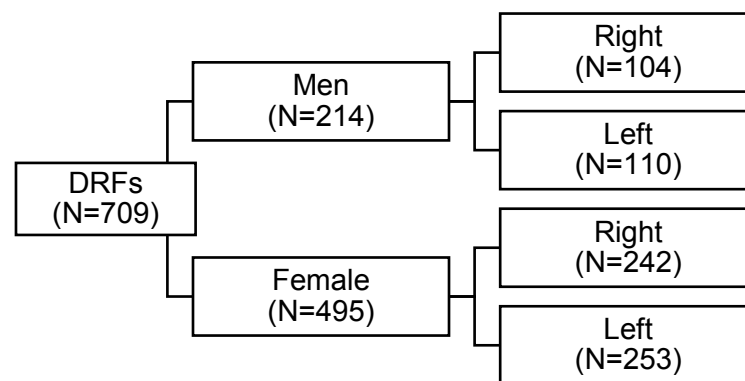


Figure 12. Patients included in study
Data are presented as absolute numbers (N)

The incidence of DRF was higher in women during 2016, than in men, accounting for 69.8% (495/709) (Figure 12). There was no significant difference between dexterity of the fractures in either gender.

The distribution of DRFs according to age groups can be seen in Table 2. DRFs occurring in men above the age of 60 are considered senile fractures, and in women fractures above the age of 70. In both genders non-senile fractures were more common (Table 2), being mostly represented in post-menopausal women (217/709) between the ages of 56 and 70.

The difference between the post-menopausal and senile incidence was not statistically significant, neither was the incidence between the middle-aged male group (40 to 60 years) and the senile group (Table 2).

As seen in Table 2 distal radius fractures without concomitant styloid fracture were more common in both genders. In women the incidence of concomitant styloid fracture was close to double with the fracture of the left radius in comparison to the right (53 versus 27 fractures respectively).

There was no season that had a remarkably higher incidence of fractures (Table 2).

Table 2. Demographic Patient data

	Female (N)		Men (N)	
Age				
	<40 years	17	<40 years	46
	40–55 years	63	40–60 years	77
	56–70 years	217	≥61 years	91
	≥71 years	198		
Diagnosis				
	Left DRF	200	Left DRF	92
	Left DRF with styloid fracture	53	Left DRF with styloid fracture	18
	Right DRF	215	Right DRF	93
	Right DRF with styloid fracture	27	Right DRF with styloid fracture	11
Season*				
	Winter	110	Winter	49
	Spring	119	Spring	63
	Summer	146	Summer	63
	Autumn	120	Autumn	39

Data are presented as absolute numbers (N)

* Grouped according to the National Geographic Society (51)

More than 95% of all fractures (F 485/495, M 207/214) were radiographically evaluated (Table 3). A high number of DRFs obtained by men (61.2%, 131/214) were not repositioned at any point during their treatment. In contrast to fractures in women, that were repositioned under local anesthesia in 58.2% of the cases (288/495). The majority of all fractures were immobilized, mostly as part of conservative treatment but also in the cases of surgical treatment (44/709) (Table 3).

Table 3. DRF Treatment

		Female (N)	Men (N)
X-ray imaging			
	No	10	7
	Yes	485	207
Reposition			
	No	196	131
	Yes	288	79
	Operative*	10	3
	Patient refusal	1	1
Immobilization			
	No	34	13
	Yes	456	199
	Above elbow	4	1
	Patient refusal	1	1
Surgery			
	No	468	194
	Yes	13	12
	Delayed	12	7
	Patient refusal	2	1

Data are presented as absolute numbers (N)

* Under operative anesthesia

After the initial visit to the emergency department, 21% (149/709) returned to the Emergency Department for follow-up. Of these, 64 patients (51 female, 13 men) needed correction of their immobilization, and 35 (31 female, 4 men) required repositioning during their follow-up.

4.2. Rehabilitation Data

All patients included in the study were cross-referenced with the records from the Institute of Physical Medicine and Rehabilitation with Rheumatology at University Hospital of Split from 2016. and 2017. In total 218 (30.7%) patients that attained a Colles' fracture in 2016. went to a primary visit after cast removal to one of the locations of the Institute of Physical Medicine and Rehabilitation with Rheumatology (Figure 13).

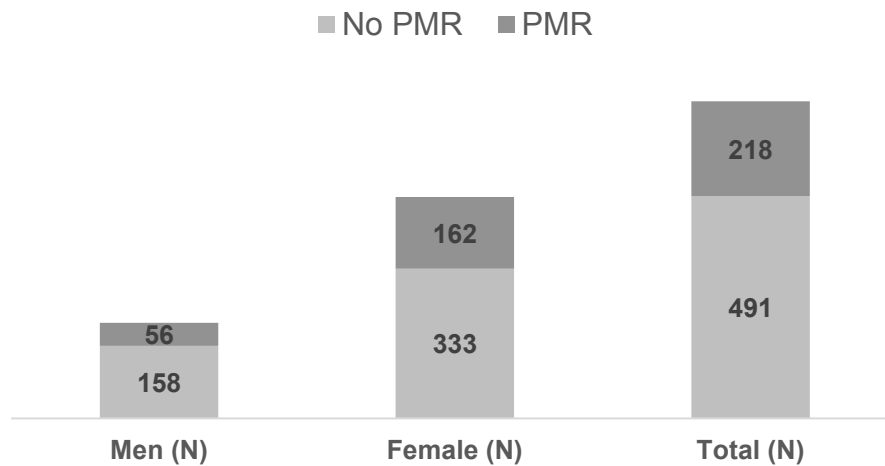


Figure 13. Number of patients that made a visit to the Institute of Physical Medicine and Rehabilitation with Rheumatology at University Hospital of Split
Data are presented as absolute numbers (N)

Initially 26.2% (56/214) of men that suffered DRFs went to a physical rehabilitation consultation, compared to 32.7% (162/495) of women (Figure 13).

The records showed that 172 patients (124 female, 48 men) began with an individual exercise protocol with a physical therapist. 6 women received only treatment in small groups. There was missing information about the protocol applied to 4 patients. The remaining 36 patients either only went to a primary check-up without initiating any rehabilitation protocol, or it was not recorded.

Of the patients that received physical therapy, majority received one to three therapy cycles (170/182) during the duration of their rehabilitation. The number of patients that underwent prior- and post-therapy ROM evaluation was 41.

5. DISCUSSION

According to data from the Croatian Institute of Public Health from 2014., injuries are the third most common cause of mortality (52). Injuries also rank as 6th cause of hospitalization in Croatia (52). Distal radius fractures are one of the most common fractures, making it a significant public health problem (1,19). According to a study performed in 2014., the incidence of DRFs for the population of Split is 20.23 per 10000 people–year (53).

The treatment and rehabilitation of DRFs continues to present many challenges, and the incidence throughout the world continues to increase as the population with increased life expectancy grows (32,48,54).

Bone composition and its mechanical properties vary as a function of age (55). The process of bone loss and gradual decrease of bone density begins in both genders around the age of 40, slowly increasing the risk of fractures over time (19). The relative weaker bones in women leads to a peak of DRFs in post-menopause, associated with the diminished estrogen levels (11). This expected peak can be seen in the post-menopausal female patients included in our study (Table 2).

The most common fracture mechanisms in non-senile adults are high energy injuries, e.g. motor vehicle accidents, sports activities and falls from greater heights (2,8). Except for the post-menopausal population, the incidence in non-senile women is significantly lower than in the senile/elderly population (1,56). The number of DRFs was higher in men under the age of 60 (non-senile), than in the senile group (123 under age 60, 91 aged 60 or above) in our study (Table 2). The male fracture distribution may be connected to the number of motor vehicle accidents, or the surge in sports related activities (1).

Literature associates DRFs in the elderly with osteoporosis and osteopenia (1,32). A distal radius fracture in an active elderly can be the first symptom of underlying osteoporosis (1,54). Meta-analyses prove the connection between sustaining a DRFs (at the age of 45 or older) and future fractures (54). A DRF doubles the risk of having a new fracture for women and triples it for men (37).

The most common mechanism of fracture is fall on an outstretched hand in the elderly, especially women with decreased bone density (1). Studies have shown that as much as 85% of elderly women who suffer a Colles' fracture may have low bone mineral density (BMD) (37). Lower BMD is associated with more severe, intra-articular fractures (1). Despite the proven association between DRF and osteoporosis, osteoporotic screening is not a part of clinical DRF treatment practice (54).

Some known risk factors for osteoporosis are: calcium deficiency, vitamin D deficiency, smoking, female gender, and alcohol consumption (8,19). Vitamin D deficiency plays a unique role in fracture mechanism of the elderly. A minimum concentration of 50 nmol/L of activated vitamin D (25(OH)D) is necessary to prevent bone demineralization (57). Despite the Mediterranean climate, it has been established that Croatia has a high prevalence of vitamin D deficiency in post-menopausal women (57). Close to three-fourths of post-menopausal women in Croatia have vitamin D concentrations <50 nmol/L (57). Low vitamin D may also lead to atrophy of type II muscle fibers (fast acting fibers), which are responsible for the “reach-out” to break a fall reflex (57). Decreased “reach-out” reflex may also be caused by dementia (1). Regardless of cause, decreased reflexes increase the risk of falling onto the side causing proximal humerus or hip fracture (1,32). Although DRFs are rarely lethal, hip fractures have a significant mortality rate (58).

A simple intervention that can prevent the development of osteoporosis, or prevent the occurrence of DRF or repeat fractures, is vitamin D supplementation (57). The high number of DRFs amongst post-menopausal women and middle-aged men in Split (Table 2) may perhaps be attributed to a decreased BMD from vitamin D deficiency. DRFs can also serve as a screening tool to identify patients with increased risk for subsequent DRFs or more debilitating fractures (32). There are grounds to recommend bone density measurement and osteoporosis screening of all patients above 50 that sustained a DRF (32,37).

The University Hospital of Split could benefit of evaluating every DRF as a possible first symptom of osteopenia and monitor vitamin D levels more frequently in both women and men.

A very low number of patient refusals of immobilization and surgical treatment were registered in the Surgical Emergency database (Table 3). The unlikely low number could be contributed to incomplete documentation, or perhaps good education and information of patients by the physicians. It is unclear whether the high number of fractures not operated (662/709, 93.4%) was because surgery was not indicated or could include patient refusals as well. Regardless of reason, majority of Colles’ fractures during 2016. were conservatively treated at University Hospital of Split (Table 3).

Despite the common impression that the frequency of DRFs is higher during the winter season, in our study no significant seasonal differences were shown (32). Perhaps the lack of increase during winter can be attributed to the Mediterranean climate in Split, with mild winter periods characterized by rare snow and ice incidence. If we include foreign citizens, the number of fractures in Summer would be increased by 82, making it the most dominant season (291/843). However, it is not clear if this is a true increase or dependent on the increase of residents in Split during the summer period.

There are numerous medical offices in and around Split that offer physical therapy, therefore a greater number of patients may have received physical therapy post-fracture than the 30.7% (218/709) that went to the Institute of Physical Medicine and Rehabilitation with Rheumatology at University Hospital of Split.

Although it is common practice to recommend rehabilitation after a distal radius fracture, no long-term differences have been proven between patients with uncomplicated fractures who perform home exercises and those who receive rehabilitation by a physical therapist (29,37). Immediate rehabilitation after cast removal can improve wrist ROM in the short term, but it does not lead to better long-term results (37,42). However, physiotherapy may cause a significant increase in wrist extension and grip strength making everyday tasks easier to perform earlier (41).

At the University Hospital of Split the physical therapy session duration depends on whether it's an individual or small group treatment. An individual therapy session (one patient, one physical therapist) lasts 45 min, while small group therapy session lasts 20 to 30 min. The rehabilitation is initiated after cast removal and the average duration of one cycle of therapy consists of 10 sessions.

The continuous increase of the DRF incidence causes an increase in the health care spending on fracture treatment and rehabilitation (56). Cost-effective choices of treatment and rehabilitation is therefore becoming more and more important (56). A possible area of cost reduction in Split could be reducing the number of patients receiving individual rehabilitation therapy, seen as there is a lack of scientifically proven benefit of individual therapy over small group therapy or home exercises (37). Over half of the patients that received physical therapy at University Hospital of Split received 2 or 3 cycles of individual physical therapy (95/180, 52.2% of patients). The high number of individual therapy sessions may contribute to an unnecessary high cost of DRF rehabilitation. Only 41 patients underwent ROM evaluation during their rehabilitation, an increase of evaluations could lower the number of unnecessary treatment cycles.

The significant costs resulting from DRFs make it important to apply preventive measures to individuals who are at high risk of suffering DRF as well as optimizing treatment protocols (1).

Some selection bias may be present in the study due to its retrospective nature. Data regarding follow-up is limited due to the lack of accessibility to the patient database of the Department of Orthopedics and Traumatology.

The place of residence as well as number of private physical therapists in and around Split may affect the number of patient rehabilitation records available from the University Hospital of Split. The study is also sensitive to incomplete documentation or human error, given the lack of digital record keeping.

6. CONCLUSIONS

1. In Split, 709 (843 including foreign citizens) patients visited the University Hospital of Split during 2016. with Colles' fractures, being mostly women (495/709). The greatest peak was in post-menopausal women (217/495). In men the majority that suffered DRFs were above 40 years old, without a great difference between the middle-aged (40–60 years) and senile (60 years and older) group.
2. Majority of patients were treated conservatively, with repositioning and/or immobilization. Of the total number of patients 44 underwent surgical treatment, either immediately or delayed. There was no significant difference in the frequency according to dexterity or season.
3. Post-fracture rehabilitation plays a big role in the recovery of full function in most cases of Colles' fractures. 30.7% (218/709) of the patients from 2016. received physical therapy at the University Hospital of Split. These numbers may be strongly affected by the number of physical therapy health facilities in and around Split. 95 of the patients that went to rehabilitation received 2 or 3 physical therapy cycles (95/180, 52.2%).
4. The lack of treatment and rehabilitation guidelines in Croatia may be causing unnecessary costs that could be limited by treatment optimization by creating clinical guidelines.

7. REFERENCES

1. Nellans KW, Kowalski E, Chung KC. The epidemiology of distal radius fractures. *Hand Clin.* 2012;28(2):113-25.
2. Porrino JA, Jr., Maloney E, Scherer K, Mulcahy H, Ha AS, Allan C. Fracture of the distal radius: epidemiology and premanagement radiographic characterization. *Am J Roentgenol.* 2014;203(3):551-9.
3. Medscape.com [Internet]. New York;; Distal Radius Fractures [updated 2016 May 6; cited 2017 October 10]. Available from: <https://emedicine.medscape.com/article/1245884>.
4. Wilson AJ. Radiology of Hand and Wrist Injuries. In: Hodler J, Von Schulthess GK, Zollikofer CL, editors. *Musculoskeletal Diseases, Diagnostic Imaging and Interventional Techniques.* 37th ed: Springer; 2005. p. 13-55.
5. Bohndorf K, Imhof H, Pope TLJ. Distal Forearm Fractures. In: *Musculoskeletal Imaging: A concise Multimodality Approach.*: Thieme; p. 84-8.
6. Rueger JM, Hartel MJ, Ruecker AH, Hoffmann M. [Fractures of the distal radius]. *Unfallchirurg.* 2014;117(11):1025-34.
7. Meena S, Sharma P, Sambharia AK, Dawar A. Fractures of distal radius: an overview. *J Family Med Prim Care.* 2014;3(4):325-32.
8. OrthopaedicsOne.com [Internet]. Toronto: OrthopaedicsOne - The Orthopaedic Knowledge Network; Distal radius (Colles) fractures [updated 2014 December 14; cited 2017 October 22] Available from: <http://www.orthopaedicsone.com/x/XYGTB>.
9. Mauck BM, Swigler CW. Evidence-Based Review of Distal Radius Fractures. *Orthop Clin North Am.* 2018;49(2):211-22.
10. Moore KL, Agur AMR, Dalley AF. *Essential Clinical Anatomy.* 4th ed.: Lippincott Williams and Wilkins; 2010.
11. Manaster BJ, May DA, Disler DG. Wrist. In: *Musculoskeletal Imaging, The Requisites in Radiology.* Philadelphia: Mosby Elsevier; 2007. p. 134-58.
12. Safadi FF, Khurana JS. Bone Structure and Function. In: Bonakdarpour A, Reinus WR, Khurana JS, editors. *Diagnostic Imaging of Musculoskeletal Diseases: A systematic Approach.* New York: Springer; 2010. p. 1-14.
13. BoneAndSpine.com [Internet]. New Delhi;; Radius Bone Anatomy [updated; cited 2018 February 8]. Available from: <http://boneandspine.com/anatomy-of-radius-bone/>.
14. Medscape.com [Internet]. New York;; Wrist Joint Anatomy [updated 2013 June 11; cited 2018 February 2]. Available from: <https://emedicine.medscape.com/article/1899456-overview>.

15. Murray JRD, Holmes EJ, Misra RR. Radius fracture - distal radial fractures. In: A–Z of Musculoskeletal and Trauma Radiology. Cambridge: Cambridge University Press; 2008. p. 266-71.
16. Vanderhave KL. Distal Radius Fracture. In: Doherty GM, editor. Surgery Current Diagnosis and Treatment.: McGraw-Hill; 2015. p. 1083-5.
17. Johnson KJ, Bache E. Imaging in Pediatric Skeletal Trauma In: Leuven BAL, Göttingen KM, Heidelberg SK, editors.: Springer; 2008. p. 122.
18. Johnson KJ, Bache E. Imaging in Pediatric Skeletal Trauma. In: Leuven BAL, Göttingen KM, Heidelberg SK, editors.: Springer; 2008. p. 295-9.
19. Bonakdarpour A. Systematic Approach to Metabolic Diseases of Bone. In: Bonakdarpour A, Reinus WR, Khurana JS, editors. Diagnostic Imaging of Musculoskeletal Diseases: A systematic Approach. New York: Springer; 2010. p. 15-60.
20. Medscape.com [Internet]. New York:; Wrist Fracture in Emergency Medicine [updated 2018 April 4; cited 2018 June 22]. Available from: <https://emedicine.medscape.com/article/828746-overview>.
21. MerckManuals.com [Internet]. New Jersey: Merck & Co., Inc.; Distal Radius Fractures (Wrist Fractures; Colles Fractures; Smith Fractures) [updated 2017 August; cited 2017 October 19]. Available from: <https://www.merckmanuals.com/professional/injuries-poisoning/fractures/distal-radius-fractures>.
22. Shehovych A, Salar O, Meyer C, Ford D. Adult distal radius fractures classification systems: essential clinical knowledge or abstract memory testing? *Ann R Coll Surg Engl.* 2016;98:525-31.
23. Kleinlugtenbelt YV, Groen SR, Ham SJ, Kloen P, Haverlag R, Simons MP, et al. Classification systems for distal radius fractures: Does the reliability improve using additional computed tomography? *Acta Orthopaedica.* 2017;88(6):681-7.
24. Herman M, Hopkins H, Stursky DJ. Fractures and Injuries of the Distal Radius and Carpus. 1st ed.: Elsevier; 2009.
25. Bigham-Sadegh A, Oryan A. Basic concepts regarding fracture healing and the current options and future directions in managing bone fractures. *Int Wound J.* 2015;12(3):238-47.
26. Bohndorf K, Imhof H, Pope TLJ. Fracture Healing. In: Musculoskeletal Imaging: A concise Multimodality Approach.: Thieme; p. 24-6.
27. Freeland AE, Luber KT. Biomechanics and biology of plate fixation of distal radius fractures. *Hand Clin.* 2005;21(3):329-39.

28. Handoll HHG, Madhok R. Conservative interventions for treating distal radial fractures in adults. *CDSR*. 2003. doi: 10.1002/14651858.CD000314.
29. Eltorai AEM, Sobel AD, Thomas NP Jr., Daniels AH, Born CT. Current Trends in the Management of Distal Radius Fractures. *Orthopedics*. 2017;40(3):145-52.
30. Sundhetskysrelsen.dk [Internet]. Copenhagen: Danish Health Authority; National clinical guideline on the treatment of distal radial fractures [updated 2016 January 18; cited 2017 December 17]. Available from: <https://www.sst.dk/en/publications/2014/ngc-distal-radius-fractures>.
31. Grgurevic T. Fizioterapijski postupci kod prijeloma palcane kosti na tipicnom mjestu [dissertation]. Split: Sveučilište u Splitu; 2013.
32. Levin LS, Rozell JC, Pulos N. Distal Radius Fractures in the Elderly. *J Am Acad Orthop Surg*. 2017;25(3):179-87.
33. Manaster BJ, May DA, Disler DG. Introduction to Imaging of Musculoskeletal Injury: Bones. In: *Musculoskeletal Imaging, The Requisites in Radiology*. Philadelphia: Mosby Elsevier; 2007. p. 3-25.
34. Ring D, Burchill G, Callamaro DR, Jupiter JB. Fracture of the Distal Radius. In: Brotzman BS, Wilk KE, editors. *Clinical Orthopaedic Rehabilitation*. Philadelphia: Mosby, Inc.; 2003. p. 55-67.
35. Costa ML, Achten J, Parsons NR, Rangan A, Griffin D, Tubeuf S, et al. Percutaneous fixation with Kirschner wires versus volar locking plate fixation in adults with dorsally displaced fracture of distal radius: randomised controlled trial. *Bmj*. 2014. doi: 10.1136/bmj.g4807.
36. Chaudhry H, Kleinlugtenbelt YV, Mundi R, Ristevski B, Goslings JC, Bhandari M. Are Volar Locking Plates Superior to Percutaneous K-wires for Distal Radius Fractures? A Meta-analysis. *Clin Orthop Relat Res*. 2015;473(9):3017-27.
37. Loisel F, Bourgeois M, Rondot T, Nallet J, Boeckstins M, Rochet S, et al. Treatment goals for distal radius fractures in 2018: recommendations and practical advice. *Eur J Orthop Surg Traumatol*. 2018. doi: 10.1007/s00590-018-2196-9.
38. Zong SL, Kan SL, Su LX, Wang B. Meta-analysis for dorsally displaced distal radius fracture fixation: volar locking plate versus percutaneous Kirschner wires. *J Orthop Surg Res*. 2015;10:108.
39. Rhee PC, Medoff RJ, Shin AY. Complex Distal Radius Fractures: An Anatomic Algorithm for Surgical Management. *J Am Acad Orthop Surg*. 2017;25(2):77-88.

40. Omicsonline.org [Internet]. Norway; Norwegian Orthopaedic Association - The Norwegian Medical Association; Treatment of distal radius fractures in adults. [updated 2015 July 27; cited 2018 July 5]. Available from: https://files.magicapp.org/guideline/ac10868f.../published_guideline_551-2_6.pdf.
41. Bruder AM, Taylor NF, Dodd KJ, Shields N. Physiotherapy intervention practice patterns used in rehabilitation after distal radial fracture. *J Physioth.* 2013;99(3):233-40.
42. Bruder A, Taylor NF, Dodd KJ, Shields N. Exercise reduces impairment and improves activity in people after some upper limb fractures: a systematic review. *J Physioth.* 2011;57(2):71-82.
43. Williams A. Modalities Used in Rehabilitation. In: Brotzman BS, Wilk KE, editors. *Clinical Orthopaedic Rehabilitation*. Philadelphia: Mosby, Inc.; 2003. p. 611-8.
44. Markov M. XXIst century magnetotherapy. *Electromagn Biol Med.* 2015;34(3):190-6.
45. McKay SD, MacDermid JC, Roth JH, Richards RS. Assessment of complications of distal radius fractures and development of a complication checklist. *J Hand Surg Am.* 2001;26(5):916-22.
46. Chung KC, Mathews AL. Management of Complications of Distal Radius Fractures. *Hand clinics.* 2015;31(2):205-15.
47. Handoll HHG, Elliott J. Rehabilitation for distal radial fractures in adults. *CDSR.* 2015;(9):1-30.
48. Quadlbauer S, Pezzei C, Jurkowitsch J, Kolmayr B, Keuchel T, Simon D, et al. Early rehabilitation of distal radius fractures stabilized by volar locking plate: a prospective randomized pilot study. *J Wrist Surg.* 2017;6(2):102-112.
49. DASH.iwh.on.ca [Internet]. Toronto: The Institute for Work & Health; The QuickDASH [updated 2006; cited 2018 July 5]. Available from: <http://www.dash.iwh.on.ca/download/quickdash/54191>.
50. Physiopedia.com [Internet].; Muscle Strength [updated 2017 June 6; cited 2018 July 3]. Available from: https://www.physio-pedia.com/index.php?title=Muscle_Strength&oldid=173074.
51. NationalGeographic.org [Internet]. Washington D.C.: National Geographic Society; Season [updated 2011 January 21; cited 2018 July 3]. Available from: <https://www.nationalgeographic.org/encyclopedia/season/>.
52. HZJZ.hr [Internet]. Zagreb: Hrvatski Zavod Za Javno Zdravstvo; Objavljeno Izvješće o umrlim osobama u Hrvatskoj u 2014. godini [updated 2015 July 31; cited 2018 July 5].

Available from: <https://www.hzjz.hr/periodicne-publikacije/objavljeno-izvjesce-o-umrlim-osobama-u-hrvatskoj-u-2014-godini/>.

53. Gavrilović V. Prijelomi distalnog dijela palčane kosti [dissertation]. Split: Sveučilište u Splitu; 2015.
54. MacIntyre NJ, Dewan N. Epidemiology of distal radius fractures and factors predicting risk and prognosis. *J Hand Ther.* 2016;29(2):136-45.
55. Boskey AL, Coleman R. Aging and Bone. *J Dent Res.* 2010;89(12):1333-48.
56. Jupiter J. Future Treatment and Research Directions in Distal Radius Fracture. *Hand Clin.* 2012;28(2):245-8.
57. Laktasic-Zerjavic N. Uloga vitamina D i kalcija u liječenju osteoporoze. *Reuma.* 2014;61(2):80-8.
58. Adams JE. Osteoporosis. In: Hodler J, Von Schulthess GK, Zollikofer CL, editors. *Musculoskeletal Diseases, Diagnostic Imaging and Interventional Techniques.* 37th ed: Springer; 2005. p. 89-105.

8. SUMMARY

Objectives: The purpose of this retrospective study was to establish the number, gender and age of patients that suffered a Colles' fracture during the calendar year 2016. in Split. As well as the prevalence of conservative treatment compared to surgical treatment, and the prevalence of post-fracture rehabilitation at University Hospital of Split.

Subjects and methods: Data was collected from the Surgical Emergency Department's paper database and cross-referenced to the Institute of Physical Medicine and Rehabilitation with Rheumatology's electronic database. All diagnosed adult distal radius fractures obtained during 2016. from Croatian citizens treated at the University Hospital of Split were included. Patients with bilateral fractures were excluded.

Results: In University Hospital of Split during 2016., 709 Croatian adults were treated for a distal radius fracture, 69.8% women (495/709). 43.8% of the female patients were post-menopausal (217/495). More men under the age of 60 (non-senile) were treated for distal radius fracture than men aged 60 or above (123 under 60, 91 60 and above). Radiographic imaging was performed of 97.6% of the patients (692/709, F 485/495, M 207/214), and 93.1% of fractures were immobilized (660/709). Female fractures were repositioned in 58.2% of cases (288/495), while only 38.8% of male fractures were repositioned (83/214). Only 44 patients underwent operative treatment (6.2%, 44/709). In total, 218 patients (30.7%, 218/709) visited the Institute of Physical Medicine and Rehabilitation with Rheumatology, 56 men (26.2% of all male patients, 56/214) and 162 women (32.7% of all female patients, 162/495). Of these, 172 patients received individual physical therapy, 6 only attended small group therapy, and 36 patients did not have a protocol registered. Majority of patients attended two or three physical therapy cycles (95/180, 52.2%).

Conclusions: Most fractures are sustained by post-menopausal women and middle-aged men, which may be connected to vitamin D deficiency and osteoporosis. Most fractures are treated conservatively by repositioning and/or immobilization. There is no significant difference of dexterity or seasonal occurrence. A low number of patients receive physiotherapy at the University Hospital of Split, most often consisting of individual therapy. University Hospital of Split would benefit of the development of distal radius fracture treatment and rehabilitation guidelines.

9. CROATIAN SUMMARY

Naslov: PRIJELOM DISTALNOG DIJELA PALČANE KOSTI: LIJEČENJE I REHABILITACIJU U KLINIČKOM BOLNIČKOM CENTRU SPLIT – RETROSPEKTIVNA STUDIJA

Ciljevi: Cilj ove retrospektivne studije bio je utvrditi broj, spol i dob ispitanika kojima je utvrđen prijelom distalnog dijela palčane kosti tijekom jedne kalendarske godine 2016. Također smo htjeli utvrditi učestalost konzervativnog liječenja u usporedbi s operativnim liječenjem te učestalost provođenja fizikalne terapije nakon prijeloma u Kliničkom bolničkom centru Split.

Ispitanici i metode: Za potrebe ove studije prikupljeni su podaci iz papirne baze podataka Hitnog kirurškog prijema te su uspoređeni s podacima iz elektronske baze podataka Zavoda za fizikalnu medicinu i rehabilitaciju s reumatologijom Kliničkom bolničkom centru Split. U studiju su uključeni svi punoljetni ispitanici koji su bili hrvatski građani s potvrđenom dijagnozom frakture distalnog dijela palčane kosti, a koji su liječeni u Kliničkom bolničkom centru Split tijekom 2016. Ispitanici koji su imali bilateralni prijelom distalnog dijela palčane kosti isključeni su iz studije.

Rezultati: U Kliničkom bolničkom centru Split tijekom 2016. godine, prijelom distalnog dijela palčane kosti imalo je 709 punoljetnih ispitanika koji su bili hrvatski građani, od čega je bilo 69,8% žena (495/709). Najveći postotak ispitanica bio je u postmenopauzalnoj dobi 43,8% (217/495). Među muškim ispitanicima s prijelomom distalnog dijela palčane kosti uočen je veći broj ispitanika u dobnoj skupini ispod 60 godina nego onih u dobnoj skupini iznad 60 godina (senilni prijelomi) (123 ispod 60, 91 60 i iznad). Radiografska dijagnostika učinjena je u 97,6% prijeloma (692/709, Ž 485/495, M 207/214), dok je 93,1% kirurški zbrinuto konzervativno, sadrenom imobilizacijom (660/709). Repozicija prijeloma učinjena je kod 58,2% ženskih ispitanica (288/495), dok je kod muških ispitanika repozicija prijeloma učinjena u samo 38,8% slučajeva (83/214). Samo su 44 ispitanika podvrgnuta operativnom zahvatu (6,2%, 44/709). Zavod za fizikalnu medicinu i rehabilitaciju s reumatologijom, radi pregleda fizijatra i odluke o provedbi fizikalne terapije, posjetilo je 218 ispitanika (30,7%, 218/709), 56 muškaraca (26,2% od svih M ispitanika, 56/214) i 162 žene (32,7% od svih Ž ispitanica, 162/495). Individualna fizikalna terapija provedena je kod 172 ispitanika, kod 6 ispitanika provedena je fizikalna terapija u maloj grupi, dok za 36 ispitanika provedba fizikalne terapije nije bila evidentirana u elektronskoj bazi podataka. Većina ispitanika bila je uključena u dva ili tri ciklusa fizikalne terapije (95/180, 52,2%).

Zaključci: Većina prijeloma distalnog dijela palčane kosti uočena je kod žena u postmenopauzi te muškaraca srednje životne dobi što bi moglo biti povezano s nedostatkom vitamin D i osteoporozom. Operativno liječenje prijeloma u većini slučajeva je konzervativno u vidu repozicije i/ili sadrene imobilizacije. Nije bilo značajne razlike u sezonskoj pojavnosti prijeloma kao ni zahvaćenosti desne ili lijeve ruke. U Kliničkom bolničkom centru Split mali broj ispitanika podvrgnut je fizikalnoj terapiji te se u većini slučajeva radilo o individualnoj fizikalnoj terapiji. Izrada kliničkih smjernica za liječenje i rehabilitaciju prijeloma distalnog palčane dijela kosti bila bi od iznimne važnosti za poboljšanje kvalitete rada u Kliničkom bolničkom centru Split.

10. CURRICULUM VITAE

Personal data

Name and Surname: Marina Belcovska
Date of birth: 15.10.1992
Citizenship: Norwegian, Macedonian (dual)
Address: Husjordløkka 1, 1555 Son, Norway
E-mail: marina.belco@gmail.com

Education/ Work experience

10.2013 – 07.2018 University of Split School of Medicine, Split, Croatia,
Doctor of Medicine
07.2016 – 12.2017 Aleris Kantarellen Living and Rehabilitation Centre, *Health worker*
08.2011 – 08.2013 University of Pecs Medical School, Pecs, Hungary, *Medical student*
05.2008 – 06.2010 Nordstrand Bakery, Oslo, Norway, *Shop employee*
08.2008 – 06.2011 Lambertseter High School, Oslo, Norway, *High school graduate*

Certificates/ Licenses

17.05.2018 Driver's license, Class B
14.03.2018 Emergency medicine Course, Acute Medical Group, Krakow, Poland
23.11.17 – 30.11.18 Doctor's Student License, Norwegian Directorate of Health
09.10.10 - 01.06.2011 MIFA- pilot leadership course, University of Oslo, Norway

Languages

Norwegian, English – Mother tongue Montenegrin, Macedonian, Croatian – Fluent
Spanish – Competent German – Basic

Further Engagements

1.10.2015 – 31.10.2017 ANSA Croatia, Event Manager
1.08.2015 – 31.08.2015 Professional SCOPE/IFMSA Internal Medicine Exchange
University Hospital Alexandrovska, Sofia, Bulgaria
01.17.2014 – 30.08.2014 Internship at JZU Clinic for Prevention and Rehabilitation of
Unspecific Respiratory and Allergic diseases, Oteshevo,
Republic of Macedonia
1.10.2010 – 1.10.2011 Nordstrand Young Conservatives, Oslo, Norway
Deputy Chairman