

Percutaneous internal ring suturing is a safe and effective method for inguinal hernia repair in adolescents : a single-center experience

Batinović, Tina

Master's thesis / Diplomski rad

2021

Degree Grantor / Ustanova koja je dodijelila akademski / stručni stupanj: **University of Split, School of Medicine / Sveučilište u Splitu, Medicinski fakultet**

Permanent link / Trajna poveznica: <https://um.nsk.hr/um:nbn:hr:171:330739>

Rights / Prava: [In copyright](#)/[Zaštićeno autorskim pravom.](#)

Download date / Datum preuzimanja: **2025-01-05**



Repository / Repozitorij:

[MEFST Repository](#)



**UNIVERSITY OF SPLIT
SCHOOL OF MEDICINE**

TINA BATINOVIĆ

**PERCUTANEOUS INTERNAL RING SUTURING IS A SAFE AND
EFFECTIVE METHOD FOR INGUINAL HERNIA REPAIR IN
ADOLESCENTS: A SINGLE-CENTER EXPERIENCE**

DIPLOMA THESIS

Academic year:

2020/2021

Mentor:

Assoc. Prof. Zenon Pogorelić, MD, PhD

Split, June 2021

TABLE OF CONTENTS

1. INTRODUCTION	1
1.1. ANATOMY OF THE INGUINAL REGION	2
1.2. INGUINAL HERNIA	4
1.2.1. Anatomy of the inguinal hernia	4
1.2.2. Types of inguinal hernia	5
1.2.3. Incidence	6
1.2.4. Clinical findings	7
1.2.5. Complications	8
1.2.6. Specific inguinal hernia types	9
1.2.7. Diagnostic approach	10
1.2.8. Treatment	11
1.2.9. Surgical techniques	12
2. OBJECTIVES OF RESEARCH	17
3. PATIENTS AND METHODS	19
3.1. Patients	20
3.2. Organization of the study	20
3.3. Place of the study	21
3.4. Methods of data collection and processing	21
3.5. Description of research	21
3.6. Outcome measures	22
3.7. Compliance with ethical standards	22
3.8. Surgery	22
4. RESULTS	24
5. DISCUSSION	28
6. CONCLUSION	33
7. REFERENCES	35
8. SUMMARY	39
9. SUMMARY IN CROATIAN	41
10. CURRICULUM VITAE	43

Acknowledgments

This thesis is dedicated to my father. Thank you for always believing in me, motivating me, inspiring me, and loving me. None of this would be possible without you.

Thank you to my family for your constant support and encouragement.

Finally, thank you to my mentor, Prof. Zenon Pogorelić for your enormous help with this thesis. I couldn't do it without your guidance!

ABBREVIATIONS

ASA – American Society of Anesthesiologists

ASIS – Anterior Superior Iliac Spine

BMI – Body Mass Index

IC – Inguinal Canal

IQR – Interquartile Range

PIRS – Percutaneous Internal Ring Suturing

WHO – World Health Organization

1. INTRODUCTION

1.1. ANATOMY OF THE INGUINAL REGION

The inguinal region is an anatomically complex region. The inguinal region of the body is located on the lower portion of the anterior abdominal wall, with the thigh inferiorly, the pubic tubercle medially, and the anterior superior iliac spine (ASIS) superolaterally (1). The inguinal canal is a passage in the lower anterior abdominal wall located just above the inguinal ligament. It starts from the internal inguinal orifice, extends medially and inferiorly through the abdominal wall layers and ends in the external inguinal orifice. This canal is about four to six centimeters in length. The length changes from over the growth period from the pediatric age to adulthood. It functions as a passageway for structures between the intra- and extra-abdominal structures. In males, it transmits the spermatic cord, gonadal vessels, genital branch of genitofemoral nerve, and lymphatics. While in females, it transmits the round ligament of the uterus, and the ilioinguinal nerve. The clinical significance of the area comes from the common surgical problem of inguinal hernias, and to a lesser extent, the inguinal lymphadenopathy and varicocele (2) (*Fig. 1*).

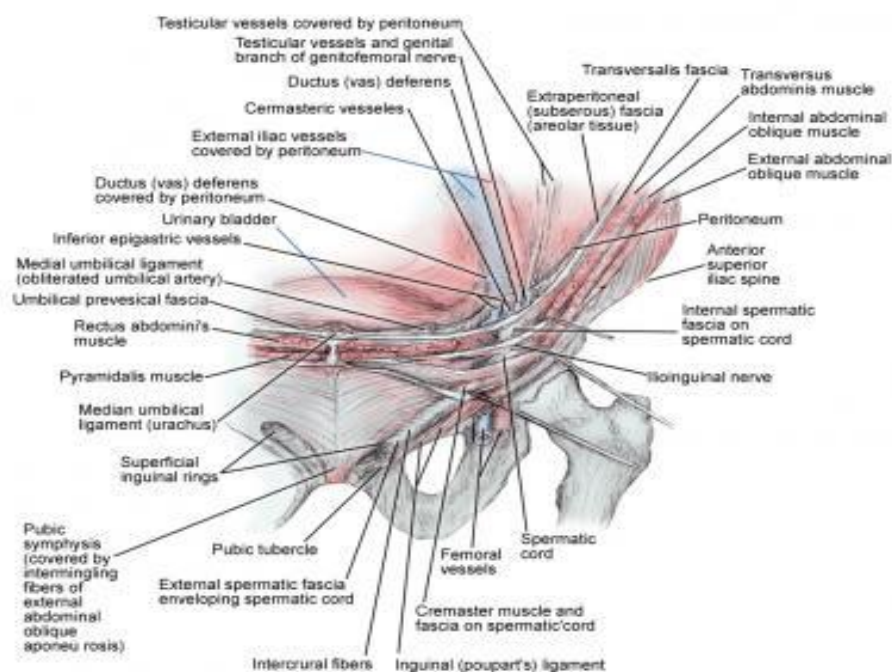


Figure 1. Anatomy of the inguinal region

Source: <https://emedicine.medscape.com>

The inguinal canal has four boundaries: the posterior and anterior walls, as well as the floor and roof. The posterior wall contains the transversalis fascia laterally and the conjoint tendon medially. The anterior wall is composed of the internal oblique muscle laterally and the aponeurosis of the external oblique muscle. The roof is composed of the internal oblique and transversus abdominis muscles. The inguinal ligament and lacunar ligament make up the floor of the inguinal canal (1) (*Fig. 2*).

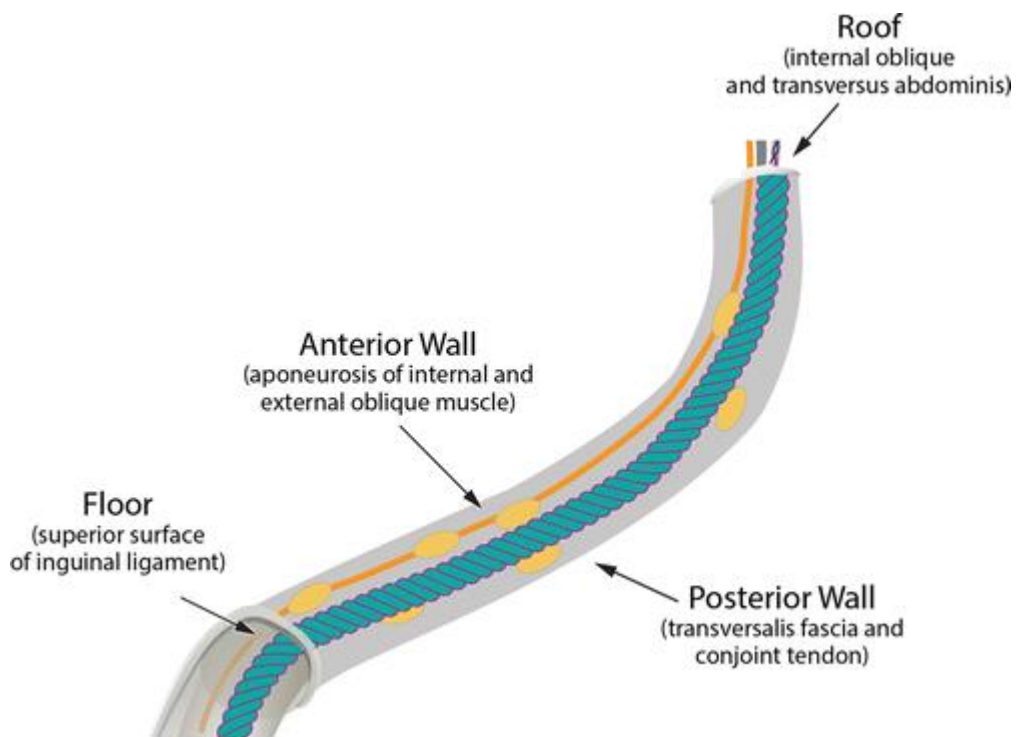


Figure 2. Anatomy of the inguinal canal boundaries
Source: <https://pubs.rsna.org/doi/full/10.1148/rg.2016150181>

The inguinal canal has two openings: the internal and external rings. The deep or internal ring is located just above the midpoint of the inguinal ligament and lateral to the epigastric vessels. The deep ring is formed by the transversalis fascia which provides the posterior covering of the contents of the inguinal ring. The superficial or external ring is the terminal end of the inguinal canal. It is located just superior to the pubic tubercle. The superficial ring has a triangular shape that is made by fibers of the external oblique muscle.

These fibers continue to cover the inguinal contents as they descend into the scrotal area. Contiguous with the superficial ring are tendinous fibers (i.e., interligamentous fibers) which function to prevent the ring from enlarging (2) (Fig. 3).

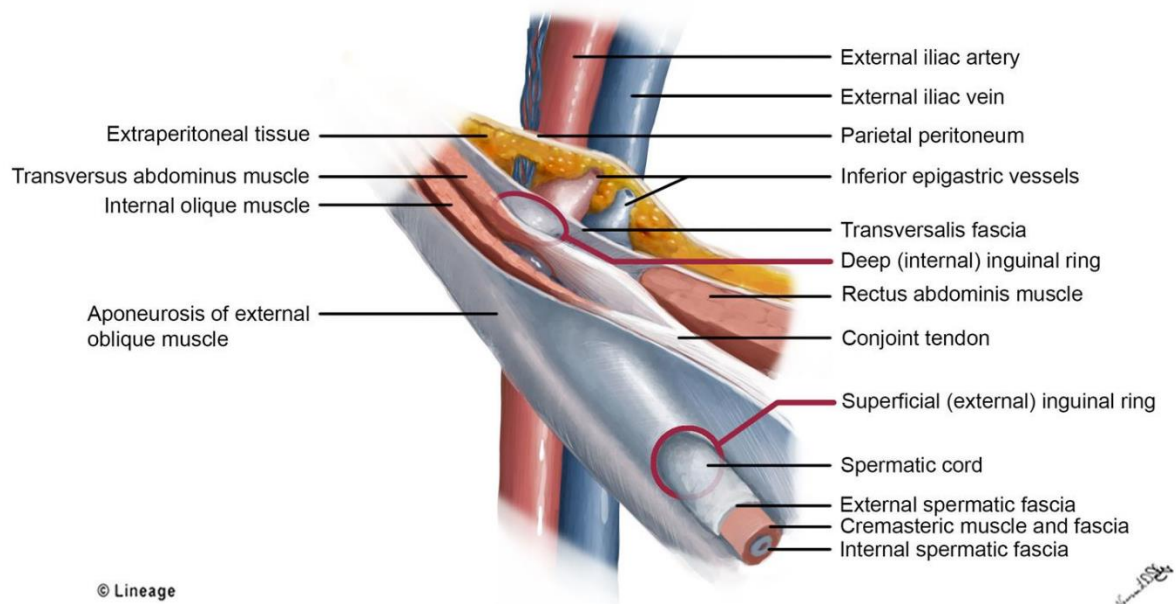


Figure 3: Anatomy of the inguinal canal

Source: <https://step1.medbullets.com/gastrointestinal/110018/inguinal-canal>

1.2. INGUINAL HERNIA

1.2.1. Anatomy of the inguinal hernia

An inguinal hernia is a protrusion of the intra-abdominal structures into the inguinal canal. There are two major types of inguinal hernias: the indirect type, which represents 50% of all inguinal hernias, and the direct type, which represents up to 25% of these protrusions. Up to 6.8% of patients are found to have combined direct and indirect hernias. Although femoral hernias also are considered groin hernias, they do not involve the inguinal canal (3).

1.2.2. Types of inguinal hernia

Inguinal hernias are subdivided into direct and indirect hernias depending on their location.

1.2.2.1. Direct inguinal hernias

This hernia forms as a result of weakening of the posterior wall of the inguinal canal, more specifically within a region called the "Hesselbach triangle". It is defined medially by the rectus abdominis muscle, laterally by the epigastric vessels, and inferiorly by the inguinal ligament. Conditions that cause increased abdominal pressure raises the likelihood of direct inguinal hernia formation. Thus, it is known as an acquired hernia. The herniation protrudes medially to the inferior epigastric artery (1). They are often seen in the elderly with chronic conditions which increase intra-abdominal pressure over a long period, e.g. chronic obstructive pulmonary disease, bladder outflow obstruction, chronic constipation, etc. Increased abdominal pressure is transmitted to both sides and as a result, direct hernias are usually bilateral. Compared to indirect hernias, they are less susceptible to strangulation as they have a wide neck (4).

1.2.2.2. Indirect inguinal hernias

An indirect inguinal hernia forms as a result of the failure of the processus vaginalis to fully obliterate. When it remains open, the potential for herniation occurs. This is why it is thought to be congenital in nature (1). Indirect inguinal hernias arise lateral and superior to the course of the inferior epigastric vessels, lateral to the Hesselbach triangle, and then protrude through the deep or internal inguinal ring into the inguinal canal. An indirect hernia enters the inguinal canal at the deep ring, lateral to the inferior epigastric vessels. It passes inferomedially to emerge via the superficial ring and, if large enough, extend into the scrotum. It is five times more common than a direct inguinal hernia, and is seven times more

frequent in males, due to the persistence of the processus vaginalis during testicular descent. Contents may include mesenteric fat (most common), peritoneal fluid, small bowel loops, mobile colon segments (sigmoid, cecum, appendix). Many are longstanding and asymptomatic, although the sheer size can become burdensome (5).

1.2.3 Incidence

About 25% of males and 2% of females develop inguinal hernias; this is the most common hernia in males and females. Approximately 75% of all hernias occur in the groin; two-thirds are indirect and one-third direct. Indirect inguinal hernias are the most common in both men and women; a right-sided predominance exists. Only 3% of hernias are femoral hernias. Between 10 and 30% of children have an abdominal wall hernia; most hernias of this type close spontaneously by age 1 year. The incidence of incarcerated or strangulated hernias in children is 10-20%; 50% of these occur in infants younger than 6 months (6). There is a clear bimodal distribution of inguinal hernias amongst men; one occurring in men from 0-5 years of age, and the other age group has a prevalence in men ~50 years of age. Females have the highest incidence of inguinal hernias at approximately 5 years of age (Fig. 4).

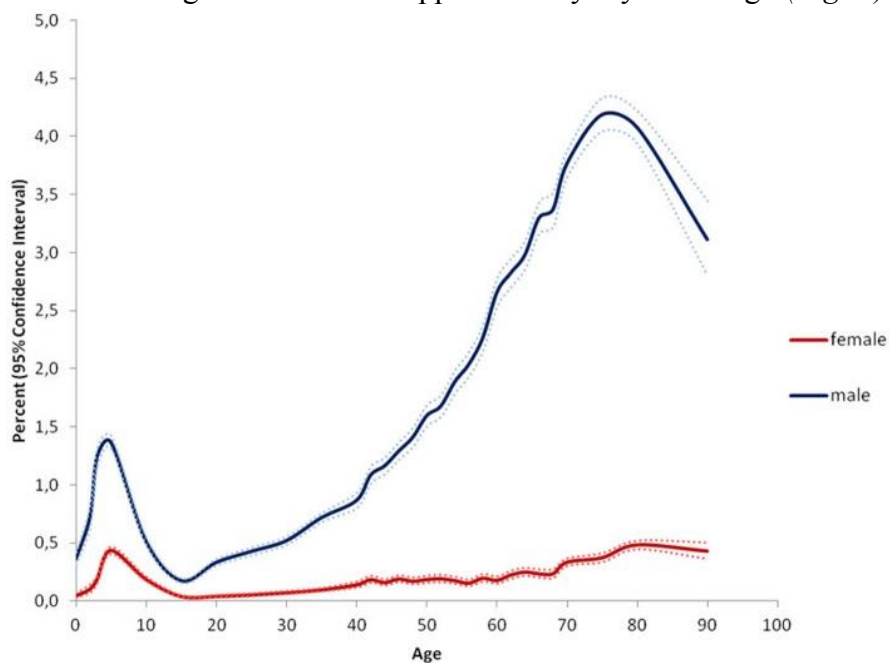


Figure 4. Incidence of Inguinal Hernias (7).

The lifetime risk of developing inguinal hernia is approximately 25% for men. Development of inguinal hernia is associated with several factors of which inheritance predominates. Low body mass index, chronic constipation, Ehlers–Danlos syndrome, and prostatectomy are additional risk factors, whereas it is still debatable if certain occupations influence on inguinal hernia formation (8). Indirect hernias usually present during the first year of life, but they may not appear until middle or old age (6). The recurrence rate after inguinal hernia repair is 3–8%. Experienced surgeons and those with more than five procedures yearly have fewer recurrences. A number of intraoperative aspects are related to hernia recurrence. Finally, obesity and smoking are patient-related factors that increase the risk of inguinal hernia recurrence (8).

1.2.4. Clinical findings

The most common symptom of inguinal hernias is a visible lump or bulge (6) (*Fig. 5*). This is common to all hernias, irrespective of type. Most cause mild to moderate discomfort that increases with activity (9). Other symptoms can include a dragging sensation that radiates to the scrotum, intermittent or continuous pain, or occasional digestive upset (6). A third of patients scheduled for surgery have no pain, and severe pain is uncommon (1.5% at rest and 10.2% on movement) (9). A hernia is termed “reducible” if the lump can be pushed through the abdominal wall. A hernia is “irreducible” if the lump resists manual pressure. An irreducible hernia can become a “strangulated” hernia if the blood supply is compromised or cut off (6). Inguinal hernias are at risk of irreducibility or incarceration, which may result in strangulation and obstruction; however, unlike with femoral hernias, strangulation is rare (9). If strangulation is present, symptoms such as fever, nausea, vomiting, and general ill or toxic appearance may be present (6).



Figure 5. Female patient found to have a sliding hernia containing incarcerated ovary as contents on both sides (10).

1.2.5. Complications

Several complications can arise as a result of inguinal hernias and their repair. An incarcerated hernia can lead to strangulation, which jeopardizes the blood supply to the organs. This condition requires immediate attention, as it can become life threatening. For example, it is mandatory to empty the bladder prior to an inguinal hernia repair to avoid a trocar injury (9). This is one of the commonest injuries occurring in hernia repair and often a reason for conversion. The various sites where it can occur is rectus muscle vessel injury during trocar insertion; inferior epigastric vessel injury; bleeding from venous plexus on the pubic symphysis; aberrant obturator vein injury; testicular vessel injury; and the most disastrous of all, iliac vessels, which requires an emergency conversion to control the bleeding and the immediate services of a vascular surgeon to repair the same. Most of the other bleeding can be controlled with cautery or clips (9). Injury to the vas deferens can cause fibrotic narrowing and must be avoided. This is best done by identifying and dividing the

structures in the deep ring or floor of the extraperitoneal space (9). Bowel injury is rare, but can occur when reducing large hernias.

The most common postoperative complication to hernias are recurrence, which may arise several years after initial hernia repair. Hematomas and seromas form at a rate of 5–25% and usually resolve spontaneously by 4–6 weeks (9). The incidence of neuralgias varies depending on the type of repair. The commonly involved nerves are lateral cutaneous nerve of thigh, genitofemoral nerve and intermediate cutaneous nerve of thigh. They are usually involved by mesh-induced fibrosis or entrapment (9). Testicular pain and swelling is usually transient. Orchitis was reported in a small number of patients, but did not lead to testicular atrophy (9). Bleeding is an unusual complication, occurring in up to 2% of patients (9-11). Infection carries an even smaller risk at <2%. Pain may be reported at the scar location, but this may decrease with time. Complications can also arise depending on the knowledge and experience of the surgeon.

1.2.6. Specific inguinal hernia types

Amyand's hernia consists of an incarcerated hernia along with acute appendicitis. This hernia type includes the appendix in the incarcerated hernia sac. Complications can include strangulation and perforation, and their associated symptoms. Patients often report symptoms similar to acute appendicitis (12).

Littre's hernia is a protrusion through a potential abdominal wall opening that contains a Meckel's diverticulum. They are also known as persistent omphalomesenteric duct hernias, and are most frequently encountered in the inguinal region (13). It habitually presents no particular symptoms, and only around 4% of the patients, having a Meckel's diverticulum, experience related complications. These include gastrointestinal bleeding, bowel obstruction, inflammation, and perforation (14).

A Richter hernia occurs when only the antimesenteric border of the bowel herniates through the fascial defect. This hernia involves only a portion of the circumference of the bowel. Thus, the bowel may not be obstructed, even if the hernia is incarcerated or strangulated, and the patient may not present with vomiting. A Richter hernia can occur with any of the abdominal hernias and is particularly dangerous in that a portion of strangulated bowel may inadvertently be reduced into the abdominal cavity, leading to perforation and peritonitis (15).

1.2.7. Diagnostic approach

The history and physical examination are usually sufficient to make the diagnosis. An abdominal bulge may disappear when the patient is in the prone position. Examination involves feeling for a bulge or impulse while the patient coughs or strains (*Fig. 6*). Although imaging is rarely warranted, ultrasonography or magnetic resonance imaging can help diagnose a hernia in an athlete without a palpable impulse or bulge on physical examination. Ultrasonography may also be indicated with a recurrent hernia or suspected hydrocele, when the diagnosis is uncertain, or if there are surgical complications (16).

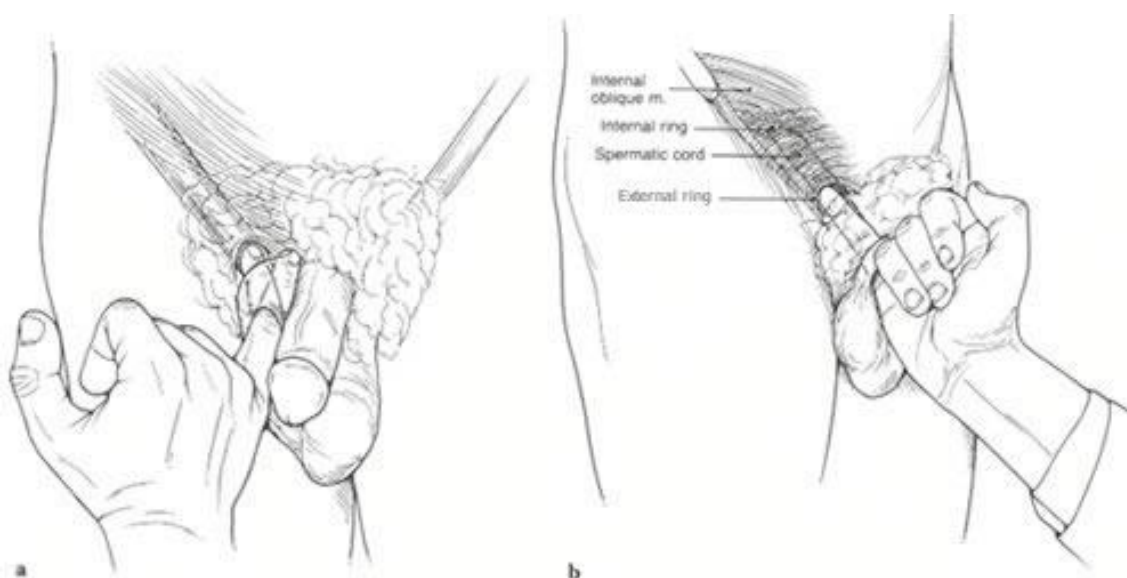


Figure 6. Palpating the external ring.
Source: <https://www.sportshernia.com>

Ultrasound is a non-invasive, non-ionising radiation modality which is highly successful at soft tissue imaging. Groin pain from an occult hernia can be a difficult clinical diagnosis made easier by good imaging. Ultrasound can accurately diagnose groin hernias and this may justify its use in the assessment of the occult hernia (17). The role of ultrasound is to distinguish between direct and indirect inguinal hernias and femoral hernias. Ultrasound can identify the contents of the hernia (bowel, omental fat, etc.) as well as determine reducibility, and identify alternative pathology (*Fig. 7*).

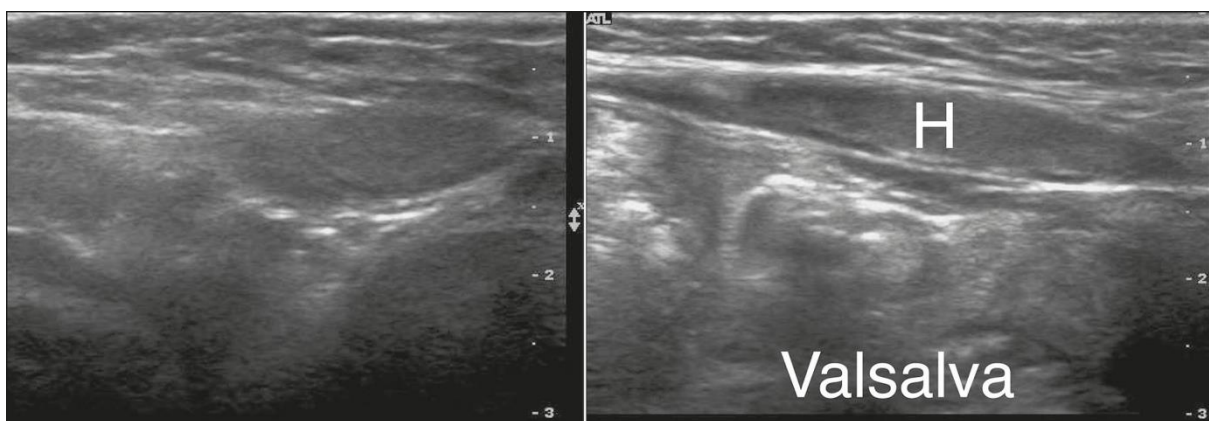


Figure 7. Direct inguinal hernia, contents enlarge with valsalva (18).

1.2.8. Treatment

Inguinal hernias do not spontaneously heal and must be surgically repaired because of the ever-present risk of incarceration (19). Generally, surgical correction must be undertaken as soon as possible after diagnosis. This is especially true in the pediatric patient. However, asymptomatic male patients may not require surgical intervention in an emergency setting. For females, however, even asymptomatic cases require surgical correction. Nonoperative reduction of an incarcerated hernia may first be attempted (20). If the patient is presenting with an acute abdomen, the abdomen must be explored during surgery. Currently, the method of choice for surgery favors the laparoscopic approach to the open procedure. Any signs of strangulation are an indication for emergency surgery. Surgical correction absolves

the risk of incarceration or obstruction, potentially fatal complications of inguinal hernias. Non Surgical methods of correction include the use of a truss, which must be worn throughout the day and may only be taken off when the patient is recumbent.

1.2.9. Surgical techniques

The purpose of surgical intervention is to return the herniated contents back to their respective cavity and to repair the weakness in the abdominal wall (21, 22). This can be accomplished by two different methods of operation: the laparoscopic or open approach. Adolescents have the additional difficulties concerning their age and body stature which pins them between pediatric and general surgery, and each case requires extra precautions and individualized care.

1.2.9.1. Laparoscopic approach

In recent times, the minimally invasive procedure has superseded the traditional open techniques previously seen as the gold standard of treatment. Laparoscopic surgery is a novel approach that is known to have major advantages over open repair, including better visualization of the peritoneal cavity, ability to operate on a possible contralateral hernia, and lower complication and procedural times. The procedure carries a mean duration of 25 minutes for laparoscopic ring closure in unilateral procedures (23-25). The procedure is cosmetically pleasing and has a shorter healing period. In pediatric patients and adolescents, after reaching the pneumoperitoneum, three trocars are introduced. A 3.5 or 5 mm telescope inserted through the umbilicus and two lateral trocars placed 3–4 cm below the umbilicus on either side (24). Suturing is performed using laparoscopic instruments. With minimally invasive techniques, patients report a lesser degree of pain and faster return to work, however there is an increased cost (23-26).

1.2.9.1.1. Percutaneous internal ring suturing

An alternative method of pediatric inguinal hernia repair includes the percutaneous internal ring suturing (PIRS) technique. PIRS is a minimally invasive method of repair for pediatric inguinal hernias. It was first introduced by Dr. Patkowski as a method of repair for inguinal hernias in the pediatric population (25). PIRS requires the insertion of a laparoscope through the umbilicus and a needle puncture point. By moving the injection needle, the thread passed under the peritoneum around the entrance into the hernia sac. The knot is tightened from outside and placed in the subcutaneous space (25-29) (*Fig. 8*). This method produces less operative stress on the body (29). The patients can return to regular activities the next day and pain after operation is minimal. The advantages of this method are that no additional incisions are necessary for the bilateral repair, a better visualization of the peritoneal cavity, and the possibility to detect a contralateral hernia that has not been realized yet (24-26). Also, minimally invasive surgery itself is beneficial due to decreased operation time, faster return to normal daily functions, better cosmetic outcomes, smaller duration of analgesia, and less pain reported by patients (25-29). It is important to note that the procedure is more difficult in males than in females, due to the extra precautions that need to be taken to avoid the vas deferens and spermatic blood vessels. It is recommended that surgeons start operating on females, then proceed to operate on males. The learning curve for surgeons is approximately 30 surgeries (27). With increasing amounts of experience, patients have an average operation time of 10 minutes for unilateral and 15 minutes for bilateral repairs, a significant decrease from the average operation time that is seen in traditional open repairs, which is around 30 minutes (26, 27).

The most frequent complications include hernia recurrence, granuloma formation, adhesions, hydrocele formation, and epigastric vessel injury (25). In the hands of a skilled surgeon, the complication rate is low, and the recurrence rate can be below 0.5% (26). The

rate of testicular atrophy and iatrogenic retention are nearly non-existent and testicular perfusion has not been affected due to the procedure (28). Complication rates and recurrence mirrors those of open techniques, and has been deemed a safe alternative for the pediatric population. Also, significantly lower level of pain and inflammatory stress response has been reported using the PIRS technique compared to open surgery (29). For these reasons it has become a popular alternative to traditional methods amongst the pediatric surgeons across Europe.

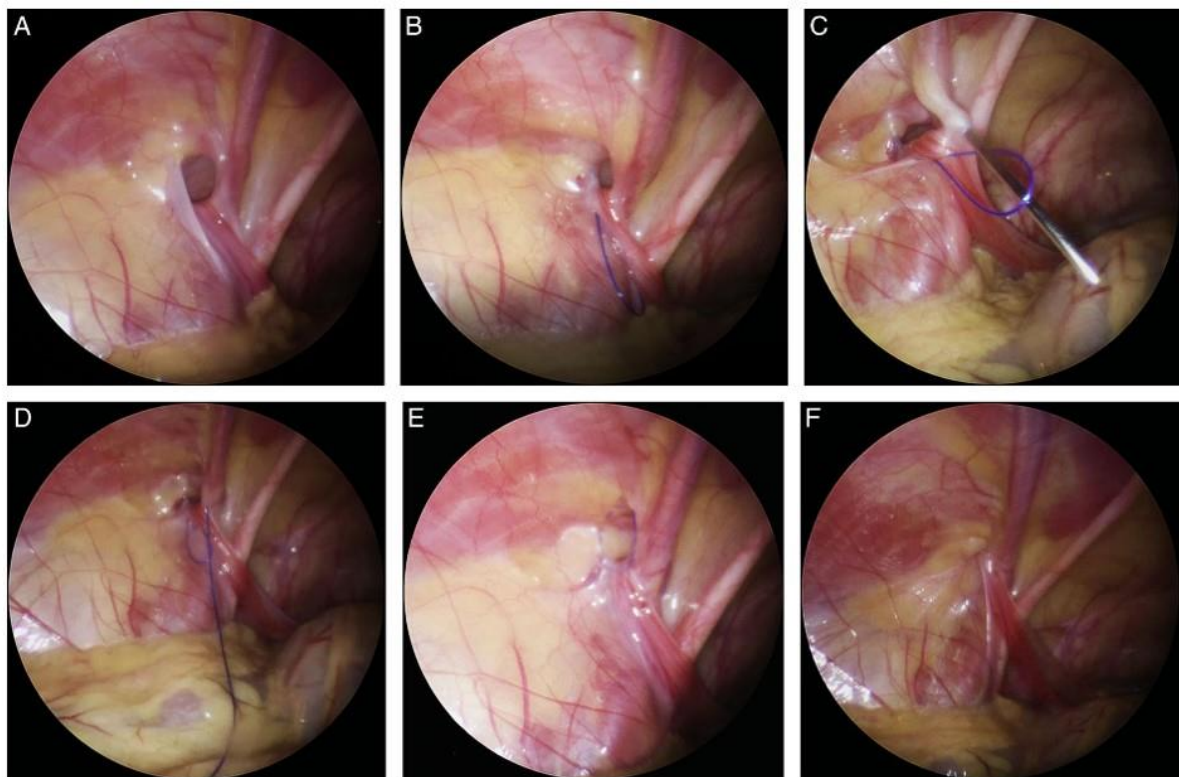


Figure 8. PIRS technique: (A)—Open internal inguinal ring; (B)—Introduction of a nylon loop; (C)—Introduction of the needle on the other side of the internal ring; (D)—Needle and suture passed through the previously introduced loop; (E)—The loop drawn out and the knot passed around internal ring; (F)—Closed internal ring (27).

1.2.9.2 Open Approach

The approach to fixing a groin hernia depends on multiple factors, including previous surgery, size of the hernia, whether abdominal contents are incarcerated and general health. Open hernia repair is carried out by making an incision near the groin hernia and identifying the abdominal contents that protrude through the weak area of the abdomen. These contents are contained in a structure called the hernia sac. The hernia sac is separated from important structures such as the spermatic cord and then returned back into the abdomen through the groin hernia. The hernial sac needs to be separated from certain structures, such as the ilioinguinal nerve, gonadal vessels, and the vas deferens (22). After ligation of the patent processus vaginalis with 3-0 or 4-0 braided absorbable sutures, the hernial defect is repaired by bringing the groin tissue back together (22, 30-32). Although a tension-free repair with mesh insertion is the standard of care for adult inguinal hernia repair, a mesh is not used in the pediatric population. The incision is closed with non-absorbable suture (22). Several types of repairs have emerged with time. One type, the Marcy repair, involves separating the hernia sac from the spermatic cord, then tying off the hernia sac or inverting the hernia sac into the retroperitoneal space. The internal ring is then tightened with a few sutures. The external oblique aponeurosis is closed. There is no tension on the repair and results are excellent (22, 29). This method carries the lowest recurrence rate, around 0.36% (22). The procedure can be performed under local or spinal anesthesia, avoiding certain complications of general anesthesia.

Another method, the Ferguson herniorrhaphy, was first described in 1899 (31). The main features of the Ferguson herniorrhaphy are: leaving the cord undisturbed; utilizing the cremaster muscle and the transversalis fascia in the repair, and suturing the internal oblique muscle and the conjoined tendon over the spermatic cord to Poupart's ligament, it being recommended that the spermatic cord not be lifted from its natural bed (31). This technique

allows the surgeon to properly explore for high ligation of the sac in the inner ring (32). Surgical complications such as fever, scrotal edema and hematoma, and wound infections classified as early complication and recurrence, testis atrophy and sensory impairment of inguinal area classified as late complications (32). Accordingly, the rate of spermatic cord injury, total rate of complications, recurrence have been reported to be 0.1%, $\leq 2\%$, and $< 1\%$, respectively (32). The prevalence rate for hematoma, hemorrhage, and testis atrophy has been reported to be 0.9%, 0.5%, and 1%, respectively (32). These factors also are influenced by the degree of the surgeon's experience.

2. OBJECTIVES OF RESEARCH

Surgical repair of inguinal hernias is one of the most common procedures in the pediatric population. All inguinal hernias need to be repaired surgically to avoid adverse complications. Laparoscopic repair of inguinal hernias at present provides significant benefits compared to open surgical repair.

This study aims to evaluate the safety, efficiency, and postoperative outcomes of adolescents undergoing PIRS for inguinal hernia repair within a 6 year period. The World Health Organization (WHO) defines adolescents as the phase of life from ages 10 to 19.

Hypotheses:

- 1) PIRS is a simple, safe, and effective method of inguinal hernia repair in adolescents with excellent outcomes and cosmetic results.
- 2) The incidence of complications and recurrence using PIRS for inguinal hernia repair in adolescents are minimal.

3. PATIENTS AND METHODS

3.1. Patients

All patients who underwent PIRS for an inguinal hernia repair at the Department of Pediatric Surgery of the University Hospital of Split in the period from October 2015 to May 2021.

Inclusion criteria:

1. Patients of both genders, between the ages of 10 to 17, with an inguinal hernia treated with the PIRS method.
2. Patients operated in the University Hospital of Split by a specialist in pediatric surgery.
3. Patients followed-up at least 3 months after the surgical procedure.

Exclusion criteria:

1. Patients out of determined age range.
2. Patients operated on by open approach or multi-port laparoscopic approach.
3. Patients who required conversion to an open procedure.
4. Patients with a follow-up of less than 3 months.
5. Patients with incomplete data.

3.2. Organization of the study

The study was carried out as a prospective cohort study using corresponding quantitative research and descriptively processed data.

3.3. Place of the study

The research took place at the Department of Pediatric Surgery, University Hospital of Split, Croatia.

3.4. Methods of data collection and processing

Demographic and clinical data, intraoperative findings, and outpatient follow up results were recorded in the Study protocol. The corresponding data was obtained by revising the study protocols and medical records. The data were analyzed using the Microsoft Excel for Windows Version 11.0 (Microsoft Corporation) and SPSS 24.0 (IBM Corp, Armonk, NY) software programs. Distributions of quantitative data were described by medians and interquartile ranges (IQR), whereas absolute rates and percentages were used to describe categorical data.

3.5 Description of research

Patients were admitted to the University Hospital of Split on the day of the surgery. Their personal information, medical history, and demographic data were noted in the Study protocol. The study evaluated the outcome, safety, and efficacy of the PIRS technique in inguinal hernia repair over a period of six years. A postoperative follow up recorded duration of hospital stay, level of pain, and any complications in the postoperative period. All patients were discharged one day post-operation. Patients attended a follow-up appointment at the outpatient clinic in the first and fourth week following surgery, and any possible complications were noted. The follow-up program included a physical examination at one, three and six months post operation to note any potential late-onset complication or hernia recurrence.

3.6. Outcome measures

The primary outcomes of the study included treatment outcomes, any possible complications either before or after operation, recurrence number and rate, conversion to an open procedure and reoperation rates. The secondary outcomes include duration of anesthesia, surgery, length of hospital stay, and the level of the pneumoperitoneum.

3.7. Compliance with ethical standards

All procedures performed in studies involving human participants were in accordance with the ethical standards of the institution and/or national research committee and with the 1964 Helsinki declaration and its later amendments or comparable ethical standards. Authors declared that the research was conducted according to the principles of the World Medical Association Declaration of Helsinki “Ethical Principles for Medical Research Involving Human Subjects”. Patients were informed in detail and informed consent was obtained from the parents or legal guardians of the patients to use the data. The study protocol was approved by the Ethics Review Board of University Hospital of Split with reference No. 2181-147-01/06/M.S.-20-9.

3.8. Surgery

Surgery starts with 3-mm supraumbilical incision, and depending on the patient's weight and age, a Veress needle is used to reach a pneumoperitoneum of 6–12 mmHg. A 3-mm port is inserted through the supraumbilical incision. A 3-mm laparoscope on the side of the hernia aids in visualization of the open internal inguinal ring. A 2 mm skin incision is made above the internal ring. A 20G spinal needle (ELDOR CSEN 38.4; Quincke Spinal Needle, Z.R.M.I. Co. Ltd. Jerusalem, Israel) is used together with a nonabsorbable

monofilament nylon loop (Prolene™ 3-0, polypropylene, Ethicon®, Cincinnati, Ohio, USA) on one side of the internal ring, preventing multiple entrances to the peritoneal cavity. This also prevents damage to the spermatic cord and blood vessels and takes as much of the edge of the entered side of the internal ring. The loop is positioned in the peritoneal cavity while the spinal needle is taken out carefully so as to not pull the loop out. The same procedure with the identical needle was performed on the opposite side of the internal ring. The needle is then passed through the previously positioned loop and the same suture is passed through the needle. After the needle has been removed and the loop is withdrawn, the internal ring is obliterated by pulling the second suture through the skin incision and tying it. The hernia repair is considered successful if occlusion of the hernia is visualized with a camera. A gauze ball is placed on the umbilical wound with a sterile drape above it and the small inguinal wound is closed using braided adhesive sterile strips or sutured.

4. RESULTS

Over the 6-year study period, 57 PIRS inguinal hernia repair procedures were performed in 51 adolescents, with median follow-up of 44 months (IQR 35, 51). The procedure was performed in 14 females (27.5%) and 37 males (72.5%) with a median age of 13 (IQR 12, 16). The patients that have undergone hernia repair are distributed by age at the time of surgery, and can be found in *Figure 9*. Most of the patients we encountered were 12 years old at the time of surgery (n=10; 19.6%) and at this age we found the most number of operations being performed. The lowest number of operations were performed at the age of 11 (n=3; 5.9%).

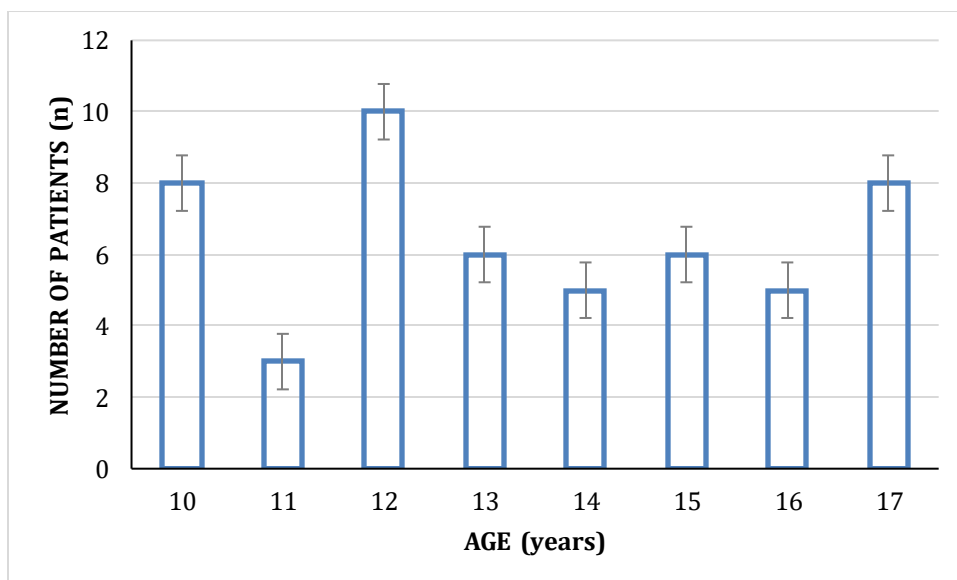


Figure 9. Distribution of patients based on age at the time of surgery.

Table 1 contains a summary of patient's demographic data. There were 30 (58.8%) right hernia repairs, 15 (29.4%) left hernia repairs and 6 (11.8%) bilateral repairs. All procedures were performed by the PIRS method and were successful. No procedures required conversion to open repair. All repairs that are reported here were performed electively.

Table 1. Patient's demographic data

Characteristic	Value
Age (years); Median (IQR)	13 (12, 16)
Gender; n (%)	
Male	37 (72.5)
Female	14 (27.5)
Height (cm); Median (IQR)	162 (149, 176)
Weight (kg); Median (IQR)	46 (35, 63)
BMI (kg/m ²); median (IQR)	18.6 (16.1, 21.3)
ASA classification; n (%)	
I	47 (92.2)
II	4 (7.8)
Lateralization of hernia; n (%)	
Right	30 (58.8)
Left	15 (29.4)
Bilateral	6 (11.8)

IQR – Interquartile range; *BMI* – Body mass index; *ASA* – American society of anesthesiologists

The median of operating time for unilateral hernias was 10 minutes (IQR 8, 14). The median operating time for bilateral hernias was 18 minutes (IQR 14.5, 24) (*Figure 10*). The median time under anesthesia for unilateral and bilateral repairs was 24 minutes (IQR 21, 29) and 30 minutes (IQR 26, 37), respectively. The average postoperative hospital stay was 24 hours (IQR 8, 24). The average level of the pneumoperitoneum was 10 mmHg (IQR 10, 12). There was 1 (1.95%) intraoperative complication (Table 2). No postoperative complications, recurrences or reoperations were recorded. The injury of blood vessels was treated conservatively and without any consequence to the patient. No complications were found on follow-up visits. No cases of suture granuloma, groin traction pain or discomfort, vas deferens injury, iatrogenic cryptorchidism, testicular atrophy or hernia recurrence were recorded.

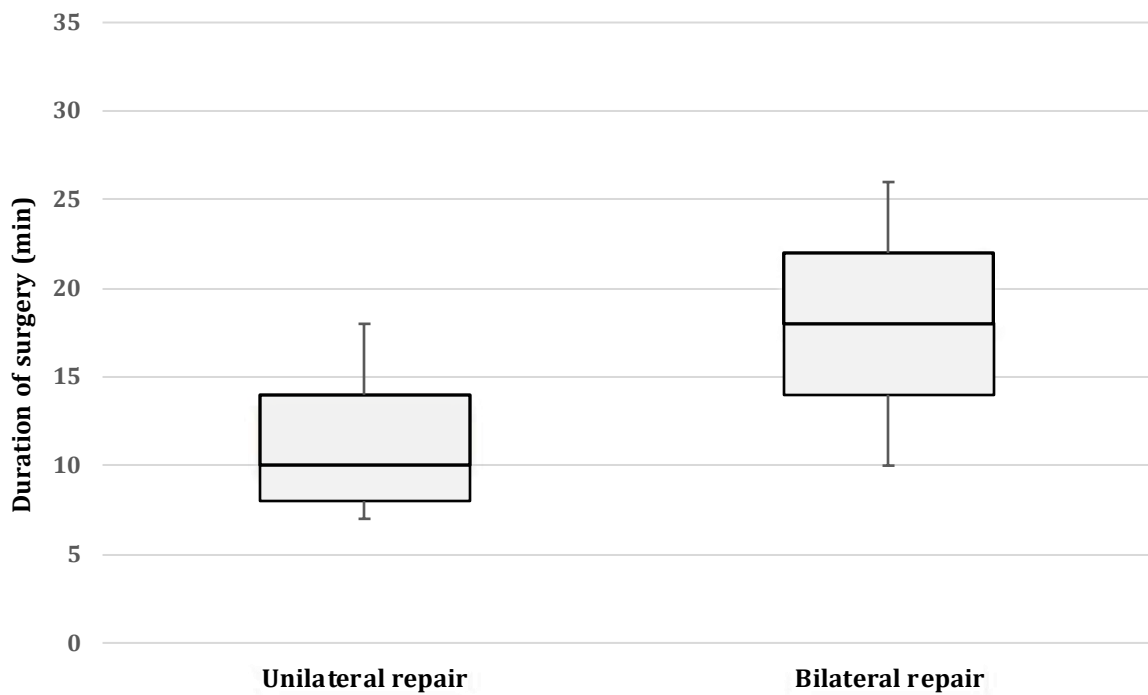


Figure 10. Comparison of duration of surgery for unilateral and bilateral repairs

Table 2. Treatment outcomes of the patients

Characteristic	Value
Duration of surgery (min); median (IQR)	
Unilateral repair	10 (8, 14)
Bilateral repair	18 (14.5, 24)
Duration of anesthesia (min); median (IQR)	
Unilateral repair	24 (21, 29)
Bilateral repair	30 (26, 37)
Pneumoperitoneum (mmHg); median (IQR)	10 (10, 12)
Additional trocar introduction; n (%)	10 (19.6)
Length of hospital stay (h); median (IQR)	24 (8, 24)
Complications; n (%)	
Intraoperative	1 (1.95)
Postoperative	0 (0)
Reoperations; n (%)	0 (0)

IQR – Interquartile range

5. DISCUSSION

In the present study, outcomes of PIRS for the treatment of inguinal hernia amongst adolescents were evaluated. The results of this study have proved that PIRS in adolescents is a safe and effective, minimally invasive method, for treatment of inguinal hernia with excellent outcomes, quick recovery, low incidence of complications and recurrences.

Across the lifespan, the incidence of inguinal hernias is lowest (<0.25%) in the adolescent population (33). Due to this low incidence, study data on this population is limited. Traditionally, open surgery has been the gold standard for treating inguinal hernias, and is the most common procedure performed in this age range (26). With minimally invasive surgery becoming more prevalent among pediatric surgeons, it is important to verify that these techniques are not inferior to their open counterparts (24, 34). PIRS is a method in which percutaneous closure of the internal inguinal ring is performed under the control of a laparoscope placed in the umbilical port. Unlike open surgery, a laparoscopic approach has several advantages. This includes avoidance of dissecting the vas deferens and spermatic vessels, significantly reduced pain, faster recovery and better cosmetic outcome to name a few (25-27).

All of the studies published to date involving PIRS as the method of repair of inguinal hernias involve the pediatric population, where the average age of patients is 2-5 years old (25-27). This is the first study that demonstrates the use of PIRS in adolescents 10-17 years old. Adolescents lie in an intermediary zone between pediatric patients and adult patients due to their physical growth, development, and degree of physical activity. It is important that they do not experience post-operative restrictions and that they can resume daily functions. One study reported a return to normal on an average of four days post-operation (35). The pathophysiology of an inguinal hernia in adolescents is more similar to that of children than in adults. For this reason, in the past, they have been treated similarly. PIRS proves to be a

safe and effective method for inguinal hernia repair in children and now, in adolescents as well.

Our study aimed to investigate outcomes of treatment in adolescent patients who had undergone inguinal hernia repair with the PIRS method. The success of a hernia surgery can be measured in various ways. One parameter is recurrence rate. In adult patients undergoing inguinal hernia repair with mesh, recurrences occur in approximately 2–5% of repairs (36). In children with inguinal hernias repaired with high ligation of the hernia sac by open or laparoscopic approach, recurrences occur in 0.5–4.0% (22, 24-27, 33-37). However, data collection in adolescents is extremely limited. Moreover, increased chronic pain has been reported in adolescents when mesh was used for inguinal hernia repair (33). Shen et al. compared the use of an acellular tissue matrix during Lichtenstein inguinal hernia repair to high ligation of the inguinal hernia sac in patients 13 to 18 years of age (38). They reported a 0.0% recurrence rate using the acellular tissue matrix Lichtenstein repair compared to a 6.0% recurrence rate with high ligation of the sac, though this difference was not statistically significant (38). They suggested that in this age group an individualized approach to the patients reduces recurrence rates (38). Ninety-five percent of recurrences occur within five years, and this is within our study range (35). Criss et al. reported that body mass index may significantly influence recurrence rates in adolescents (37). BMI was not significantly associated with recurrence in our cohort of patients. However, in this study, using the PIRS method for inguinal hernia repair with median follow-up of 44 months, no recurrences were recorded.

Another parameter that can be measured is complication rate. We recorded 1 (1.95%) intraoperative complication. This may be attributable to the skill of a surgeon. It was previously reported that the overall number of intraoperative and postoperative complications in the PIRS method significantly decreased after 30–45 operated patients, and reached a

minimum after 60 procedures (27). After 25–30 procedures per surgeon, the number of complications decreases to a minimum (27). The most common intraoperative complications recorded for PIRS is puncture of the epigastric veins and the most common postoperative complication was hydrocele formation (27). The initial usage of the PIRS technique had been associated with higher rates of ipsilateral recurrence and residual hydroceles in the past (26). This could be attributed to several factors including the inexperience of the surgeons, the use of absorbable suture, the use of a single suture for larger defects (26-27). To the best of our knowledge, no cases of testicular atrophy or iatrogenic cryptorchidism after PIRS were recorded in literature (28).

Traditional laparoscopic hernia repair, requires placement of multiple trocars and has been associated with increased duration of surgery due to intracorporeal suturing, increased postoperative pain and higher recurrence rates (26). Operation time for PIRS is significantly lower than in classical three port laparoscopic hernia repair. Medians of operative times for unilateral and bilateral repairs are 11 to 19 min and 18 to 24 min, respectively (27). In our study, we recorded a median operative time of 8 to 14 minutes for an unilateral operation and 14.5 to 24 minutes for bilateral repairs.

PIRS leaves a very cosmetically appealing result. Most patients report near invisibility of the scar after only a short time. Only very thin patients sometimes report that they can feel a subcutaneous suture. During PIRS, the peritoneum is reached by a blunt needle under direct vision, avoiding the anatomy of the groin structure. This causes less trauma, and leaves no surgical incision on the abdominal wall (25-27). No cases of suture granuloma, groin traction pain or discomfort, vas deferens injury, iatrogenic cryptorchidism, testicular atrophy or hernia recurrence were recorded in this study.

Pain is a factor which affects patients' ability to return to normal functioning. One study reports that 6.7% of adolescents experience inguinal neuralgia after high ligation (35).

Comparatively, 10-11% of adults experience this (35). A study involving children with a median age of 4.7 years reported inguinal neuralgia in 5.1% of patients (35). None of the patients we have worked with have reported inguinal neuralgia. PIRS has been associated with a decreased level of pain due to decreased surgical stress and inflammatory response (29). PIRS is also not shown to affect or decrease testicular vascularization (28).

This study is limited by having a relatively small population size involving patients with a healthy, average BMI and no preexisting medical conditions. More research should be undertaken to determine would changing these parameters affect the outcomes of procedures. Another possible limitation is a single-center design of the study.

Additional investigation should be taken to determine the effects of an adolescents' comorbidities on inguinal hernia repair, such as cardiac or gastrointestinal comorbidities, and the potential benefits of this minimally invasive method of repair with their chronic conditions, as the shorter operation time may be an attractive option in this population.

6. CONCLUSION

PIRS has proven to be an effective, simple, and safe method for inguinal hernia repair in adolescents. It provides excellent overall and cosmetic outcomes. There is a low incidence of complications and recurrence rates. According to our results PIRS could be considered to become one of the possible approaches for inguinal hernia repair for the adolescent population.

7. REFERENCES

1. Moore KL, Dalley AF, Agur AMR. Abdomen. In: Moore KL, Dalley AF, Agur AMR, editors. *Moore clinically oriented anatomy*, 7th ed. Toronto: Lippincott Williams & Wilkins. 2014. p. 201–5.
2. Tuma F, Lopez RA, Varacallo M. Anatomy, abdomen and pelvis, inguinal region (inguinal canal). In: StatPearls. Treasure Island (FL): StatPearls Publishing; 2020. p. 1–9.
3. Revzin MV, Ersahin D, Israel GM, Kirsch JD, Mathur M, Bokhari J, et al. US of the inguinal canal: Comprehensive review of pathologic processes with CT and MR imaging correlation. *Radiographics*. 2016;36:2028–48.
4. Iftikhar N, Kerawala A. Quality of life after inguinal hernia repair. *Pol Przegl Chir*. 2021;93:1–5.
5. Latenstein CSS, Thunnissen FM, Harker M, Groenewoud S, Noordenbos MW, Atsma F, et al. Variation in practice and outcomes after inguinal hernia repair: a nationwide observational study. *BMC Surg*. 2021;21:45.
6. Li J, Bao P, Shao X, Cheng T. The Management of indirect inguinal hernia sac in laparoscopic inguinal hernia repair: A systemic review of literature. *Surg Laparosc Endosc Percutan Tech*. 2021. doi: 10.1097/SLE.0000000000000944.
7. Burcharth J, Pedersen M, Bisgaard T, Pedersen C, Rosenberg J. Nationwide prevalence of groin hernia repair. *PloS one*. 2013;8:e54367.
8. Jensen KK, Henriksen NA, Jorgensen LN. Inguinal hernia epidemiology. In: Hope W, Cobb W, Adrales G. (eds) *Textbook of hernia*. Springer, Cham; 2017. p.11–22.
9. Jenkins JT, O'Dwyer PJ. Inguinal hernias. *BMJ*. 2008;336:269–72.
10. Basrur GB. Bilateral inguinal hernias containing ovaries. *Clinics and Practice*. 2015;5:708.
11. Chowbey PK, Pithawala M, Khullar R, Sharma A, Soni V, Baijal M. Complications in groin hernia surgery and the way out. *J Minim Access Surg*. 2006;2:174–7.
12. Manatakis DK, Tasis N, Antonopoulou MI, Anagnostopoulos P, Acheimastos V, Papageorgiou D, et al. Revisiting Amyand's hernia: A 20-year systematic review. *World J Surg*. 2021. doi: 10.1007/s00268-021-05983-y.
13. Usman A, Rashid MH, Ghaffar U, Farooque U, Shabbir A. Littre's Hernia: A rare intraoperative finding. *Cureus*. 2020;12:e11065.
14. Bendjaballah A, Taieb M, Ammari S, Khiali R. Littre's Hernia: A unusual tricky situation of Meckel's diverticulum. *World J Surg Surgical Res*. 2019;2:1150.

15. Magnoli M, Floridi A, Giuliani D, Monti M, Segalini E. Laparoscopic treatment for an inguinal Richter's hernia: an unusual indication in case of acute small bowel obstruction. *ANZ J Surg.* 2019;89:E470–1.
16. Williams ML, McCarthy ASE, Lord SJ, Aczel T, Brooke-Cowden GL. Impact of ultrasound on inguinal hernia repair rates in Australia: a population-based analysis. *ANZ J Surg.* 2021. doi: 10.1111/ans.16845.
17. LeBlanc KE, LeBlanc LL, LeBlanc KA. Inguinal hernias: diagnosis and management. *Am Fam Physician.* 2013;87:844–8.
18. Nunes F, Rocha P, Francisco de Assis C, Antonio R, José F, Buarque de Gusmão F. Ultrasound evaluation of inguinoscrotal pain: an imaging-based review for the ultrasonographer. *Radiol Bras.* 2018;51:193–9.
19. Bradley M, Morgan D, Pentlow B, Roe A. The groin hernia - an ultrasound diagnosis? *Ann R Coll Surg Engl.* 2003;85:178–80.
20. Liu J, Shen Y, Nie Y, Zhao X, Wang F, Chen J. If laparoscopic technique can be used for treatment of acutely incarcerated/strangulated inguinal hernia? *World J Emerg Surg.* 2021;16:5.
21. Perko Z, Rakić M, Pogorelić Z, Družijanić N, Kraljević J. Laparoscopic transabdominal preperitoneal approach for inguinal hernia repair: a five-year experience at a single center. *Surg Today.* 2011;41:216–21.
22. Pogorelić Z, Rikalo M, Jukić M, Katić J, Jurić I, Furlan D, et al. Modified Marcy repair for indirect inguinal hernia in children: a 24-year single-center experience of 6826 pediatric patients. *Surg Today.* 2017;47:108–13.
23. Chinnaswamy P, Malladi V, Jani KV, Parthasarathi R, Shetty RA, Kavalakat AJ, et al. Laparoscopic inguinal hernia repair in children. *JSLs.* 2005;9:393–8.
24. Esposito C, Montupet P. Laparoscopic treatment of recurrent inguinal hernia in children. *Pediatr Surg Int.* 1998;14:182–4.
25. Patkowski D, Czernik J, Chrzan R, Jaworski W, Apoznański W. Percutaneous internal ring suturing: a simple minimally invasive technique for inguinal hernia repair in children. *J Laparoendosc Adv Surg Tech A.* 2006;16:513–7.
26. Pogorelić Z, Čohadžić T, Jukić M, Nevešćanin Biliškov A. Percutaneous internal ring suturing for the minimal invasive treatment of pediatric inguinal hernia: A 5-year single surgeon experience. *Surg Laparosc Endosc Percutan Tech.* 2021;31:150–4.

27. Pogorelić Z, Huskić D, Čohadžić T, Jukić M, Šušnjar T. Learning curve for laparoscopic repair of pediatric inguinal hernia using percutaneous internal ring suturing. *Children (Basel)*. 2021;8:294.
28. Pogorelić Z. Effects of laparoscopic hernia repair by PIRS (Percutaneous Internal Ring Suturing) technique on testicular artery blood supply. *J Invest Surg*. 2019;32:348–9.
29. Jukić M, Pogorelić Z, Šupe-Domić D, Jerončić A. Comparison of inflammatory stress response between laparoscopic and open approach for pediatric inguinal hernia repair in children. *Surgical Endoscopy*. 2019;33:3243–50.
28. Hewitt DB, Chojnacki K. Groin hernia repair by open surgery. *JAMA*. 2017;318:764.
30. Družijanić N, Sršen D, Pogorelić Z, Mijaljica G, Juričić J, Perko Z, et al. Preperitoneal approach for femoral hernia repair. *Hepatogastroenterology*. 2011;58:1450–4.
31. Summers JE. Classical herniorrhaphies of Bassini, Halsted and Ferguson. *Am J Surg*. 1947;73:87–99.
32. Nazem M, Dastgerdi MM, Sirousfard M. Outcomes of pediatric inguinal hernia repair with or without opening the external oblique muscle fascia. *J Res Med Sci*. 2015;20:1172–6.
33. Kim SH, Jung HS, Park S, Cho SS. Inguinal hernia repair with or without mesh in adolescent males. *Ann Surg Treat Res* 2021;100:246–51.
34. Gibbons AT, Hanke RE, Casar Berazaluce AM, Abdulhai S, Glenn IC, McNinch NL, et al. Recurrence after laparoscopic high ligation in adolescents: a multicenter international retrospective study of ten hospitals. *J Ped Surg*. 2021;56:126–9.
35. Gasior AC, Knott EM, Kanters A, St. Peter SD, Ponsky TA. Two-center analysis of long-term outcomes after high ligation inguinal hernia repair in adolescents. *Am Surg*. 2015;81:1260–2.
36. Taylor MA, Cutshall ZA, Eldredge RS, Kastenber ZJ, Russell KW. High ligation in adolescents: Is it enough? *J Ped Surg*. 2020. doi: 10.1016/j.jpedsurg.2020.11.006.
37. Criss CN, Gish N, Gish J, Carr B, McLeod JS, Church JT, et al. Outcomes of adolescent and young adults receiving high ligation and mesh repairs: a 16-year experience. *J Laparoendosc Adv Surg Tech*. 2018;28:223–8.
38. Shen YM, Chen J, Tian ML, Yang S, Liu SJ, Wang MG. Lichtenstein repair of indirect inguinal hernias with acellular tissue matrix grafts in adolescent patients: a prospective, randomized, controlled trial. *Surg Today*. 2014;44:429–35.

8. SUMMARY

Background: Percutaneous internal ring suturing (PIRS) has been proved to be a safe and effective laparoscopic technique for hernia repair in younger children but without evidence of safety and efficacy among adolescents. Therefore, the aim of this study was to determine the outcomes of treatment of PIRS for inguinal hernia repair in adolescents between the ages of 10-17 years old.

Methods: All adolescents who underwent PIRS for an inguinal hernia repair, between February 2015 and April 2021 at single center, were enrolled in a prospective cohort study. Certain parameters, such as patients' age at the time of surgery, gender, body mass index, lateralization of hernia, surgical and anesthesia times, level of pneumoperitoneum, length of hospital stay, complications and recurrences were recorded.

Results: A total of 57 PIRS inguinal hernia repairs were performed in 51 adolescents (37 (72.5%) males) with a median age of 13 (interquartile range, IQR 12, 16) years and median follow-up of 44 (IQR 35, 51) months. Right-side predominance was noted with 30 (58.8%) right hernia repairs, 15 (29.4%) left hernia repairs, and 6 (11.8%) bilateral hernia repairs. Median surgical time was 10 (IQR 8, 14) min for unilateral and 18 (IQR 14.5, 24) min for bilateral repair. Median hospital stay was 24 (IQR 8, 24) hours. Regarding intraoperative complications only one (1.95%) inferior epigastric vein injury was recorded. During the follow-up period, no complications or recurrence were recorded.

Conclusion: PIRS is an effective and safe technique for inguinal hernia repair in adolescents with excellent outcomes and a low incidence of complications and recurrences rates.

9. SUMMARY IN CROATIAN

Naslov rada: Perkutana plastika unutarnjeg otvora preponskog kanala – nova minimalno invazivna metoda liječenja preponske kile u adolescentima: iskustvo jednog centra.

Cilj istraživanja: Perkutana plastika unutarnjeg otvora preponskog kanala (PIRS) je minimalno invazivna kirurška tehnika liječenja preponske kile u djece, međutim nema dokaza o sigurnosti upotrebe ove metode u adolescenata. Cilj ove studije je procijena učinkovitosti i ishoda liječenja preponske kile u adolescenata u dobi od 10–17 godina korištenjem PIRS-a.

Ispitanici i metode: Svi adolescenti koji su operirani zbog preponske kile PIRS tehnikom, u razdoblju od 1. veljače 2015. do 1. travnja 2021. godine, uključeni su u prospektivno kohortno istraživanje. Svakom adolescentu zabilježene su slijedeće varijable: dob, spol, indeks tjelesne mase, lateralizacija kile, duljina trajanja operacijskog zahvata i anestezije, razina pneumoperitoneuma, duljina boravka u bolnici, intraoperacijske i/ili poslijeoperacijske komplikacije i recidivi.

Rezultati: Ukupno je PIRS tehnikom operirano 57 kila u 51 adolescenata (37 (72.5%) muškog spola) s medijanom dobi od 13 (interkvartilni raspon, IQR 12, 16) godina i medijanom praćenja od 44 mjeseca. Desnostrana kila zabilježena je u 30 (58.8%), lijevostrana u 15 (29.4%) i obostrana u 6 (11.8%) adolescenata. Medijan duljine trajanja operacijskog zahvata iznosio je 10 (IQR 8, 14) min za jednostrane i 18 (IQR 14.5, 24) min za obostrane kile. Medijan duljine trajanja bolničkog liječenja bio je 24 (IQR 8, 24) h. Zabilježena je jedna (1,95%) intraoperacijske komplikacije i to ozljeda epigastričnih vena. Tijekom razdoblja praćenja, nisu zabilježene poslijeoperacijske komplikacije, kao ni recidivi.

Zaključci: PIRS je sigurna i učinkovita kirurška tehnika liječenja preponske kile u adolescenata s izvrsnim ishodima liječenja i niskom učestalošću komplikacija i recidiva.

10. CURRICULUM VITAE

PERSONAL INFORMATION

NAME AND SURNAME: Tina Batinović

DATE AND PLACE OF BIRTH: March 26 1997, Smithtown, New York

NATIONALITY: Croatian-American

CURRENT ADDRESS: Poljicka 28A Split, Croatia

E-MAIL: tinabatinovic@yahoo.com

EDUCATION

2003–2007 Mount Sinai Elementary School, Mount Sinai, New York, USA

2007– 2011 Mount Sinai Middle School, Mount Sinai, New York, USA

2011–2015 Mount Sinai High School, Mount Sinai, New York USA

2015–2021 Medical Studies in English at the University of Split, School of Medicine, Split, Croatia

ACCOMPLISHMENTS

2015–2019 Member of Faculty Council

2015–2020 Student Representative

PUBLICATIONS

2021 „Impact of an environmental epidemiology board game on knowledge, experience, and attitudes among children: a pilot study“.

OTHER

Languages: English, Croatian, Spanish