

Comparison of the outcomes of testicular torsion during the COVID-19 pandemic versus the pre-pandemic period : A systematic review and meta-analysis

Artuković, Leon

Master's thesis / Diplomski rad

2022

Degree Grantor / Ustanova koja je dodijelila akademski / stručni stupanj: **University of Split, School of Medicine / Sveučilište u Splitu, Medicinski fakultet**

Permanent link / Trajna poveznica: <https://urn.nsk.hr/urn:nbn:hr:171:350920>

Rights / Prava: [In copyright](#)/[Zaštićeno autorskim pravom.](#)

Download date / Datum preuzimanja: **2024-11-22**



Repository / Repozitorij:

[MEFST Repository](#)



**UNIVERSITY OF SPLIT
SCHOOL OF MEDICINE**

LEON ARTUKOVIĆ

**COMPARISON OF THE OUTCOMES OF TESTICULAR
TORSION DURING THE COVID-19 PANDEMIC VERSUS
THE PRE-PANDEMIC PERIOD: A SYSTEMATIC REVIEW
AND META-ANALYSIS**

DIPLOMA THESIS

Academic year:

2021/2022

Mentor:

Assoc. Prof. Zenon Pogorelić, MD, PhD

Split, 2022

First, I would like to express my very great appreciation to my mentor Prof. Zenon Pogorelić, MD, PhD for his remarkable dedication, support and help in writing my diploma thesis.

And I also want to thank my family – for everything they did for me. And my friends for being supportive and believing in me throughout this journey.

LIST OF ABBREVIATIONS

CI – Confidence Interval

COVID – Corona Virus Disease

EMBASE – Excerpta Medica dataBASE

IV – Inverse Variance method

MM – Mantel-Haenszel method

PICOS – Population, Intervention, Comparison, Outcome and Study design

PRISMA – Preferred Reporting Items for Systematic Review and Meta-Analysis

RR – Relative Risk

SARS – Severe Acute Respiratory Syndrome

WMD – Weighted Mean Difference

TABLE OF CONTENTS

1. INTRODUCTION	1
1.1. ACUTE SCROTUM.....	2
1.2. ANATOMY OF THE SCROTUM.....	2
1.3. ANATOMY OF THE TESTIS AND EPIDIDYMIS.....	3
1.4. CAUSES OF ACUTE SCROTUM.....	5
1.4.1. TESTICULAR TORSION.....	6
1.4.2. TORSION OF TESTICULAR APPENDAGE.....	8
1.4.3. EPIDIDYMITIS.....	8
1.4.4. ORCHITIS.....	9
1.4.5. TESTICULAR TRAUMA.....	9
1.4.6. LESS COMMON CAUSES OF ACUTE SCROTUM.....	10
1.5. CLINICAL PRESENTATION OF ACUTE SCROTUM.....	10
1.6. DIAGNOSIS AND TREATMENT OF ACUTE SCROTUM.....	12
1.6.1. IMAGING DIAGNOSTICS IN ACUTE SCROTUM.....	12
1.6.2. LABORATORY DIAGNOSTICS OF ACUTE SCROTUM.....	13
1.6.3. TREATMENT OF ACUTE SCROTUM.....	14
1.7. THE PANDEMIC OF CORONAVIRUS COVID-19.....	17
2. OBJECTIVES	20
2.1. AIM OF STUDY.....	21
2.2. HYPOTHESIS.....	21
3. PATIENTS AND METHODS	22
3.1. STUDY DESIGN.....	23
3.2. SEARCH STRATEGY.....	23
3.3. ELIGIBILITY CRITERIA.....	24
3.4. DATA SYNTHESIS.....	25
3.5. METHODOLOGICAL QUALITY ASSESSMENT.....	25
3.6. STATISTICAL ANALYSIS (QUANTITATIVE SYNTHESIS).....	26
4. RESULTS	28
4.1. STUDY CHARACTERISTICS.....	29
4.2. SUMMARY OF THE INCLUDED STUDIES.....	31
4.3. METHODOLOGICAL QUALITY ASSESSMENT.....	33
4.4. OUTCOME ANALYSIS.....	33
4.4.1. DURATION OF SYMPTOMS.....	33

4.4.2.	PROPORTION OF CHILDREN WITH DELAYED PRESENTATION	34
4.4.3.	PROPORTION OF CHILDREN REQUIRING ORCHIECTOMY	35
5.	DISCUSSION	36
6.	CONCLUSION	41
7.	REFERENCES	43
8.	SUMMARY	51
9.	CROATIAN SUMMARY	53
10.	CURRICULUM VITAE	55

1. INTRODUCTION

1.1. ACUTE SCROTUM

First time mentioned in 1970 by Moharib and Kahn it represents a term referring to a number of common urological emergency states (1). The correct diagnosis coupled with swift and adequate treatment are of great importance for this condition since failure to accomplish either task will result in high morbidity for the patient. Therefore, the physician has to be well educated and have a high degree of suspicion considering relatively common incidence of acute scrotum to overcome any dilemmas in the process of diagnosis.

Acute Scrotum describes a clinical syndrome resulting from a number of disorders and is described by pain, swelling of the scrotum and redness of the scrotal skin. The cause of acute scrotum can stem from a number of pathologic conditions including testicular torsion, acute epididymitis, torsion of appendix testis, infarction of the testis, allergic scrotal edema, incarcerated scrotal hernia, testicular tumors, insect bites, inflamed hydrocele, trauma. When we talk about the presentation in emergency clinical practice, the most common causes are epididymitis, testicular torsion and torsion of appendix testis (1–9).

1.2. ANATOMY OF THE SCROTUM

The scrotum is functionally a cutaneous pouch, which develops from the labioscrotal folds in males to accommodate the testes after they descent (10).

The scrotal sac itself is made up of two histologically distinguishable layers: strongly pigmented skin superficially and, slightly deeper, a layer of dartos fascia which contains the smooth muscle fibers (*m. dartos*) responsible for the rugose appearance of scrotal sac. Cold environment provokes *m. dartos* and *m. cremaster* into thickening of the scrotal sac and elevating the testicles respectively in order to decrease heat loss. The extension of Dartos fascia creates the scrotal septum, which divides the scrotum into two halves – each containing a testicle with its respective epididymis, nerves and blood vessels (10–12). Figure 1 depicts the anatomical cross section of the scrotum.

Externally the septum is marked by raphe scroti, a cutaneous ridge created by the merging of labioscrotal swellings in embryology. The surface of fascia dartos is devoid of fat and is

connected anteriorly to the membranous layer of the subcutaneous tissue of the abdomen. The perineal artery and its distal posterior scrotal branches together with cremasteric artery and its anterior scrotal and deep pundental branches supply the scrotum with arterial blood. The course of scrotal veins is near and parallel to their arteries (10). The scrotal venous blood drains into the internal pudental vein, the greater saphenous vein and the femoral vein. The lymphatic vessels of scrotum drain into the superficial inguinal nodes (11). The anterior surface of scrotum is innervated by nerve fibers originating from the lumbar plexus (genitofemoral nerve and ilioinguinal nerve), and the posterior surface is innervated by the branches of the pudental nerve (12).

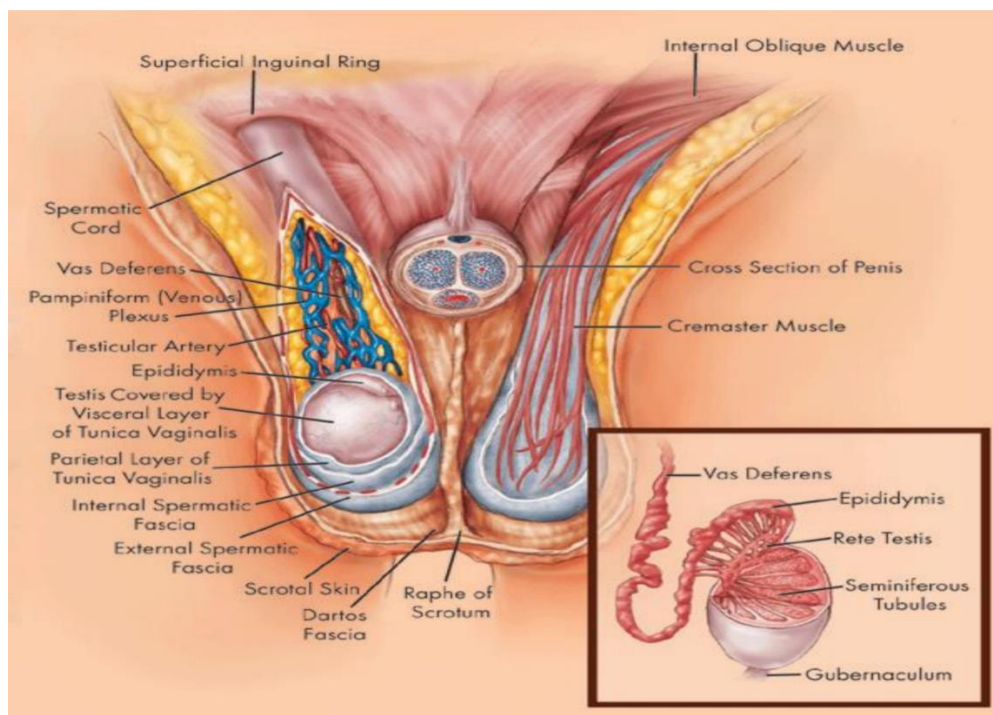


Figure 1. Scrotal anatomy. Source: <http://www.rudyard.org/scrotum-anatomy/>.

1.3. ANATOMY OF THE TESTIS AND EPIDIDYMIS

As the male embryo develops, the testis separates from the primitive kidney and descends inside the abdominal cavity. Throughout the course of the seventh and eight months of embryonal development the testis descends from the entrance of inguinal canal to the scrotal sac. The failure

of the testis to descent usually leaves them positioned in the abdomen or in the inguinal canal, the term for such condition is cryptorchidism (5).

The testes are male paired reproductive glands that produce male sex hormones – mostly testosterone, and male reproductive cells – spermatozoa. The spermatic cord is bound to the testes inside the scrotal sac. The left testicle usually sits inferior to the one on the right. The outermost layer – the tunica albuginea, is a tough fibrous sheet that thickens into a ridge on its inner posterior side creating the testicular mediastinum. Several of the septa reach inward from this structure and separate the seminiferous tubules, a crucial apparatus for sperm production. Seminiferous tubules then merge with the straight tubules within the mediastinum constituting rete testis (10). Tunica vaginalis is a peritoneal sac that partially surrounds the testicle, epididymis and the inferior part of ductus deferens. The visceral layer of tunica vaginalis completely covers the surface of each testicle except for a small portion where the testicle attaches to the epididymis and the spermatic cord. As an analogue to the visceral layer, the parietal layer surrounds the testis and stretches superiorly into the distal part of spermatic cord. These two layers are separated with a small amount of fluid, the fluid allows the testicle to move freely inside the scrotum (11). The arterial supply of the testicle comes from the testicular, cremasteric and deferent artery. The veins draining the testicle and epididymis create the pampiniform plexus anterior to the vas deferens surrounding the testicular artery in the spermatic cord. Pampiniform plexus alongside the cremasteric muscle and the dartos muscle makes the testicle thermoregulation apparatus, responsible for the maintenance of constant temperature inside the testicle. Each pampiniform plexus converges to create the left and right testicular veins, which drain into the left renal vein and the inferior vena cava respectively. Lymph is drained from the testicle alongside the testicular artery and vein into retroperitoneal lymph nodes. Testicular plexus gives autonomic branches to the testicular nerve, containing vagal parasympathetic and visceral afferent fibers. The sympathetic supply also comes through the testicular nerve from the celiac ganglion (12).

Epididymis is an elongated structure found on the posterior superior surface of the testicle. It is divided into three parts – head, neck, and tail. The head is the superior part of the epididymis, it is wider than the rest of the epididymis and is made up of lobules created by the endings of 12–14 efferent ductules. The body of epididymis is the curved part of epididymal duct and the tail part continues into the rete testis, which is connected to the ejaculatory duct allowing the sperm to

travel from the epididymis to the prostatic part of the urethra (Figure 2). About 90% of males also have a round formation on the superior part of the testis called Appendix testis which is believed to be a remnant of the Müllerian duct.

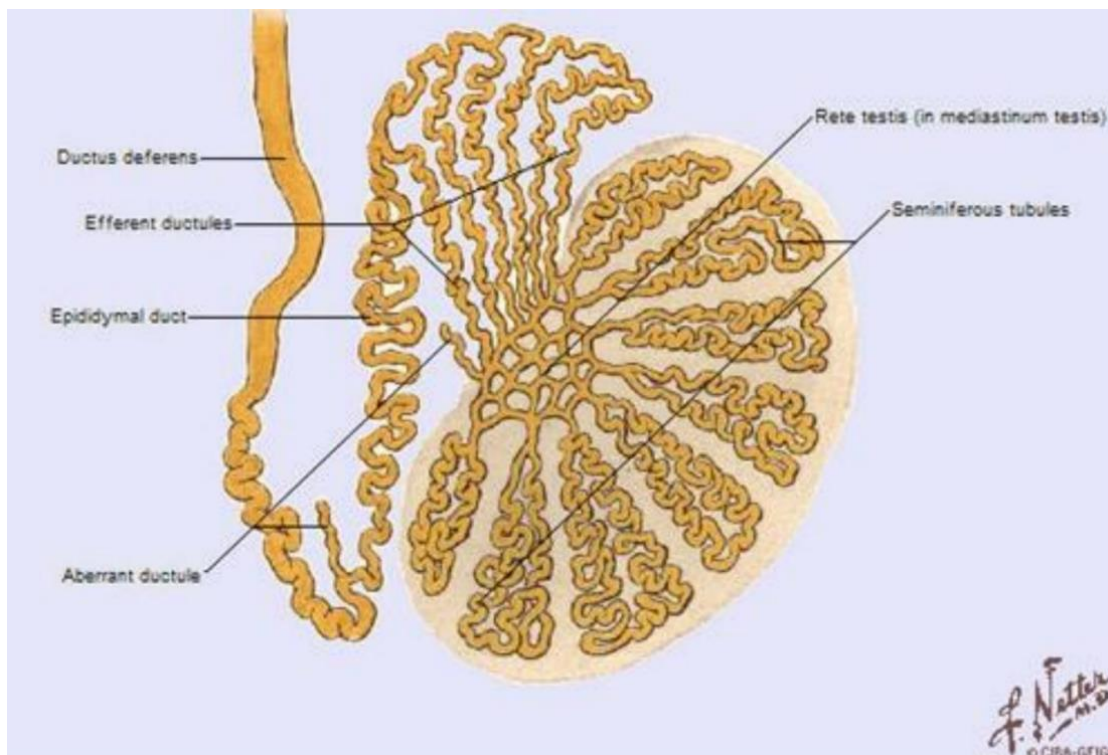


Figure 2. Testis, epididymis and ductus deferens presented schematically. Source: Interactive Atlas of Human Anatomy by Franck Netter.

1.4. CAUSES OF ACUTE SCROTUM

There are three conditions that most often cause acute scrotum, they are testicular torsion, torsion of the appendix testis and epididymo-orchitis, with testicular torsion requiring most urgent intervention. Less common but notable causes include trauma, testicular infarction, scrotal edema, testicular tumors and Henoch-Schönlein purpura (13).

1.4.1. TESTICULAR TORSION

Testicular torsion occurs when a testicle rotates 180 degrees or more around its vertical axis, after which there is a cessation of blood flow to the testis resulting in an infarction and finally testicular gangrene. The overall incidence of testicular torsion in patients under 25 years of age is 1:4000, with two pronounced peaks in incidence – infants before the age of one (suffering exclusively from extravaginal torsion) and in boys around 13 years of age. The incidence plummets after the age of 30 (14–19).

There are two types of testicular torsion – intravaginal or extravaginal. When the testicle with or without its corresponding epididymis twists around its tunicae we are talking about intravaginal torsion. In extravaginal torsion the testicle with its epididymis both rotate around the vertical axis in the area of the spermatic cord (20). The former is more likely to develop in and after puberty, while the latter is more common in the neonatal period (21). The predisposition for extravaginal torsion stems from the abnormal suspension of testis inside the tunica vaginalis, oversized tunica vaginalis, insufficient testicular ligament or a combination of those. These conditions can - spontaneously or provoked by increased physical activity, sports or an impact to the testicle - lead to the cessation of blood flow to very delicate structures of the testis, with the end result being a hemorrhagic infarction and testicular gangrene. Anomalies predisposing to extravaginal torsion most often happen bilaterally, with the most common one being the so called “bell clapper” deformity (22). A “bell clapper” testis is almost entirely surrounded by tunica vaginalis with minimal fixation to its mesentery which leaves it in a transverse position with the ability to rotate freely (Figure 3). The onset of neonatal torsion happens *In utero*, and local presentation is the most apparent finding on delivery. The presentation of neonatal torsion is characterized by a very hard content in the scrotum, it is usually painless and with pronounced scrotal skin edema. When torsion happens in adolescence, we have a clinical presentation characteristic of testicular torsion - it includes a very painful scrotum followed by nausea, vomiting and sweating. Sometimes however, the only presentation is an isolated abdominal pain without any pain in the area of scrotum (18).

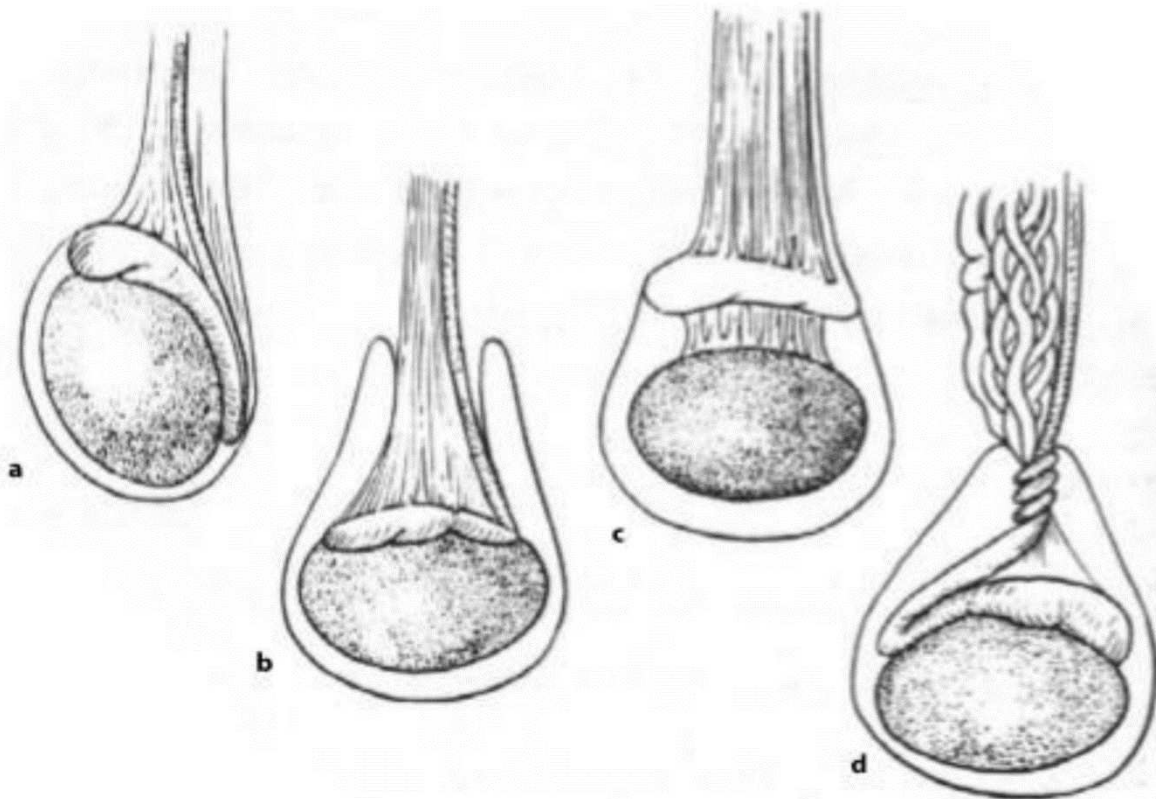


Figure 3. The anatomy of (a) normal attachments, (b) bell-clapper deformity, (c) abnormal mesorchium and (d) intravaginal torsion. Source: Heyns CF, Visser AJ. *Andrology for the Clinician*.

Both testis and epididymis are painful on palpation, with edematous covering skin which is usually red in color. The therapy is surgical, and the state of the testis upon surgical examination determines the procedure. If the testicular viability appears to be maintained, the therapy consists of detorsion and fixation of the testis. If, however the testicular gangrene is present, an orchidectomy is performed and contralateral testis is fixed (1–8, 16–19).

In the patients suffering from an undescendent testis (cryptorchidism) there is a higher possibility of torsion within the abdomen or the inguinal canal (18). When the torsion happens in the abdominal cavity there are no local symptoms rather there are pronounced nausea, vomiting and abdominal pain (18, 19). If the torsion occurs in the inguinal cavity the scrotum is empty and the local finding is a painful hard lump in the inguinum (18, 19). Because of the above mentioned

reasons in each male patient complaining to the lower abdominal pain examination of the inguino-scrotal region is mandatory

1.4.2. TORSION OF TESTICULAR APPENDAGE

The testicular appendix (Hydatid Morgagni) is an embryonal remnant of the Müllerian duct situated on the superior part of the testis. The clinical picture is dominated by scrotal pain that is medium to severe in nature. On palpation, the finding of precisely localized pain in one spot inside the scrotum can aid in diagnosis (15, 16). Clinical picture can however resemble testicular torsion so caution is advised when assessing the patients. “Blue dot” sign is a blue luminescent structure that can be seen in these patients upon translumination (6). The treatment can be both surgical (removal of the affected cyst) or even conservatively with symptomatic therapy if the diagnosis is certain (2, 4, 5, 7)

1.4.3. EPIDIDYMITIS

Epididymitis refers to the inflammation of epididymis. There are multiple causes to this condition, both viral and bacterial, with neonates and younger children more susceptible to epididymitis as a result of urogenital malformations (3, 21, 23, 24). Some systemic diseases have epididymitis as a complication – namely sarcoidosis, Kawasaki disease and Henoch-Schönlein purpura. Symptoms of epididymitis begin as mild to moderate scrotal pain with testicular swelling which increases in volume over couple of days, sometimes even causing dysuria (25). Other complications include testicular infarction, recurrent testicular infections, abscess formation and even testicular atrophy. The therapy of epididymitis remains conservative (treatment of underlying condition, antibiotics, antipyretics, rest) (2–5, 24, 25).

1.4.4. ORCHITIS

Orchitis refers to the inflammation of the testis. It can be caused by inflammation reaching the testis from other parts of the body, such as the progression of epididymitis which we call orchido-epididymitis. It can be of both viral and bacterial origin. Of note is the Parotitis virus which causes testicular inflammation in boys usually older than ten (2, 26). Pain in the testis, swelling and hardening of the testis with associated nausea, vomiting, febrility and pain when voiding. Orchitis can be further complicated by abscess and/or fistula formation with resulting sterility and testicular atrophy. As in epididymitis, the treatment is conservative (2, 3, 26–29).

1.4.5. TESTICULAR TRAUMA

Most common traumatic conditions for the testis are laceration, contusion and penetrating injuries. These injuries are fairly uncommon, accounting for less than 1% of all traumatic injuries owing to its relatively protected anatomical location and to high mobility of the scrotum. Most common mechanism of injury is blunt force trauma, mostly from injuries suffered while playing sport or from a motorcycle accident (30, 31). The peak incidence is in boys between 15 and 40 years old (29). The anatomical location of the right testis makes it more susceptible to incarceration between the inner thigh and pubis, hence more susceptible to testicular trauma (31). Thorough physical examination and imaging is required for the selection of adequate treatment, with ultrasound being the method of choice for its ability to reliably identify various scrotal and testicular injuries. The most severe testicular injury is testicular rupture, it requires an immediate surgical intervention, with the probability for testicular salvage dropping sharply 72 hours after the onset of injury (31).

1.4.6. LESS COMMON CAUSES OF ACUTE SCROTUM

1.4.6.1. IDIOPATHIC SCROTAL EDEMA

Very uncommon entity of unknown etiology and pathogenesis. swelling and redness of the scrotum are the hallmarks of this condition. Edema is developing rapidly, most often unilaterally and without pain, but with increased sensitivity in affected area. Testis and epididymis are however normal to palpation, but palpation is difficult owing to voluminous edema. It resolves spontaneously with the scrotal edema disappearing within 24-48 hours. It most often happens in boys between three and nine years old (2, 4, 32).

1.4.6.2. TESTICULAR INFARCTION

There are two types of testicular infarction: idiopathic and neonatal. Idiopathic infarction is most common in boys between 2 and 15 years old and affects the upper third of the testis. The cause of idiopathic infarction is suspected to be testicular vessel thrombosis in patients with impaired coagulation and periarteritis nodosa. Neonatal hemorrhagic infarct can be unilateral or bilateral. The suspected causes are delivery trauma and spontaneously corrected torsion. Testicular infarction is not easily distinguishable from torsion which is why it always warrants surgical exploration (2, 33, 34)

Other rare causes mentioned in literature that can present as acute scrotum are testicular tumors, Henoch-Schönlein purpura, hydrocele and incarcerated scrotal hernia (2-4, 6)

1.5. CLINICAL PRESENTATION OF ACUTE SCROTUM

In order to accurately diagnose the cause of acute scrotum we mainly make use of a thorough physical examination, ultrasound and laboratory testing. If the findings are inconclusive, further tests such as magnetic resonance imaging and scintigraphy can be utilized. When discovering the cause of the condition, as with many other conditions, anamnesis plays a key role. It is very helpful

to inquire the patient about the pain, its time of onset, location at onset, intensity and character, along with other possible signs of urogenital disease. The combination of thorough anamnesis and clinical examination are the key to the correct diagnosis, gathering this information may prove to be difficult at times because of the shame felt by the patient and the changes in the testicular anatomy. Performing the examination in a warm environment decreases the possibility of testicular retraction into the inguinum, the room should be well lit. Visual examination should be performed with the child in the standing position allowing for an easier assessment of the position of the testis, and any skin changes namely redness or ecchymosis. Palpation should be performed with the patient in a supine position with the knees in flexion, using warm hands to inspect the asymptomatic testis first, then its epididymis and then the affected testis and epididymis thoroughly along with both proximal inguinal regions. Fullness and thickness of the spermatic cord, asymmetries or organ enlargement can be suggestive of the diagnosis. The detailed evaluation of anatomical structures is usually made much more difficult by the frequent swelling and pain of the testicle. Translucence can be of use, especially to differentiate solid mass from fluid. The most usual findings are ipsilateral scrotal swelling and redness, with the testicle hard and painful to palpation and positioned horizontally (Figure 4).

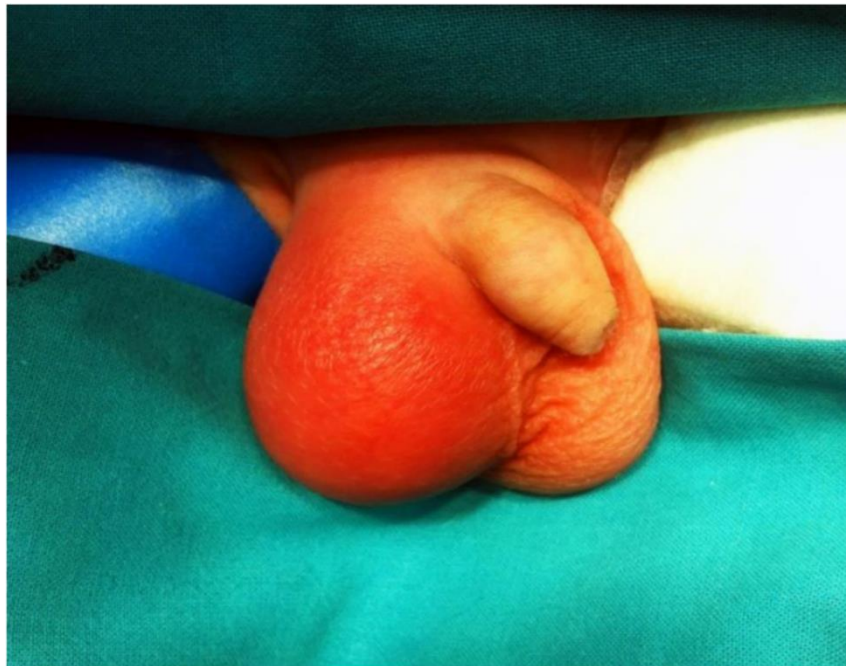

Figure 4. Pathognomonic findings of acute scrotum: induration, redness and edema of the scrotum. Source: Personal archive of mentor

Phren's sign is commonly used to describe the ease of pain upon elevation of testis above the symphysis, it is inconsistent but it can be used to aid in the diagnosis of epididymitis and orchitis. Inflammatory conditions differ from torsion in that the pain subsides over time. Phren's sign has not been proven in clinical practice to be effective in differentiating testicular torsion from other causes of acute scrotum (4, 6, 7). Cremasteric reflex is always absent in the case of testicular torsion, which can aid in diagnosis. Specificity of such finding in this case is 60% (3, 35).

1.6. DIAGNOSIS AND TREATMENT OF ACUTE SCROTUM

1.6.1. IMAGING DIAGNOSTICS IN ACUTE SCROTUM

In the majority of cases the physical examination and anamnesis are pathognomonic for acute scrotum and no further imaging is needed before proceeding to the operating room. However, Doppler ultrasound and standard ultrasound are the first line of imaging when trying to exclude testicular torsion (36) (Figure 5). The advantages of ultrasound are quick assessment, noninvasiveness, availability and the ability of ultrasound to differentiate important anatomical structures needed in differential diagnosis. The specificity and sensitivity when using the combination of standard and Doppler ultrasound are 80%–100% and 85–100% respectively in the diagnosis of testicular torsion (37–41). False negative findings for testicular torsion are sometimes caused when post torsion hyperemia is mistaken for orchid-epididymitis or when the flow through the tunicae is mistaken for testicular circulation (37–41).

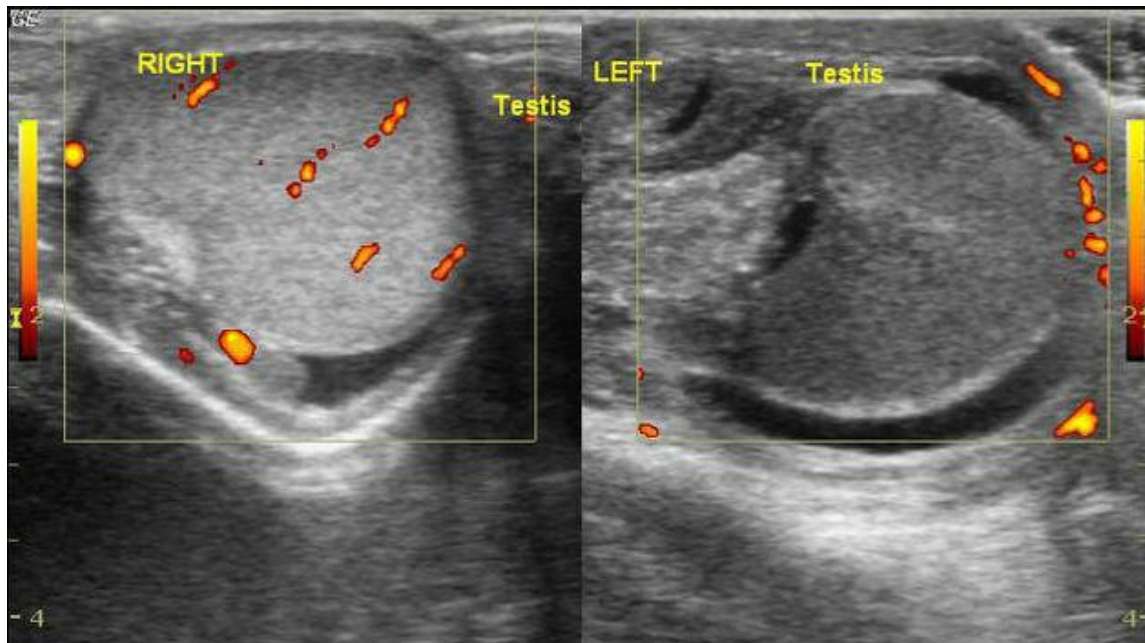


Figure 5. Doppler ultrasound. The left testis is diffusely hypoechoic without any mass lesions. There is no flow on the Doppler imaging. The left spermatic cord shows twisting. Source: <https://radiopaedia.org/>.

Another type of imaging used rarely is scintigraphy with Technetium 99m pertechnetate. The availability of such examinations is limited, and visualizing smaller prepubertal testes is difficult, with insufficient anatomical details to entail a more widespread use. When examining for testicular torsion, scintigraphy demonstrates an 80–90% sensitivity and 60–95% specificity (40–43).

Magnetic resonance imaging is seldom used to demonstrate and evaluate testicular torsion due to long examination times, limited availability and price. However, sensitivity and specificity of magnetic resonance when used to evaluate testicular torsion is 95–100% (5, 44, 45).

1.6.2. LABORATORY DIAGNOSTICS OF ACUTE SCROTUM

The laboratory analysis is sometimes used in conjunction with the imaging methods to differentiate between causes of acute scrotum. The most common parameters assessed are complete blood count, sedimentation and C-reactive protein. Complete blood count, sedimentation

and also leukocyte count have not been proven to be useful in differentiating between inflammatory and non-inflammatory causes of acute scrotum in children (46). C-reactive protein and child age however can be of use to differentiate inflammatory from non-inflammatory causes alongside imaging modalities (46). The relatively quick results of laboratory tests make them more appropriate in diagnosing an emergent condition like testicular torsion where wasting time can be detrimental to the survivability of the testis.

1.6.3. TREATMENT OF ACUTE SCROTUM

The emergent nature of testicular torsion makes the appropriate diagnosis and treatment needed in a relatively short period of time in order to salvage the testis. The testicular salvage rate overall is 40–60%, but it is highly dependent upon the time between the onset of torsion and surgical detorsion (18, 19, 46–48). The literature shows an approximate time of 4 hours between the onset of torsion and subsequent destruction of semen producing apparatus (47). If there is surgical intervention within 6 hours after onset we can expect positive outcome for the patient with a normalization of spermiogram parameters over time in 90-100% of cases. If operative treatment is provided within 6–12 hours after the onset of torsion the testicular salvage rate drops to 20–50%, however if more than 12 hours pass until the surgery is performed, the chance of recovery of affected testis is close to 0% (18, 19, 49–52).

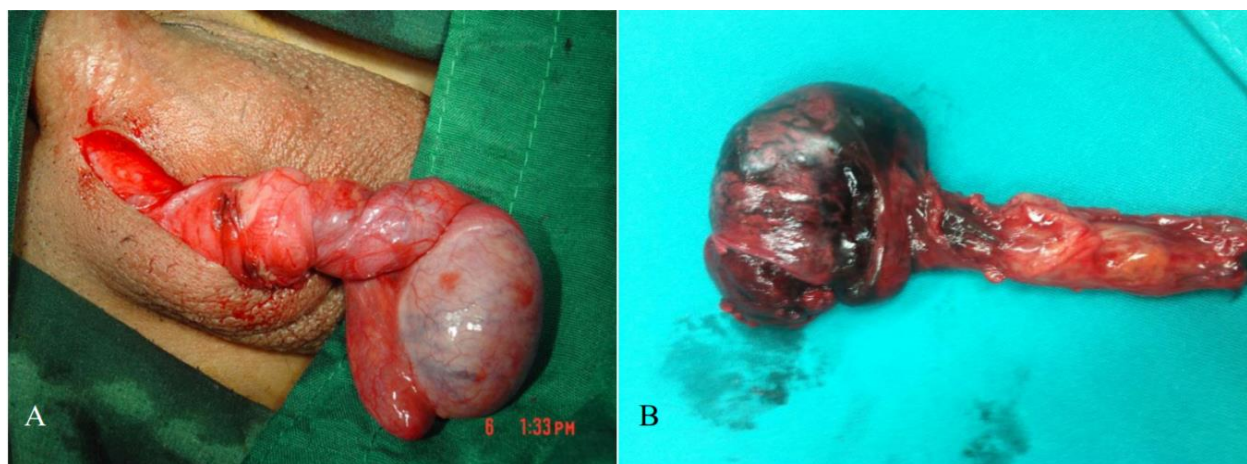


Figure 6. Intraoperative findings in testicular torsion: A) A 270° torsion with a vital testis; B) a 540° testicular torsion which resulted in a gangrenous testis. Source: Personal archive of mentor.

If the underlying cause of acute scrotum has not been determined neither by anamnesis, physical examination nor imaging or if we are not certain of the viability of the testicle we resort to surgical exploration of scrotum. Manual detorsion is not recommended in pediatric patients with testicular torsion (53).

Surgical exploration is possible using two approaches. One is accomplished with a vertical incision through the scrotal raphe, and another transversely through the affected side of the scrotum. The vertical incision through the scrotal raphe is convenient for exploration of both testicles at once. However, in proven unilateral acute scrotum we most commonly make a transverse incision only on the affected side. After we make the transverse incision, we proceed to make an incision on the tunica vaginalis which reveals the testis for inspection, which provides with a definite diagnosis of the cause of the torsion (2, 3, 18, 19). If upon inspection we find testicular torsion, and the testis is still viable, we perform a detorsion and fixation. If the detorsed testis doesn't show signs of improvement upon the return of circulation we put a compress on, soaked with warm saline, and wait 10-20 minutes. If even after this effort there is no return of circulation, another incision is made through the tunica albuginea, and if it does not provoke new bleeding and the testis is necrotic an orchidectomy is performed, and the contralateral testis is fixed. Following the surgery, a testicular prosthesis can be placed (Figure 6).

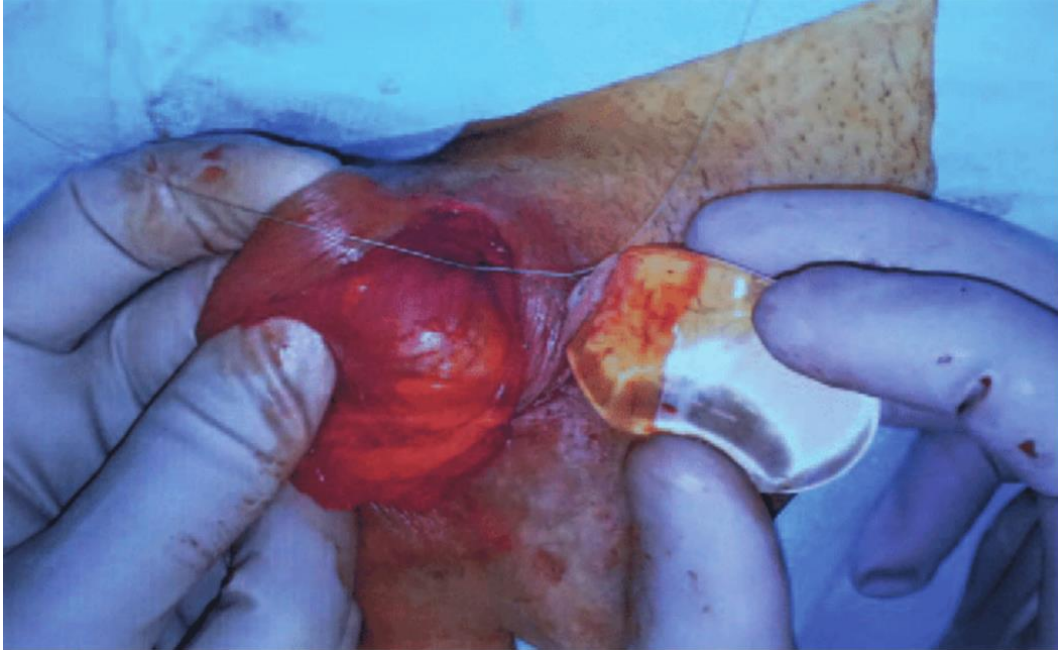


Figure 6. Anchoring of the prosthesis to the bottom of the scrotal sac. Source: <https://www.researchgate.net>.

If upon inspection we find the testicular viability borderline, we detorse it and leave it in the scrotum for two days and then perform a “second look” surgery (54). Algorithm of treatment of the patients with testicular torsion has been shown in Figure 7. If the testicular appendage is torted, we excise it and fix the ipsilateral testis, and if epididymitis is encountered the inflammatory exudate is evacuated and the testis is rinsed with saline (2, 3). In the case of testicular trauma, and if the testis is viable, attempts at primary reposition of the testis are made and reconstruction of tunica albuginea is performed in order to try to salvage the testis (31).

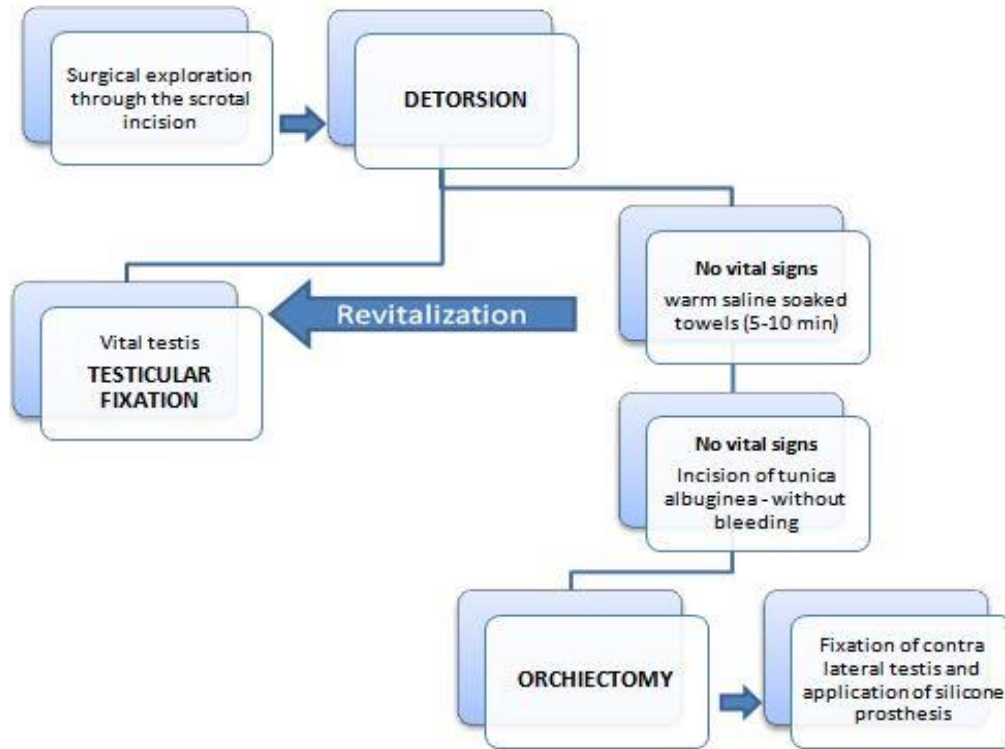


Figure 7. Algorithm of treatment of acute scrotum at the Department of pediatric surgery in University Hospital of Split.

1.7. THE PANDEMIC OF CORONAVIRUS COVID-19

The pandemic of coronavirus was caused by the disease that results from the infection by coronavirus-2 (SARS-CoV-2). The disease can present as a severe acute respiratory syndrome with a characteristic hyper-inflammatory response with possible complications consisting of vascular damage, microangiopathy, angiogenesis and widespread thrombosis (55). Apart from the damage this disease can cause to its sufferers, the pandemic it caused has had a detrimental effect on the society, most of all the healthcare institutions and personnel. The ensuing lockdowns and social distancing measures deprived the healthcare system of workers. Some hospitals were facing rearrangements, limited access to patients and some were outright closed (56). This development has made hospitals a hot spot for infected patients, while also making them understaffed from the consequences of the disease on workers themselves, including an alarming number of fatalities (Figure 8). Therefore, there is a risk of an emerging tendency that patients avoid hospitals, including emergency departments which can prove to be disastrous especially for patients with

serious acute conditions. This phenomenon was observed and a link between the COVID-19 pandemic and increased avoidance of the emergency department for other conditions has been proven (57, 58). One notable example is the reduction in hospitalizations of patients suffering from myocardial infarction in many countries when comparing the pandemic period to the pre pandemic period (59). In some countries literature also proves that there is a reduction in visits to the emergency department with regards to all diagnostic groups in pediatrics (60, 61). There were also fewer hospitalizations and patient visitations regarding chronic complex conditions that suggests the avoidance of emergency departments by patients during the COVID-19 pandemic (60). Recent meta-analysis clearly showed that there was a significantly higher incidence of complicated appendicitis in children during the COVID-19 pandemic than in the pre-COVID-19 period, because the patients avoided emergency departments. Additionally, a significantly higher proportion of children was managed via the non-operative management during the COVID-19 pandemic in comparison to the pre-pandemic period (62).

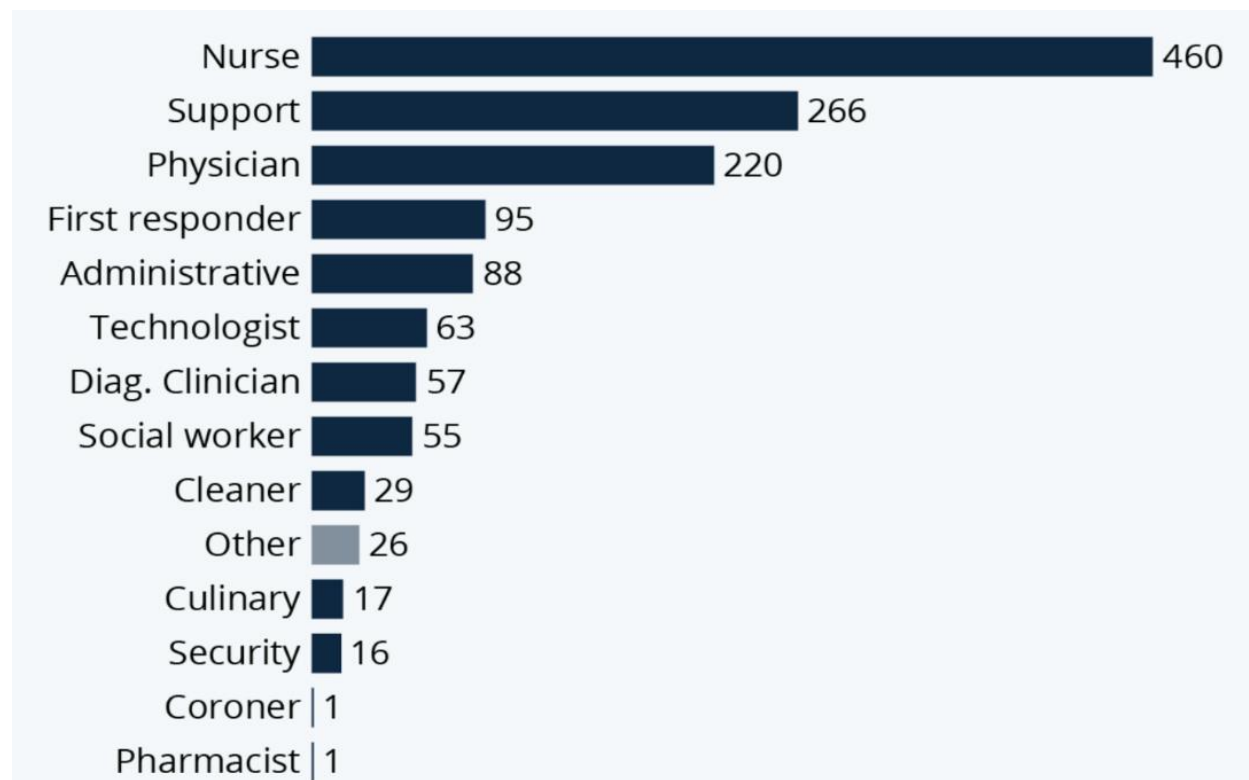


Figure 8. The death toll of US health care workers up to December 23, 2020. Source: Kaiser Health News/ The Guardian.

This behavior puts such patients at risk of increased morbidity and mortality, and such outcomes alongside other consequences of delayed diagnosis and treatment can create an even bigger burden on the healthcare system by prolonging the hospital stay which in turn also increases the financial burden on both the healthcare and the patient (60).

Testicular torsion is an example of a condition where a delay in hospital admission can negate all possible attempts to recover the testis, even with correct and rapid diagnosis and proper surgical skills, because, as previously mentioned, if more than 6 hours pass between onset and treatment the chances of testis surviving drop sharply (17, 18, 53–56). The less frequent hospital attendance for patients with acute testicular pain requiring surgical exploration was documented in at least one study, and such conditions predispose to higher possibility of undiagnosed testicular torsion in the community (63). Furthermore, backing this concern are multiple studies showing a higher incidence in orchiectomy procedures through the pandemic period when comparing it to the retrospective timeframe of the previous year(s) (64, 65).

2. OBJECTIVES

2.1. AIM OF STUDY

The purpose of this study is creating a meta-analysis which investigates comparative studies that focus on how COVID-19 pandemic impacted pediatric testicular torsion. This study investigates this impact by comparing three parameters: orchiectomy rate, the fraction of children presenting with a delay ($>24h$), and the duration of symptoms.

2.2. HYPOTHESIS

We propose a hypothesis that there will be an increase in the percentage of testicular torsion patients with a delayed presentation throughout the time of COVID-19 pandemic occurrence. We therefore also hypothesize that there will be prolonged duration of symptoms and a higher orchiectomy rate throughout the time of COVID-19 pandemic occurrence compared to the pre-pandemic levels.

3. PATIENTS AND METHODS

3.1. STUDY DESIGN

This diploma thesis was designed to be a meta-analysis of six studies, of these, five are designed as a retrospective study and one as a prospective cohort, focusing on the influence COVID-19 pandemic had on various outcomes of testicular torsion by measuring time before presentation in the emergency department, the duration of symptoms and the proportion of those cases resulting in an orchiectomy. Prespecified protocol was not registered prior to performing this analysis, likewise there was no requirement for an approval from the Ethics Committee of the University of Split, School of Medicine for this study design. This study was performed under the Department of Pediatric Surgery, University Hospital of Split in Croatia with collaboration from the Department of Pediatric surgery, Kokilaben Dhirubhai Ambani Hospital, Mumbai in India.

3.2. SEARCH STRATEGY

The literature exploration for this study was performed in accordance with the PRISMA guidelines (Preferred Reporting Items for Systematic Reviews and Meta-Analyses) (66). Student and mentor conducted on their own a preliminary literature search in the PubMed database on August 30, 2021. Following the confirmation of absence of any published meta-analysis investigating this subject, mentor and student searched through the PubMed, Web of Science, Scopus, and EMBASE literature bases (Table 1) during the same day. The search keywords utilized were: (COVID-19 OR novel coronavirus OR coronavirus OR SARS-CoV-2) AND (orchiopexy OR testicular torsion OR orchiectomy OR orchidectomy OR orchidopexy). Once the articles deemed relevant were singled out, any duplicates were removed. The records that were left remaining were subjected to screening by the established eligibility criteria in order to pick the relevant articles for inclusion in the meta-analysis. No grey literature search was performed and no external authors were contacted for additional data nor to obtain additional studies. If any discrepancy concerning the search strategy between two investigators was revealed, this was addressed and resolved by joint discussion involving the input of an external expert from the Department of Pediatric surgery, University Hospital of Split.

Table 1. Detailed search strategy.

Database	Studies
PubMed	20
Web of science	14
SCOPUS	12
EMBASE	22
Total	68
Duplications	38
After duplication removal	30

EMBASE – Excerpta Medica dataBASE

3.3. ELIGIBILITY CRITERIA

In order for obtained studies to be selected for inclusion in this analysis, they needed to satisfy the criteria for inclusion in accordance to Population, Intervention, Comparison, Outcome and Study design (PICOS) questionnaire, as follows:

1. **Patient population:** This included all patients less than 18 years of age that suffered from testicular torsion (as a clinico-radiological diagnosis) and presented during COVID-19 pandemic.
2. **Intervention:** Consisted of detorsion followed either by orchidopexy or by orchidectomy.
3. **Comparison:** Patients suffering from testicular torsion with a similar course of treatment that presented during the pre-pandemic period.
4. **Outcome:** The symptoms duration (the average time from onset until the presentation in the emergency department), the fraction of patients admitted with a delay in presentation (>24 hours), and the fraction of patients requiring an orchiectomy are the outcomes investigated in this analysis.
5. **Study Design:** Each comparative study in which orchiectomy rates were researched has been found eligible to be included. Furthermore, the location of torsion (left/right) or the type of operation (scrotal/inguinal) were not the eligibility criteria investigated in this analysis. All review articles, case series, expert opinions, letters toward editor, editorials, and commentary articles were left out. Additionally, the studies with the full-texts unavailable were also not included.

3.4. DATA SYNTHESIS

Version 15.24 of Microsoft Excel spreadsheets were utilized to extract data. We extracted the data for each individual study, including the overall sample size, the proportion of children requiring orchiectomy, and the number of subjects in each patient group, the incidence of torsion (per month or per week) in both groups, the proportion of children with delayed presentation, the average duration of symptoms, and the average age at presentation. Furthermore, information about the authors first name, the year when the study was published and its design type were also included.

3.5. METHODOLOGICAL QUALITY ASSESSMENT

Two investigators independently performed the quality assessment utilizing the Downs and Black scale (Table 2) (67). The scale can yield a total score between 0 and 32, in accordance to its 27 possible items of assessment. The aforementioned scoring was utilized and each study underwent an assessment concerning the risk of bias, with possible declarations for amount of bias classified as low (scores above 23), moderate (score ranging between 16 and 23), or high (score ranging from 0 to 15). Subsequently, we incorporated kappa statistics, utilizing this method to adjudicate the inter-observer agreement with regards to the Downs and Black scores (68). The agreement is therefore judged and graded into five classes: slight (values between 0 and 0.20), fair (0.21–0.40), moderate (0.41–0.60), substantial (0.61–0.80), with the highest score of almost perfect with values ranging from 0.81 and 1.

Table 2. Downs and Black scale scores for the included studies by Observer 1 and Observer 2. The total scores and inter-observer agreement are also depicted in this table.

Study	Reporting	External validity	Internal validity-bias	Internal validity-confounding	Power	Total scores
<i>Methodological assessment by Observer 1</i>						
Nelson et al., 2020	9	3	5	1	1	19
Holzman et al., 2021	10	3	5	1	1	20
Lee et al., 2021	9	3	5	2	0	19
Littman et al., 2021	9	3	5	2	0	19
Pogorelić et al., 2021	9	3	5	2	0	19
Shields et al., 2021	9	3	5	1	0	18
<i>Methodological assessment by Observer 2</i>						
Nelson et al., 2020	8	3	5	2	1	19
Holzman et al., 2021	10	3	5	1	1	20
Lee et al., 2021	9	3	5	2	0	19
Littman et al., 2021	9	3	5	2	0	19
Pogorelić et al., 2021	9	3	5	1	0	18
Shields et al., 2021	9	3	5	1	0	18
<i>Total scores and inter-observer agreement</i>						
Study	Observer 1	Observer 2	Mean	Kappa value	P	
Nelson et al., 2020	19	19	19	0.957	<0.0001	
Holzman et al., 2021	20	20	20			
Lee et al., 2021	19	19	19			
Littman et al., 2021	19	19	19			
Pogorelić et al., 2021	19	18	18.5			
Shields et al., 2021	18	18	18			

3.6. STATISTICAL ANALYSIS (QUANTITATIVE SYNTHESIS)

The baseline data were extracted, followed by their expression as mean or median average, as numbers or as proportions and ranges. Cochrane Collaboration system RevMan 5.4 was chosen to conduct this meta-analysis. Risk ratio and mean difference, with their respective 95% confidence intervals were calculated for both dichotomous and for continuous outcomes in each study respectively. Subsequently, the Mantel-Haenszel and inverse variance (IV) were the methods utilized to estimate the pooled risk ratio and weighted mean difference respectively. I^2 statistics were utilized for the evaluation of the level of heterogeneity within the included studies. If the

heterogeneity was found to be substantial, a random-effects model was selected ($I^2 > 50\%$). statistical significance was assigned to studies with a P -value of under 0.05. In this analysis, for the purpose of convenience, Group A and Group B were assigned to patients which were admitted during COVID-19 pandemic and prior to the COVID-19 pandemic respectively.

4. RESULTS

4.1. STUDY CHARACTERISTICS

The database was searched and yielded 68 articles according to our search criteria, however 38 of which were found to be duplications. Following the exclusion of these 38 articles, the 30 that remained were investigated for eligibility on the basis of their abstract (Figure 9). The screening of abstracts resulted in the removal of 22 further articles. Full text evaluation resulted in removal of two more, as they were case reports (69, 70). The final meta analysis consisted of the remaining six studies (66, 67, 71–74). Of those, five had a retrospective study design (66, 67, 72–74). Holzman et al. was a prospect cohort study with pre-pandemic group retrospectively compared (71). Finally, 711 patients, 238 in group A, and 473 in B, have been included in the meta-analysis.

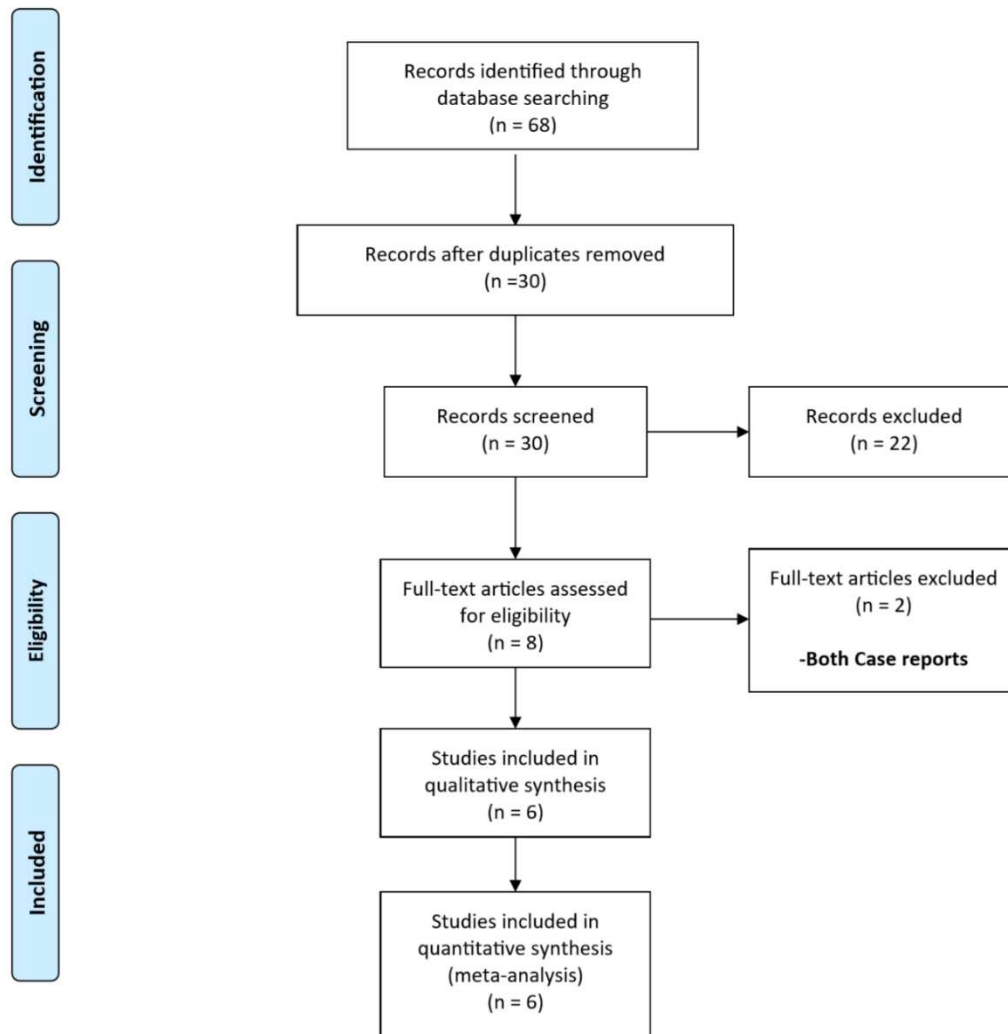


Figure 9. the method of screening for relevant articles utilizing PRISMA (Preferred Reporting Items for Systematic Review and Meta-Analysis) flow diagram.

All included studies with their baseline characteristics are presented in table 3. Neither study found a significant difference concerning the age of presentation comparing the two groups. Excluding the study by Lee et al. (72) all other described an increase in incidence of testicular torsion in the A group. Four of six studies also investigated the proportion of patients referred from other centers/hospitals (71–74). No significant difference was discovered between group A and B concerning the proportion of referred patients. The side of the torsed testicle and the severity of torsion were only investigated by two of the included studies (66, 67). The baseline findings within included studies are presented in Table 4.

Table 3. Baseline information concerning the selected studies

Author	Study design	No of patients		Percent of patients referred		Median (IQR) age at presentation; in years		Incidence of torsion per month	
		A	B	A	B	A	B	A	B
Nelson et al., 2020	Retro	17	77	47	49	15.2 (14.2-16)	14.2 (12.6-15.8)	1.3 [§]	0.7 [§]
Holzman et al., 2021	Pro	84	137	43	45	13.1 (10.7-14.7)	13.7 (11.6-15.2)	16.5	10.5
Lee et al., 2021	Retro	27	55	44	55	14 (13-15)	14 (12-15)	3.86	3.93
Littman et al., 2021	Retro	21	57	62	71	12.9 (2.1)*	12.9 (2.6)*	3 [§]	1.6 [§]
Pogorelić et al., 2021	Retro	51	68	-	-	15 (14-16)	14 (13-16)	5.6	4.8
Shields et al., 2020	Retro	38	79	-	-	13 (12-14)	14 (12-15)	38 [†]	10.8 [†]

Abbreviations: Retro, retrospective study, Pro, prospective cohort, A and B, groups A (pandemic) and B (pre-pandemic) patient groups.

*Mean (range).

§ Incidence per week.

† Incidence over a 12 month period

Table 4. Studies reviewed in the meta analysis and their findings.

Author	Period of observation		Average duration of symptoms (standard deviation) in hours		Orchiectomy rate	
	A	B	A	B	A	B
Lee et al., 2021	March 11, 2020- Oct 1, 2020	March 11- Oct 1, 2018 & 2019	8.8 (7.6)	23.2 (32.0)	33.3%	50.9%
Holzman et al., 2021	March-July, 2020	Jan, 2019-Feb, 2020	23.8 (32.1)	13.2 (18.0)	40.5%	29.2%
Nelson et al., 2020	March-May, 2020	Jan, 2018-Feb, 2020	14.1 (30.6)	8.0 (11.6)	29.4%	16.9%
Shields et al., 2021	March-Dec, 2020	Same months of 2015-2019	23.0 (33.1)	20.3 (32.5)	50%	38%
Pogorelić et al., 2021	March 11-Dec 31, 2020	Jan 1, 2019-March 10, 2020	22.3 (32.8)	10.3 (14.4)	43.1%	16.2%
Littman et al., 2021	March 15-May 4, 2020	Same months of 2015-2019	21.3 (29.7)	23.2 (35.0)	25%	44.7%

Abbreviations: A and B, patient groups A (pandemic) and B (pre-pandemic). Jan – January; Feb – February; Oct – October; Dec – December; SD – Standard Deviation.

4.2. SUMMARY OF THE INCLUDED STUDIES

Nelson et al., 2020 (74)

This retrospective study from the United States of America (USA) included 94 patients (pandemic/pre-pandemic=17/77) admitted with testicular torsion. Duration of symptoms and the rate of orchiectomies were compared between the pandemic (three-month period) and before the pandemic (fourteen-month period). Of note was a significant rise in the incidence of torsion during the period of the pandemic, however the study discovered no difference in the orchiectomy rates and duration of symptoms between the two groups. The time under infarction (the time from symptom onset to entry in the operation room) was also shown to be similar between two groups.

Holzman et al., 2021 (71)

A multicenter study, conducted within seven pediatric hospitals in Canada and the USA. The patients with testicular torsion admitted to these hospitals were prospectively enrolled at the time of the pandemic (five-month period). The mean duration of symptoms and the rate of orchiectomies in these patients was compared with patients presented with torsion in the preceding

fourteen months. There was a significantly longer mean duration of symptoms observed in the pandemic period (17.9 versus 7.5 hours; $P=0.04$). However, there was no statistical significance in orchiectomy rates when comparing the two groups.

Lee et al., 2021 (72)

This study is a retrospective study conducted in the institution of tertiary care in the USA. The characteristics of the patients and their outcomes were compared between 55 and 27 patients presenting with torsion during the pandemic (March - October 2020) with pre-pandemic (same time frame in 2018 and 2019) period. Interestingly, the average duration of symptoms was significantly shorter in the pandemic group. Also, the proportion of children with the delayed presentation was low in the pandemic group. However, the parameter of orchiectomy rate did not produce a significant difference between the group A and B.

Littman et al., 2021 (73)

This study conducted in USA is a retrospective study with a total of 78 patients with testicular torsion. Of these, 57 and 21 subjects belonged to the pandemic (seven-week period) and the pre-pandemic (same time-frame in the preceding five years) groups respectively. When investigating the characteristic of patients at presentation and the orchiectomy rates, no significant difference was reported among the two patient groups.

Pogorelić et al., 2021 (66)

This is a retrospective study conducted in Croatia, in six medical centers. The outcomes of two groups of patients with testicular torsion, i.e. those presenting during the pandemic (March 11th, 2020 – December 31st, 2020) and prior to the pandemic (January 1st, 2019- March 10th, 2020) were compared. The duration of symptoms was reported to be significantly higher among the pandemic group with 47% of patients presenting to the hospital 24 hours following the onset of symptoms. In comparison, a delayed healthcare presentation was seen in <10% of the patients during the pre-pandemic period. Also, the orchiectomy rates were observed to be significantly higher (43% vs. 16%; $P=0.001$) during the period of the pandemic.

Shields et al., 2021 (67)

A retrospective study conducted in the USA. The characteristics and outcomes of 38 and 79 children presenting with testicular in the group A (pandemic period, ten-month period in 2020) and before the pandemic (similar months of 2019) respectively, were compared. The study found a significantly higher incidence in testicular torsion during the period of the pandemic when compared with the pre-pandemic period. Both the duration of symptoms and the orchiectomy rate were shown to be significantly higher during the pandemic. However, those differences were not statistically significant.

4.3. METHODOLOGICAL QUALITY ASSESSMENT

Table 2 depicts the the analysis of quality independently performed by both observers. The included studies had an average Downs and Black score ranging between 18 and 20, and all of them were found to have a moderate risk of bias. Holzman et al (71) and Shields et al (67) had the lowest and highest risk of biased investigating, respectively. Next, the inter-observer agreement for Downs and Black scores was adjudged by the kappa statistics and was found to be high on perfect (Kappa=0.957; $P<0.001$).

4.4. OUTCOME ANALYSIS

4.4.1. DURATION OF SYMPTOMS

The average duration of symptoms (in hours) was reported by all six studies (66, 67, 71–74). Pooling the data (Figure 10) revealed that there was in fact no significant difference when it comes to the duration of symptoms (on average) between the comparative groups (WMD: 2.6, 95% CI ranged from 6.78 to 11.99, P -value of 0.59). For this outcome, the heterogeneity among the reviewed studies was tested, and proved to be statistically significant ($I^2=78\%$, $P=0.0004$).

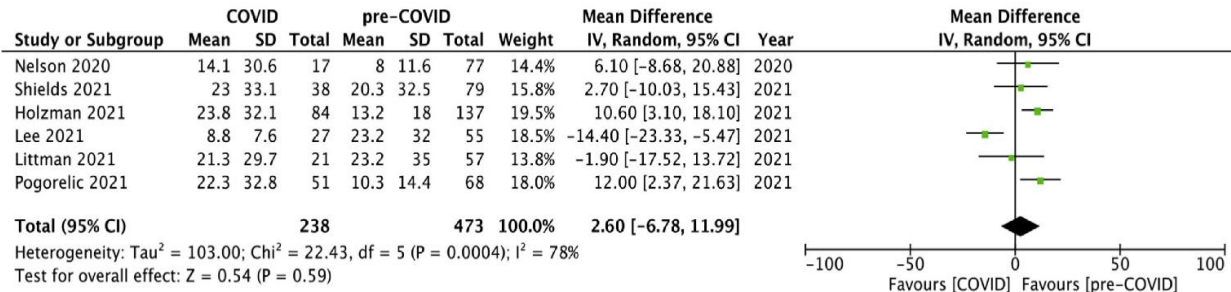


Figure 10. Two groups are compared using the Forest plot method, COVID (group A) versus pre-COVID (group B), in terms of the average duration of symptoms (hours). COVID, Coronavirus Disease 2019. CI, confidence interval. IV, inverse variance method..

4.4.2. PROPORTION OF CHILDREN WITH DELAYED PRESENTATION

Out of six studies, four have made investigations on this outcome (66, 71–73) between the two groups of patients. The delay in presentation was observed in 65/183 patients in group A and 94/317 patients in group B. When pooled risk ratio (Figure 11) was calculated it showed no significant difference in the delay of presentation between the two patient groups (RR=1.03, 95% CI 0.52–2.02, $P=0.94$). Concerning this outcome, the the heterogeneity was investigated and calculations proved it to be significant ($P=0.004$; $I^2=78\%$).

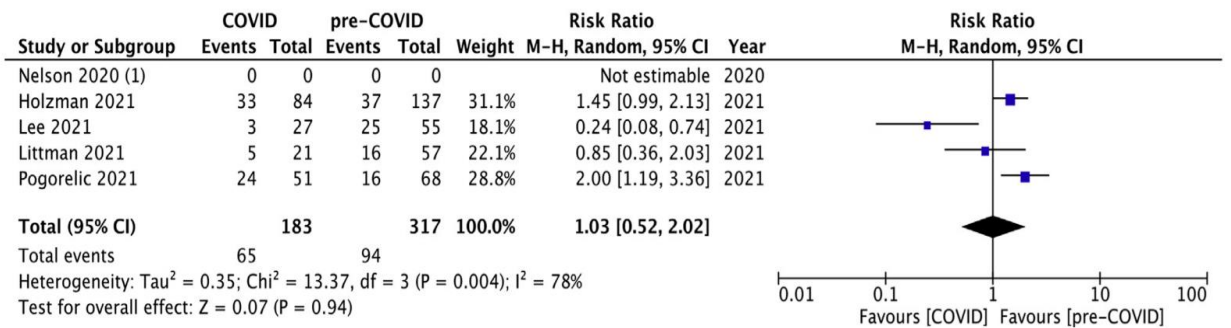


Figure 11. Forest plot graph depicting the two groups, COVID versus pre-COVID, concerning the proportion of children arriving with delayed presentation (over 24 h) to the healthcare facility. COVID, Coronavirus Disease 2019. MH, Mantel-Haenszel method. CI, confidence interval.

4.4.3. PROPORTION OF CHILDREN REQUIRING ORCHIECTOMY

This outcome was investigated in all studies in this review (66, 67, 71–74). 97 out of 237 patients from group A and 143 out of 463 patients from group B required orchiectomy. When data was pooled (Figure 12) no significant difference was observed in the rate of orchiectomies performed between the groups A and B (RR=1.23, 95% CI 0.82–1.84, $P=0.31$). Heterogeneity among the studies involved was estimated and was found to be statistically significant for this outcome ($P=0.01$; $I^2=66\%$).

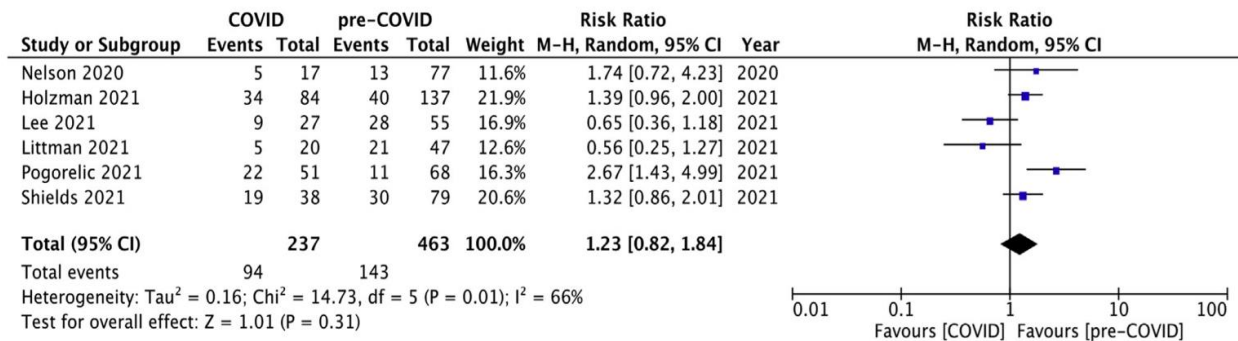


Figure 12. Depicted is the forest plot comparing the two groups, COVID (group A) against pre-COVID (group B), in terms of the orchiectomy rate. MH, Mantel-Haenszel method. CI, confidence interval.

5. DISCUSSION

When it comes to the management of testicular torsion, the time between onset and presentation is critically important as late diagnosis (and subsequent surgical treatment) put the viability of the affected testis at risk. On the other hand, over diagnosing testicular torsion in the presence of acute scrotum exposes patients to unnecessary surgery. The relationship between the time the affected testis spent under torsion (ischemic time) and testicular survival was investigated in a systematic review which compiled 30 studies with 2,166 cases in total (75). When surgery was performed within the "golden" 6 hours from the onset of symptoms 97.2% of cases resulted in a viable testis. As the time under torsion increases, the testicular survival drops to 24.4% after 24 to 48 hours of ischemia (19, 75). When it comes to the most common age when we expect testicular torsion studies observe a bimodal distribution with the first rise in incidence happening in neonatal period and the second peak occurring around puberty (76). A great challenge for physicians is a torsion happening in the antenatal period or early postnatal period as it presents as a scrotal swelling that is not always accompanied by pain and acute inflammation (77). In these cases we expect a very poor outcome as the normal testicular function is very rarely maintained.

COVID-19 pandemic has posed a significant challenge for the healthcare system, with the volume of new patients burdening otherwise comfortably operating healthcare institutions. This outbreak has created the need of treatment for a great number of infected patients along with other procedures. Recently a systematic review appeared with a purpose to demonstrate that during the pandemic there was exclusivity of the emergency department strictly for urgent cases and oncological interventions, and the hypothesis was proven to be correct (78). In the following time, urologists conducted more research investigating COVID-19 influence on urgent cases, one of such articles found that direct emergency department visits from patients dropped from 219 to 107 after the pandemic hit, but it also found that those patients arriving to the emergency department on a referral from their general practitioner visited the emergency department at a similar rate (74 to 72) when observed in identical time periods (from March 9th to April 14th) in 2020 (during the time of COVID-19 pandemic) and 2019 (before the pandemic) (79). This article also helped highlight the fact that frequency of visitations for the following emergency conditions: acute urinary retention, cystitis, sepsis, hematuria, trauma and acute scrotum remained the same when compared in the scope of these two time periods (79). It is noteworthy that these patients may be infectious at admission; therefore, studies have suggested that when there is a case in which a patient presents to the emergency department suffering from ongoing COVID-19 infection,

maximum efforts should be utilized to evaluate the possibility of postponing the surgical intervention to the point when the patient is no longer posing a risk of infection or is suffering a risk of perioperative complications due to the infection (78). Consequently, surgeons may find themselves with a limited treatment options available, one example is the discouraged use of laparoscopic techniques in infected patients because of concerns that by such intervention the virus located in the peritoneum is released as an aerosol which puts staff and the environment at risk of contamination (78, 80).

All emergency surgeries have been affected by the pandemic in one way or another, however the studies included in this review directed their research at testicular torsion, comparing between the outcomes of such conditions during the time of the pandemic and prior to the pandemic. The investigation concentrated on three outcomes: the mean time of duration of symptoms, the fraction of children with a delay in presentation (>24 h), and the proportion of such patients requiring orchidectomy. No statistically significant discrepancy in the mean duration of symptoms between the group A and B was found. While in three of the included studies (67, 73, 74) no significant discrepancy in the mean duration of symptoms was observed, the articles by Holzman et al. (71) and Pogorelić et al. (66) did demonstrate a significantly increased average duration of symptoms during the pandemic. Rather interestingly, in one of the included studies, the average duration of symptoms in cases presented during the pandemic was found to be shorter when comparing it to pre-pandemic cases (72). Secondly, the fraction of patients with delayed presentation also showed no difference between the group A and B. While two studies depicted a higher proportion during the pre-pandemic period (72, 73) the other two demonstrated a higher proportion of patients with delayed presentation during the COVID-19 pandemic (66, 71). Finally, in terms of orchidectomy rates no significant difference between the two patient groups was found. While several studies did show a higher proportion of orchidectomies performed in the period of COVID-19 pandemic, only one study proved statistically a significant change in the proportion of orchidectomies performed, with the rate of orchidectomy procedures between cases occurring during pandemic and pre-pandemic periods of 43% vs. 16%, respectively (66).

The exact variable causing the outcome variations between the studies included is unknown. One possible difference that can cause such variations lies in their sample size and study designs. Studies conducted in one center, with limited sample size (67, 72–74) were the ones

showing no significant difference in the parameters investigated, while these discrepancies were statistically significant in poly-center studies providing more abundant sample size (66, 71). More non-modifiable variables that may affect individual studies and their findings are the travel time between the patient's home and the healthcare institution, the availability of centers that provide surgical care through the ongoing pandemic, a readily available surgeon, etc. Although significantly important, the transfer rates of the hospital show minor differences between the pandemic and pre-pandemic time frames (71). The nature of the condition that provokes embarrassment among the patients and lack of parental awareness in some regions might be a factor that contributes to a higher delay when it comes for the patient to seek treatment. Furthermore, the time frame between the diagnosis and onset of surgical intervention was taken into account when measuring time under ischemia. The delayed results of COVID testing before the surgery could potentially have a consequence of elevated orchietomy rates during the pandemic period. But, even with all of this taken into account, the analysis we here conducted did not prove an existence of a significant discrepancy in the pooled estimation for the outcome for the groups A and B. This leads us to believe that the observed variations among the studies involved in this analysis are geographic and seasonal in origin, with the fulminant nature of the disease, dramatic symptomatology and urgency of investigated condition ultimately take precedence over all these subtle variations.

This review and its results need to be interpreted within the context of its few limitations. All of the included comparative studies have been found having an moderate risk of bias to begin with. There is also limited sample size for these studies. In addition, all but one study were retrospective in nature which can stem bias due to variable reporting. Non-uniform reporting in one case of the study outcomes (the fraction of patients presenting with a delay in admission) was observed between these studies. Of these six studies, Only four reported this outcome. Similar variable reporting was discovered among the baseline characteristics (percentage of patients admitted via referrals). Thirdly, in this meta-analysis there was pooling of heterogenous data ($I^2 > 50\%$ for all outcomes). The subjects were not only from different locations geographically, but also were recruited in different month of the year. In fact, some studies even had their patients and controls treated in different months of the year (66, 71, 74). This can stem variations in outcome as previously published studies have demonstrated the difference in seasonal occurrence of testicular torsion (13). Also, additional factors, including but not limited to: the vicinity of the

healthcare facility, the quantity of healthcare institutions providing appropriate surgical treatment through the pandemic, a readily available surgeon proficient in this intervention, have been shown to affect the study outcomes. Finally, the surgeries performed on these patients were by different surgeons. This can also have an impact on the orchidectomy rates. Further studies desirably ones having a larger and more homogeneous sample size need to be conducted before a definite conclusion can be drawn.

To our best knowledge, our present analysis is the only one comparing the outcomes of patients presenting with acute testicular torsion during the pandemic and pre-pandemic periods. However, due to the existence of moderate risk of bias, the confidence in the evidence provided by the included studies remains limited. The strengths of this review involve reporting and external validity on the other hand the weaknesses lie in internal validity and power.

6. CONCLUSION

The results of this meta-analysis demonstrate no significant discrepancy in the time under symptoms, the fraction of children with delayed presentation to a medical facility, and the frequency of orchidectomy procedures between patients suffering from acute testicular torsion who presented during the pandemic and those treated in the period before the pandemic. We are however prevented when it comes to estimating the overall effect by the presence of moderate risk of bias among the studies included in this analysis. Further studies with a larger and more homogeneous study sample are needed before a definite conclusion can be drawn.

7. REFERENCES

1. Moharit NH, Krahn HP. Acute scrotum in children with emphasis on torsion of spermatic cord. *J Urol.* 1970;104:610.
2. Knight PJ, Vassy LE. The diagnosis and treatment of the acute scrotum in children and adolescents. *Ann Surg.* 1984;200:664–73.
3. Župančić B. Akutni skrotum. *Paediatr Croat.* 1999;43:175–80.
4. Holcomb GW, Murphy JP. *Aschraft's pediatric surgery*, 7th ed, Philadelphia: Saunders Elsevier; 2019. p. 846.
5. Virtanen HE, Toppari J. Epidemiology and pathogenesis of cryptorchidism. *Hum Reprod.* 2008;14:49–58.
6. Mäkelä E, Lahdes-Vasama T, Rajakorpi H, Wikström. A 19-year review of paediatric patients with acute scrotum. *Scand J Surg.* 2007;96:62–6.
7. Cavusoglu YH, Karaman A, Erdogan D, Aslan MK, Varlikli O, Cakmak O. Acute scrotum. Etiology and management. *Indian J Pediatr.* 2005;72:201–3.
8. Jefferson RH, Pérez LM, Joseph DB. Critical analysis of the clinical presentation of acute scrotum: A 9-year experience at a single institution. *J Urol.* 1997;158:1198–200.
9. Edelsberg JS, Surh YS. The acute scrotum. *Emerg Med Clin North Am.* 1988;6:521–46.
10. Duančić V. Razvitak urogenitalnog sustava. In: Švajger A, editor. *Osnove embriologije čovjeka*. 8th ed. Beograd-Zagreb, Medicinska knjiga; 1985. p. 129–46.
11. Krmpotić-Nemanić J. Systemata genitalia, spolni organi. In: Krmpotić-Nemanić J, Marušić A, editors. *Anatomija čovjeka*, 2nd ed. Zagreb, Medicinska naklada; 2007. p. 367–86.
12. Moore KL. Pelvis and Perineum. In: Taylor C, Heise J, Montalbano J, editors. *Clinically oriented anatomy*. 6th ed. Philadelphia: Lippincott Williams & Wilkins; 2009. p. 326–439.
13. Pogorelić Z, Mustapić K, Jukić M, Todorčić J, Mrklić I, Meštrović J et al. Management of acute scrotum in children: a 25-year single center experience on 558 pediatric patients. *Can J Urol.* 2016;23:8594–601.
14. Williamson RC. Torsion of the testis and other allied conditions. *Br J Surg.* 1976;63:465–76.

15. Melekos MD, Asbach HW, Markou SA. Etiology of acute scrotum in 100 boys with regard to age distribution. *J Urol*. 1988;139:123–5.
16. Edelsberg JS, MPH, Surh YS. The acute scrotum. *Emerg Med Clin North Am*. 1988;6:521–44.
17. Hermann D. The pediatric acute scrotum. *Pediatr Ann*. 1989;18:198–204.
18. Pogorelić Z, Mrklič I, Jurić I. Do not forget to include testicular torsion in differential diagnosis of lower acute abdominal pain in young males. *J Pediatr Urol*. 2013;9:1161–5.
19. Pogorelić Z, Mrklič I, Jurić I, Biočić M, Furlan D. Testicular torsion in the inguinal canal in children. *J Pediatr Urol*. 2013;9:793–7.
20. Kylat RI. Perinatal testicular torsion. *Arch Pediatr*. 2021;28:75–9.
21. Fenner MN, Roszart DA, Texter JH. Testicular scanning: evaluating the acute scrotum in the clinical setting. *Urology*. 1991;38:237–41.
22. Nassiri N, Zhu T, Asanad K, Vasquez E. Testicular Torsion From Bell-clapper Deformity. *Urology*. 2021;147:275.
23. Ciftci AO, Senocak ME, Cahit Tanyel F, Buyukpamukcu N. Clinical predictors for differential diagnosis of acute scrotum. *Eur J Pediatr Surg*. 2004;14:333–8.
24. Baruch K, Zlotzkevic L, Horne T, Efrati Y, Serour F, Lotan G. Epididymis in childhood: A clinical retrospective study over 5 years. *IMAJ*. 2001;3:833–5.
25. Wein AJ, McDougal SW. Inflammatory conditions of the male genitourinary tract: prostatitis and related conditions, orchitis, and epididymitis. In: McDougal SW, editor. *Campbell-Walsh Urology*. 11th ed. Philadelphia, Saunders Elsevier; 2015: p. 304–34.
26. Kliegman RM. Viral Infections. In: Behrman RE, editor. *Nelson Textbook of Pediatrics*. 20th ed. Philadelphia, Saunders Elsevier; 2016; p. 1538–672.
27. Trojian TH, Lishnak TS, Heiman D. Epididymitis and orchitis: an overview. *Am Fam Physician*. 2009;79:583–7.
28. Manson AL. Mumps orchitis. *Urology*. 2004;36:355–8.

29. Buckley JC, McAninch JW. Use of ultrasonography for the diagnosis of testicular injuries in blunt scrotal trauma. *J Urol*. 2006;175:175–8.
30. Deurdulian C, Mittelstaedt CA, Chong WK, Fielding JR. US of acute scrotal trauma: optimal technique, imaging findings, and management. *Radiographics*. 2007;27:357–69.
31. Pogorelić Z, Jurić I, Biočić M, Furlan D, Budimir D, Todorčić J et al. Management of testicular rupture after blunt trauma in children. *Pediatr Surg Int*. 2011;27:885–9.
32. Klin B, Lotan G, Efrati Y, Zlotkevich L, Strauss S. Acute idiopathic scrotal edema in children revisited, *J Pediatr Surg*. 2002;37:1200–2.
33. Sharma SB, Gupta V. Segmental testicular infarction. *Indian J Paediatr*. 2005;72:81–2.
34. Ruibal M, Quintana JL, Fernandez G, Zungri E. Segmental testicular infarction. *J Urol*. 2003;170:187–8.
35. Rabinowitz R. The importance of the cremasteric reflex in acute scrotal swelling in children. *J Urol*. 1984;132:89–90.
36. Baker LA, Sigman D, Matthews RI, Benson J. An analysis of clinical outcomes using color doppler testicular ultrasound for testicular torsion. *Pediatrics*. 2000;105:604–7.
37. Pepe P, Panella P, Pennisi M, Aragona F. Does color Doppler sonography improve the clinical assessment of patients with acute scrotum? *Eur J Radiol*. 2006;60:120–4.
38. Stehr M, Boehm R. Critical validation of colour Doppler ultrasound in diagnostics of acute scrotum in children. *Eur J Pediatr Surg*. 2003;13:386–92.
39. Coley BD, Frush DP, Babcock DS. Acute testicular torsion: Comparison of unenhanced and contrast- enhanced power Doppler US, color Doppler US and radionuclide imaging. *Radiology*. 1996;199:441–6.
40. Middleton WD, Siegel BA, Melson GL. Acute scrotal disorders: prospective comparison of color Doppler US and testicular scintigraphy. *Radiology*. 1990;177:177–81.
41. Yuan Z, Luo Q, Chen L. Clinical study of scrotum scintigraphy in 49 patients with acute scrotal pain: a comparison with ultrasonography. *Ann Nucl Med*. 2001;15:225–9.

42. Flores II, LG, Shiba T. Scintigraphic evaluation of testicular torsion and acute epididymitis. *Ann Nucl Med.* 1996;10:89–92.
43. Annand SS, Mukherjee PB, Kumar PG, Singh J. Scrotal Scintigraphy in a Case of Acute Scrotum. *MJAFI.* 2008;64:92–4.
44. Terai A, Yoshimura K, Ichioka K. Dynamic contrast-enhanced subtraction magnetic resonance imaging in diagnostics of testicular torsion. *Urology.* 2006;67:1278–82.
45. Masako D, Yuji W. MR Imaging of Acute Scrotum. *J Magn Reson Imaging.* 2011;34:1137–42.
46. Meštrovic J, Biočić M, Pogorelić Z, Furlan D, Družijanić N, Todorčić D et al. Differentiation of inflammatory from non-inflammatory causes of acute scrotum using relatively simple laboratory tests: prospective study. *J Pediatr Urol.* 2013;9:313–7.
47. Weiss AP, Van Heukelom J. Torsion of an undescended testis located in the inguinal canal. *J Emerg Med.* 2012;42:538–9.
48. Candocia FJ, Sack-Solomon K. An infant with testicular torsion in the inguinal canal. *Pediatr Radiol.* 2003;33:722–4.
49. Günther P, Rübber I. The acute scrotum in childhood and adolescence. *Dtsch Arztebl Int.* 2012;109:449–57.
50. Drlik M, Kocvara R. Torsion of spermatic cord in children: A review. *J Pediatr Urol.* 2013;9:259–66.
51. Saxena A, Castellani C, Rutenstock E, Höllwarth M. Testicular torsion: a 15-year single centre clinical and histological analysis. *Acta Paediatr.* 2012;101:282–6.
52. Mellick LB. Torsion of the testicle: it is time to stop tossing the dice. *Pediatr Emerg Care.* 2012;28:80–6.
53. Sessions AE, Rabinowitz R, Hulbert WC, Goldstein MM, Mevorach RA. Testicular torsion: direction, degree, duration and disinformation. *J Urol.* 2003;169:663–5.
54. Moyad R, Barnett B, Lapidus J, Soiderer MH. Therapy of questionably infarcted testis. *Invest Urol.* 1975;12:387–8.

55. Stasi C, Fallani S, Voller F, Silvestri C. Treatment for COVID-19: An overview. *Eur J Pharmacol.* 2020;889:173644.
56. Chung HS, Lee DE, Kim JK, Yeo IH, Kim C, Park J, et al. Revised triage and surveillance protocols for temporary emergency department closures in tertiary hospitals as a response to COVID-19 crisis in Daegu metropolitan city. *J Kor Med Sci.* 2020;35:e189.
57. Dolić M, Antičević V, Dolić K, Pogorelić Z. Questionnaire for Assessing Social Contacts of Nurses Who Worked with Coronavirus Patients during the First Wave of the COVID-19 Pandemic. *Healthcare (Basel).* 2021;9:930.
58. Lange SJ, Ritchey MD, Goodman AB, Dias T, Twentyman E, Fuld J et al. Potential indirect effects of the COVID-19 pandemic on use of emergency departments for acute life-threatening conditions - United States, January-May 2020. *Am J Transplant.* 2020;20:2612–17.
59. De Rosa S, Spaccarotella C, Basso C, Calabrò MP, Curcio A, Filardi PP et al. Reduction of hospitalizations for myocardial infarction in Italy in the COVID-19 era. *Eur Heart J.* 2020;41:2083–88.
60. Lazzerini M, Barbi E, Apicella A, Marchetti F, Cardinale F, Trobia G. Delayed access or provision of care in Italy resulting from fear of COVID-19. *Lancet Child Adolesc Health.* 2020;4:e10–e11.
61. McDonnell T, Nicholson E, Conlon C, Barrett M, Cummins F, Hensey C, et al. Assessing the impact of COVID-19 public health stages on paediatric emergency attendance. *Int J Environ Res Publ Health.* 2020;17:6719.
62. Pogorelić Z, Anand S, Žuvela T, Singh A, Križanac Z, Krishnan N. Incidence of complicated appendicitis during the COVID-19 pandemic versus the pre-pandemic period: A systematic review and meta-analysis of 2782 pediatric appendectomies. *Diagnostics (Basel).* 2022;12:127.
63. Norton SM, Considine S, Dowling C, D'Arcy F. Where are the paediatric patients with testicular torsion during the COVID-19 pandemic? *Ir J Med Sci.* 2021:1–4.
64. Pogorelić Z, Milanović K, Veršić AB, Pasini M, Divković D, Pavlović O et al. Is there an increased incidence of orchietomy in pediatric patients with acute testicular torsion during COVID-19 pandemic?-A retrospective multicenter study. *J Pediatr Urol.* 2021;17:479.e1–479.e6.

65. Shields LBE, Daniels MW, Peppas DS, Rosenberg E. Testicular torsion in patients with intellectual and developmental disabilities. *Glob Pediatr Health*. 2021;8:2333794X211059119.
66. Moher D, Liberati A, Tetzlaff J, Altman DG; PRISMA Group. Preferred reporting items for systematic reviews and meta-analyses: the PRISMA statement. *PLoS Med*. 2009;21;6:e1000097.
67. Downs SH, Black N. The feasibility of creating a checklist for the assessment of the methodological quality both of randomised and non-randomised studies of health care interventions. *J Epidemiol Community Health*. 1998;52:377–84.
68. Landis JR, Koch GG. The measurement of observer agreement for categorical data. *Biometrics* 1977;33:159–74.
69. Yu X. Caution of the etiology of testicular swelling in the context of COVID-19 pandemic-it may not be testicular torsion. *Pediatr Emerg Care*. 2021;37:e499.
70. Parrón D, Gartzia A, Iturregui AM, Imaz I, Manini C, García-Olaverri J, et al. SARS-CoV-2-Associated obliterative arteritis causing massive testicular infarction. *Clin Pract*. 2021;11:246–9.
71. Holzman SA, Ahn JJ, Baker Z, Chuang KW, Copp HL, Davidson J, et al. A multicenter study of acute testicular torsion in the time of COVID-19. *J Pediatr Urol*. 2021;478.e1-478.e6
72. Lee AS, Pohl HG, Rushton HG, Davis TD. Impact of COVID-19 pandemic on the presentation, management and outcome of testicular torsion in the pediatric population - an analysis of a large pediatric center. *Can J Urol*. 2021;28:10750–55.
73. Littman AR, Janssen KM, Tong L, Wu H, Wang MD, Blum E, et al. Did COVID-19 affect time to presentation in the setting of pediatric testicular torsion? *Pediatr Emerg Care* 2021;37:123–35.
74. Nelson CP, Kurtz MP, Logvinenko T, Venna A, McNamara ER. Timing and outcomes of testicular torsion during the COVID-19 crisis. *J Pediatr Urol* 2020;16:841.e1-e5.
75. Mellick LB, Sinex JE, Gibson RW, Mears K. A systematic review of testicle survival time after a torsion event. *Pediatr Emerg Care*. 2019;35:821–25.
76. Sharp VJ, Kieran K, Arlen AM. Testicular torsion: diagnosis, evaluation, and management. *Am Fam Physician*. 2013;88:835–40.

77. Pogorelić Z, Jukić M, Škrabić V, Mrklič I, Fridl Vidas V, Jurić I, et al. Bilateral simultaneous testicular torsion in a newborn: Report of a case. *Acta Medica (Hradec Kralove)*. 2017;60:120–23.
78. De Simone B, Chouillard E, Di Saverio S, Pagani L, Sartelli M, Biffi WL, et al. Emergency surgery during the COVID-19 pandemic: what you need to know for practice. *Ann R Coll Surg Engl*. 2020;102:323–32.
79. Cicerello E, Mangano MS, Cova G, Zordani A. Urological emergency activities during COVID-19 pandemic: Our experience. *Arch Ital Urol Androl*. 2020; 92:282–5.
80. Angelos G, Dockter AG, Gachabayov M, Latifi R, Bergamaschi R. Emergency colorectal surgery in a COVID-19 pandemic epicenter. *Surg Technol Int*. 2020;36:18–21.

8. SUMMARY

Objectives: This study aimed to investigate whether COVID-19 pandemic influenced the outcome of testicular torsion in three parameters: longer duration of symptoms, delay in the presentation to the medical facility, and orchidectomy rate when compared to the period prior to COVID-19 pandemic.

Methods: Four scientific bases were systematically searched for relevant articles. The terms used in the search were (coronavirus OR novel coronavirus OR COVID-19 OR SARS-CoV-2) AND (testicular torsion OR orchidopexy OR orchidectomy OR orchiectomy OR orchiopexy). All boys suffering from testicular torsion prior COVID-19 and those suffering during COVID-19 period were eligible by inclusion criteria. Two groups were compared by the average duration of symptoms, the fraction of patients who presented with a delay (>24 h), and by the proportion of patients requiring orchidectomy. Methodological quality assessment was performed using the Downs and Black scale.

Results: This review consists of six comparative studies, five of which are retrospective, and one prospective cohort. 711 patients in total were included, 473 of whom presented during the COVID-19 period. There was no significant discrepancy observed among the two patient groups in all three parameters: the average duration of symptoms (WMD: 2.6, 95% CI -6.78–11.99, $P=0.59$), the fraction of patients with delayed presentation (RR=1.03, 95% CI 0.52–2.02, $P=0.94$), and orchidectomy rate (RR=1.23, 95% CI 0.82–1.84, $P=0.31$). A moderate risk of bias was present in all included studies.

Conclusion: There was no statistically significant difference in the duration of symptoms, the fraction of patients with delayed presentation and the rate of orchidectomy procedures performed among the patients presenting with testicular torsion during COVID-19 pandemic and pre-COVID-19 pandemic. However, there is a limitation in strength of evidence in the comparative studies we included, the reason behind such limitation is a moderate risk of bias presented in these studies.

9. CROATIAN SUMMARY

Naslov rada: Usporedba ishoda torzije testisa u djece tijekom COVID-19 pandemije naspram perioda prije COVID-19 pandemije: Sustavni pregled i meta analiza

Ciljevi: Procijeniti je li pandemija bolesti korona virusa 2019 (COVID-19) rezultirala produljenim trajanjem simptoma, odgođenim dolaskom u medicinsku ustanovu i posljedično većim brojem orhidektomija u djece s torzijom testisa u usporedbi s razdobljem prije pandemije COVID-19.

Metode: Provedeno je sustavno pretraživanje četiri znanstvene baze podataka. Upotrijebljeni pojmovi za pretraživanje bili su (koronavirus ILI novi koronavirus ILI SARS-CoV-2 ILI COVID-19) I (torzija testisa ILI orhidektomija ILI orhiektomija ILI orhidopeksija ILI orhiepeksija). Kriteriji za uključivanje bili su svi dječaci s torzijom testisa tijekom trajanja pandemije COVID-19 i prije pandemije COVID-19. Usporedba prosječnog trajanja simptoma, udjela djece s odgođenom prezentacijom (>24 h) i udjela djece kojoj je potrebna orhiektomija napravljena je između dvije skupine. Za metodološku ocjenu kvalitete korištena je ljestvica Downs i Black.

Rezultati: Prikazana meta-analiza uključivala je šest komparativnih studija (pet retrospektivnih studija). Uključeno je ukupno 711 bolesnika (473 tijekom razdoblja COVID-19). Nema značajnih razlika u prosječnoj duljini trajanja simptoma (WMD: 2,6; 95% CI -6,78–11,99 $P=0,59$), udjelu djece s odgođenom prezentacijom (RR=1,03; 95% CI 0,52–2,02, $P=0,94$) kao ni u stopi orhiektomije (RR=1,23; 95% CI 0,82–1,84, $P=0,31$) između dvije ispitivane skupine bolesnika. Sve studije su imale umjereni rizik od pristranosti.

Zaključak: Trajanje simptoma, udio djece s odgođenom prezentacijom i stopa orhiektomije nisu se značajno razlikovali među djecom s torzijom testisa tijekom pandemije COVID-19 i prije pandemije COVID-19. Međutim, zbog umjerenog rizika od pristranosti, razina dokaza dostupnih usporednih studija je ograničena.

10. CURRICULUM VITAE

PERSONAL INFORMATION:

Name and surname:	Leon Artuković
Date and place of birth:	June 27 th 1998. Split, Croatia
Citizenship:	Croatian, United States
Address:	Domovinskog rata 74, 21312 Podstrana
E-mail:	artukovicleon@hotmail.com

EDUCATION:

2004 – 2012: Osnovna škola Strožanac

2012 – 2016: III. Gimnazija Split

2016 – 2022: Medical Studies in English at the Split School of Medicine

LANGUAGES:

Croatian (mother tongue)

English (C2)

PUBLICATIONS:

Pogorelić Z, Anand S, Artuković L, Krishnan N. Comparison of the outcomes of testicular torsion among children presenting during the Coronavirus Disease 2019 (COVID-19) pandemic versus the pre-pandemic period: A systematic review and meta-analysis. *J Pediatr Urol.* 2022. doi: 10.1016/j.jpuro.2022.01.005.