

# Comparison of surgical outcome in lapidus arthrodesis surgery - plantar vs. dorsomedial plating systems in a sample from Franconia

---

Lippuner, Johanna

Master's thesis / Diplomski rad

2023

Degree Grantor / Ustanova koja je dodijelila akademski / stručni stupanj: **University of Split, School of Medicine / Sveučilište u Splitu, Medicinski fakultet**

Permanent link / Trajna poveznica: <https://um.nsk.hr/um:nbn:hr:171:416424>

Rights / Prava: [In copyright](#)/[Zaštićeno autorskim pravom.](#)

Download date / Datum preuzimanja: **2024-11-25**



Repository / Repozitorij:

[MEFST Repository](#)



**UNIVERSITY OF SPLIT  
SCHOOL OF MEDICINE**

**Johanna Luise Lippuner**

**COMPARISON OF SURGICAL OUTCOME IN LAPIDUS ARTHRODESIS  
SURGERY – PLANTAR VS. DORSOMEDIAL PLATING SYSTEMS IN A SAMPLE  
FROM FRANCONIA**

**Diploma Thesis**

**Academic year:**

**2022/2023**

**Mentor:**

**Prof. Johannes Brachmann**

**Split, July 2023**

## Table of Content

1. INTRODUCTION.....	1
<b>1.1. Hallux Valgus</b> .....	2
1.1.1. Definition.....	2
1.1.2. Pathophysiology.....	2
1.1.3. Classification and associated Pathologies.....	4
1.1.4. Ethiology and Epidemiology.....	5
<b>1.2. Diagnostic Approach</b> .....	5
<b>1.3. Treatment</b> .....	9
1.3.1. Conservative Treatment.....	9
1.3.2. Surgical Treatment.....	9
<b>1.4. The Lapidus Procedure</b> .....	17
1.4.1. The Modified Lapidus Procedure.....	18
1.4.2. Complications.....	19
1.4.3. Plating Systems in Lapidus Procedure.....	20
2. OBJECTIVES.....	24
3. MATERIALS AND METHODS.....	26
<b>3.1. Data Sources and Study Objects</b> .....	27
<b>3.2. Collected Data and Measurements</b> .....	30
<b>3.3. Methodology of the Study</b> .....	32
<b>3.4. Statistical Analysis</b> .....	34
4. RESULTS.....	35
5. DISCUSSION.....	42
6. CONCLUSION.....	46
7. REFERENCES.....	48
8. SUMMARY.....	60
9. CROATIAN SUMMARY.....	62

## ACKNOWLEDGMENTS

*First of all, I want to express my appreciation and thanks to my mentor Prof. J. Brachman for giving guidance throughout the process of thesis writing. His feedback and continuous encouragement have greatly contributed to the successful completion of this study.*

*I would like to extend my sincere appreciation to Dr. W. Willauschus, alphaMED clinic Bamberg, for generously providing the essential data required for my research.*

*Dr. Willauschus's contribution played a pivotal role in the execution of my study and I am truly grateful for the time, effort and resources invested in collecting and sharing this valuable information.*

*Furthermore, I would like to acknowledge the remarkable support and assistance provided by F. Hüttner throughout this research endeavor. His willingness to answer my calls, even in the middle of the night, and his unwavering commitment to assisting me with subject-related questions have been invaluable. I would also like to extend my appreciation to the entire team of the Regiomed Klinikum Lichtenfels, especially to Dr. J. Harrer, U. Mandlmeier, Dr. M. Kapetanowski and M. Zivanovic for their support and cooperation during this research project. Their assistance in administrative matters, technical support, language skills and access to the literature have been instrumental in ensuring a smooth research process.*

*Additionally, I want to express my gratitude to my colleagues and friends, Julia, Justus and Marie, who provided valuable insights, engaged in stimulating discussions and offered critical feedback throughout the development of this thesis. Their collaborative spirit and intellectual exchange have significantly enriched my research journey.*

*Last but not least, I am deeply grateful to my family, my parents, my sister and my grandparents, for their unwavering encouragement and support during all phases of my academic pursuit. Their love, support and belief in my abilities have been a constant source of motivation and strength. I am forever grateful for your approval.*

*While the individuals mentioned above have been specifically acknowledged, I would like to express my appreciation to everyone who has contributed directly or indirectly to the completion of this thesis and medical studies. Your impact on my academic growth and personal development is immeasurable.*

*Thank you all for your invaluable contributions.*

## LIST OF ABBREVIATIONS

AOFAS	–	American Orthopedic Foot and Ankle Society
BMI	–	Body mass index
CT	–	Computed tomography
DASA	–	Distal articular set angle
DMAA	–	Distal metatarsal articulation angle
EHB	–	<i>(musculus)</i> Extensor hallucis brevis
EHL	–	<i>(musculus)</i> Extensor hallucis longus
HV	–	Hallux valgus
HVA	–	Hallux valgus angle
IMA 1-2	–	Intermetatarsal angle between the first and second metatarsal bones
IP	–	Interphalangeal (joint)
<i>m.</i>	–	Musculus
MA	–	<i>Metatarsus adductus</i>
MRI	–	Magnetic resonance imaging
MT	–	Metatarsal (bone)
MTP	–	Metatarsophalangeal (joint)
PASA	–	Proximal articular set angle
PROM(s)	–	Patient-reported outcome measure(s)
TMT	–	Tarsometatarsal (joint)
VAS	–	Visual analogue scale

## **1. INTRODUCTION**

## **1.1.Hallux Valgus**

### **1.1.1. Definition**

Hallux valgus (HV) was first described by Carl Heuter in 1871 (1) and represents the most common deformity of the human forefoot (2). HV is defined by deviation of the normal alignment of the great toe in relation to the articular surfaces of the first metatarsophalangeal (MTP) joint and is primarily visible as a lateral deviation of the proximal phalanx on the metatarsal head, which may progress to subluxation of the first MTP-joint (3).

Consequently, the deformity can arise either from medial deviation of the first metatarsal (*metatarsus primus varus*) as seen in splayfoot deformity with fan-shaped widening of the metatarsal rays (4) or, less commonly, from a lateral deviation of the first phalanx, also termed *hallux valgus interphalangeus* (5).

The term *hallux valgus superductus* applies if the hallux crosses over the second toe, *hallux valgus subductus* denotes the displacement of the hallux under the second toe (6).

The term “first ray” describes the first metatarsal bone in connection with the medial cuneiform bone, moving together as a single, unified arch segment by means of a stable union with a dense plantar ligament (7). In the literature, it is commonly referred to as only the “first metatarsal” to describe the combined kinematics of the first metatarsal-cuneiform arch segment (7–9), as will be done in this thesis.

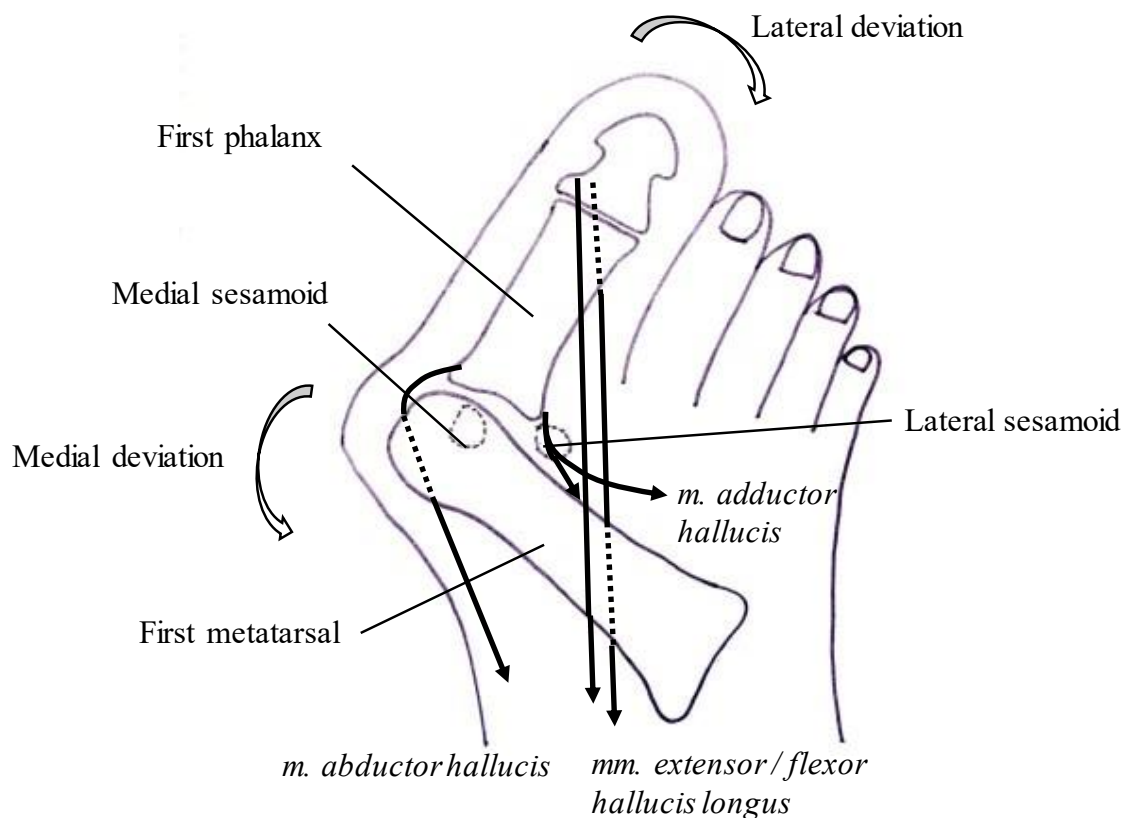
### **1.1.2. Pathophysiology**

The pathophysiology is complex, involving disbalances between the extrinsic and intrinsic muscles and the ligaments of the foot. The normal alignment of the first metatarsus is maintained by tension of the *musculus (m.) peroneus longus* laterally and the *m. abductor hallucis* medially, while collateral ligaments prevent movement in the axial or transverse plane at the first MTP-joint (4, 10). In progressive HV, the tensile strength of the medial collateral ligament weakens, leading to a lateral displacement of the first phalanx and valgus displacement of the first MTP-joint (10, 11).

The first metatarsophalangeal joint has a substantial role in the transfer of body weight during the gait cycle (13). The deformity worsens due to imbalance of moments acting on the first phalanx during gait. Plantar pressure is highest near the end of the stance, when the load carried by the hallux approaches 40% of the body weight (14).

To redirect the distribution of weight to the medial side of the hallux, gait compensations in form of walking with a laterally rotated foot angle or excess foot pronation can be observed (15–17). The ground force moment is countered mostly by the *m. flexor hallucis longus* in form of dorsiflexion of the hallux (18–20).

Snijders *et al.* introduced a model of these force phenomena to visualise the vicious cycle of valgus positioning of the hallux, with the medial component of the ground reaction force acting to increasingly displace the first metatarsal into adduction (20). Additionally, the misdirected moment action of the *m. flexor hallucis longus* shifts from a plantar direction to a lateral direction and therefore changing the joint direction from the normal sagittal plane to a transverse plane (17, 18). The biomechanics are visualised in Figure 1 (21).



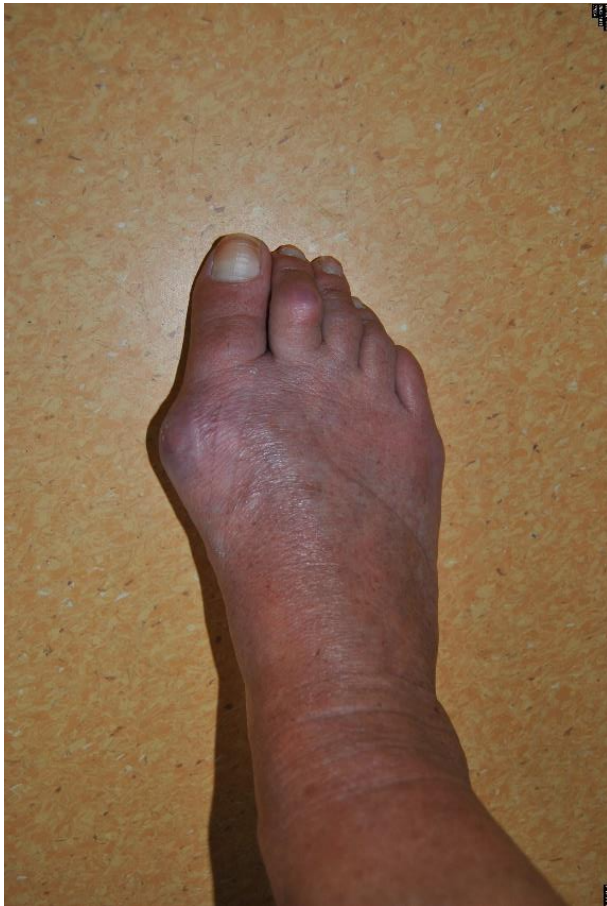**Figure 1.** Schematic representation of the pathophysiology of hallux valgus deformity. Adapted from Thieme Atlas of Anatomy: General Anatomy and Musculoskeletal System (21).

The directions of the arrows correspond to the direction of pull of the muscles listed above.



### 1.1.3. Classification and associated Pathologies

According to the beforementioned progressive pathology, HV deformity can generally be divided into two groups: congruent- and subluxated first MTP joint (19). The congruent first MTP-joint can be distinguished from the subluxated form by fully functional tightening of the plantar aponeurosis and a mechanically stable forefoot. Furthermore, the congruent first MTP-joint exerts only a pseudo-exostosis of the medial metatarsal head and pain is caused only by wearing closed, tight-fitted shoes. The subluxated first MTP-joint on the other hand, displays instability of the first forefoot ray and therefore transfers the problem towards the second forefoot ray, leading to mechanical and functional difficulties (22). Severe subluxation results in an uncovered medial aspect of the metatarsal articular surface that is exposed to trauma, giving rise to hypertrophy and leading to the classical clinical picture of HV (15) as depicted in Figure 2.



**Figure 2.** Clinical picture of hallux valgus (right foot - dorsal view) (by courtesy of Dr. W. Willauschus)

A preceding deformity to HV is the *metatarsus adductus* (MA) deformity, a congenital condition in which supination of the hindfoot through the subtalar joint leads to adduction of the metatarsals. The prevalence of MA in patients with HV is approximately 30% (23), further underlining the necessity for a comprehensive approach to the treatment of HV deformity.

HV is not only characterised by bony changes but also by extensive changes of the soft tissue arch and sesamoid mechanisms (24), especially in terms of subluxation of the sesamometatarsal articulation (15, 24).

It is commonly associated with a splay foot deformity and an overloading of the second to fourth metatarsal heads may cause midfoot pain (6), which may also be referred to as transfermetatarsalgia (26). According to Wülker and Schulze, metatarsalgia can be classified either as biomechanical or structural. Structural causes for metatarsalgia include degenerative, rheumatic, inflammatory and neoplastic changes (27). Transfermetatarsalgia is a biomechanical metatarsalgia (27) due to overload of the second to fourth metatarsal heads and may also arise iatrogenic after forefoot surgery with excessive shortening or elevation of the first metatarsal (28).

#### **1.1.4. Etiology and Epidemiology**

HV is a common, progressive forefoot problem with a predilection for women, a systematic review from 2015 proposing a female-male ratio of 10:1 (29). Tight-fitting and high-heeled shoes are one of the most important predisposing factors despite genetics (30). Further risk factors include a long first metatarsal bone and an oval shaped MTP joint articular surface (4). A higher body mass index (BMI) is unanticipatedly not involved in the pathogenesis and even inversely related to the odds of developing HV (31).

The inheritance seems to follow a pattern of autosomal-dominant hereditary transmission with incomplete penetrance (32). A genome-wide meta-analysis from 2020 identified a novel locus in the intronic region of *CLCA2* on chromosome 1, an expression quantitative trait locus for *COL24A1*, a gene belonging to the family of the collagen genes and having a potential role in the pathogenesis of HV (33).

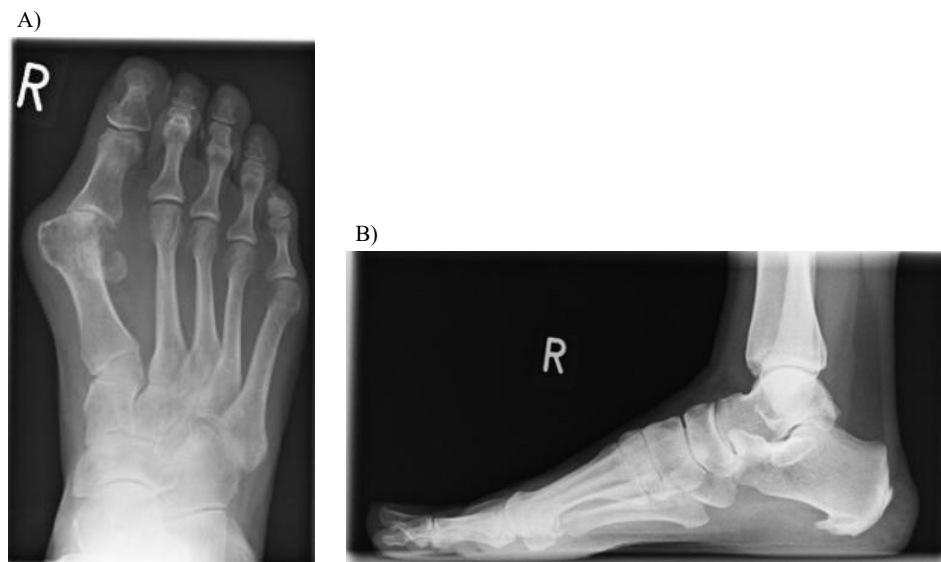
The prevalence is 23% in adults between 18 and 65 years of age, increasing with age to 35.7% in the population older than 65 years of age (34).

#### **1.2. Diagnostic Approach**

The diagnosis of HV is based on a clinical examination with adjunctive radiological imaging techniques to quantify the extent of the deformity. Patients typically describe a chronic sharp or deep pain at the MTP joint that worsens with ambulation, occasionally being accompanied by aching pain at the head of the second metatarsal and by a tingling or burning pain at the dorsal part of the deformity due to irritation of the medial dorsal cutaneous nerve (10).

Morton *et al.* published a study on hypermobility of the first forefoot ray and designated it as the primary cause of forefoot-pathologies (35). A pathological mobility is defined as a dorsal displacement of the first metatarsal head exceeding five to eight millimeters compared to the other metatarsal heads under simulated mechanical strain (36).

The physical examination encompasses not only the HV deformity with associated blisters or ulcerations, but also associated pathologies that should be considered when contemplating treatment options, including hallux rigidus, osteochondrosis, subluxation of the second MTP-joint and especially the associated splay foot deformity (*pes planovalgus*) (22). Radiological examination includes weightbearing *anteroposterior* or *dorsoplantar* (Figure 3A) and a strict *lateral* view (Figure 3B) (22).



**Figure 3.** Radiograph of the foot (by courtesy of Dr. W. Willauschus)

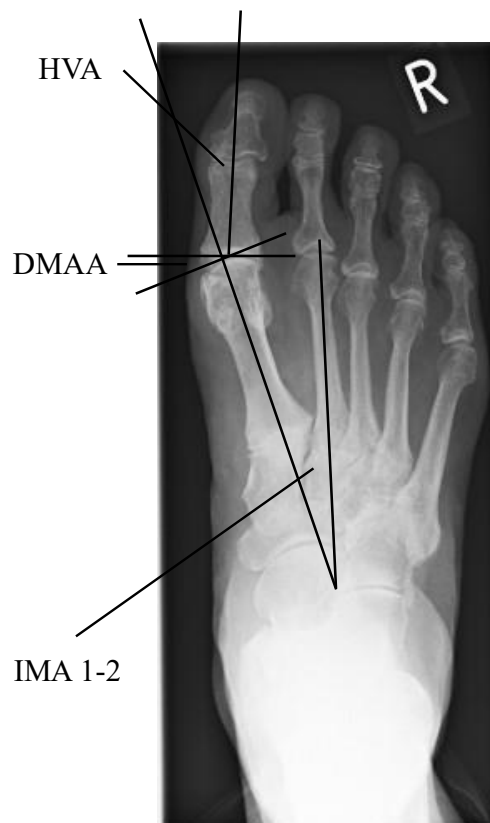A) Dorsoplantar view

B) Lateral view

The *dorsoplantar* view is most important for preoperative planning, as it delineates signs of arthritis, the width of the first metatarsal bone, the congruence of the proximal metatarsal joint, the position of the sesamoid bones and it can be used for angular measurements (22). The distal metatarsal joint will only be assessed intraoperatively, since radiological measurements are not precise (22).

The most commonly used angular measurement to quantify the severity of a preoperative HV deformity and the degree of operative correction are the hallux valgus angle (HVA) and the 1-2 intermetatarsal angle (IMA 1-2) (37).

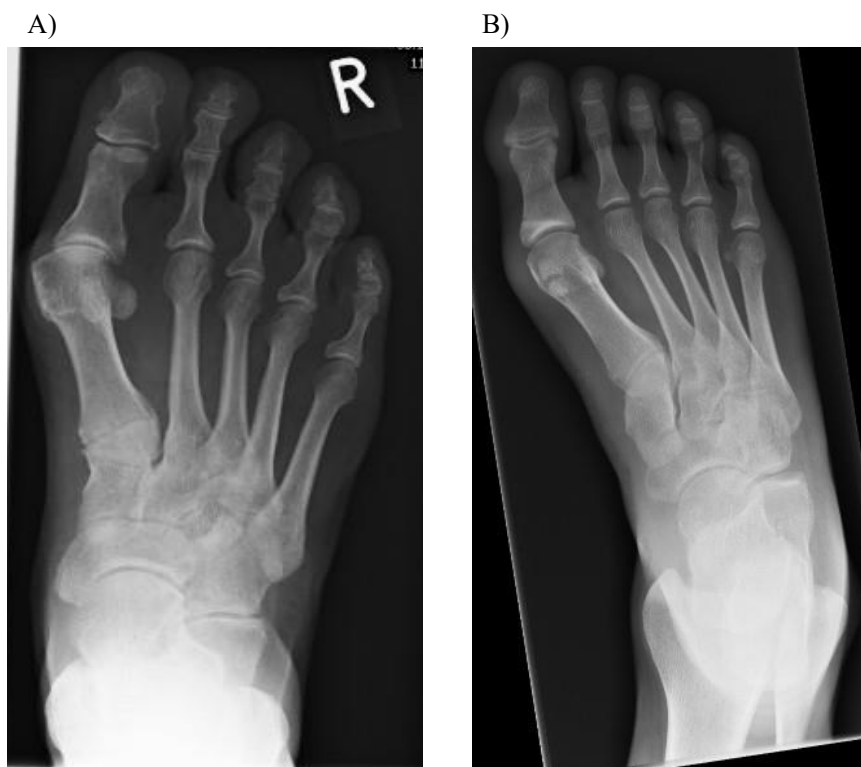
The HVA is measured according to Smith *et al.* with two reference lines traversing the mid-longitudinal axes of the first *metatarsus* and first phalanx, with each axis intersecting the respective diaphyseal region (38), referring to the offset in first MTP joint positioning (37). The IMA 1-2 is measured after the manner of Hardy and Clapham with two longitudinal axes bisecting the first and second metatarsal shaft-mids (39). The deformity is classified as severe when the HVA exceeds 40° and the IMA 1-2 is greater than 16° (37, 40). Another important angle is the distal metatarsal articular angle (DMAA). The DMAA is measured between the perpendicular of the longitudinal axis and a parallel line to the distal articular surface of the first metatarsal bone (41, 42) and represents MTP congruity. The DMAA should normally not exceed eight to ten degrees (28, 41, 42). The measurements of the HVA, IMA 1-2 and DMAA are depicted in Figure 4. Two further angles not as commonly evaluated in Germany are the proximal- and distal articular set angles (PASA and DASA, respectively). The PASA denotes the relationship between the distal articular surface of the first metatarsal and its longitudinal axis, while the DASA determines the alignment between the proximal articular surface of the proximal phalanx and its longitudinal axis and should not exceed 7.5% (43).



**Figure 4.** Radiographic angular measurement of the hallux valgus angle (HVA), intermetatarsal 1-2 angle (IMA 1-2) and distal metatarsal articular angle (DMAA).  
(Radiograph by courtesy of Dr. W. Willauschus)

Pathobiomechanical studies show, that focusing only on the IMA 1-2 is an inadequate simplification of the complex three dimensional deformity HV (44). It is recommended to include diagnostic findings of instability and rotational displacement or extended radiological examination with an axial view to assess associated pathologies of the sesamoid bones. Furthermore, cross-sectional imaging (CT and MRI) allow for determination of alternate aetiologies of pain and for further assessment of the plantar plate, cartilage and collateral ligaments (45, 46) in the optimal decision making of treatment options.

The subluxation of the first metatarsophalangeal joint in HV deformity leads to progressive reduction in health related quality of life with increasing severity of HV deformity due to reduced physical function and bodily pain (47). However, radiographic severity of the deformity must not necessarily correlate with the subjective perception on the impact of the health-related quality of life (48), marking the necessity for a patient-centred approach in informed decision making on therapeutic options for HV deformity. The direct comparison between an HV deformity and an anatomically correct position of the first MTP joint in an anteroposterior X-ray is shown in Figure 5.



**Figure 5.** Anteroposterior radiograph of two different right feet  
A) Hallux valgus deformity of a right foot (by courtesy of Dr. W. Willauschus);  
B) Normal, anatomical alignment of the first ray with congruent metatarsophalangeal (MTP) joint (by courtesy of J. Zeitler).

### **1.3. Treatment**

#### **1.3.1. Conservative Treatment**

Conservative orthopaedic measures may prevent a deterioration of HV at an early stage of disease (49). These may include toe spread, valgus splint and bunion shields (30).

A large systematic review with metanalysis including 2066 articles showed that orthoses design with a toe separator or an element allowing for anatomic alignment of the forefoot is crucial for reducing the HVA and relieving pain (50), but a randomised controlled trial conducted by Torkki *et al.* concluded only short-term symptomatic relief by orthoses in a randomised controlled trial (51). Many patients will therefore seek alternative treatment options upon progressive deformity or persistent pain (52). Torkki's study group from Finland also concluded that the best outcomes regarding pain, cosmetic disturbance and footwear problems were achieved by surgical intervention as compared to a conservative approach (51). This conclusion is consistent with a systematic review from 2017, which found that surgery is more effective in reducing pain than conservative treatment (53).

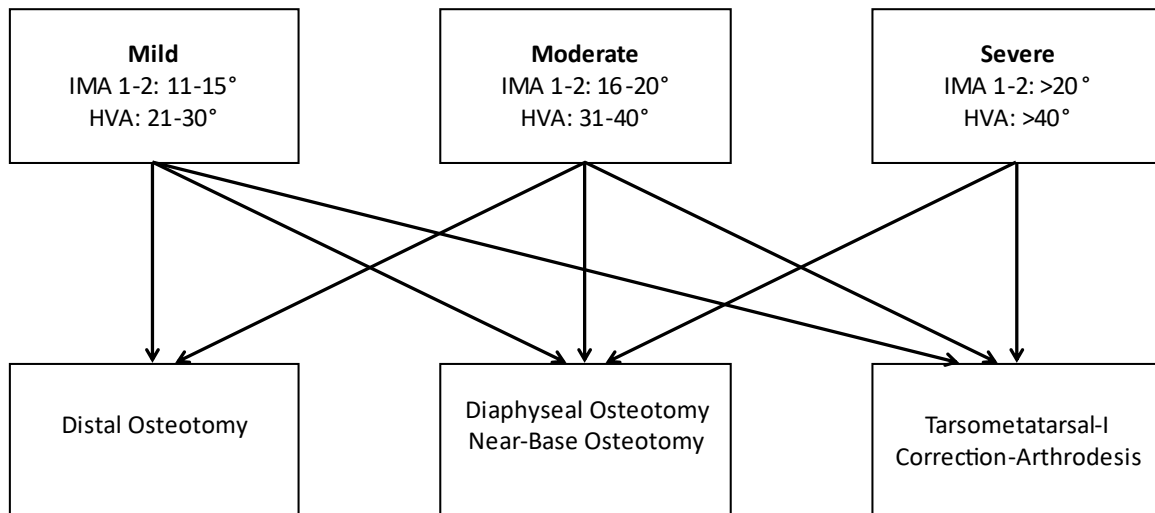
An exception to this general rule is HV in children. Congenital HV is rare and usually appears in early childhood as a developmental pathology in which conservative treatment with physical therapy and padding is generally sufficient (54).

#### **1.3.2. Surgical Treatment**

More than 150 different surgical procedures addressing common foot and ankle pathologies accompanying the HV deformity are described in the literature (49). Naturally, the key objective of these surgeries is to correct pain and deformity while preserving or reestablishing normal foot function (55). Ford and Hamilton further suggested that the choice of the most efficient surgical procedure should attempt to restore the normal mechanics of the first ray and should therefore not be exclusively based on the degree of the IMA 1-2 (55). Hence, extensive biomechanical and anatomic understanding of the forefoot and especially the first ray are inevitable in order to provide the patient with the best possible surgical correction.

Despite the correction of the bony axis, the first metatarsophalangeal joint needs to be centered and stabilized. Essential for a successful outcome is balancing of the first MTP-joint by separating the contracted joint capsule and ligaments, the correction of the bony axis, the alignment of the DMAA and the closure of the joint capsule without tension (22).

In Germany, the current S2 guidelines for Hallux valgus suggest the classification of severity of the HV based on radiologic measurement of the IMA 1-2 and HVA and recommends the level of surgical correction accordingly (Figure 6) (56).



**Figure 6.** The classification of Hallux Valgus based on radiographic measurement of the Intermetatarsal 1-2 angle (IMA 1-2) and the Hallux valgus angle (HVA) and the proposed corresponding surgical correction plane.  
Adapted from Waizy H *et al.* Die aktuelle S2-Leitlinie zum Hallux valgus (56).

The abovementioned operation techniques can be categorized according to their localization into distal, diaphyseal and proximal osteotomies and into open or percutaneous procedures (44). The most common approaches are to be described in somewhat more detail in the following paragraphs.

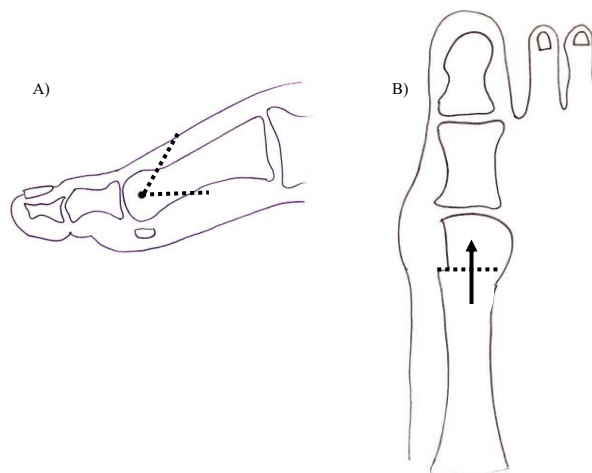
### 1.3.2.1. Distal Metatarsal-Correction-Osteotomy

A distal osteotomy, for example the Chevron (Austin) osteotomy, is the method of choice for a mild to moderate malposition of the hallux with congruent joint lines, as depicted in Figure 5, with the upper limit for Chevron correction is a HVA of  $35^\circ$  and an IMA 1-2 of  $15^\circ$  (36).

The operation is a horizontally directed “V”-shaped displacement osteotomy of the first metatarsal head combined with a soft tissue structure release and balancing on both sides of the first MTP joint (57). The Chevron osteotomy allows for shortening, lengthening, rotation and plantar displacement of the first metatarsal head (44).

The skin incision is placed medial to allow open access to the first MTP joint. After removal of the pseudo-exostosis, a hole is drilled centrally into the metatarsal head and two cuts are performed in an  $60^\circ$  angle to each other, meeting at the centrally placed drillhole (Figure 7A) (2). In the case of a high DMAA or a severely laterally displaced joint surface of the metatarsal head, a narrow, medial bony wedge can be removed from the proximal fragment for further correction (36), such as in an adjunctive Akin osteotomy that will be described in the proceeding paragraphs. The head fragment is then displaced medially to close the osteotomy (36).

In the original Chevron procedure, no fixation was intended (58) but due to loss of correction and development of pseudoarthrosis, an internal stabilization with a small screw is preferred by most surgeons (Figure 7B) (36).



**Figure 7.** The Chevron (Austin) osteotomy: schematic placement and fixation.

Adapted from Wülker *et al.* Operationsatlas Fuß und Sprunggelenk (36).

A) Placement of the Chevron osteotomy at an  $60^\circ$  angle (medial view).

B) Direction of screw-fixation of the osteotomy (dorsoplantar view).

\*↑ denotes screw direction and ---- the osteotomy



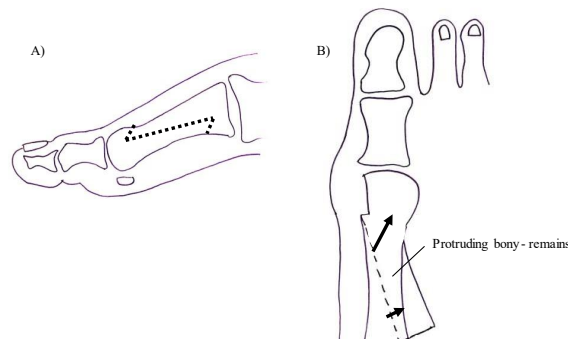
### 1.3.2.2. Diaphyseal Metatarsal-Correction-Osteotomy

From a mechanical standpoint, a more proximal metatarsal osteotomy can achieve a greater degree of correction and is therefore recommended for more severe HV deformities (59), namely an HVA greater than  $31^\circ$  and an IMA 1-2 greater than  $16^\circ$  (56). The indication for a “Scarf”-osteotomy is mild to moderate HV deformity. Its correction- power for the IMA 1-2 is averaged to  $7,8^\circ$  and for the HVA to  $18^\circ$  (58). Similar to the Chevron osteotomy, the scarf osteotomy allows for correction in length, rotation and plantar displacement of the first metatarsal head (44). The scarf osteotomy is particularly indicated in juvenile hallux valgus, which usually presents with a markedly increased DMAA (42). This is due to its correction power by allowing translation or pivoting of the fragment (60–62).

The term “scarf osteotomy” refers to carpentry, when beveling the ends of two pieces of wood and securely fastening them so that they overlap to create one continuous piece (63).

This method dates back to 1926, first described by Meyer (64), and was widely popularized at the end of the 20<sup>th</sup> century by Weil (65) in America and Barouk (59, 65–67) in Europe. The Weil osteotomy is described for the lesser metatarsals, meaning the metatarsal bones two to five, and has been performed since 1985 by L. S. Weil in Chicago (63). According to Barouk, the scarf osteotomy is only one of four necessary steps to correct the HV deformity. It is essential to combine it with an MTP lateral release, a medial capsuloraphy and a proximal osteotomy at the great toe (60). These proximal osteotomies may be a shortening osteotomy or an Akin osteotomy, which will be discussed in the next subsection.

The osteotomy cuts for the scarf osteotomy are depicted in Figure 8A. The head-shaft-fragment is then displaced laterally until the desired level of correction has been reached (36). The scarf osteotomy is usually stabilized by two screws for compression of the fragments after shifting and the protruding bony remains on the dorsal surface are removed (Figure 8B) (36).



**Figure 8.** The Scarf osteotomy: schematic placement and fixation.  
Adapted from Wülker *et al.* Operationsatlas Fuß und Sprunggelenk (36).  
A) Placement of the Scarf osteotomy (medial view).  
B) Directions of screw-fixation of the osteotomy (dorsoplantar view).  
\*↑ denotes screw direction and ---- the osteotomy

### **1.3.3.3. Proximal Opening- and Closing- Base Wedge Osteotomies**

The opening and closing base wedge osteotomies are performed proximal on the first metatarsal and differ from the abovementioned distal Chevron osteotomy in that they are more powerful in correcting an increased IMA 1-2 due to a larger leverage effect (68, 69) and are indicated for a moderate HV deformity (56).

#### **1.3.3.3.1. Opening Wedge Osteotomy**

The primary objective of an open wedge osteotomy is to correct the *metatarsus primus varus* deformity, an intrinsic factor that contributes to the development of hallux valgus deformity (15). In the past, this technique was infrequently used for HV correction because it leads to the elongation of the first metatarsal, which in turn leads to tightening of the soft tissues surrounding the first MTP joint and increases the likelihood of joint compression and subsequent development of arthritis (70). A main advantage is that preservation of the metatarsal length decreases the risk for iatrogenic transfermetatarsalgia (71, 72). The osteotomy can be fixated by staples, screws or plating systems (72, 73).

#### **1.3.3.3.2. Closing Wedge Osteotomy**

The procedure of a closing wedge osteotomy for HV treatment was first described by Loison in 1901 and was altered by Juvara in 1919 through an oblique osteotomy (74). It is a technically demanding procedure, requiring precise wedge resection to adequately correct the IMA 1-2 while preserving the medial cortex as a hinge (75). Common complications include elevation or shortening of the first metatarsal (76, 77) and nonunion due to poor bone healing or unstable fixation (70, 75, 78). These complications arise mainly due to incorrectly placed osteotomies, which naturally occur less frequently in a technically less demanding open wedge osteotomy.

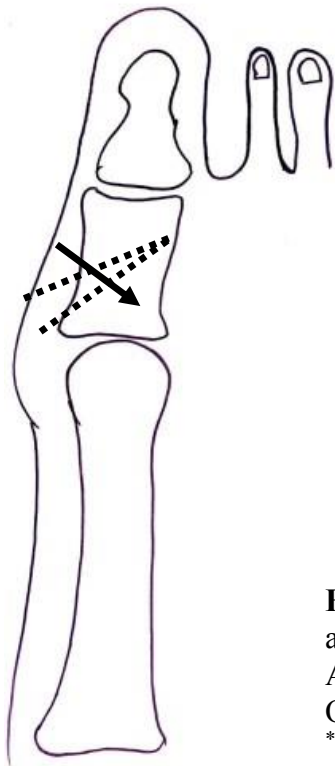
The clinical outcomes and occurrence of complications do not demonstrate the same level of favorability as other techniques such as basal chevron osteotomy (78, 79). Baravarian, Green and Kim even published a point-counterpoint article, in which they stated that the Lapidus procedure, explained in the next paragraphs, should replace the closing base wedge osteotomy (80). However, closing base wedge osteotomy is very effective in correcting moderate to severe HV deformities due to its proximity to the apex of the deformity (58) and remains a solid component in the clinical guidelines for operative correction of symptomatic HV (56).

#### 1.3.3.4. Akin Osteotomy

The Akin osteotomy is a medially based closing wedge osteotomy first described by OF Akin in 1925 (81). It can be used as an additional procedure for *hallux valgus interphalangeus* in the region of the first phalanx or as a singular surgery and is usually fixated with a small staple or screw (44). Indications for an isolated akin osteotomy are correction of the proximal and distal articular set angles (PASA and DASA, respectively) by placing the osteotomy more proximally or distally (82).

The term "cheat akin" procedure refers to a method of correcting the alignment of the great toe, which results in an unsightly and excessively curved inward appearance of the medial surface through removing a larger wedge but disregarding the IMA 1-2 and congruity of the first MTP joint (83).

The main objective of this surgery is to maintain the lateral cortex of the phalanx as an additional point of fixation (84). However, intraoperative fracture of the lateral cortex is the most common complication (85). As a closing wedge osteotomy, the Akin osteotomy leads to shortening of the proximal phalanx with removal of a bone wedge and should therefore be kept at the minimal amount necessary (82) to prevent iatrogenic postoperative metatarsalgia (27). A schematic representation of the osteotomy and direction of screw fixation is provided in Figure 9 (86).



**Figure 9.** The Akin osteotomy: schematic placement and fixation (dorsoplantar view). Adapted from Sanhudo J. Clinical Tip: Modified Akin Osteotomy (86).

\*↑ denotes screw direction and ---- the osteotomy

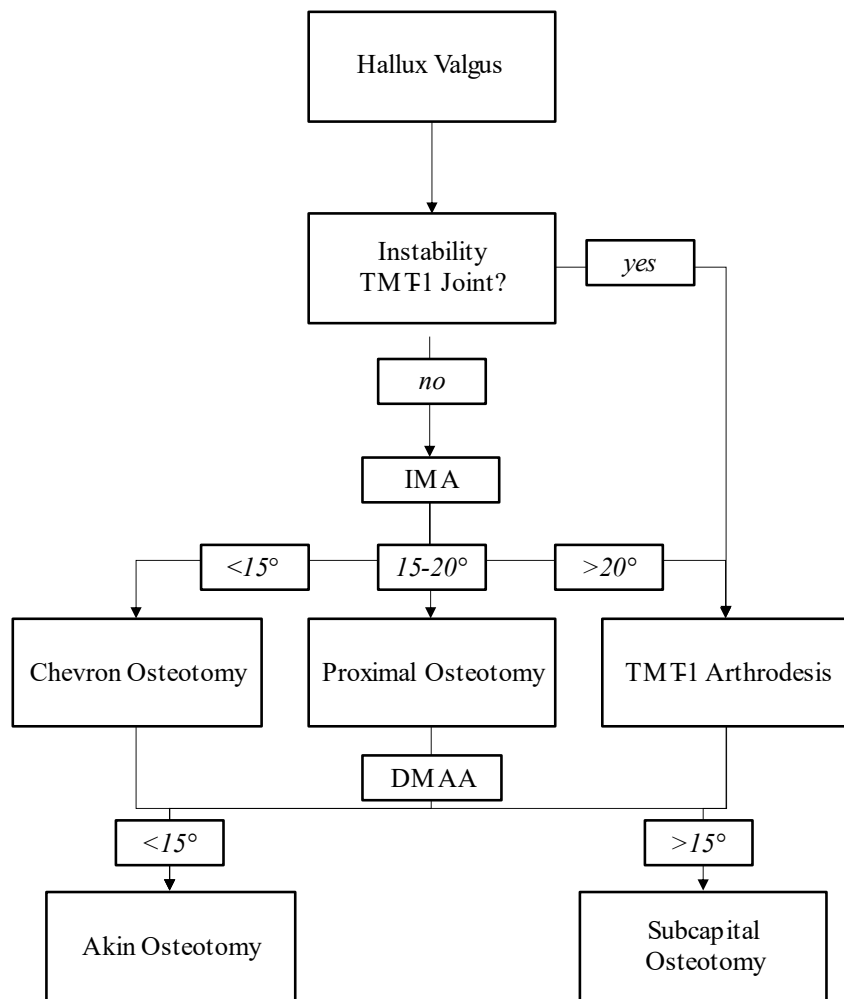
### **1.3.3.5. Tarsometatarsal 1 Arthrodesis**

The Chevron- and Scarf- osteotomies described in the preceding paragraphs focus mainly on the correction of the HV deformity in a horizontal plane (36). However, through increased mobility of the first metatarsal not only in medial but also in dorsal direction, severe HV is a deformity in the horizontal and in the sagittal plane (36) and must be addressed by a different approach.

The first tarsometatarsal (TMT) joint is composed of the articulation between the base of the first metatarsal and the distal surface of the medial cuneiform bone. The first arthrodesis was described by Albrecht in 1911 (87). This surgical procedure was assumed by Paul W. Lapidus in 1934 (88), who popularized the method in the following years (89). The Lapidus procedure is employed especially when hypermobility of the first metatarsal is evident on clinical examination (60) with dorsal displacement of the first metatarsal head exceeding five to eight millimeters compared to the other metatarsal heads under simulated mechanical strain (36). However, assessment of hypermobility is not exact and requires a significant amount of experience (90).

Indications for Lapidus arthrodesis despite hypermobility are degenerative arthritis (91) and severe HV with an IMA 1-2 and an HVA exceeding 20° and 40° respectively (56). For a DMAA exceeding 10°, a subcapital osteotomy should be added to restore normal joint-line alignment (92).

Arthrodesis or stiffening of the first TMT joint and the resulting loss of motion does not negatively influence function, since its physiological mobility, moderate dorsiflexion and plantar flexion coupled with small amounts of inversion and eversion (93), is neglectable (7). The abovementioned surgical techniques and their indications are summarized in Figure 10 (2).



**Figure 10.** Summary of surgical procedures for hallux valgus and their indications according to clinical and radiological findings including the intermetatarsal 1-2 angle (IMA 1-2) and the distal metatarsal articular angle (DMAA).

Adapted from Rammelt S. Fuß- und Sprunggelenkchirurgie-Das Kursbuch (2).

\*TMT-1 denotes the first tarsometatarsal joint

#### 1.4. The Lapidus Procedure

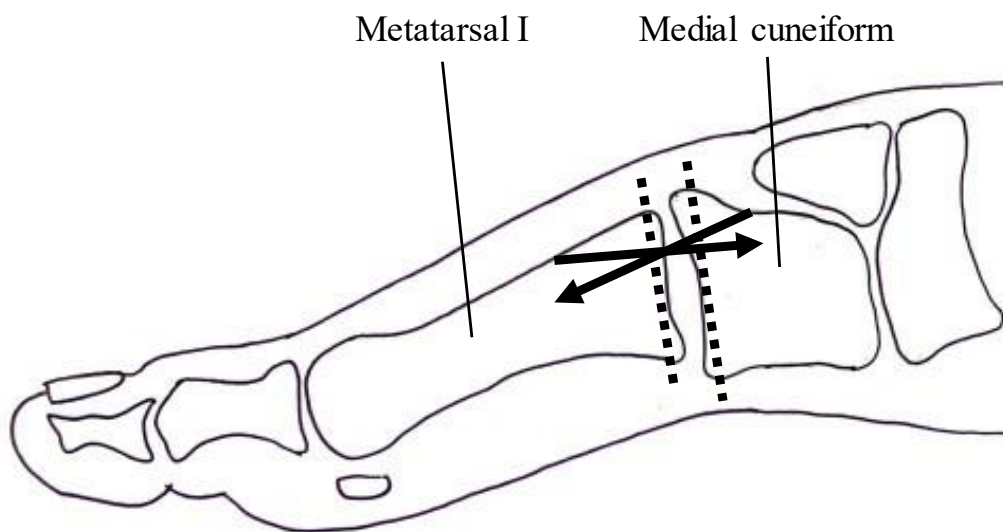
The Lapidus technique, as described in Lapidus' publication in 1934 (72), involves several steps. In the distal soft-tissue procedures, a medial approach is made at the level of the first MTP joint. The muscle bellies and tendons of the *abductor hallucis* and *flexor hallucis brevis* are identified and separated plantarly. A U-shaped capsulotomy is created with its base at the proximal phalanx. The *adductor hallucis* tendon is subcutaneously cut, and a dorsally-oriented capsulotomy is made. The U-shaped capsule flap is then sutured onto the *abductor hallucis longus* tendon using number 0 chromic catgut, applying considerable tension but not excessively tight (72). Next, the bunionectomy is performed at the level of the medial sagittal groove using small wood-carving chisels. The goal is to preserve the round shape of the metatarsal head while targeting the metatarsal neck. This step may or may not include a dorsal cheilectomy. For the TMT arthrodesis, a dorsal incision is made between the *extensor hallucis longus* (EHL) muscle medially and the *extensor hallucis brevis* (EHB) muscle laterally (72). The joint preparation involves shaving the articular surfaces of the base of the first metatarsal and medial cuneiform without removing wedges of bone. The cortex of the first and second metatarsals is removed, while leaving the bone chips in place. In terms of fixation, a bony tunnel is created at the dorsolateral part of the base of the first metatarsal. A number 0 chromic catgut suture is passed through the tunnel and fixated to the dorsal ligaments located between the medial and intermediate cuneiforms (72). Postoperative immobilization consists of using a 12cm long and 7mm wide steel corset positioned on the medial aspect of the first metatarsal, covered with a well-padded dressing. This immobilization method is maintained for a period of 3 to 4 weeks. Weightbearing is allowed based on the patient's pain tolerance, with or without the use of crutches. Special canvas shoes or wool socks are recommended during the initial month following the surgery (72).

Today, the “original” Lapidus procedure with chromic catgut fixation and aftercare with wool socks is antiquated. Furthermore, the fixation with simple suture material was insufficient and lead to a large number of pseudoarthrosis (36), with early reports suggesting nonunion rates up to 20% (94–97).

### 1.4.1. The Modified Lapidus Procedure

A number of modifications have been added over the years and the term “Lapidus procedure” has become synonymous with the many modified approaches to first tarsometatarsal arthrodesis (98). The “modified Lapidus arthrodesis” denotes the isolated arthrodesis of the first TMT joint as compared to Lapidus’ additional intercuneiform screw connection (99).

The fixation methods of the arthrodesis have significantly improved through the use of one or multiple screws for stability (36). With the introduction of a gutter or channel for the screw head, slipping of the screw head and fragmentation of the metatarsal basis can be prevented (36). Drilling of a gliding hole (lag screw technique) through the base of the metatarsal bone allows for further compression of the arthrodesis which promotes direct bone healing in contrast to healing with callus (100). Common positioning of the screws in Lapidus arthrodesis are portrayed in Figure 11 (36).



**Figure 11.** The Tarsometatarsal arthrodesis of the first ray: schematic placement of the osteotomies and fixation (medial view).

Adapted from Wülker *et al.* Operationsatlas Fuß und Sprunggelenk (36).

\*↑ denotes screw direction and ---- the osteotomy

### 1.4.2. Complications

The most common complication of the modified Lapidus procedure is recurrence of the deformity (101, 102). The reasons for recurrence are heterogenous and includes surgeon's factor like under-correction of the initial deformity and deformity components that were not addressed at the primary procedure (102), marking the necessity for a thorough clinical and radiological examination of the three dimensional deformity before concluding on a treatment plan. Wirth *et al.* reported a recurrence in 8.1% (2.9-16%) (101), while Thompson *et al.* found only 4% recurrence with 2% revision (103). Similar outcomes were reported by Lagaay (104).

Another common complication is pseudoarthrosis or nonunion of the arthrodesis. This complication has already been described for the original Lapidus procedure and continues to pose a huge problem even with modern techniques, with rates of 7.5% (1.8-18%) being reported in the literature (101, 105, 106). Risk factors for nonunion associated with modified Lapidus procedure include previous bunionectomy and an increased preoperative HVA (107).

Further complications include pain and irritation of the soft tissue surrounding the implanted screws or plates (108) and transfermetatarsalgia due to shortening of the first ray (109, 110). Their frequencies are listed in Table 1 (111).

**Table 1.** Complications in Lapidus arthrodesis surgery

Complication	Prevalence
Recurrence	8.1% (2.9-16%)
Nonunion	7.5% (1.8-18%)
Arthritis of first MTP* - joint	13.1% (2-25%)
Impaired mobility of the first MTP* - joint	12.1% (1-17.6%)
Transfermetatarsalgia	9.4% (0-28%)
Hallux Varus <sup>†</sup>	4.8% (0-8.7%)

Adapted from Wirth CJ. Komplikationen bei der Behandlung von Fehlentwicklungen und Erkrankungen des Fußes. Komplikationen Kompakt: Orthoäpdie und Unfallchirurgie (111).

\*Metatarsophalangeal (MTP)

<sup>†</sup>Overcorrection of the deformity



### 1.4.3. Plating Systems in Lapidus Procedure

With the increasing employment of angle-stable plating systems in orthopaedic surgery over the past ten years (112), the Lapidus procedure has also evolved and plate-fixation has become the new gold standard due to accelerated recovery and biomechanical benefits (105, 113, 114).

Plate techniques are superior to compression screws under cyclic loading conditions and could shorten the period of non-weightbearing and reduce the risk of nonunion (105, 113). Plating systems are particularly useful for patients with poor bone quality (115), with excellent patient satisfaction and functional outcome (116).

Another benefit is the early weightbearing (83). The arthrodesis usually needs around six weeks to consolidate, and most postoperative protocols typically involve non-weightbearing during that time (83). A multicentre retrospective review of 80 cases by Neil Blitz with an early-weightbearing protocol after two weeks showed a 100% union rate at 45 days and no compromise of correction (96), an outcome that was replicated by Walther *et al.* using a plantar plate with 0% nonunion (117). In long-term follow-ups, the results continue to be successful even eight years after the procedure (118).

Early full weightbearing has many advantages despite the obvious effect on the quality of life when not being dependent on crutches or other assistive devices. Prolonged immobilisation leads to musculoskeletal complications including decreased muscle strength, contractures and soft tissue changes (96). Furthermore, cardiovascular complications including orthostatic hypotension and thrombosis or embolisms may arise (119). Other possible complications include respiratory diseases, genitourinary problems and central nervous system changes that could adversely affect balance and coordination (120). Balance and coordination are crucial for all daily activities, but even more so in patients already suffering from mobility problems due to a pathologic forefoot deformity such as hallux valgus.

Fracture healing is influenced by the amount of motion between the bone fragments or the force transmitted across the callus, also known as the mechanical environment in the fracture (121, 122). Rigid stabilisation of the callus preventing mechanical stimulation slows or might even arrests the healing process while a mechanical overload due to unstable fixation may also negatively influence healing and lead to hypertrophic pseudoarthrosis (123, 124). A semi-rigid fixation allowing for some mechanical stimulation of the fracture gap while at the same time compressing the fragments to allow healing without callus formation therefore seems to be the most desirable way to strike a balance in arthrodesis.

Many different plating systems striving for a good bony healing response are available on the market, although they differ in terms of stability, rigidity and placement (125, 126). The plates can be placed dorsally, medially or plantarly through different surgical approaches (127). The dorsal access follows the alignment of the first ray from the medial cuneiform distally towards the first MTP joint proximally and medial to the *extensor hallucis longus* tendon (128). For a medial access, the initial incision is placed between the dorsal and plantar neurovascular bundles, starting at the metatarsal's midpoint. The *flexor hallucis longus* tendon is easily maintained during the dissection (129). For plantar placement of the plating systems, the abovementioned medial access is used.

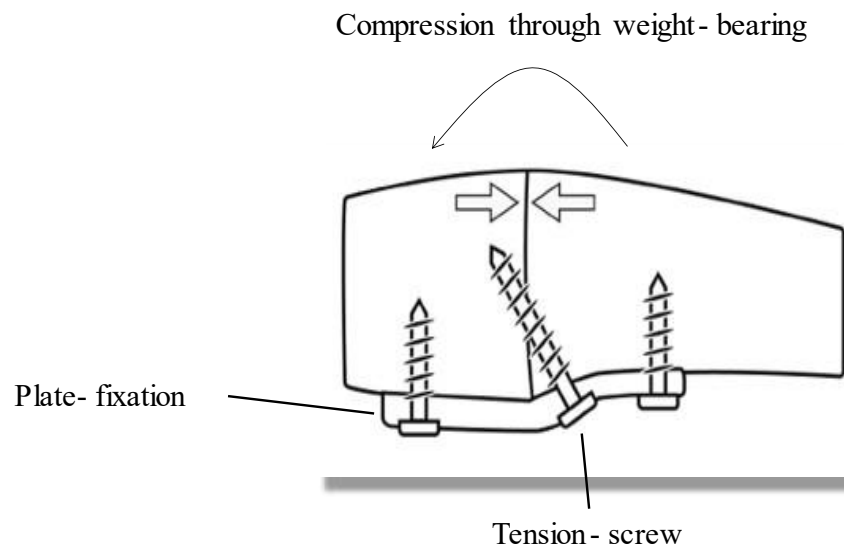
The disadvantages of a dorsal approach include the thin soft tissue cover, proximity to the nerve and vascular bundle, and the more challenging removal of cartilage from the deeply located TMT1 joint (130). In the case of a medial approach, it is important to preserve the medial venous plexus to avoid wound healing complications (130), that are reported in up to 14% of cases (95, 109, 131). Dorsal placement might lead to pain and soft tissue irritation due to interference with the tendon of the *tibialis anterior* muscle (108). The plantar tendon insertion area of the *peroneus longus*- and *tibialis anterior* tendon is not damaged by the medial approach (132, 133) and skin irritation can be prevented by plantar placement of the plate beneath the muscle belly of the *m. abductor hallucis* (109).

Drummond *et al.* compared these three locations with identical plates for stiffness and force resistance and found that the dorsal plate position is inferior to medial or plantar placement in all measured outcomes (127). These findings are consistent with a large systematic review from 2022 that further concluded that the medial and plantar approaches provide an excellent option to increase control and avoid the elevation in the first metatarsal joint and resulting transfermetatarsalgia (134).

Clinical evidence on the superiority of the type of plating system used is sparse and the majorities of studies could not show a statistically significant difference in effectiveness of different plate types (134). Rosenfeld suggested that the use of specially designed plates in order to control dorsiflexion of the first metatarsal in combination with a compression screw is highly successful (116).

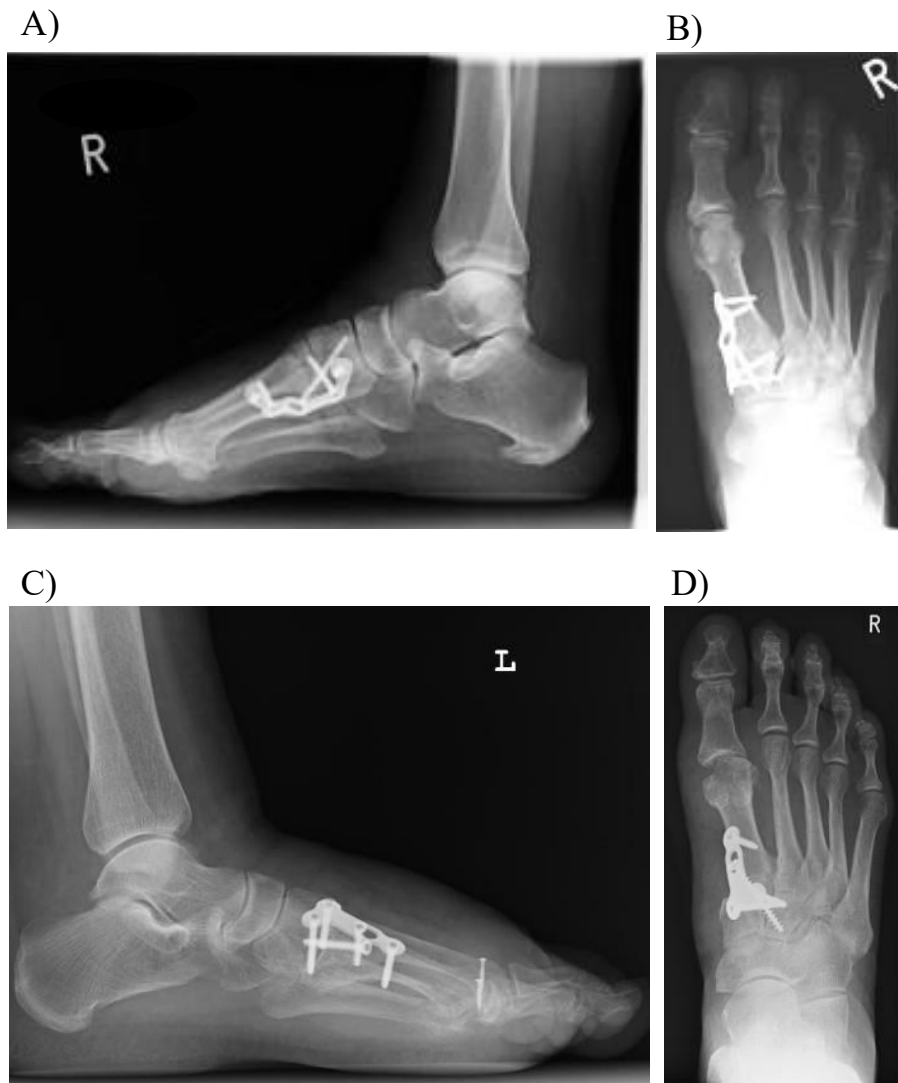The first angle-stable plate specifically designed for the forefoot was developed by E. Orthner in 2001 and was extended in the following year by a tension screw inserted between the first and second metatarsal bones due to delayed full weightbearing (135).

A more recent specially designed plate for optimal, biomechanically logical compression is the plantar tension band osteosynthesis as shown in Figure 12 (136) and Figure 12. This plating system combines the tension screw with a stabilising plate and allows for further compression of the arthrodesis due to its plantar placement and the bodyweight acting on the osseous gap.



**Figure 12.** Schematic presentation of the plantar tension band osteosynthesis with a plantar plating system for Lapidus procedure (medial view). The arrows denote the direction of compression through pressure on the plating system generated by weightbearing  
Adapted from Klos et al. Plantar versus dorsomedial locked plating for Lapidus arthrodesis: a biomechanical comparison (136).

Klos *et al.* (136) compared the plantar plating system combined with a compression screw with a dorsomedial angle- stable plate in a biomechanical study and found that the plantar plate showed a statistically significant greater initial stiffness, a smaller range of motion or displacement and a greater load to failure (136). He concluded that there is a biomechanical benefit which needs to be validated through a clinical study (133), which is the aim of this thesis. An anteroposterior and a lateral radiograph of the foot after a Lapidus arthrodesis with a dorsomedial and a plantar plate is depicted in Figure 13.



**Figure 13.** Anteroposterior and lateral radiograph of a right foot (A) and left and right foot (B) after a Lapidus arthrodesis (by courtesy of Dr. W. Willauschus).  
 A and B) Lapidus arthrodesis with a plantar plating system (lateral and anteroposterior view).  
 C and D) Lapidus arthrodesis with a dorsomedial plating system (lateral and anteroposterior view).

## **2. OBJECTIVES**

Our study group's intent was to compare the outcomes of two common approaches to the Lapidus arthrodesis in symptomatic hallux valgus, the plantar- and the dorsomedial plating systems.

Our hypothesis was that the plantar-plating system in Lapidus arthrodesis surgery is superior to the dorsomedial plating system in terms of radiological outcome and patient-reported outcome. To validate the two different techniques, the following main outcome measures were defined.

1. Postoperative radiological analysis of HVA and IMA 1-2
2. Patient-reported outcome quantified by American Orthopaedic Foot and Ankle Society (AOFAS) scoring system (ranging from 10-100) and pain score on Visual Analogue Scale (VAS) (ranging from 0-10).

Secondary outcome measures include whether the patient would repeat the operative correction with a simple yes or no answer and which overall grade or score the patient would give the operation according to the German school grading system ranging from 1 to 6 with 1 being the best (very good). Furthermore, we analysed radiologically whether pseudoarthrosis developed that consequently lead to reoperation with a simple yes or no answer and the number of reoperations necessary expressed numerically. Moreover, the time until the patient had full weightbearing on the operated foot, despite the recommendation of the surgeon, were documented in weeks.

### **3. MATERIALS AND METHODS**

### **3.1. Data Sources and Study Objects**

This study is an observational retrospective study comparing the surgical outcomes between two different plating systems in Lapidus arthrodesis surgery. The sample is taken from the patients operated on symptomatic HV deformity in the alphaMED orthopaedic clinic in Bamberg, Germany, either with plantar or dorsomedial plating system.

All data was taken from patient pre- and postoperative histories during the time frame of January 2014 until December 2017 including patient records and radiographs.

Patients who are younger than 18 years of age were excluded from the study. Additionally, individuals with a history of previous foot fractures or surgeries were not eligible to participate. Patients with chronic musculoskeletal or neurological pathologies that may affect ligament stability or normal skeletal development were also excluded. Finally, any lower limb pathological findings discovered during clinical examination led to exclusion from the study. The study includes patients who have symptomatic HV and require a surgical correction based on the German S2 Guidelines for HV with previously failed conservative treatment. Participants must be older than 18 years of age, and both males and females are eligible to participate.

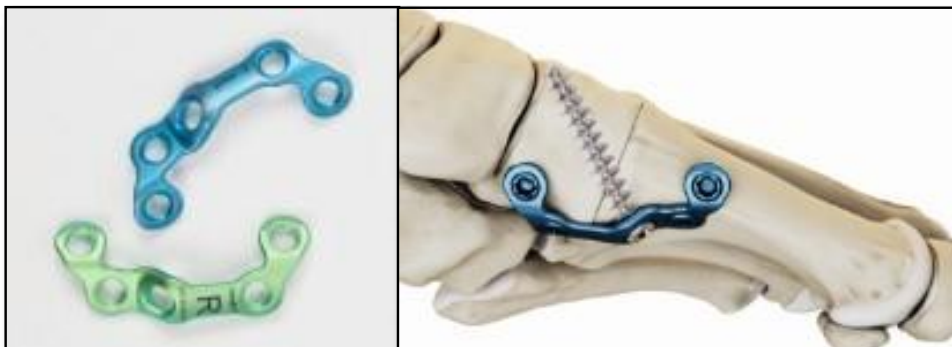43 patients were supplied with the dorsomedial Titanium Lapidus Plating System (AR-8941)<sup>®</sup> illustrated in Figure 14A, and 34 patients with the Plantar Lapidus Plating System<sup>®</sup> (Figure 14B). Both plating systems were used from the company Arthrex<sup>®</sup> (Naples, FL).



A)



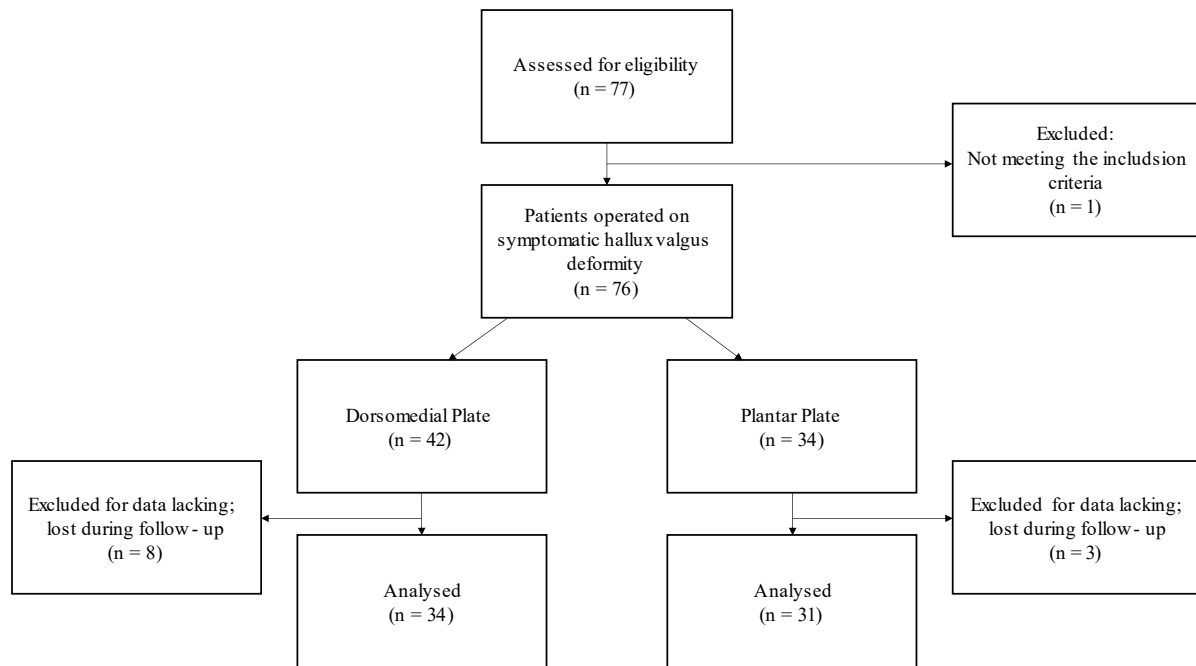
B)



**Figure 14.** The dorsomedial and plantar Lapidus plating systems from Arthrex®

- A) Dorsomedial Titanium Lapidus Plating System®: T-shaped plate with 4 screw holes. The middle screw hole oval and can be filled with a tension screw in any direction. The other screw holes are angle stable and the screws need to be inserted coaxial to the plate. The right picture denotes the dorsomedial positioning of the plate over the first tarsometatarsal joint. Modified from Arthrex® Surgical Technique (149).
- B) Plantar Lapidus Plating System®: halfmoon-shaped anatomical plate with 5 angle-stable screw holes in multiaxial directions. The middle screw hole is directed towards the dorsal base of the medial cuneiform bone and is filled with the tension screw. The right picture denotes the plantar positioning of the plate over the first tarsometatarsal joint. Modified from Arthrex® Surgical Technique (150).

One patient under the age of 18 years supplied with a dorsomedial plate was excluded from this study. Furthermore, eight patients had to be excluded from the study in the dorsomedial plate group due to insufficient postoperative follow-up. This also applies to three patients provided with a plantar plate that were lost during follow-up (Figure 15).



**Figure 15.** Flow chart of the study to illustrate patient selection.

The patient sample has an age range from 28 to 77 years of age and is therefore a good representation of the population. The mean age of patients at the time of surgery was 49.65 years, with the age ranges in both the dorsomedial- and the plantar plate group being very similar and therefore easily comparable (Table 2). Both males and females were included, but no differentiation between the sexes was made.

**Table 2.** Subgroup characteristics

Subgroup	Dorsomedial Plate	Plantar Plate	Total
Individuals	34	31	65
Minimum and maximum age [years]	28	35	28
Mean age [years]	50.23	49.06	49.65

The stage of disease was integrated by the previously failed conservative treatment and patient's wish for a surgical correction of the deformity and was quantified by clinical and radiological analysis of the malformation.

### 3.2. Collected Data and Measurements

Preoperative measures included clinical examination, radiological examination and measurement of the HVA and IMA 1-2, AOFAS scoring for the first forefoot ray and pain on the VAS. The AOFAS scoring system for the first forefoot ray was handed out to all patients in German language and is portrayed in Table 3 (137). It is internationally widely used due to its simple structure (138, 139), consisting only of eight questions (106).

**Table 3.** The American Orthopedic Foot and Ankle Society (AOFAS) Score for the first Forefoot Ray, validated German version.

Parameter		Score
Schmerz	kein	40
	leicht, gelegentlich	30
	mittelmäßig, täglich	20
	heftig, fast immer	0
Funktion (Einschränkung der Aktivität)	keine Einschränkungen, keine Stütze/ Hilfe	10
	keine Einschr. bei den täglichen Aktivitäten, Einschr. bei Freizeitaktivitäten, keine Hilfen	7
	Einschr. Bei den tägl. Aktivitäten/ Freizeitakt., Stock	4
	starke Einschr. bei den tägl. Aktivitäten und Freizeitaktivitäten, Gehstütze, Krücke, Rollstuhl	0
Schuhwerk	modische Konfektionsschuhe ohne Einlagen	10
	Konfektionsschuhe mit Einlagen	5
	orthopädische Schuhe	0
MTP <sup>†</sup> Beweglichkeit	normal, oder leichte Einschränkungen (75%-100% von normal)	10
	mäßige Einschränkungen (30%-74%)	5
	Massive Einschränkungen (<30%)	0
IP <sup>‡</sup> Beweglichkeit	keine Einschränkung	5
	stark eingeschränkt	0
MTP-IP <sup>†‡</sup> Stabilität	Stabil	5
	eindeutig stabil	0
Schwiele am Hallux MTP- IP <sup>†‡</sup> Gelenk	keine oder symptomlos	5
	mit Symptomen	0
Achsenstellung	gut, Zehen achsengerecht	15
	mittelmäßig, gewisse Achsenabweichung	8
	schlecht, Achsenfehlstellung	0
		Total 100*

\*Grading: Excellent=90-100 points; Good=75-89 points; Fair=60-74 points; Poor=<60 points

<sup>†</sup>Metatarsophalangeal (MTP)

<sup>‡</sup>Interphalangeal (IP)

Adapted from Richter M., American Foot and Ankle Society (AOFAS) Score (137).

The original AOFAS Ankle- Hindfoot Score developed by Kitaoka *et al.* in 1994 in English language is provided in Table 4 (139).

**Table 4.** The American Orthopedic Foot and Ankle Society (AOFAS) scoring system for the first forefoot ray

	Parameter	Score
Pain	None	40
	Mild, occasional	30
	Moderate, daily	20
	Severe, almost always present	0
Function (activity limitations)	No limitations	10
	No limitations of daily activities (employment)	7
	Limited daily and recreational activities; use of a cane	4
	Severe limitation of daily and recreational activities; use of a cane, crutches or wheelchair	0
Footwear requirements	Fashionable, conventional shoes, no insert required	10
	Comfort footwear, shoe insert	5
	Modified / orthopaedic shoes	0
MTP <sup>†</sup> joint motion (dorsiflexion / plantarflexion)	Normal or mild restriction ( $\geq 75\%$ )	10
	Moderate restriction (30%-74%)	5
	Severe restriction (<30%)	0
IP <sup>‡</sup> joint motion (plantarflexion)	No restriction	5
	Severe restriction	0
MTP-IP <sup>†‡</sup> stability	Stable	5
	Definitely unstable or able to dislocate	0
Callus related to hallux MTP-IP <sup>†‡</sup>	No callus or asymptomatic callus	5
	Callus, symptomatic	0
Alignment	Good, hallux well aligned	15
	Fair, some degree of hallux malalignment observed, no symptoms	8
	Poor, obvious symptomatic malalignment	0
		Total 100*


\*Grading: Excellent=90-100 points; Good=75-89 points; Fair=60-74 points; Poor=<60 points

<sup>†</sup>Metatarsophalangeal (MTP)

<sup>‡</sup>Interphalangeal (IP)

Adapted from Kitaoka *et al.* Clinical rating systems for the ankle-hindfoot, midfoot, hallux, and lesser toes (139).

The VAS scale is a validated, subjective measure for acute and chronic pain. Scores are recorded by making a handwritten mark on a 10cm line representing a continuum between “no pain” and “worst pain” (140). An example not true to scale is provided in Figure 16.



**Figure 16.** The visual analogue scale (VAS) for pain assessment. Adapted from Delgado *et al.* Validation of Digital Visual Analog Scale Pain Scoring With a Traditional Paper-based Visual Analog Scale in Adult (140).

Postoperative measures included clinical and radiological examinations of the operated first forefoot ray with measurements of the HVA and IMA 1-2, AOFAS score and pain score on VAS. Additionally, all patients needed to answer whether they would repeat the operative correction with a simple yes or no answer and rank their outcome according to the German school scoring system ranging from one to six with one being the best (very good). Clinically and radiographically verified pseudoarthrosis and reoperations necessary were collected and time until the patient achieved full weightbearing on the operated foot in weeks were noted.

### 3.3. Methodology of the Study

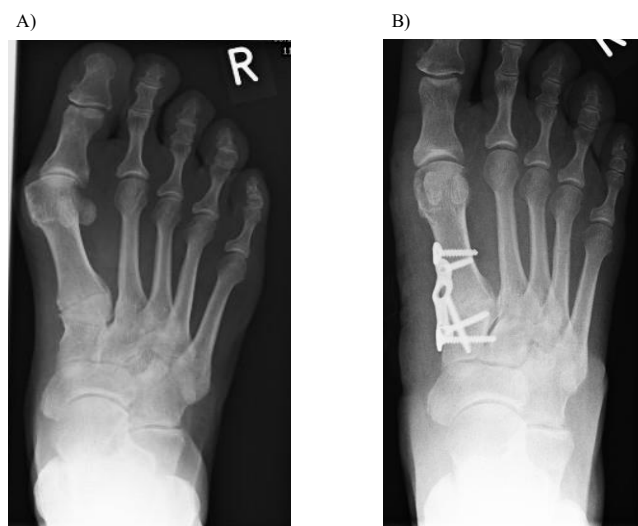
All patients were operated on by the patient same experienced certified foot surgeon in the alphaMED clinic in Bamberg, Germany, after previously failed conservative treatment.

The surgical procedures do not differ substantially between the dorsomedial and plantar plating technique, except for a slightly more dorsally or more plantarly placed medial skin incision, respectively. The procedure, as it is performed by Dr. W. Willauschus in the alphaMED clinic in Bamberg, will be described in the following paragraphs.

A medial skin incision allowing open access to the surgical site including the first MTP-joint and the base of the first metatarsal is made. The capsule of the first MTP-joint is then incised in a Y-form. After detachment of the *m. adductor hallucis* and the sesamoid bone lateral and plantar and removal of the medial exostoses at the head of the first metatarsal, the capsule is reduced medially with a 2.0 vicryl suture. The MT1 head is temporarily trans-fixated onto the MT5 head with a Kirschner-wire and the base of the MT1 is prepared. The capsule and fibres or filaments of the *m. tibialis posterior* are visualised before the arthrotomy from dorsomedial is performed.

The cartilage at the base of the MT1 and on the medial cuneiform is sparsely resected with a saw before the subchondral sclerosis is broken up with a Kirschner-wire and a chisel. The MT1 is then reduced into the desired position and fixated with another Kirschner-wire onto the medial cuneiform bone. The degree of correction in the sagittal and horizontal plane is then verified by X-ray. The plantar plate is now adjusted by bending so that the two distal screw holes are at a right angle towards each other. The dorsomedial plate does not need to be bended for adjustment. Both plates are then applied at their respective location over the first TMT-joint and the two distal screws are inserted. The arthrodesis is then compressed by insertion of the tension screw in the so-called lag screw technique. Lastly, the two proximal screws are inserted and a final X-ray verification of the degree of correction and location of the plate and screws is performed.

Both groups were provided with the same standardised follow-up scheme. This included obtaining radiological images in all three planes (anteroposterior, lateral and oblique) without weightbearing one day after the operation and with full weight bearing after six and twelve weeks to radiologically control the dimension of correction, bony consolidation and location of the osteosynthetic material. Immobilisation in a “short walker” orthosis and crutches and in a dorsal positioning splint at night with partial, pain-adapted weightbearing for six weeks. Full weightbearing was enabled after the second x-ray control after six weeks. A pre- and postoperative anteroposterior radiographic imaging of a foot is provided in Figure 17.



**Figure 17.** Anteroposterior radiograph of a right foot  
(by courtesy of Dr. W. Willauschus)

A) Preoperative x-ray with severe Hallux valgus deformity of the right foot

B) Six- weeks postoperative image of a Lapidus arthrodesis with a plantar plating system and anatomically correct alignment of the first ray.

A full anonymisation of the sample was performed by the operating surgeon. Only the prementioned scores and age of the patient were documented in an excel table for the purpose of analysis for this study. There was no possibility of concluding the identity of any of the patients from the gathered data. All data were collected in the routine pre- and postoperative management of the patients.

This thesis proposal was approved on the 16.05.2023 by the IRB-ethical committee of the Regiomed Medical School in cooperation with the University of Split, School of Medicine.

There was no financing granted for this study. The patients did not receive any money for participating. The author declares no conflict of interest conducting this study.

### **3.4. Statistical Analysis**

Statistical tests were performed using the JASP program (Version 0.17.2.1, University of Amsterdam, Netherlands) with descriptive statistics and comparison of the main and secondary outcome measures between the two groups with a two-sample independent student's t-test and Mann-Whitney- or rank-sum test with 95% confidence interval. The statistical significance value was set at  $P \leq 0.05$ .

## **4. RESULTS**



As visualized in Table 5, the mean preoperative HVA in the dorsomedial plating group and plantar plating group were 47.412° (21-67°) and 48.871° (36-63°) respectively. The mean IMA 1-2 likewise differed only slightly between the two groups, with 20.5° (13-27°) in the dorsomedial- and 22.516° (15-31°) in the plantar plating group. The HVA and IMA 1-2 in the two groups are illustrated in Figure 18A and 18B, respectively.

The preoperative AOFAS score was graded as poor in both groups, with an average of 37.765 points in the dorsomedial group and 38.774 points in the plantar plating group.

**Table 5.** Preoperative descriptive statistics

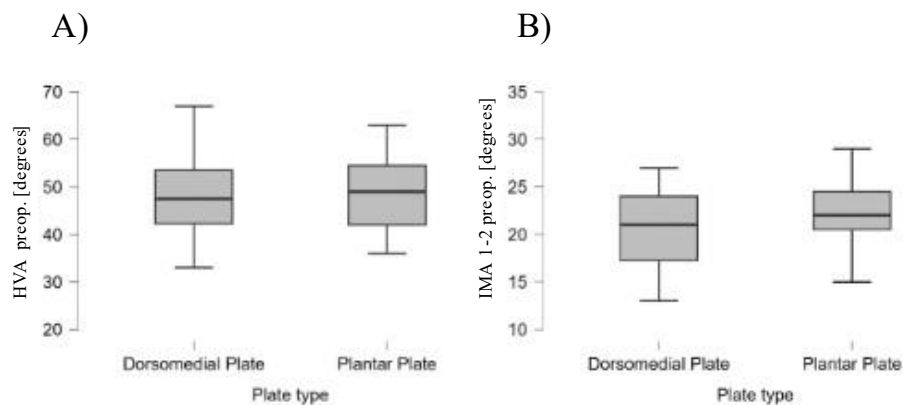
	<b>Dorsomedial Plate (N=34)</b>	<b>Plantar Plate (N=31)</b>
HVA* [degrees]	47.412±10.040	48.871±8.350
IMA 1-2† [degrees]	20.500±3.902	22.516±3.705
AOFAS‡	37.765±10.151	38.774±9.875

Data are presented as mean±standard deviation

\*Hallux valgus angle (HVA)

†Intermetatarsal 1-2 angle (IMA 1-2)

‡American Orthopedic Foot and Ankle Society (AOFAS) scoring system ranging from 0 to 100 points



**Figure 18.** Boxplots of preoperative forefoot angles in the dorsomedial- and plantar plating groups

A) Preoperative Hallux valgus angle (HVA) in degrees

B) Preoperative Intermetatarsal 1-2 angle (IMA 1-2) in degrees

All variables collected pre- and postoperatively significantly improved with the surgical procedure, independent of the plate type used (Table 6). HVA was corrected by an average of 33.862° (95% CI: 31.333-36.390) ( $P<0.001$ ) and IMA 1-2 on average by 11.846° (95% CI: 10.986-12.706) ( $P<0.001$ ). The AOFAS score improved by an average of 38.508 points (95% CI: 34.452-42.563) ( $P<0.001$ ).

**Table 6.** Paired samples t- test for pre- and postoperatively collected variables

<b>Pre- and Postoperative Measures</b>	<b>t</b>	<b>df</b>	<b>P*</b>	<b>Mean Difference</b>	<b>SE Difference</b>	<b>95% CI for Mean Difference</b>
HVA <sup>†</sup> [degrees]	26.758	64	<0.001	33.862	1.265	31.333-36.390
IMA 1-2 <sup>‡</sup> [degrees]	27.526	64	<0.001	11.846	0.430	10.986-12.706
AOFAS <sup>§</sup>	18.967	64	<0.001	38.508	2.030	42.563-34.452

\*Student's paired samples t- test on JASP program

<sup>†</sup>Hallux valgus angle (HVA)

<sup>‡</sup>Intermetatarsal 1-2 angle (IMA 1-2)

<sup>§</sup>American Orthopedic Foot and Ankle Society (AOFAS) score ranging from zero to 100

In the dorsomedial plating group, the HVA improved from a mean of 47.412° (95% CI: 44.037-50.786) to 13.941° (95% CI: 11.416-16.466). The IMA 1-2 was corrected from an average of 20.500° (95% CI: 19.188-21.812) preoperatively to 9.000° (95% CI: 19.188-21.812) postoperatively. The mean time until full weightbearing of the operated foot achieved was 7.294 weeks (95% CI: 6.122-8.466). The mean postoperative AOFAS score was 77 (95% CI: 72.154-81.846) points which is graded as "good". Pain on the visual analogue scale was averaged at 3.265 (95% CI: 2.350-4.180). The mean grade assigned to the overall surgical procedure by the patients was 1.912 (95% CI: 1.621- 2.203) which translates to "good" in the German school grading system. These descriptive results are visualized in Table 7.

**Table 7.** Descriptive statistics for the dorsomedial plating group

	Mean	95% Confidence Interval Mean	Minimum	Maximum
Grade*	1.912±0.866	1.621-2.203	1.000	4.000
Weeks until full weightbearing	7.294±3.486	6.122-8.466	2.000	15.000
HVA preop <sup>†</sup> [degrees]	47.412±10.040	44.037-50.786	21.000	67.000
HVA postop <sup>†</sup> [degrees]	13.941±7.511	11.416-16.466	2.000	34.000
IMA 1-2 preop <sup>‡</sup> [degrees]	20.500±3.902	19.188-21.812	13.000	27.000
IMA 1-2 postop <sup>‡</sup> [degrees]	9.000±2.807	8.057-9.943	4.000	14.000
AOFAS preop <sup>§</sup>	37.765±10.151	34.353-41.177	25.000	65.000
AOFAS postop <sup>§</sup>	77.000±14.416	72.154-81.846	47.000	100.000
Pain <sup>  </sup>	3.265±2.723	2.350-4.180	0.000	10.000

Data are presented as mean±standard deviation

\* German school grading system ranging from one to six

<sup>†</sup>Hallux valgus angle (HVA)

<sup>‡</sup>Intermetatarsal 1-2 angle (IMA 1-2)

<sup>§</sup>American Orthopedic Foot and Ankle Society (AOFAS) score ranging from zero to 100

<sup>||</sup>Pain on the Visual analogue scale (VAS) ranging from zero to ten

In the plantar plating group, the HVA decreased from a mean of 48.871° (95% CI: 45.932-51.810) to 14.581° (95% CI: 12.465-16.696). Additionally, the IMA 1-2 demonstrated a successful correction, with a reduction from an average of 22.516° (95% CI: 21.212-23.820) preoperatively to 10.290° (95% CI: 9.367-11.214) postoperatively. It took the patients averagely 4.806 (95% CI: 4,187-5.426) weeks until full weight bearing on the operated foot was reached. The postoperative AOFAS score averaged at 76.484 (95% CI: 72.512-80.456) points (good). Pain on the visual analogue scale was averaged at 2.742 (95% CI: 1.909-3.575).

The mean grade assigned to the overall surgical procedure by the patients was 1.484 (95% CI: 1.246-1.722) which translates to “very good” in the German school grading system. The descriptive results for the plantar plating group are visualized in Table 8.

**Table 8.** Descriptive statistics for the plantar plating group

	Mean	95% Confidence Interval Mean	Minimum	Maximum
Grade*	1.484±0.677	1.246-1.722	1.000	4.000
Weeks until full weightbearing	4.806±1.759	4.187-5.426	1.000	8.000
HVA preop <sup>†</sup> [degrees]	48.871±8.350	45.932-51.810	36.000	63.000
HVA postop <sup>†</sup> [degrees]	14.581±6.010	12.465-16.696	3.000	32.000
IMA 1-2 preop <sup>‡</sup> [degrees]	22.516±3.705	21.212-23.820	15.000	31.000
IMA 1-2 postop <sup>‡</sup> [degrees]	10.290±2.623	9.367-11.214	6.000	17.000
AOFAS preop <sup>§</sup>	38.774±9.875	35.298-42.250	20.000	60.000
AOFAS postop <sup>§</sup>	76.484±11.284	72.512-80.456	48.000	95.000
Pain <sup>  </sup>	2.742±2.366	1.909-3.575	0.000	9.000

Data are presented as mean±standard deviation

\* German school grading system ranging from one to six

<sup>†</sup>Hallux valgus angle (HVA) pre- and postoperative

<sup>‡</sup>Intermetatarsal 1-2 angle (IMA 1-2) pre- and postoperative

<sup>§</sup>American Orthopedic Foot and Ankle Society (AOFAS) score ranging from zero to 100 pre- and postoperative

<sup>||</sup>Pain on the Visual analogue scale (VAS) ranging from zero to ten postoperative

For comparison of the two groups, an independent samples t-test (student's test) was used. For the variables that deviated from normality in the test of equality of variances (Levene's test), a Mann-Whitney test was conducted.

The main outcome measures defined for this study and their respective *P*-values are depicted in Table 9. Neither the postoperative radiological analysis of the HVA nor the IMA 1-2 showed a statistically significant difference between the two different plating systems (*P*=0.708 and *P*=0.061, respectively). The postoperative AOFAS score did not differ significantly between the groups (*P*=0.874), with 77 and 76.484 points in the dorsomedial and plantar groups, respectively, both scores translating to “good” on the grading scale. The postoperative pain level also showed no statistically significant difference (*P*=0.414) between the groups, with 3.265 and 2.742 points on the VAS, respectively.

**Table 9.** T- test for the main outcome measures

Main Outcome Measures	t	df	P*
HVA postop <sup>†</sup>	-0.377	63	0.708
IMA 1-2 postop <sup>‡</sup>	-1.910	63	0.061
AOFAS postop <sup>§</sup>	0.160	63	0.874
Pain <sup>¶</sup>	0.823	63	0.414

\* Student's independent sample t-test

<sup>†</sup>Hallux valgus angle (HVA) postoperative

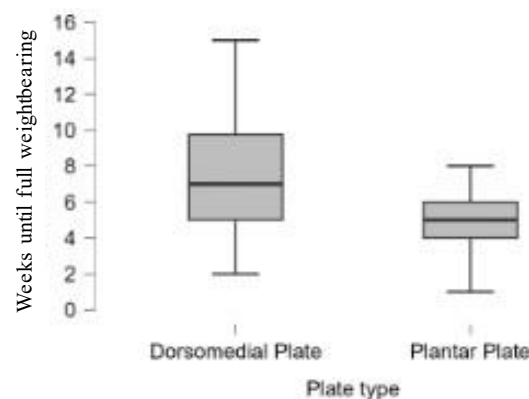
<sup>‡</sup>Intermetatarsal 1-2 angle (IMA 1-2) postoperative

<sup>§</sup>American Orthopedic Foot and Ankle Society (AOFAS) score ranging from zero to 100 postoperative

<sup>¶</sup>Pain on the Visual analogue scale (VAS) ranging from zero to ten postoperative

For the secondary outcome measures, the study group reported the number of pseudoarthrosis and reoperations necessary, weeks until full weight bearing and patient reported outcome in the form of an overall grading of the operation and whether the patient would repeat the operation with a simple yes or no answer. Three pseudoarthrosis were observed in the dorsomedial plating group that were not indicated for reoperation and none in the plantar plating group.

The time until full weight bearing of the operated foot was reached was significantly shorter ( $P=0.002$ ) in the plantar plating group as compared to the medial plating group with a mean of only  $4.806\pm 3.486$  weeks until full weight bearing was attained in the plantar group and  $7.294\pm 1.759$  weeks in the dorsomedial group (Figure 19).



**Figure 19.** Boxplot of weeks until full weightbearing after Lapidus arthrodesis surgery.

The patient reported outcome measures (PROM) of grading the operation did not differ significantly between the two groups ( $P=0.024$ ), although the grade “very good” was awarded with higher frequency in the plantar plating group (Table 10). The worst grade in both groups was a 4 or sufficient, no grade below 4 was recorded as a patient reported outcome measure.

**Table 10.** Frequencies of grades

Plate type	Grade	Frequency	Percent (%)
Dorsomedial Plate (N=34)	Very good	11	32.353
	Good	18	52.941
	Satisfactory	2	5.882
	Sufficient	3	8.824
Plantar Plate (N=31)	Very good	18	58.065
	Good	12	38.710
	Satisfactory	0	0.000
	Sufficient	1	3.226

27 out of 34 patients (79.4%) in the dorsomedial- and 29 out of 31 (93.5%) patients in the plantar plating group answered with “yes” to the question whether they would repeat the operation (Table 11).

**Table 11.** Frequencies of repeating- operation wish

Plate type	Redo	Frequency	Percent [%]
Dorsomedial Plate (N=34)	No	7	20.588
	Yes	27	79.412
Plantar Plate (N=31)	No	2	6.452
	Yes	29	93.548

There was no statistically significant difference in reoperating wish between the two groups ( $P=0.104$ ) although a slight tendency of higher patient satisfaction with nearly 94% reoperation- wish in the plantar plating group was observed. The results of the t-tests for the secondary outcome measures are listed in Table 12.

**Table 12.** T-test for secondary outcome measures

Secondary Outcome Measures	Statistic	df	$P^*$
Weeks until full weightbearing	759.000	63	0.002
Grading <sup>†</sup>	682.500	63	0.024
Redo of the Operation	452.500	63	0.104

\* Mann- Whitney independent samples t- test

<sup>†</sup> German school grading system ranging from one to six

## **5. DISCUSSION**

The Lapidus procedure is indicated for severe HV deformity (36) which can be fixated by a number of different plating systems (125, 126). This study aimed to compare to common approaches, the dorsomedial and the plantar plating systems in Lapidus arthrodesis surgery.

Our results are consistent with the literature (96, 114, 117, 131). All variables collected pre- and postoperatively including the HVA, IMA 1-2 and AOFAS score, improved significantly upon surgical treatment ( $P < 0.001$ ).

In experimental studies conducted on forefoot models, the plantar angle-stable plate construct showed a biomechanical benefit, which allows for conclusion of earlier resumption of weightbearing and lower rates of nonunion (136). Walther *et al.* could implement these results in a clinical study and showed fewer pseudoarthrosis, fewer hardware-problems including pain and soft tissue irritation (108) and no complications in wound healing in the plantar plating group compared to the dorsal plating group (117). Similar results showing superiority of the plantar plating system were published by Gutteck *et al.* (131). This study could reproduce these outcomes and most of our primary and secondary outcome measures had a tendency to be better in the plantar plating group but were statistically non-significant.

In the dorsomedial plating group, the HVA improved by a mean  $33.471^\circ$ . The IMA 1-2 was corrected by  $11.5^\circ$  from an average of  $20.500 \pm 3.902^\circ$  preoperatively to  $9.000 \pm 2.807^\circ$  postoperatively. In the plantar plating group, the HVA decreased by an average of  $34.29^\circ$  and the IMA 1-2 demonstrated a reduction of  $12.226^\circ$ . The correction power of the IMA 1-2 is consistent with the work of Walther *et al.*, who published  $11^\circ$  correction of the IMA 1-2 with a plantar plate (117). Similarly, Gutteck *et al.* achieved  $10.7^\circ$  reduction of the IMA 1-2 with a dorsal plate and  $10.2^\circ$  with a plantar plate (131). The reduction of the HVA in this study of a mean of  $33.862^\circ$  in both groups is substantially larger as compared to the literature. Olms *et al.* reported  $19.2^\circ$  correction (141), similar to the work of Orthner and Hofstätter with a correction of  $19^\circ$  (135). This might be explained by the fact that we only included patients with previously failed conservative treatment in an advanced stage of the disease, needing larger corrections for anatomical realignment of the first ray.

The postoperative pain level showed no statistically significant difference between the dorsomedial and plantar plating groups, with a mean of 3.265 and 2.742 points on the VAS, respectively ( $P = 0.414$ ). The patient reported outcome of grading the operation did not differ significantly between the two groups ( $P = 0.024$ ), although the grade “very good” was awarded with higher frequency in the plantar plating group (58% vs. 32%). 27 out of 34 patients (79.4%) in the dorsomedial- and 29 out of 31 (93.5%) patients in the plantar plating group answered with “yes” to the question whether they would repeat the operation.



There was no statistically significant difference in this outcome between the two groups ( $P=0.104$ ) although a slight tendency of higher patient satisfaction with nearly 94% reoperation-wish in the plantar plating group was observed. The slightly higher patient satisfaction and lower postoperative pain level might be explained by the “safe zone” of plantar placement with less irritation of the central tendon parts (132), superior force resistant (127) and excellent control to avoid elevation of the first metatarsal and transfermetatarsalgia (134).

The time until full weightbearing of the operated foot was reached was significantly shorter in the group supplied with the plantar plating system. These findings are consistent with the biomechanical benefit described for the tension-band effect of the plantar plating system (136), represented by earlier full weightbearing and a 100%-union rate. The main results as compared to the literature are summarized in Table 13 (114, 128).

**Table 13.** Comparison with results from the literature

	<b>Dorsomedial Plate</b>	<b>Plantar Plate</b>
Our Study (N=65)	Pseudoarthrosis: 3 Postoperative AOFAS*: 77	Pseudoarthrosis: 0 Postoperative AOFAS*: 76.5
Walther <i>et al.</i> † (N=40)	Pseudoarthrosis: 2 Hardware problems: 3 Delayed wound healing: 1	Pseudoarthrosis: 0 Hardware problems: 1 Delayed wound healing: 0
Gutteck <i>et al.</i> ‡ (N=34)	Pseudoarthrosis: 1 Hardware problems: 2 Delayed wound healing: 0 Postoperative AOFAS*: 91	Pseudoarthrosis: 0 Hardware problems: 0 Delayed wound healing: 0 Postoperative AOFAS*: 92

\*American Orthopedic Foot and Ankle Society (AOFAS) score ranging from zero to 100

†Walther M *et al.* Die Arthrodesse des Tarsometatarsal-I-Gelenkes mit einer plantaren Zuggurtungsosteosynthese (114).

‡Gutteck *et al.* Comparative study of Lapidus bunionectomy using different osteosynthesis methods (128).

The main shortcoming of this study is the lack of information about comorbidities in the operated patients, which may reflect in the surgical outcome. Smoking is not only strongly correlated with delayed wound healing following surgical procedures (142), but may also inhibit fracture healing through delayed chondrogenesis and endochondral ossification (143), which represent two of the most common complications in Lapidus arthrodesis surgery. There was no differentiation between the sexes and no information about bone density, a risk factor that is especially present in postmenopausal women.

Furthermore, other adverse effects such as arthritis and impaired mobility were only included in the postoperative AOFAS score and cannot be considered individually from the gathered data.

The main PROMs are highly subjective and based on the patient's overall experience with the clinic and the doctors, and are not necessarily limited to the surgical outcome of the hallux valgus. This might not only reflect in the overall grade for the surgery, but also in the reoperation wish, the AOFAS score and postoperative pain level. The level of pain an individual suffers is generally hard to quantify and is influenced by far more than simple aching or dullness in the operation wound. This bias can also be applied to the time until full weightbearing was reached. According to the clinic's postoperative protocol, pain-adapted weightbearing of the operated foot is allowed immediately, and full weightbearing after the second x-ray control after six weeks. This variable was specifically intended to ascertain the true time point, when pain-adapted became full weightbearing, despite the recommendations in the postoperative protocol. This moment in time however, is also difficult to verify and relies only on the subjective memory of the patients.

The sample is limited to 65 patients from Franconia, operated in a single clinic by the same experienced foot surgeon. Most patients have been connected to the clinic since the onset of their initial symptoms of HV and have high expectations for surgical treatment after conservative measures have been exhausted. This might reflect in an overall worse grade and patient satisfaction, when the high expectations are not met immediately postoperatively. Additionally, this study excluded patients with neurological and connective tissue disorders affecting the overall stability of the foot and can therefore not be applied to individuals suffering from concomitant foot deformities (144).

Further limitations arise from the methods of variable collection. Guyton criticized the AOFAS scoring system for not being a purely self-assessment score and for its mathematical weakness. He pointed out that the points are asymmetrically distributed, with "pain" accounting for 40 of the maximal 100 points (145), and the individual point distribution for the individual subcategories cannot be traced in the overall result. Another possible bias lies with the measurement of the HVA and IMA 1-2 on dorsoplantar and lateral foot radiographs. Saltzmann published error rates of 6° and 4° for the HVA and IMA 1-2 respectively (146), which can lead to severe over- and underestimation of the deformity or degree of surgical correction. The same applies to the DMAA, which is highly affected by longitudinal rotation and varus deviation of the first metatarsal and shows a poor interobserver reliability (147, 148).

## **6. CONCLUSION**

All variables collected pre- and postoperatively including the HVA, IMA 1-2 and AOFAS score, improved significantly upon surgical treatment.—However, no statistically significant difference was found in most of the outcomes between the plantar- and the dorsomedial plating group, although a tendency for a better patient reported outcome can be defined by higher frequency of the grade “very good” and bigger reoperation in the plantar plating group and quantified by a 100% union rate in the plantar plating group.

The time until full weightbearing of the operated foot was reached was significantly shorter in the plantar plating groups as compared to the medial plating.

The plantar plating system as compared to the dorsomedial plating system in Lapidus arthrodesis surgery is superior in terms of early full weightbearing and rates of pseudoarthrosis which can be translated to better and faster healing tendency. However, bony consolidation was not quantified radiologically in this study and further investigation would be necessary to confirm these findings, changing the study design to a prospective, double- blinded randomized study with clinical surveillance of the postoperative period.

Whichever plating system used, the surgical treatment of severe, symptomatic HV deformity remains the gold standard for treatment and significantly improves the deformity as quantified by radiologically and patient-reported outcomes.

## **7. REFERENCES**

1. Cardoso V, Mansur H, Castro I. Avaliação da qualidade de vida e parâmetros radiológicos após a correção do hálux valgo. *Sci J Foot Ankle*. 2019;13:3–9.
2. Rammelt S. Fuß- und Sprunggelenkchirurgie; Das Kursbuch. Schattauer GmbH; 2016. p. 89–116.
3. Piggott H. The natural history of hallux valgus in adolescence and early adult life. *J Bone Jt Surg*. 1960;42:749–60.
4. Coughlin MJ, Jones CP. Hallux Valgus: Demographics, Etiology, and Radiographic Assessment. *Foot Ankle Int*. 2007;28:759–77.
5. Strydom A, Saragas NP, Ferrao PNF. A radiographic analysis of the contribution of hallux valgus interphalangeus to the total valgus deformity of the hallux. *Foot ankle Surg Off J Eur Soc Foot Ankle Surg*. 2017;23:27–31.
6. Jezussek D, Höhle W, Schuh A. Clinical signs and diagnosis of hallux valgus. *MMW Fortschr Med*. 2006;148:33-34,36.
7. Wanivenhaus A, Pretterklieber M. First tarsometatarsal joint: anatomical biomechanical study. *Foot Ankle*. 1989;9:153–7.
8. Romash MM, Fugate D, Yanklowit B. Passive motion of the first metatarsal cuneiform joint: preoperative assessment. *Foot Ankle*. 1990;10:293–8.
9. Glasoe WM, Yack HJ, Saltzman CL. Anatomy and biomechanics of the first ray. *Phys Ther*. 1999;79:854–9.
10. Kuhn J, Alvi F. Hallux Valgus [Internet]. StatPearls Publishing. 2023. Available from: <https://www.ncbi.nlm.nih.gov/books/NBK553092/>.
11. Perera AM, Mason L, Stephens MM. The pathogenesis of hallux valgus. *J Bone Joint Surg Am*. 2011;93:1650–61.
12. Coughlin MJ. Hallux valgus. *J Bone Joint Surg Am*. 1996;78:932–66.
13. Hughes J, Clark P, Klenerman L. The importance of the toes in walking. *J Bone Joint Surg Br*. 1990;72:245–51.
14. Kernozek TW, Elfessi A, Sterriker S. Clinical and biomechanical risk factors of patients diagnosed with hallux valgus. *J Am Podiatr Med Assoc*. 2003;93:97–103.
15. Mann RA, Coughlin MJ. Hallux valgus-etiology, anatomy, treatment and surgical considerations. *Clin Orthop Relat Res*. 1981:31–41.
16. Talbot KD, Saltzman CL. Hallucal rotation: a method of measurement and relationship to bunion deformity. *Foot ankle Int*. 1997;18:550–6.
17. Inman VT. Hallux valgus: a review of etiologic factors. *Orthop Clin North Am*. 1974;5:59–66.

18. Saltzman CL, Aper RL, Brown TD. Anatomic determinants of first metatarsophalangeal flexion moments in hallux valgus. *Clin Orthop Relat Res.* 1997;261–9.
19. Sanders AP, Snijders CJ, van Linge B. Medial deviation of the first metatarsal head as a result of flexion forces in hallux valgus. *Foot Ankle.* 1992;13:515–22.
20. Snijders CJ, Snijder JG, Philippens MM. Biomechanics of hallux valgus and spread foot. *Foot Ankle.* 1986;7:26–39.
21. Wesker K. *Thieme Atlas of Anatomy: General Anatomy and Musculoskeletal System.* New York: Georg Thieme Verlag; 2007. p. 416.
22. Sommer C. *Operationstechniken in der Fußchirurgie - Eine praktische OP- Anleitung.* Springer Vienna; 2011. p. 50–72.
23. Aiyer AA, Shariff R, Ying L, Shub J, Myerson MS. Prevalence of metatarsus adductus in patients undergoing hallux valgus surgery. *Foot ankle Int.* 2014;35:1292–7.
24. Bascarević ZL, Vukasinović ZS, Bascarević VD, Stevanović VB, Spasovski D V, Janićić RR. Hallux valgus. *Acta Chir Iugosl.* 2011;58:107–11.
25. Tanaka Y, Takakura Y, Sugimoto K, Kumai T, Sakamoto T, Kadono K. Precise anatomic configuration changes in the first ray of the hallux valgus foot. *Foot ankle Int.* 2000;21:651–6.
26. Wang XJ, Bao BX, Wei FY, Zhang JZ. Clinical effects of simple hallux valgus surgery for transfer metatarsalgia. *Zhonghua Yi Xue Za Zhi.* 2017;97:2737–41.
27. Wülker N, Schulze M. *Fachlexikon Orthopädie Fuß.* ecomed Medizin & Biowissenschaften; 1996.
28. Dockery G. Evaluation and Treatment of Metatarsalgia and Keratic Disorders. In: Myerson MS, editor. *Foot and Ankle Disorders.* Saunders Company Philadelphia; 2000. p. 359–77.
29. Harb Z, Kokkinakis M, Ismail H, Spence G. Adolescent hallux valgus: a systematic review of outcomes following surgery. *J Child Orthop.* 2015;9:105–12.
30. Hecht PJ, Lin TJ. Hallux valgus. *Med Clin North Am.* 2014;98:227–32.
31. Golightly YM, Hannan MT, Dufour AB, Renner JB, Jordan JM. Factors associated with hallux valgus in a community-based cross-sectional study of adults with and without osteoarthritis. *Arthritis Care Res.* 2015;67:791–8.
32. Piqué-Vidal C, Solé MT, Antich J. Hallux valgus inheritance: pedigree research in 350 patients with bunion deformity. *J Foot Ankle Res.* 2007;46:149–54.

33. Arbeeveva L, Yau M, Mitchell BD, Jackson RD, Ryan K, Golightly YM, et al. Genome-wide meta-analysis identified novel variant associated with hallux valgus in Caucasians. *J Foot Ankle Res.* 2020;13:11.
34. Nix S, Smith M, Vicenzino B. Prevalence of hallux valgus in the general population: a systematic review and meta-analysis. *J Foot Ankle Res.* 2010;3:21.
35. Morton D. *The Human Foot. Its Evolution, Physiology and Functional Disorders.* Postgraduate Medical Journal. 1940. p. 270.
36. Wülker N, Stephens M, Cracchiolo A. *Operationsatlas Fuß und Sprunggelenk.* 2nd ed. Georg Thieme Verlag KG; 2007.10–35 p.
37. Coughlin MJ, Saltzman CL, Nunley JA 2nd. Angular measurements in the evaluation of hallux valgus deformities: a report of the ad hoc committee of the American Orthopaedic Foot & Ankle Society on angular measurements. *Foot ankle Int.* 2002;23:68–74.
38. Smith RW, Reynolds JC, Stewart MJ. Hallux valgus assessment: report of research committee of American Orthopaedic Foot and Ankle Society. *Foot Ankle.* 1984;5:92–103.
39. Hardy RH, Clapham JCR. Observations on hallux valgus; based on a controlled series. *J Bone Joint Surg Br.* 1951;33:376–91.
40. Coughlin MJ. Hallux valgus in men: effect of the distal metatarsal articular angle on hallux valgus correction. *Foot ankle Int.* 1997;18:463–70.
41. Lau BC, Allahabadi S, Palanca A, Oji DE. Understanding Radiographic Measurements Used in Foot and Ankle Surgery. *J Am Acad Orthop Surg.* 2022;30:139–54.
42. Robinson AHN, Limbers JP. Modern concepts in the treatment of hallux valgus. *J Bone Joint Surg Br.* 2005;87:1038–45.
43. Xu H, Jin K, Fu Z, Ma M, Liu Z, An S, et al. Radiological characteristics and anatomical risk factors in the evaluation of hallux valgus in chinese adults. *Chin Med J.* 2015;128:51–7.
44. Stukenborg-Colsman C, Plaass C, Baumbach S, Ettinger S. Hohe Prävalenz - geringe Therapieevidenz: Hallux Valgus - Diagnostik und Therapie. *Orthopädie und Unfallchirurgie - Mitteilungen und Nachrichten.* 2023;13:34–8.
45. Choi JY, Ahn HC, Baek HS, Park JH, Suh JS. Factors influencing medial sesamoid arthritis in patients with hallux valgus deformity: Magnetic resonance imaging evaluation. *Foot ankle Surg Off J Eur Soc Foot Ankle Surg.* 2019;25:612–7.



46. Sanders AP, Weijers RE, Snijders CJ, Schon LC. Three-dimensional reconstruction of magnetic resonance images of a displaced flexor hallucis longus tendon in hallux valgus. *J Am Podiatr Med Assoc.* 2005;95:401–4.
47. Menz HB, Roddy E, Thomas E, Croft PR. Impact of hallux valgus severity on general and foot-specific health-related quality of life. *Arthritis Care Res.* 2011;63:396–404.
48. Lewis TL, Ray R, Gordon DJ. The impact of hallux valgus on function and quality of life in females. *Foot ankle Surg Off J Eur Soc Foot Ankle Surg.* 2022;28:424–30.
49. Zirngibl B, Grifka J, Baier C, Götz J. Hallux valgus: Etiology, diagnosis, and therapeutic principles. *Orthopade.* 2017;46:283–96.
50. Kwan M-Y, Yick K-L, Yip J, Tse C-Y. Hallux valgus orthosis characteristics and effectiveness: a systematic review with meta-analysis. *BMJ Open.* 2021;11:047273.
51. Torkki M, Malmivaara A, Seitsalo S, Hoikka V, Laippala P, Paavolainen P. Surgery vs orthosis vs watchful waiting for hallux valgus: a randomized controlled trial. *JAMA.* 2001;285:2474–80.
52. Stukenborg-Colsman C. Hallux valgus. *Orthopade.* 2017;46:387.
53. Klugarova J, Hood V, Bath-Hextall F, Klugar M, Mareckova J, Kelnarova Z. Effectiveness of surgery for adults with hallux valgus deformity: a systematic review. *JBI database Syst Rev Implement reports.* 2017;15:1671–710.
54. Rampal V, Giuliano F. Forefoot malformations, deformities and other congenital defects in children. *Orthop Traumatol Surg Res.* 2020;106:115–23.
55. Ford LA, Hamilton GA. Procedure selection for hallux valgus. *Clin Podiatr Med Surg.* 2009;26:395–407.
56. Waizy H, Dohle J. Die aktuelle S2e-Leitlinie zum Hallux valgus. *Dtsch Ärzteverlag.* 2016;5:668–72.
57. Leventen EO. The Chevron procedure. *Orthopedics.* 1990;13:973–6.
58. Austin DW, Leventen EO. A new osteotomy for hallux valgus: a horizontally directed “V” displacement osteotomy of the metatarsal head for hallux valgus and primus varus. *Clin Orthop Relat Res.* 1981:25–30.
59. Trnka H-J. Osteotomies for hallux valgus correction. *Foot Ankle Clin.* 2005;10:15–33.
60. Barouk L. Scarf osteotomy for hallux valgus correction. Local anatomy, surgical technique and combination with other forefoot procedures. *Foot Ankle Clin.* 2000:525–55.
61. Smith AM, Alwan T, Davies MS. Perioperative complications of the Scarf osteotomy. *Foot ankle Int.* 2003;24:222–7.

62. Dereymaeker G. Scarf osteotomy for correction of hallux valgus. Surgical technique and results as compared to distal chevron osteotomy. *Foot Ankle Clin.* 2000;5:513–24.
63. Molloy A, Widnall J. Scarf osteotomy. *Foot Ankle Clin.* 2014;19:165–80.
64. Meyer M. Eine neue Modifikation der Hallux-valgus-Operation. *Zbl Chir.* 1926;53:3215–68.
65. Barouk LS. The Weil Lesser Metatarsal Osteotomy. In: *Forefoot Reconstruction*. Paris: Springer Paris; 2005. p. 115–38.
66. Barouk LS. Notre experience de l'osteotomie "scarf" des premier et cinquieme metatarsiens. *Med Chir Pied.* 1992;8:67–84.
67. Barouk LS. Osteotomie scarf du premier metatarsiens. *Med Chir Pied.* 1994;10:111–20.
68. Barouk LS. Forefoot reconstruction. In: Springer. 2nd ed. Paris: Springer- Verlag; 2003. p. 389.
69. Sammarco GJ, Idusuyi OB. Complications after surgery of the hallux. *Clin Orthop Relat Res.* 200;59–71.
70. Mothorshed RA. Osteotomies of the first metatarsal base. In: Banks AS, Downey MS, Martin DE, Miller SJ, editors. *McGlamry's comprehensive textbook of foot and ankle surgery*. Philadelphia. Lippincott Williams & Wilkins; 2001.
71. Easley ME, Trnka H-J. Current concepts review: hallux valgus part II: operative treatment. *Foot ankle Int.* 2007;28:748–58.
72. Wanivenhaus AH, Feldner-Busztin H. Basal osteotomy of the first metatarsal for the correction of metatarsus primus varus associated with hallux valgus. *Foot Ankle.* 1988;8:337–43.
73. Wukich DK, Roussel AJ, Dial DM. Correction of metatarsus primus varus with an opening wedge plate: a review of 18 procedures. *J Foot Ankle Surg.* 2009;48:420–6.
74. Juvara E. Nouveau procédé pour la cure radicale du hallux valgus. *Press Méd.* 1919;40:395–7.
75. Martin DE, Blich EL. Alternatives to the closing base wedge osteotomy. *Clin Podiatr Med Surg.* 1996;13:515–31.
76. Schubert JM, Reilly CH, Gudas CJ. The closing wedge osteotomy. A critical analysis of first metatarsal elevation. *J Am Podiatry Assoc.* 1984;74:13–24.
77. Banks AS, Cargill RS 2nd, Carter S, Ruch JA. Shortening of the first metatarsal following closing base wedge osteotomy. *J Am Podiatr Med Assoc.* 1997;87:199–208.

78. Trnka HJ, Mühlbauer M, Zembsch A, Hungerford M, Ritschl P, Salzer M. Basal closing wedge osteotomy for correction of hallux valgus and metatarsus primus varus: 10- to 22-year follow-up. *Foot ankle Int.* 1999;20:171–7.
79. Resch S, Stenström A, Egund N. Proximal closing wedge osteotomy and adductor tenotomy for treatment of hallux valgus. *Foot Ankle.* 1989;9:272–80.
80. Podiatry Learning Network [Internet]. Baravarian B, Green DR, Kim P: Point-Counterpoint: Should The Lapidus Replace The Closing Base Wedge Osteotomy?; 2004 Oct [cited 2023 Jun 5] Available from: <https://www.hmpgloballearningnetwork.com/site/podiatry/article/3035>
81. Akin OF. The treatment of hallux valgus: a new operative procedure and its results. *Med Sentin.* 1925;33:678–9.
82. Frey C, Jahss M, Kummer FJ. The Akin procedure: an analysis of results. *Foot Ankle.* 1991;12:1–6.
83. Healthcare Financials [Internet]. Gerogia: PodiatryPrep; Schwartz NH, Greenberg PM, Neese DJ. The Akin Osteotomy and its Modifications [Internet]. Foot and Ankle Research Consortium. Norcross, Gerorgia; 2020 [cited 2023 Jun 6]. Available from: [https://healthcarefinancials.files.wordpress.com/2020/07/311.akin\\_osteotomy](https://healthcarefinancials.files.wordpress.com/2020/07/311.akin_osteotomy).
84. Martinez Gimenez E, Verdu Roman C, Sanz-Reig J, Morales Santías M, Bustamante Suarez de Puga D, Mas Martinez J. Progressive Akin Osteotomy. *Clin Med Insights Arthritis Musculoskelet Disord.* 2019;12:11.
85. Douthett SM, Plaskey NK, Fallat LM, Kish J. Retrospective Analysis of the Akin Osteotomy. *J Foot Ankle Surg.* 2018;57:38–43.
86. Sanhudo J. Clinical Tip: Modified Akin Osteotomy. *Foot ankle Int - Am Orthop Foot Ankle Soc and Swiss Foot Ankle Soc.* 2005;26:901–2.
87. Albrecht G. Zur Pathologie und Therapie des Hallux valgus. *Rus Wratsch.* 1911;10:14–9.
88. Lapidus PW. Operative corrections of metatarsus varus primus in hallux valgus. *Surg Gynecol Obs.* 1934;58:183–91.
89. Lapidus PW. The author's bunion operation from 1931 to 1959. *Clin Orthop.* 1960;16:119–35.
90. Hase C. Die orthopädische Untersuchung des ausgewachsenen Fußes. *Orthoädie und Unfallchirurgie up2date.* 2015;10:505–20.

91. Yeung T, Lui TH. Arthroscopic Lapidus Arthrodesis of the First Tarsometatarsal Joint for Treatment of Hallux Valgus Deformity of the Foot. *Arthrosc Tech.* 2022;11:1065–9.
92. Shah MA, Stirling BE, Gonzalez TA, Jackson JB. Hallux Valgus with Increased DMAA Correction by Modified Lapidus Procedure. *Foot & Ankle Orthopaedics.* 2022;18;7:24.
93. Mansfield PJ, Neumann DA. Chapter 11 - Structure and Function of the Ankle and Foot. In: Mansfield PJ, Neumann DABT-E of K for the PTA. 3rd edition. St. Louis (MO): Mosby; 2019. p. 311–50.
94. Fuhrmann RA. Arthrodesis of the first tarsometatarsal joint for correction of the advanced splayfoot accompanied by a hallux valgus. *Oper Orthop Traumatol.* 2005;17:195–210.
95. Menke CRD, McGlamry MC, Camasta CA. Lapidus arthrodesis with a single lag screw and a locking H-plate. *J Foot Ankle Surg.* 2011;50:377–82.
96. Blitz NM, Lee T, Williams K, Barkan H, DiDimenico LA. Early weight bearing after modified lapidus arthrodesis: a multicenter review of 80 cases. *J Foot Ankle Surg.* 2010;49:357–62.
97. Myerson MS, Schon LC, McGuigan FX, Ozgur A. Result of arthrodesis of the hallux metatarsophalangeal joint using bone graft for restoration of length. *Foot ankle Int.* 2000;21:297–306.
98. Symeonidis PD, Anderson JG. Original and Modified Lapidus Procedures: Proposals for a New Terminology. *J Bone Joint Surg Am.* 2021;103:15.
99. Clark HR, Veith RG, Hansen STJ. Adolescent bunions treated by the modified Lapidus procedure. *Bull Hosp Jt Dis Orthop Inst.* 1987;47:109–22.
100. Stürmer KM. Elastic plate osteosynthesis, biomechanics, indications and technique in comparison with rigid osteosynthesis. *Unfallchirurg.* 1996;99:816–29.
101. Wirth CJ, Püschmann H. Häufigkeit der Komplikationen. In: Wirth CJ, Mutschler W, Bischoff HP, Püschmann H, Neu J, editors. *Orthopädie und Unfallchirurgie - vermeiden-erkennen-behandeln.* Stuttgart: Thieme; 2010. p. 10-13.
102. Duan X, Kadakia AR. Salvage of recurrence after failed surgical treatment of hallux valgus. *Arch Orthop Trauma Surg.* 2012;132:477–85.
103. Thompson IM, Bohay DR, Anderson JG. Fusion rate of first tarsometatarsal arthrodesis in the modified Lapidus procedure and flatfoot reconstruction. *Foot ankle Int.* 2005;26:698–703.

104. Lagaay PM, Hamilton GA, Ford LA, Williams ME, Rush SM, Schuberth JM. Rates of revision surgery using Chevron-Austin osteotomy, Lapidus arthrodesis, and closing base wedge osteotomy for correction of hallux valgus deformity. *J Foot Ankle Surg.* 2008;47:267–72.
105. Saxena A, Nguyen A, Nelsen E. Lapidus bunionectomy: Early evaluation of crossed lag screws versus locking plate with plantar lag screw. *J Foot Ankle Surg.* 2009;48:170–9.
106. Patel S, Ford LA, Etcheverry J, Rush SM, Hamilton GA. Modified lapidus arthrodesis: rate of nonunion in 227 cases. *J Foot Ankle Surg.* 2004;43:37–42.
107. Wang B, Manchanda K, Lalli T, Wukich DK, Liu GT, Raspovic K, et al. Identifying Risk Factors for Nonunion of the Modified Lapidus Procedure for the Correction of Hallux Valgus. *J Foot Ankle Surg.* 2022;61:1001–6.
108. Peterson KS, McAlister JE, Hyer CF, Thompson J. Symptomatic Hardware Removal After First Tarsometatarsal Arthrodesis. *J Foot Ankle Surg.* 2016;55:55–9.
109. Klos K, Wilde CH, Lange A, Wagner A, Gras F, Skulev HK, et al. Modified Lapidus arthrodesis with plantar plate and compression screw for treatment of hallux valgus with hypermobility of the first ray: a preliminary report. *Foot Ankle Surg.* 2013;19:239–44.
110. Ahn J, Lee HS, Seo JH, Kim JY. Second Metatarsal Transfer Lesions Due to First Metatarsal Shortening After Distal Chevron Metatarsal Osteotomy for Hallux Valgus. *Foot ankle Int.* 2016;37:589–95.
111. Wirth CJ. Komplikationen bei der Behandlung von Fehlentwicklungen und Erkrankungen des Fußes. In: Wirth CJ, Mutschler W, Neu J, editors. *Komplikationen Kompakt: Orthopädie und Unfallchirurgie.* Stuttgart: Thieme; 2016. p. 172–4.
112. Claes L. Das Prinzip der winkelstabilen Platte - eine kritische Bewertung. *Orthopädie und Unfallchirurgie up2date.* 2011;6:3–15.
113. Klos K, Gueorguiev B, Mückley T, Fröber R, Hofmann GO, Schwieger K, et al. Stability of medial locking plate and compression screw versus two crossed screws for lapidus arthrodesis. *Foot ankle Int.* 2010;31:158–63.
114. Scranton PE, Coetzee JC, Carreira D. Arthrodesis of the first metatarsocuneiform joint: a comparative study of fixation methods. *Foot ankle Int.* 2009;30:341–5.
115. Jones C, Coughlin M, Petersen W, Herbot M, Paletta J. Mechanical comparison of two types of fixation for proximal first metatarsal crescentic osteotomy. *Foot ankle Int.* 2005;26:371–4.
116. Kumar S, Pradhan R, Rosenfeld PF. First metatarsophalangeal arthrodesis using a dorsal plate and a compression screw. *Foot ankle Int.* 2010;31:797–801.

117. Walther M, Simons P, Nass K, Röser A. Die Arthrodesese des Tarsometatarsal-I-Gelenkes mit einer plantaren Zuggurtungsosteosynthese. *Orthop Traumatol.* 2011;23:52–60.
118. Coughlin MJ, Grebing BR, Jones CP. Arthrodesis of the first metatarsophalangeal joint for idiopathic hallux valgus: intermediate results. *Foot ankle Int.* 2005;26:783–92.
119. Dittmer DK, Teasell R. Complications of immobilization and bed rest. Part 1: Musculoskeletal and cardiovascular complications. *Can Fam Physician.* 1993;39:1428-1432,1435-1437.
120. Teasell R, Dittmer D. Complications of immobilization and bed rest. Part 2: Other complications. *Can Fam Physician.* 1993;39:1440-1442,1445.
121. Blenman PR, Carter DR, Beaupré GS. Role of mechanical loading in the progressive ossification of a fracture callus. *J Orthop Res Soc.* 1989;7:398–407.
122. Claes LE, Heigele CA. Magnitudes of local stress and strain along bony surfaces predict the course and type of fracture healing. *J Biomech.* 1999;32:255–66.
123. Aro HT, Chao EY. Bone-healing patterns affected by loading, fracture fragment stability, fracture type, and fracture site compression. *Clin Orthop Relat Res.* 1993:8–17.
124. Chao EY, Aro HT, Lewallen DG, Kelly PJ. The effect of rigidity on fracture healing in external fixation. *Clin Orthop Relat Res.* 1989:24–35.
125. Cohen DA, Parks BG, Schon LC. Screw fixation compared to H-locking plate fixation for first metatarsocuneiform arthrodesis: a biomechanical study. *Foot ankle Int.* 2005;26:984–9.
126. Gruber F, Sinkov VS, Bae S-Y, Parks BG, Schon LC. Crossed screws versus dorsomedial locking plate with compression screw for first metatarsocuneiform arthrodesis: a cadaver study. *Foot ankle Int.* 2008;29:927–30.
127. Drummond D, Motley T, Kosmopoulos V, Ernst J. Stability of Locking Plate and Compression Screws for Lapidus Arthrodesis: A Biomechanical Comparison of Plate Position. *J Foot Ankle Surg.* 2018;57:466–70.
128. AO Surgery Reference [Internet]. Buckley RE, Nousianine MT, Mohammad KF, Yoo B. Dorsal approach to the first metatarsal. 2021 [updated 2022; cited 2023 Jun 23]. Available from: <https://surgeryreference.aofoundation.org/orthopedic-trauma/adult-trauma/midfoot/approach/dorsal-approach-to-the-first-metatarsal>
129. Dayton P, Glynn A, LoPiccolo J. Medial Incision Approach to the First Metatarsophalangeal Joint. *J Foot Ankle Surg.* 2001;40:414–7.

130. Ettinger S, Stukenborg-Colsman C, Yao D, Claassen L, Savov P, Plaass C. Komplikationen nach TMT-I-Arthrodesse zur Behandlung von Hallux valgus Deformitäten. *Fuß Sprunggelenk*. 2017.
131. Gutteck N, Wohlrab D, Zeh A, Radetzki F, Delank K-S, Lebek S. Comparative study of Lapidus bunionectomy using different osteosynthesis methods. *Foot Ankle Surg*. 2013;19:218–21.
132. Schilde S, Ketelhut L, Kielstein H, Delank K-S, Gutteck N. Anatomical study of Lapidus arthrodesis using two different plantar plate systems. *Foot Ankle Surg*. 2020;26:585–90.
133. Plaass C, Claassen L, Daniilidis K, Fumy M, Stukenborg-Colsman C, Schmiedl A, et al. Placement of Plantar Plates for Lapidus Arthrodesis: Anatomical Considerations. *Foot ankle Int*. 2016;37:427–32.
134. López-López D, Larrainzar-Garijo R, De-Bengoa-Vallejo RB, Losa-Iglesias ME, Bayod-López J. Effectiveness of the Lapidus plate system in foot surgery: A PRISMA compliant systematic review. *Int Wound J*. 2022;19:507–14.
135. Orthner E, Hofstätter SG. Lapidusarthrodesse mit unidirektionaler winkelstabiler Platte und sofortiger Vollbelastung – eine prospektive Studie. *Fuß Sprunggelenk*. 2009;7:178–85.
136. Klos K, Simons P, Hajduk A-S, Hoffmeier KL, Gras F, Fröber R, et al. Plantar versus dorsomedial locked plating for Lapidus arthrodesis: a biomechanical comparison. *Foot ankle Int*. 2011;32:1081–5.
137. Deutsches Fußzentrum [Internet]. Richter M. American Orthopaedic Foot and Ankle Society (AOFAS) Score, Erster Vorfußstrahl / 1st Forefoot Ray (Validierte deutsche Version, max. 100 Punkte). 2011 [cited 2023 Jun 3]. Available from: [https://www.deutsches-fusszentrum-richter.de/sitesmedia/rummelsberg/downloads/01\\_medizin-pflege/fachabteilungen/fuss/merkblaetter\\_richter/aofas\\_deutsch](https://www.deutsches-fusszentrum-richter.de/sitesmedia/rummelsberg/downloads/01_medizin-pflege/fachabteilungen/fuss/merkblaetter_richter/aofas_deutsch).
138. Kostuj T, Schaper K, Baums M, Lieske S. Eine Validierung des AOFAS-Ankle-Hindfoot-Scale für den deutschen Sprachraum. *Fuß Sprunggelenk*. 2014;12:100–6.
139. Kitaoka HB, Alexander IJ, Adelaar RS, Nunley JA, Myerson MS, Sanders M. Clinical rating systems for the ankle-hindfoot, midfoot, hallux, and lesser toes. *Foot ankle Int*. 1994;15:349–53.
140. Delgado DA, Lambert BS, Boutris N, McCulloch PC, Robbins AB, Moreno MR, et al. Validation of Digital Visual Analog Scale Pain Scoring With a Traditional Paper-based Visual Analog Scale in Adults. *J Am Acad Orthop Surg Glob Res Rev*. 2018;2:88.

141. Olms K, Braemer A, Randt T, Radigk S, Schulz AP. Die Lapidus Arthrodesse zur Korrektur des Hallux valgus. *Fuß Sprunggelenk*. 2009;7:164–72.
142. Araco A, Gravante G, Sorge R, Araco F, Delogu D, Cervelli V. Wound infections in aesthetic abdominoplasties: the role of smoking. *Plast Reconstr Surg*. 2008;121:305-310.
143. El-Zawawy HB, Gill CS, Wright RW, Sandell LJ. Smoking delays chondrogenesis in a mouse model of closed tibial fracture healing. *J Orthop Res Soc*. 2006;24:2150–8.
144. Seidenstein AH, Torrez TW, Andrews NA, Patch DA, Conklin MJ, Shah A. Pediatric hallux valgus: An overview of history, examination, conservative, and surgical management. *Paediatr Child Health*. 2022;27:75–81.
145. Guyton GP. Theoretical limitations of the AOFAS scoring systems: an analysis using Monte Carlo modeling. *Foot ankle Int*. 2001;22:779–87.
146. Saltzman CL, Brandser EA, Berbaum KS, DeGnore L, Holmes JR, Katcherian DA et al. Reliability of standard foot radiographic measurements. *Foot ankle Int*. 1994;15:661–5.
147. Vittetoe DA, Saltzman CL, Krieg JC, Brown TD. Validity and reliability of the first distal metatarsal articular angle. *Foot ankle Int*. 1994;15:541–7.
148. Robinson AHN, Cullen NP, Chhaya NC, Sri-Ram K, Lynch A. Variation of the distal metatarsal articular angle with axial rotation and inclination of the first metatarsal. *Foot ankle Int*. 2006;27:1036–40.
149. Arthrex GmbH [Internet]. Midfoot Plating Techniques, Surgical Technique. 2018 [cited 2023 Jul 07]. Available from: [https://www.arthrex.com/resources/LT2-0433-EN/midfoot-plating-techniques?referringteam=foot\\_and\\_ankle](https://www.arthrex.com/resources/LT2-0433-EN/midfoot-plating-techniques?referringteam=foot_and_ankle)
150. Arthrex GmbH [Internet]. Plantar Lapidus Plate - Surgical Technique. 2017 [cited 2023 Jul 07]. Available from: [https://www.arthrex.com/resources/LT2-0488-EN/plantar-lapidus-plate?referringteam=foot\\_and\\_ankle](https://www.arthrex.com/resources/LT2-0488-EN/plantar-lapidus-plate?referringteam=foot_and_ankle)



## **8. SUMMARY**

**Objectives:** This thesis wanted to compare the outcomes of two common approaches to the Lapidus arthrodesis in symptomatic hallux valgus, the plantar- and the dorsomedial plating systems quantified by radiological analysis of the deformity and patient-reported outcome measures (PROMs). The hypothesis was that the plantar- plating system is superior to the dorsomedial plating system.

**Material and methods:** This is an observational retrospective study conducted at the alphaMED orthopaedic clinic in Bamberg, Germany, from January 2014 to December 2017. The study included 43 patients treated with the dorsomedial Titanium Lapidus Plating System (AR-8941)® and 34 patients treated with the Plantar Lapidus Plating System® for symptomatic HV deformity. Preoperative measures included clinical and radiological examinations, as well as assessment of HVA and IMA 1-2, AOFAS score, and pain on the VAS. Postoperative measures included clinical and radiological examinations, assessment of the HVA and IMA 1-2, AOFAS score, pain score on VAS, patient satisfaction, and German school scoring system ranking. Pseudoarthrosis, reoperations and time to full weightbearing were collected.

**Results:** All variables collected pre- and postoperatively including the HVA, IMA 1-2 and AOFAS score, improved significantly upon surgical treatment ( $P<0.001$ ). However, no statistically significant difference was found between the plantar- and the dorsomedial plating group, including the HVA, IMA 1-2, AOFAS score, postoperative pain level, overall grade and reoperation wish, although the grade “very good” was awarded with higher frequency and the reoperation wish was bigger in the plantar plating group. Three cases of pseudoarthrosis were observed in the dorsomedial plating group and none in the plantar plating group, showing no statistically significant difference but again a tendency for better outcome in the plantar plating group. The time until full weightbearing of the operated foot was reached however, was significantly shorter ( $P=0.002$ ) in the plantar plating groups as compared to the medial plating groups.

**Conclusion:** As hypothesized, the plantar plating system as compared to the dorsomedial plating system in Lapidus arthrodesis surgery is superior in terms of early full weightbearing and rates of pseudoarthrosis which can be translated to better and faster healing tendency. However, bony consolidation was not quantified radiologically in this study and further investigation would be necessary to confirm these findings, changing the study design to a prospective, double- blinded randomized study with clinical surveillance of the postoperative period. Whichever plating system used, the surgical treatment of severe HV deformity remains the gold standard for treatment and significantly improves the deformity as quantified by radiologically and patient-reported outcomes.

## **9. CROATIAN SUMMARY**

**Naslov:** USPOREDBA KIRURŠKOG ISHODA KOD OPERACIJE LAPIDUS ARTRODEZE – PLANTARNI VS. DORZOMEDIJALNI PRISTUP

**Ciljevi:** Ova disertacija ima za cilj usporediti ishode dvaju uobičajenih pristupa u Lapidus artrodezi kod simptomatskog hallux valgusa, plantarnog i dorzomedijalnog sustava pločica, kvantificiranih radiološkom analizom deformiteta i mjera ishoda izvješćenih od strane bolesnika. Hipoteza je da je plantarni sustav pločica superiorniji u odnosu na dorsomedijalni sustav pločica.

**Materijal i metode:** Ovo je opservacijska retrospektivna studija provedena u ortopedskoj klinici alphaMED u Bambergu, Njemačka, od siječnja 2014. do prosinca 2017. godine. U studiju je uključeno 43 bolesnika koji su liječeni dorzomedijalnim Titanijum Lapidus sustavom pločica (AR-8941)<sup>®</sup> i 34 bolesnika koji su liječeni Plantarnim Lapidus sustavom pločica<sup>®</sup> za simptomatski deformitet HV. Preoperativne mjere uključivale su klinički i radiološki pregled, kao i procjenu HVA i IMA 1-2, AOFAS rezultata i boli na VAS-u. Poslijeoperacijske mjere uključivale su klinički i radiološki pregled, procjenu HVA i IMA 1-2, AOFAS rezultata, ocjenu boli na VAS ljestvici, zadovoljstvo bolesnika i ocjenjivanje operacije prema njemačkom školskom sustavu bodovanja (od 1 do 6), pri čemu je 1 najbolji (najviši, vrlo dobro). Prikupljeni su podaci o pseudartrozi, reoperacijama i vremenu do potpunog opterećenja noge.

**Rezultati:** Sve varijable prikupljene prije i poslije operacije, uključujući HVA, IMA 1-2 i AOFAS rezultate, značajno su se poboljšale nakon kirurškog liječenja ( $P < 0.001$ ). Međutim, nije pronađena statistički značajna razlika između skupina s plantarnim i dorzomedijalnim pristupom, uključujući HVA, IMA 1-2, AOFAS rezultate, razinu boli nakon operacije, ukupnu ocjenu i želju za reoperacijom, iako je ocjena "vrlo dobro" dodijeljena s većom frekvencijom, a želja za reoperacijom bila veća u grupi s plantarnim pristupom. Uočena su tri slučaja pseudartroze u skupini bolesnika s dorzomedijalnim pristupom dok u skupini s plantarnim pristupom ih nije bilo, što pokazuje da nema statistički značajne razlike, ali opet postoji tendencija boljeg ishoda u skupini s plantarnim pristupom. Vrijeme do potpunog opterećenja operirane noge bilo je značajno kraće ( $P = 0.002$ ) u skupini s plantarnim pristupom u usporedbi s dorzomedijalnom skupinom.

**Zaključci:** Kao što je hipoteza sugerirala, plantarni sustav pločica u usporedbi s dorsomedijalnim sustavom pločica u Lapidus artrodezi je superiorniji u pogledu rane potpune podrške tjelesne težine i stope pseudartroze, što se može prevesti u bolje i brže zacjeljivanje. Međutim, cijeljenje kostiju nije bilo kvantificirano radiološki u ovoj studiji, te bi daljnje istraživanje bilo potrebno kako bi se potvrdili ovi nalazi, mijenjajući dizajn studije u prospektivnu, dvostruko slijepu randomiziranu studiju s kliničkim nadzorom postoperativnog razdoblja. Bez obzira na to koji se sustav pločica koristi, kirurško liječenje teškog HV deformiteta ostaje zlatni standard liječenja i značajno poboljšava deformitet, što je kvantificirano radiološki i od strane samih bolesnika.