

Multinucleated giant extravillous trophoblast cells in the decidua of placentas from pregnancies complicated with preeclampsia

Berkovic, Anna Helene

Master's thesis / Diplomski rad

2017

Degree Grantor / Ustanova koja je dodijelila akademski / stručni stupanj: **University of Split, School of Medicine / Sveučilište u Splitu, Medicinski fakultet**

Permanent link / Trajna poveznica: <https://um.nsk.hr/um:nbn:hr:171:654689>

Rights / Prava: [In copyright](#)/[Zaštićeno autorskim pravom.](#)

Download date / Datum preuzimanja: **2025-01-28**



Repository / Repozitorij:

[MEFST Repository](#)



**UNIVERSITY OF SPLIT
SCHOOL OF MEDICINE**

Anna Berkovic

**MULTINUCLEATED GIANT EXTRAVILLOUS TROPHOBLAST
CELLS IN THE DECIDUA OF PLACENTAS COMPLICATED
WITH PREECLAMPSIA**

Diploma thesis

Academic year: 2016/2017

Mentor: Sandra Zekic Tomas, MD, PhD

Split, July, 2017

Contents

1. Introduction	4
1.1. Preeclampsia.....	4
1.1.1. Definition.....	5
1.1.2. Epidemiology.....	5
1.1.3. Etiology	6
1.2. Placenta.....	7
1.2.1. Development of placenta and its role in normal pregnancy.....	7
1.2.2. Placenta in preeclampsia	10
1.2.3. Multinucleated Giant Cells.....	11
2. Hypothesis	13
3. Material and Methods	15
4. Results	18
5. Discussion	21
6. Conclusion	24
7. References	26
8. Summary (English)	30
9. Summary (Croatian)	32
10. Curriculum Vitae	34

Acknowledgment

I want to thank Sandra Zekic Tomas, MD, PhD, who has patiently mentored me throughout the work for my diploma thesis and introduced me so kindly to pathology and laboratory work.

1. Introduction

1.1. Preeclampsia

1.1.1. Definition

Preeclampsia (PE) is a pregnancy related disorder, characterized by raised blood pressure and signs of kidney damage. The onset of this condition is usually after 20 weeks of gestation.

According to the American College of Obstetricians and Gynecologists (ACOG), the criteria for the diagnosis of PE include onset of a new episode of hypertension during pregnancy, characterized with persistent hypertension (systolic blood pressure ≥ 140 mmHg or diastolic blood pressure ≥ 90 mm Hg) and substantial proteinuria (>300 mg/L/24 hours) (1). In case of absence of proteinuria or proteinuria below the diagnostic threshold, other diagnostic criteria are required. They include impaired liver function, new-onset thrombocytopenia, pulmonary edema, visual or cerebral disturbances or renal insufficiency (1).

PE can progress to severe PE, which includes liver dysfunction, edema, pain, low platelet count as well as vascular and cerebral disturbances. Less than 1% of women with PE proceed to the most severe form, named eclampsia, which is characterized by eclamptic seizures (2).

1.1.2. Epidemiology

Hypertensive disorders of pregnancy (HDP) complicate up to 10% of all pregnancies. They include gestational hypertension, chronic hypertension, chronic hypertension superimposed with PE and PE. The later one affects about 3% of all pregnancies, making up a substantial part of HDP (3).

PE/eclampsia is a major cause of maternal and fetal mortality and morbidity. The maternal death rate of eclampsia and preeclampsia is 0-1.8% in developed countries and as high as 14% in developing countries. Fetal mortality is estimated to be 13-30% (4).

Women with a previous history of PE are at 7 times higher risk of developing the condition in following pregnancies (5). Other risk factors include: age over 40 years, first pregnancy (primipara), maternal obesity, maternal diabetes (type 1 or type 2), previous hypertension, coagulation disorders, systemic diseases, like systemic lupus erythematosus (SLE), kidney diseases and multiple pregnancy (6).

1.1.3. Etiology

The etiology of PE remains unknown. One of the most accepted theories characterized PE as a multisystem disorder due to abnormal response of the maternal vasculature to placentation.

In normal pregnancies, structural modifications of the spiral arteries by invasion of the cytotrophoblasts (CTB) causes them to be highly dilated and thus to become less resistant. This allows them to be less sensitive to vasoconstrictive substances. The described physiological change plays a vital role for the supply of nutrients to the placenta and eventually the foetus (7).

In placentas from pregnancies complicated with PE, this remodelling process has failed and the remaining increased uterine arterial resistance is preserved or even increased. In addition, the preserved sensitivity to vasoconstrictive substances induces a condition of chronic placental ischemia and oxidative stress (8).

Fetal complications develop as sequel to placental ischemia whereas maternal complications are caused by oxidative stress triggering the release of certain substances into the maternal circulation. These substances include free radicals, oxidized lipids, cytokines, and serum soluble vascular endothelial growth factor 1 (9).

They are responsible for the vascular endothelial dysfunction seen in PE, including vascular hyperpermeability, thrombophilia and hypertension (8).

Another mechanism contributing to the development of PE is a disturbed trophoblast life cycle. Changes in apoptosis, meaning programmed cell death of the trophoblast, is thought to be one of the core factors for evoking an inflammatory response from the mother, as seen in PE. The normal trophoblast lifecycle, which is approximately 25 days long (10), includes differentiation and proliferation of mononucleated CTB with eventual fusion into multinucleated syncytiotrophoblasts, followed by the formation of syncytial knots. Those syncytial knots represent dying remnants of the trophoblast and they are finally shed from the surface of villi into the maternal circulation, where maternal pulmonary macrophages eliminate them. The described process is also known as trophoblast turnover (11).

In PE however, several studies revealed an imbalance between proapoptotic and antiapoptotic factors and therefore an increased apoptosis, which is believed to be crucial in the development of PE (11,12). In this context, aponecrosis, meaning incomplete apoptosis and eventual necrosis with formation of impaired syncytial knots, is another important parameter. Compared to

apoptosis with normal formation of syncytial knots, those produced from apoptosis are still capable of evoking an inflammatory response from the mother (13).

PE is a disorder with a high risk of progression to more severe conditions like eclampsia, which includes convulsions. The risk of developing cardiovascular disorders and chronic kidney disease due to metabolic stresses and vascular injury induced by PE is increased. In case of severe PE, the clinical findings despite hypertension and proteinuria also include signs of microangiopathy, systemic endothelial dysfunction and the HELLP syndrome (haemolysis, low platelet count and elevated liver function tests) (14).

Other symptoms include swelling, shortness of breath and visual disturbances. Preterm delivery, placental abruption, caesarean delivery and even stillbirth show an increased occurrence in pregnancies complicated with PE. The need for preterm delivery, as only known cure for PE, poses a risk for the neonatal wellbeing. Late preterm neonates appear to have a significantly higher mortality rate than term infants (15-19).

The decreased uteroplacental blood flow during pregnancy and the resulting ischemia increases the risk for the foetus to develop intrauterine growth retardation. Neonatal thrombocytopenia, increased risk for neutropenia, bronchopulmonary dysplasia and variable neurodevelopmental outcomes are further complications for the neonate (20).

1.2. Placenta

1.2.1. Development of placenta and its role in normal pregnancy

Six days after fertilization, the blastocyst attaches to the endometrium. The trophoblast, which is the outer layer of the blastocyst, proliferates and differentiates into the outer syncytiotrophoblast (STB) and the inner CTB to enable the implantation of the embryo. The CTB give rise to amnioblasts, which eventually form the amnion. The STB on the other hand, invade the endometrium and form lacunae, which become filled with maternal blood. Primitive intervillous spaces form by fusion of several lacunae. Primitive villi develop from CTB proliferation. The chorion is formed by extraembryonic mesoderm and the primitive villi. Chorionic villi, which are in contact with the maternal blood in the lacunae develop from the villous trophoblast (VTB). The chorionic plate is built by rapidly proliferating villi along the decidua basalis. Extravillous trophoblast (EVTB) that is formed by CTB in the tips of villi, penetrate the maternal vessels and

help to anchor the placenta. Besides, EVTB is further classified into interstitial and the endovascular trophoblast. The later is responsible for the remodeling of the spiral arteries shortly after implantation. This process is crucial in the development of the placenta. It ensures the high flow, low resistance uteroplacental vasculature in the normal placenta. The remodelling of spiral arteries by endovascular trophoblast has two peaks in time. The first one is around 8 to 10 weeks of gestation and involves the invasion into decidual segments of spiral arteries. At 16 to 18 weeks of gestation the second peak occurs with invasion into myometrial segments. This mechanism ensures gradual loss of spiral artery musculature and replacement with fibrinoid material to enable a successful pregnancy (21).

Umbilical vessels formed by the mesoderm in the core of the villi, the allantois and remnants of the yolk sac build up the umbilical cord. In the end there is a fusion of amnion and chorion to form the amniochorionic membrane, which eventually fuses with the decidua capsularis and the decidua parietalis as the embryo grows (22,24).

The placenta is fully functional by the end of the third month of gestation. Its role is to provide nutrients and oxygen for the foetus as well as to eliminate waste products. Furthermore it has an immunologic role, as IgG antibodies may pass to provide passive immunity for the foetus. It also serves as endocrine organ, secreting human chorionic gonadotropin to ensure that the pregnancy may take place as well as a set of different other hormones. Since the placenta carries much more blood than actually needed by the foetus, it also has a compensatory function in case of diminished blood flow (25).

When fully developed, on gross examination, the placenta is composed of the placental disk, extraplacental membranes and the umbilical cord (Figure 1).

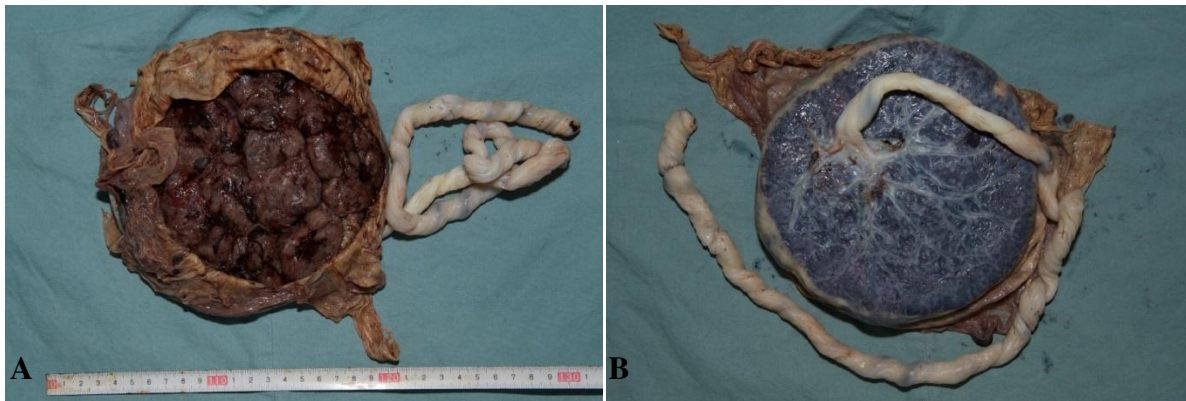

Figure 1. Gross image of term placenta. A. Maternal side of the term placenta. B. Foetal side of the placenta with the umbilical cord. (*Images taken from the personal archive of the mentor with mentor's permission*).

Cotyledons and the basal plate can be found on the maternal side of the placental disk, whereas foetal side, which is covered with the amnion, is called chorionic plate. The latter is the place for umbilical cord insertion. Extraplacental membranes are usually attached to placental disk margins (23).

Microscopically, the basal plate includes decidua basalis, EVTB and maternal blood vessels. The chorionic plate is composed of subchorionic fibrin, umbilical blood vessel branches, chorion and amnion. In between basal and chorionic plate, stem, intermediate and terminal villi as well as intervillous spaces are seen, building the placental parenchyma. Septa, made out of EVTB are subdividing the basal plate into cotyledons. The membranes consist of amniotic epithelium, connective tissue and chorion, which is composed of EVTB and involuted villi, attached decidua parietalis and capsularis as well as maternal blood vessels and yolk sac remnants (Figure 2).

Finally, the umbilical cord is made of two arteries, one vein, Wharton's jelly and surface epithelium (23).

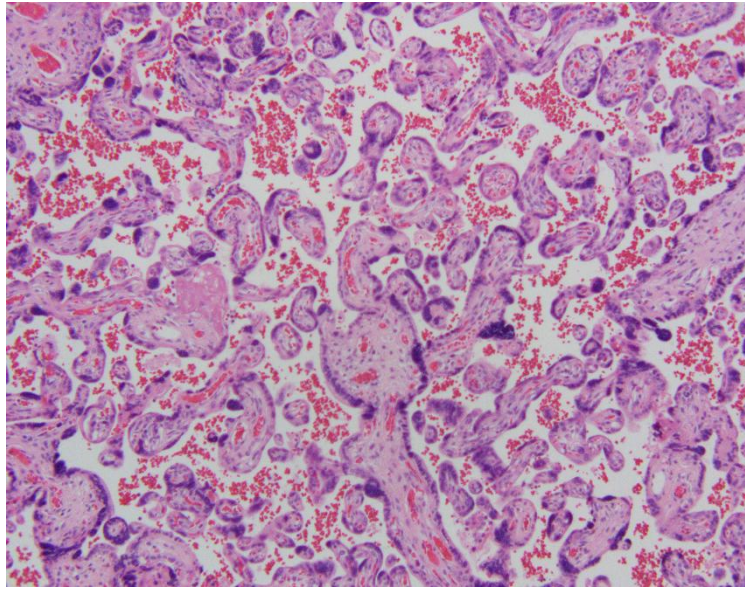


Figure 2. Histology of term placenta with placental villi, syncytial knots and intervillous spaces with maternal blood (Hematoxylin&Eosin, magnification 100x, Olympus BX41 microscope; *image taken by candidate at the Pathology Department*).

1.2.2. Placenta in preeclampsia

Abnormalities in the placenta are believed to be the major components in the PE development. Diminished blood flow through the placenta due to defects in the maternal vasculature to adapt to normal pregnancy is the core pathological feature of PE. At about 10 weeks of gestation, the intervillous space becomes vascularized and CTB undergoes changes to respond to the previous low oxygen environment. The differentiation into the invasive trophoblast phenotypes allows the spiral arteries to be modified into flaccid, funnel shaped large diameter vessels, which are insensitive to humoral or neural vasoconstrictive substances. In PE however, these vessels remain contractile and cause a large amount of oxidative stress. Acute atherosclerosis, the occlusion of vessels by fibrinoid surrounded by foam cells, is another change seen microscopically in the unmodified spiral arteries, contributing to the state of underperfusion (Figure 3) (26,27).

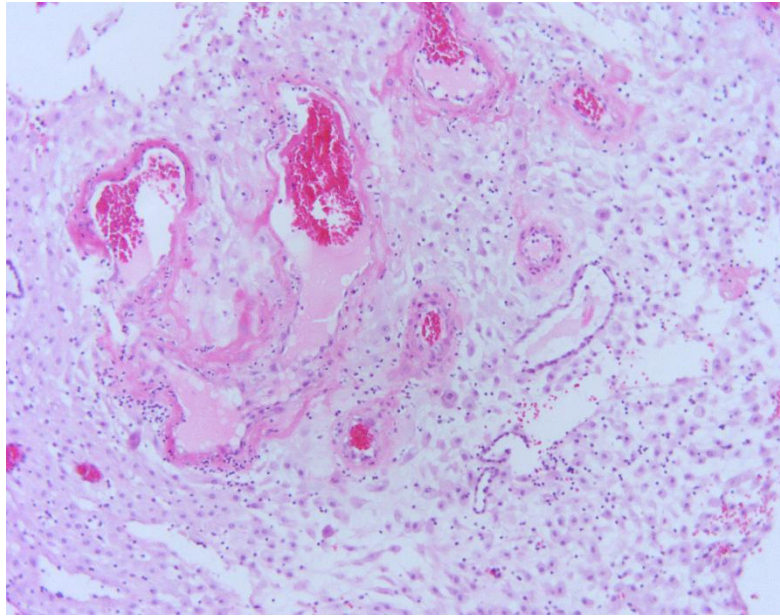


Figure 3. Acute atherosclerosis of blood vessels in the decidua basalis from placenta with preeclampsia (Hematoxylin&Eosin, magnification 100x, Olympus BX41 microscope; *image taken from the personal archive of the mentor with the mentor's permission*)

Histologically, numerous large syncytial knots, small sclerotic villi and accelerated villous branching are seen due to hypoxia and resulting reactive oxygen species. Especially in severe PE, also gross morphological changes like infarctions and abnormal placental shape might be noted. Despite some characteristic changes in placentas of pregnancies complicated with PE, the exact linkage between abnormal trophoblast invasion and the maternal disease remains unknown (26,27).

1.2.3. Multinucleated Giant Cells

Multinucleated Giant Cells (MGC) constitute a subgroup of EVTB near the site of implantation, which have lost their invasive properties (28,29). Their trophoblastic origin was confirmed by immunohistochemical labelling and observation with a light microscope by Pijnenborg *et al.* as well as Wells and Bulmer (30,31).

MGCs appear to be larger than the surrounding trophoblast and contain two or more nuclei, which is probably attributed to cell fusion (Figure 4).

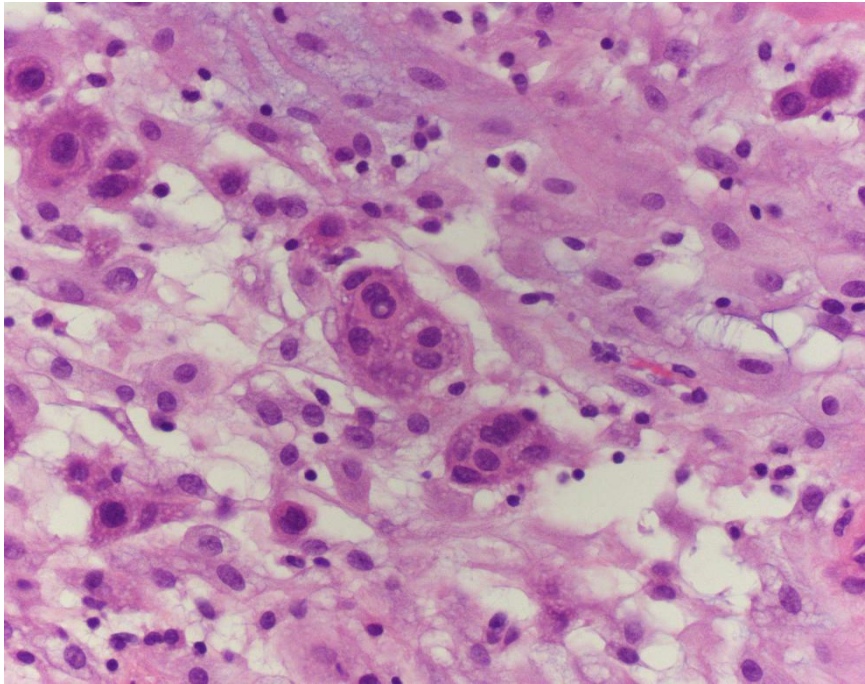


Figure 4. Multinucleated giant cells (MGC) in the decidua basalis from placenta with preeclampsia (Hematoxylin&Eosin, magnification 400x, Olympus BX41 microscope; *image taken by candidate at the Pathology Department*).

MGC mostly appear in mid pregnancy but they can also be seen later (28).

Usually MGCs can be found as a normal component of the implantation site but they appear to be increased in placentas of pregnancies complicated by PE and decreased in placenta creta (32-35). Hence, they are not merely a characteristic of maternal vascular underperfusion in PE but also linked to other types of pregnancy related disorders associated with placental hypoxia. Their significance lies in being very specific and therefore MGC might be used to retrospectively clarify perinatal mortality and morbidity, meaning when seen in excess number in placentas from full term pregnancies, they could be indicative of pre-existing hypoxia (29).

2. Hypothesis

Placentas from pregnancies complicated with PE show an increased number of MGC in the decidua basalis compared to placentas from normal pregnancies.

3. Material and Methods

The study was conducted upon approval of the local Ethics Committee and after all participants provided informed consent.

Overall this study included 30 placentas.

The studied group was represented by 15 placentas from singleton term pregnancies complicated with PE, which was diagnosed based on following criteria: systolic blood pressure >140 mmHg and diastolic blood pressure >90 mmHg; proteinuria >300 mg/L per 24 hours (1).

The remaining 15 placentas were collected from singleton term pregnancies without clinical signs of PE and posed the control group.

General exclusion criteria for both groups were: diagnosis of HELLP syndrome (platelets <100x10⁹/L, AST and ALT >70 U/L, and LDH >600 U/L) (14), renal diseases, vascular diseases like hypertension, or any other maternal condition existing prior to pregnancy.

Within 20 minutes after delivery, placentas were collected from the delivery room of the University Hospital of Split, fixed in 4% buffered formalin and sent to the Pathology Department for further evaluation.

Placental samples, all containing decidua basalis, were taken from the macroscopically normal part of the placental disk, near to the umbilical cord insertion site. Sections of 4- μ m thickness were cut from previously paraffin embedded placental samples. Afterward they were mounted on silanized slides and dried at 37°C. After hematoxylin and eosin staining, histologic examination was performed using an Olympus BX 41 microscope (Olympus, Tokyo, Japan).

Immunohistochemistry was done after the paraffin slices were mounted on super frost slides (Thermoscientific, Darmstadt, Germany) and further processed in the automatic stainer (Ventana Bench Mark Ultra autostainer, Tucson, USA). CK7 antibody (rabbit monoclonal antibody, clone SP52, Ventana, Tucson, USA) was used to distinguish EVTB from decidual cells (DC) in the decidua basalis with Ultra view Universal DAB detection kit (Ventana, Tucson, USA). DC were CK7 negative whereas EVTB cells were CK7 positive.

Since MGC are considered to be EVTB, they were also CK7 positive (Figure 5).

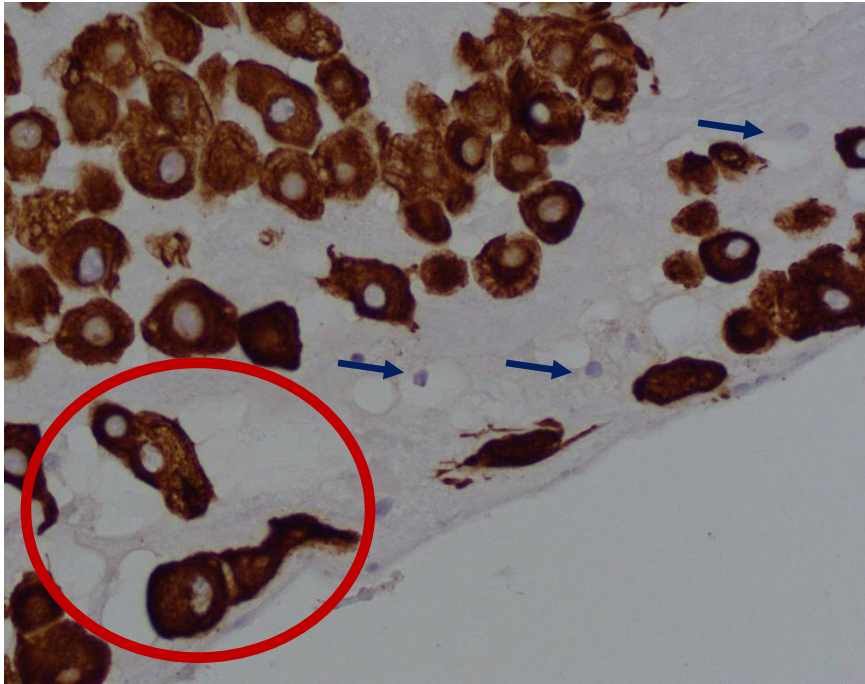


Figure 5. Immunohistochemical staining with CK7, brown membranous and cytoplasmic staining of extravillous trophoblast (EVTB) and multinucleated giant cells (MGC, marked with red circle). Decidual cells (DC) are negative (blue arrows). (Magnification 400x, Olympus BX41 microscope; *image taken by candidate at the Pathology Department*).

For each sample, the number of MGC, EVTB and DC in the decidua basalis was determined by the use of Olympus BX 41 microscope and Olympus cell D1 image analyser.

Statistical analysis was done by the MedCalc software (MedCalc softare, Mariakerke, Belgium) using the chi-square-test, t-test for independent samples and Mann-Whitney test, depending on the result distribution. Statistical significance was set at $p < 0.05$. Results were expressed as mean with standard deviation or median with minimum and maximum value, depending on the result distribution determined by Kolmogorov-Smirnov test.

4. Results

Fifteen placentas from PE were included in the studied group and the same number of placentas from normal pregnancies in the control group. There was no statistically significant difference regarding maternal age ($p=0.390$; $t=0.872$; $DF=27$), gestational age ($p=0.644$; $t=0.468$; $DF=28$), birth weight ($p=0.657$; $t=0.449$; $DF=28$) and neonatal gender ($p=0.695$; $\chi^2 = 0.153$; $DF=1$) between investigated groups (Table 1).

There was no statistically significant difference in the number of DC and EVTB between both groups ($p=0.112$; $t=1.643$; $DF=28$); ($p=0.115$; $Z=3.846$) as well as in MGC/EVTB ratio ($p=0.113$; $Z=1.587$) (Table 2).

The number of MGC was significantly higher in the PE group compared to control group ($p<0.001$; $Z=3.765$). Likewise MGC/DC ratio was significantly higher in the PE group compared to control ($p<0.001$; $Z=1.587$) (Table 2).

Table 1. Age of participants, gestational age at birth as well as birth weight and gender of the neonate

	PE group (N=15)	Control group (N=15)	p
Age of the mother (years)	34 ± 7.14	31 ± 7.86	0.390*
Gestational age (weeks)	38 ± 1.36	38 ± 0.94	0.644*
Birth weight (grams)	3304±971.88	3429±462.34	0.657*
Gender (male sex)	11	10	0.695†

*Student t-test

†chi-square tests

The values are presented as arithmetic mean ± standard deviation or general number.

Table 2. The number of multinucleated giant cells (MGC), decidual cells (DC) and extravillous trophoblast (EVTB) as well as the ratio between MGC and DC and MGC and EVTB

	PE group (N=15)	Control group (N=15)	p
MGC	3 (0-15)	0 (0-4)	<0.001*
DC	205.46 ± 227.64	325.46± 167.95	0.112†
EVTB	880 (153-2290)	420 (61-2438)	0.115*
MGC/DC	0.03 (0-14)	0 (0-0.01)	<0.001*
MGC/EVTB	0 (0-0.04)	0 (0-0.02)	0.113*

*Mann-Whitney U test

† Student t-test

The values are presented as median with minimum and maximum values or as arithmetic mean ± standard deviation.

5. Discussion

PE is a very heterogeneous condition with many influencing factors and a still unknown etiology. Many of those factors are being investigated to show their interference with normal placental development. This study aimed to show the number of placental MGC in the decidua basalis from PE placentas and to compare the results with MGC number in placentas from normal pregnancies.

Results of this study have shown that there is a significant difference in the number of MGC in PE placentas compared to the control group, MGC being higher in the studied group.

To the best of my knowledge, it is the first study to investigate the number of MGC in the decidua basalis from PE pregnancies solely and to compare them with the results from normal placentas.

MGC can also be found in normal pregnancies, especially in mid pregnancy (28). Their function is largely unknown. It is thought that they are created from EVTB by cell fusion (29-31).

A significant increase of MGC in the studied group suggests that MGC formation is being triggered by a hypoxic injury pattern. There are many different placental responses to hypoxia. Not only the duration of hypoxia plays a role, but also whether it is a preuterine, uterine or postuterine pattern of hypoxia as Stanek pointed out (36). He described that MGC in the decidua basalis, as well as excessive EVTB numbers are less commonly seen in preuterine pattern of chronic placental hypoxia (e.g. maternal anemia). Also, he emphasized that this pattern has a better prognosis than other types of placental hypoxia and concluded that it is most probably due to hypoxic preconditioning. This implies that the specific hypoxic injury pattern plays a major role in the production of MGC. Hence, they are not increased in all hypoxic patterns, which makes them relatively specific for certain types of hypoxia, as for chronic uterine hypoxic pattern seen in PE (36). Still it is not clear, if there are other factors being involved, which might trigger the development of MGC in conditions like PE.

Cowden Dahl et al. discuss hypoxia-induced changes on molecular level that might be involved in MGC production (37). Especially hypoxia-inducible factors (HIFs) seem to be included in giant cell formation and differentiation (37). This means, that although hypoxia might be the main mechanism to trigger MGC production, many different pathways on molecular level seem to be of importance for the formation of MGC.

Stanek et al. reported a significantly increased number of MGC, not only in PE, but also in other high-risk pregnancies associated with this chronic uterine hypoxic injury pattern. These findings suggested the high value of MGC in explaining perinatal mortality and morbidity (29), because it might function as indicator for hypoxia.

The number of MGC was likewise found to be significantly higher in placenta previas by Biswas et al. (38), which might also be explained by hypoxia due to bleeding, inadequate attachment or changes in spiral arterioles, and therefore placental malperfusion. This would support the theory that placental hypoxia is the main trigger for MGC increase. Van Beekhuizen et al. on the other hand, reported a decreased number of MGC in retained placentas (placenta adhesiva) and concluded that the missing fusion of trophoblasts and hence the decreased number of MGC might be a factor involved in the pathology of placenta adhesiva (39). This finding implies, that MGC play a role in the regulation of placental adhesion and are needed in order to prevent the event of retained placenta whereas their abundance is a sign of placental hypoxia.

As Stanek et al. pointed out, MGC measurement could be used retrospectively to explain adverse pregnancy outcomes (29). Since the number of MGCs is also elevated in other pregnancy related complications than PE, it is not specific for this condition (38). Also it is not clear whether MGCs contribute to the development of PE or are they just an indicator of placental hypoxia.

Moreover this study showed a significant increase in the MGC/DC ratio in the studied group compared to control, but there was no statistically significant difference in the number of DC and EVTB between both groups, meaning that the number of DC and EVTB did not have any influence on the increased number of MGC.

This study was limited by a relatively small sample size (N=15 in each group). Also, it was difficult to distinguish between EVTB and DC on the basis of standard hemalaun and eosin (H&E) slides, so CK7 antibody staining was introduced to avoid possible errors.

6. Conclusion

Concluding, this study suggests that there is an increased number of MGC in the decidua basalis in placentas from pregnancies with PE compare to placentas from normal pregnancies. This finding might be a useful marker in the workup of pregnancies that have been complicated by PE. The exact etiology of the formation of MGCs and possible contribution to the course of PE is yet to be determined.

7. References

1. American College of Obstetricians and Gynecologists, Task Force on Hypertension in Pregnancy. Establishing the Diagnosis of Preeclampsia and Eclampsia. In: American College of Obstetricians and Gynecologists. Hypertension in Pregnancy. Washington, USA: American College of Obstetricians and Gynecologists; 2013. p. 17-20.
2. Reece EA. Pre-Eclampsia-Eclampsia Syndrome. In: Reece EA, Barbieri RL, editors. Obstetrics and Gynecology: The Essentials of Clinical Care. Stuttgart, New York: Thieme; 2010. p. 149-57.
3. Hutcheon JA, Lisonkova S, Joseph KS. Epidemiology of pre-eclampsia and the other hypertensive disorders of pregnancy. *Best Pract Res Clin Obstet Gynaecol*. 2011;25(4):391-403.
4. Medscape [Internet]. USA: Ross MG, Ramus RM, Pierce JG; 2016. Eclampsia Outcome; 2016 Jul 06 [cited 2017 Jun 25]. Available from: <http://emedicine.medscape.com/article/253960-overview#a20>
5. Duckitt K, Harrington D. Risk factors for pre-eclampsia at antenatal booking: Systematic review of controlled studies. *BMJ*. 2005;330(7491):565.
6. Mayo Clinic [Internet]. USA: Mayo Clinic Staff; 2017, Preeclampsia Symptoms and causes; 2017 Apr 21 [cited 2017 May 16]. Available from: <http://www.mayoclinic.org/diseases-conditions/preeclampsia/basics/risk-factors/con-20031644>
7. Fisher SJ, McMaster M, Roberts JM. The Placenta in Normal Pregnancy and Preeclampsia. In: Taylor RN, Roberts JM, Cunningham FG, editors. Chesley's Hypertensive Disorders in Pregnancy. 4th ed. Amsterdam, the Netherlands: Academic Press Elsevier; 2009. p. 81-112.
8. Uzan J, Carbonnel M, Piconne O, et al. Pre-eclampsia: pathophysiology, diagnosis, and management. *Vasc Health Risk Manag*. 2011;7:467-74.
9. Roberts JM. Endothelial dysfunction in preeclampsia. *Semin Reprod Endocrinol*. 1998;16:5-15.
10. Roje D, Tomas SZ, Prusac IK, et al. Trophoblast apoptosis in human term placentas from pregnancies complicated with idiopathic intrauterine growth retardation. *J Matern Fetal Neonatal Med*. 2011;24(5):745-51.
11. Tomas SZ, Prusac IK, Roje D, et al. Trophoblast Apoptosis in Placentas from Pregnancies Complicated by Preeclampsia. *Gynecol Obstet Invest*. 2011;71(4):250-5.
12. Hupperth B, Kingdom JC. Apoptosis in the trophoblast—role of apoptosis in placental morphogenesis. *J Soc Gynecol Investig*. 2004;11(6):353-62.

13. Formigli L, Papucci L, Tani A, et al. Aponecrosis: morphological and biochemical exploration of a syncretic process of cell death sharing apoptosis and necrosis. *J Cell Physiol.* 2000;182(1):41-49.
14. Al-Jameil N, Aziz Khan F, Fareed Khan M, et al. A brief overview of preeclampsia. *J Clin Med Res.* 2014;6(1):1-7.
15. Dudell GG, Jain L. Hypoxic respiratory failure in the late preterm infant. *Clin Perinatol.* 2006;33(4):803-30.
16. Jain L, Dudell GG. Respiratory transition in infants delivered by cesarean section. *Semin Perinatol.* 2006;30(5):296-304.
17. Martin JA, Hamilton BE, Sutton PD, et al. Births: final data for 2005. *Natl Vital Stat Rep.* 2007;56(6):1-103.
18. Raju TN, Higgins RD, Stark AR, et al. Optimizing care and outcome for late-preterm (near-term) infants: a summary of the workshop sponsored by the National Institute of Child Health and Human Development. *Pediatrics.* 2006;118(3):1207-14.
19. Wang ML, Dorer DJ, Fleming MP, et al. Clinical outcomes of near-term infants. *Pediatrics.* 2004;114(2):372-6.
20. Backes CH, Markham K, Moorehead P, et al. Maternal preeclampsia and neonatal outcomes. *J Pregnancy.* 2011;2011:214365.
21. Lyall F, Bulmer JN, Duffie L, et al. Human Trophoblast Invasion and Spiral Artery Transformation. *Am J Pathol.* 2001;158(5):1713-21
22. Joshi VV. Development of the Placenta. In: Joshi VV, editors. *Handbook of Placental Pathology.* New York, Tokyo: Igaku-Shoin; 1994. p. 2.
23. Joshi VV. Structure of the Placenta. In: Joshi VV, editors. *Handbook of Placental Pathology.* New York, Tokyo: IGAKU-SHOIN; 1994. p. 2-7.
24. Wang Y, Zhao S. *Vascular Biology of the Placenta.* San Rafael (CA): Morgan & Claypool Life Sciences; 2010. Chapter 2, Placental Blood Circulation. Available from: <https://www.ncbi.nlm.nih.gov/books/NBK53254/>
25. Gude NM, Roberts CT, Kalionis B, et al. Growth and function of the normal human placenta. *Thromb Res.* 2004;114(5-6):397-407.
26. Roberts JM, Escudero C. The placenta in preeclampsia. *Hypertens. Pregnancy.* 2012;2(2):72-83.
27. Myatt L. Role of placenta in preeclampsia. *Endocrine.* 2002;19(1):103-11.

28. Al-Lamki RS, Skepper JN, Burton GJ. Are human placental bed giant cells merely aggregates of small mononuclear trophoblast cells? An ultrastructural and immunocytochemical study. *Hum Reprod.* 1999;14(2):496-504.
29. Stanek J, Biesiada J. Sensitivity and specificity of finding of multinucleate trophoblastic giant cells in deciduas in placentas from high-risk pregnancies. *Hum Pathol.* 2012;43(2):261-8.
30. Pijnenborg R, Dixon G, Robertson WB, et al. The pattern of interstitial trophoblast invasion of the myometrium in early human pregnancy. *Placenta.* 1981;2(4):303-16.
31. Wells M, Bulmer JW. The human placental bed: histology, immunohistochemistry and pathology. *Histopathology* 1988;13(5):483-98.
32. Redline JD, Patterson P. Pre-eclampsia is associated with an excess of proliferative immature intermediate trophoblast. *Hum Pathol.* 1995;26:594-600.
33. Kim KR, Jun SY, Kim JY, et al. Implantation site intermediate trophoblasts in placenta cretas. *Modern Pathol.* 2004;17:1483-90.
34. Khong TY, Robertson WB. Placenta creta and placenta previa creta. *Placenta* 1987;8:399-409.
35. Stanek J, Drummond Z. Occult placenta accreta: the missing link in the diagnosis of abnormal placentation. *Pediatr Dev Pathol.* 2007;10:266-72.
36. Stanek J. Hypoxic patterns of placental injury: a review. *Arch Pathol Lab Med.* 2013;137(5):706-20.
37. Cowden Dahl KD, Fryer BH, Mack FA, et al. Hypoxia-inducible factors 1alpha and 2alpha regulate trophoblast differentiation. *Mol Cell Biol.* 2005;25(23):10479-91.
38. Biswas R, Sawhney H, Dass R, et al. Histopathological study of placental bed biopsy in placenta previa. *Acta Obstet Gynecol Scand.* 1999;78(3):173-9.
39. Van Beekhuizen HJ, Joosten I, de Groot AN, et al. The number of multinucleated trophoblastic giant cells in the basal deciduas is decreased in retained placenta. *J Clin Pathol.* 2009;62(9):794-7.
40. Litton C, Stone J, Eddleman K, et al. Noninvasive prenatal diagnosis: past, present, and future. *Mt Sinai J Med.* 2009;76(6):521-8.

8. Summary (English)

MULTINUCLEATED GIANT EXTRAVILLOUS TROPHOBLAST CELLS IN THE DECIDUA OF PLACENTAS COMPLICATED WITH PREECLAMPSIA

Objectives: To compare the number of Multinucleated Giant Cells (MGC) in the decidua basalis of placentas complicated with preeclampsia (PE) and placentas from normal pregnancies.

Subject and Method: Fifteen placental samples from pregnancies complicated with PE and the same number of placental samples from normal pregnancies were taken. For each placental sample the number of MGC, extravillous trophoblast (EVTB) and decidual cells (DC) was counted in the decidua basalis. Immunohistochemistry with primary antibody CK7 was used to distinguish EVTB and MGC from DC. The MGC/DC ratio and MGC/EVTB ratio was also determined.

Results: MGC number was significantly higher in placentas complicated with PE. Likewise MGC/DC ratio was found to be significantly higher in the studied group. There was no statistically significant difference in EVTB and DC number as well as MGC/EVTB ratio.

Conclusion: Increased MGC number in the decidua basalis could be a morphological sign of PE and hypoxic conditions in the placenta.

9. Summary (Croatian)

MULTINUKLEARNE ORIJAŠKE STANICE EKSTRAVILOZNOG TROFOBLASTA U DECIDUI POSTELJICA IZ TRUDNOĆA S PREEKLAMPSIJOM

Ciljevi: Usporediti broj multinuklearnih orijaških stanica (MOS) u decidui basalis posteljica iz trudnoća s preeklampsijom (PE) i posteljica iz normalnih trudnoća.

Materijali i metode: U ispitivanu skupinu je uključeno petnaest uzoraka posteljica iz trudnoća s PE. Isti broj uzoraka posteljica iz normalnih trudnoća je činio kontrolnu skupinu. U svakom uzorku je određen broj MOSa, stanica ekstraviloznog trofoblasta (EVTB) i decidualnih stanica (DS) u decidui basalis. Za razlikovanje stanica EVTB i MOSa od DSa korišteno je imunohistokemijsko bojanje s primarnim protutijelom CK7. Određen je i odnos MOS/DS i MOS/EVTB.

Rezultati: Broj MOS je bio značajno veći u ispitivanoj skupini posteljica u odnosu na kontrolnu skupinu. Odnos MOS/DS je također bio značajno veći u ispitivanoj skupini posteljica. Nije bilo statistički značajne razlike u broju stanica EVTB, DS kao i u odnosu MOS/EVTB između dvije skupine.

Zaključak: Povišeni broj MOSa u decidui basalis jedan je od morfoloških znakova koji mogu ukazivati da se radi o posteljici trudnoće s PE, to jest o postojanju hipoksičnih uvjeta.

10. Curriculum Vitae

Name: Anna Berkovic

Date & Place of Birth: 05.08.1992, Göttingen, Germany

Nationality: German

Current Adress: Bandelstraße 11, 45136 Essen, Germany

Parents: Dr. Katharina Berkovic, Prof. Dr. Dinko Berkovic

Email: civokreb@hotmail.de

Education

September 2002-July 2004 St. Bernhard Gymnasium Schiefbahn

September 2004-July 2011 Burggymnasium Essen

July 2011 Diploma from German secondary school (A level), qualifying for university admission or matriculation

October 2011-July 2017 Medical Studies in English, Medical Faculty, 21000 Split

September 2014 Working experience, Internal Medicine, Krankenhaus Neuwerk, Mönchengladbach, Germany

September 2015 Working experience, Internal Medicine, Kranknehaus Neuwerk, Mönchengladbach, Germany

July 2017 anticipated Diploma Thesis under supervision of Sandra Zekic Tomas, MD, PhD

Other

Languages: Croatian (C1), English (C2)

Publication:

Kosovic I, Prusac IK, Berkovic A, Marusic J, Mimica M, Tomas SZ. Expression of EGF, EGFR, and proliferation in placentas from pregnancies complicated with preeclampsia. *Hypertens Pregnancy*. 2017 Feb;36(1):16-20.