

Expression pattern of Snail in the kidneys of streptozotocin-induced diabetic rats

Ksouri, Samy Mehdi

Master's thesis / Diplomski rad

2017

Degree Grantor / Ustanova koja je dodijelila akademski / stručni stupanj: **University of Split, School of Medicine / Sveučilište u Splitu, Medicinski fakultet**

Permanent link / Trajna poveznica: <https://um.nsk.hr/um:nbn:hr:171:636532>

Rights / Prava: [In copyright](#)/[Zaštićeno autorskim pravom.](#)

Download date / Datum preuzimanja: **2024-11-25**



Repository / Repozitorij:

[MEFST Repository](#)



**UNIVERSITY OF SPLIT
SCHOOL OF MEDICINE**

Samy Ksouri

**EXPRESSION PATTERN OF SNAIL IN THE KIDNEYS OF STREPTOZOTOCIN-
INDUCED DIABETIC RATS**

Diploma thesis

Academic year:

2016/2017

Mentor:

Katarina Vukojević, MD, PhD

Split, September 2017.

**UNIVERSITY OF SPLIT
SCHOOL OF MEDICINE**

Samy Ksouri

**EXPRESSION PATTERN OF SNAIL IN THE KIDNEYS OF STREPTOZOTOCIN-
INDUCED DIABETIC RATS**

Diploma thesis

Academic year:

2016/2017

Mentor:

Katarina Vukojević, MD, PhD

Split, September 2017.

TABLE OF CONTENTS:

| | |
|--|----|
| 1. INTRODUCTION..... | 1 |
| 1.1. Diabetic nephropathy..... | 2 |
| 1.1.1 Definition..... | 2 |
| 1.1.2. Etiology..... | 2 |
| 1.1.2.1. Pathophysiology of DN as a glomerular disease..... | 2 |
| 1.1.2.2. Molecular basis of glomerular injury..... | 3 |
| 1.1.2.3. Other pathological changes present in the glomerulus..... | 3 |
| 1.1.2.4. DN as a tubulointerstitial disease..... | 4 |
| 1.1.2.5. Molecular basis of tubulointerstitial injury..... | 4 |
| 1.1.2.6. Pathological changes present in the tubulointerstitium..... | 4 |
| 1.2 Epithelial-mesenchymal transition..... | 5 |
| 1.2.1. Definition..... | 5 |
| 1.2.2. Molecular basis of EMT..... | 5 |
| 1.2.3. Importance of Snail in EMT..... | 6 |
| 1.2.4. EMT and Snail in the literature..... | 7 |
| 2. OBJECTIVES..... | 9 |
| 3. MATERIALS AND METHODS..... | 9 |
| 3.1. Ethical background..... | 11 |
| 3.2. Experimental Animals..... | 11 |
| 3.3. Induction and validation of diabetes..... | 11 |
| 3.4. Tissue collection and immunohistochemistry..... | 12 |
| 3.5. Statistics..... | 13 |
| 4. RESULTS..... | 14 |
| 5. DISCUSSION..... | 24 |
| 6. CONCLUSIONS..... | 27 |
| 7. REFERENCES..... | 29 |
| 8. SUMMARY..... | 32 |
| 9. CROATIAN SUMMARY..... | 34 |
| 10. CURRICULUM VITAE..... | 36 |

I hereby would like to convey my sincere gratitude and indebtedness to my mentor Katarina Vukojević, MD, PhD, who patiently helped me throughout the writing of my diploma thesis and introduced me so kindly to laboratory work.

The animal model and all the chemical and materials used in the study were financed by the School of Medicine, University of Split Institutional grant for excellence 2015. and 2016.

1. INTRODUCTION

Diabetes mellitus (DM) is a metabolic disease of multiple etiology whose long-term consequences include damage and possible failure of diverse body tissues and organs. At the root of this disorder is a defect in insulin secretion from the pancreas, a dysfunction in insulin's action, or both. This process leads to long-standing hyperglycemia which in turn disrupts the normal protein, carbohydrates and fat metabolism. Although the symptoms of DM can be mild or even entirely absent, the chronically increased blood sugar level continues its deleterious action insidiously. On top of being at an increased risk for cerebrovascular, cardiovascular and peripheral vascular diseases, diabetic patients can develop during the course of their illness several complications ranging from diabetic foot to diabetic retinopathy and nephropathy (1). It is the latter that will constitute the main focus of this paper.

1.1. Diabetic nephropathy

1.1.1 Definition

Diabetic nephropathy (DN) is defined as pathological proteinuria in the presence of type I or type II DM. In combination with hypertensive nephropathy they are the most common causes of end-stage renal disease (ESRD) in both developed and under-developed nations (2). DN is a common complication of type I and type II DM — in fact one of the most common chronic medical conditions in the world — with 20-30% of diabetic patients developing microalbuminuria after 15 years with the disease (2). When the albumin secretion reaches 300 mg per day it is called macroalbuminuria and the patients are said to have overt nephropathy. The pathological changes from this progression lead to renal dysfunction and chronic kidney disease (CKD) terminating in eventual kidney failure.

1.1.2. Etiology

1.1.2.1. Pathophysiology of DN as a glomerular disease

Being charged with the initial and primordial role of filtering the blood as it arrives in the

renal corpuscles, the glomeruli are the first to react to the long-standing hyperglycemia. Through hemodynamic changes, hyperglycemia causes glomerular hyperperfusion and hyperfiltration which, in addition to the shear stress from the increased flow and hydrostatic pressure, leads to albumin leakage from glomerular capillaries (3). On top of those hemodynamic modifications, hyperglycemia causes glomerular injury directly through activation of protein kinase C, increased production of advanced glycosylation end products, and diacylglycerol synthesis (3). The combination of those two processes results in the upregulation of transforming growth factor- β 1 (TGF- β 1) production by mesangial cells.

1.1.2.2. Molecular basis of glomerular injury

TGF- β 1 acts at the glomerular level by increasing extracellular matrix (ECM) deposition of several proteins including collagen types I, IV, V, VI, fibronectin and laminin. This has for effect to induce mesangial expansion and glomerular basement membrane thickening (3). It is worth noting that low enzymatic degradation of ECM also plays a role in that excessive accumulation.

Other growth factors play important roles in promoting glomerular structural changes in diabetic sclerosis. Sometimes they do so by upregulating TGF- β 1 gene expression which is what platelet-derived growth factor (PDGF) does, other times they do so through an alternative pathway and this is what was found for connective tissue growth factor (CTGF). CTGF induces transient actin cytoskeleton disassembly in mesangial cells, high production of fibronectin, collagen types I and IV, and mesangial cell hypertrophy (3).

1.1.2.3. Other pathological changes present in the glomerulus

On top of the glomerular basement membrane thickening and the mesangial expansion, other glomerular alterations are present in DN like podocyte foot processes shortening, thinning and detachment (4). The fenestrated area of endothelial cells was also found to be reduced, the glycocalyx, which plays an important role in preventing glomerular protein leakage, is weakened,

and the communication between glomerular endothelial cells and adjacent glomerular cells is distorted (4).

1.1.2.4. DN as a tubulointerstitial disease

Although being defined mainly as a glomerular disease, DN affects much more than just the filtration part of the nephron. The tubules and the interstitium surrounding them also are subject to the pathological influence of diabetes.

1.1.2.5. Molecular basis of tubulointerstitial injury

After long exposure to increased levels of glucose, angiotensin II, pro-inflammatory cytokines like TGF- β 1 and extracellular matrix proteins are produced by tubular cells. The presence of angiotensin II, on top of its obvious hemodynamic effects, leads to an increased expression of TGF- β 1 in proximal tubular and interstitial cells (5). This consequently amplifies the fibrosis in the renal tubulointerstitium.

On top of those direct effects, glucose and other advanced glycation end products as well as proteins coming through the glomerulus affect the renal tubule and more specifically its proximal segment. All of those factors promote TGF- β 1 expression and fibrosis.

It has become clear that tubulointerstitial pathology is not just the consequence of glomerular injury but that instead the tubules represent a primary target for several pathophysiological influences. DN should therefore be thought as a disorder affecting the entire nephron.

1.1.2.6. Pathological changes present in the tubulointerstitium

As with most glomerular diseases, in diabetic nephropathy the extent of the tubular interstitial injury correlates with the long term renal function. Pathological changes that are

associated with diabetic nephropathy include thickening of the tubular basement membrane (TBM), tubular atrophy, interstitial fibrosis, and arteriosclerosis (5). It has been established that interstitial expansion, in particular, correlates closely with the degree of renal dysfunction, protein loss (6, 7) and mesangial enlargement in type I (8) and type II diabetes (9).

1.2 Epithelial-mesenchymal transition

1.2.1. Definition

It has been suggested that the interstitial fibroblasts that contribute to the interstitial expansion and fibrosis that occurs in renal disease are, in part, derived from epithelial–mesenchymal transition (EMT) as opposed to a pool of mesenchymal cells. EMT involves the transformation of epithelial cells to mesenchymal cells. It is characterized by the loss of epithelial cell polarity which is achieved through fading of differentiated junctions, cytoskeleton rearrangement and organelles redistribution (10). Loss of E-cadherin expression represents one of the most important hallmark of EMT (12). This change is not uniform: it can be reversed through a mesenchyme-to-epithelium transition (MET) as it is the case in normal renal development, it can be permanent as in tumors, or alternatively epithelial cells can exhibit fibroblast like qualities without displaying significant scattering. Under physiological conditions, EMT takes place during wound healing at the edge of injury. EMT also plays a very important role in the invasiveness potential of many metastatic cancers (12).

1.2.2. Molecular basis of EMT

The importance of the GTPase switch protein Ras that transduces signals from many different tyrosine kinase surface-receptor in EMT is well documented. Literature also emphasize that several other pathways downstream of Ras are needed for a complete EMT. Mitogen-activated protein kinase (MAPK) as well as phosphoinositide 3-kinase (PI3K) activation are two important examples of the complex molecular interactions needed in the process of EMT.

TGF β signaling has also been shown to be an important inducer of EMT in concordance with the Ras pathway. Although TGF- β main function classically lies in growth arrest and apoptosis induction, high levels of the cytokine are found concomitantly with a significant increase in mutated H-Ras as well as a strong accumulation of Smad2 during the spindle carcinoma stage in a chemically induced skin squamous cell carcinoma (10). Smad2 is known to mediate the signal of TGF- β by modulating the gene expression in the nucleus through the formation of transcription repressor complex with other cofactors so its reactional increase to elevated TGF- β can be easily understood. The difficulty lies in the fact that neither Smad2 nor mutated H-Ras alone can lead to a full EMT. H-Ras is primordial for protection against TGF- β induced apoptosis and it does so through the activation of PI3K as well as by promoting accumulation of Smad2 in the nucleus. More research is needed to fully understand how these two pathways co-operate in abolishing the classical growth arrest and apoptosis signals of TGF- β (10).

1.2.3. Importance of Snail in EMT

The pathway of interest to us is the one involving Snail, a zinc finger transcriptional repressor that can control E-cadherin expression in epithelial cells. Snail is a superfamily of genes that has been found to control gastrulation and neural crest EMT through E-cadherin down-regulation. (10) Snail is located in the fibroblast growth factor receptor 1 (FGFR1) pathway downstream of MAPK and Ras GTPase and is a target of the inflammatory cytokines TGF- β . Its induction though relies also on the simultaneous activation of MAPK and PI3K which inhibits apoptosis.

It is worth noting that Snail expression can as well be stimulated by serum response factor (SRF). SRF is a transcription factor that can be activated by TGF- β through its initial upregulation of RhoA GTPase expression. In the setting of DN, SRF is activated during podocyte EMT stimulated by hyperglycemia (11). This leads to an up-regulation of the core EMT regulatory gene Snail. Similarly, blockade of SRF reduced Snail expression, protected podocytes from EMT and improved the proteinuria (11).

The inflammatory cytokine TNF α was also found to influence the levels of the transcription factor Snail by stabilizing it through the activation of the NF- κ B pathway. Activation of the latter is necessary for the induction of COP9 signalosome 2 which in turn blocks the ubiquitination and degradation of Snail (12).

1.2.4. EMT and Snail in the literature

EMT and Snail have become the target of extensive research especially in oncology where it was found that a good correlation is present between the expression of E-cadherin transcriptional repressor and tumor evolution (10). Indeed, Snail overexpression correlates with tumor grade, nodal metastasis as well as tumor recurrence and predicts a poor outcome in patients with various cancers (12). EMT as a process has also been shown to occur in wound healing and in organ fibrosis (13-17). During long term diabetes kidney fibrosis and damage is preceded by glomerular hypertrophy, and podocyte loss and extensive proteinuria which can lead to glomerular sclerosis (18-20).

Current literature is therefore mainly interested in Snail for its role in tumor invasiveness and not much can be found concerning Snail expression in the kidneys exposed to the harmful effects of diabetes.

2. OBJECTIVES

AIM:

The aim of the present study is to investigate the significance of Snail expression in the development of DN by observing the activity of Snail in 2 weeks and 2 months diabetic kidney samples, and then comparing them to healthy rat tissue of the same age.

HYPOTHESIS:

Snail being so inherently linked to inflammatory processes we expect Snail expression to increase between 2 weeks and 2 months in the diabetic kidney samples while in the control groups we predict no significant changes to be present.

3. MATERIALS AND METHODS

3.1. Ethical background

The experimental protocol was approved by The Ethics Committee of the University of Split, School of Medicine. All performed procedures were in accordance with the ethical standards of the institutional research committee and with the 1964 Helsinki declaration.

3.2. Experimental Animals

Male Sprague-Dawley rats were acquired from the University of Split, each of them weighing between 160 and 180 grams. The rats were raised under controlled conditions consisting of an environment temperature of $22\pm 1^{\circ}\text{C}$ and a 12-hour light/12-hour dark lighting schedule.

3.3. Induction and validation of diabetes

Experiments were performed using a type I diabetes rat model. Diabetes was introduced into the rats via an intraperitoneal injection of 55 mg/kg streptozotocin (STZ) dissolved in citrate buffer, at a pH of 4.5 after overnight fasting (21). Rats were given standard laboratory food, ad libitum, which is made up of 27% proteins, 9% fat and 64% carbohydrates (4RF21 GLP, Mucedola, Settimo Milanese, Italy).

In order to verify diabetes within the rat models, the blood glucose and body weights of the rats were taken. Blood glucose level was measured in the morning at 8 am after overnight fasting. A One Touch Vita instrument (LifeScan, High Wycombe, UK) measured the plasma glucose of the rats by accessing tail vein blood, and a standard scale measured body weights. Rats with a glucose level above 16.5 mmol/L were considered diabetic and were used in subsequent experimentation. Success rate of diabetic induction was about 80%.

The rats were separated into 2 groups based on the duration of diabetes as measured from the point of injection to the termination of the experiment (2 weeks, 2 months). Each

experimental group was matched with a control group consisting of non-diabetic rats raised over the same time period. Control group rats were given intraperitoneal injections with just citrate buffer. 6 animals were raised for each of the 2 control groups and the 2 experimental groups, totaling 24 rat models.

3.4. Tissue collection and immunohistochemistry

Experimental rats were anesthetized with isoflurane (Forane, Abbott Laboratories, Queenborough, UK). Then, 300 mL of Zamboni's fixative at pH 4 (4% paraformaldehyde and 15% picric acid in 0.1 M phosphate-buffered saline) was perfused. Kidney samples were removed and post fixed in the same fixative solution for further analysis.

Kidney samples were removed and post fixed in 300 mL of Zamboni's fixative at pH 4 (4% paraformaldehyde and 15% picric acid in 0.1 M phosphate-buffered saline) for further analysis. The kidney samples were then processed with transverse cuts and then embedded in paraffin blocks. These blocks were then cut into 7 μm thick sections and investigated under immunofluorescence. After deparaffinization, tissue sections were rehydrated using alcohol and water. The samples were then thoroughly rinsed in distilled water and headed in a microwave oven with sodium citrate buffer (pH 6.0) at 95°C for 12 minutes. Samples were cooled at room temperature before being incubated with primary antibody.

Goat anti-Snail antibody from Abcam (ab53519, Cambridge, UK) was diluted at 1:500 ratio in Dako REAL antibody diluent (Dako Denmark A\S, Glostrup, Denmark) then applied to the sample tissue. Following the application of the primary antibody, the tissue sample was kept overnight in a humidified chamber at room temperature. Sections were rinsed with PBS and incubated with the secondary antibody, donkey anti-goat from Abcam (ab150129, Cambridge, UK) for one hour in a humidified chamber. The final stained kidney samples were observed and imaged using a BX51 microscope (Olympus, Tokyo, Japan) equipped with a DP71 digital camera (Olympus, Tokyo, Japan). Following imaging they were processed with Cell A Imaging Software for Life Sciences Microscopy (Olympus Tokyo, Japan). 4',6-diamidino-2-phenylindole (DAPI), hematoxylin & eosin (H&E) and Mallory staining were also performed.

Kidney sections were analyzed focusing on two areas: cortex and medulla. For each of the listed areas, 5 non-overlapping fields were captured for analysis using 40× objective magnification, each field representing one image. Microphotographs were examined using ImageJ software (National Institutes of Health, Bethesda, MD, USA).

Kidney sections were semi-quantitatively analysed and described as four categories in regards to the staining intensity: (0) indicating the absence of any reactivity, (1) a mild reactivity, (2) moderate reactivity, (3) strong reactivity (Figure 8.). Two researchers independently analysed the staining intensity. The amount of positive cells within each area (glomerulus, proximal convoluted tubule, distal convoluted tubule, collecting duct) were compared between the experimental diabetic groups and control groups. Distinct analyses were conducted for the 4 sections at each time point, and then the data was aggregated for all areas of the control and diabetic rats and evaluated.

3.5. Statistics

Mann-Whitney test was used for statistical analysis to examine the differences between the control groups and the diabetic groups. Data analysis was conducted using GraphPad Prism (GraphPad Software, La Jolla, CA, USA). Data was expressed as a mean ± standard deviation, with $p < 0.05$ serving as the marker of statistical significance.

4. RESULTS

H&E staining showed normal kidney morphology in both groups. In the 2 weeks and 2 months groups H&E staining displays no obvious differences between both groups (figure 1 and 2). However in 2 months old kidneys morphological changes in glomeruli of diabetic group occurs (figure 1). These changes are related to glomerular hypertrophy and podocyte lost, which can lead to mesangial expansion and glomerular sclerosis.

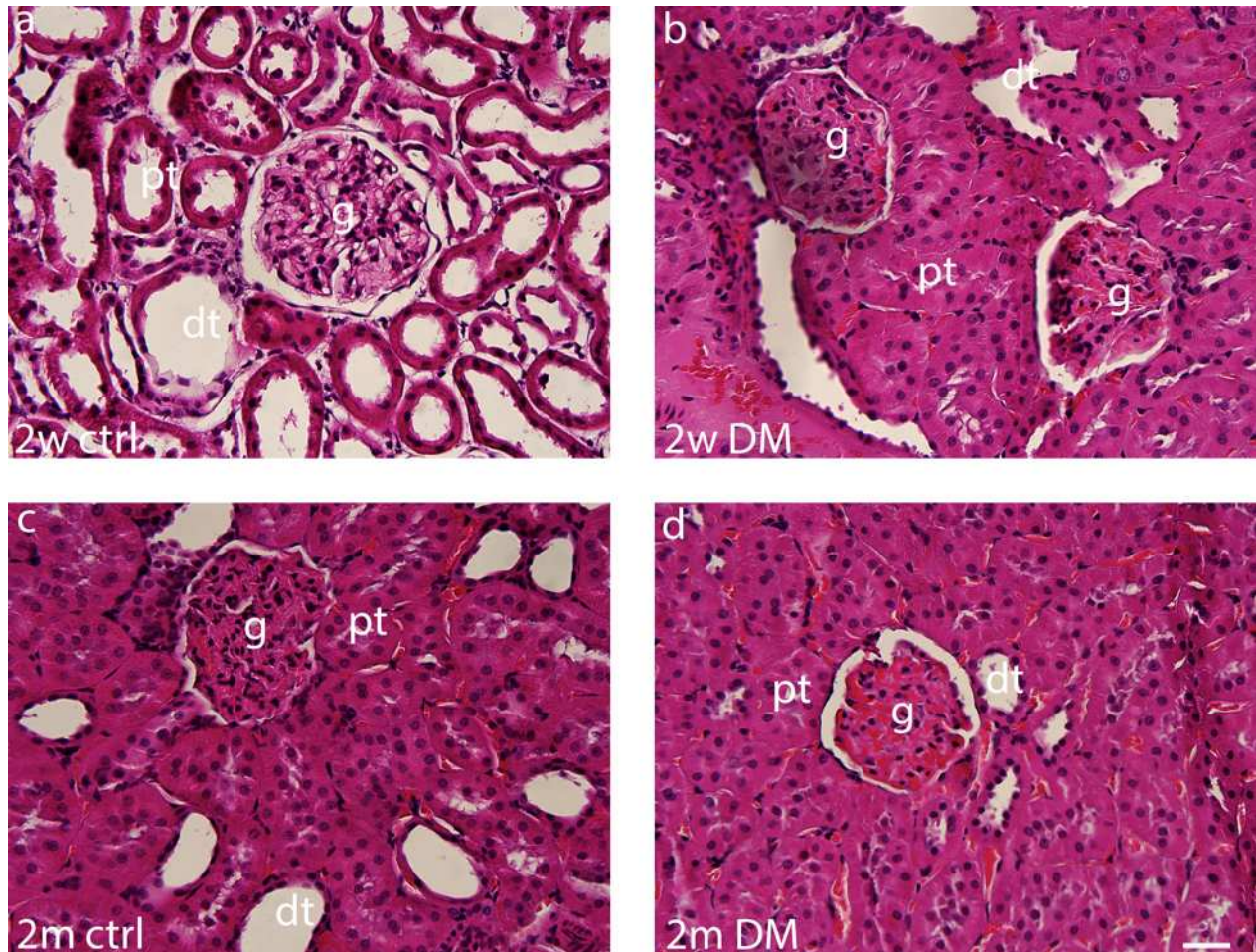


Fig. 1. Transversal section through the kidney tissue with the areas of interest: kidney cortex at 2 weeks in control (a) and diabetes (b); at 2 months in control (c) and diabetes (d). Scale bar 25 μ m. Legend: dt- distal tubule; g- glomerulus; pt- proximal tubule; ctrl- control; DM- diabetes mellitus type 1.

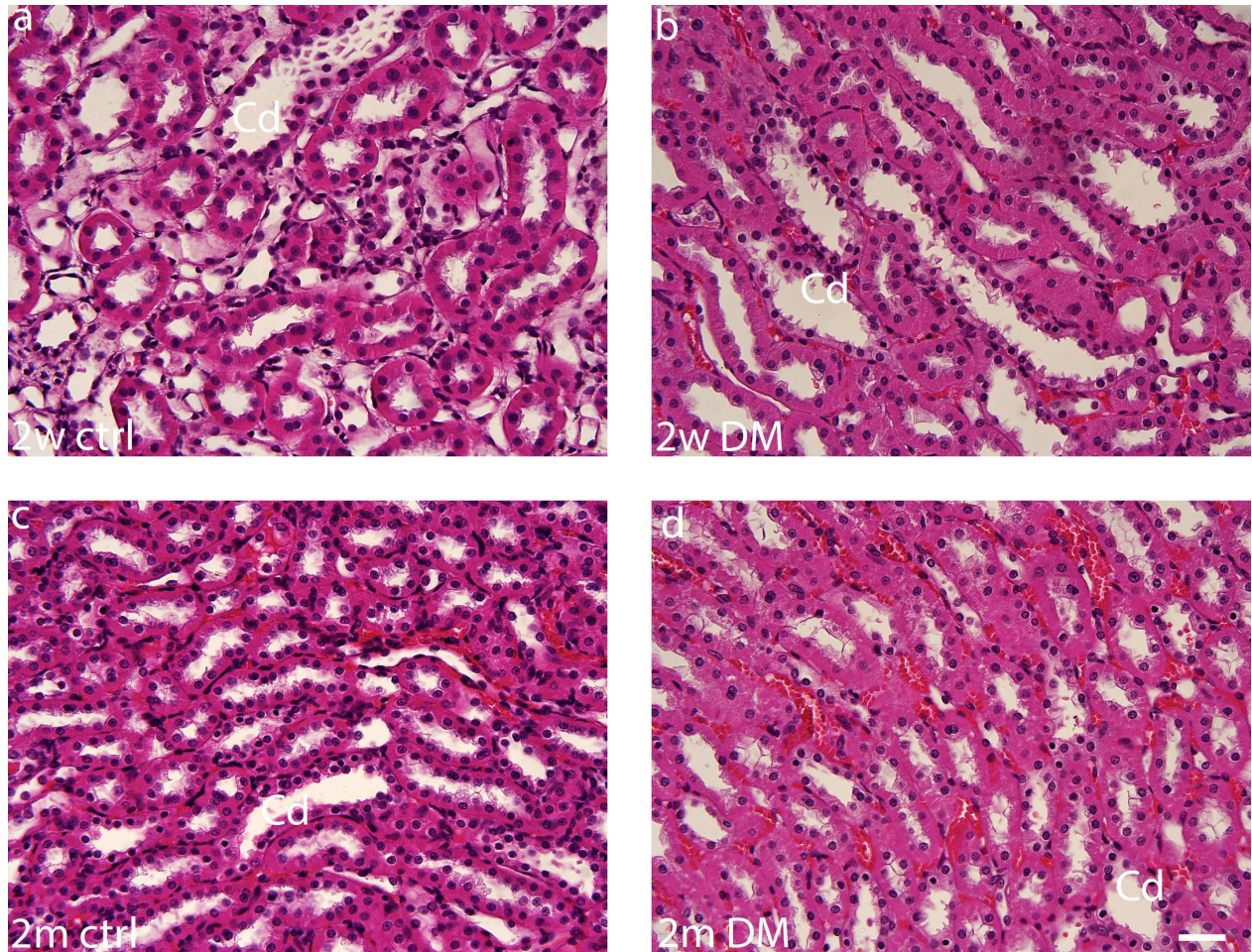


Fig. 2. Transversal section through the kidney tissue with the areas of interest: kidney medulla at 2 weeks in control (a) and diabetes (b); at 2 months in control (c) and diabetes (d). Scale bar 25 μ m. Legend: Cd- collecting ducts; ctrl- control; DM- diabetes mellitus type 1.

Mallory staining in the 2 weeks groups showed no obvious difference and normal kidney morphology is present in both diabetic and control groups (figure 3 and 4 a,b). In the 2 months groups we can see differences in regards to the extent of damage through replacement of podocytes with connective tissue cells (figure 3 and 4 c,d).

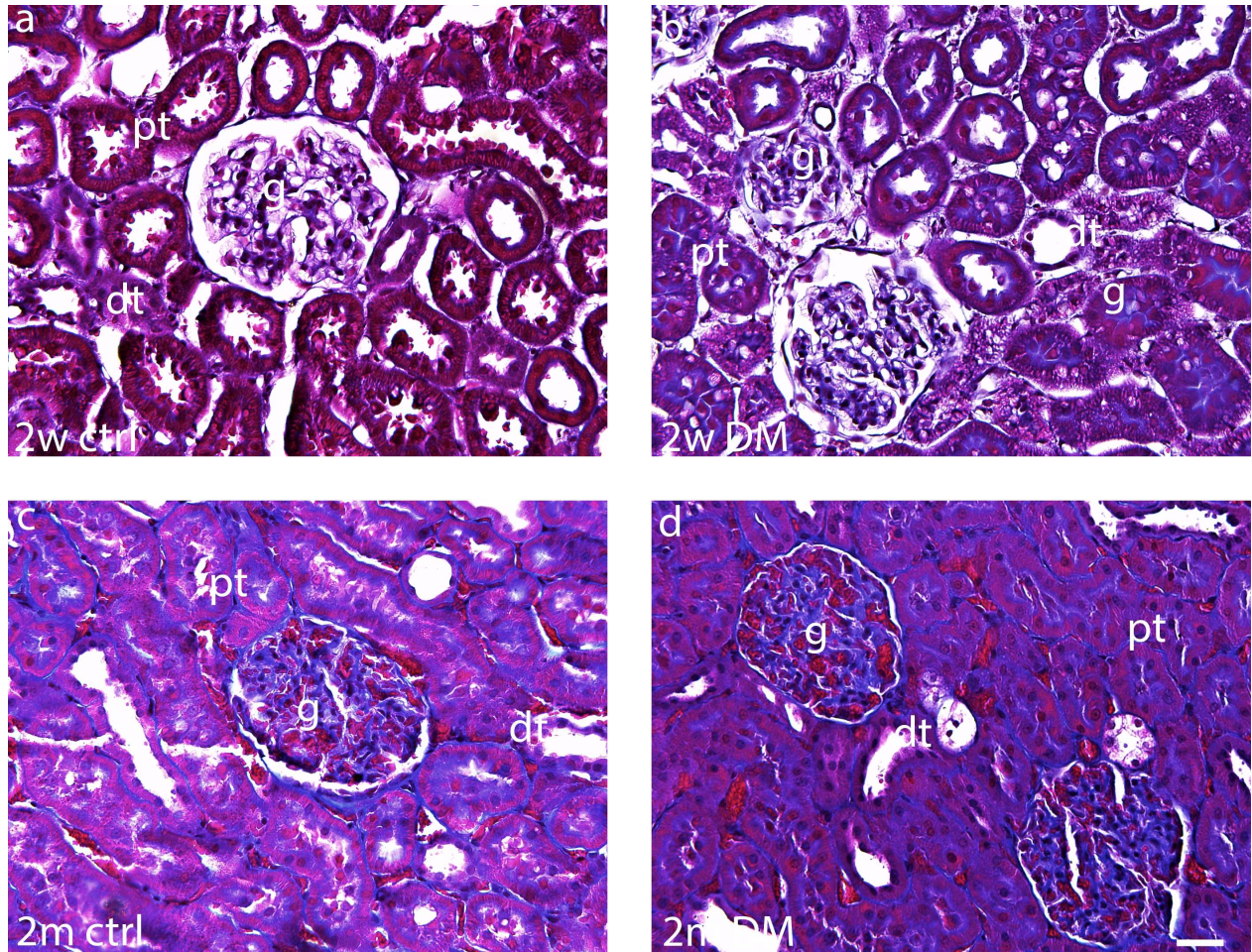


Fig. 3. Transversal section through the kidney tissue with the areas of interest: kidney cortex at 2 weeks in control (a) and diabetes (b); at 2 months in control (c) and diabetes (d). Scale bar 25 μ m. Legend: dt- distal tubule; g- glomerulus; pt- proximal tubule; ctrl- control; DM- diabetes mellitus type 1

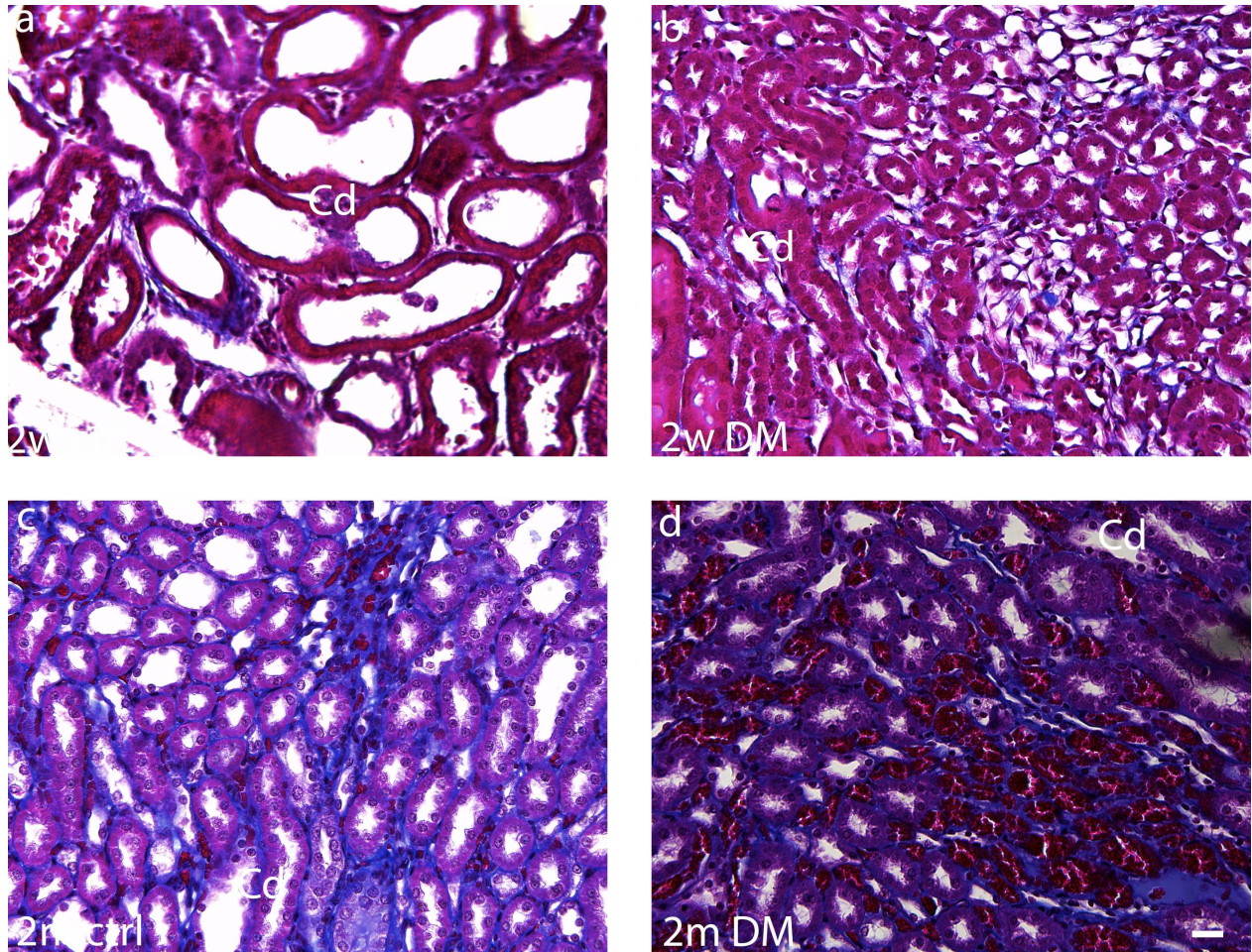


Fig. 4. Transversal section through the kidney tissue with the areas of interest: kidney medulla at 2 weeks in control (a) and diabetes (b); at 2 months in control (c) and diabetes (d). Scale bar 15 μ m. Legend: Cd- collecting ducts; ctrl- control; DM- diabetes mellitus type 1.

Snail positive cells were seen as green staining of cytoplasm within different areas of the cortex and medulla of kidneys during 2 weeks and 2 months after induction of diabetes mellitus (Figure 5 and 6). Cytoplasmic staining is better observed when images were merged with DAPI nuclear stain as shown on figure 5 and 6.

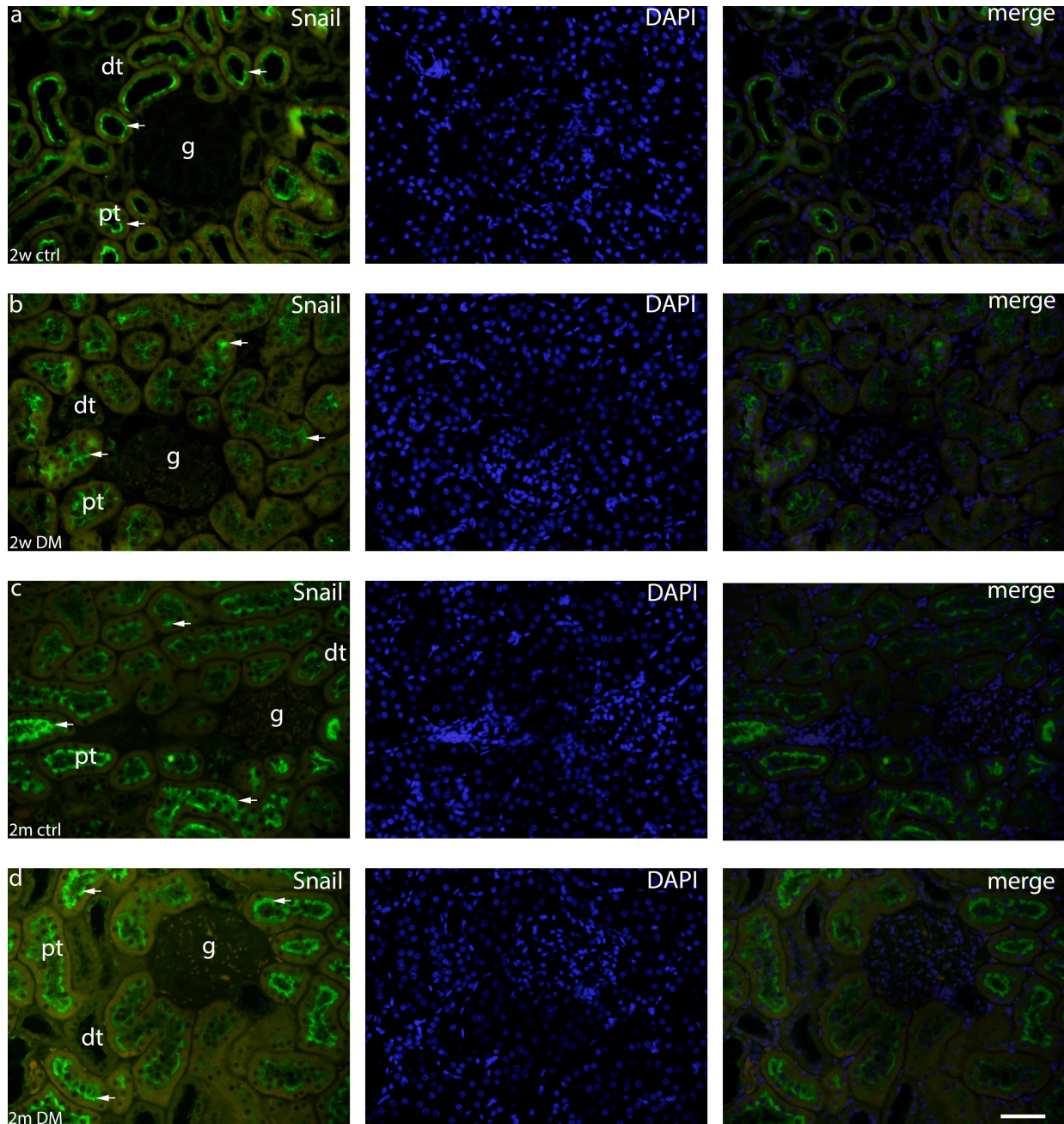


Fig. 5. Snail positive cells were seen as green staining of cytoplasm (arrows) within different areas of the cortex of kidneys. Co-localization of Snail and DAPI nuclear stain are shown in the far-right column (merge). Kidney cortex in control and DM at 2 weeks (a, b) and 2 months (c, d). Scale bar 25 μ m. Legend: dt- distal tubule; g- glomerulus; pt- proximal tubule; ctrl- control; DM- diabetes mellitus type 1

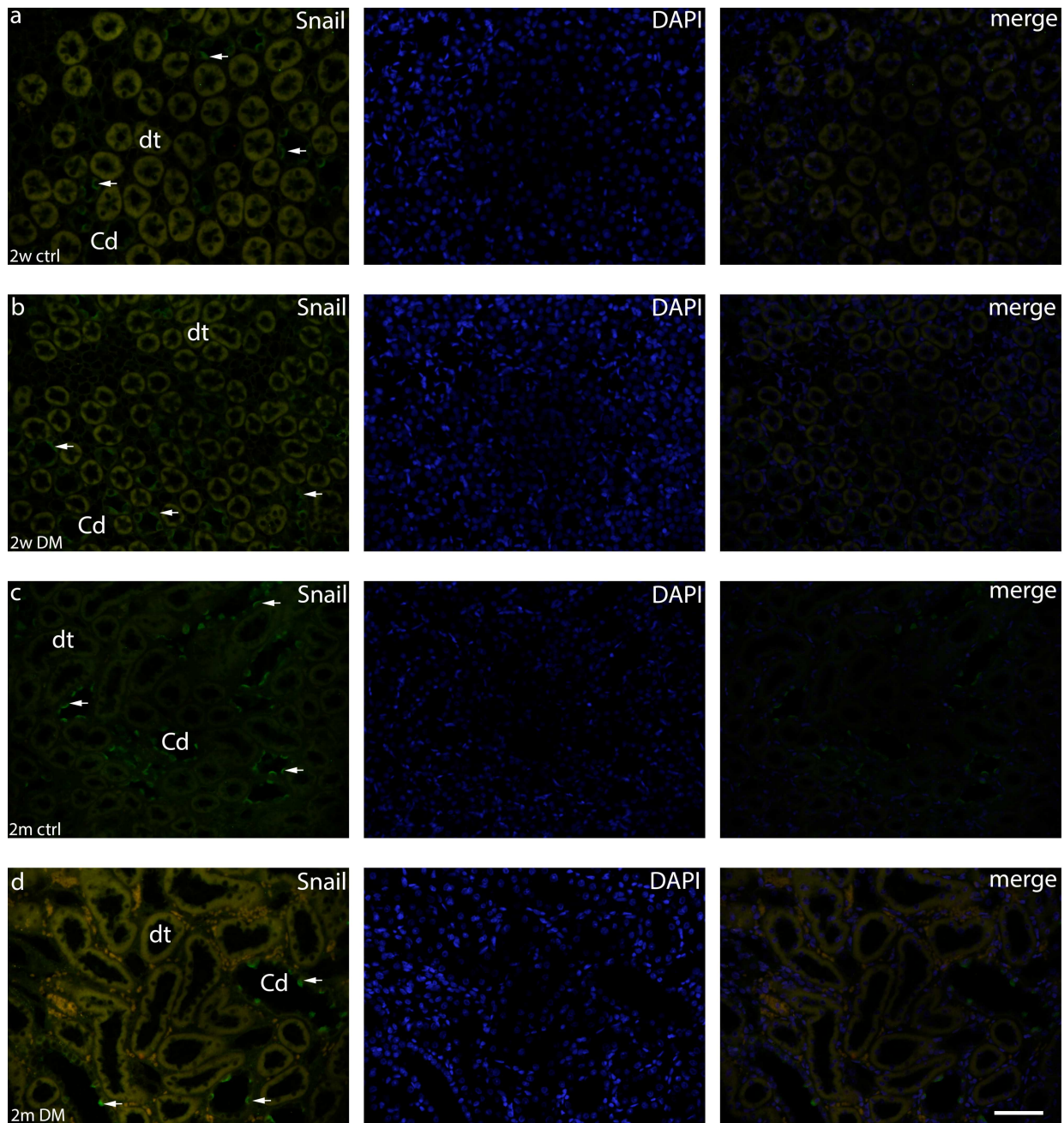


Fig. 6. Snail positive cells were seen as green staining of cytoplasm (arrows) within different areas of the medulla of kidneys. Co-localization of Snail and DAPI nuclear stain are shown in the far-right column (merge). Kidney medulla in control and DM at 2 weeks (a, b) and 2 months (c, d). Scale bar 25 μ m. Legend: dt- distal tubule; g- glomerulus; pt- proximal tubule; ctrl- control; DM- diabetes mellitus type 1

Threshold area percent of Snail positive cells in 2 weeks and 2 months of control and diabetic rat groups revealed statistically significant difference between control and diabetic group with higher threshold area percent of Snail in control groups (Figure 7.).

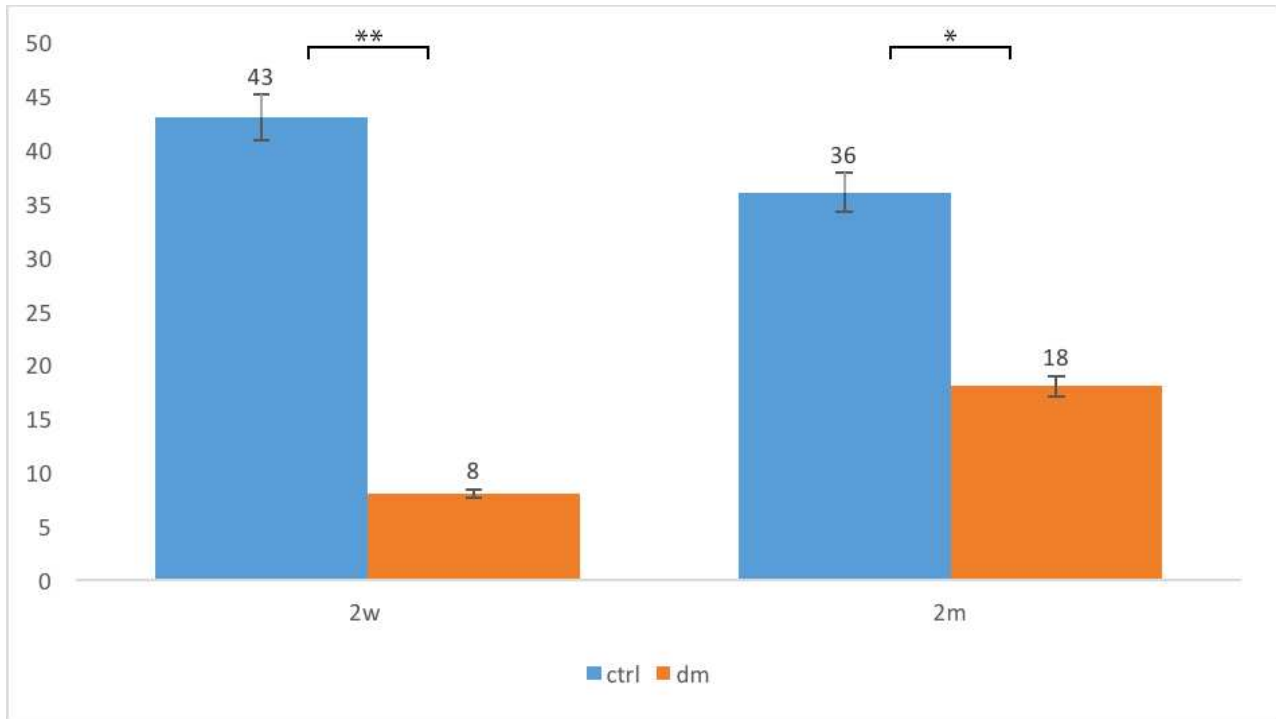


Fig. 7. Threshold area percent of Snail positive cells in 2 weeks (2w) and 2 months (2m) of control and diabetic rat groups. Asterisk denotes significant difference: * $p < 0.05$, ** $p < 0.01$. Data presented as $M \pm SD$. Legend: ctrl- control; dm- diabetes mellitus type 1

Snail expression is mostly located within cortex in the proximal tubules. Strong intensity of Snail expression can be seen in proximal tubules in control in both 2 weeks and 2 months' groups, while in both diabetic groups Snail staining intensity was mild (Figure 8.).

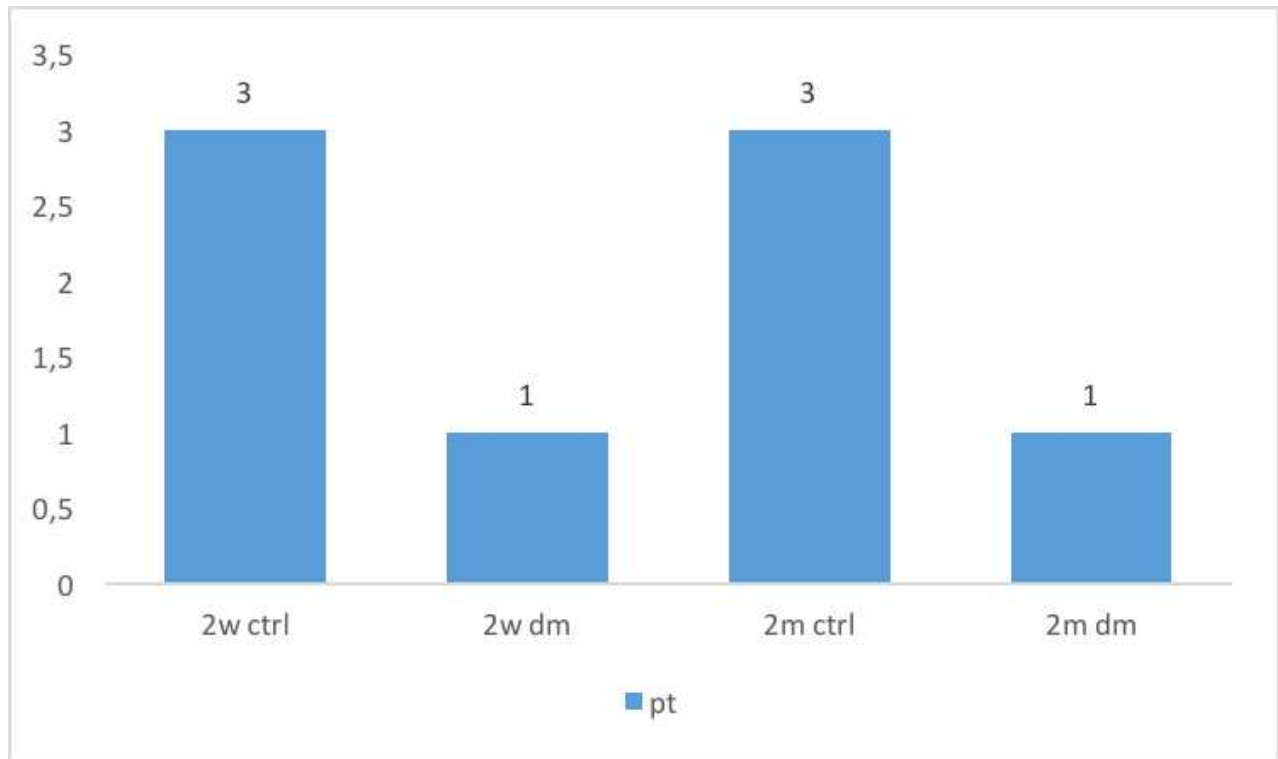


Fig. 8. Staining intensity of Snail in proximal tubules (pt) in 2 weeks (2w) and 2 months (2m) of control and diabetic rat groups. Legend: ctrl- control; dm- diabetes mellitus type 1.

In the proximal tubules, the highest percentage of Snail positive cells was observed in 2-weeks control group (90%), while the lowest percentage of Snail positive cells was observed in 2 months' diabetic group (12%). While remaining approximately the same for the control group, the percentage of Snail positive cells in the proximal tubules of diabetic kidneys is decreasing from 55% after 2 weeks to 12% after 2 months (Figure 9.).

Snail positive cells can also be found in the collecting ducts but the percentages remain very low there with 8% for the 2 weeks control group decreasing mildly to 7% after 2 months and with 2% in the 2 weeks diabetic group. Snail staining of collecting ducts is absent after 2 months in the diabetic group.

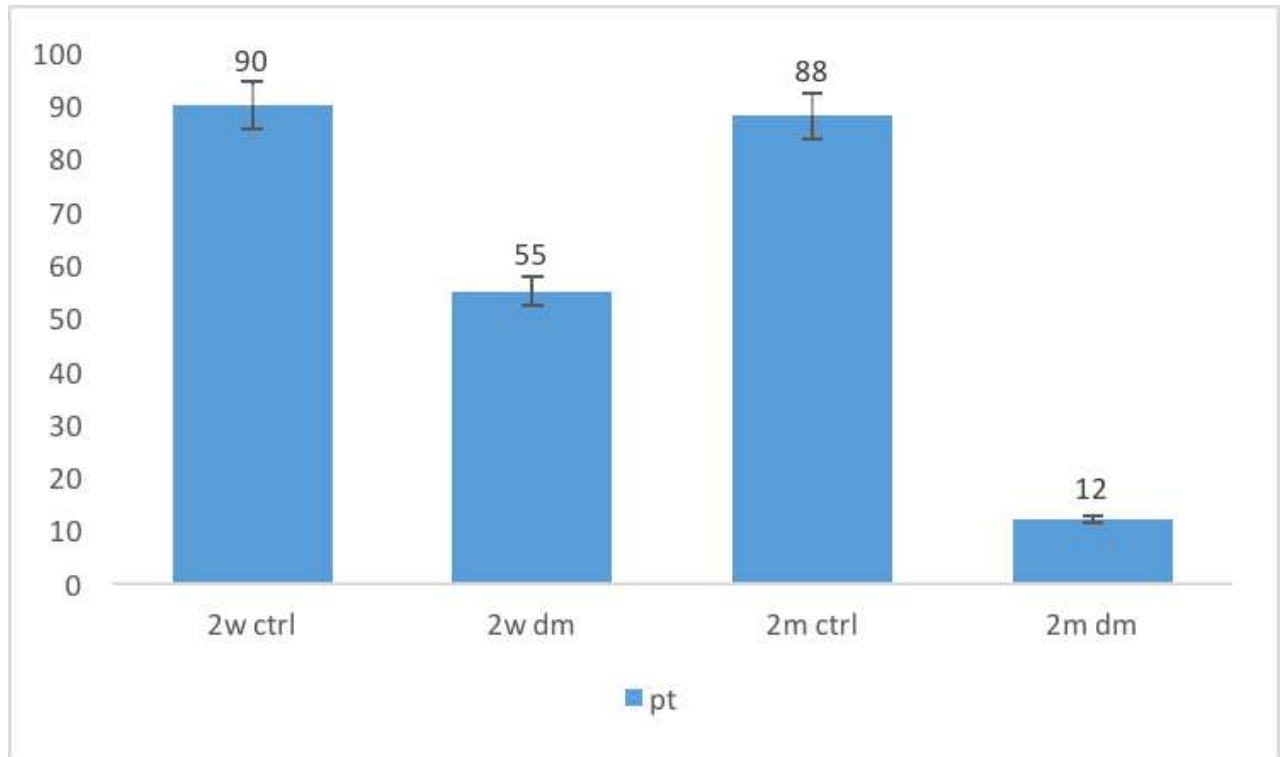


Fig. 9. Percentage of Snail positive cells in proximal tubules (pt) in 2 weeks (2w) and 2 months (2m) of control and diabetic rat groups. Legend: ctrl- control; dm- diabetes mellitus type 1.

5. DISCUSSION

In our research, HE and Mallory staining showed us the first signs of glomerulosclerosis in diabetic rats after 2 months. Changes in cells during diabetic nephropathy have been followed for a long time, but a lot of them still remain unclear. Wu et al., whom sacrificed rats after 1, 4, and 8 weeks, showed that autophagic disorders can contribute to early diabetic nephropathy, and that autophagy is important for regulation of cellular homeostasis in kidneys (18). Menini et al. showed that glomerular cell apoptosis was higher in diabetic rats vs controls after 4 and 6 months (19). Glomerular cell apoptosis, which can lead to glomerular sclerosis, is the aftermath of a process that started with glomerular hypertrophy itself leading to podocyte loss followed by proteinuria (19). Similar finding in other research, also with rats sacrificed after 4, 8 weeks and 6 months, where the authors indicated glomerular apoptosis after 6 months of DM induction through the MIB-5 positivity which can lead to glomerular sclerosis (20). The limitation of our study in this regard is the lack of data on proteinuria level and blood level of urea and creatinine which could give important additional information about the development of diabetic nephropathy.

Snail expression in healthy kidneys is important to maintain normal homeostasis of potential regenerative capacity in kidneys. During normal aging this expression is decreasing, but in diabetes mellitus Snail expression is impaired already at 2 weeks after diabetes induction showing very early negative effect on potential regenerative capacity in kidneys. Namely, Snail suppresses Cadherin-16 and consequently represses the kidney differentiation factor HNF-1 β . This is a novel route by which Snail disrupts epithelial homeostasis. Snail activation is sufficient to induce EMT and kidney fibrosis in adult transgenic mice (5).

After 2 months of diabetes induction, Snail expression in kidneys is slowly recovering but is still two times lower than in healthy 2-months control. This finding implies that other recovery mechanisms are involved in order to preserve potential regenerative capacity in kidneys.

Snail expression is mostly located within cortex in the proximal tubules. This finding is important because proximal tubules make up a significant portion of the kidneys and carry out diverse regulatory and endocrine functions where numerous transporters are located (5). Additionally, number of inherited and acquired tubular disorders are connected to impaired transporters in the proximal tubules (5). Similarly, proximal tubules have intrinsic immune

characteristics with an active role in ischemic injury that can be observed in long term diabetes in kidney (10). It is therefore not surprising that proximal tubule-related occurrences are linked to the pathogenesis of a vast array of kidney diseases (10).

Snail can also be seen in the collecting ducts in the kidneys medulla but the percentage of Snail positive cells remains very low there and is almost completely absent in the diabetic groups. Strong intensity of Snail expression can be seen in proximal tubules in control in both 2 weeks and 2 months' group, while in both diabetic group Snail staining intensity was mild. Strong Snail intensity in proximal tubules is in line with earlier mentioned importance of Snail in regulatory kidney functions (11, 12). Namely, Snail controls major biological processes responsible for renal fibrogenesis, including mesenchymal reprogramming of tubular epithelial cells, shutdown of fatty acid metabolism, cell cycle arrest and inflammation of the microenvironment surrounding tubular epithelial cells (11, 12). All these processes are activated in diabetic nephropathy therefore the loss of Snail expression in diabetes contributes to development of diabetic nephropathy.

Studying changes of kidneys during aging can allow insights into the kidney physiology of healthy rats and the diabetic pathophysiology of diabetic rats. Therefore, further studies giving information about the long-term effects of diabetes on kidney pathophysiology are needed to elucidate the role of Snail expression in diabetic nephropathy.

6. CONCLUSION

1. Snail expression in healthy kidneys is important to maintain normal homeostasis of potential regenerative capacity in kidneys.
2. In diabetes mellitus Snail expression is impaired already at 2 weeks after diabetes induction.
3. Snail expression in proximal tubules is important because of the key role of proximal tubules in regulatory kidney functions.
4. Snail controls major biological processes responsible for renal fibrogenesis, mesenchymal reprogramming of tubular epithelial cells and homeostasis of the microenvironment surrounding tubular epithelial cells.

7. REFERENCES

1. Alberti K, Zimmet P. Definition, diagnosis and classification of diabetes mellitus and its complications. *Diabet Med.* 1998;15(7):539-53.
2. Ghaderian SB, Hayati F, Shayanpour S, Mousavi SSB. Diabetes and end-stage renal disease; a review article on new concepts. *J Renal Inj Prev.* 2015; 4(2): 28-33.
3. Schena F. Pathogenetic Mechanisms of Diabetic Nephropathy. *J Am Soc Nephrol.* 2005;16(Suppl 1):30-3.
4. Fu J, Lee K, Chuang P, Liu Z, He J. Glomerular endothelial cell injury and cross talk in diabetic kidney disease. *Am J Physiol Renal Physiol.* 2014;308(4):287-97.
5. Gilbert R, Cooper M. The tubulointerstitium in progressive diabetic kidney disease: More than an aftermath of glomerular injury?. *Kidney Int.* 1999;56(5):1627-37.
6. Bader R, Bader H, Grund K, Mackensen-Haen S, Christ H, Bohle A. Structure and Function of the Kidney in Diabetic Glomerulosclerosis. *Pathol Res Pract.* 1980;167(2-4):204-16.
7. Lane P, Steffes M, Fioretto P, Mauer S. Renal interstitial expansion in insulin-dependent diabetes mellitus. *Kidney Int.* 1993;43(3):661-7.
8. Mauer S, Steffes M, Ellis E, Sutherland D, Brown D, Goetz F. Structural-functional relationships in diabetic nephropathy. *J Clin Invest.* 1984;74(4):1143-55.
9. Ueno M, Kawashima S, Nishi S, Shimada S, Shimada N, Karasawa R, et al. Tubulointerstitial lesions in non-insulin dependent diabetes mellitus. *Kidney Int.* 1997;52(Suppl 63):191-4.
10. Thiery JP. Epithelial–mesenchymal transitions in development and pathologies. *Curr Opin Cell Biol.* 2003;15(6):740-6.
11. Zhao L, Wang X, Sun L, Nie H, Liu X, Chen Z, et al. Critical role of serum response factor in podocyte epithelial–mesenchymal transition of diabetic nephropathy. *Diab Vasc Dis Res.* 2015;13(1):81-92.
12. Wu Y, Deng J, Rychahou P, Qiu S, Evers B, Zhou B. Stabilization of Snail by NF- κ B Is required for inflammation-induced cell migration and invasion. *Cancer Cell.* 2009;15(5):416-28.
13. Lamouille S, Xu J, Derynck R. Molecular mechanisms of epithelial–mesenchymal transition. *Nat Rev Mol Cell Biol.* 2014;15(3):178–96.
14. Huang L, Wu R, Xu A. Epithelial-mesenchymal transition in gastric cancer. *Am J Transl Res.* 2015;7(11):2141–58.
15. Li M, Luan F, Zhao Y, Hao H, Zhou Y, Han W, et al. Epithelial-mesenchymal transition: An emerging target in tissue fibrosis. *Exp Biol Med (Maywood)* 2016;241(1):1–13.

17. Moustakas A, Heldin CH. Mechanisms of TGF β -Induced Epithelial–Mesenchymal Transition. *J Clin Med*. 2016;5(7):63.
18. Wu WH, Zhang MP, Zhang F, Liu F, Hu ZX, Hu QD, et al. The role of programmed cell death in streptozotocin-induced early diabetic nephropathy. *J Endocrinol Invest*. 2011;34(9):296-301.
19. Menini S, Iacobini C, Oddi G, Ricci C, Simonelli P, Fallucca S, et al. Increased glomerular cell (podocyte) apoptosis in rats with streptozotocin-induced diabetes mellitus: role in the development of diabetic glomerular disease. *Diabetologia*. 2007;50(12):2591-9.
20. Pesce C, Menini S, Pricci F, Favre A, Leto G, DiMario U, et al. Glomerular cell replication and cell loss through apoptosis in experimental diabetes mellitus. *Nephron*. 2002;90(4):484-8.
21. Bakovic M, Juric Paic M, Zdrilic E, Vukojevic K, Ferhatovic L, Marin A, et al. Changes in cardiac innervation during maturation in long-term diabetes. *Exp Gerontol*. 2013;48(12):1473-8.

8. SUMMARY

Title: EXPRESSION PATTERN OF SNAIL IN THE KIDNEYS OF STREPTOZOTOCIN-INDUCED DIABETIC RATS

Objectives: The most prevalent cause of chronic kidney disease is diabetic nephropathy (DN), which can lead to end-stage renal disease (ESRD) and premature death in developed countries but knowledge about these changes is still unsatisfactorily. Specific factors can be used to study developmental pathways and changes in rat diabetic kidneys. Snail is a superfamily of genes that has been found to control gastrulation and neural crest EMT through E-cadherin down-regulation. Snail is located in the fibroblast growth factor receptor 1 (FGFR1) and has a regulatory role in kidney physiology by involvement in the pathway downstream of MAPK and Ras GTPase. The aim of the study was to analyse whether prolonged DM induces changes in immunofluorescence expression of Snail in rat's kidney and how it contributes to DN during ageing.

Materials and methods: Diabetes mellitus (DM) was induced by i/p injecting 55 mg/kg streptozotocin (STZ) to male Sprague-Dawley rats, and was validated by measuring blood glucose level. Control group received citrate buffer. Animals were sacrificed after 2 weeks and 2 months. Cortex areas (glomeruli, proximal and distal tubules) and medullary areas (collecting ducts and distal tubules) were analysed with antibodies raised against Snail.

Results: Snail expression is mostly located within cortex in the proximal tubules. Strong intensity of Snail expression can be seen in proximal tubules in control in both 2 weeks and 2 months' groups, while in both diabetic groups Snail staining intensity was mild. In the proximal tubules, the highest percentage of Snail positive cells was observed in 2-weeks control group (90%). Snail positive cells can also be found in the collecting ducts but the percentages remain very low there with 8% for the 2 weeks control group decreasing mildly to 7% after 2 months and with 2% in the 2 weeks diabetic group. Snail staining of collecting ducts is absent after 2 months in the diabetic group.

Conclusion: Our findings suggest that Snail is linked to regulatory functions in kidney's proximal tubules and that the loss of Snail expression in diabetic kidneys can lead to advanced DN. This finding can contribute to better understanding of the pathogenesis of DN during short-term DM.

9. CROATIAN SUMMARY

NASLOV: IZRAŽAJ SNAIL-A U BUBREZIMA ŠTAKORA SA STREPTOZOTOCIN-INDUCIRANIM DIJABETESOM

Ciljevi: Najčešći uzrok kronične bolesti bubrega je dijabetička nefropatija (DN) koja može dovesti do terminalne bolesti bubrega (ESRD) i prerane smrti u razvijenim zemljama, no znanje o tim promjenama i dalje je nezadovoljavajuće. Specifični faktori mogu se koristiti za proučavanje razvojnih putova i promjena u dijabetičkim bubrezima štakora. Snail je superobitelj gena koji je pronađen za kontrolu gastrulacije i diferencijacije neuralnog grebena putem EMT-a kroz nizvodnu regulaciju E-cadherin. Snail se nalazi u receptoru faktora rasta fibroblasta 1 (FGFR1) i ima regulatornu ulogu u fiziologiji bubrega uključivanjem u stazu nizvodno od MAPK i Ras GTPase. Analizirali smo da li produljeni DM uzrokuje promjene u imunofluorescencijskoj ekspresiji Snaila u bubrezima štakora i kako to doprinosi DN-u tijekom starenja.

Materijali i metode: Diabetes mellitus (DM) je induciran i/p injektiranjem 55 mg/kg streptozotocina (STZ) mužjacima Sprague-Dawley štakora i validiran mjerenjem razine glukoze u krvi. Kontrolna skupina je primila citratni pufer. Životinje su žrtvovane nakon 2 tjedna i 2 mjeseca. Područja kore (glomeruli, proksimalni i distalni tubuli) i medularna područja (sabirni kanali i distalni tubuli) analizirani su protutijelima na Snail.

Rezultati: Izražaj Snaila se uglavnom nalazi unutar korteksa u proksimalnim tubulama. Jaki intenzitet ekspresije Snaila može se vidjeti u proksimalnim tubulama u kontroli u obje skupine od 2 tjedna i 2 mjeseca, dok je u obje dijabetičke skupine intenzitet bojenja Snaila bio blag. U proksimalnim tubulama, najveći postotak stanica pozitivnih na Snail zapažen je u kontrolnoj skupini od 2 tjedna (90%). Snail pozitivne stanice se također mogu naći u sabirnim kanalima, ali postotci ostaju vrlo niski, s 8% u 2. tjednu kontrolne skupine koja se blago smanji na 7% nakon 2 mjeseca i 2% u 2. tjednu u dijabetičkoj skupini. Izražaj Snaila je odsutan nakon 2. mjeseca u dijabetičkoj skupini.

Zaključci: Naši nalazi sugeriraju da je izražaj Snaila povezan s regulacijskim funkcijama u proksimalnim tubulama bubrega, a gubitak izražaja Snaila kod dijabetičkih bubrega može dovesti do naprednog DN. Naš rad može doprinijeti boljem razumijevanju patogeneze DN tijekom kratkotrajnog DM.

10. CURRICULUM VITAE

Personal Data:

Name and Surname: Samy Ksouri

Date and place of birth: January 26th 1993 in Grasse

Citizenship: French, Tunisian

Address: 10 rue Nicolo, 75116, Paris

E-mail: samy.ksouri@gmail.com

Education:

2011-2017 University of Split School of Medicine, Split, Croatia

2007-2010 Lycée Jean-Baptise Say, Paris

Languages:

Native French, native spoken Arabic

Fluent English, conversational Spanish and Croatian

Further Engagement:

Participated in an exchange program with Penn State University – College of Medicine during the summer 2017

Received the Dean's Award for having the highest GPA of all second year English students

Elected three years in a row as treasurer for the International Student Association – University of Split School of Medicine (ISA – USSM)