

An unusual presentation of testicular torsion in children : a single-centre retrospective study

Neumann, Christopher

Master's thesis / Diplomski rad

2018

Degree Grantor / Ustanova koja je dodijelila akademski / stručni stupanj: **University of Split, School of Medicine / Sveučilište u Splitu, Medicinski fakultet**

Permanent link / Trajna poveznica: <https://um.nsk.hr/um:nbn:hr:171:608395>

Rights / Prava: [In copyright](#)/[Zaštićeno autorskim pravom.](#)

Download date / Datum preuzimanja: **2025-03-06**



Repository / Repozitorij:

[MEFST Repository](#)



UNIVERSITY OF SPLIT



**UNIVERSITY OF SPLIT
SCHOOL OF MEDICINE**

Christopher Neumann

**AN UNUSUAL PRESENTATION OF TESTICULAR TORSION IN
CHILDREN: A SINGLE – CENTRE RETROSPECTIVE STUDY**

Diploma thesis

Academic year:

2017/2018

Mentor:

Assist. Prof. Zenon Pogorelić, MD, PhD

Split, July 2018

CONTENT

1. INTRODUCTION.....	1
1.1. ACUTE SCROTUM.....	2
1.2. ANATOMY.....	2
1.2.1. ANATOMY OF THE SCROTUM.....	2
1.2.2. ANATOMY OF THE TESTIS AND EPIDIDYMIS.....	3
1.3. TESTICULAR TORSION.....	5
1.3.1. HISTORY AND OVERVIEW.....	5
1.3.2. EPIDEMIOLOGY.....	7
1.3.3. RISK FACTORS.....	7
1.3.4. CLINICAL PRESENTATION.....	8
1.3.5. DIFFERENTIAL DIAGNOSIS.....	8
1.3.6. DIAGNOSIS AND MANAGEMENT.....	10
1.3.7. AN UNUSUAL PRESENTATION OF TESTICULAR TORSION.....	13
2. OBJECTIVES OF RESEARCH.....	15
3. MATERIAL AND METHODS.....	17
3.1. PATIENTS.....	18
3.2. ORGANIZATION OF THE STUDY.....	18
3.3. PLACE OF THE STUDY.....	18
3.4. METHODS OF DATA COLLECTION AND PROCESSING.....	18
3.5. DESCRIPTION OF RESEARCH.....	19
3.6. TREATMENT AND FOLLOW-UP.....	19
4. RESULTS.....	20
5. DISCUSSION.....	29
6. CONCLUSION.....	33
7. REFERENCES.....	35
8. SUMMARY (English).....	39
9. SUMMARY (Croatian).....	41
10. CURRICULUM VITAE	43

Acknowledgement:

I want to thank my mentor Assist. Prof. Zenon Pogorelić, MD, PhD, for patiently helping me throughout my diploma thesis.

And I also want to thank my family – for everything they did for me.

1.1. ACUTE SCROTUM

Acute scrotum is a collective term for a series of common urological emergency events. Thus knowledge about these entities is fairly important to be able to make the correct diagnosis and initiate the treatment, since otherwise dramatic consequences for the patient are inevitable.

Acute scrotum is a clinical syndrome provoked by several different conditions, characterized by painful swelling and redness of the scrotum. Approximately 40 years ago, the term acute scrotum was mentioned for the first time by Moharit and Krahn (1).

The collective term includes pathological conditions like testicular torsion, epididymitis, twisting of the spermatic cord, torsion of the testicular appendage, testicular tumor, trauma, incarcerated scrotal hernia, inflamed hydrocele and insect bite. In the medical emergency setting, the most frequent presenting cases out of these conditions are acute epididymitis, torsion of the testicular appendages and testicular torsion (1-9).

1.2. ANATOMY

1.2.1. ANATOMY OF THE SCROTUM

The scrotal sac is a cutaneous pouch, made up of two histological distinguishable layers. The superficial one is a strongly pigmented layer of skin and the deeper one the dartos fascia. The latter contains smooth muscle fibers and thereby causes the typical rugose appearance of the scrotal skin. The dartos layer together with the cremaster muscle is responsible for the adaptation to heat loss and draws, when triggered, the testicles closer to the body (10).

The continuation of the dartos fascia creates a septum within the scrotum and thus divides it into a left and a right compartment. From the external view the septum is recognizable by the scrotal raphe, which is a cutaneous ridge originated by the fusion of the embryonic labioscrotal swelling. These labioscrotal swellings are two cutaneous outpouchings originating from the anterior abdominal wall (11).

The arterial blood supply of the scrotum is derived from the posterior scrotal branches of the perineal artery, the anterior scrotal branches of the deep pudendal artery and by the cremasteric artery. The scrotal veins take course next to their arteries (10).

The lymphatic drainage is directed towards the the superficial inguinal lymph nodes.

Branches of the lumbar plexus to the anterolateral surface and branches of the sacral plexus to the posterior and inferior surface, provide the nerve supply to the scrotum (11). Figure 1 illustrates an anatomical overview.

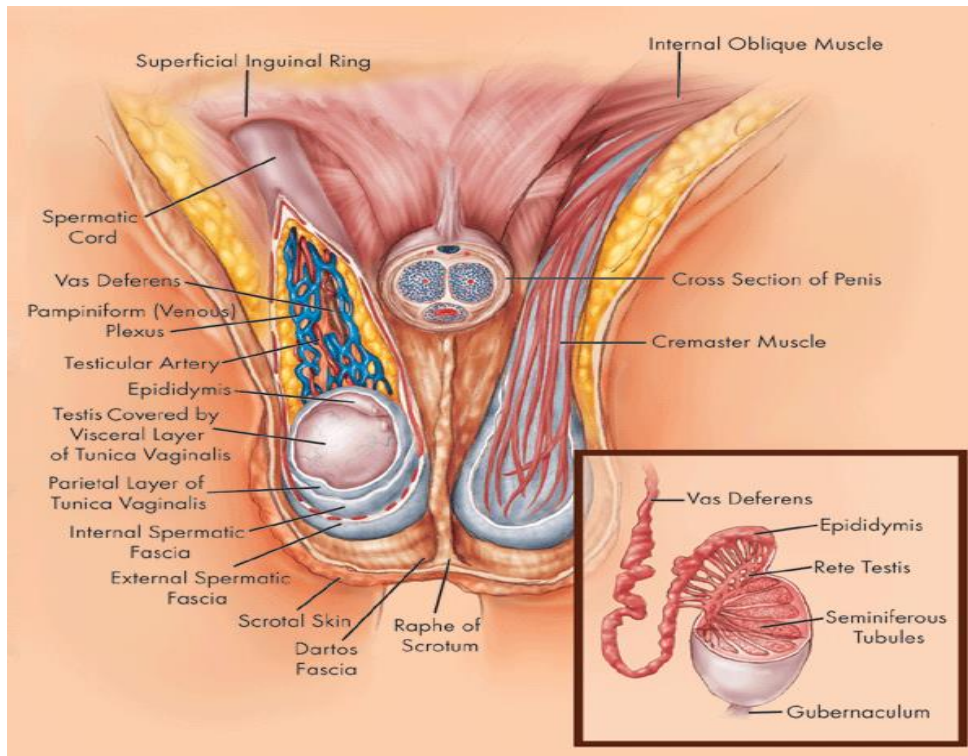


Figure 1. Scrotal anatomy. Taken from <http://www.rudyard.org/scrotum-anatomy/>.

1.2.2. ANATOMY OF THE TESTIS AND EPIDIDYMIS

The male reproductive organs are glands that produce spermatozoa and hormones, especially testosterone. The testicles are attached to the spermatic cord within the scrotal sac. Commonly the left side is situated slightly inferior compared to the right one. The outermost layer is the parietal layer of the tunica vaginalis, followed by the visceral layer of the tunica vaginalis. Inbetween those layers is a small collection of liquid, which gives the testicles the capability to maneuver within the scrotum. The tunica vaginalis as a whole, can be seen as a distal part of the embryonic processus vaginalis (10,11). The tunica albuginea is a strong fibrous layer surrounding the testicles, which forms the mediastinum of the testis at the

internal posterior side. From this structure, several septa stretch inward and separate the seminiferous tubules, which are necessary for the sperm production (Fig. 2). In the mediastinum, the seminiferous tubules unite with the straight tubules and together they constitute the rete testis (10). The testicular artery originates from the abdominal aorta and continues retroperitoneally until it enters the inguinal canal via the deep inguinal ring and joins the spermatic cord. The pampiniform venous plexus, is a venous mesh that surrounds the testicular artery within the spermatic cord. It represents another heat regulatory mechanism, next to the cremasteric and dartos muscles. Superiorly the plexus veins fuse together and form the right- and left testicular vein. The right testicular vein connects to the inferior vena cava, whereas the left one joins the left renal vein (10,11).

The spinal segments Th 10 and Th 11 are responsible for the innervation of the testicles (4). The epididymis is located on top of the posterior aspect of the testicle. The duct of the epididymis forms the epididymis itself, by deflecting and bending many times to such a small extent, that it appears to be a compact structure. Efferent ductules connect the rete testis with the epididymis, which is crucial for the sperm transport. The epididymis is anatomically divided into head, body and tail. The latter one is continuous with the ductus deferens (10).

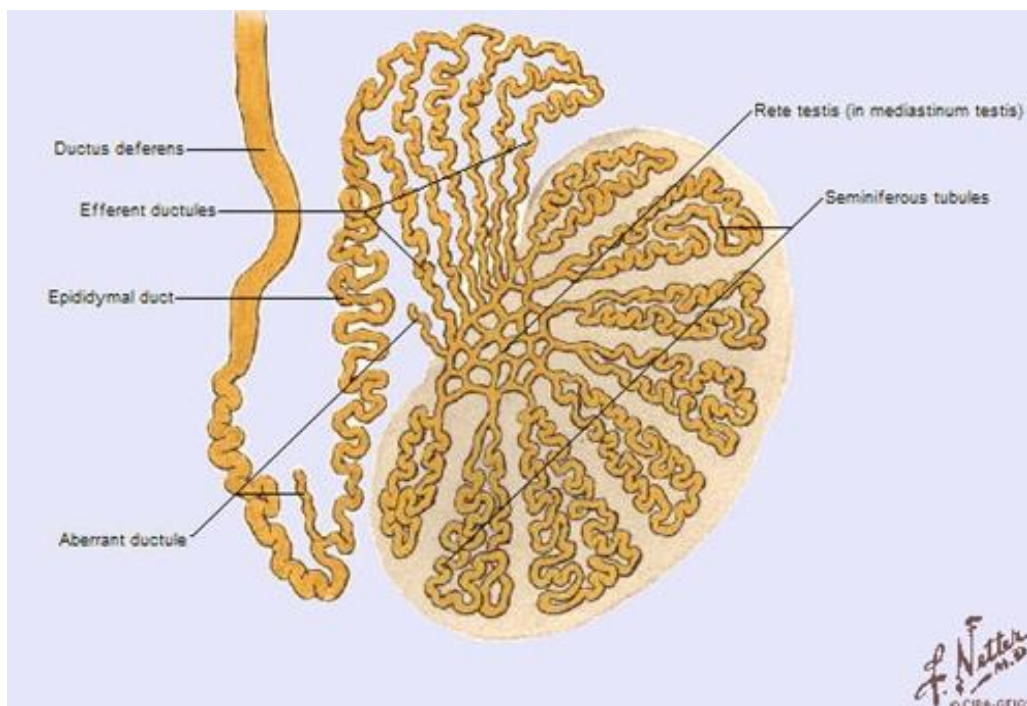


Figure 2. Schematic presentation of testis, epididymis and ductus deferens. Taken from „Interactive Atlas of Human Anatomy“ by Franck Netter.

1.3. TESTICULAR TORSION

1.3.1. HISTORY AND OVERVIEW

Chronicles of testicular torsion (TT) date back to the ancient Greece. According to a myth, young males sometimes got hit by a divine arrow, leading to scrotal pain and even loss of the testicle (12). The physician Delasiauve was the first one in history to publish a case of TT in 1840. Forty-one years later, Lanton characterized the first case of a twisted and fully descended testis. In 1893, Defontaine introduced the operative reduction of an intrascrotal torsion. The general differentiation into a more specified extravaginal torsion was established by Taylor in 1897. Until 1919, only 124 incidences had been documented, whereas between 1923 and 1930 the double amount of cases were reported, most likely due to the raised awareness of this condition (13). The long history of this urological state emphasizes its significance.

TT refers to the longitudinal rotation of spermatic cord structures and the resultant interfering with the ipsilateral blood supply of the testis (14). Posing a state of emergency, a diagnosis must be readily established and the surgical management must be initiated as soon as possible. An immediate salvage attempt to avert necrosis of the affected testicle, has a success rate of 90-100% within the first 6 hours, decreasing to 20-50% within 6-12 hours and even less than 10% past 12 hours (15,16).

TT can be subdivided into intravaginal testicular torsion (iTt) and extravaginal testicular torsion (eTT), which describe the condition in relation to the tunica vaginalis. The iTT is the most prevalent type (13). Twisting of anatomical elements intravaginally can take place at three different levels: Rotation of the intravaginal spermatic cord, distortion of the mesorchium between testis and epididymis and epididymal torsion in itself. Rotation of the intravaginal spermatic cord occurs commonly in the setting of the so-called bell-clapper deformity (Fig. 3b). Introduced by Muschat in 1931, this term describes a deformed connection between the tunica vaginalis and the testicle, causing a higher mobility of the testis and thereby higher probability of an iTT.

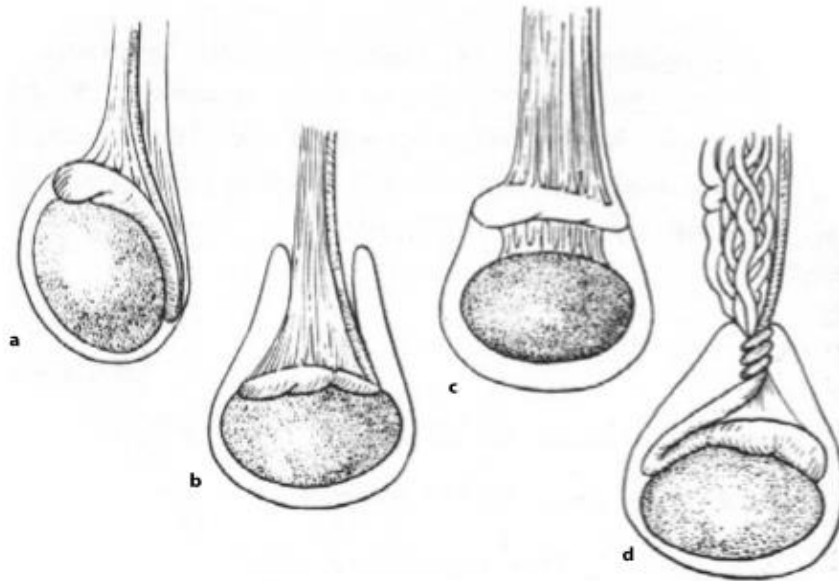


Figure 3. The anatomy of (a) normal attachments, (b) bell-clapper deformity, (c) abnormal mesorchium and (d) intravaginal torsion. Taken from Heyns CF, Visser AJ. *Andrology for the Clinician*.

The eTT denotes the twisting of the entire spermatic cord along with the processus vaginalis. The attachment of the posterior aspect of the testicle to the mesorchium takes place approximately 7-10 days after birth, hence eTT is predominantly an event in neonates (13,16). The chief complaints on examination are sudden onset of severe pain, nausea and vomiting, swelling of the scrotum, abdominal pain, fever and a possible high-riding testicle (17). A measurable cremasteric reflex suggests an epididymitis rather than a TT (16).

1.3.2. EPIDEMIOLOGY

TT is a well-known entity worldwide, representing around 10-15% of all acute scrotal pathologies in childhood. Although it may occur at any age, it is most common to appear in adolescent boys and has another incidence peak in the neonatal period. In the former, intravaginal torsion predominates whereas in the latter, extravaginal torsion is seen more often respectively (16,18). According to an US study, altogether 4.5 out of 100,000 males in the range of 1-25 years will have this condition (14,19).

Cryptorchidism is a quite common phenomenon at birth, with 2-8% (5,20). Whereas the frequency of this condition decreases to 1% in male infants between 6 months – 1 year of age (21).

Up to 42% of young males, who are surgically treated for TT, need to undergo an orchidectomy. Even if the blood flow is successfully restored, many suffer from altered semen parameters and decreased fertility (16).

1.3.3. RISK FACTORS

The anatomical bell-clapper deformity is with 90% of all presenting cases of TT the most influential predisposition (22). It is estimated that around 12% of the male population inherits this structural abnormality. Since not all children, affected by the bell-clapper deformity, develop TT and TT may occur even in the absence of the former mentioned deformity, other triggering factors also play an important role in the pathogenesis of this condition. The action of the cremasteric muscle is believed to be an important initiating force either way. Cremasteric muscular spasm can be provoked by cold weather, trauma or sports. Nocturnal erections can also elicit TT during the sleeping phase, by triggering the cremasteric reflex. Additionally, the testes enlarge comparatively to the spermatic cord at the age of 12-18 years and thereby increase the risk of developing TT (3,13).

In the setting of torsion in the inguinal region, besides the premise of cryptorchidism and its own risk factors, it has been reported that neuromuscular disorders can lead to abnormal cremasteric muscle contractions, which in turn may contribute to TT (23).

1.3.4. CLINICAL PRESENTATION

The usual course of TT includes the sudden onset of sharp scrotal pain, which can be accompanied by nausea and vomiting. In regard to the age, affected children normally will inform their parents or caregivers about the continuous bothering pain. Since it is a progressive process, additional symptoms as the following tend to appear: Scrotal erythema, scrotal edema (Fig. 4), testicular induration, raised horizontal testicle position, absence of ipsilateral cremasteric reflex, abdominal pain, groin pain and fever (15,18).

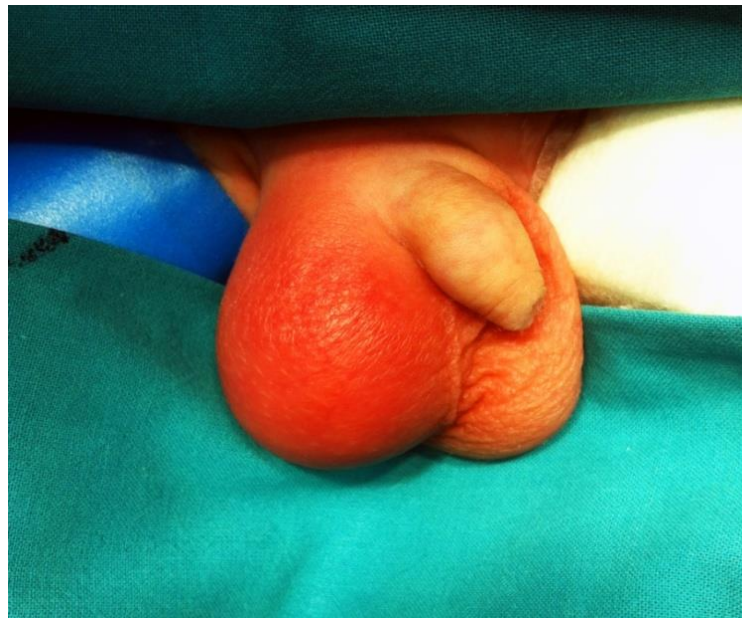


Figure 4. Characteristic clinical presentation of an acute scrotum: Red indurated and edematous scrotum. (Personal archive of mentor)

1.3.5. DIFFERENTIAL DIAGNOSIS

Acute scrotal conditions are widespread urological emergencies. Recognizing TT and being able to differentiate it from the remaining possible conditions, is of major importance. Differential diagnosis of the most common acute scrotal conditions includes the following: Epididymitis, twisting of testicular appendage, spermatic cord torsion, hydrocele, scrotal edema, idiopathic edema, trauma, incarcerated hernia and testicular tumor (15). Differential diagnosis of acute scrotum is presented in Table 1.

Table 1. Differential diagnosis of acute scrotum.

<i>Diagnosis</i>	<i>Clinical clues</i>
Epididymo-orchitis	Altered genitourinary structure or function Recent viral illness
Hematologic disorders	Abnormal laboratory values Diffusely hard testicle (in leukemia or lymphoma)
Idiopathic scrotal edema	No sign or symptoms of infection Swelling of overlying scrotal skin
Infection	Abnormal urinalysis Altered genitourinary anatomy Epididymal or testicular tenderness Fever
Inguinal hernia or hydrocele	Fluctuation of swelling or mass throughout day or with activity
Torsion of the appendix, testicle or appendix epididymis	Blue dot sign Tenderness over the head of the testicle or epididymis
Torsion of the spermatic cord	Absent or decreased blood flow on ultrasonography High-riding testicle Nausea, vomiting, or both Palpable twist in cord Sudden onset of symptoms
Trauma	Ecchymosis History of trauma or mechanism of injury
Tumor	Elevated tumor markers or abnormal laboratory test results Hard mass within testicle Systemic symptoms (if metastatic)
Varicocele	Dull, aching pain Fluctuation of swelling or pain throughout day or with activity

1.3.6. DIAGNOSIS AND MANAGEMENT

The first step to diagnose TT is a thorough history and physical examination. If these investigations strongly support the suspicion for TT, a direct surgical exploration is indicated. The physician in charge should not prolong the process with time-consuming imaging methods. Obscure findings on the presentation however, can be reassured by using the Doppler ultrasonography, which has a sensitivity of 89.9% and a specificity of 98.8% with a 1% false-negative rate in TT (16,18). Showing the nonexistent testicular blood-flow with the Color Doppler method, approves an exploratory surgery (16). An evaluation algorithm of a patient with an acute scrotum is shown in Fig. 5.

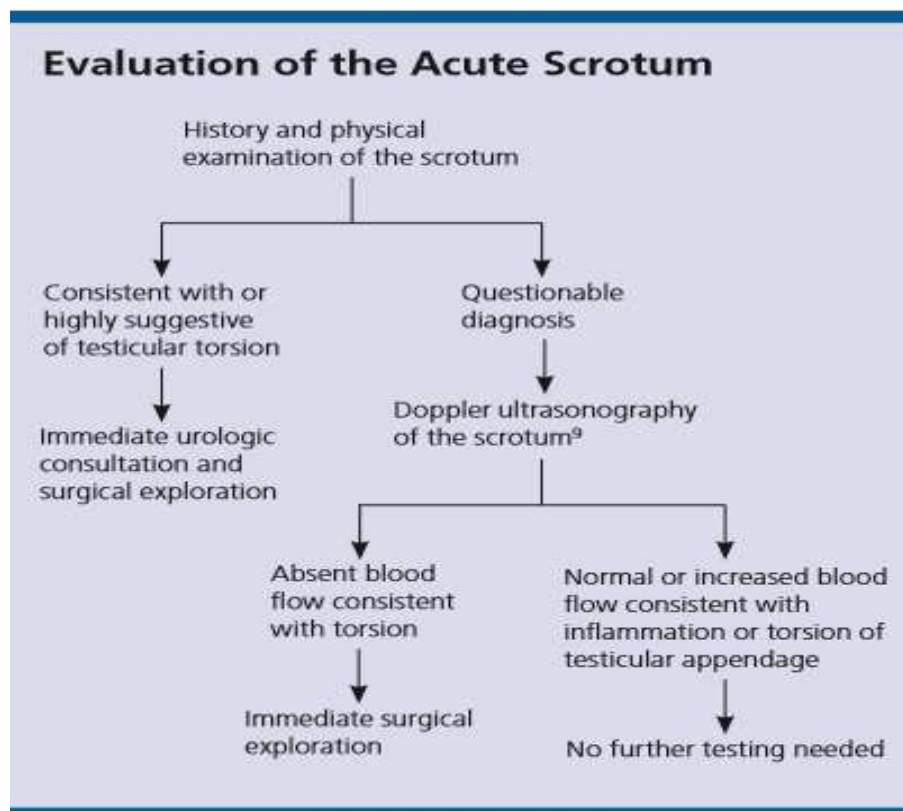


Figure 5. Algorithm for evaluating acute scrotal pain. Taken from Am Fam Physician. 2013;88(12):835-40.

At times, due to prevailing circumstances, it might happen, that the essential operation cannot be performed immediately. In this situation, manual detorsion and cooling of the scrotum with ice is justified. However, those procedures must not be considered as substitutions, but more as bridging interventions, until an operation theatre is available (16).

Current diagnostic methods are non-specific, time consuming, and not always available, resulting in loss of diagnostic time. Additionally, blood samples are routinely obtained in patients with an acute scrotum. During infection or tissue injury, the elevated white blood cell count (WBC), C-reactive protein (CRP) and erythrocyte sedimentation rate (ESR) are accompanied by alteration in the concentrations of several serum proteins. These markers may be helpful in differentiation of inflammatory from non-inflammatory causes of acute scrotum (24).

The use of analgetics for a manual detorsion is controversially described in literature. On the one hand, its effect will relax the cremasteric muscle and possibly ease the detorsion, while on the other hand, it might mask the pain relief due to the effective removal of the blood blockade, which in turn is an important indicator for a successful procedure (13,16).

A surgical exploration has two different possible outcomes. When the affected testicle is untwisted by the surgeon and shows signs of viability (Fig. 6a), a bilateral orchiopexy is made. If the testis is adjudged to be necrotic (Fig. 6b), an orchidectomy is necessary, as well as an orchiopexy on the contralateral healthy testicle. The latter one is performed prophylactically, to avoid possible TT development on the other side as well (16,18).

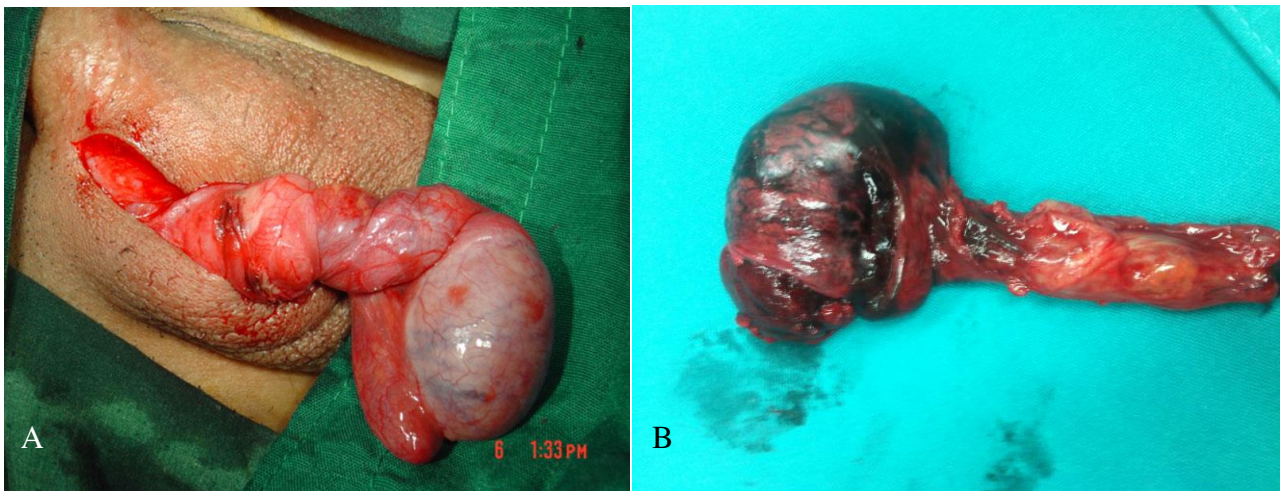


Figure 6. Intraoperative findings of TT. A) vital testis, torsion degree 270°; B) gangrenous testis, torsion degree 540°.

As previously mentioned, iTT is the most prevalent type and associated with the bell-clapper deformity. A diagnosed TT is always presumed to be bilateral since the bell-clapper deformity occurs on both sides in 66% of cases (13,16).

If it turns out to be an eTT during a procedure, a contralateral orchiopexy is still advised by literature, because of the unknown etiology of the condition (16). The algorithm for the intraoperatively decision making is shown in Fig. 7.

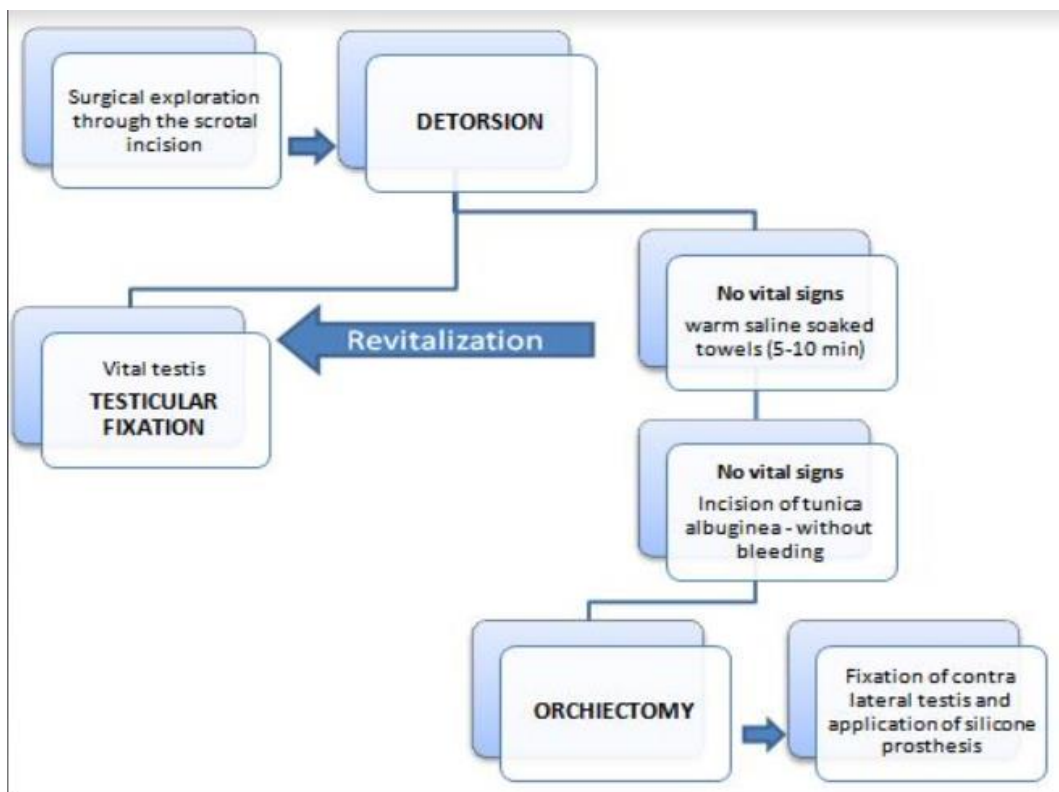


Figure 7. Management of acute scrotum at the Department of pediatric surgery in University Hospital of Split.

Children normally do not need further monitoring, apart from the standard surveillance in the recovery room. Patients operated for TT commonly recover quickly, but should receive control checkups as outpatients for several weeks. During those inspections, optional a prosthesis can be addressed and planned with the legal guardians and the patient. It should be mentioned that TT may reappear, aside from the previous testicular fixation (14,18).

1.3.7. AN UNUSUAL PRESENTATION OF TESTICULAR TORSION

Considering TT and its typical presentation, the correct and fast diagnosis should be a matter of routine. The scrotal pain guides the physician's concern clearly towards the etiological genital area. Thereupon immediately the next steps, for evaluating the condition and planning the treatment, can be initiated. However, children may possibly present without the indicative scrotal pain and may show different inconspicuous symptoms (14,15). The potential variable presentation is a distinctive feature of TT.

An important potential presentation of children with TT, which needs to be highlighted, is the initial lower abdominal pain and/or inguinal pain pathology. This occurs especially in the early stages of the condition. In that case, the pain is characterized by shifting towards the scrotal area a few hours after the onset. Before this typical pain migration, valuable time tends to be wasted by not considering TT as a possible diagnosis. Lower abdominal pain is a symptom with an extensive list of possible differential diagnosis. Thus TT can mimic abdominal conditions, like appendicitis and hence delay or even misguide the accurate diagnosis. This often results in diminished chances to salvage the affected testicle and to prevent an orchiectomy (15).

A different unusual variant of TT can occur in the setting of cryptorchidism. The term cryptorchidism refers to the undescended testis, that did not migrate into the scrotum. It is a multifactorial process, which is yet not fully understood. Usually, after 23 weeks of gestation the testicular descent is supported by the development of the gubernaculum, processus vaginalis, spermatic vessels and scrotum (18). Testicles sometimes tend to only complete the descending process within the first year of life. Hence it is common to wait until the boy reaches the age of 1 year, before initiating any steps regarding the undescended testis. The incidence of cryptorchidism at 1 year of age decreases to 1%. A still undescended testis at this age indicates an orchiopexy (25). If the testicle fails to reach its destined position in the scrotum, it can lead to various unfortunate sequelae. The increased temperature can lead to infertility. Also testicular tumors are more likely to occur and it is frequently connected with the development of hernias (5,19-22). Risk factors for cryptorchidism are associated with genetic predisposition, placental insufficiency and exposure to specific endocrine disrupting substances (26). Scientific literature about cryptorchidism is often primarily focused on the issue of the higher risks of infertility, although the risk of TT is as well a quite possible resultant complication. The incidence of TT in the setting of cryptorchidism is approximately

10 times higher (27). The maldescended testicle can be described as abdominal, inguinal or subinguinal, according to its position. The inguinal position is the most frequent one with 75% (16). The exact mechanism behind torsion in the inguinal region is not completely understood. The relatively broad testicle in comparison to its mesentery might be a crucial factor (21). The most common age for inguinal TT is around the age of 1 year.

TT in the inguinal canal can have a different symptomatic, compared to the typical TT and might resemble some abdominal pathologies (25). TT can also occur on both sides and hence carries a high risk of hypogonadism. Bilateral torsion accounts for 2% of all cases (14). In the case of a suspected bilateral perinatal TT, an early bilateral exploration is crucial (28). Immediate surgical exploration is always indicated in the case of a TT, regardless of the location of the testicle (23,29). The basic principles of detorsion, checking for viability of the testis, performance of whether an orchiopexy or an orchidectomy, are the same for the different presenting types of TT. An example of a clinically evident and pathohistologically confirmed necrotic testicle is shown in Fig. 8.

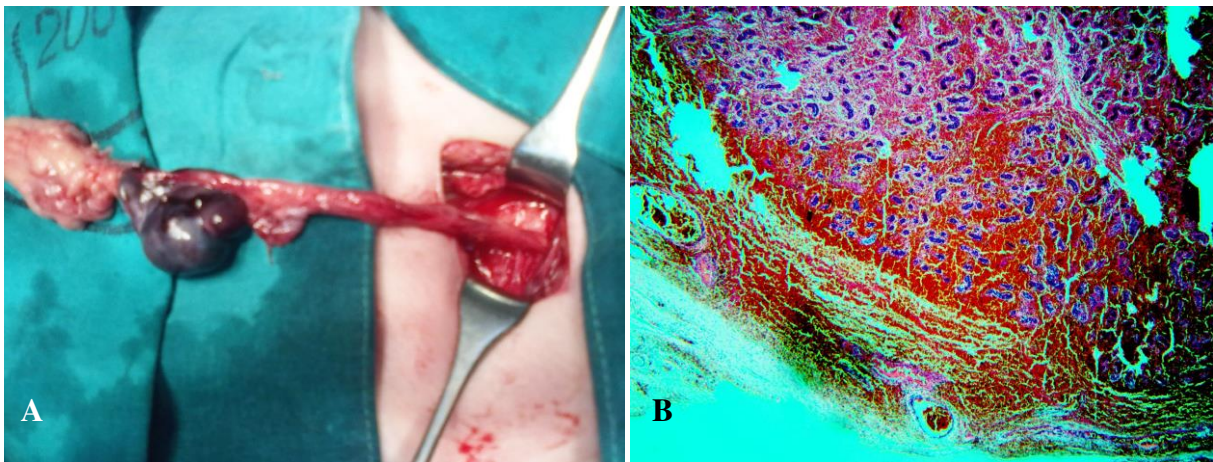


Figure 8. TT in the inguinal canal. A) intraoperative findings – necrotic testicle B) pathohistology of a gangrenous testicle. (Personal archive of mentor)

2. OBJECTIVES OF RESEARCH

The aim of this study is to identify and highlight unusual presentations of the TT and to clarify their peculiarities, by showing demographic and clinical characteristics of patients, who were operated for TT.

The focus lies on two studied groups, one including patients with only abdominal pain as the presenting symptom, while the other is composed of patients with TT in the inguinal canal. In both cases, it is a rather difficult diagnosis, because of the misleading and rare symptom(s) which are considered unusual.

3. MATERIAL AND METHODS

3.1. PATIENTS

In the time period from January 1999 until December 2017, the case records of 149 pediatric patients, who underwent surgery for TT, were retrospectively reviewed.

Inclusion criteria:

1. Male patients, 0-17 years of age
2. Patients presented with abdominal pain as the only symptom of TT
3. Patients presented with TT in inguinal canal

Exclusion criteria:

1. Patients older than 17 years of age
2. Patients operated in another institutions, and followed-up at our outpatient clinic
3. Patients with typical presentation of TT
4. Patients with incomplete data, or that have been followed-up less than three months

3.2. ORGANIZATION OF THE STUDY

The study was carried out as a cross sectional study by corresponding qualitative research and descriptively processed data.

3.3. PLACE OF THE STUDY

The research took place at the Department of Pediatric Surgery in the University Hospital of Split, Croatia.

3.4. METHODS OF DATA COLLECTION AND PROCESSING

The corresponding data was obtained by revising the written protocols and records. The Software used for processing the collected data was Microsoft Word and Microsoft Excel.

3.5. DESCRIPTION OF RESEARCH

The patients were divided into 2 distinct groups. The set criteria for one group was the presentation with abdominal pain and without the classical, pinpointing towards TT, scrotal pain. The other group includes all boys with TT in the inguinal region. The respective medical records contained informations for the majority of the patients, about the physical examination, medical history, ultrasound, intraoperative reports, outcome and long-term consequences. Those case reports were reviewed in a retrospective manner. The parameters in the focus of this research were: age, presenting symptoms, physical examination, lateralization, degree of torsion, outcome of treatment and complications.

3.6. TREATMENT AND FOLLOW-UP

TT was assessed by physical examination. The confirmation of this condition was made by the Doppler ultrasound method and scrotal exploration. Results of the Doppler ultrasound investigations are not listed, because this diagnostic tool was utilized only in the recent years. The arrangements for the emergency exploratory surgery were immediately initiated and carried out. After successful anesthesia, the affected hemiscrotum was incised horizontally and explored. The next step was an instant manual detorsion. If the testicle showed signs of viability, an orchiopexy was subsequently performed. In the case of a shady and darker appearance of the testis, the testicle was enveloped into warm saline-soaked compresses, for a minimum of 5 minutes. Possible changes of the colour of the testicle were observed. If no improvement was detectable, the surgeon performed an incision into the tunica albuginea of the testis, to check for further signs of possible viability. The absence of bright bleeding was considered as an indicator to chose an orchiectomy.

The removed testicles were send to the pathology department, where the necrotic state of the organ was confirmed. Regular checkups after the operation were made in the time span of 14, 30, 90 and 365 days and subsequently once a year. Additional to the exploratory surgery, a few months following the operation, an implantation of a silicone prosthesis was carried out in most of the cases.

4. RESULTS

In the selected period of the study, 149 patients with the median age of 14 years, underwent surgery for TT. The left testicle was more often affected. Out of those 149 children, 25 patients were included in the study (14 patients who presented with abdominal pain only, and 11 who presented with testicular torsion in the inguinal canal).

The symptoms of the 149 patients, who underwent surgery for TT, varied from pain and tenderness to groin pain and elevated temperature. Since almost all patients had more than one symptom, note that Figures 9 a, b and c only list each symptom isolated, without taking the different combinations or time of occurrence into consideration. The most common presenting clinical symptoms were scrotal edema, scrotal pain/tenderness and an absent cremasteric reflex with an occurrence of around 87%, 85% and 82%, respectively (Table 2. Abdominal pain, groin pain and elevated temperature (>37°C) represent with 19%, 7% and 5%, the least common symptoms (Fig. 9a). The symptoms distribution in the inguinal TT group shows clearly, that in those 11 children abdominal pain (90.9%) predominated, followed by groin pain (45.45%) and nausea (45.45%) (Fig. 9b).

In the abdominal pain group, evidently abdominal pain (100%) is the symptom of focus and was accompanied by groin pain (42.83%) and nausea (50%) in around half of the cases (Fig. 9c).

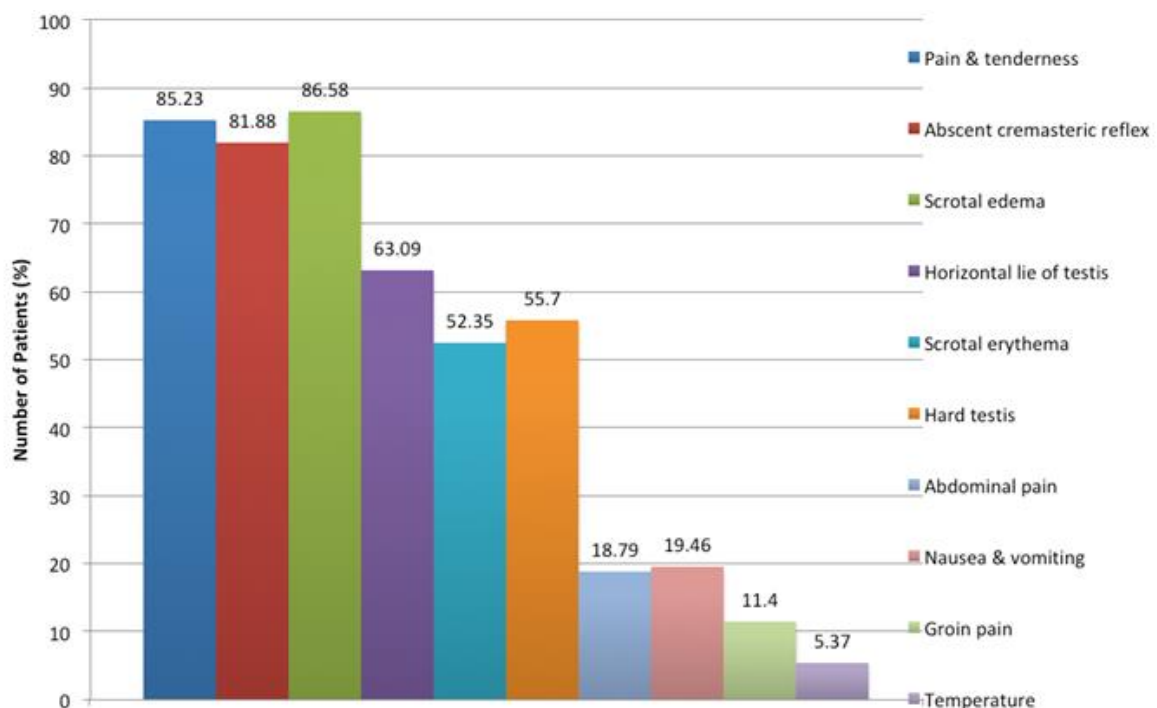


Figure 9a. Distribution of symptoms of all patients with TT (n=149)

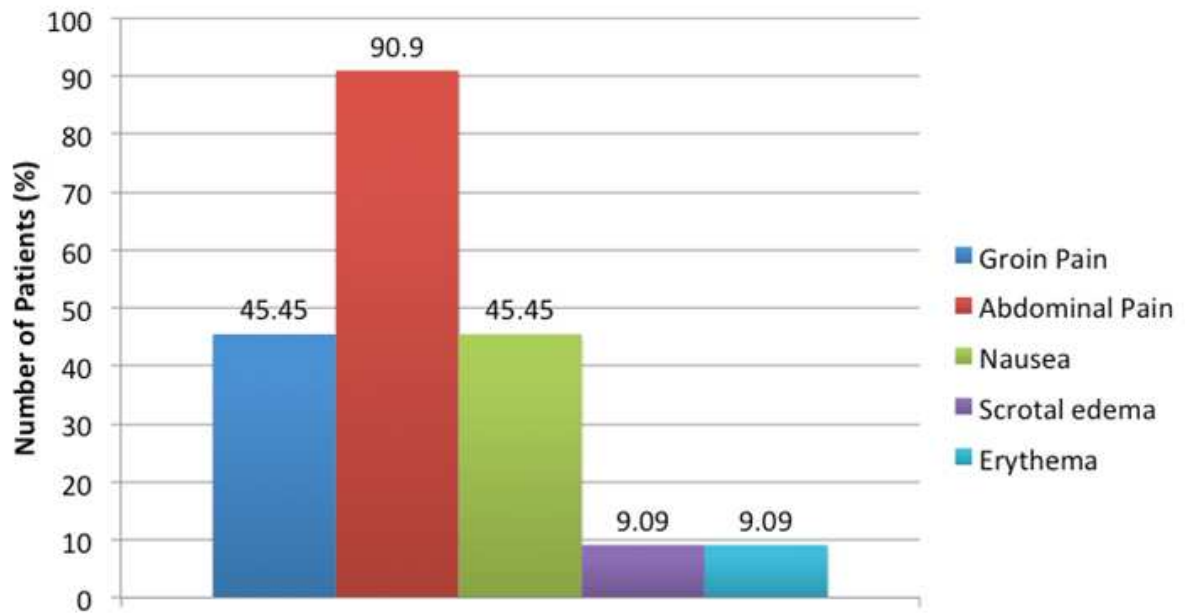


Figure 9b. Distribution of symptoms of patients with inguinal TT (n=11)

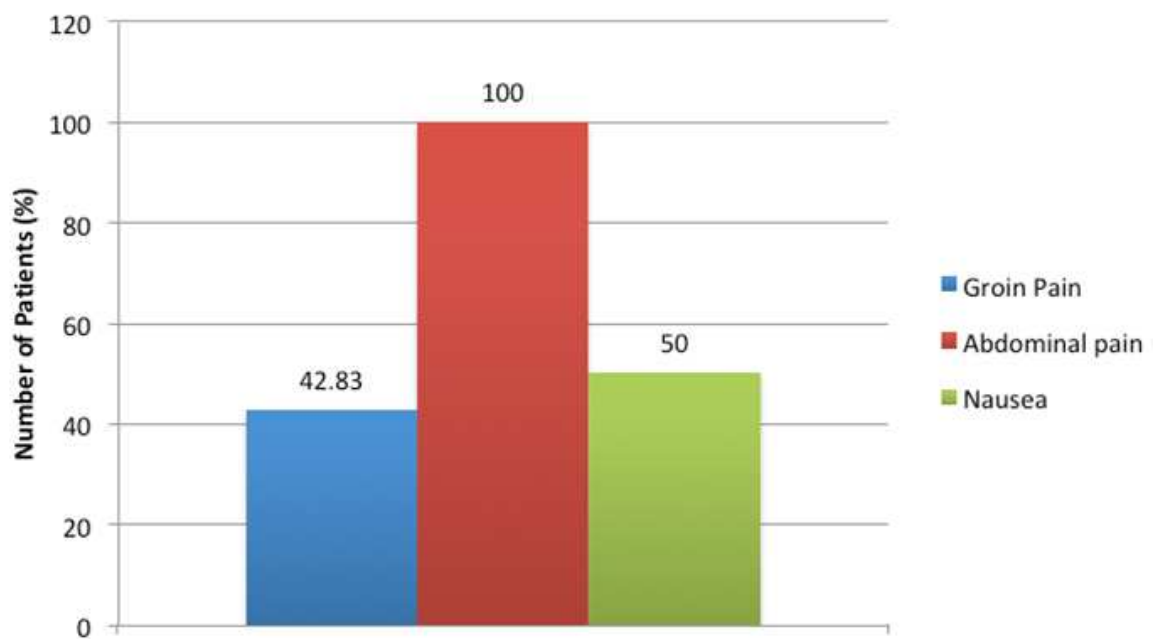


Figure 9c. Distribution of symptoms of patients with TT and predominantly abdominal pain (n=14)

Table 2 shows an overview of the demographic data, clinical data and treatment outcome in all patients with TT, as well as in patients with an inguinal torsion and in those presenting with abdominal pain only. The median age of all children with TT (n=149) at the moment of surgery was 14 years (range 0 days- 17 years). Eleven boys (7.38%) out of the total number of patients, turned out to have a testicular torsion within the inguinal canal and 14 (9.39%) children presented with abdominal pain only. Within all participants, the left side was affected in 56% (n=84) of the cases, as opposed to the right side, which was affected in 44% (n=65) of cases. In the boys with inguinal TT and in those presenting with abdominal pain, the right side was in both groups more often affected. The duration of the symptoms varied substantially and ranged from 1 hour to 120 hours with a median of 6 hours, with only 63 out of 149 patients staying below the golden 6 hours. In the two studied subgroups, the duration was even longer, with a respective median for the inguinal TT group of 24 hours (range 3-60 h) and for the abdominal pain group of 17 hours (range 3-72 h). In the majority of the cases (69.8%) a detorsion and fixation was performed, whereas in 45/149 patients an orchidectomy was necessary. In the other two subgroups however, more than half of the patients needed an orchidectomy. The orchidectomy was performed in the inguinal TT group in 54.54% and in the abdominal group in 57.14% of the cases.

Table 2. Characteristics, operative findings and outcome of all patients with TT.

Patient characteristics	Testicular torsion (n=149)	Inguinal torsion (n=11)	Abdominal pain (n=14)
Demographic data			
Age, median (range)	14 (0-17)	13 (0-16)	13 (3-17)
Lateralization			
Left, n (%)	84 (56)	5 (45.45)	5 (36)
Right, n (%)	65 (44)	6 (54.54)	9 (64)
Clinical data			
Symptom duration (h), median (range)	6 (1-120)	24 (3-60)	17 (3-72)
<6 h, n (%)	63 (42.28)	2 (18.18)	5 (35.71)
6-12 h, n (%)	35 (23.48)	2 (18.18)	/
12-24 h, n (%)	18 (12.08)	2 (18.18)	5 (35.71)
24-72 h, n (%)	26 (17.44)	5 (45.45)	4 (28.57)
>72 h, n (%)	7 (4.69)	/	/
Scrotal pain, n (%)	127 (85.23)	/	/
Scrotal edema, n (%)	129 (86.58)	1 (9.09)	/
Scrotal erythema, n (%)	78 (52.35)	1 (9.09)	/
Nausea, n (%)	29 (19.46)	5 (45.45)	7 (50)
Groin pain, n (%)	17 (11.4)	5 (45.45)	6 (42.83)
Absent cremasteric reflex, n (%)	122 (81.88)	/	/
Hard testis, n (%)	83 (55.7)	/	/
Horizontal testis, n (%)	94 (63.09)	/	/
Abdominal pain, n (%)	28 (18.79)	10 (90.9)	14 (100)
Torsion degree, median (range)	360 (90 - 1080)	360 (180 - 720)	360 (180 - 720)
Treatment outcomes			
Operational procedure			
Detorsion and fixation, n (%)	104 (69.8)	5 (45.45)	6 (42.86)
Orchidectomy, n (%)	45 (30.2)	6 (54.54)	8 (57.14)
Complications, n (%)	2 (1.34)	/	1 (7.14)

A more extensive list about the characteristic findings about the group of the 11 patients with the inguinal TT is shown in Table 3. The age distribution ranged from 0 to 16 years with a mean age of 8.81 years. In 6 cases, the affected side was the right one. The mean duration of symptoms in the inguinal group was 27.81 h (range 3-60 h). In 2/11 (18.18%) cases the patients presented within 6 h. The symptoms were mostly limited to abdominal pain and groin pain, but also scrotal erythema, edema and nausea was reported (Fig. 9b). In 6 out of 11 children, the first physical examination didn't include a genital examination. In five cases, where the patients directly received a genital examination, the first examination was carried out four times by physicians, who are specialized in the pediatric field and one time by general practitioners. After the referral in all cases to whether a pediatrician or a pediatric surgeon, the second physical examination always included a genital evaluation. In the second evaluation the condition of TT in the inguinal canal was recognized in all 6 cases. In 6/11 cases an orchidectomy was performed, because testicular gangrene was found intraoperatively (Fig. 10). The follow up showed a successful outcome and no complications. All children with detorsed and fixed testicle reported no pain or any other noticeable problems.

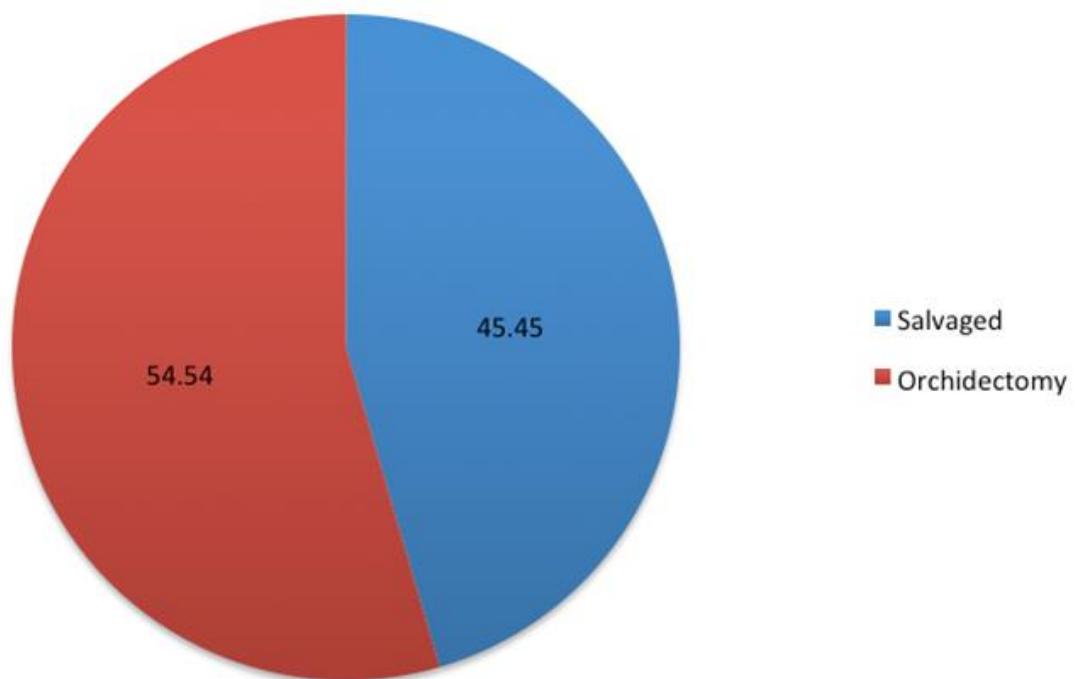


Figure 10. Clinical outcome in patients with inguinal TT (n=11).

Table 3. Patient characteristics, operative findings and outcome in group of patients presenting with torsion in the inguinal canal (n = 11).

Patient	Age	Side	Duration of symptoms (h)	Presenting symptoms	Genital examination				Intraoperative findings	Degree of TT	Outcome
					1st examination		2nd examination				
					Genital examination	Testicular torsion Recognized – YES/NO	Genital examination	Testicular torsion Recognized – YES/NO			
1	14	L	56	Groin pain, scrotal edema, erythema, nausea	NO	NO (ER physician)	YES	YES (pediatric surgeon)	Testicular gangrene	360°	Orchidectomy
2	13	R	5	Abdominal pain, groin pain	YES	YES (pediatrician)	-	-	Inguinal torsion	720°	Salvaged
3	15	L	60	Abdominal pain, nausea	NO	NO (pediatrician)	YES	YES (pediatric surgeon)	Testicular gangrene	360°	Orchidectomy
4	16	R	4	Abdominal pain	YES	YES (ER physician)	-	-	Testicular gangrene	360°	Salvaged
5	15	R	6	Abdominal pain, groin pain, nausea	YES	YES (pediatric surgeon)	-	-	Testicular torsion	270°	Salvaged
6	1	L	36	Abdominal pain	NO	NO (ER physician)	YES	YES (pediatrician)	Testicular gangrene	360°	Orchidectomy
7	0	R	16	Abdominal pain, groin pain, nausea	YES	YES (pediatrician)	-	-	Testicular gangrene	180°	Salvaged
8	9	R	48	Abdominal pain	NO	NO (ER physician)	YES	YES (pediatrician)	Testicular gangrene	360°	Orchidectomy
9	13	L	3	Abdominal pain	YES	YES (pediatrician)	-	-	Testicular torsion	360°	Salvaged
10	1	L	48	Abdominal pain, nausea	NO	NO (pediatrician)	YES	YES (pediatrician)	Testicular gangrene	360°	Orchidectomy
11	0	L	24	Abdominal pain, groin pain	NO	NO (ER physician)	YES	YES (pediatric surgeon)	Testicular gangrene	360°	Orchidectomy

Table 4 shows 14 selected patients out of the 149 children with TT. The main symptom and also including criteria for this group, was the abdominal pain (n = 14, 100%), often combined with groin pain and vomiting, but no classical TT signs, like scrotal edema and scrotal tenderness.

The age was in the range of 3-17 years with a mean of 12.78 years. The right testicle was affected in 9 cases (64%) and the left one in 5 (36%). In 9 out of 14 children, the first physical examination didn't include a genital examination. In those 5 cases, where the patients directly received a genital examination, the first examination was carried out three times by physicians, who are specialized in the pediatric field and two times by general practitioners. After the referral in all cases to whether a pediatrician or a pediatric surgeon, the second physical examination always included a genital evaluation. In the second evaluation, the condition of TT was recognized in all 9 cases. The mean duration of the symptoms in the observed group was 20.07 h (range 3-72 h). In 5/14 (35.71%) cases the children presented within 6h. Out of these 14 operated boys, the testicles of 6 (42.86%) were salvaged and in 8 (57.14%) cases, an orchidectomy was performed because of gangrene of the testis (Fig. 11). The follow up showed a successful outcome and no complications, except one reported wound infection. All children with detorsed and fixed testicle reported no pain or any other noticeable problems.

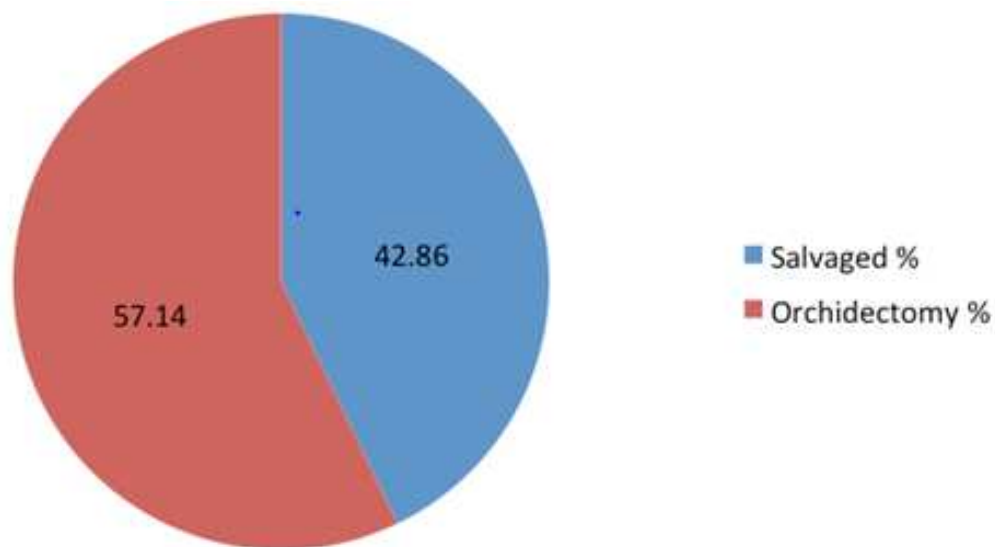


Figure 11. Clinical outcome in patients with abdominal pain (n=14).

Table 4. Patient characteristics, operative findings and outcome in group of patients presenting with abdominal pain (n = 14)

Patient	Age	Side	Duration of symptoms (h)	Presenting symptoms	Genital examination				Intraoperative findings	Degree of TT	Outcome
					1st examination		2nd examination				
					Genital examination	Testicular torsion Recognized – YES/NO	Genital examination	Testicular torsion Recognized – YES/NO			
1	14	R	3	Abdominal pain, nausea	YES	YES (pediatrician)	-	-	Testicular torsion	720°	Salvaged
2	13	R	5	Abdominal pain, groin pain	NO	NO (ER physician)	YES	YES (pediatric surgeon)	Inguinal torsion	720°	Salvaged
3	9	L	18	Abdominal pain, nausea	NO	NO (GP)	YES	YES (pediatric surgeon)	Testicular gangrene	360°	Orchidectomy
4	16	L	36	Abdominal pain	NO	NO (GP)	YES	YES (pediatrician)	Testicular gangrene	360°	Orchidectomy
5	12	R	3	Abdominal pain, groin pain, nausea	YES	YES (pediatrician)	-	-	Testicular torsion	360°	Salvaged
6	13	L	24	Abdominal pain	NO	NO (resident of surgery)	YES	YES (pediatric surgeon)	Testicular gangrene	360°	Orchidectomy
7	16	R	48	Abdominal pain, groin pain, nausea	NO	NO (ER physician)	YES	YES (pediatric surgeon)	Testicular gangrene	270°	Orchidectomy
8	3	R	72	Abdominal pain	NO	NO (pediatrician)	YES	YES (pediatric surgeon)	Testicular gangrene	720°	Orchidectomy
9	17	L	4	Abdominal pain	YES	YES (GP)	-	-	Testicular torsion	360°	Salvaged
10	17	R	16	Abdominal pain, nausea	NO	NO (pediatrician)	YES	YES (pediatrician)	Testicular gangrene	540°	Orchidectomy
11	12	R	10	Abdominal pain, groin pain	YES	YES (pediatric surgeon)	-	-	Testicular gangrene	180°	Salvaged
12	13	R	5	Abdominal pain	YES	YES (GP)	-	-	Testicular torsion	180°	Salvaged
13	12	R	18	Abdominal pain, groin pain, nausea	NO	NO (ER physician)	YES	YES (pediatric surgeon)	Testicular gangrene	360°	Orchidectomy
14	12	L	19	Abdominal pain, groin pain, nausea	NO	NO (GP)	YES	YES (pediatric surgeon)	Testicular gangrene	720°	Orchidectomy

5. DISCUSSION

Children represent a very challenging group of patients, especially in the case of emergency. Time is an important factor and the communication, needed for a thorough anamnesis, is often not, or only partially possible.

TT is a pediatric emergency that most commonly occurs during puberty, but may be seen at any age. The child usually presents after a sudden onset of pain in the scrotal area with an edematous, painful on touch and indurated testicle, often lying in a horizontal position (15). The treatment consists of an attempt to surgically explore the area and reestablish the inhibited blood flow. Then the following step depends on the viability of the testis, whether it is still vital and can be put back into a fixed position or an orchidectomy is necessary (16). A salvage attempt within 6 hours has a success rate of 90-100%, strongly successively decreasing after that time frame. Accordingly to 25-65% within 6-12 h and to 0-24% within 12-24 h (14-16). Thus the outcome is time depended. There are two essential time frames, where valuable time tends to get lost. The first one is the duration of the symptoms, until the child indicates the problem and manages to present to the emergency room. The second window, is the time the responsible physician needs to make the accurate diagnosis and initiate the treatment. So to speak, until finally the inhibited blood supply gets reversed. Atrophy of the testicle is an unpreventable event, if the pain lasted more than 8h (14,15). In general, approximately 32% of the children with TT receive an orchidectomy (14,21).

In 104 (69.8%) out of the 149 (100%) patients in our study, the surgeons were able to salvage the affected testicle. The duration of the symptoms ranged from 1-120 h and 63 (42.28%) patients presented within 6 hours.

Torsion of the testicle in the inguinal canal is a rare event and infrequently reported. Candocia *et al.* mention in their case report, the increased incidence of TT, in the setting of boys with maldescended testis in the association with spastic neuromuscular disorders (23). Cryptorchidism can be subdivided into inguinal, subinguinal or abdominal, dependent on the position of the testicle. The testis is found in 75% within the inguinal canal. Nonetheless, TT in the inguinal canal itself is quite unusual (25,28,30). The phenomenon of an undescended testis is present in 3.5% of full-term infants, but decreases to 1% at the age of 1 year, because of its self-resolving and often just delayed nature (20,23). Following those data, TT in the inguinal canal is expected to peak at the age of 1 year, even though the mean age in our study is 8.81 years. A possible explanation is, that the condition of cryptorchidism was not recognized before, because those patients were mostly from rural areas and did not visit any medical institution.

The case of a 14-months-old boy, who refused weight bearing on his left leg, turned out to be a testicular torsion in the inguinal canal. This report exemplifies the possible obscurity of that condition (31). The symptoms of an inguinal torsion can resemble an appendicitis or other similar conditions, connected to the umbrella term – acute abdomen (30-32).

The goal of the treatment of torsion in the inguinal canal is a testicular preserving orchiopexy, if the testis is still viable. In a study, carried out by Zilberman *et al.*, 5/11 boys received an orchidectomy (32). In general, the few available studies and case reports containing the topic of TT and undescended testis state, that the correct diagnosis is frequently delayed and the resultant orchidectomy often necessary (23,30,33,34).

In our study, 11 (7.38%) children, out of the total number of patients, had an inguinal TT. In 6/11 children with inguinal TT, the outcome was an orchidectomy. The mean duration of symptoms in the inguinal group was 27.81 h (range 3-60 h). Only 2 patients presented within the first 6 h. Our data show that in 6/11 cases in the inguinal group, the first physical examination did not include a genital examination and thus the condition kept being undetected, until they were examined again. In most of the cases the first investigating physician was not a specialized pediatrician. Therefore the neglected genital examination could be a consequence of the inexperience of the physician. The second evaluation always included the genital examination and also always correctly diagnosed TT. Thus the genital evaluation represents a reliable method to diagnose TT.

Abdominal pain is a demanding symptom, with a broad spectrum of differential diagnosis. The possibilities range from a simple harmless condition to an acute state of emergency. Drawing the wrong conclusion might lead to serious consequences for the patient. Hence the physician, responsible for the first examination, is obligated to investigate the pathology behind the abdominal pain by any means. Performing a complete physical examination also implies an inspection of the genital area (6,35,36). The typical presentation of TT includes sudden onset of sharp testicular pain and scrotal swelling, which can be accompanied by additional features. The testicular innervation originates from Th 10 and Th 11. On the other hand, the anterior part of the scrotal area is innervated by L1 and the posterior one by S2/S3. So the anatomy can lead to various diffuse and misleading pain stimuli, that are sensed by the patient outside of the affected area (37). In the reported case of a boy with abdominal pain, the physician didn't perform a genital examination. In a second examination a pediatrician detected scrotal bruising and a tender testis. A surgery was immediately initiated, but the testis was already gangrenous and had to be removed (36). In

another case of two boys, with abdominal pain as the leading the symptom, the genital evaluation was neglected aswell. In both patients the intraoperative findings showed a non viable testis and they had to undergo an orchidectomy (37). A further example for the easily misdiagnosed TT, presenting with abdominal pain, is the report of a boy, who got wrongly diagnosed with appendicitis. Additional evaluations revealed an incomplete TT (38). Anderson *et al.* stated that 22% of their patients were troubled by abdominal pain, which frequently overshadowed the pain in the scrotal area. They also reported 3 cases of unnecessary appendectomies, due to the misconception of appendicitis, instead of the actual existing TT (39).

In New York an insurance company claimed, that TT is placed on the 4th position of common misdiagnosed conditions (40). TT is also the 3rd most common reason of accusations for medical malpractice against physicians (36).

In our study 11 patients with inguinal TT and 14 patients with TT, presenting with abdominal pain, represent 16.77% of the reviewed 149 patients in total. The mean duration of the symptoms in the observed abdominal group was 20.07 h (range 3-72 h), and 5/14 presented within the valuable 6 h. The duration of the symptoms is a well researched predictor for the outcome (27). In the abdominal pain group 8/14 children received an orchidectomy. Our results show, that no immediate genital examination was performed in 9 out of 14 cases, in the patients with abdominal pain, which possibly is due to the unfamiliar presentation. The inferior outcome of the groups with an unusual presentation, reflects the difficulties of the unacquainted characteristics of these uncommon cases.

The possible misleading presentation, the fact that children often have difficulties to properly express themselves, the narrow golden time window to resolve the situation – the conglomeration of those circumstances makes TT prone to false decisions and subsequent malpractice. The quintessence is to include the genital evaluation in the first physical examination in male children. The responsible physician simply needs the knowledge about the possible unusual presentations of TT, thus he can act accordingly.

Announcing and emphasizing informations about the different odd presentations of TT into the common medical knowledge, could improve the general outcome.

The main limitation of this study is its retrospective character. The medical records are prone to bias. Duration of the symptoms is a subjective information and can have significant inaccuracies. Statements from children depending on the age are disputably reliable. Thus it is possible that sometimes less symptoms were reported by the patients, than they actually had.

6. CONCLUSION

TT, particularly in regard to torsion in the inguinal canal or presenting dominantly with abdominal pain, can be easily missed, but needs to be recognized on time, to salvage the affected testicle. A high level of suspicion is required for the diagnosis of TT presenting in an unusual manner. TT presenting in an uncommon manner is very often misdiagnosed and often leads to orchidectomy. The intention of this study is to emphasize a possible presentation of TT, which is unexpected or out of the ordinary and furthermore to highlight the importance of a complete physical examination, including the genital evaluation.

7. REFERENCES

1. Moharit NH, Krahn HP. Acute scrotum in children with emphasis on torsion of spermatic cord. *J Urol.* 1970;104:610.
2. Knight PJ, Vassy LE. The diagnosis and treatment of the acute scrotum in children and adolescents. *Ann Surg.* 1984;200:664-73.
3. Župančić B. Akutni skrotum. *Paediatr Croat.* 1999;43:175-80.
4. Holcomb GW, Murphy JP. *Aschraft's pediatric surgery*, Philadelphia. Saunders Elsevier; 2010.
5. Virtanen HE, Toppari J. Epidemiology and pathogenesis of cryptorchidism. *Hum Reprod.* 2008;14:49-58.
6. Mäkelä E, Lahdes-Vasama T, Rajakorpi H, Wikström. A 19-year review of paediatric patients with acute scrotum. *Scand J Surg.* 2007;96:62-6.
7. Cavusoglu YH, Karaman A, Erdogan D, Aslan MK, Varlikli O, Cakmak O. Acute scrotum- Etiology and management. *Indian J Pediatr.* 2005;72:201-3.
8. Jefferson RH, Pérez LM, Joseph DB. Critical analysis of the clinical presentation of acute scrotum: A 9-year experience at a single institution. *J Urol.* 1997;158:1198-200.
9. Bunce PL. *Scrotal abnormalities. Urologic surgery.* Hagerstown: Harper&Row; 1975.
10. Moore KL. *Clinically oriented anatomy.* 6th ed. Philadelphia: Lippincott Williams & Wilkins; 2009.
11. Schiebler TH. *Anatomie.* 9th ed. Berlin: Springer; 2004.
12. Ross SS, Ruhston HG. Testicular Torsion. In: Rabinowitz R, Hulbert W, Mevorach R, editors. *Pediatric Urology for the Primary Care Physician.* New York: Humana Press; 2014. p. 175-81.
13. Heyns CF, Visser AJ. Problem: Emergencies in Andrology. In: Schiller WB, Comhaire FH, editors. *Andrology for the Clinician.* Berlin, Heidelberg, New York: Springer-Verlag; 2006. p. 134-47.
14. Pogorelić Z, Mustapić K, Jukić M, Todorčić J, Mrkličić I, Meštrović J et al. Management of acute scrotum in children: a 25-year single center experience on 558 pediatric patients. *Can J Urol.* 2016;23:8594-601.
15. Pogorelic Z, Mrklic I, Juric I. Do not forget to include testicular torsion in differential diagnosis of lower acute pain in young males. *J Pediatr Urol.* 2013;9:1161-65.
16. Sharp VJ, Kieran K, Arlen AM. Testicular torsion: diagnosis, evaluation, and management. *Am Fam Physician.* 2013;88:835-40.

17. Mayo Clinic [Internet]. USA: Mayo Clinic Staff; 2016. Testicular torsion; 2016 Feb 04 [cited 2018 Jan 12]. Available from: <https://www.mayoclinic.org/diseases-conditions/testicular-torsion/symptoms-causes/syc-20378270>.
18. Bowlin PR, Gatti JM, Murphy PJ. Pediatric Testicular Torsion. *Surg Clin North Am*. 2017;97:161-72.
19. Mansbach JM, Forbes P, Peters C. Testicular torsion and risk factors for orchiectomy. *Arch Pediatr Adolesc Med*. 2005;159:1167-71.
20. Marchetti F, Bua J, Tornese G, Piras G, Toffol G, Ronfani L et al. Management of cryptorchidism: a survey of clinical practice in Italy. *BMC Pediatr*. 2012;12:4.
21. Medscape [Internet]. USA: Oreoluwa; 2017. Cryptorchidism; 2017 Mar 27 [cited 2018 Jan 11]. Available from: <https://emedicine.medscape.com/article/438378-overview?pa=u8PdVdgy3QjCrSZ3%2F0UIJoBwh1V%2FntXXhC21EQRF6wiwpDEYSPWVQQQuBDm8%2FrA9t56MI7dGTgNawPfsOtJla9Q%3D%3D>.
22. Ringdahl E, Teague L. Testicular torsion. *Am Fam Physician*. 2006;74:1739-43.
23. Candocia FJ, Sack-Solomon K. An infant with testicular torsion in the inguinal canal. *Pediatr Radiol*. 2003;33:722-4.
24. Meštrović J, Biočić M, Pogorelić Z, Furlan D, Družijanić N, Todorčić D et al. Differentiation of inflammatory from non-inflammatory causes of acute scrotum using relatively simple laboratory tests: prospective study. *J Pediatr Urol*. 2013;9:313-7.
25. Pogorelić Z, Mrkličić I, Jurić I, Biočić M, Furlan D. Testicular torsion in the inguinal canal in children. *J Pediatr Urol*. 2013;9:793-7.
26. Brouwers MM, Bruijne LM, Gier RP, Zielhuis GA, Feitz WF, Roeleveld N. Risk factors for undescended testis. *J Pediatr Urol*. 2012;8:59-66.
27. Moslemi MK, Abedinzadeh M, Al-Mousawi S. Torsion of testis in an infant with unilateral UDT. *Case Rep Med*. 2010;2010:3.
28. Candocia FJ, Sack-Solomon K. Testicular torsion in the inguinal region in an extremely low birth weight infant. *Korean J Pediatr*. 2010;53:852-4.
29. Weiss AP, Van Heukelom J. Torsion of an undescended testis located in the inguinal canal. *J Emerg Med*. 2012;42:538-9.
30. Pogorelić Z, Jukić M, Škrabić V, Mrkličić I, Vidas VF, Jurić I et al. Bilateral simultaneous testicular torsion in a newborn: report of a case. *Acta Medica (Hradec Kralove)*. 2017;60:120-3.
31. Knight RM, Cuenca PJ. Torsion of undescended testis in a 14-month-old child refusing to bear weight. *West J Emerg Med*. 2011;12:515-9.

32. Zilberman D, Inbar Y, Heyman Z, Shinhar D, Bilik R, Avigad I et al. Torsion of the cryptorchid testis – can it be salvaged? *J Urol.* 2006;175:2287-9.
33. Singh RD, Singh RK. Torsion of undescended testis in an infant: case for early orchiopexy. *J Indian Med Assoc.* 2011;109:593-4.
34. Sheref YM, Johnson MH, Traxel EJ, Khanna G. Case report: torsion of a cryptorchid testicle in an infant. *Emerg Radiol.* 2011;18:487-9.
35. Guta D, Leduc F, Herman D. Acute abdominal pain: the importance of genital examination. *Acta Chir Belg.* 2011;111:398-9.
36. Mellick LB. Torsion of the testicle; it is time to stop tossing the dice. *Pediatr Emerg Care.* 2012;28:80.
37. Corbett CR, Baer ST, Grimmett BM. Testicular torsion presenting with abdominal pain. *J R Coll Gen Pract.* 1986;36:36-8.
38. Rathous I, Pesková M, Sváb J, Cermák S, Votrubová J, Mára M. Organ torsion and abdominal symptoms-case reports. *Rozhl Chir.* 2002;81:14-7.
39. Anderson JB, Williamson RC. Testicular torsion in Bristol: a 25-year review. *Br J Surg.* 1988;75:988-92.
40. Perrotti M, Badger W, Prade S, Moran ME. Medical malpractice in urology, 1985 to 2004: 469 consecutive cases closed with indemnity payment. *J Urol.* 2006;176:2154-7.

8. SUMMARY

Objective: The aim of this study was to investigate demographic and clinical characteristics and outcomes of the treatments of the patients with an unusual presentation of the acute scrotum and to clarify their peculiarities.

Subjects and Methods: From January 1999 until December 2017, a number of 149 patients received an operation for TT in the pediatric surgery department of the University Hospital of Split. Out of that number, 25 patients were indentified with unusual presentation of an acute scrotum (14 patients who presented with an abdominal pain only, and 11 who presented with testicular torsion in inguinal canal). For each patient following parameters were investigated: age, symptoms, lateralization, degree of torsion, physical examination, outcomes of treatment, long-term consequences and complications.

Results: Eleven boys (7.38%) out of the total number of patients 149 (100%) turned out to have a testicular torsion within the inguinal canal and 14 (9.39%) children presented with abdominal pain only. The median age of all children with TT (n=149) at the moment of surgery was 14 years (range 0 days- 17 years). The duration of the symptoms varied substantially and ranged from 1 hour to 120 hours with a median of 6 hours, with only 63 (42.28%) out of the 149 patients staying below the golden 6 hours. Only 2/11 (18.18%) children of the inguinal group and 5/14 (35.71%) children of the abdominal group presented within 6 h. In the group with inguinal TT, the age distribution ranged from 0 to 16 years with a median age of 13 years. The symptoms were mostly abdominal pain (90.9%), followed by groin pain (45.45%), nausea (45.45%), scrotal edema (9.09%) and erythema (9.09%). In 6 out of 11 children, the first physical examination didn't include a genital examination. The median duration of symptoms in the inguinal group was 24 h (range 3-60 h). In the group with abdominal pain, the age distribution ranged from 3 to 17 years with a median age of 13 years. The symptoms were limited, besides the abdominal pain, to groin pain (42.83%) and nausea (50%). In 9 out of 14 children, the first physical examination didn't include a genital examination. The median duration of the symptoms in this group was 17 h (range 3-72 h). Orchiectomy was performed in the inguinal TT group in 54.54% and in the abdominal group in 57.14% of the cases.

Conclusion: Testicular torsion, particularly in regard to torsion in the inguinal canal or presenting dominantly with abdominal pain can be easily misdiagnosed, but needs to be recognized on time, to salvage the affected testicle. The complete physical examination, including the genital examination, needs to be performed in each male patient presenting with lower abdominal or groin pain.

9. SUMMARY IN CROATIAN

Cilj istraživanja: Cilj ove studije je istražiti demografske i kliničke značajke, te ishode liječenja u bolesnika koji su liječeni zbog neuobičajene kliničke slike akutnog skrotuma i razjasniti njihove osobitosti.

Ispitanici i metode: Od siječnja 1999. do prosinca 2017. 149 bolesnika operirano je zbog torzije testisa u Klinici za dječju kirurgiju KBC-a Split. Od ukupnog broja bolesnika zabilježeno je 25 bolesnika koji su imali neuobičajenu kliničku sliku akutnog skrotuma (14 bolesnika koji su imali dominantno abdominalnu simptomatologiju i 11 bolesnika koji su imali torziju testisa u preponskom kanalu). Svakom bolesniku zabilježeni su sljedeće značajke: dob, simptomi, lateralizacija torzije, stupanj torzije, fizikalni nalaz, ishodi liječenja, praćenje i komplikacije.

Rezultati: Jedanaest dječaka (7,38%) od ukupno 149 imalo je torziju testisa u preponskom kanalu, a 14 (9,39%) ih je imalo torziju koja je bila praćena isključivo abdominalnom simptomatologijom, bez boli u testisu. Medijan dobi za svu djecu s torzijom testisa (n=149) u trenutku kirurškog zahvata iznosio je 14 godina (raspon 0 dana- 17 godina). Medijan trajanja simpoma iznosio je 6 sati (raspon 1-120 sati). Samo 63 (42,28%) bolesnika došla su unutar tzv. zlatnog perioda od 6 sati. Samo 2/11 (18,18%) djece u grupi torzija u preponskom kanalu i 5/14 (35,71%) djece s abdominalnom simptomatologijom javilo se unutar 6 h od početka simptoma. U grupi torzija u preponskom kanalu medijan dobi iznosio je 13 godina (raspon 0-16 godina). Najčešći simptom bio je bol u trbuhu (90,9%), a slijedili su ga bol u preponi (45,45%), mučnina (45,45%), otok skrotuma (9,09%) i crvenilo (9,09%). U 6 od 11 dječaka prvi pregled nije uključivao pregled genitalne regije. Medijan trajanja simptoma u ovoj grupi bio je 24 h (raspon 3-60 h). U grupi torzija s predominantno abdominalnom simptomatologijom medijan dobi iznosio je 13 godina (raspon 3-17 godina). Bol u trbuhu bila je dominantni simptom u svih bolesnika u ovoj grupi, a slijede je bol u preponi (42,8%) i mučnina (50%). U 9 od 14 dječaka prvi pregled nije uključivao pregled genitalne regije. Medijan trajanja simptoma u ovoj skupini bio je 17 sati (raspon 3-72 sati). U skupini bolesnika s torzijom testisa u preponskom kanalu orhidektomija je učinjena u 54,54% dječaka, a u skupini torzija s predominantno abdominalnom simptomatologijom čak u 57,14% dječaka.

Zaključak: Torzija testisa, osobito ako nema uobičajenu simptomatologiju i prezentira se kao torzija u preponskom kanalu ili dominantno abdominalnom simptomatologijom lako može biti previđena, iako bi trebala biti prepoznata na vrijeme da bi se testis sačuvao. Kompletan fizikalni pregled, uključujući pregled genitalne regije treba biti sastavni dio svakog pregleda u dječaka i adolescenata koji se žale na bol u trbuhu ili preponi.

10. CURRICULUM VITAE

PERSONAL INFORMATION

NAME AND SURNAME: Christopher Neumann

DATE AND PLACE OF BIRTH: April 6th 1989, Würzburg

NATIONALITY: German

CURRENT ADDRESS: Klarina 13, 21000 Split, Croatia

E-MAIL: c.ich@gmx.de

EDUCATION

June 2009:

Abitur at Dietrich-Bonhoeffer-Gymnasium in Wertheim

October 2009 – 2010:

Voluntary Social Service at the Red Cross in Wertheim

October 2010 – January 2011:

Internship at the primary school Centro Educativo in Ecuador

March 2011 – June 2012:

Molecular Biology Studies at the University of Salzburg

October 2012 – July 2018:

Medical Studies in English at the Split School of Medicine

OTHER

Languages: English, Spanish