

Expression pattern of Syndecan-1 and HSP-70 in hip tissue of patients with osteoarthritis

Kaufman, Julian

Master's thesis / Diplomski rad

2019

Degree Grantor / Ustanova koja je dodijelila akademski / stručni stupanj: **University of Split, School of Medicine / Sveučilište u Splitu, Medicinski fakultet**

Permanent link / Trajna poveznica: <https://um.nsk.hr/um:nbn:hr:171:793439>

Rights / Prava: [In copyright](#)/[Zaštićeno autorskim pravom.](#)

Download date / Datum preuzimanja: **2025-02-02**



Repository / Repozitorij:

[MEFST Repository](#)



**UNIVERSITY OF SPLIT
SCHOOL OF MEDICINE**

JULIAN ALEXANDER KAUFMAN

**EXPRESSION PATTERN OF SYNDECAN-1 AND HSP-70 IN HIP
TISSUE OF PATIENTS WITH OSTEOARTHRITIS**

Diploma Thesis

Academic Year:

2018/2019

Mentor:

Assoc. Prof. Katarina Vukojević, MD, PhD

Split, July 2019

TABLE OF CONTENTS

1. INTRODUCTION.....	1
1.1. Osteoarthritis.....	2
1.2. Pathogenesis of osteoarthritis.....	3
1.3. Syndecan-1 and its role in osteoarthritis.....	5
1.4. HSP-70 and its role in osteoarthritis.....	6
2. OBJECTIVES.....	8
3. MATERIALS AND METHODS.....	10
3.1. Ethical background.....	11
3.2. Study design.....	11
3.3. Study population.....	11
3.4. Tissue collection.....	11
3.5. Immunohistochemistry.....	12
3.6. Statistical analysis.....	14
4. RESULTS.....	15
5. DISCUSSION.....	20
6. CONCLUSIONS.....	23
7. REFERENCES.....	25
8. SUMMARY.....	29
9. CROATIAN SUMMARY.....	31
10. CURRICULUM VITAE.....	33

ACKNOWLEDGEMENT

First of all, I would like to thank my mentor Assoc. Prof. Katarina Vukojević, MD, PhD who has not only helped me with the laboratory work necessary for my thesis but has also supported me throughout my last years in medical school. I also want to thank Davor Čarić, MD who helped me tremendously in collecting data and guiding me through my thesis. I am very grateful to have had them by my side as it would not have been possible without.

Furthermore, I want to thank Assist. Prof. Joško Božić, MD, PhD Vice Dean of the University of Split School of Medicine for not only being a great professor but also a great friend who I could ask anything anytime.

Lastly, I would also like to thank my parents, Uta Schroeder and Joel Kaufman, my siblings, Sharon, Brooks, Jennifer, Stacey and my oldest friend Catherine Smith for always being there for me when I needed them and supporting me in everything I did since the day I was born.

All the chemicals and materials used in the study were financed by the University of Split School of Medicine, Institutional grant for excellence 2015. and 2016. awarded to Assoc. Prof. Katarina Vukojević

LIST OF ABBREVIATIONS

OA - Osteoarthritis

DIP - Distal Interphalangeal Joints

PIP - Proximal Interphalangeal Joints

MRI - Magnetic Resonance Imaging

ESR - Erythrocyte Sedimentation Rate

ECM - Extracellular Matrix

CRP - C-reactive Protein

PGE - Prostaglandin E

IL - Interleukin

iNOS- induced Nitric Oxide Synthase

TGF β - Transforming Growth Factor β

FGF - Fibroblast Growth Factor

VEGF - Vascular Endothelial Growth Factor

NGF - Nerve Growth Factor

MMP - Matrix-Metalloproteinase

COX - Cyclooxygenase

FLS - Fibroblast Like Synoviocytes

US - Ultrasound

GAG - Glycosaminoglycan

ADAMTS - Activation of a Disintegrin And Metalloproteinase with Thrombospondin Motifs

TNF α - Tumor Necrosis Factor alpha

NO - Nitric Oxide

sGAG - sulfated Glycosaminoglycan

PFA - Paraformaldehyde

PBS - Phosphate Buffered Saline

DAPI - 4',6-Diamidino-2-Phenylindole

HSPGs - Heparan Sulfate Proteoglycans

1. INTRODUCTION

1.1. Osteoarthritis

Osteoarthritis (OA) is a chronic degenerative disease of the joints in the human body (1,2). It is the most common form of arthritis nowadays affecting 250 million people worldwide (3,4). The most frequent risk factors are obesity, trauma, age and genetic predisposition. OA can be classified as primary (idiopathic, multifactorial and unknown cause) and secondary (following fractures, joint infections, angular deformities, joint dysplasias etc.) (3,5,6). Furthermore, OA is characterized mainly by deterioration of articular cartilage most commonly in the hip, knee, proximal interphalangeal joint (PIP) and distal interphalangeal joint (DIP) (1). Patients classically suffer from crepitus, decreased range of motion, stiffness, swelling in the morning that deteriorates during the day and most importantly pain with activity that improves with rest (2,7). It is diagnosed by anamnesis, clinical examination and imaging studies such as x-ray or magnetic resonance imaging (MRI) indicating joint space narrowing with osteophytes and subchondral sclerosis (7). The American College of Rheumatology have created criteria that are frequently used for the clinical diagnosis of hip OA (Table 1). In addition, synovial fluid may be extracted and analyzed. Fluid in OA will be straw-colored and will contain less than 2000 cells/ μl (7). Even though OA is not considered to be an inflammatory disease without elevated markers, it should be noted that there is local inflammation like synovitis. However, it is not known whether the inflammatory reaction is induced by it or whether this is secondary to changes of OA (3,7). Furthermore, cartilage itself is incapable of inducing pain or inflammation since there is lack of vasculature and innervation (3,8,9). This means that pain must derive from other joint components, like synovium, joint capsule, ligaments, subchondral bone and muscles (3,8,9).

Table 1. American College of Rheumatology criteria for the diagnosis of hip osteoarthritis (10)

Clinical criteria A	Clinical criteria B	Clinical plus radiographic criteria
Hip pain; and Hip internal rotation <15°; and ESR ^a ≤45mm/h or hip flexion ≤115° if ESR unavailable	Hip pain; and Pain with internal hip rotation; and Morning stiffness of hip ≤60min; and Over 50years of age	Hip pain; and any 2 of the following: ESR <20mm/h Radiographic femoral and/or acetabular osteophytes Radiographic joint space narrowing

^aErythrocyte Sedimentation Rate

Unfortunately, conservative treatment is limited to physical therapy, weight loss, chronic intake of NSAIDs and intraarticular injections of cortisone, viscosupplements, platelet rich plasma and bone marrow aspirate concentrate (7,11,12). Consequently, the only definite treatment is joint replacement in advanced cases (7,11). Since our population is growing older and becoming more obese it is of utmost importance to further investigate this disease (7).

1.2. Pathogenesis of osteoarthritis

The pathogenesis of OA is multifactorial and mainly based on pathologic changes in the articular cartilage, subchondral bone and synovium (3,13,14). One major cause is biomechanical stress from trauma, abnormal joint morphology and increased weight bearing on articular cartilage (3,6,13). This results in damage to the homeostatic balance of synthesis and degradation of joint tissue consequently leading to end stage OA (13). Repetitive shear stress in the joint from trauma or obesity has been affiliated with molecular and cellular changes, such as increased expression of pro-inflammatory mediators and increased apoptotic activity (13,15). Following the primary cartilage damage, segments of chondrocytes and extracellular matrix (ECM) are liberated in the synovial fluid (14). Upon extraction, it was observed that it included many inflammatory factors such as C-reactive protein (CRP), prostaglandins (PGE), leukotrienes (LKB4), complement constituents, cytokines (TNF, IL1 β , IL6, IL15, IL17, IL18, IL21), induced nitric oxide synthase (iNOS) and growth factors (TGF β , FGFs, VEGF, NGF) produced by components of the joint including chondrocytes, subchondral osteoblasts and synovial membrane (3,14,15). Locally, these constituents may

initiate the matrix metalloproteinases (MMPs) and other hydrolytic enzymes (cyclooxygenase 2 (COX2) and PGE) to damage collagen and proteoglycans resulting in articular cartilage and ECM breakdown (3,14). These proinflammatory mediators are transcribed by the transcription factor NF- κ B, activated by synovial membrane inflammation (14). In order to protect itself, ECM breakdown liberates damage-associated molecular patterns that are identified by the innate immune cells, such as macrophages and mast cells (3). However, this overwhelming extent of inflammation can cause damage to the underlying tissue (3). In fact, osteophytes were identified to be caused partially by macrophages researched in animal studies (3). Usually, humans have protective growth factors, such as fibroblast 18 or transforming growth factor B (3). However, in for example knee OA they are altered and can thus become harmful (3).

The area between subchondral bone and articular cartilage, called the osteochondral junction, has also been found to be an important component of OA (13,16,17). Both constituents work together by adapting in an organized manner to changed biochemical loading (13). Whenever there is an increased stress on the joint both components react in different ways (13). While subchondral bone reacts with accelerated degree of turnover manifesting as deterioration of subchondral and trabecular bone structure, the articular cartilage experiences microcracks due to microdestruction allowing increased vascularization (13,16). This causes a transit of cytokines and growth factors in both directions bridging cartilage and subchondral bone not only mechanically but also biochemically (13,16). The exact molecules have not been entirely researched but it is thought that pro-inflammatory cytokines and osteoclast-stimulating factors liberated by the damaged cartilage move towards the subchondral bone causing a change in its structure (13). And pro-inflammatory signalling molecules liberated by osteoblasts from subchondral bone move towards articular cartilage causing degradation (13).

It has also been researched that synovitis is a common finding in OA (3,18). Normally, synovial membrane is made up of two layers intima and subintima consisting of cells, like macrophages, fibroblast-like synoviocytes (FLS), smooth muscle cells and endothelium of blood vessels (14,18,19). But during inflammation, the synovial surface cell layer is thickened and contains inflammatory cells, such as lymphocytes and plasma-cells. Moreover, one can find neoangiogenesis and fibrosis during inflammation (14,18,19).

When visualizing synovitis under arthroscopy, MRI, ultrasound (US) and biopsies, one can see that the inflammation and its symptoms appear before the bony changes occur (14,19). Therefore, since there is increased joint instability and primary damage to the articular cartilage in the early stage, synovial inflammation actually has more significance than (14). Moreover, increased hyperplasticity and inflammation from increased vascularity, synovial line thickness and expression of inflammatory factors were more pronounced in early stage when compared to advanced OA (14). However, it is important to note that even though more inflammatory factors are present in early stage, synovial membrane may be more substantial in the advanced stage (14).

1.3. Syndecan-1 and its role in osteoarthritis

Syndecan-1 belongs to the family of Syndecans (20,21). They are transmembrane cell surface proteoglycans that carry glycosaminoglycan (GAG) chains, such as heparan and chondroitin sulphate, which are covalently bound to the core protein (20,22). Syndecans and MMPs work together on keeping the normal ECM homeostasis in balance (22). In addition, they react to inflammatory signals by stimulating a disintegrin and metalloproteinase with thrombospondin motifs (ADAMTS) proteinases causing division of aggregated proteoglycans (15,22). This shows that Syndecans may be implicated in modification of cellular activities such as proliferation and differentiation (22). Moreover, Syndecans are known to be coreceptors for cytokines and more importantly ECM receptors that cause cell adhesion with the matrix and other cells (20,22). Therefore, Syndecans may have a role in angiogenesis and migration of leukocytes which are essential constituents of disease development for synovitis (20). In fact, Heparan sulfate chains specific for Syndecans also affect osteoblastogenesis and osteoclastogenesis which are both associated with OA (22).

So far, four Syndecans have been recognized (20,21). Firstly, Syndecan-1 is expressed mainly on epithelial cells but can also be found on endothelial cells (20,21). Syndecan-2 is mostly expressed on fibroblasts, carcinogenous and endothelial cells (20,21). Syndecan-3, however, is found mostly in musculoskeletal and neuronal cells, specifically in cerebellar fibrillar plaques in Alzheimer (20,21). Lastly, Syndecan-4 can be found on many cells including endothelial and epithelial (20).

Focusing on Syndecan-1, it is expressed in many different developmental processes, such as tissue organization, like angiogenesis and wound healing and limb bud and tooth development. Moreover, it is also found to be associated with not only controlling inflammatory responses but also attaching to chemokines and causing chemokinetic gradients (20,21).

Increased expression in OA due to proliferation of chondrocytes has been detected (22). Previous research on mice has shown that in early OA maturing chondrocytes classically change their phenotype, similar to tissue repair, producing not only more type IIa procollagen but also transcription factor Sox9 (22). However, this does not suffice as the cartilagenous damage continues to endstage OA (22). This repair is very similar to that of wounds in which Syndecan-1 plays a crucial role which is why it was chosen for further investigation (22).

1.4. HSP-70 and its role in osteoarthritis

HSP-70 belongs to the family of heat shock proteins where the 70 indicates its molecular weight measured in kDa (23). Another name for HSP-70 is stress protein or molecular chaperone (24). This is because chondrocytes, when exposed to environmental or mechanical stress, start producing it in high numbers after being stimulated by IL-1, IL-2 and tumor necrosis factor alpha (TNFalpha) (23,24). HSP-70's physiologic role is to protect the structural integrity and cellular proteins by inhibiting multiple pathways of apoptosis, such as Nitric Oxide (NO) induced caspase 3, the previously mentioned NF- κ B, JNK, apoptosome formation and mitochondrial cytochrome C release (23-26). Moreover, it protects the cells from oxidative stress which otherwise would result in apoptosis and necrosis (23).

Furthermore, it has been researched in rats, when exposed to different severities of exercise, that little and intermediate workout increased HSP-70 expression actually preventing OA by promoting cell metabolism to provide enough sulfated glycosaminoglycan (sGAG) to the ECM in the joint as shown in figure 1 (26). However, severe exercise resulted in OA despite increased HSP-70 potentially exceeding its capacity of protection (26). This may be due to increased expression of HSP-90 which was found to restrict the properties of HSP-70 and activate the NF- κ B which is a major factor in the pathogenesis of OA (26).

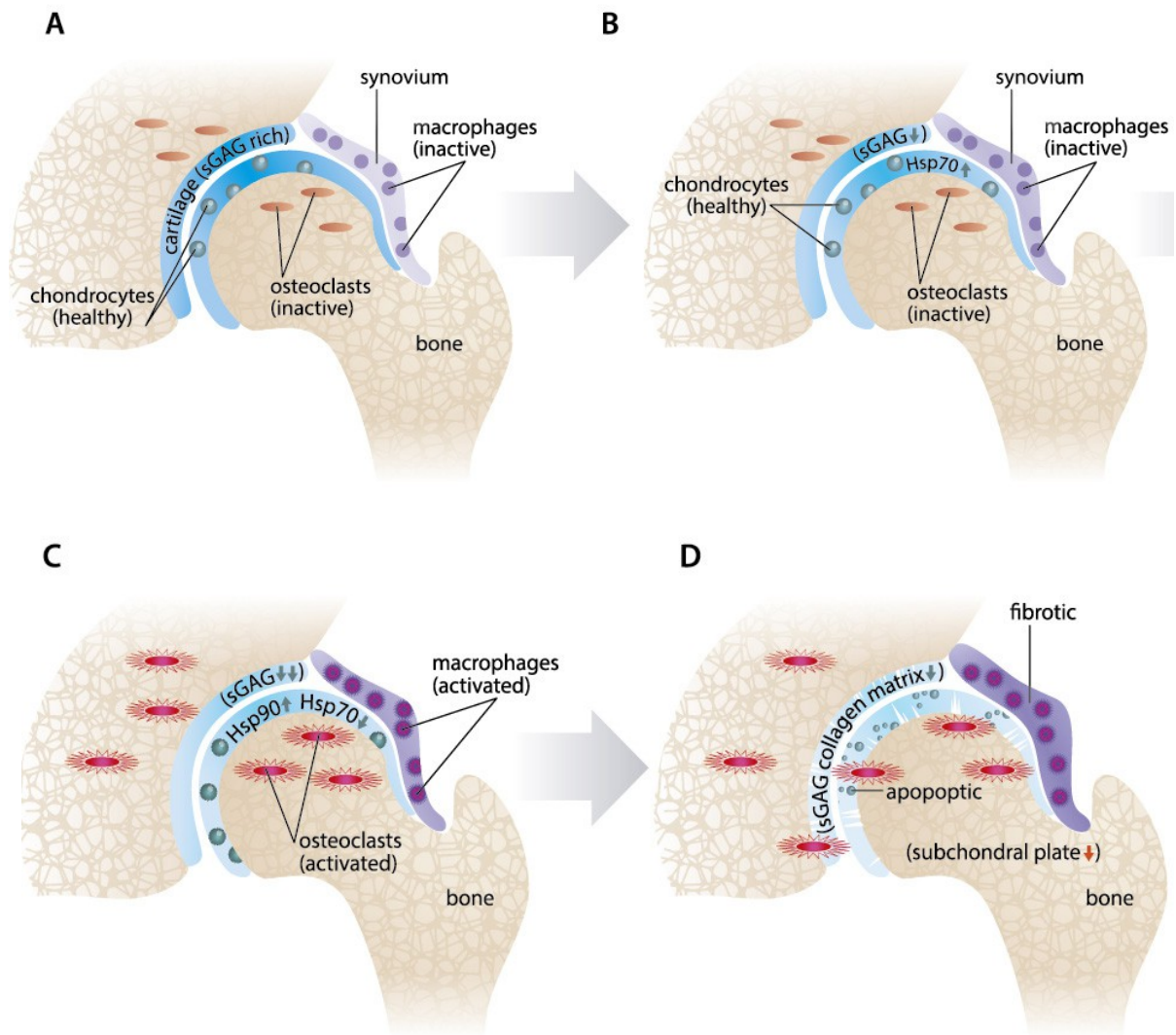


Figure 1. Representation of hypothetical roles of HSP-70 and HSP-90 in osteoarthritis (OA). Healthy cartilage (A). Stressed cartilage during running (B). Persisting biomechanical stress (C). Osteoarthritis (D) (26).

Clearly, HSP70 has some important role in the pathogenesis and development of OA which is why it was also chosen for the purpose of this paper.

2. OBJECTIVES

The purpose of this study was to investigate the expression of Syndecan-1 and HSP-70 in synovial, chondral and subchondral tissue in the hip of human patients with osteoarthritis according to their disease severity. Since OA in the knee has been researched frequently the interest was whether the same process with the same markers also occurs in the hip. Depending on the results, the expression could be the aim of a new pharmacologic agent targeting Syndecan-1 and HSP-70 to ameliorate the symptoms of osteoarthritis in the hip.

Hypothesis

Syndecan-1 and HSP-70 are overly expressed in synovial, chondral and subchondral tissue in patients with severe osteoarthritis of the hip.

3. MATERIALS AND METHODS

3.1. Ethical background

The experimental protocol was approved by the Ethics Committee of the University Hospital Split. All performed procedures were in compliance with the ethical standards of the institutional research committee and the 1964 Helsinki declaration.

3.2. Study design

This cross-sectional study was performed in the Department of Orthopedics and Traumatology of the University Hospital Split (KBC) and in the Department of Anatomy, Histology and Embryology of the University of Split School of Medicine. The tissue was collected in the period of 2017 to 2018.

3.3. Study population

Eight patients were included in this study. Six patients were diagnosed with severe osteoarthritis of the hip by an orthopedic surgeon on the basis of anamnesis, clinical examination and standard hip x-ray. The other two patients underwent total hip replacement for a femoral neck fracture and were used as control. Patients were included and excluded according to the American College of Rheumatology criteria for the diagnosis of hip osteoarthritis. In addition, they were scored according to the Harris Hip Score, Oxford Hip Score and the radiologic Kellgran Lawrence grading scale. In order to be put in the group of severe OA they had to reach a Kellgran Lawrence grade of at least 3, an Oxford Hip Score of maximally 27 out of 48 (48 meaning least dysfunction) and/or a Harris Hip Score of maximally 70 out of 100 (100 meaning least dysfunction) (27). The patients used as control all had Kellgran Lawrence grades of 0 or 1. The Oxford Hip Score and the Harris Hip Score were not able to be assessed in these patients with a femoral neck fracture since these two scores assess the range of motion.

3.4. Tissue collection

Total hip arthroplasty was performed on included patients (Implant: Pinnacle Acetabular Cup System and Corail Hip System by Depuy, Johnson and Johnson, USA).

Then, tissue from the weight bearing area of the pathologic femur adjacent to the most damaged but still cartilage containing zone was removed in a triangular manner with an oscillating saw (Trauma Reckon Sytem by Synthes, Switzerland) and was put in a sterile

plastic cup used for pathohistology to be sent to the laboratory. Originally, the tissue was collected in a transverse manner from the weightbearing area as seen in figure 2. However, this resulted in too big of tissue sample which was not optimal for the process of decalcification with osteosoft and further analysis with immunohistochemistry.

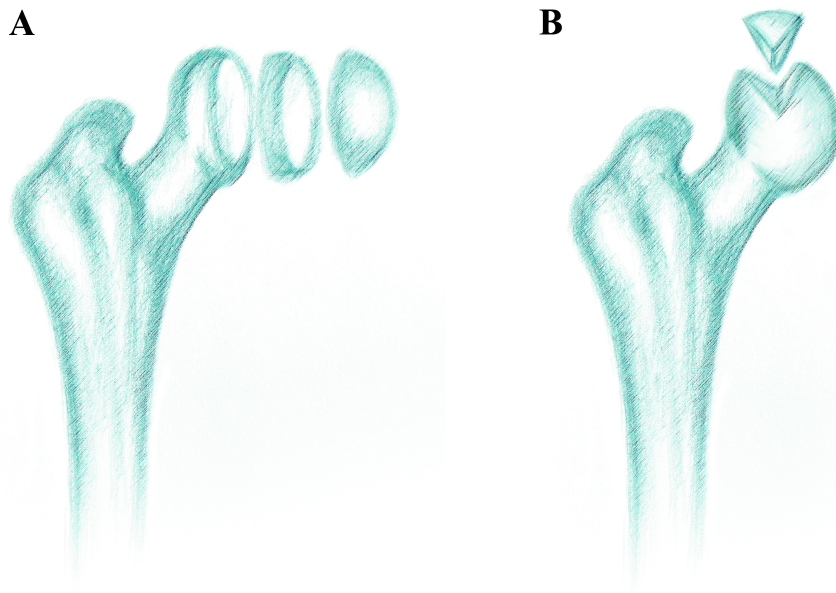


Figure 2. Tissue extraction. Original, not optimal transverse collection (A) and ideal triangular collection used for this research (B).

3.5. Immunohistochemistry

The tissue samples were collected and fixed in 4% Paraformaldehyde (PFA) in Phosphate buffered saline (PBS) overnight and transferred to osteosoft solution for 6 months. In the pilot study we used four samples and titrated an appropriate time for incubation of osteosoft (from one, two, three and four months). However, the results were not optimal for further analysis because the decalcification process was not complete. Therefore, we collected new samples and incubated them for 6 months.

The tissue samples were then embedded in paraffin blocks and cut transversely (7 μm thin sections) and mounted on slides. These were then deparaffinated in Xylol for three times five minutes.

Following this, they were rehydrated two times for ten minutes in 100% ethanol, five minutes in 95% ethanol, five minutes in 70% ethanol and five minutes in distilled water. Next, the slides were heated in citrate buffer (pH 6.0) at 700 Watt in a microwave for 12 minutes. After they had cooled off at room temperature for 20 minutes the slides were rinsed with PBS for four times five minutes. Afterwards, they were dried and the tissue was encircled by a PAP pen. Block protein was then put on the tissue sections for 30 minutes. After the block protein was removed and the slides had dried the primary antibodies were applied on all of the sections except for one which was used as negative control. The two antibodies from Abcam (Cambridge, England) used were raised in mouse (ab34164-100) diluted at 1:100 targeting Syndecan-1 and in rabbit (ab31010) diluted at 1:500 targeting HSP-70. They were kept over night covered by parafilm in a humidified dark chamber at room temperature.

The next day the slides were rinsed with PBS two times for five minutes. Afterwards, the secondary antibodies were applied for one hour. The secondary antibodies from Abcam (Cambridge, England) for Syndecan-1 were raised in goat (ab6786) diluted at 1:400 appearing red on immunofluorescence and the ones for HSP-70 were raised in donkey (ab150073) diluted at 1:400 appearing green on immunofluorescence. The slides were then again rinsed with PBS twice each for five minutes before 4',6-diamidino-2-phenylindole (DAPI) for nuclear staining was applied for two minutes. Following this, they were again rinsed with PBS twice for five minutes and dried. Lastly, they were mounted in Immu-mont and coverslipped in order to observe and capture images of the sections using an Olympus (Tokyo, Japan) BX51 microscope equipped with an Olympus (Tokyo, Japan) DP71 digital camera.

All images were observed and saved with Cella Imaging Software for Life Sciences Microscopy from Olympus (Tokyo, Japan). The sections were analyzed focusing mainly on synovial, chondral and subchondral tissue. Ten non overlapping fields were taken using 40× objective magnification, each field representing three images. One for Syndecan-1 expression, one for HSP-70 expression and one for nuclear expression with DAPI. These images were then further observed and merged using Adobe Photoshop (Adobe Systems, MI, USA). The cells staining positively for Syndecan-1 and HSP-70, respectively, and all the nuclei stained with DAPI were counted using ImageJ software (National Institutes of Health, Bethesda, MD, USA).

The number of positive and negative nuclei from all usable merged images for each patient was calculated and compared between groups (control and severe OA).

3.6. Statistical analysis

Data analysis was conducted with GraphPad Prism (GraphPad Software, La Jolla, CA, USA) and Mann-Whitney t-test was used for statistical analysis to examine the difference between control and severe OA in the cartilage, subchondral and synovial tissue. Data was expressed as mean \pm standard deviation and statistical significance was $p < 0.05$.

4. RESULTS

Immunohistochemical staining with Syndecan-1 and HSP-70 antibodies revealed positive expression of both markers as seen in Figure 3.

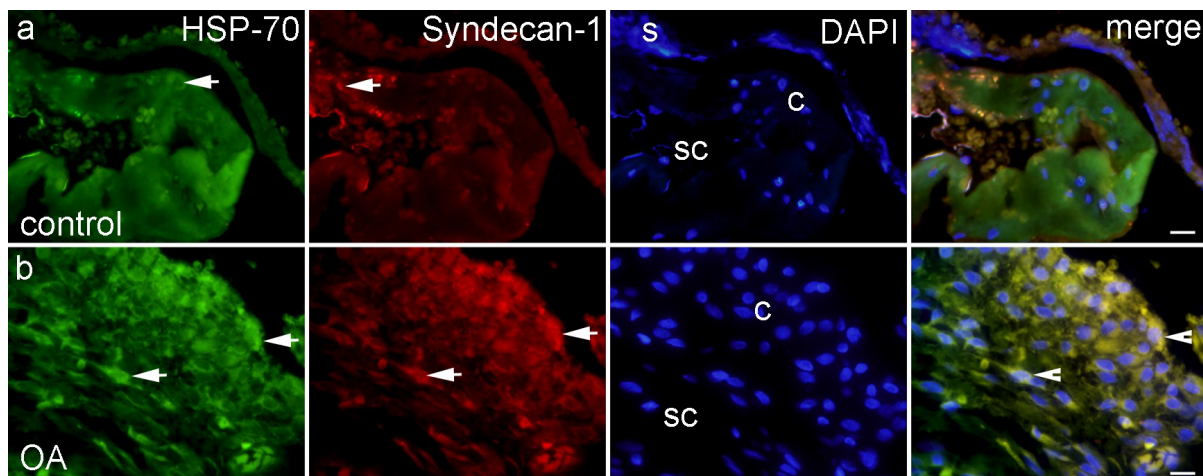


Figure 3. HSP-70 positive cells were seen as green staining (arrows) and Syndecan-1 as red staining within different areas of the chondral and synovial tissue. Co-localization of HSP-70 & Syndecan-1 merged with DAPI nuclear stain are displayed in the far right column (arrowheads). Control patients (a) and patients with severe osteoarthritis (b). Scale bar for a is 17 μ m and for b 10 μ m. Legend: s- synovium; sc- subchondral tissue; c- cartilage; OA- severe osteoarthritis

The following charts (Figures 4-8) demonstrate the amount of cell positivity in cartilage and subchondral tissue in the control patients with mild OA and patients with severe OA according to Harris Hip Score, Oxford Hip Score and Kellgran Lawrence grading. One can see that the cartilage and subchondral tissue in patients with severe OA contained abundant positive cells with a mean positive cell count of 120 \pm 16 and 142 \pm 23 for Syndecan-1 and 120 \pm 24 and 136 \pm 28 for HSP-70, respectively. On the contrary, the control patients only had minimal positivity with a mean positive cell count of 30 \pm 4 and 34 \pm 16 for Syndecan-1 and 30 \pm 5 and 33 \pm 22 for HSP-70, respectively. Synovial tissue could not be identified enough for presentation. However, it followed the trend of chondral and subchondral tissue.

It was established that there was a statistical significance of both Syndecan-1 and HSP-70 with $p < 0.05$ in cartilage and $p < 0.001$ in subchondral tissue between control and severe OA.

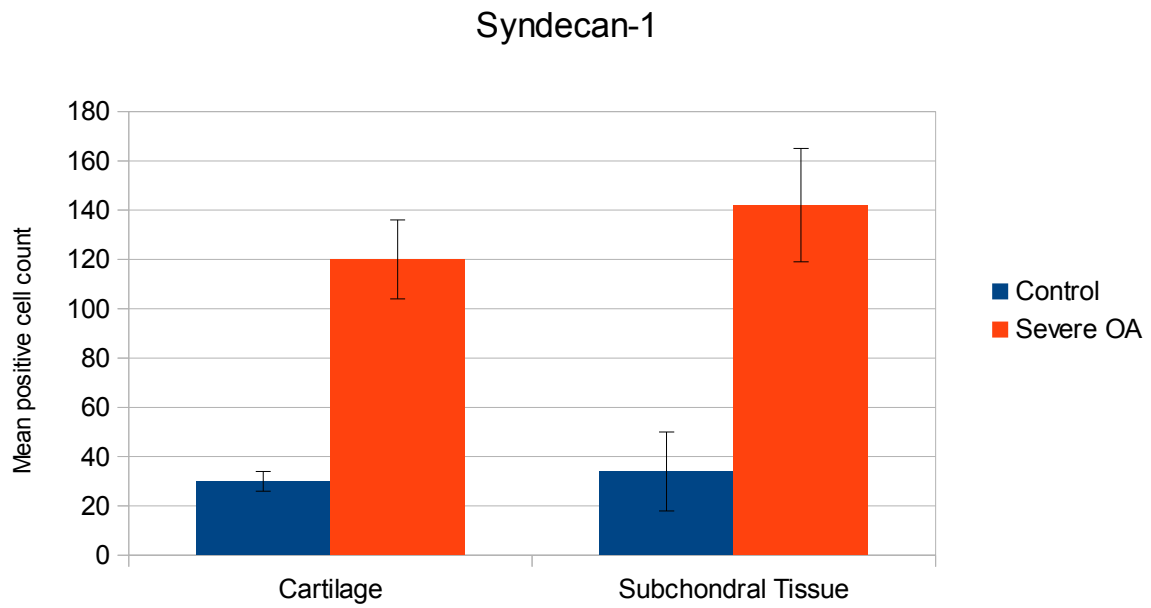


Figure 4. Mean positive cell count of Syndecan-1 in cartilage and subchondral tissue in control and severe OA. Data are presented as mean±SD.

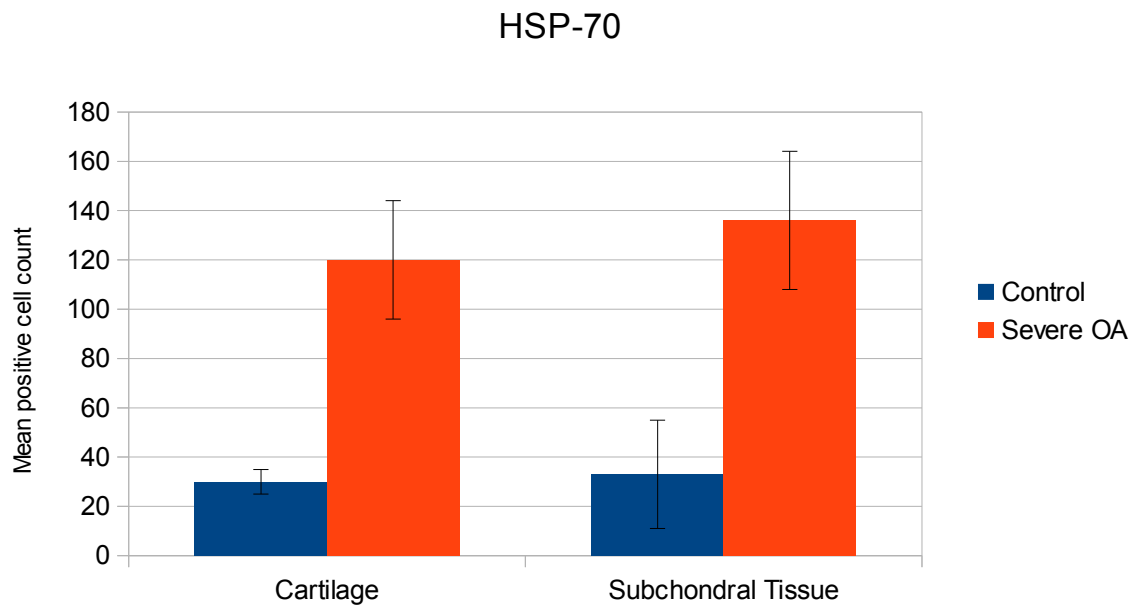


Figure 5. Mean positive cell count of HSP-70 in cartilage and subchondral tissue in control and severe OA. Data are presented as mean±SD.

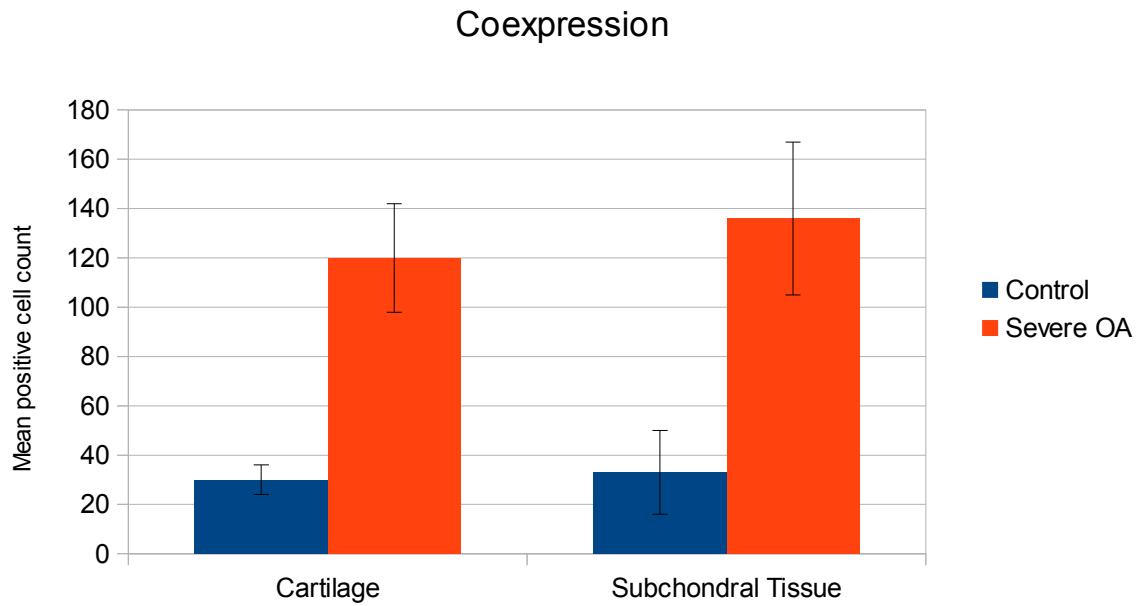


Figure 6. Mean positive cell count of HSP-70 and Syndecan-1 coexpressed in cartilage and subchondral tissue in control and severe OA. Data are presented as mean±SD.

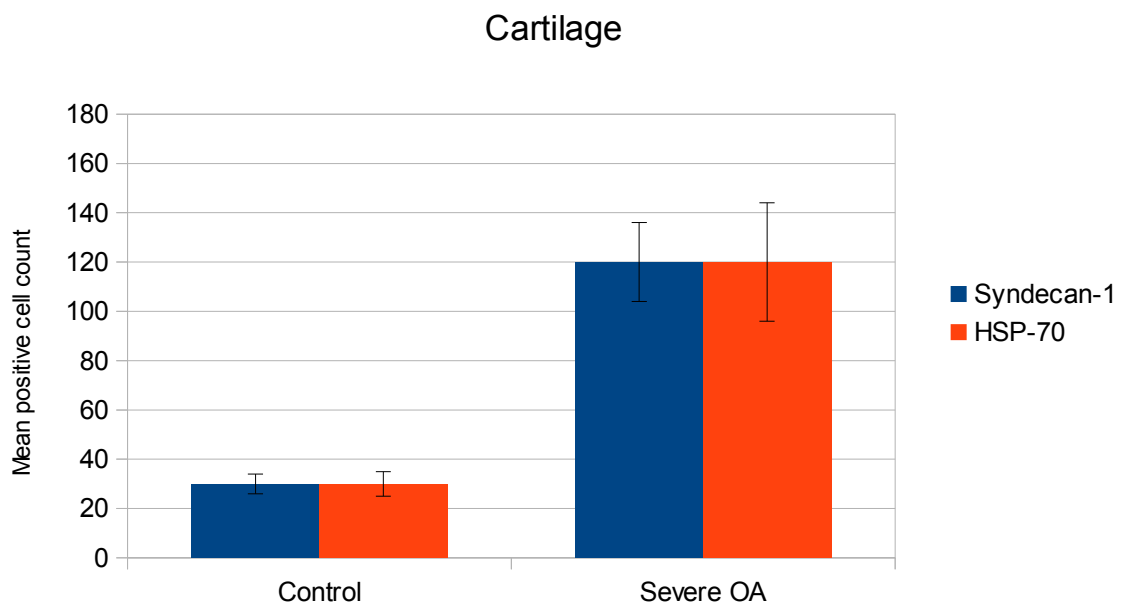


Figure 7. Mean positive cell count of Syndecan-1 and HSP-70 in cartilage in control and severe OA. Data are presented as mean±SD.

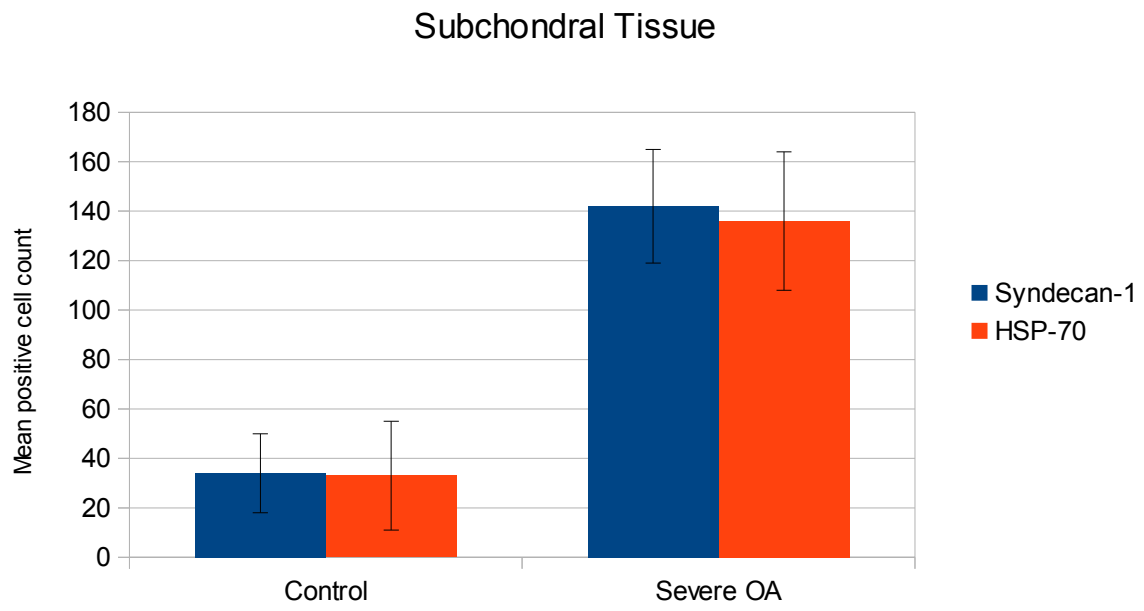


Figure 8. Mean positive cell count of Syndecan-1 and HSP-70 in subchondral tissue in control and severe OA. Data are presented mean±SD.

5. DISCUSSION

The results of immunohistochemical staining in this study show that there in fact is an increased expression of Syndecan-1 and HSP-70 in chondral, subchondral and synovial tissue of patients with severe OA in comparison with the control patients. Both markers were found abundantly in cartilage, subchondral and synovial tissue.

When interpreting the results one can say that there is an increase in cells due to damage of cartilage and a resulting proliferation of chondrocytes trying to repair the damage. Moreover, the inflammation of the synovium causes an increase in synovial lining cell thickness. Also, the accelerated turnover of subchondral bone as a reaction to structural damage is a cause for increased cell production. The reason for a higher number of cells in subchondral tissue compared to cartilage is probably the more developed vascularity and the resulting higher differentiation of cells in the subchondral tissue. Nevertheless, there is also an increased hyperplasticity and layering in the cartilage in the patients with severe OA, whereas normally the cartilage is lined with only one layer.

Most of these chondral, subchondral and synovial cells were found to coexpress Syndecan-1 and HSP-70. This can be explained by the fact that in the chondral, subchondral and synovial tissue Syndecan-1 becomes expressed by the proliferating cells that try to repair the damage. In this way, Syndecan-1 can trigger angiogenesis and attach to chemokines provoking a chemokinetic gradient similar to wound healing. In addition, the proliferating cells also produce HSP-70 to protect their structure and proteins since it inhibits apoptosis inducing pathways.

There is a lack of similar studies on this topic since most research papers focused on the knee. Nevertheless, results were all alike. When tested on knees in mice, Salminen-Mankonen et al. also proved an upregulation of Syndecan-1 in OA of the knee (22). He attributed it to the body's attempt to repair the damage that had taken place in the joint (22). Furthermore, increased expression of Syndecan-1 in OA and decreased expression in the control group is in concordance with Patterson et al. who demonstrated a similar increase in heparan sulfate proteoglycans (HSPGs) in inflammatory diseases of the knee in his study in 2007 (20).

Focusing on HSP-70, results of other studies also correlate with our findings. Grossin et al. transduced chondrocytes with HSP-70 vectors and found out that these cells were not only more resistant to cell death but also that overexpression of HSP-70 decreased the severity of OA in rats (28). Furthermore, in 2018 Ngamurkos et al. came to the conclusion

that HSP-70 levels in human knees were increased according to their disease severity and that it could be used as a biomarker for the prediction of OA severity (23). Nevertheless, HSP-70 overexpression alone might not be sufficient in protection of cartilage (26). According to Siebelt et al., HSP-90 might play a bigger role (26). They suggested that HSP-70 is less responsive to a higher load because HSP-90 restricts its action in increased biomechanical stress (26). When inhibiting HSP-90 in rats they realized that it not only improved subchondral bone thickness but also reduced macrophage activation (26). Further research is needed in order to find out the exact correlation between HSP-70 and HSP-90 in humans since this could be a possible therapeutic intervention to impede OA.

One of the limitations of our study was that we did not have another group without any OA to see a baseline and whether there is a constant rise in Syndecan-1 and HSP-70. Since most people have at least mild OA in their sixties and total hip replacement is usually not done before it is difficult to find a group without any OA. However, this was beyond the scope of this research. In addition, the sample size could be increased in the next studies as we only included 6 patients with severe OA and only 2 as controls. Moreover, since there wasn't enough synovial tissue identified it was not possible to present tangible results. Nevertheless, the trend was similar to that of chondral and subchondral tissue. For future research it would be important to extract solely synovium.

In conclusion, the results of our study strongly suggest that HSP-70 and Syndecan-1 play an important role in the onset and regulation of OA in the hip and that they do not differ from results in previous research on the knee. They are part of the process that tries to heal or protect the chondral, subchondral and synovial tissue in the hip by causing angiogenesis, increasing inflammatory cells and preventing apoptosis. This means that pharmaceutical agents might help by increasing the expression of HSP-70. However, increasing HSP-70 alone might not work since HSP-90 will limit its activity in severe OA as mentioned previously. It would be important to create an agent that can enhance HSP-70 and block HSP-90 at the same time. On the contrary, overexpression of Syndecan-1 will increase inflammation and exacerbate symptoms. Consequently, a pharmaceutical drug blocking Syndecan-1 could decrease the inflammatory response and its associated symptoms.

6. CONCLUSIONS

1. Patients with severe osteoarthritis had increased staining of Syndecan-1 and HSP-70 in the cartilage of the hip compared to patients who underwent total hip replacement for a femoral neck fracture.
2. Patients with severe osteoarthritis had increased staining of Syndecan-1 and HSP-70 in the subchondral tissue of the hip compared to patients who underwent total hip replacement for a femoral neck fracture.
3. Increased expression implies that Syndecan-1 and HSP-70 could play a significant role in the complex pathophysiology of osteoarthritis but further research is needed in order to make these findings applicable for clinical treatments.

7. REFERENCES

1. Satter HA. Musculoskeletal Pathology. In: Husain A. Satter. Fundamentals of Pathology: Medical Course and Step 1 Review. 2016 ed. Chicago: Pathoma LLC; 2016. p. 193-201.
2. Mirmaroufi N, Ghahramanian A, Behshid M, Jabbarzadeh F, Onyeka TC, Asghari-Jafarabadi M et al. Relationship between self-efficacy and pain control in Iranian women with advanced knee osteoarthritis. *Niger J Clin Pract.* 2019;22:460-8.
3. Mora JC, Przkora R, Cruz-Almeida Y. Knee Osteoarthritis: pathophysiology and current treatment modalities. *J Pain Res.* 2018;11:2189-96.
4. Hunter DJ, Bierma-Zeinstra S. Osteoarthritis. *Lancet.* 2019;393:1745-59.
5. Huang BK, Tan W, Scherer KF, Rennie W, Chung CB, Bancroft LW. Standard and Advanced Imaging of Hip Osteoarthritis. What the Radiologist Should Know. *Semin Musculoskelet Radiol.* 2019;23:289-303.
6. Vina ER, Kwok CK. Epidemiology of osteoarthritis: literature update. *Curr Opin Rheumatol.* 2018;30:160-7.
7. Le T, Bhushan V, Chen VL, King MR. High Yield Facts In Musculoskeletal. In: Le T, Bhushan V, Chen V, King M. First Aid for the USMLE Step 2 CK, 9th ed. New York City: Mcgraw-Hill Education; 2016. p. 235-56.
8. Perrot S. Osteoarthritis pain. *Best Pract Res Clin Rheumatol.* 2015;29:90-7.
9. Salaffi F, Ciapetti A, Carotti M. The sources of pain in osteoarthritis: a pathophysiological review. *Reumatismo.* 2014;66:57-71.
10. Altman R, Alarcon G, Appelrouth D, Bloch D, Borenstein D, Brandt K et al. The American College of Rheumatology criteria for the classification and reporting of osteoarthritis of the hip. *Arthritis Rheum.* 1991;34(5):505-14.
11. Stott A. Hyaluronic Acid and Other Conservative Treatment Options for Osteoarthritis of the Ankle. *Orthop Nurs.* 2017;36:361-2.
12. Mei-Dan O, Carmont M, Laver L, Mann G, Maffulli N, Nyska M. Intra-articular injections of hyaluronic acid in osteoarthritis of the subtalar joint: a pilot study. *J Foot Ankle Surg.* 2013;52:172-6.
13. Murphy NJ, Eyles JP, Hunter DJ. Hip Osteoarthritis: Etiopathogenesis and Implications for Management. *Adv Ther.* 2016;33:1921-46.
14. Ostojic M, Soljic V, Vukojevic K, Dapic T. Immunohistochemical characterization of early and advanced knee osteoarthritis by NF- κ B and iNOS expression. *J Orthop Res.* 2017;35:1990-7.

15. Sacitharan PK. Ageing and Osteoarthritis. *Subcell Biochem.* 2019;91:123-59.
16. Funck-Brentano T, Cohen-Solal M. Subchondral bone and osteoarthritis. *Curr Opin Rheumatol.* 2015;27:420-6.
17. Karsdal MA, Bay-Jensen AC, Lories RJ, Abramson S, Spector T, Pastoureau P et al. The coupling of bone and cartilage turnover in osteoarthritis: opportunities for bone antiresorptives and anabolics as potential treatments? *Ann Rheum Dis.* 2014;73:336-48.
18. Mathiessen A, Conaghan PG. Synovitis in osteoarthritis: current understanding with therapeutic implications. *Arthritis Res Ther.* 2017;19:18.
19. Scanzello CR, Goldring SR. The role of synovitis in osteoarthritis pathogenesis. *Bone.* 2012;51:249-57.
20. Patterson AM, Cartwright A, David G, Fitzgerald O, Bresnihan B, Ashton BA et al. Differential expression of syndecans and glypicans in chronically inflamed synovium. *Ann Rheum Dis.* 2007;67:592-601.
21. Stepp MA, Pal-Ghosh S, Tadvalkar G, Pajoohesh-Ganji A. Syndecan-1 and Its Expanding List of Contacts. *Adv Wound Care (New Rochelle).* 2015;4:235-49.
22. Salminen-Mankonen H, Säämänen AM, Jalkanen M, Vuorio E, Pirilä L. Syndecan-1 expression is upregulated in degenerating articular cartilage in a transgenic mouse model for osteoarthritis. *Scand J Rheumatol.* 2005;34:469-74.
23. Ngarmukos S, Scaramuzza S, Theerawattanapong N, Tanavalee A, Honsawek S. Circulating and Synovial Fluid Heat Shock Protein 70 Are Correlated with Severity in Knee Osteoarthritis. *Cartilage.* 2018;1:1947603518790075.
24. Takahashi K, Kubo T, Goomer RS, Amiel D, Kobayashi K, Imanishi J et al. Analysis of heat shock proteins and cytokines expressed during early stages of osteoarthritis in a mouse model. *Osteoarthritis Cartilage.* 1997;5:321-9.
25. Kang EH, Kim DJ, Lee EY, Lee YJ, Lee EB, Song YW. Downregulation of heat shock protein 70 protects rheumatoid arthritis fibroblast-like synoviocytes from nitric oxide-induced apoptosis. *Arthritis Res Ther.* 2009;11:R130.
26. Siebelt M, Jahr H, Groen HC, Sandker M, Waarsing JH, Kops N et al. Hsp90 inhibition protects against biomechanically induced osteoarthritis in rats. *Arthritis Rheum.* 2013;65:2102-12.

27. Nilsson A, Bremander A. Measures of hip function and symptoms: Harris Hip Score (HHS), Hip Disability and Osteoarthritis Outcome Score (HOOS), Oxford Hip Score (OHS), Lequesne Index of Severity for Osteoarthritis of the Hip (LISOH), and American Academy of Orthopedic Surgeons (AAOS) Hip and Knee Questionnaire. *Arthritis Care Res (Hoboken)*. 2011;11:S200-7.
28. Grossin L, Cournil-Henrionnet C, Pinzano A, Gaborit N, Dumas D, Etienne S et al. Gene transfer with HSP 70 in rat chondrocytes confers cytoprotection in vitro and during experimental osteoarthritis. *FASEB J*. 2006;20:65-75.

8. SUMMARY

Objectives: The purpose of this study is to investigate the expression of Syndecan-1 and HSP-70 in synovial, chondral and subchondral tissue in the hip of human patients with osteoarthritis according to their disease severity.

Materials and methods: Total hip arthroplasty with tissue extraction from the weightbearing area of the pathologic femoral head was performed on all patients. Patients were divided into two groups according to their disease severity defined by their Kellgran Lawrence, Harris Hip and Oxford Hip Score: control (femoral neck fracture) and severe Osteoarthritis (OA). Chondral, subchondral and synovial tissues were analyzed with raised antibodies against Syndecan-1 and HSP-70.

Results: Immunohistochemical staining with Syndecan-1 and HSP 70 antibodies revealed positive expression of both markers. It was established that the chondral, subchondral and synovial tissue in patients with severe OA contained abundant positive cells with a mean positive cell count of 120 ± 16 and 142 ± 23 for Syndecan-1 and 120 ± 24 and 136 ± 28 for HSP-70, respectively. On the contrary, patients without OA had only minimal positivity with a mean positive cell count of 30 ± 4 and 34 ± 16 for Syndecan-1 and 30 ± 7 and 33 ± 22 for HSP-70, respectively. Synovial tissue could not be identified enough for presentation. However, it followed the trend of chondral and subchondral tissue. It was established that there was a statistical significance of both Syndecan-1 and HSP-70 with $p < 0.05$ in cartilage and $p < 0.001$ in subchondral tissue between control and severe OA.

Conclusions: Patients with severe osteoarthritis had increased staining of Syndecan-1 and HSP-70 in the cartilage and subchondral tissue of the hip compared to patients who underwent total hip replacement for a femoral neck fracture. Increased expression implies that Syndecan-1 and HSP-70 could play a significant role in the complex pathophysiology of osteoarthritis but further research is needed in order to make these findings applicable for clinical treatments.

9. CROATIAN SUMMARY

Naslov: EKSPRESIJA PROTEINA SINDEKAN-1 I HSP-70 U TKIVU PACIJENATA S TEŠKIM OSTEOARTRITISOM KUKA

Ciljevi: Svrha ovog istraživanja bila je usporediti razinu ekspresije proteina sindekan-1 i HSP-70 u sinoviji, hrskavici i subhondralnoj kosti pacijenata s teškim osteoartritisom (OA) kuka i pacijenata bez osteoartritisa.

Materijali i metode: Sukladno težini pripadajuće bolesti, određenoj prema Kellgren-Lawrence, Harris Hip i Oxford Hip klasifikaciji, ispitanici su podijeljeni u dvije grupe: eksperimentalna grupa (teški OA) i kontrolna grupa (prijelom vrata femura). Svim ispitanicima učinjena je totalna artroplastika kuka s ekstrakcijom patološki oštećenog tkiva. Ekstrahirano tkivo sinovije, hrskavice i subhondralne kosti je imunohistokemijski analizirano pri čemu su korištena protutijela na sindekan-1 i HSP-70.

Rezultati: Imunohistokemijska analiza s protutijelima na sindekan-1 i HSP-70 pokazala je pojačanu ekspresiju obaju proteina u hrskavici (H) i subhondralnoj kosti (SHK) u eksperimentalnoj grupi u odnosu na kontrolnu. Zbog nedovoljno ekstrahiranog sinovijalnog tkiva, na sinoviji nije bilo moguće pouzdano usporediti grupe, no dojam je da bi rezultat bio sukladan onom u H i SHK. U pacijenata s teškim OA, u H i SHK, zabilježeno je obilje "pozitivnih" stanica sa srednjom vrijednošću od 120 ± 16 i 142 ± 23 za sindekan-1 te 120 ± 24 i 136 ± 28 za HSP-70. U pacijenata bez osteoartritisa zabilježena je blaga ekspresija ispitivanih proteina u H i SHK sa srednjom vrijednošću "pozitivnih stanica" od 30 ± 4 i 34 ± 16 za sindekan-1 te 30 ± 7 i 33 ± 22 za HSP-70. Utvrđena razlika u ekspresiji navedenih proteina statistički je značajna s razinom značajnosti $p < 0,05$ za hrskavicu i $p < 0,001$ za subhondralno tkivo.

Zaključci: Ekspresija proteina sindekan-1 i HSP-70 u hrskavici i subhondralnoj kosti pacijenata s teškim osteoartritisom kuka je značajno veća u odnosu na pacijente bez osteoartritisa. Povećana ekspresija proteina sindekan-1 i HSP-70 sugerira moguću značajnu ulogu navedenih proteina u složenoj patofiziologiji osteoartritisa. Ipak, daljnja istraživanja su nužna da bi nalazi ovog istraživanja našli mjesto u kliničkoj promjeni.

10. CURRICULUM VITAE

Personal Information

Name: Julian Alexander Kaufman

Date of Birth: 19.02.1994

Place of Birth: Boston, Massachusetts, U.S.A

Nationality: Dual- American and German

Address: Turnseestraße 21, 79102 Freiburg, Germany

E-mail: julian_kaufman@yahoo.de

Education

October 2013 - September 2019: University of Split School of Medicine, Split, Croatia

October 2004 - July 2012: Berthold Gymnasium, Freiburg, Germany

Other Activities

August 13th - August 26th, 2018: Scholarship for an Elective Exchange Program with Pennstate College of Medicine, Hershey, Pennsylvania in the Department of Nephrology

June 2018: Rector's Award for the Academic Year of 2016/2017

October 2015 - September 2019: Director of Activities for the International Student Association, University of Split School of Medicine, Split, Croatia

October 2017 - September 2019: Captain of the Faculty Futsal Team

January 2017 - February 2018: Demonstrator for Pathophysiology

March 2015 - 2017: Demonstrator for Anatomy

Languages

German (Native Language)

English (Native Language)

Croatian (B1 Level)