

Uniportal VATS procedure for lung cancer treatment at University Hospital of Split

Hoursch, Victor

Master's thesis / Diplomski rad

2019

Degree Grantor / Ustanova koja je dodijelila akademski / stručni stupanj: **University of Split, School of Medicine / Sveučilište u Splitu, Medicinski fakultet**

Permanent link / Trajna poveznica: <https://um.nsk.hr/um:nbn:hr:171:644695>

Rights / Prava: [In copyright](#)/[Zaštićeno autorskim pravom.](#)

Download date / Datum preuzimanja: **2025-03-06**



Repository / Repozitorij:

[MEFST Repository](#)



**UNIVERSITY OF SPLIT
SCHOOL OF MEDICINE**

Victor Hoursch

**UNIPORTAL VATS PROCEDURE FOR LUNG CANCER
TREATMENT AT UNIVERSITY HOSPITAL OF SPLIT**

Diploma Thesis

Academic Year:

2018/2019

Mentor:

Assist. Prof. Dragan Krnić, MD, PhD

Split, July 2019

TABLE OF CONTENTS

1. INTRODUCTION	1
1.1. Anatomy of The Lungs	2
1.2. Lung Cancer	3
1.2.1. Epidemiology and Prevalence	3
1.2.2. Etiology	4
1.2.3. Histology/Classification	5
1.2.3.1. Small-Cell Lung Carcinoma	5
1.2.3.2. Non-Small-Cell Lung Cancer	6
1.3. Treatment Options of Lung Cancer	7
1.3.1. Radiotherapy	7
1.3.2. Chemotherapy	8
1.3.3. Surgery	8
1.4. Thoracotomy	9
1.5. Thoracoscopy	10
1.5.1. Multiportal VATS	10
1.5.2. Uniportal VATS	11
1.5.2.1. Definition	11
1.5.2.2. History	11
1.5.2.3. Procedure	12
1.5.2.4. Indications and Advantages	14
1.5.2.5. Contraindications and Limitations	14
1.5.2.6. Further Developments	15
2. OBJECTIVES	16
3. SUBJECTS AND METHODS	18
3.1. Data Collection	19
3.2. Subjects	19
3.3. Description of the Study	19
3.3.1. Primary Outcomes	20
3.3.2. Secondary Outcomes	20
3.4. Statistical Analysis	20
4. RESULTS	21
5. DISCUSSION	25
6. CONCLUSIONS	30
7. REFERENCE	32
8. SUMMARY	37
9. CROATIAN SUMMARY	41
10. CURRICULUM VITAE	43

ACKNOWLEDGEMENTS

Firstly, I would like to thank my mentor Assist. Prof. Dragan Krnić, who guided me through this diploma thesis and helped me finish an important chapter of my life.

Thank you to my family, particularly my parents for always supporting me in any way possible. They enabled me to pursue my dream career and I wouldn't be where I am now without them.

Danke Mama und Papa!

During my six years in Split, I made friends for life and I am thankful for each and every one of them.

Last but not least, I want to thank Marina, who continuously gave me the best of everything throughout the last years.

1. INTRODUCTION

1.1. Anatomy of The Lungs

The lungs are a paired organ that can be divided into the left and the right lung. They are connected to the trachea via the main bronchi. The entire lung is covered with a serous membrane that reduces friction called the visceral pleura, which is continuous with the parietal pleura covering the inside of the thorax and surface of the diaphragm. The right lung has three lobes: superior, middle and inferior, while the left lung only has two lobes: superior and inferior (1). Each lobe is separated from one another by so called fissures. The oblique fissure divides the left superior and inferior lobes. The right lung is split into its three lobes by the oblique and horizontal fissures. In turn, each lobe can further be divided into multiple bronchopulmonary segments. These segments each connect to a segmental bronchus and are supplied with blood by separate arteries (2).

Air enters the lungs via the tracheobronchial tree. This starts with the trachea, which splits into the left and right bronchus. These two main bronchi enter the lung at the hilum. In the lung the bronchi again split into the smaller lobar bronchi and eventually the tertiary or segmental bronchi. The tracheobronchial tree then further branches into bronchioles and ends in the respiratory bronchioles. These in turn give rise to the alveolar ducts, sacs and alveoli, with which they make up the functional gas exchanging unit of the lung. These units are called acini (2).

Right and left lung are supplied with blood by the left and right pulmonary artery, respectively. A superior and inferior pulmonary vein drain blood from each side. As the pulmonary arteries enter the hilum, they become part of the root of the lung and closely follow the tracheobronchial tree's branching pattern. They become lobar and then segmental arteries (3). Nutrition and oxygen to the supporting tissues of the lungs, the root of the lungs and the visceral pleura is provided by the left and right bronchial arteries. Branches of the bronchial arteries reach as far as the respiratory bronchioles. Most the lung's venous drainage flows into the superior and inferior, left and right pulmonary veins, which connect directly to the left atrium. The pulmonary veins do not follow the course of the tracheobronchial tree. The remainder of the lungs drain into the bronchial veins. These flow into the azygous vein on the right and in the superior intercostal or accessory hemi-azygous vein on the right and eventually into the superior vena cava and right atrium (2).

1.2. Lung Cancer

1.2.1. Epidemiology and Prevalence

In 2018 there were a total of 3,021 new cases of lung cancer in Croatia and over two million new cases worldwide (4). This makes lung cancer the most common cancer as well as the most common cause of cancer deaths worldwide (5-7). While lung cancer incidence is the highest in central and eastern Europe and eastern Asia, Croatia has one of the highest incidence and mortality rates of all European countries (7,8). Most patients are diagnosed at an advanced stage of disease, and despite advances in treatment thanks to decades of research, the prognosis remains poor with very low survival rates (5,9,10). Persistent cough, chest pain, hemoptysis and weight loss are considered important symptoms of lung cancer, but are fairly unspecific (9). All of those are common symptoms of several benign conditions (11). Because stage at diagnosis is in correlation with mortality, this explains lung cancer's extraordinary mortality rates, which are higher than for any other cancer. Almost every fifth patient that dies of cancer in the world had lung cancer (7).

The incidence and mortality of lung cancer vary with age, sex, ethnicity and socioeconomic groups. Advanced age is associated with cancer and decreased survival rates in both sexes (10). The average age at diagnosis is around 70 years and older (5,10). There are differences especially in incidence between the sexes. Men have significantly higher overall incidence rates than women (7). Worldwide, lung cancer is the most common oncologic condition in men, though ranking second in more developed countries after prostate cancer. For women lung cancer's incidence is second only to breast cancer, while having one of the highest mortality rates (7,12). In 2013, lung cancer was the third most common cancer of women in Croatia and came 4th in 2018, while men were only diagnosed more often with prostate cancer (4,8). In more developed countries one can find increased rates of lung cancer as well as increased mortality (5,10). This can be explained by higher rates of smokers and a longer history of smoking in those countries.

1.2.2. Etiology

There is no doubt today that the most important risk factor and causative agent for lung cancer is cigarette smoking (5,8,12). The incidence of cancer has continuously risen since the 1930s when smoking became popular and it closely follows smoking prevalence (8,12). Even though there has not been any major breakthrough as with other malignancies, lung cancer has recently seen a decline in mortality. This is thanks to a continuous reduction in smokers and progress in early detection and treatment (6,10). In the period 2001 to 2013, data suggests that every fourth adult Croatian was an everyday smoker, which is of immense clinical importance, considering that smoking accounts for almost 90% of lung cancers (5,8).

It is known since the 1950s that there is a correlation between smoking and lung cancer. Since then scientists have identified a wide variety of carcinogens in cigarette smoke (10,13,14). This direct correlation between tobacco smoking and the development of lung cancer creates a unique potential for risk reduction. Today many countries have introduced anti-smoking campaigns and banned advertising in an effort to reduce the number of smokers (12). However, globally the total number is expected to increase to 1.9 billion by 2025, if the current trend does not change, making it a worldwide health crisis even though just 1 in 9 of those will eventually get lung cancer (10).

The amount of carcinogens and tar inhaled varies between cigarette brands, the presence and effectiveness of a filter, the duration and intensity of inhalation and how long the smoke was allowed to cool before inhalation (10). NNK (4-(methylnitrosamino)-1-(3-pyridyl)-1-butanone) and PAH (polycyclic aromatic hydrocarbon) are two of the carcinogens contained in tobacco smoke (14). NNK is considered the most important inducer of cancer by causing K-ras oncogene activation, found in 24% of lung adenocarcinomas, while PAH causes mutations in the p53 tumor suppressor gene found in about 40-60% of primary lung cancers and neither of these mutations necessarily disappear with smoking cessation (10,13). The same carcinogens are inhaled by passive smokers, however at much lower doses (13).

Approximately a quarter of all lung cancer patients worldwide are "never smokers". "Never smokers" are defined as having smoked fewer than 100 cigarettes in their lifetime. These 25% of patients are mostly women and younger patients, and have a better survival rate than smokers (5,10).

In addition to smoking there are other risk factors for lung cancer, which can be behavioral, environmental and genetic (5). They include, but are not limited to air pollution, occupational exposure to chemicals and carcinogens such as asbestos, silica dust and arsenic, infections, COPD and residential exposure to radon. Radon is the second most common risk factor after smoking, generating about 10% of cases. Asbestos is the most common occupational carcinogen, which as a group accounts for approximately 5-10% of lung cancers. How likely an individual is to develop lung cancer in part also depends on his or her genetic susceptibility (5). Furthermore, the risk of lung cancer increases multifold with a first-degree relative who previously developed the disease (5,8,10). This is why a positive family history of lung cancer can be an indication for cancer screening (15).

1.2.3. Histology/Classification

The progression from normal cells, through preneoplastic and eventually into malignant cells involves a series of changes in DNA (10). This process starts with metaplasia of the bronchial epithelium and is initially reversible. With repeated exposure to irritants and carcinogens eventually neoplastic cells with uncontrolled proliferation develop, which at this stage is called carcinoma in situ (16). At this stage, the cancer is still contained and asymptomatic. With more extensive spread and local tissue invasion, the tumor can cause obstruction, nerve damage and plural effusion (16). These can manifest as cough, pain, hemoptysis and difficulty breathing.

For simplicity, lung tumors are divided into small-cell lung carcinomas (SCLC) and non-small-cell lung carcinomas (NSCLC) (16). NSCLC make up for 85% of lung cancers and includes adenocarcinomas, squamous cell carcinomas and large cell carcinomas. Out of these, adenocarcinoma has recently become the most common subtype (10,14,17). Tumors arise more often in the right lung and in the upper lobes (17).

1.2.3.1. Small-Cell Lung Carcinoma

SCLC arise from neuroendocrine cells and bare the worst prognosis of the different lung cancer types (16). Small-cell lung carcinoma has two stages. If it is contained to one hemithorax it is called limited. If it has spread beyond a single hemithorax it is referred to as extensive stage (18). SCLCs are most often found centrally in the lung and metastasize early

(19). Metastasis can be found in many places, but most commonly in the ipsilateral pulmonary and hilar lymph nodes, mediastinal lymph nodes, the rest of the lung, liver, bone and even brain (17).

1.2.3.2. Non-Small-Cell Lung Cancer

Generally, NSCLC have a better prognosis as well as 5-year survival rate. Non-small cell lung carcinoma can be staged using the TNM system, which is based on the tumor (T), lymph node status (N) and presence/absence of metastases (M), as seen in Table 1. In addition it can be categorized into early cancer without mediastinal involvement (I/II), locally advanced cancer (III A/B) and metastatic cancer (IV) (17,18). The most common type of NSCLC, the adenocarcinoma, is typically a peripheral tumor (10,17).

Table 1. TNM Staging of Lung Cancer (20)

Tumor	
T _x	Tumor cell in sputum/bronchial washing but not assessed in imaging or bronchoscopy
T ₀	No evidence of tumor
T _{is}	Carcinoma in situ
T ₁	≤ 3cm surrounded by lung/visceral pleura, not involving main bronchus
T _{1a(mi)}	Minimally invasive carcinoma
T _{1a}	≤ 1 cm
T _{1b}	> 1 to ≤ 2 cm
T _{1c}	> 2 to ≤ 3cm
T ₂	> 3 to ≤ 5 cm or involvement of main bronchus without carina, regardless of distance from carina
T _{2a}	> 3 to ≤ 4 cm
T _{2b}	> 4 to ≤ 5 cm
T ₃	> 5 to ≤ 7 cm in greatest dimension or tumor of any size that involves chest wall, pericardium, phrenic nerve or satellite nodules in same lobe
T ₄	> 7 cm in greatest dimension or tumor with invasion of mediastinum, diaphragm, heart, great vessels, recurrent laryngeal nerve, carina, trachea, esophagus, spine or separate tumor in different lobe of ipsilateral lung
Nodes	
N ₁	Ipsilateral peribronchial and/or hilar nodes and intrapulmonary nodes
N ₂	Ipsilateral mediastinal and/or subcarinal nodes
N ₃	Contralateral mediastinal or hilar; ipsilateral/contralateral scalene/supraclavicular nodes
Metastasis	
M ₁	Distant metastasis
M _{1a}	Tumor in contralateral lung or pleural/pericardial nodule/malignant effusion
M _{1b}	Single extrathoracic metastasis, including single non-regional lymph node
M _{1c}	Multiple extrathoracic metastasis in one or more organs

1.3. Treatment Options of Lung Cancer

Lung cancer can generally be treated with radiotherapy, chemotherapy, surgery or a combination of these treatment modalities (17,18). However, small-cell lung carcinoma is widely considered inoperable due to its tendency to metastasize early and its characteristically difficult to operate tumors. Exact treatment plans are tailored to each patient based on the specific tumor and its stage, as well as the physical and mental state of the patient.

1.3.1. Radiotherapy

The use of radiotherapy in oncology is very versatile. If for any reason surgery is contraindicated for a patient with stage I/II NSCLC, radiotherapy is a good alternative. This also includes patients that refuse to undergo surgery. For early stage disease, radiotherapy can even be curative and at locally advanced stages radiotherapy often becomes the treatment of choice (17,21,22). In addition, radiotherapy can be used postoperatively and even preoperatively to improve survival (17,22). A good example for this are Pancoast tumors, also called superior sulcus tumors. Pancoast tumors are a group of tumors that penetrate the apical chest wall. They produce a special set of symptoms consisting of severe pain in the arm and shoulder, atrophy and weakening of hand muscles, Horner's syndrome and edema (23). This results out of the tumors proximity to anatomic structures like the brachial plexus, phrenic and vagus nerves, sympathetic ganglia and major blood vessels. The main treatment modality consists of perioperative chemoradiation (24).

Even though small-cell lung carcinoma is primarily treated with chemotherapy, there have been studies that show improved survival for limited stage disease with the use of concomitant radio- and chemotherapy. For advanced stages however, regardless of NSCLC or SCLC, radiotherapy is only of palliative value (16,17).

Radiation damages surrounding tissues and can have severe adverse effects, hence it is important to always weigh its benefits against potential downsides (22). Standard protocols for the radiologic treatment of lung cancer vary between countries and institutions and proper radiologic treatment involves meticulous planning for each individual patient.

1.3.2. Chemotherapy

Chemotherapy is especially of value for the treatment of small-cell lung carcinoma and for patients with metastatic disease. It is the mainstay of treatment for limited SCLC, but research also indicates that adjuvant chemotherapy can be of benefit in early stage NSCLC. If NSCLC is locally advanced and inoperable, it is best treated with a concomitant combination-agent chemotherapy and radiation (17). Exact treatment protocols vary and are tailored to the specific tumor. One well established and common treatment regimen is a cisplatin-based adjuvant therapy. Platinum-based chemotherapy to improve survival and quality of life in advanced NSCLC is another example (25). Just like radiotherapy, chemotherapy can have severe systemic toxicity. Therefore, it needs to be administered with extreme care and its value to the patient at his or her specific stage of disease needs to be thoroughly considered. A recent development has been to treat inoperable stage III NSCLC with targeted immunotherapy, such as the monoclonal antibody durvalumab or the EGFR inhibitor afatinib (26,27)

1.3.3. Surgery

Surgery is the fundamental treatment modality for early stage non-small cell lung cancer and can even improve the outcome in very localized small-cell lung carcinomas (17,21). As mentioned above, surgery can also be performed with neoadjuvant and /or adjuvant chemo- or radiotherapy. How radical the surgical resection needs to be performed depends on the stage and location of the primary tumor, and generally anatomical resections with systematic nodal resections are performed (17). Surrounding lymph nodes, most commonly mediastinal and/or hilar, are resected to check for metastasis. Regardless of the type and extent of operation, the completeness of resection, oncologic efficacy, safety and survival are the most important points to consider (28-30). Different surgical approaches will be discussed below.

Principally surgery requires a patient in good health, who is fit enough to undergo the stress of anesthesia and a lengthy recovery process. This is determined by age, cardiovascular and pulmonary function tests, comorbidities, performance status and nutrition (17,31). Especially important is the patient's pulmonary reserve as it limits the possible extent of the resection (32,33).

Surgery is indicated for stage I/II NSCLC, with lobectomy being the standard of care. It can also be applicable in conjunction with chemo- and radiotherapy for larger, locally advanced NSCLC without metastasis (31). Small-cell lung cancer is typically considered inoperable due to its tendency for early metastasis and special morphology of tumors. However, resection of small peripheral small-cell lung tumors can improve the patient's survival rate (17,31).

1.4. Thoracotomy

For a long time, if surgery was indicated, thoracotomy was the treatment of choice for lung cancer patients (28,34). Despite advances in thoracoscopic procedures, which are now the treatment of choice, posterolateral and anterolateral thoracotomies are still being performed (34,35). They are still indicated for large or difficult to reach tumors, where the posterolateral open approach enables improved exposure compared to minimally invasive techniques (36).

There are two commonly used versions of the open technique: classical posterolateral thoracotomy and muscle-sparing posterolateral thoracotomy (37). The innovation of the muscle sparing technique has been of great clinical value, as the separation of large muscles was one of the classical procedure's biggest disadvantages (36). The patient is placed in a lateral decubitus position to achieve maximum spreading of the intercostal spaces and then a cut through skin and subcutaneous tissue is performed just beneath the tip of the scapula. The incision closely follows the contour of the rib, which should be around the 6th rib (37). Once the latissimus dorsi and serratus anterior muscles are reached, the two operations differ in either transecting the muscles (classical) or separating their respective attachments and thereby sparing the muscle fibers themselves (muscle-sparing) (36). Next, the muscles in the chosen intercostal space are divided along the superior border of the lower rib, in order to avoid nerve and vascular damage, which is a common postoperative complication in thoracotomies (35,37). Then, after rib retraction, the pleural space can be entered, and the necessary resection performed. After a drainage is placed, the incision is closed stepwise in order to achieve the best healing outcome, starting with pericostal sutures. These are followed by subcutaneous and skin sutures. Finally the chest drains is fixed to the skin (37).

When thoracoscopic operations are performed, there may be complications like major bleeding, incomplete lung collapse, dense adhesions and other unforeseen technical,

anatomical and oncological issues. In those cases, it may be necessary to convert the operation to an open thoracotomy (38-40). This is achieved by either connecting multiple ports, if present, or enlarging the single incision in case of a uniportal approach. However, unplanned conversion bare higher risks of morbidity, mortality and cancer recurrence and should therefore be avoided if possible (38,41).

An open thoracotomy is a major surgery and bares general surgical risks connected to general anesthesia, bleeding and infection. In addition, there are some well-established disadvantages of an open thoracotomy specifically. As mentioned above one of the most common problems of the non-muscle-sparing technique is a postoperative limitation in muscle movements of the chest and shoulder girdle (36). It limits early mobilization and requires extensive physical therapy. Another complication is severe postoperative pain. A large portion of patients suffer of chronic pain syndromes and require analgesic treatment for months or years. This results out of damage to intercostal nerve fibers during spreading of the and/or incision in the intercostal space. In some cases, a rib may even be fractured in this process (37).

1.5. Thoracoscopy

The first thoracoscope was invented by Jacobaeus, a Swedish doctor, at the beginning of the 20th century and since the 90s multiportal VATS has firmly established itself in the world of thoracic surgery (29,39). This minimally invasive approach to lung surgery has many advantages, also seen in other fields that apply keyhole surgery. Those include: smaller incisions and therefore better cosmetic results, less postoperative pain, reduced blood loss, faster recovery and thereby hospital stay, and decreased morbidities and mortality (39,42,43). Modern thoracoscopic procedures can be categorized by the specific surgical approach, into multiportal and uniportal VATS.

1.5.1. Multiportal VATS

VATS stands for video-assisted thoracic surgery and multiportal refers to the number of incisions used by the surgeon. After it was proven that multiportal VATS lobectomy had an equivalent oncological efficacy for lung cancer as open thoracotomy and was a safe procedure, it quickly became the new gold standard of care for lung cancer in many institutions (28,34,44).

VATS is performed under general anesthesia with the patient being in a lateral decubitus position just like in the open procedure. Usually double-lumen intubation is used in order to facilitate the ventilation of only one side of the lung (45). The exact number of ports or trocars vary but most common are triportal or biportal approaches that require incisions of 3-5 cm (29,41,46). Once the pleural space is entered, the steps are almost identical to resection via thoracotomy (43). At the University Hospital of Split most multiportal VATS are performed utilizing only two ports. One for the operative tools and one utility port for the thoracoscope and later drain placement.

Contraindications for video-assisted thoracic surgery are very large tumors that cannot be evacuated through the small incisions and such tumors that are too locally invasive or advanced in order to be sufficiently resected via this approach (38,47).

1.5.2. Uniportal VATS

1.5.2.1. Definition

Uniportal refers to the amount of ports or openings used during the operation. Therefore "Uniportal VATS" describes a minimal invasive, laparoscopic surgical technique that utilizes one single, small incision in the chest wall (29,45).

1.5.2.2. History

Multiportal VATS has existed for decades in the world of thoracic surgery and has proven to be advantageous in many ways, as discussed above. Since then, surgeons have continuously thrived to further reduce the invasiveness of operations in the hope to increase postoperative quality of life, without compromising safety and oncological efficacy (46,48).

This ultimately led to the introduction of uniportal VATS, which was first depicted by Rocco and colleagues (45). At first, the uniportal approach was utilized mainly for minor thoracic procedures like treatment of pneumothorax, biopsies, wedge resections and evacuation of hemothorax (39). There were doubts about uniportal VATS being suitable for more complicated procedures in regard to its safety and oncologic results (41,49,50). However, multiple studies in recent years have eliminated these doubts to the most extent and proven that the uniportal approach is safe, and at least equivalent to the gold standard (29,51,52).

The evolution of uniportal VATS mainly became possible due to the development of better video cameras, improved energy devices and specialized surgical equipment such as articulated endoscopic staplers and curved, thinner instruments (29,49,53). The pinnacle of this progress was in 2010, when Gonzalez-Rivas executed the first uniportal lobectomy for early stage lung cancer (29,42). Since this milestone the uniportal technique has become widely used for major, more complicated surgeries such as lobectomies, vascular reconstruction and sleeve lobectomies (29,39,42,54).

1.5.2.3. Procedure

Uniportal VATS is performed under general anesthesia with double-lumen intubation (40,44). The patient is placed in a lateral decubitus position just like in the open and multiportal techniques (44,45). A single incision of 4-6 cm is made in the 4th to 6th intercostal space, either in the mid-axillary line or the anterior chest wall. The location of the incision largely depends on the position of the pulmonary lesion (44,53). The leading surgeon and his assistant both stand in front of the patient, as seen in Figure 1 (42).

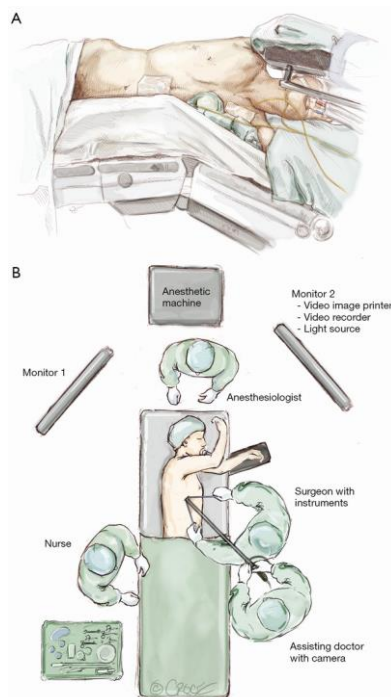


Figure 1. Position of Surgeons and Patient (55)

Dr. Beth Croce, Medical Illustrator for the *Annals of Cardiothoracic Surgery*

Most often, a 30-degree thoracoscope is used (34,53). The single access is used for camera entry, surgical instruments as well as specimen retrieval at the end of the operation (48,51). The idea is to create conditions similar to the open technique, only with the operative fulcrum moved into the chest cavity (40). This creates a parallel orientation of instruments and the thoracoscope, which facilitates improved eye-to-hand coordination and preserves depth of the visual field (41,48). To provide the best overview of the operating field the camera is kept most of the time in the posterior (upper) edge of the incision (55).

The exact sequence of the operation differs with the type of resection and anatomical variation. A commonly applied order is to first dissect the pulmonary vein, then the artery and at last the main bronchus (44,45). To perform a left lower lobectomy, the lung is retracted, and the pulmonary ligament is exposed. The ligament is then cut open in order to reveal the pulmonary vein. Next the pulmonary artery and then the bronchus are divided. The resection is completed by division of the fissure (55). Fissure and blood vessels are divided by staplers if possible. Sometimes the angle is too awkward to use a stapler, in which case vascular clips or sutures may be used. Once resected, the lobe is removed in a protective bag.

For a right lower lobectomy, the steps are essentially the same as for the left side. However, special attention must be directed to identifying and avoiding the bronchus and artery of the middle lobe. This may require the removal of inter-bronchial lymph nodes before dividing the artery.

To perform a left upper lobectomy, it is recommended to initially divide the upper arterial trunk. After that step, the upper lobe vein is divided (47). At last the bronchus and fissure are stapled. In order to achieve a right upper lobectomy similar steps are followed. As with lower right lobectomy, middle lobe structures must be identified and protected before the fissure is divided. The middle lobe is resected by first cutting the anterior part of the major fissure. This exposes the vein and enables its dissection. Next, the bronchus is revealed and stapled. Finally, the medial segmental artery and then the remaining of portion of the fissure are divided (45).

After resection of the lung is accomplished and the specimen is removed in an endobag to avoid tumor seeding and spillage of tumor contents (48,53,55). Then surgeon carries out a systematic lymph node dissection (53). In order to remove subcarinal, paratracheal and hilar lymph nodes, the operating table is moved into different positions. This moves the lung and

provides better angles for resection (45). Once completed, the incision is closed by suturing the muscles and subcutaneous tissue, without applying intercostal sutures, and a chest drain is placed (47,53).

1.5.2.4. Indications and Advantages

Uniportal VATS has similar prerequisites as multiportal VATS in regard to patient selection, and the same preoperative check-ups as for any surgical patient should be carried out (55). In addition, research suggests that the uniportal technique may be more suitable for elderly patients and patients with poor pulmonary reserve (41).

When uniportal VATS first entered the field of thoracic surgery, possible advantages included decreased postoperative pain, shorter hospital stays and earlier mobilization (39,53). However, many studies have shown that there is no difference between uniportal and multiportal treatment outcomes except in regards of pain control (49,56). Still, these studies also show as mentioned previously, that uniportal VATS is safe and has comparable oncological results.

Uniportal VATS has some benefits over its multiportal counterpart, nonetheless. It provides a more direct view of the structures of interest and anatomy inside the chest (51). In addition, the parallel orientation of instruments and thoracoscope technically make the operation easier and prevents awkward angles that are intrinsic to the multiportal technique (44).

1.5.2.5. Contraindications and Limitations

Contraindications are mostly concerned with tumor size as well as competency and comfort of the surgeon (45,47). If the tumor is too large to be retrieved through the single incision or too difficult to reach, the uniportal technique may not be applicable. Furthermore, the small single incision can become crowded by the camera and several surgical instruments, which may be interfering with each other inside the pleural space (49). This however can be limited with long, thin and angulated specialized instruments (45). Some medical institutions also mention the issue of not being able to palpate and identify small lesions through the incision (44,47). Uniportal VATS requires a lot of experience and training. It's learning curve

is strongly influenced by the number of performed surgeries and previous experience with minimally invasive techniques (52).

As with any operation there are risks connected to infection and anesthesia. The limited space in the uniportal technique can make it difficult to control bleeding. Additionally, prolonged air leak may result out of an improper resection of a bronchus. Major bleeding, technical difficulties or anatomical variations may make a conversion to an open operation necessary (39).

1.5.2.6. Further Developments

In 2014, Liu *et al.* performed the first successful left upper lobectomy through a subxiphoid incision. The subxiphoid approach is a variation of uniportal VATS. It utilizes a single incision just below the sternum, as the name suggests. The location of the incision has the advantage that it is not limited by the intercostal spaces. That means that intercostal nerve damage can completely be avoided and simplifies specimen retrieval. In addition, the subxiphoid approach provides an improved view on hilar structures and produces better cosmetic results.

On the other hand, it has been noted that major bleeding may be difficult to control and special instruments, as well as surgical training are required to ensure safety and efficacy (39,41).

Another recent advance in thoracic surgery has been to perform surgery on an awake, non-intubated patient (42). An epidural catheter, paravertebral and vagal nerve blocks achieve the required anesthesia. This technique was originally developed to avoid postoperative complications associated with intubation such as airway injuries, ventilation-related injuries, nausea, vomiting and pneumonia. It requires a very competent anesthesiologist, capable of immediate conversion to intubated general anesthesia and the surgeon must have a clear conversion plan in case of any complications. Extensive previous experience with minimally invasive surgery is of utmost importance. In addition, patients must be carefully selected. Obesity, coagulation disorders, non-compliance for awake surgery, ASA score above two and hemodynamic instability are all contraindications for the non-intubated approach (39).

2. OBJECTIVES

AIMS:

1. Determine the surgical duration, duration of chest drainage, and length of postoperative period for the 3 different surgical techniques.
2. Compare the parameters among the 3 techniques to find differences and possible superiorities.

HYPOTHESIS:

Uniportal VATS is a superior procedure (measured by surgical duration, duration of chest drainage, and length of postoperative period) compared to multiportal VATS and open thoracotomy for the treatment of lung cancer.

3. SUBJECTS AND METHODS

3.1. Data Collection

Patient data was obtained from the archives of the Department of Surgery, University Hospital of Split. Data collected was the age, name and gender of each patient, his or her diagnosis, the dates of admission, release and operation, the type and length of operation and duration of chest drainage.

3.2. Subjects

Any patient that was surgically treated for lung cancer at University Hospital Split in the years 2016, 2017 and 2018 was included in the original data sampling. The first operation recorded was on the 7th of January 2016 and the last on the 15th of November 2018. In some instances, it was not possible to cross-reference a release document with the corresponding patient file and those patients were excluded due to insufficient data. Patients that didn't undergo either uniportal VATS, multiportal VATS or open thoracotomy were excluded as well. After exclusion there was a total of 150 patients included in the retrospective study.

3.3. Description of the Study

The subjects were grouped into five study groups according to the type of operation they underwent. The three main groups: Open Thoracotomy, Multiportal VATS, Uniportal VATS and two subgroups in which operations had to be converted to an open procedure: Converted Multiportal VATS and Converted Uniportal VATS. In the three main study groups there were 114 patients, while the two conversion groups included 36 patients in total. In order to evaluate the different types of operations and compare the three main study groups, three parameters were calculated and defined as primary outcomes measures of the study.

3.3.1. Primary Outcomes

The primary outcomes of this retrospective study were:

- The duration of the operation obtained from the surgical protocol, measured in minutes
- The recovery time, which is the difference of the date of operation and the date of release, measured in days
- The duration of chest drainage, starting from the day of operation until the day the drain was removed, measured in days

3.3.2. Secondary Outcomes

Secondary outcomes were the age and gender of each patients as well as the conversion rates of uniportal and multiportal VATS operations, respectively.

3.4. Statistical Analysis

Statistical analyses were performed using statistical software MedCalc for Windows, version 19.0.4 (MedCalc Software, Ostend, Belgium). Continuous data was expressed as medians with 95% confidence intervals, while categorical data was presented as whole numbers and percentages.

Chi-square tests were performed for gender and conversion ratio comparisons, with a *P* value <0.05 being statistically significant. Age, operation duration, recovery time and drainage duration were all compared among the different study groups using the Kruskal Wallis test, also with a *P* value <0.05 being statistically significant.

4. RESULTS

A total of 150 patients were included in the study. Patient ages ranged from 18 to 79 years. From total number of patients, 94 were male (62.67%) and 56 patients female (37.33%). Table 2 shows the age and gender distribution among the main study groups. There was no statistically significant difference in age and gender between them. The median age of patients in all three groups was above 60 years.

Table 2. Gender and Age Distribution

(N=114)	Multiportal VATS (N=59)	Uniportal VATS (N=32)	Open Thoracotomy (N=23)	<i>P</i>
Female gender (n, %)	23 (39)	17 (53.1)	5 (21.7)	0.287*
Age (years)	63(59.5-65.0)	64.5 (61.9- 67.0)	64 (57.3-69.0)	0.569†

Data are presented as median (95% CI) or as absolute number (%)

* Chi Square test

† Kruskall Wallis test

The operation parameters for the investigated 3-year period are summarized in Table 3. When an operation is first attempted in a minimally invasive fashion and then must be converted for any reason, it inherently becomes a longer intervention and is often followed by a prolonged recovery period. Therefore, the study only compares operation parameters among the three main groups which maintained their respective operation method without being converted.

Table 3. Operation Parameters

(N=114)	Multiportal VATS (N=59)	Uniportal VATS (N=32)	Open Thoracotomy (N=23)	<i>P*</i>
Operation duration (min)	150 (120.0- 180.0)	110 (70.0- 150.0)	145 (120.0- 180.4)	0.093
Recovery time (days)	7 (7.0-7.0)	7 (6.0-8.0)	9 (7.0-11.0)	0.086
Drainage duration (days)	5 (4.0-5.0)	5 (4.0-5.0)	6† (5.0-7.0)	0.016

Data are presented as medians (95% CI)

* Kruskall Wallis test

† Significantly different than other two groups.

All operations assessed in Table 3 were major lung resections such as pneumectomies, lobectomies and sub-lobar resections. Over the last 3 years, most patients were operated by multiportal VATS (N=59). This was followed by uniportal VATS with 32 patients. Only 23 patients were originally operated by open thoracotomy.

Operation duration, recovery period and drainage duration were determined as good outcome measures in order to assess a potential superiority of one of the procedures, particularly uniportal VATS. Statistical analysis using the Kruskal Wallis test showed that there was only a statistically significant difference in drainage duration ($P=0.016$), with open thoracotomy having a significantly longer chest drainage time than the other two operation methods.

Table 4 presents, how many multiportal and uniportal VATS procedures had to be converted for any reason. The Chi-square test was performed and showed no statistically significant difference in conversion rates between the two operations.

Table 4. Conversion to Open Thoracotomy

	Multiportal VATS	Uniportal VATS	<i>P</i>*
Total	87	40	
Converted	28	8	
Conversion Ratio	0.32	0.20	0.283

*Chi-square

Uniportal VATS has only been performed for a few years at the University Hospital of Split. The obtained data was therefore additionally examined for each individual study year in order to see whether there was a learning curve manifesting itself by a decline in uniportal VATS operation duration over time. However, there was no clear trend to be seen. Although this was in part due to missing data sets, which made the construction of a graph impossible.

5. DISCUSSION

Uniportal VATS has been routinely performed in the last few years for the treatment of lung cancer at the University Hospital of Split. At the same time, open thoracotomies and multiportal VATS have been continuous treatment modalities for lung cancer. In this retrospective study we examined whether uniportal VATS can be considered a superior surgery compared to multiportal VATS and thoracotomy. In order to compare the different procedures, outcome measures that reflect efficiency of the operations and postoperative quality of life had to be defined. In our study these parameters were limited to the duration of the surgery itself, the recovery period defined as the time between the operation and the release from the hospital, and the duration of the thoracic drainage.

Following the rising popularity of uniportal VATS in recent years there have been many studies comparing it to the current choice of treatment, multiportal VATS, and open thoracotomy. At first, uniportal VATS had to prove its safety for the patient in order to even be considered as an alternative. Additionally, when used for the treatment of lung cancer, the oncological efficacy of uniportal VATS is of utmost importance (29). Safety of a procedure is typically assessed by mortality and conversion rates. In our study there was no significant difference in the conversion rates of uniportal and multiportal VATS suggesting a comparable risk and safety of the two procedures. This finding is in concordance with research done in Germany and Taiwan (42,48). Furthermore, other studies have found similar mortality and morbidity between the minimally invasive operations, while being significantly lower compared to open thoracotomy (39). Oncologic efficacy can be measured in two ways: the number of lymph nodes and lymph nodes stations during resection and long-term survival and recurrence rates (30). Despite doubts it has now been demonstrated in multiple studies that comparable standards of resection between uniportal and multiportal VATS as well as open thoracotomy are possible (28).

After establishing uniportal VATS safety and oncologically equivalence, it makes sense to look at potential benefits compared to the gold standard treatment. Uniportal VATS utilizes only a single incision which, compared to the multiportal or open surgery, produces much less trauma. Probably the most commonly suggested advantage of uniportal VATS has been reduced postoperative pain as a direct result of its reduced invasiveness (53). Other proposed benefits are a shorter hospital stay, leading to reduced costs and a shortened recovery period (39). In our study we did not investigate the postoperative pain of patients. This is because it requires data collected in the form of a pain scoring system like the analog pain scale for each patient.

Not only is this data a subjective measurement, but it is also not routinely collected at the University Hospital of Split and therefore impossible to gather in a retrospective manner. However, multiple studies have found lower postoperative pain scores and pain for uniportal VATS (29,39,44).

In our study we assessed the postoperative outcome by measuring the length of the immediate recovery period. This was defined as starting after the surgery and ending with the release of the patient from the hospital. A less invasive surgery should lead to a quicker recovery. Furthermore, if there were and intra-or postoperative complications, they should be reflected in a prolonged hospital stay. Despite this assumption, we did not observe any statistical difference in recovery time between uniportal VATS, multiportal VATS and open thoracotomy. These results have been reproduced in other studies and suggest the need for further investigations of the actual impact of the type of surgery on the duration of the recovery period following lung cancer (44,51). Another postoperative outcome we investigated was how long a chest drainage was necessary. As mentioned previously, prolonged air leakage may be a complication of lung surgery. Therefore, we selected chest drain duration as an easy to assess surrogate for general postoperative complications and intraoperative precision. Results showed that patients operated for lung cancer with an open thoracotomy required a chest drain for significantly longer time than uniportal and multiportal VATS techniques. They also showed that there was no statistical difference in drainage time between the two minimally invasive groups.

Other studies have demonstrated mixed results regarding chest drainage. Some have found that there is no difference between surgical techniques whatsoever, while others suggest that the drainage duration is reduced with uniportal VATS (44,48,56). It seems possible that the extent of the lung resection, comorbidities and other factors related to pulmonary function and anesthesia affect the exact results. Therefore, we would suggest that in further studies a more standardized approach should be taken in order to decrease possible variables as much as possible.

The third parameter we investigated in our study was the operation duration. This was obtained from the surgery documentation forms of each patient. How long an operation takes on average can give a good indication on how readily it can be performed and how complex it is. Furthermore, if looked at over a period of time, it can project a learning curve of the surgeon.

In our study operation times did not significantly differ between the three investigated operations throughout the last three years. Again, these results confirmed the findings of other studies (44,48). Operations that had to be converted had very long durations. This, however, is to be expected as a minimally invasive attempt followed by a conversion and after that an open procedure, naturally requires more time. Therefore, we excluded converted operations from the comparisons.

Since the overall patient data was incomplete with regard to the operation time and - as far as recorded, the operation durations did not show a decreasing trend over the investigated 3-year period, we were not in a position to comment on a learning curve regarding VATS.

Overall, our analysis confirms the trend of other studies that compare uniportal VATS with other treatment modalities for the treatment of lung cancer. Uniportal VATS is safe and although not investigated by us, seems to provide equivalent oncologically results as multiportal VATS and open thoracotomy (28,29). Generally, uniportal VATS can reach equivalent outcomes to its multiportal counterpart and both minimally invasive techniques appear to be superior to open thoracotomy in certain aspects. In order to say whether or not uniportal VATS is superior to multiportal VATS for the treatment of lung cancer, however, requires further research and especially long-term studies. Most patients in Split have been operated for lung cancer by multiportal VATS, which is the current international treatment of choice. At this stage though, uniportal VATS can be a viable alternative and its utilization probably depends on the surgeon's preference.

Our study has several limitations. First, we did not take the tumor staging of each patient into account. The size and invasiveness of a tumor can have great effects on the course of an operation. Even though most patients included in the study underwent a lobectomy, other types of resections were included which might have further limited the validity of parameters like operation time and drainage duration. Second, the surgeries included were carried out by different surgeons. This makes it harder to compare them, as each individual surgeon might be more comfortable with a different operation modality and therefore affect the outcome measures.

In order to determine the future role of uniportal VATS for lung cancer treatment at the University Hospital of Split and other medical centers, more investigations are needed. They should include additional parameters like postoperative pain scores, intraoperative blood loss, cancer recurrence and long and short-term survival rates. The data collection should be performed in a prospective manner. This would make it possible to follow the patients throughout the treatment process as well as ensure that all variables of interest are being recorded. Moreover, more significant results could be obtained if patients are divided by their tumor stage and operations are grouped according to the extent of resection.

6. CONCLUSIONS

1. Open thoracotomy patients had a significantly longer duration of chest drainage than patients that underwent uniportal VATS or multiportal VATS operations.
2. There was no significant difference in the duration of chest drainage between uniportal VATS and multiportal VATS
2. There was no significant difference in the recovery time of patients undergoing open thoracotomy, uniportal VATS or multiportal VATS.
4. There was no significant difference in the operation duration between open thoracotomy, uniportal VATS or multiportal VATS.

7. REFERENCE

1. StatPearls [Internet]: StatPearls Publishing; Anatomy, Thorax, Lungs.; 2019. Available from: <https://www.ncbi.nlm.nih.gov/pubmed/>.
2. Moore KL, Dalley AF, Agur AMR. Clinically Oriented Anatomy. 7 ed: Lippincott Williams and Wilkins; 2014. p. 106-20.
3. Medscape.com [Internet]. Lung Anatomy: Overview, Gross Anatomy, Microscopic Anatomy. 2017. Available from: <https://emedicine.medscape.com/article/1884995-overview>.
4. Gco.iarc.fr [Internet]. Globocan: Cancer Today; March 2019. Available from: <https://gco.iarc.fr/today/home>
5. de Groot PM, Wu CC, Carter BW, Munden RF. The epidemiology of lung cancer. *Transl Lung Cancer Res.* 2018;7:220-33.
6. Siegel RL, Miller KD, Jemal A. Cancer statistics, 2018. *CA Cancer J Clin.* 2018;68:7-30.
7. Ferlay J, Soerjomataram I, Dikshit R, Eser S, Mathers C, Rebelo M, *et al.* Cancer incidence and mortality worldwide: sources, methods and major patterns in GLOBOCAN 2012. *Int J Cancer.* 2015;136:359-86.
8. Siroglavić KJ, Polić Vižintin M, Tripković I, Šekerija M, Kukulj S. Trends in incidence of lung cancer in Croatia from 2001 to 2013: gender and regional differences. *Croat Med J.* 2017;58:358-63.
9. Sung MR, Leigh NB. Improving lung cancer diagnosis: the evolving role of patients and care providers. *J Thorac Dis.* 2019;11:422-4.
10. Dela Cruz CS, Tanoue LT, Matthay RA. Lung Cancer: Epidemiology, Etiology, and Prevention. *Clin Chest Med.* 2011;32:605-44.
11. Hamilton W, Peters T, Round A, Sharp D. What are the clinical features of lung cancer before the diagnosis is made? A population based case-control study. *Thorax.* 2005;60:1059-65.
12. Ridge CA, McErlean AM, Ginsberg MS. Epidemiology of Lung Cancer. *Semin Intervent Radiol.* 2013;30:93-8.
13. Vineis P, Alavanja M, Buffler P, Fontham E, Franceschi S, Gao YT, *et al.* Tobacco and cancer: recent epidemiological evidence. *J Natl Cancer Inst.* 2004;96:99-106.
14. Pfeifer GP, Denissenko MF, Olivier M, Tretyakova N, Hecht SS, Hainaut P. Tobacco smoke carcinogens, DNA damage and p53 mutations in smoking-associated cancers. *Oncogene.* 2002;21:7435-51.
15. Tammemägi MC, Katki HA, Hocking WG, Church TR, Caporaso N, Kvale PA, *et al.* Selection Criteria for Lung-Cancer Screening. *N Engl J Med.* 2013;368:728-36.

16. Damjanov I. Pathology for the Health Professions. 4 ed: Elsevier Inc.; 2012. p. 188-91
17. Barrett Deatrck K, Long J, Chang AC. Thoracic Wall, Pleura, Mediastinum & Lung. In: Doherty GM, editor. Current Diagnosis & Treatment: Surgery. 14 ed: Lange; 2015. p. 378-85.
18. MerckManuals.com [Internet]. Merck & Co., Inc.; Lung Carcinoma; 2016. Available from: <https://www.merckmanuals.com/professional/pulmonary-disorders/tumors-of-the-lungs/lung-carcinoma#sec05-ch062-ch062b-1405>.
19. See K, Barnett S, Manser R, Barnes H. Surgery for limited-stage small-cell lung cancer. Cochrane Database Syst Rev. 2017;4 doi:10.1002/14651858.CD011917.pub2.
20. Detterbeck FC, Boffa DJ, Kim AW, Tanoue LT. The Eighth Edition Lung Cancer Stage Classification. Chest. 2017;151:193-203.
21. Schwartz RM, Alpert N, Rosenzweig K, Flores R, Taioli E. Changes in quality of life after surgery or radiotherapy in early-stage lung cancer. J Thorac Dis. 2019;11:154-61.
22. Baker S, Dahele M, Lagerwaard FJ, Senan S. A critical review of recent developments in radiotherapy for non-small cell lung cancer. Radiat Oncol. 2016;11:115.
23. Marulli G, Battistella L, Mammana M, Calabrese F, Rea F. Superior sulcus tumors (Pancoast tumors). Ann Transl Med. 2016;4:239.
24. Nikolaos P, Vasilios L, Efstratios K, Panagiotis A, Christos P, Nikolaos B, *et al*. Therapeutic modalities for Pancoast tumors. J Thorac Dis. 2014;6:180-93.
25. Wakelee H, Kelly K, Edelman MJ. 50 Years of Progress in the Systemic Therapy of Non-Small Cell Lung Cancer. Am Soc Clin Oncol Educ Book. 2014:177-89.
26. Visconti R, Morra F, Guggino G, Celetti A. The between Now and Then of Lung Cancer Chemotherapy and Immunotherapy. Int J Mol Sci. 2017;18:1374.
27. Jain NA, Otterson GA. Immunotherapy in inoperable stage III non-small cell lung cancer: a review. Drugs Context. 2019;8:212578.
28. Sihoe AD. Reasons not to perform uniportal VATS lobectomy. J Thorac Dis. 2016;8:333-43.
29. Ng CSH, Gonzalez-Rivas D, D'Amico TA, Rocco G. Uniportal VATS—a new era in lung cancer surgery. J Thorac Dis. 2015;7:1489-91.
30. Reddy RM. Long-term outcomes and quality of life should be the future focus of research measuring effectiveness of lung cancer surgery approaches. J Thorac Dis. 2019;11:361-3.
31. Fountain SW. Guidelines on the selection of patients with lung cancer for surgery. Thorax. 2001;56:89-108.

32. Shamji FM. Absolute and relative contraindications to pulmonary resection: effect of lung cancer surgery guidelines on medical practice. *Thorac Surg Clin.* 2013;23:247-55.
33. Cancer.org [Internet] American Cancer Society; Surgery for Non-Small Cell Lung Cancer Internet; 2016. Available from: <https://www.cancer.org/cancer/non-small-cell-lung-cancer/treating/surgery.html>.
34. Salati M, Rocco G. The uni-portal video-assisted thoracic surgery: achievements and potentials. *J Thorac Dis.* 2014;6:618-22.
35. Leandro JD, Rodrigues OR, Slaets AFF, Schmidt AF, Yaekashi ML. Comparison between two thoracotomy closure techniques: postoperative pain and pulmonary function. *J Bras Pneumol.* 2014;40:389-96.
36. Loscertales J, Congregado M, Moreno S, Jimenez-Merchan R. Posterolateral thoracotomy without muscle division: a new approach to complex procedures. *Interact Cardiovasc Thorac Surg.* 2012;14:2-4.
37. Durrleman N, Massard G. Posterolateral thoracotomy. *Multimed Man Cardiothorac Surg.* 2006; DOI:10.1510/mmcts.2005.001453
38. Hanna JM, Berry MF, D'Amico TA. Contraindications of video-assisted thoracoscopic surgical lobectomy and determinants of conversion to open. *J Thorac Dis.* 2013;5:182-9.
39. Mineo TC, Ambrogi V. A glance at the history of uniportal video-assisted thoracic surgery. *J Vis Surg.* 2017;3:157.
40. Rocco G, Martucci N, La Manna C, Jones DR, De Luca G, La Rocca A, *et al.* Ten-year experience on 644 patients undergoing single-port (uniportal) video-assisted thoracoscopic surgery. *Ann Thorac Surg.* 2013;96:434-8.
41. Nardini M, Bilancia R, Dunning J. Perspective on uniportal thoracic surgery: where do we stand and what is the future. *J Vis Surg.* 2017;3:164.
42. Ismail M, Helmig M, Swierzy M, Neudecker J, Badakhshi H, Gonzalez-Rivas D, *et al.* Uniportal VATS: the first German experience. *J Thorac Dis.* 2014;6:650-5.
43. Lacin T, Swanson S. Current costs of video-assisted thoracic surgery (VATS) lobectomy. *J Thorac Dis.* 2013;5:190-3.
44. Wang L, Liu D, Lu J, Zhang S, Yang X. The feasibility and advantage of uniportal video-assisted thoracoscopic surgery (VATS) in pulmonary lobectomy. *BMC Cancer.* 2017;17:75.
45. Gonzalez-Rivas D, Fieira E, Delgado M, Mendez L, Fernandez R, de la Torre M. Uniportal video-assisted thoracoscopic lobectomy. *J Thorac Dis.* 2013;5:234-45.

46. Nachira D, Meacci E, Ismail M, Gonzalez-Rivas D, S. M. Why to change from multiportal to uniportal VATS? *Video-assist Thorac Surg.* 2018;3:14.
47. Ismail M, Swierzy M, Nachira D, Rückert JC, Gonzalez-Rivas D. Uniportal video-assisted thoracic surgery for major lung resections: pitfalls, tips and tricks. *J Thorac Dis.* 2017;9(4):885-97.
48. Chang JM, Kam KH, Yen YT, Huang WL, Chen W, Tseng YL, *et al.* From biportal to uniportal video-assisted thoracoscopic anatomical lung resection: A single-institute experience. *Medicine (Baltimore).* 2016;95:e5097.
49. Migliore M, Calvo D, Criscione A, Borrata F. Uniportal video assisted thoracic surgery: summary of experience, mini-review and perspectives. *J Thorac Dis.* 2015;7:378-80.
50. Solaini L, Prusciano F, Bagioni P, Di Francesco F, Basilio Poddie D. Video-assisted thoracic surgery major pulmonary resections. Present experience. *Eur J Cardiothorac Surg.* 2001;20:437-42.
51. McElnay PJ, Molyneux M, Krishnadas R, Batchelor TJP, West D, Casali G. Pain and recovery are comparable after either uniportal or multiport video-assisted thoracoscopic lobectomy: an observation study. *Eur J Cardiothorac Surg.* 2014;47:912-5.
52. Nachira D, Meacci E, Porziella V, Vita ML, Congedo MT, Chiappetta M, *et al.* Learning curve of uniportal video-assisted lobectomy: analysis of 15-month experience in a single center. *J Thorac Dis.* 2018;10:3662-9.
53. Gonzalez D, Paradela M, Garcia J, Dela Torre M. Single-port video-assisted thoracoscopic lobectomy. *Interact Cardiovasc Thorac Surg.* 2011;12:514-5.
54. Reinersman JM, Passera E, Rocco G. Overview of uniportal video-assisted thoracic surgery (VATS): past and present. *Ann Cardiothorac Surg.* 2016;5:112-7.
55. AD S. Uniportal video-assisted thoracoscopic lobectomy. *Ann Cardiothorac Surg.* 2016;5:133-44.
56. Akter F, Routledge T, Toufektzian L, Attia R. In minor and major thoracic procedures is uniport superior to multiport video-assisted thoracoscopic surgery? *Interact Cardiovasc Thorac Surg.* 2015;20:550-5.

8. SUMMARY

Objectives: The aim of this study was to determine the operation duration, chest drainage duration and length of postoperative hospital stay for lung cancer patients that underwent either uniportal VATS, multiportal VATS or open thoracotomy surgeries at the University Hospital of Split in the observed period. Furthermore, the study compared the three operation techniques, using the determined parameters, in order to investigate possible superiorities or inferiorities between them.

Subjects and Methods: From January 2016 until December 2018, 150 patients (94 males and 56 females) who underwent surgery for the treatment of lung cancer at the Department of Surgery, University Hospital of Split, were included in the retrospective study. Patients were divided according to the type of surgery they underwent. There were three main groups: Multiportal VATS (N=59), Uniportal VATS (N=32) and Open Thoracotomy (N=23). These groups were compared regarding operation duration, chest drainage duration and length of postoperative hospital stay. In addition, two subgroups for converted uniportal and multiportal VATS operations were formed.

Results: The median age of the included patients was 64 years (18-79 years). Most patients were operated by multiportal VATS (87), of which 28 operations had to be converted to an open operation. The second most frequent operation was uniportal VATS (40), with a total of 8 conversions needed. There was no statistical difference in the operation's respective conversion ratios ($p=0.283$). When comparing non-converted uniportal VATS and multiportal VATS with open thoracotomies there was no statistically significant difference between gender distribution ($p=0.287$), age ($p=0.569$), operation durations ($p=0.093$) or postoperative recovery times ($p=0.086$). The drainage duration was significantly longer in open thoracotomies (6 days) compared to the two minimally invasive operations ($p=0.016$). There was no difference between uniportal VATS (5 days) and multiportal VATS (5 days) with respect to drainage duration.

Conclusion: This study shows that minimally invasive operation techniques, namely multiportal and uniportal VATS, are in many cases better suited surgeries for the treatment of lung cancer than an open thoracotomy. This is in concordance with the findings of other recent

studies and reflected in multiportal VATS being the gold standard of lung cancer treatment. However, there is no clear superiority of uniportal VATS over multiportal VATS to be observed, despite its even less invasive nature. On the other hand, the results also show no drawbacks between the two techniques, suggesting an equivalent clinical value of uniportal VATS in the treatment of lung cancer.

9. CROATIAN SUMMARY

Naslov: UNIPORTALNI VATS U LIJEČENJU KARCINOMA PLUĆA U KLINIČKOM BOLNIČKOM CENTRU SPLIT

Ciljevi: Cilj ovog rada bio je utvrditi trajanje operacije, trajanje drenaže prsnog koša i trajanje poslijeoperacijske hospitalizacije bolesnika s karcinomom pluća koji su podvrgnuti uniportalnom VATS-u, multiportalnom VATS-u i torakotomijskim postupcima u Kliničkom bolničkom centru Split, u promatranom razdoblju. Nadalje, koristeći utvrđene parametre, studija je uspoređivala tri operacijske tehnike u smislu moguće superiornosti ili inferiornosti među njima.

Ispitanici i metode: Od siječnja 2016. do prosinca 2018. u retrospektivnu studiju uključeno je 150 bolesnika (94 muškarca i 56 žena) koji su na kirurškom odjelu Kliničke bolnice Split podvrgnuti operaciji liječenja karcinoma pluća. Prema vrsti operacije kojoj su podvrgnuti, ispitanici su podijeljeni u tri glavne skupine: ispitanici liječeni multiportalnim VATS - om (N = 59), uniportalnim VATS - om (N = 32) i otvorenom torakotomijom (N = 23). Te skupine ispitanika uspoređene su s obzirom na trajanje operacije, trajanje drenaže prsnog koša i duljinu postoperativnog boravka u bolnici. Osim toga, formirane su dvije podskupine za konvertirane uniportalne i multiportalne VATS zahvate.

Rezultati: Medijan dobi uključenih ispitanika je 64 godine (18-79 godina). Većina ispitanika operirana je multiportalnim VATS-om (87), od čega je 28 operacija konvertirano u otvorenu operaciju. Druga najčešća operacija bila je uniportalni VATS (40), s ukupno 8 potrebnih konverzija. Nije dokazana statistički značajna razlika u stopi konverzije u otvorenu torakotomiju između dvije vrste VATS zahvata ($p = 0,283$). Pri usporedbi nekonvertiranih uniportalnih VATS i multiportalnih VATS zahvata s otvorenim torakotomijama nije bilo statistički značajne razlike između spolne raspodjele ($p = 0,287$), dobi ($p = 0,569$), trajanja operacije ($p = 0,093$) ili duljine poslijeoperacijske hospitalizacije ($p = 0,086$). Trajanje drenaže bilo je značajno duže u ispitanika s otvorenim torakotomijama (6 dana), u usporedbi s oba tipa minimalno invazivnih operacija ($p = 0,016$). Nije bilo razlike između uniportalnog VATS-a (5 dana) i multiportalnog VATS-a (5 dana) u odnosu na trajanje drenaže prsnog koša.

Zaključci: Ova studija pokazuje da su minimalno invazivne operacijske tehnike, odnosno multiportalni i uniportalni VATS, bolji izbor od otvorene torakotomije u kirurškom liječenju karcinoma pluća. To je u skladu s nalazima drugih nedavnih studija koje naglašavaju vrijednost tehnike multiportalnog VATS-a kao zlatnog standarda u liječenju karcinoma pluća. Međutim, ne postoji jasna superiornost uniportalnog VATS-a nad multiportalnim, iako je riječ još manje invazivnoj tehnici. S druge strane, rezultati također ne ukazuju niti nedostatke pojedine od ove dvije tehnike, što upućuje na ekvivalentnu kliničku vrijednost uniportalnog VATS-a u liječenju karcinoma pluća.

10. CURRICULUM VITAE

Personal Data

Name and Surname: Victor Hoursch
Date of Birth: 13.06.1995
Citizenship: German
Address: Schemelsbruch 8, 45478 Mülheim, Germany
E-mail: vichoursch@gmail.com

Education

10.2013 – 07.2019 University of Split School of Medicine, Split, Croatia,
Doctor of Medicine
09.2011 – 07.2013 Malvern College, Malvern, United Kingdom,
International Baccalaureate
09.2005 – 07.2011 Landfermann-Gymnasium, Duisburg, Germany
08.2001 – 07.2005 Katholische Grundschule Arnoldstraße, Mülheim, Germany

Languages

German Mother Tongue
English C2

Further Engagements

05.2016 - 07.2019 Captain and Founding Member, Split Legion Lacrosse Club
03.2014 – 07.2018 Director of Events, International Student Association
of the University of Split School of Medicine (ISA-USSM)