

Tissue characteristics in retinal surface disorders

Joseph, Arun

Master's thesis / Diplomski rad

2019

Degree Grantor / Ustanova koja je dodijelila akademski / stručni stupanj: **University of Split, School of Medicine / Sveučilište u Splitu, Medicinski fakultet**

Permanent link / Trajna poveznica: <https://um.nsk.hr/um:nbn:hr:171:356770>

Rights / Prava: [In copyright](#)/[Zaštićeno autorskim pravom.](#)

Download date / Datum preuzimanja: **2025-02-19**



Repository / Repozitorij:

[MEFST Repository](#)



**UNIVERSITY OF SPLIT
SCHOOL OF MEDICINE**

Arun Joseph

**TISSUE CHARACTERISTICS IN RETINAL SURFACE
DISORDERS**

Diploma thesis

Academic year:

2018/2019

Mentor:

Assist. Prof. Ljubo Znaor, MD, PhD

Split, July 2019

**UNIVERSITY OF SPLIT
SCHOOL OF MEDICINE**

Arun Joseph

**TISSUE CHARACTERISTICS IN RETINAL SURFACE
DISORDERS**

Diploma thesis

Academic year:

2018/2019

Mentor:

Assist. Prof. Ljubo Znaor, MD, PhD

Split, July 2019

TABLE OF CONTENTS

1. INTRODUCTION.....	1
1.1. The eye.....	2
1.2. The retina.....	4
1.3. The Vitreous.....	8
1.4. Retinal disorders.....	10
1.4.1 Vitreoretinal interface.....	10
1.4.2. Retinal detachment	11
1.4.3. Dystrophies and degenerations.....	12
1.4.4. Macular edema	13
1.4.5. Retinal inflammations.....	13
1.4.6. Neoplasia.....	14
1.4.7. Epiretinal membranes.....	14
2. OBJECTIVES OF RESEARCH.....	19
3. MATERIAL AND METHODS.....	21
3.1. PATIENTS.....	22
3.2. ORGANIZATION OF THE STUDY.....	22
3.3. PLACE OF THE STUDY.....	22
3.4. METHODS OF TISSUE PRESERVATION AND PROCESSING.....	23
4. RESULTS.....	24
5. DISCUSSION.....	28
6. CONCLUSION.....	32
7. REFERENCES.....	34
8. SUMMARY (English).....	40
9. SUMMARY (Croatian).....	42
10. CURRICULUM VITAE	44

ACKNOWLEDGEMENT

These six years at the University of Split School of Medicine has been the highlight of my life so far. It has provided me not only life lessons in medicine but also memories that will last a lifetime. I found best friends, I found love and I found myself. I am very grateful and proud to have studied here. I would like to take this opportunity to thank everyone who has been a part of this journey with me for giving me this experience. You are all valuable pieces of the puzzle of my life.

I would like to thank Prof., Znaor for taking up my request to be part of his research and offering prompt assistance whenever I needed. I would also like to thank Prof., Vukojevic and her team for offering all the help they can with this project and Dr. Zaja for her understanding and sincere guidance in every step of the way. Last but not least I would like to thank my family for all their support and patience throughout these years and throughout my degrees to finally reach here, the end that marks a new beginning. I did it.

1. INTRODUCTION

1.1. The eye

The human eye, the organ of our vision, consists of the eyeball and the optic nerve. It is contained within the orbit which also accommodates its accessory visual structures (1).

The eyeball contains the optical apparatus of the visual system. It measures approximately 25mm in diameter and inhabits most of the anterior orbit and is suspended by six extrinsic muscles that control its movement and a fascial apparatus. A connective tissue layer composed of the bulbar fascia posteriorly and the bulbar conjunctiva anteriorly, surrounds and supports the eyeball within the orbit. A potential space known as the episcleral space lies between the bulbar fascia and the outer layer of the eyeball enabling its movements (1,2).

The eyeball itself consists of three layers; the fibrous layer, the vascular layer and the inner layer. The fibrous layer is the outer coat that forms the external fibrous skeleton of the eyeball and provides its protection and structural integrity. The sclera forms part of the fibrous layer. It is the tough and opaque outer layer of the eye due to the dense, irregular arrangement of collagen fibrils, and transitions anteriorly to become cornea at the limbus and posteriorly into the optic nerve dural sheath. Type I collagen predominates in the sclera, however it also consists of types III, V, and VI collagen. In addition, elastic fibers also constitute a small part of the scleral fibrillary scaffold and together with the collagen they confer mechanical properties, including viscoelasticity and limited distension of the sclera (1-3).

The cornea is the transparent portion of the fibrous layer with a radius of 7.8mm and forms the most anterior part of the eye, see figure 1. It makes up one-sixth of the circumference of the globe. The anterior surface of the cornea is continually bathed by tears, while the posterior surface is covered by aqueous humor (1,2). The surface of the cornea, together with the associated tear film, is responsible for most of the refractive power of the eye. Hence, its function is to refract light rays and guide its focus on to the retina. The main thickness of the cornea consists of regularly arranged collagen fibers, which along with the regular smooth epithelium and lack of blood vessels, is responsible for its transparency (1,4).

The two parts of the fibrous layer varies mainly in terms of the regularity of the arrangement of the collagen fibers and the degree of hydration of each. While the sclera is relatively avascular, the cornea is completely avascular, receiving its nourishment from capillary beds around its periphery at the corneal limbus, lacrimal fluid on its external surface which provides oxygen from the air and aqueous humor on its internal surfaces (1,2). Drying of the corneal surface can cause ulceration. The cornea is innervated by the ophthalmic branch

of the trigeminal nerve and is extremely sensitive to touch eliciting blinking, flow of tears and pain to even very small foreign bodies. The corneal limbus is the angle formed by the intersecting curvatures of sclera and cornea at the corneoscleral junction which is a 1-mm wide, gray, and semi-transparent circle including numerous capillary loops involved in nourishing the avascular cornea (1,4).

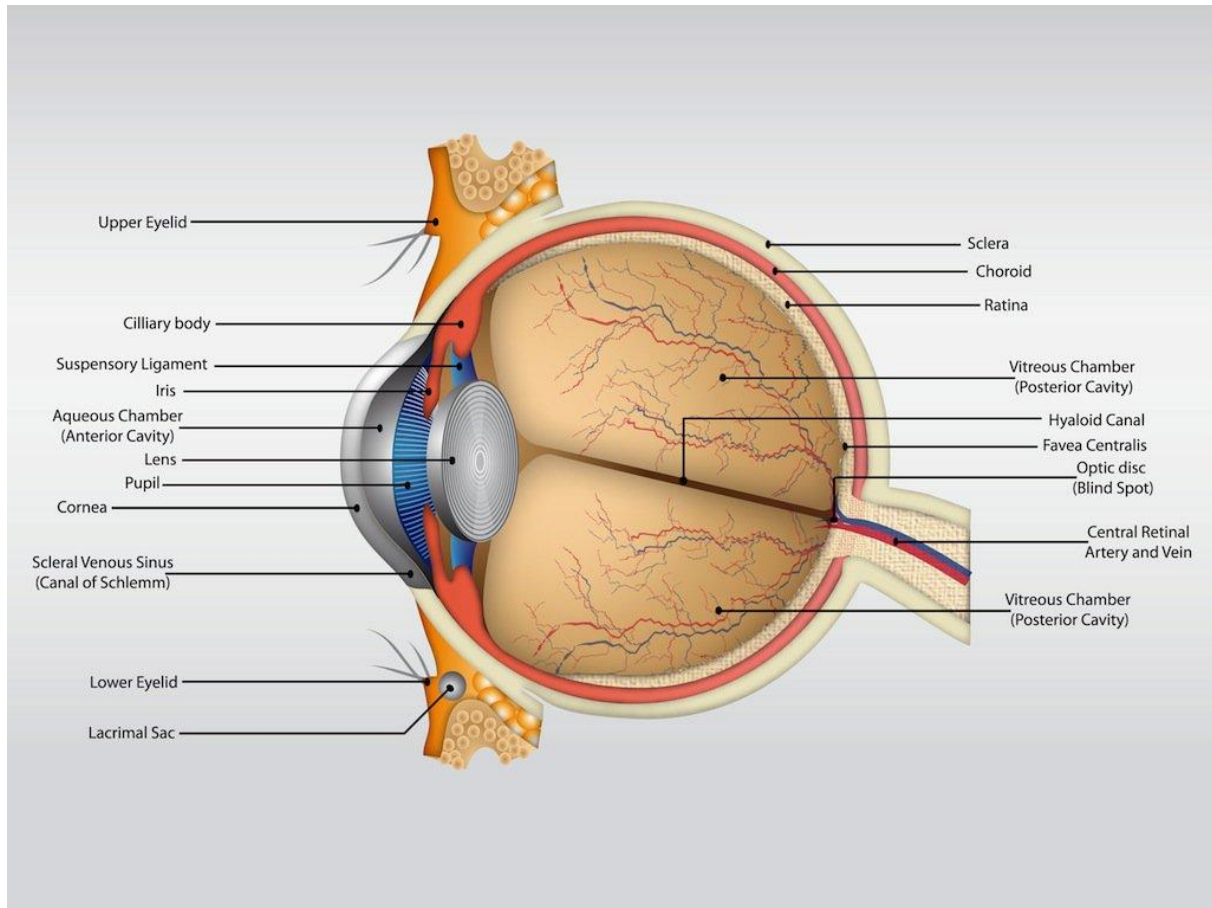


Figure 1. The anatomy of the eyeball.

SOURCE: <https://www.freevector.com/eye-anatomy-vector>

The uvea is the vascular layer of the eyeball. It consists of the choroid, ciliary body, and iris and forms the inner coat of the eye. The choroid is a dark reddish-brown highly vascular layer lining most of the sclera and is positioned between the sclera and the retina. It attaches firmly to the pigment layer of the retina however; it can easily be removed from the sclera. The choroid not only forms the largest part of the vascular layer of the eyeball but it also has the highest perfusion rate per gram of tissue of all vascular beds of the body and it is the segment responsible for the “red eye” reflection. Within this pigmented and dense vascular bed, larger vessels are located externally near the sclera and the fine yet extensive capillary network known as the capillary lamina of the choroid are embedded deep and

adjacent to the avascular light-sensitive layer of the retina, which it supplies with oxygen and nutrients (1,5).

The choroid is continuous anteriorly with the ciliary body which is a ring-like thickening of the layer posterior to the corneoscleral junction that and divides the posterior chamber of the eye from the vitreous body. It is muscular as well as vascular and connects the ora serrata with the circumference of the iris. The ciliary body contains the ciliary muscle whose contraction and relaxation controls the focus of the lens, vessels, and provides attachment for the lens by use of its fibrous connective tissue – zonular fibers. The ciliary processes on the internal surface of the ciliary body, secrete aqueous humor that fills the anterior segment of the eyeball, the interior of the eyeball anterior to the lens, suspensory ligament, and ciliary body (1,6).

The iris lies on the anterior surface of the lens. It is a thin contractile diaphragm with the pupil in its center. When the eye lids are open, the size of the pupil varies to regulate the amount of light entering the eye by use of two involuntary muscles: the parasympathetically stimulated, circularly arranged sphincter pupillae that causes miosis and the sympathetically stimulated, radially arranged dilator pupillae that causes mydriasis. The nature of the pupillary responses is paradoxical: sympathetic responses usually occur immediately, yet it may take up to 20 minutes for the pupil to dilate in response to low lighting. While although parasympathetic responses are typically slower than sympathetic ones, parasympathetically stimulated papillary constriction is normally instantaneous. Abnormal sustained mydriasis unresponsive to light may occur in certain diseases or as a result of trauma or the use of certain drugs (1,7).

1.2. The retina

The inner, layer of the eyeball is the retina. It is a thin multilayer consisting mainly of neuronal cells derived from the neuroectoderm. Serving its role as one of the most important parts of the eye, the retina receives, modulates and transmits visual stimuli from the outside world to the optic nerve and, ultimately, the visual cortex of the brain. It measures approximately 0.4 mm in thickness at the border of the optic nerve head and tends to become thinner toward the periphery until it reaches nearly 0.14 mm at the ora serrata which is the serrated junction between the retina and the ciliary body (8,9).

The highly specialized anatomy of the retina consists grossly of two functional parts with distinct locations: the optic and non-visual parts. The optic part of the retina is visual light sensitive and has two layers: a neural layer which is known as the neuroretina and a

pigmented layer which is known as the retinal pigment epithelium (RPE). The neuroretina is divided into nine layers: outer and inner segments of photoreceptors (rods and cones), external limiting membrane, outer nuclear layer, outer plexiform layer, inner nuclear layer, inner plexiform layer, ganglion cell layer, nerve fiber layer and internal limiting membrane (ILM) (Figure 2) (8-13).

The RPE is a monolayer of cuboidal cells containing numerous melanosomes which provides its pigmentation. In the embryo the RPE arises separately from the neural retina. The pigmented granules absorb scattered light and by doing so improve the optical qualities of the eye and protect the sensitive cells of the neural retina from photo oxidative stress. The tightly interlocked cells of the RPE are located beneath the highly vascular choroid and hence they serve to transport and regulate the flow of ions, nutrients, metabolites and water to and from the overlying outer neurosensory retina. Moreover, they also phagocytize discarded membranes from the rod and cone cells and thereby play an important role in keeping the eye as an immunologically privileged site. Glycosaminoglycan ground substance, known as the interphotoreceptor matrix fills the extracellular space between the photoreceptors and RPE. The basement membrane of the RPE comprises of the inner layer of Bruch's membrane which is the innermost layer of the choroid. The remainder of Bruch's membrane is composed of an inner collagenous zone, central elastin, an outer collagenous zone and the basement membrane of the choriocapillaris. Bruch's membrane divides the retina and RPE from the choroid, and defects within this membrane induces the growth of choroidal vessels into the sub-retinal space in choroidal neovascularization. The optic part of the retina terminates anteriorly along the irregular posterior border of the ciliary body - the ora serrata (8-13).

The photoreceptive layer is composed of the outer and inner segments of the photoreceptor cells - rods and cones. The outer segment contains layers of membrane disks, which encompasses visual pigment molecules and are constantly renewed. New disks are added to the base of the outer segment at the cilium and old disks are moved outwards, eventually taken up at the photoreceptor tip and consumed by the apical processes of the RPE in a diurnal cycle. The outer segment narrows at the cilium, which demarcates the beginning of the inner segment. The inner segment is divided into Golgi body and ribosome-rich inner myoid and the mitochondria-rich outer ellipsoid. The external limiting membrane, separating the inner and outer segments from the photoreceptor nuclei, is not in fact a true membrane but is rather molded by the terminal bar attachments of the cell bodies of rods, cones and Müller cells. The nuclei of both the photoreceptor cells are contained within the outer nuclear layer

and the axons of the photoreceptor cells and their synapses with bipolar cells forms the outer plexiform layer. Around the foveolar area, the axons of the cones take a divergent course to meet the nerve fiber layer of Henle which are eccentric-positioned neurons of inner retina and ganglion cells (8-13).

The inner neural retina is composed of several distinct cell types. The photoreceptor cells are connected to the dendrites of the ganglion cells in the outer plexiform layer by glutamatergic or glycinergic bipolar cells. GABAergic (γ -aminobutyric acid) neurons that connect to the photoreceptor cells and synapse with bipolar cells forms the horizontal cells. This is where the 'on' and 'off' responses are generated by the bipolar cells, to regulate signal transduction. In general, the 'on' bipolar cells terminate in the inner side of the inner plexiform layer and 'off' bipolar cells terminate in the outer side of the inner plexiform layer. Amacrine cells which are the intrinsic interneurons of the inner retina receive synaptic input from bipolar cells and other amacrines, and in turn provide input to amacrine and ganglion cells as well as feedback to bipolar cells. They receive excitatory glutamatergic input from bipolar cells and mainly inhibitory input from other amacrine cells mediated by GABA C receptors. Müller cells on the other hand act as specialized glial cells to form retinal scaffolding, provides support for the inner segments of the photoreceptors and create the acellular fibrous ILM. The nuclear bodies of all these distinct cell types compose the inner nuclear layer of the retina. Furthermore, the axons of the bipolar and amacrine cells connect to the dendrites of the ganglion cells to compose the inner plexiform layer (14). The nuclei of the ganglion cells make up the ganglion cell layer and their axons on their journey to the optic disk form the nerve fiber layer. Finally, the footpads of Müller cells form a basement membrane structure which in turn makes the ILM (8-13).

The non-visual retina is an anterior continuation of the RPE and a layer of supporting cells. The non-visual retina stretches over the ciliary part of the retina and the posterior surface of the iris which is considered the iridial part of the retina to reach the pupillary margin. The ocular fundus is the internal part of the posterior eyeball that focuses the light that enters the eye and the retina of the ocular fundus contains the optic disc otherwise known as the optic papilla which is a distinctive circular area where the sensory fibers and vessels brought by the optic nerve (CN II) enters the eyeball. As it contains no photoreceptors, the optic disc is insensitive to light and therefore this part of the retina is referred to as the blind spot (8-13) (Figure 1).

Lateral to the optic disc is the macula of the retina or macula lutea, otherwise known as the yellow spot due to its yellow color during retinal red-free light examination. The macula lutea is a small elliptical area of the retina with specialized photoreceptor cones for visual acuity and it is not normally observed with an ophthalmoscope. At the center of the macula is the fovea centralis, approximately 1.5 mm in diameter in the neural retina and 0.35 mm thick on the outside. The center of the fovea is the foveola, approximately 0.18mm in diameter and it is the area responsible for sharp central vision. Cones reach a high density between 4,000– 5,000/mm² in the macula and approximately 15,000/mm² in the fovea. Rods reach their greatest density 20° from the point of fixation. Foveal cones can match with up to 5 ganglion cells, while on average the retinal ganglion cells match with roughly 130 different photoreceptors (8-13).

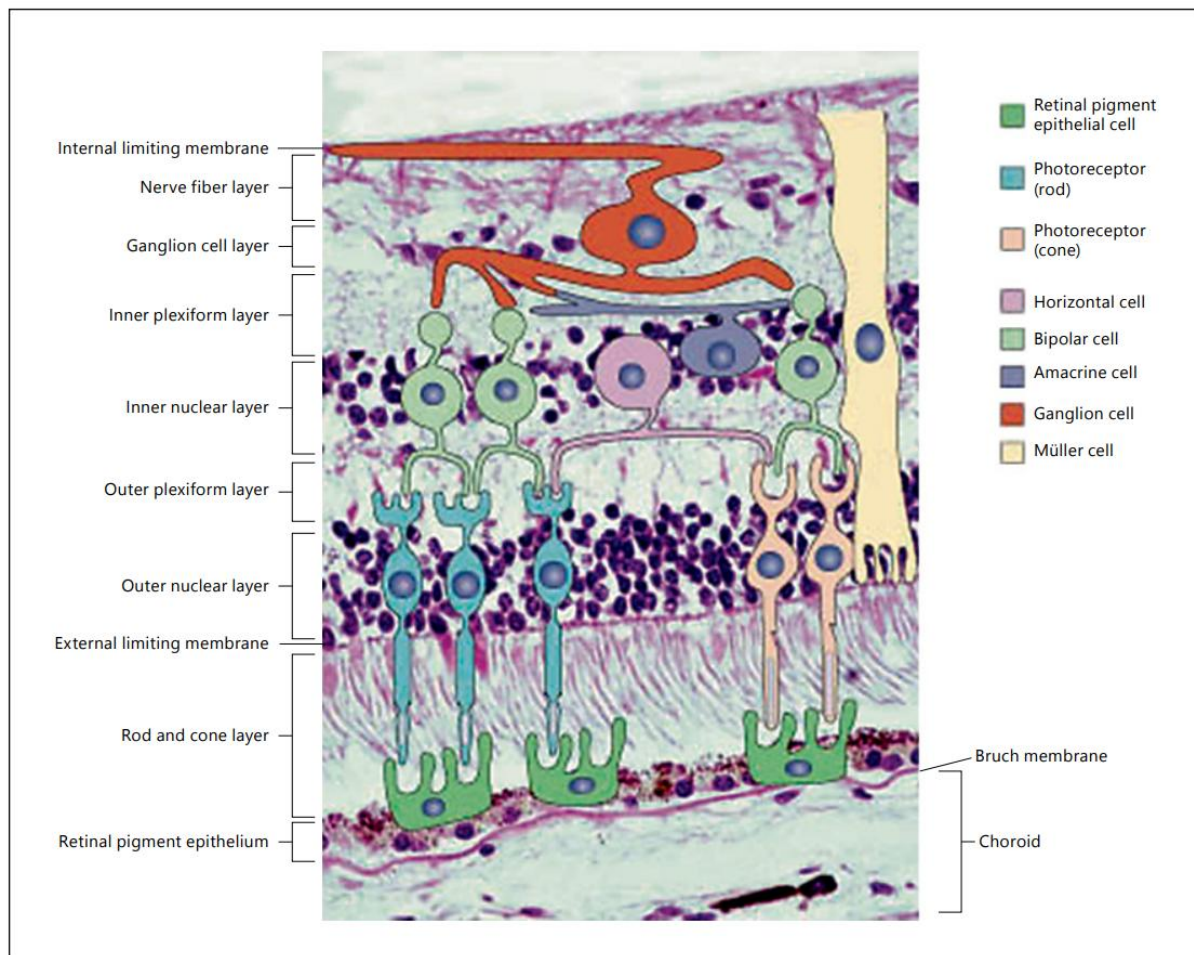


Figure 2. Photomicrograph of the retina combined with a diagram of pertinent retinal cells. The 10 layers of the retina (neuroretina and RPE) are identified along the left and the different cell types in the box on the right. Original magnification x 200.

SOURCE:

https://www.researchgate.net/publication/283260442_Retinal_Anatomy_and_Pathology

Apart from for the rods and cones of the neural layer which receive its nutrients from the capillary lamina of the choroid through osmosis across Bruch's membrane and through the RPE, the retina is supplied by the central retinal artery which splits into four arteriole branches at the optic disk. The arterioles are seven to eight smooth muscle cells thick and run in the nerve fiber layer below the ILM. A corresponding system of retinal veins unites to form the central vein of the retina (8-13).

Aging induces changes in the normal retina include the development of a few small drusen between RPE and Bruch's membrane, alterations in shape, size and accumulation of lipofuscin in the RPE. Thickening of Bruch's membrane and the ILM and epiretinal membrane formation can also be seen (12).

1.3. The vitreous

The vitreous is the transparent gel like formation that fills the posterior segment of the eye and occupies 80% of its volume. It is composed of water, connective tissue, predominantly type II collagen, glycosaminoglycans, and hyaluronic acid. Defects in the vitreous chamber have a vital role in many diseases of the posterior segment of the eye. Understanding its structure and age-related changes are crucial to gaining a better perspective on many vitreoretinal disorders (9-11).

The vitreous body provides mechanical stability to the eyeball and prevents retinal detachment. It contains interconnected cisterns and canals, one of which is the ciliobursal canal which connects the ciliary body and macula and is hypothesized to mediate forms of cystoid macular edema. The anterior surface of the vitreous body is called the anterior cortical gel. The hyaluronic acid molecules fill the three-dimensional collagen fiber networks. Condensation of these peripheral collagen fibrils forms the hyaloid membrane and is attached to adjacent structures at the ligament of Wieger along the posterior capsule of the lens, at the vitreous base at the ora serrata where the collagen fibers are especially dense and at the funnel of Martegiani surrounding the periphery of the optic disc. The vitreous can be divided into 2 main topographic areas: the central, or core vitreous and the peripheral, or cortical, vitreous. The retrolental indentation of the anterior vitreous is called the patellar fossa and the potential space between lens and anterior cortical gel bordered by the Wieger ligament is called the Berger space. The vitreous is also firmly attached to the retinal vessels, optic nerve, and the macula. The densely packed collagen fibers in the cortical vitreous form the cortical gel and the fibers running posteriorly and parallel to the inner surface of the retina, form the preretinal tract. Hence the vitreous is surrounded by a basal laminar bag provided by the lens and the retina with the annular gap between the vitreous base and lens, which allows diffusion

between the aqueous and vitreous compartments. As the vitreous peels off the inner retinal surface due to aging or trauma, areas that are particularly adherent, which are at the optic nerve, macula, blood vessels and ora serrata, are subject to traction, which can result in avulsion of a vessel to produce a retinal or vitreous hemorrhage, or a retinal tear or operculum. The premacular bursa, otherwise known as the precortical vitreous pocket is a space formed by the posterior attachment of the vitreous to the macula (9-11, 15-17).

The vitreous body itself does not have any blood vessels or nerves. Thus, the slow immune response from nearby structures allows pathogens to multiply for a relatively long time before the onset of an immune response is mediated. The vitreous body can also undergo developmental, pathological and age-related changes that compromises its structural integrity. Some such pathologies include muscae volitantes or floaters, Terson syndrome which is a combination of intraocular and subarachnoid hemorrhage secondary to aneurysmal rupture, asteroid hyalosis - a common degenerative process in which calcium pyrophosphate particles collect within the vitreous gel, synchysis scintillans which occurs as a result of chronic vitreous hemorrhage often in a blind eye, amyloidosis, vitreous cyst which can be congenital or acquired, acquired cysts being caused by a range of pathology such as trauma and inflammation and persistent fetal vasculature which are remnants of the hyaloid vessels that forms a Bergmeister papilla, seen as a tuft at the optic disc or a Mittendorf dot on the posterior lens surface. Synchysis can also result with age when depolymerization of the hyaluronic acid and collapse of the collagen filaments results in vitreous liquefaction (9-11, 16,17).

Vitreous hemorrhage is a common condition with discharge of blood into the vitreous body and its adjacent structures. It has many causes but it is mainly caused as a result of trauma and diseases such as proliferative diabetic retinopathy (PDR), posterior vitreous detachment, and tumors. It can result in vision loss, appearance of floaters and typically resolves spontaneously. However, vitrectomy is indicated if the retina is affected or severe disease progression occurs (16,17).

Posterior vitreous detachment (PVD) is another serious complication where the posterior vitreous cortex along with the delineating posterior hyaloid membrane (PHM), is separated from the ILM of the neurosensory retina posterior to the vitreous base. Etiologies include age-related degeneration of the vitreous tissue, elongation of the ocular bulb, and eye injuries. Patients are commonly asymptomatic, but floaters and photopsia may occur. Asymptomatic individuals do not require treatment however, symptomatic patients with retinal injury including retinal tears, retinal holes or retinal detachment, require prompt

treatment (9-11, 16,17).

1.4. Retinal disorders

As illustrated above, the retina is an extremely complex structure. The complexity of the human retina means that a wide range of pathology can result from a variety of insults to the retina. The type, duration and severity of the injury to the retina as well as the cells and tissues involved judges the capacity of retinal tissue to respond to such injuries. Retinal pathology often results from a disruption of its architecture. While the specific pathological and clinical manifestations of the many retinal diseases are varied, many conditions share certain key pathophysiology that may be amenable to therapy. A few of the major pathological processes in retinal diseases are shown below (8,12).

1.4.1. Vitreoretinal interface

Traction on the macula by the vitreous or hyaloid can result in many pathologies. Metamorphopsia, a type of distorted vision in which a grid of straight lines appears wavy or blank can present as a result of incomplete perifoveal vitreoretinal separation which causes the vitreomacular traction syndrome, in which traction upon the fovea produces cystic changes. This pathology also distorts the foveal architecture to produce decreased vision (17,18).

Vitreous traction as well as traction by the ILM or an epiretinal membrane are all causes for macular holes formation. Traction of the vitreous on the retina are also thought to cause schisis cavities commonly seen in myopic degeneration and also perhaps X-linked retinoschisis (17,18).

Diabetes is a condition that underlies many pathologies in the eye. As well as the complications above, the vitreoretinal interface is also thought to play a role in diabetic retinopathy. Conventionally, diseases due to vitreoretinal traction are treated using surgical mechanical separation of the hyaloid from the retina and eliminating vitreous traction through vitrectomy. An example is anti-vascular endothelial growth factor (VEGF) therapy resistant cases of diabetic edema, due to a contracted hyaloid, respond well to vitrectomy and release of hyaloid attachment to the central retina (19).

Recent studies have shown ocriplasmin as a mode of treatment in the vitreomacular traction syndrome and macular holes. Ocriplasmin induces enzymatic separation of the vitreous from the retina by promoting conversion of plasminogen to plasmin and causes separation of laminin and fibronectin molecules. It digests these molecules and consequently separates these structures. These molecules are thought to play an important role in the

adherence of vitreous collagen fibrils to the ILM. Whether agents such as ocriplasmin can be used as part of therapy in hyaloid separation prior to or during vitrectomy surgery, or a solution to other conditions involving vitreoretinal traction such as diabetic macular edema and schisis, is still under research (17,18).

1.4.2. Retinal detachment

Retinal detachment (RD) refers to separation of the neurosensory retina from the RPE. This results in the accumulation of subretinal fluid in the potential space between the neurosensory retina and RPE. Types of RD can be mainly classified into: rhegmatogenous, tractional, exudative and tumor related. Rhegmatogenous RD which is the most common type, results from a break or tear in the retina. Tractional RD traction results from vitreous strands that exert tensile forces on the retina causing the neurosensory retina to be pulled away from the RPE by contracting vitreoretinal membranes in the absence of a retinal break. The traction can be due to fibrovascular membranes in a variety of conditions, especially those involving retinal neovascularization, such as diabetic retinopathy, sickle cell retinopathy or retinopathy of prematurity. Exudative detachments caused by subretinal fluid which can be blood, lipids, or serous fluid that accumulate between the neurosensory retina and the RPE. Coats disease is a typical example. Fluid accumulation are due complications such as leakage of fluid into the subretinal space due to choroidal inflammation, retinal vascular lesions and choroidal tumors. Moreover, combined tractional–rhegmatogenous RD results when a retinal break is a result of traction from an adjacent area of fibrovascular proliferation and subclinical or asymptomatic RD is generally refers to an asymptomatic break that does not usually give rise to a subjective visual field defect but is surrounded by a relatively small amount of subretinal fluid, by definition extending further than one disc diameter away from the edge of the break but less than two disc diameters posterior to the equator (10-12, 19).

Primary RD typically results from a tear. In rare cases, secondary RD can also result from a tear due to other disorders or injuries and combinations of both are even more rare. Chronic RD can lead to proliferative vitreoretinopathy (20-22).

Histologically, detachment of the retina from the RPE brings about neural retinal atrophy due to weak choroidal blood supply to the outer retina leading to loss of photoreceptor outer segments and serous fluid in the subretinal space. Currently no pharmacotherapeutic agents have been developed for RD however, neuroprotective agents have shown promising results in animal models (23,35).

1.4.3. Dystrophies and degenerations

Dystrophies and degenerations typically befall simultaneously, although involvement can be asymmetric. Dystrophies are usually conditions that are congenital which thereafter can be non-progressive or progressive, on the other hand degenerations are progressive and are generally acquired later in life. These include both peripheral and central, or macular, dystrophies and degenerations. The pathophysiology that results in dystrophies, degenerations and their treatments are often varied. Atrophy of the rods and cones and/or RPE is generally noted in these conditions, especially in later stages (8,12).

Age-related macular degeneration (AMD) is the progressive degeneration of the macula in the elderly and is the most common retinal degenerative condition whose incidence is augmented with older age. Geographic atrophy, otherwise known as the dry form of AMD is characterized by are small yellow or white accumulations of extracellular material that build up between Bruch's membrane and the RPE which are known as drusen, and can result in the loss of photoreceptors and RPE as well as thickening and disruption of Bruch's membrane and lipofuscin accumulation in the RPE. Thus, compensatory RPE cell proliferation resulting in hyper pigmentary changes are observed in geographic atrophy. The role of inflammation as a cause is being hypothesized by many as inflammatory-related molecules being seen in drusen deposits. RPE atrophy can be seen on later stages of dry AMD which in turn results in eventual degeneration of the overlying photoreceptors and can lead to retinal atrophy that may extend to the outer retinal layers in severe cases (6,24).

Choroidal neovascularization (CNV) which occurs due to loss of structural integrity of the Bruch's membrane and the growth of tortuous vessels from the choriocapillaris into the sub-RPE and subretinal spaces, is the defining characteristic of wet neovascular or exudative AMD. This type of AMD affects approximately 10-15% of individuals with age-related macular degeneration, but accounts for approximately 90% of all cases of severe vision loss from the disease. Abnormal blood vessels beneath the retina growing toward the macula have the potential to break, bleed, and leak fluid, causing macular damage and causing it to lift up and pull away from its base resulting in severe and rapid central vision loss. Consequentially the subretinal and/or intraretinal fluid accumulation will disrupt the precise alignment of photoreceptors and RPE, which along with fibrovascular scar formation by the neovascular membranes, as well as toxicity from the associated hemorrhage, lead to subsequent degeneration and atrophy of overlying photoreceptors (12,24).

As well as AMD, CNV is occupied with other pathologies as well, such as pathologic myopia, primary ocular histoplasmosis syndrome, choroidal rupture, angioid streaks and

inflammatory chorioretinal diseases such as punctate inner choroidopathy. Moreover, in addition to retinal diseases that responds to hypoxia, such as diabetic retinopathy, vein occlusion, sickle cell retinopathy, retinopathy of prematurity, familial exudative retinopathy, CNV can also result in the development of retinal and optic disk neovascularization. In some cases, angiogenesis may also arise in the iris or the angle, subsequently causing neovascular glaucoma. CNV is the most compliant to therapy of all the pathological processes concerned with AMD. Tissue plasminogen activators such as alteplase has a role in surgical therapies for displacing these hemorrhages from the macula by facilitating the lysis of fibrin clots. Several single-nucleotide polymorphisms associated with AMD include complement factors H, B, 2 and 3, ARMS2/HtrA1, CX3CR1 and VEGF (12, 24).

VEGF, an endothelium-specific mitogen, has a very potent role in neovascularization. VEGF production and release are hypoxia driven and it promotes neovascularization and vascular permeability by binding to the VEGF receptors on vascular endothelium. Therefore, its inhibition has been one of the highlights in ophthalmology research to reduce leakage from choroidal neovascular vessels and promote their regression (12,20,24).

1.4.4. Macular edema

Absence of lymphatic drainage within the retina makes the tissue particularly vulnerable to edema. Several conditions including vascular occlusion, diabetic retinopathy, uveitis or Irvine-Gass syndrome which results from postsurgical inflammation, can all be a cause of macular edema, as well as a combination of events including, microvascular damage, inflammation, increased transmural hydrostatic pressure and breakdown of the inner blood-retinal barrier. Edema disrupts the precise structure of the retina and thus limits vision and subsequently leads to irreversible damage to the neuroretina. Treatments depends on the etiology as the pathophysiology responsible for macular edema vary from disease to disease. The therapy options include nonsteroidal anti-inflammatory drugs, intra-ocular corticosteroids; carbonic anhydrase inhibitors to increase fluid reabsorption across the RPE and anti-VEGF agents, which reduce vascular permeability (12,26).

1.4.5. Retinal inflammations

Retinitis or chorioretinitis, manifest pathologically with inflammatory cells infiltrating the retina and/or choroid, as mentioned above. Edema due to increased vascular permeability and leukocytosis leads to swelling and degeneration of neural retinal cells along with retinal hemorrhages and accumulation of microglia and macrophages. Inflammatory vascular

occlusion can also occur leading to infarction - cotton wool spots formation, or cystoid body formation as the axons of nerve fibers undergo swelling. Chorioretinal scar formation, hyaline and/or calcareous degenerations and fibro glial scar can result as a consequence of the natural inflammatory healing process, thereby promoting hypertrophy and hyperplasia of nearby RPE. Furthermore, astrocyte proliferation in the lesion can lead to retinal gliosis (26,27).

Retinitis can present as either non-granulomatous or granulomatous, and either infectious or noninfectious. Infectious causes are numerous and include viruses such as cytomegalovirus and other herpes viruses, bacteria including mycobacterial and syphilitic infections, fungi such as *Candida* or *Aspergillus* and parasitic infections such as toxoplasmosis and onchocerciasis. Treatment including systemic, topical, local or intraocular corticosteroids, as well as immunosuppressive therapies for noninfectious and systemic and local antimicrobials sometimes in combination with corticosteroids for infectious retinitis (12,28).

1.4.6. Neoplasia

Tumors of the retina can arise from any cell type including photoreceptors, RPE and glial cells. Therapy depends on the specific tumor involved and its spread. Treatments includes surgery, laser/cryotherapy, radiation therapy and local or systemic chemotherapy (8,12).

1.4.7. Epiretinal membranes

An epiretinal membrane (ERM) is a transparent, avascular, fibro cellular membrane that develops on the inner retinal surface that adheres to and covers the ILM of the retina. The clinical presentation can vary from completely asymptomatic, diagnosed on routine examination, to profoundly symptomatic with metamorphopsia, micropsia or macropsia, photopsia, decreased visual acuity and loss of central vision. ERMs may occur without any pre-existing ocular conditions or surgical procedures, termed idiopathic ERM (iERM), or they can be associated with other conditions such as retinal vascular occlusion and diabetic retinopathy, trauma or surgery, these are referred to as secondary ERM (10,11,29).

In iERM residual vitreous tissue remains on the retinal surface following cortical separation in approximately 50% of eyes, with subsequent proliferation. Schisis of the posterior vitreous may leave variable portions of the posterior cortical vitreous attached to the macula, allowing glial cells from the retina to proliferate along the retinal surface and hyalocytes to proliferate on posterior cortical vitreous remnants on the retinal surface. iERM

is commonly found in aging population with autopsy studies showing 2% of patients older than 50 years and in 20% older than 75 years with iERM. They affect both sexes equally and they tend to be bilateral in 10% of the cases and are usually milder cases than secondary ERM. The predominant cell type in iERM is glial cells, probably derived from laminocytes which are the indigenous posterior hyaloid membrane cell population. ERM development can occur at any stage of PVD which can extend over the course of year (19,29).

As mentioned above, secondary ERM can occur following retinal detachment surgery, which is the most frequent cause of secondary ERM, retinal break, panretinal photocoagulation, retinal cryotherapy, retinal vascular disease, inflammation and trauma. Binocularity is dependent on whether both eyes are affected by the causative factors. Cellular constituents of secondary ERM are more varied with predominantly pigment cells which are thought to be derived from the RPE (10,11,29).

The main components of ERM are extracellular matrix structures such as fibronectin and collagen and cells of extra retinal and retinal origin such as glial cells, fibroblasts, and hyalocytes. Structurally iERMs can be divided into two types that have different clinical presentations: simple and tractional ERMs. Membranes with gentle cellophane-like films on the ILM with mild to no visual symptoms are known as simple iERMs. These membranes are usually composed mostly of glial cells. Tractional iERMs are usually accompanied by decreased vision and metamorphopsia as they are thicker with contractile properties that cause surface wrinkling of the retina. They are composed of glial cells as well as contractile cells (30-32).

ERM can be subdivided further into cellophane maculopathy (CP) and macular pucker (MP) based on their level of traction and cell type. Tangential traction in the inner retina may cause CM or tangential traction in full thickness retina may trigger MP. Traction on the macula causes gradual anatomical and functional deterioration proportional to traction forces and their duration of action. In Gass classification for ERM the translucent membranes not associated with retinal distortion are Grade 0 as is the case in CM. The membranes causing disorganized wrinkling of the inner retina are Grade 1 as in crinkled CM and the opaque membranes causing full-thickness retinal distortion are Grade 2, this is seen in MP. The progression of ERM from CM to MP is as a fibrotic process as there is an increased extra cellular matrix protein deposition and the membrane contraction in which myofibroblasts has a central role (30,31).

Several theories for the pathophysiological mechanisms responsible for the development of iERM have been proposed, including the role of glial cells, fibroblasts,

hyalocytes assisted by cytokines and growth factors present in the vitreous fluid however, the types of cells that produce iERMs and the mechanism by which they reach the retinal surface has been under research for many years. Only recently with improvements in imaging techniques coupled with immunocytochemistry and proteomic techniques, the understanding of the development of iERMs has evolved (31-33).

Surgically excised ILM specimens morphologically analyzed has demonstrated a variety of cells in iERM, including glial cells such as Muller cells, fibrous astrocytes, and microglia, hyalocytes, RPE cells, fibroblasts, and myofibroblasts. Nevertheless, since the cells in the vitreous commonly undergo prominent morphologic changes via transdifferentiation which essentially makes them indistinguishable from each other by morphologic criteria alone. Therefore, ultrastructural criteria alone are not sufficient for identifying the origin of cells. Thus, recent research has focused on using immunohistochemical markers of structural proteins such as intermediate filament proteins to assist in cell-type determination. Refer to table 1 for routinely used antibodies against structural proteins and their respective target cells (30-33).

Simple iERMs with little traction predominantly have glial cells whereas myofibroblasts are the major cell type in tractional ERMs. Zhao *et al.* in a study on epiretinal cell proliferation in macular pucker and vitreomacular traction syndrome, found Muller cells and hyalocytes to be the predominant cell type in macular pucker specimens. The presence of glial cells and hyalocytes were shown on all surgically removed iERM specimens as they stained positive for glial fibrillary acidic protein (GFAP), CD45, CD68, CD163, vimentin, and cellular retinaldehyde binding protein (CRALBP) through immunostaining. Kir4.1 was also found in iERMs, which is reported to be found on Muller cell end-feet membranes. However, in this study, immunostaining for pan-cytokeratin was negative, predicting a very low role of RPE cells in iERMs. Muller cell immunomarkers including GFAP, CRALBP, vimentin, and Kir4.1 as well as all hyalocyte markers were all stained positive indicating the important roles of these cells in iERMs. Remarkably, this study also found colocalizations of GFAP and hyalocyte markers CD45 and CD163 in 20% of specimens. As surprising as this may be, hyalocytes with positive GFAP expression have been described in other species therefore these double-labelled cells may represent hyalocytes. Since hyalocytes are considered to be of macrophage lineage, they could have phagocytosed GFAP positive debris or apoptotic cells, which might be an explanation for their immunopositivity for GFAP. Overall these results reassure the hypothesis that hyalocytes and Muller cells constitute the major cell type in iERMs. More recently, research has also focused on the role of the posterior

hyaloid in iERM formation and contraction and proteomics have also clarified the growth factors and cytokines involved in iERM formation, most importantly nerve growth factor, glial cell line-derived growth factor, and transforming growth factor β 1 (31-34).

As described previously the ability of ERM to contract is believed to cause distortion of the retinal structure and decreased visual acuity. Surgical intervention with vitrectomy and membrane removal are currently recommended for patients with visual impairment as early surgical intervention for symptomatic ERM has been linked to better postoperative visual outcome. While the postoperative outcome in advanced cases of ERM was reported to remain unsatisfactory. Conversely, early vitrectomy and ERM removal is a matter of debate in patients with good visual acuity, as it is suggested to increase the risk of postoperative visual loss and cataract development (34,35-39).

Table 1. Antibodies used for immunocytochemical staining.

Antibodies	Target cells/structure
Glial fibrillary acidic protein	Glial cells
Vimentin	Glial cells
Cellular binding (CRALBP)	retinaldehyde protein Glial cells/Retinal pigment epithelial cells
Kir4.1	Muller cell end-feet membranes
CD 45	Hyalocytes
CD 64	Hyalocytes
CD 168	Hyalocytes
Pan-cytokeratin	Retinal pigment epithelial cells
Neurofilament	Retinal ganglion cells
Alpha-smooth actin	muscle Fibroblasts/ Myofibroblasts
CD68	Microphages and Microglia

2. OBJECTIVES

The aim of this study was to analyze the tissue characteristics in retinal surface disorders in four groups of patients including iERM, macular rupture, retinal detachment and diabetic retinopathy. Tissue analysis will be carried out using immunohistochemistry. Samples from each group were evaluated for their expression of vascular endothelial growth factor (VEGF) which correlate angiogenesis and their expression of NESTIN (NES) which is a type VI intermediate filament protein found in immature neuronal tissues and represent states of stemness, or differentiation, among retinal cells (40-43), using antibodies against VEGF and NESTIN.

In this study we hypothesise that VEGF is more expressed in less differentiated cells which should also show an overexpression of NESTIN.

3. MATERIALS AND METHODS

3.1. Patients

ERM samples were collected over 4 years from 157 patients whose age group ranged between 12 and 82 years. The median age was 71 years. 85 out of the 157 patients were male and 72 were female. The inclusion criteria for the study was the diagnosis of ERM that were confirmed with optical coherence tomography (OCT) and visual acuity of 0.5 or less. The ERM tissues were collected during the Pars Plana Vitrectomy (PPV) surgery while removing this tissue from the eye along with the vitreous gel. Some of the surgeries were carried out under general anaesthesia and other under local or sub-tenon's anaesthesia. The patients in this study who underwent PPV surgery and removal of ERM had a visual acuity of 0.5 or less, this was the primary criteria for selective surgery. The patients also had metamorphosia which is a type of distorted vision in which a grid of straight lines appears wavy and parts of the grid may appear blank. Some samples also contained retinal tissue including ILM.

Other co-morbidities in these patients were not considered as an exclusion criteria for sample collection from these patients as these tissues are rare, minute, fragile and comorbidities other than the ones used for grouping these samples were not considered a factor that would influence the tissue characteristics of these retinal surface disorders and hence not relevant for this study.

3.2. Organisation of the study

The samples obtained were categorised into four groups based on the morbidities of patients from whom the samples were collected. These groups were: patients with iERM, ruptured macula, retinal detachment (including fresh, trauma and re-detachment) and finally diabetic retinopathy/fibrovascular proliferation. Specimens analysed included inner limiting membranes, epiretinal membranes and specimens from proliferative vitreoretinopathy.

3.3. Place of the study

The surgeries took place at the Department of ophthalmology, University Hospital of Split, Croatia. The samples were preserved, sliced and stained with hematoxylin and eosin staining at the pathology department and the immunohistochemical staining and analysis of the tissue were carried out at the medical faculty of University of Split School of Medicine.

3.4. Methods of tissue preservation and processing

The samples were processed with transverse cuts and then embedded in paraffin blocks. These blocks were then cut into 7 μm thick sections and investigated under immunofluorescence. After de-paraffinization, tissue sections were rehydrated using alcohol and water. The samples were then thoroughly rinsed in distilled water and heated in a microwave oven with sodium citrate buffer (pH 6.0) at 95°C for 12 minutes. The slides were then cooled at room temperature before being incubated with primary antibody.

Following the application of the primary antibody - NESTIN, the tissue sample was kept overnight in a humidified chamber at room temperature. Sections were rinsed with PBS and incubated with the secondary antibody - VEGF for one hour in a humidified chamber. Slides were mounted with the mounting media and cover slip applied. Sections were observed and images were captured using a BX51 microscope (Olympus, Tokyo, Japan) equipped with a DP71 digital camera (Olympus, Tokyo, Japan).

Images were processed with Cella Imaging Software for Life Sciences Microscopy (Olympus Tokyo, Japan). Microscopic imaging from Hematoxylin and eosin stain were also performed. Images were captured for analysis using 40 \times objective magnification and 100x oil immersion magnification and microphotographs were examined using Image J software (National Institutes of Health, Bethesda, MD, USA). Cells that expressed NESTIN or VEGF or both together were analyzed and the results were compared between the groups.

To evaluate the expression of VEGF and NESTIN protein, we used a scoring system used by Tsanou *et al.* during their immunohistochemical study of angiogenesis and proliferative activity in epiretinal membranes, which corresponds to the sum of scoring intensity (0 = negative, 1 = weak, 2 = intermediate and 3 = strong staining) and was semiquantitatively scored as +, ++ and +++ corresponding to small, moderate and high amount of positive cells, respectively (43).

4. RESULTS

Due to its minute size and fragility, out of 157 samples collected, only 80 were able to be preserved in paraffin wax and only 41 samples in total (from 38 patients) were viable after slicing and hematoxylin and eosin staining. Out of these 41 samples five showed reaction to the antibodies used. One from the iERM category and four from the retinal detachment category. No samples were viable from the other two categories.

Table 2 and table 3 Shows the results from the four groups compared using the scoring system by Tsanou *et al.* (43).

Table 2. VEGF and NESTIN expression in the four groups of patients.

Proteins	Group 1 (iERM)	Group 2 (Macular rupture)	Group 3 (Retinal detachment)	Group 4 (Diabetic retinopathy)
VEGF	+	-	+	+
NESTIN	+	-	++	+

Semiquantitative scoring system for the expression of VEGF and NESTIN scored as +, ++ and +++ corresponding to small, moderate and high number of positive cells, respectively in the four groups of patients.

As it can be seen from table 2, group 2 did not produce any viable results. NESTIN and VEGF were not expressed in any of the patients from these which corresponded to samples from patients with rupture of the macula. This could be due to the fragility of the sample in this category of patients. Extracting ERM samples from patients who have a macular rupture is of great difficulty as the ERM samples are not able to be extracted as a whole from this category. They are extracted in pieces.

Group 1, 3 and 4 all expressed a small amount of VEGF however, Group 3 expressed a moderate amount of NESTIN compared to Group 1 and 4 which only expressed a small amount.

Table 3. VEGF and NESTIN Staining intensity.

Proteins	Group 1 (iERM)	Group 2 (Macular rupture)	Group 3 (Retinal detachment)	Group 4 (Diabetic retinopathy)
VEGF	1	0	1	1
NESTIN	1	0	2	2

Staining intensity scored from 0 to 3 (0 = negative, 1 = weak, 2 = intermediate and 3 = strong staining).

Staining intensity of the samples produced corresponding results to that of the level of expression. Groups 2 and 4 showed 0 or negative intensity and VEGF staining showed a weak staining in both Groups 1 and 3, whereas NESTIN showed a 2 or intermediate level of staining in Group 3 samples compared to Group 1 where it only showed a 1 or weak staining.

Shown below are images from immunohistochemistry showing representative samples from Groups 1 and 3 expressing the primary and secondary antibodies - NESTIN (green) and VEGF (red) respectively. Colocalization of the two markers were also seen in some cases especially within the inflammatory cells, as visible on Figure 3c. The fluorescence in these inflammatory cells should be received with caution as they are active most of the time and so the secondary antibody binds to them instead of the primary antibody and hence, they express a degree of autofluorescence.

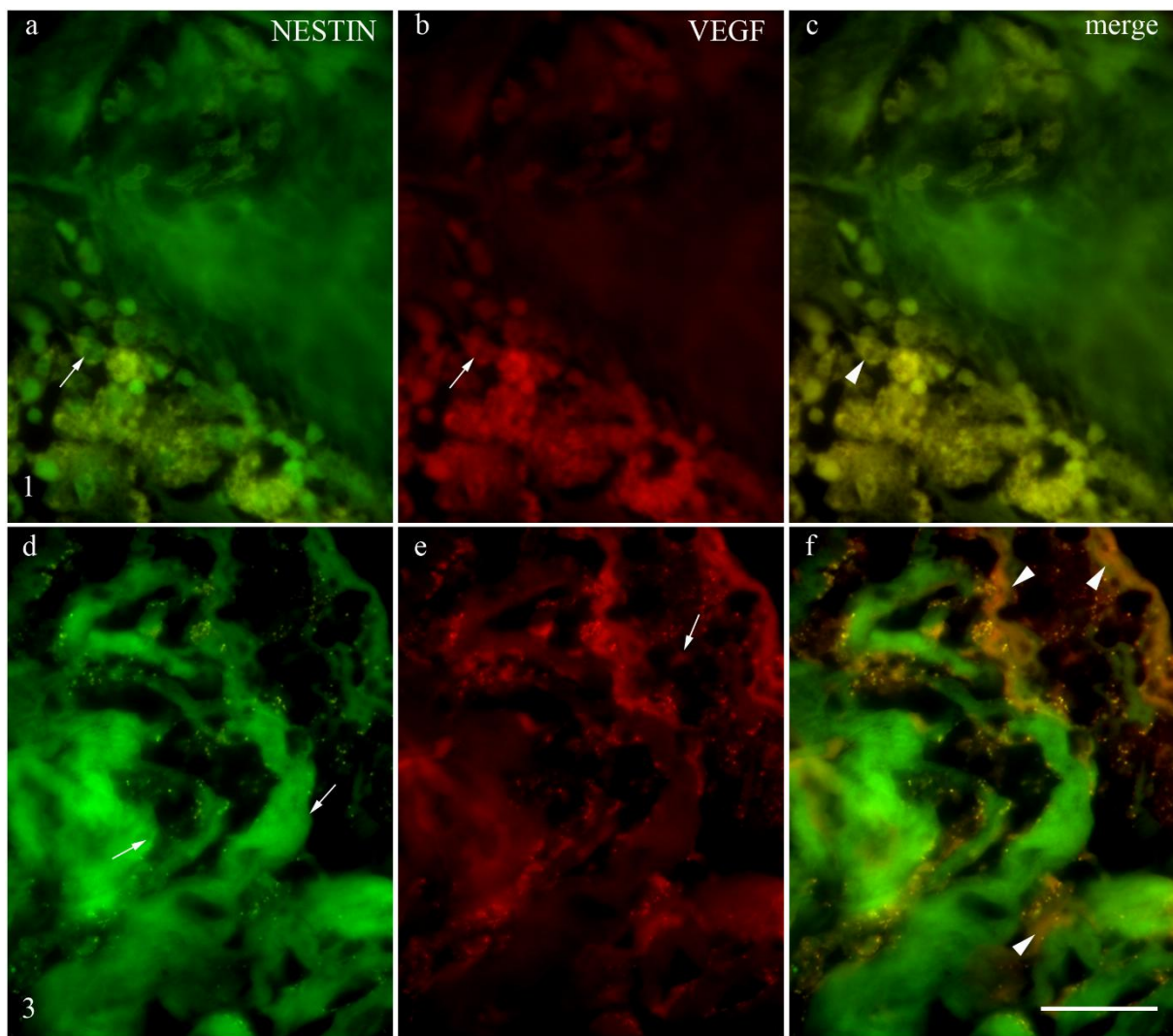


Figure 3. Expression of NESTIN, VEGF and their colocalization in retinal tissue at x100 magnification. A and D shows the expression of NESTIN in green. B and E shows the expression of VEGF in red. The arrow heads on C and F shows the colocalization of these markers. The bar on F measures 40 micro meters.

5. DISCUSSION

Although the tissue characteristics of retinal surface disorders, especially the ERM are not fully understood, many growth factors seem to be implicated in their pathogenesis and progression. Angiogenesis is a vital factor involved in a large number of eye diseases that cause severe loss of vision. In the process of vascularisation cell-derived angiogenic factors as well as the appropriate synthesis of extracellular matrix components necessary for anchorage of migrating endothelium are activated. Due to its expression induced by hypoxia, VEGF is of particular interest. This phenomenon is the major factor of pathologic retinal angiogenesis (43).

VEGF is a mitogen for endothelial cells *in vitro*, and its effect are complex multistep processes in which capillary endothelial cells demonstrate their normal cell–cell attachments, migrate and proliferate into the peri-vascular extracellular matrix, in which they eventually refrain from cell–cell associations to create new capillaries (43,44). We found positive expression in all the groups except for Group 2.

VEGF-positive cells showed similar expression in three out of four categories. These were all avascular tissues and their VEGF expression points towards likelihood of angiogenesis in these avascular tissues. These results were similar to that of several previous studies by Tsanou *et al.* were specifically abundant and presented an intense immunoreactivity in PDR membranes, they were also present in the relatively avascular PVR membranes, in accordance with other studies (43-46). This phenomenon could be partly attributed to its production by retinal pigmented epithelial cells, which are present in both types of membranes. On the other hand, Frank *et al.* in their study found contradicting results to ours (47). They found no evidence of VEGF immunoreactivity in avascular membranes. In agreement with its pivotal role in vascular development, VEGF also stimulates differentiation, survival, migration, proliferation, tubulogenesis and vascular permeability in endothelial cells and exerts pleiotropic effects on diverse cell types and tissues (43,31)

Regardless of our finding, VEGF on its own is not always capable of angiogenesis. Previous studies have shown that this could be the result of the presence of endothelial growth factor inhibitors, such as transforming growth factor (48), secreted by glial cells that prevent VEGF from exerting its angiogenic activity. The role of glial cells in ERM has long been discussed throughout several studies. In accordance with previous studies (49), the presence of glial cells, labelled by GFAP, was not related to new vessel formation, suggesting that they may not have an important role in vascularization of the tissues, although it has been suggested that astrocytes modulate retinal vasculogenesis (50,51) by effecting the distribution of fibronectin and laminin proteins (31). Despite the controversy our results suggest a

potential for angiogenesis and proliferative neural tissue characteristics (as they stained positive for NESTIN) in these tissues.

VEGF is one of the most widely studied vitreoretinal growth factors, especially because of its expression in ERM tissues. In a study by Mandelcorn *et al.* 11 (85%) of 13 iERMs stained positively for VEGF, but there was no statistically significant relationship between the presence of VEGF and leakage on fluorescein angiogram (52). In a study by Chen *et al.* they also found positive VEGF immunoreactivity of iERMs (53). However, since retinal glia have been known to produce VEGF, this is not surprising (54). It is interesting to note that there are no blood vessels in iERM despite the presence of VEGF. One possibility is that there are other cells in the iERM other than endothelial cells that are targeted by VEGF. It is also probable that factors such as the endothelial growth inhibitory factors, like TGF-beta, may be a preventative factor that inhibits VEGF from exerting its angiogenic activity (31,48).

As aforementioned, NESTIN was expressed in all of the samples except samples from Group 2 which belonged to macular ruptures. NESTIN, which is a neural stem-cell marker, is reportedly mainly expressed in Muller glial stem cells during the embryonic stage (32, 54-57). As mentioned before, in a study by Zhao *et al.* Muller cells and hyalocytes were found to be the predominant cell type in macular pucker specimens (33).

Immunocytochemistry has made it apparent that the most abundant cell types found in the ERMs are glia, macrophages, RPE cells, and fibroblasts (44). Evidence exists for the presence of NESTIN-1 positive neural progenitor like cells in these membranes (58). These studies by Mayer *et al.* emphasize the capacity of Müller cells, the predominant retinal glial cells, to express NESTIN-1 in response to a variety of acute damages such as retinal detachment (59), and hypothesize that Müller cells are able to re-differentiate into retinal neurons after a neurodegenerative disease (60). This evidence in concordance with the results from this study, where we also found NESTIN positivity in Groups 1, 3 and 4 and the most expression of NESTIN was seen in Group 3 which are sample from patients who had retinal detachment.

Therefore, NESTIN being one of the markers for progenitor cells, Mayer *et al.* found NESTIN staining patterns associated with cells of neural and glial morphology in both the adult human retina and ERMs removed during retinal surgery (44,58). These results are comparable to the results from this study.

In the adult human retina, NESTIN staining has shown that the ora serrata may be a growth or germinal zone equivalent to the anatomically similar ciliary margin zone (CMZ). The CMZ gives rise to new retinal cells (15,16). The expression of NESTIN is also known to

be upregulated under ischemic and traumatic pathological conditions in the adult rat retina. In 2003, Mayer *et al.* also reported the presence of NESTIN not only in the CMZ of the adult human retina, but also in the optic nerve head, the posterior retina, and ERMs as mentioned above. However, the nature of the ERMs were not clear in terms of idiopathic or secondary ERMs (58,61-64).

In a study by Ueki *et al.* no NESTIN-positive cells were observed in any iERMs, however they were observed in 7 of the 8 secondary ERMs. The study showed that there are a large number of NESTIN-positive undifferentiated cells in secondary ERMs, and this may be related to the onset and pathogenesis of secondary ERM, including ERM from retinal detachments and ERMs associated with PDR. These results were consistent with our findings as the most expression of NESTIN positive tissue was in Group 3 which are samples from retinal detachments, see tables 2 and 3. Furthermore, Group 4 samples which corresponds to PDR also showed expression of NESTIN, similar to the results obtained by Ueki and his team (32). The intensity of staining for NESTIN was also higher in Groups 3 and 4.

On the other hand, Group 1 in our study whose sample were taken from iERMs also showed mild expression of NESTIN in contrast to Ueki et al (32).

In conclusion, the findings of this study indicate that there are different histological characteristics between different retinal surface disorders, especially ERMs that are idiopathic and secondary. The pathogenesis of secondary ERM as in Groups 2, 3 and 4 is suggestive as a result of intraocular inflammation and/or retinal ischemic changes.

Given the immaturity of the ERM tissue, the results from this study confirms the hypothesis that VEGF is more expressed in less differentiated cells which also show an overexpression of NESTIN. This correlates with our results obtained, from Groups 1, 3 and 4.

This study was limited to the number of patients and the samples that we were able to obtain. Due to the fragility and minute size of the tissue in question, obtaining these samples and preserving them was of great difficulty and we were not able to use all of them as tissue broke down during their preservation in paraffin wax and some during the staining process. In future studies on the topic, it was discussed that the use of a confocal microscope would allow better visualization of these markers especially because the samples would not have to undergo embedding in paraffin wax. Furthermore, the samples could be tested for their expression of Ki67 and GFAP and results compared to published studies to acquire more conclusive results.

6. CONCLUSION

Despite the advances in imaging technology, immunohistochemistry, and proteomics, the exact mechanism in the development and pathogenesis of some retinal surface disorders such as iERM formation is still unclear. We found NESTIN positive tissue in our samples which suggests their proliferation capacity and their immaturity. Positive VEGF expression in these tissues in accordance with studies carried out before suggests their potential for angiogenesis especially in patients with retinal detachments and diabetic retinopathy. Further studies are needed to evaluate the cells, cytokines, and growth factors involved in iERM formation.

7. REFERENCES

1. Moore K. Clinically oriented anatomy. 8th ed. Philadelphia: LWW; 2017. p. 889-913.
2. René C. Update on orbital anatomy. Eye. 2006;20(10):1119-29.
3. Sclera - an overview | ScienceDirect Topics (Internet). Sciencedirect.com. 2019. Available from: <https://www.sciencedirect.com/topics/neuroscience/sclera>
4. Cornea - an overview | ScienceDirect Topics (Internet). Sciencedirect.com. 2019. Available from: <https://www.sciencedirect.com/topics/neuroscience/cornea>
5. Uvea - an overview | ScienceDirect Topics (Internet). Sciencedirect.com. 2019. Available from: <https://www.sciencedirect.com/topics/neuroscience/uvea>
6. Nickla D, Wallman J. The multifunctional choroid. Prog Retin Eye Res. 2010;29(2):144-68.
7. Iris | eye (Internet). Encyclopedia Britannica. 2019. Available from: <https://www.britannica.com/science/iris-eye>
8. Nguyen QD, Rodrigues EB, Farah ME, Mieler WF, Do DV. Retinal Pharmacotherapeutics. Dev Ophthalmol. 2016;55:7-17
9. Lang G. Ophthalmology. Stuttgart: Thieme; 2007. p. 328-37.
10. Kanski J, Bowling B. Clinical ophthalmology. Barcelona: Elsevier; 2016. p. 681-713.
11. Basic and clinical science course. American academy of ophthalmology; New York; 2016. p. 82-100.
12. Gupta M, Herzlich A, Sauer T, Chan C. Retinal Anatomy and Pathology. Dev Ophthalmol. 2016;55:7-17.
13. Retina - an overview | ScienceDirect Topics (Internet). Sciencedirect.com. 2019. Available from: <https://www.sciencedirect.com/topics/neuroscience/retina>
14. Amacrine Cell - an overview | ScienceDirect Topics (Internet). Sciencedirect.com. 2019. Available from: <https://www.sciencedirect.com/topics/neuroscience/amacrine-cell>
15. Eye Anatomy Vector Art & Graphics | freevector.com (Internet). FreeVector.com. 2019. Available from: <https://www.freevector.com/eye-anatomy-vector>
16. Vitreous Humour - an overview | ScienceDirect Topics (Internet). Sciencedirect.com. 2019. Available from: <https://www.sciencedirect.com/topics/veterinary-science-and-veterinary-medicine/vitreous-humour>
17. Diseases of the vitreous body – Knowledge for medical students and physicians (Internet). Amboss.com. 2019. Available from: https://www.amboss.com/us/knowledge/Diseases_of_the_vitreous_body
18. Gandorfer A. Epiretinal pathology of vitreomacular traction syndrome. BJO. 2002;86(8):902-9.

19. Learn about Common Retinal Disorders (Internet). Bayarearetina.com. 2019. Available from: <http://bayarearetina.com/retinaldisorders.html>
20. Miller J, Le Couter J, Strauss E, Ferrara N. Vascular endothelial growth factor A in intraocular vascular disease. *Ophthalmology*. 2013;120(1):106-14.
21. Kreissig I. Primary retinal detachment: A review of the development of techniques for repair in the past 80 years. *Taiwan J Ophthalmol*. 2016;6(4):161-9.
22. Mohammad Rafieetary M. Rhegmatogenous Retinal Detachment: How to detect, how to manage (Internet). *Reviewofoptometry.com*. 2019. Available from: <https://www.reviewofoptometry.com/article/rhegmatogenous-retinal-detachment-how-to-detect-how-to-manage>
23. Kang H, Luff A. Management of retinal detachment: a guide for non-ophthalmologists. *BMJ*. 2008;336(7655):1235-40.
24. Gillies M, Daien V, Nguyen V, Barthelmes D. Re: Comparison of Age-Related Macular Degeneration Treatments Trials (CATT) Research Group, *et al*. Five-year outcomes with anti-vascular endothelial growth factor treatment of neovascular age-related macular degeneration: The comparison of age-related macular degeneration treatments trials. *Ophthalmology*. 2017;124(3):31-2.
25. Tranos P, Wickremasinghe S, Stangos N, Topouzis F, Tsinopoulos I, Pavesio C. Macular edema. *Surv Ophthalmol*. 2004;49(5):470-90.
26. Retinal inflammation - an overview | ScienceDirect Topics (Internet). *Sciencedirect.com*. 2019. Available from: <https://www.sciencedirect.com/topics/neuroscience/retinal-inflammation>
27. Whitcup S, Nussenblatt R, Lightman S, Hollander D. Inflammation in retinal disease. *Int J Inflam*. 2013;2013:1-4.
28. Hamel C. Retinitis pigmentosa. *Orphanet J Rare Dis*. 2006;1(1):40.
29. Hejsek L, Stepanov A, Dohnalova A, Rehakova T, Jiraskova N. The natural evolution of idiopathic epimacular membrane. *Biomed Pap*. 2017;161(1):100-6.
30. Batman C, Citrik M. The impact of macular surgery in different grades of epiretinal membrane. *Int J Ophthalmol*. 2017;10(12): 1877–82.
31. Joshi M, Agrawal S, Christoforidis J. Inflammatory mechanisms of idiopathic epiretinal membrane formation. *Mediators Inflamm*. 2013;2013:1-6.
32. Ueki M, Morishita S, Kohmoto R, Fukumoto M, Suzuki H, Sato T *et al*. Comparison of histopathological findings between idiopathic and secondary epiretinal membranes. *Int J Ophthalmol*. 2016;36(5):713-8.

33. Zhao F, Gandorfer A, Haritoglou C, Scheler R, Schaumberger M, Kampik A *et al.* Epiretinal cell proliferation in macular pucker and vitreomacular traction syndrome. *Retina*. 2013;33(1):77-88.
34. Lee S, Pak K, Kwon H, Park S, Lee J, Byon I. Association between tangential contraction and early vision loss in idiopathic epiretinal membrane. *Retina*. 2018;38(3):541-9.
35. Yorston D. *Retinal Diseases and VISION 2020*. CEHJ. 2003;16(46):19–20.
36. Wang W, Lo A. Diabetic retinopathy: Pathophysiology and treatments. *Int J Mol Sci*. 2018;19(6):16-8.
37. Romano M, Iardi G, Ferrara M, Cennamo G, Allegrini D, Pafundi P *et al.* Intraretinal changes in idiopathic versus diabetic epiretinal membranes after macular peeling. *PLOS ONE*. 2018;13(5):e0197065.
38. Stevenson W, Prospero Ponce C, Agarwal D, Gelman R, Christoforidis J. Epiretinal membrane: optical coherence tomography-based diagnosis and classification. *Clin Ophthalmol*. 2016;10:527-34.
39. Hamoudi H, Correll Christensen U, La Cour M. Epiretinal membrane surgery: an analysis of 2-step sequential- or combined phacovitrectomy surgery on refraction and macular anatomy in a prospective trial. *Acta Ophthalmol Scand*. 2017;96(3):243-50.
40. Weleber R, Kurz D, Trzuppek K. Treatment of retinal and choroidal degenerations and dystrophies: current status and prospects for gene-based therapy. *Ophthalmol Clin North Am*. 2003;16(4):583-93.
41. García-Layana A, García-Arumí J, Ruiz-Moreno J, Arias-Barquet L, Cabrera-López F, Figueroa M. A review of current management of vitreomacular traction and macular hole. *J Ophthalmol*. 2015;2015:1-14.
42. Schmitt S, Aftab U, Jiang C, Redenti S, Klassen H, Miljan E *et al.* Molecular characterization of human retinal progenitor cells. *Invest Ophthalmol Vis Sci*. 2009;50(12):5901.
43. Tsanou E, Ioachim E, Stefanidou M, Gorezis S, Charalabopoulos K, Bagli H *et al.* Immunohistochemical study of angiogenesis and proliferative activity in epiretinal membranes. *Int J Clin Pract*. 2005;59(10):1157-61.
44. Andjelić S, Lumi X, Yan X, Graw J, Moe M, Facskó A *et al.* Characterization of ex vivo cultured neuronal- and glial- like cells from human idiopathic epiretinal membranes. *BMC Ophthalmol*. 2014;14(1):165.

45. Armstrong D, Augustin A, Spengler R, Al-Jada A, Nickola T, Grus F *et al.* Detection of vascular endothelial growth factor and tumor necrosis factor alpha in epiretinal membranes of proliferative diabetic retinopathy, proliferative vitreoretinopathy and macular pucker. *Ophthalmologica*. 1998;212(6):410-4.
46. Schneeberger S, Hjelmeland L, Tucker R, Morse L. Vascular endothelial growth factor and fibroblast growth factor 5 are colocalized in vascular and avascular epiretinal membranes. *Am J Ophthalmol*. 1997;124(4):447-54.
47. Frank R, Amin R, Elliott D, Puklin J, Abrams G. Basic fibroblast growth factor and vascular endothelial growth factor are present in epiretinal and choroidal neovascular membranes. *Am J Ophthalmol*. 1996;122(3):393-403.
48. Behzadian M, Wang X, Jiang B, Caldwell R. Angiostatic role of astrocytes: Suppression of vascular endothelial cell growth by TGF- β and other inhibitory factor(s). *Glia*. 1995;15(4):480-90.
49. Hosoda Y, Okada M, Matsumura M, Ogino N, Honda Y, Nagai Y. Epiretinal membrane of proliferative diabetic retinopathy: An immunohistochemical study. *Ophthalmic Res*. 1993;25(5):289-94.
50. Jiang B, Alibezhadian M, Caldwell R. Astrocytes modulate retinal vasculogenesis: Effects on endothelial cell differentiation. *Glia*. 1995;15(1):1-10.
51. Mandelcorn E, Khan Y, Javorska L, Cohen J, Howarth D, Mandelcorn M. Idiopathic epiretinal membranes: cell type, growth factor expression, and fluorescein angiographic and retinal photographic correlations. *Can J Ophthalmol*. 2003;38(6):457-63.
52. Chen Y, Hackett S, Schoenfeld C, Viores M, Viores S, Campochiaro P. Localisation of vascular endothelial growth factor and its receptors to cells of vascular and avascular epiretinal membranes. *BJO*. 1997;81(10):919-26.
53. Hata Y, Nakagawa K, Sueishi K, Ishibashi T, Inomata H, Ueno H. Hypoxia-induced expression of vascular endothelial growth factor by retinal glial cells promotes in vitro angiogenesis. *Virchows Arch*. 1995;426(5):479-86.
54. Bhatia B, Singhal S, Lawrence J, Khaw P, Limb G. Distribution of Müller stem cells within the neural retina: Evidence for the existence of a ciliary margin-like zone in the adult human eye. *Exp Eye Res*. 2009;89(3):373-82.
55. Bhatia B, Jayaram H, Singhal S, Jones M, Limb G. Differences between the neurogenic and proliferative abilities of Müller glia with stem cell characteristics and the ciliary epithelium from the adult human eye. *Exp Eye Res*. 2011;93(6):852-61.

56. Chidlow G, Daymon M, Wood J, Casson R. Localization of a wide-ranging panel of antigens in the rat retina by immunohistochemistry. *J Histochem Cytochem.* 2011;59(10):884-98.
57. Frøen R, Johnsen E, Petrovski G, Berényi E, Facskó A, Berta A *et al.* Pigment epithelial cells isolated from human peripheral iridectomies have limited properties of retinal stem cells. *Acta Ophthalmol Scand.* 2011;89(8):635-44.
58. Mayer E. Nestin positive cells in adult human retina and in epiretinal membranes. *BJO.* 2003;87(9):1154-8.
59. Luna G, Lewis GP, Banna CD, Skalli O, Fisher SK. Expression profiles of Nestin and synemin in reactive astrocytes and Müller cells following retinal injury: a comparison with glial fibrillar acidic protein and vimentin. *Mol Vis.* 2010;16:2511–23.
60. Valamanesh F, Monnin J, Morand-Villeneuve N, Michel G, Zaher M, Miloudi S *et al.* Nestin expression in the retina of rats with inherited retinal degeneration. *Exp Eye Res.* 2013;110:26-34.
61. Fang M, Hu Z, Li Y, Li J, Yew D, Ling S. Nestin positive cells in the retina and spinal cord of the sturgeon after hypoxia. *Int J Neurosci.* 2009;119(4):460-70.
62. Xue L, Ding P, Xiao L, Hu M, Hu Z. NESTIN, A new marker, expressed in Müller cells following retinal injury. *Can J Neurol Sci.* 2010;37(5):643-9.
63. Holman M, Chidlow G, Wood J, Casson R. The effect of hyperglycemia on hypoperfusion-induced injury. *Invest Ophthalmol Vis Sci.* 2010;51(4):2197.
64. Xue L, Ding P, Xiao L, Hu M, Hu Z. NESTIN is induced by hypoxia and is attenuated by hyperoxia in Müller glial cells in the adult rat retina. *Int J Exp Pathol.* 2011;92(6):377-81.

8. SUMMARY

Objectives: The objective of this study was to analyze the tissue characteristics in retinal surface disorders in four groups of patients including iERM, macular rupture, retinal detachment and diabetic retinopathy. It was hypothesised that VEGF is more expressed in less differentiated cells which should also show an overexpression of NESTIN.

Materials and methods: ERM samples were collected over 4 years from 157 patients whose age group ranged between 12 and 82 years. The median age was 71 years. 85 out of the 157 patients were male and 72 were female. The inclusion criteria for the study was the diagnosis of ERM that were confirmed with optical coherence tomography (OCT) and visual acuity of 0.5 or less. The ERM tissues were collected during the Pars Plana Vitrectomy (PPV) surgery. The samples were embedded in paraffin blocks before they were cut and stained using immunohistochemistry. NESTIN was the primary antibody used and VEGF was the secondary antibody. Sections were observed and images were captured using a BX51 microscope (Olympus, Tokyo, Japan) equipped with a DP71 digital camera (Olympus, Tokyo, Japan). Images were then processed with Cella Imaging Software for Life Sciences Microscopy (Olympus Tokyo, Japan). Microscopic imaging with Hematoxylin and eosin stain were also performed. Tsanou *et al.* scoring system was used to evaluate the expression of VEGF and NESTIN. The intensity of staining was scored 0 to 3 (0 = negative, 1 = weak, 2 = intermediate and 3 = strong staining) and was semiquantitatively scored as +, ++ and +++ corresponding to small, moderate and high number of positive cells, respectively.

Results: We found that the expression of NESTIN was mostly seen in ERMs of retinal detachments and VEGF was equally expressed in Groups 1, 3 and 4. Neither of the proteins were expressed in Group 2 samples which represented iERMs. It was also discussed that during future studies, it would be ideal to use a confocal microscope which will allow better tissue preservation and the expression of Ki67 and GFAP would also be analyzed.

Conclusions: It was concluded that the exact mechanism in the development and pathogenesis of some retinal surface disorders such as iERM formation is still unclear. We found NESTIN positive tissue in our samples which suggests their proliferation capacity and their immaturity. Positive VEGF expression in these tissues shows their potential for angiogenesis especially in patients with retinal detachments and diabetic retinopathy. The results from this study confirmed the hypothesis that VEGF is more expressed in less differentiated cells which also show an overexpression of NESTIN.

9. CROATIAN SUMMARY

Naslov: Karakteristike tkiva u poremećajima površine retine.

Ciljevi: Cilj ovog istraživanja je analiza karakteristika tkiva u poremećajima površine mrežnice u četiri skupine bolesnika, uključujući iERM, rupturu makule, odvajanje mrežnice i dijabetičku retinopatiju. Pretpostavljeno je da je VEGF izraženiji u manje diferenciranim stanicama, što bi također trebalo pokazati prekomjernu ekspresiju NESTIN-a.

Materijali i metode: Uzorci ERM-a prikupljeni su tijekom 4 godine od 157 pacijenata bolesnika čija se dobna skupina kretala između 12 i 82 godina. Srednja dob bila je 71 godina. Od ukupnog broja bolesnika 85 ih je bilo muškog spola, a 72 ženskog. Kriteriji za uključivanje u studiju bili su dijagnoza ERM-a koja je potvrđena optičkom koherentnom tomografijom (OCT) i oštrinom vida od 0,5 ili manje. ERM tkiva prikupljena su tijekom operacije Pars Plana Vitrektomije (PPV). Uzorci su ugrađeni u parafinske blokove prije nego što su izrezani i imunohistokemijski obojeni. NESTIN je primarno korišteno protutijelo, a VEGF je sekundarno antitijelo. Promatrane su sekcije i snimljene su slike pomoću mikroskopa BX51 (Olympus, Tokyo, Japan) opremljenog digitalnim fotoaparatom DP71 (Olympus, Tokyo, Japan). Slike su zatim obrađene pomoću Cella Imaging Software-a za mikroskopiju Life Sciences (Olympus Tokyo, Japan). Također su provedena mikroskopska snimanja s Hematoxylin i eosin bojama. Tsanou i sur. Sustav bodovanja korišten je za procjenu ekspresije VEGF-a i NESTIN-a. Intenzitet bojenja je bodovan 0-3 (0 = negativno, 1 = slabo, 2 = srednje i 3 = jako) i bio je polu-kvantitativno ocjenjen kao +, ++ i +++ što odgovara malom, umjerenom i velikom broju pozitivnih stanica.

Rezultati: Otkrili smo da se ekspresija NESTIN-a uglavnom vidi u ERM-u retinalnih izdvajanja, a VEGF je jednako izražen u skupinama 1, 3 i 4. Nijedan od proteina nije ekspresiran u uzorcima skupine 2 koji su predstavljali iERM. Također je raspravljano da bi tijekom budućih studija bilo idealno koristiti konfokalni mikroskop koji će omogućiti bolje očuvanje tkiva i analizirati ekspresiju Ki67-a i GFAP-a.

Zaključci: Zaključeno je da je točan mehanizam u razvoju i patogenezi nekih poremećaja površine mrežnice kao što je iERM formacija još uvijek nejasan. Našli smo NESTIN pozitivno tkivo u našim uzorcima što sugerira njihovu sposobnost proliferacije i njihovu nezrelost. Pozitivna ekspresija VEGF-a u tim tkivima pokazuje njihov potencijal za angiogenezu, posebno u bolesnika s retinalnim odvajanjima i dijabetičkom retinopatijom. Rezultati ove studije potvrdili su hipotezu da je VEGF izraženiji u manje diferenciranim stanicama koje također pokazuju prekomjernu ekspresiju NESTIN-a.

10. CURRICULUM VITAE

Personal Information

Name: Arun Joseph

Date of birth: 06/11/1991

Address: 29 Mill Bridge Close, Retford, Nottinghamshire, UK

Email: arunjoseph91@gmail.com

Education

September 2013 – July 2019

Medicine (m.d.), University of Split School of Medicine, Croatia

September 2010 – september 2013

Biomedical Science (BSc Honours) – upper 2.1, University of Lincoln

September 2006 – July 2010

A levels, McAuley catholic high school and sixth form

Mathematics, Chemistry, Biology (grades B-C) and AS Level in Philosophy and Ethics

Experience

April 2016 - Present

Voluntary Twinning Officer the Diocese of Hallam, Sheffield

October 2018 – February 2019

Pharmacy Dispenser, Jhoots Pharmacy, Retford

May 2007 – October 2018

Carer for the elderly/ Administration Department Manager, Glenesk Residential Care Home, Retford, Nottinghamshire

August 2013, August 2016

Volunteer Queen's Medical Centre Nottingham

March 2016 – July 2016

English Language Tutor Inicijativa Larkin D.O.O

March 2015 – April 2015

Anatomy Demonstrator University of Split School of Medicine

October 2012 – May 2013

Stem Cell Research Project University of Lincoln, Lincoln

January 2009 – December 2012

Voluntary Carer Bassetlaw Hospice, Retford Nottinghamshire