

Percutaneous internal ring suturing : a novel minimally invasive technique for inguinal hernia repair in children : a 5-year single surgeon experience

Čohadžić, Tin

Master's thesis / Diplomski rad

2020

Degree Grantor / Ustanova koja je dodijelila akademski / stručni stupanj: **University of Split, School of Medicine / Sveučilište u Splitu, Medicinski fakultet**

Permanent link / Trajna poveznica: <https://um.nsk.hr/um:nbn:hr:171:678698>

Rights / Prava: [In copyright](#)/[Zaštićeno autorskim pravom.](#)

Download date / Datum preuzimanja: **2024-11-28**



Repository / Repozitorij:

[MEFST Repository](#)



**UNIVERSITY OF SPLIT
SCHOOL OF MEDICINE**

Tin Čohadžić

**PERCUTANEOUS INTERNAL RING SUTURING: A NOVEL
MINIMALLY INVASIVE TECHNIQUE FOR INGUINAL HERNIA
REPAIR IN CHILDREN:
A 5-YEAR SINGLE SURGEON EXPERIENCE**

Diploma thesis

Academic year:

2019/2020

Mentor:

Assoc. Prof. Zenon Pogorelić, MD, PhD

Split, July 2020

CONTENT

1. INTRODUCTION	1
1.1. ANATOMY OF THE INGUINAL REGION	2
1.2. INGUINAL HERNIA	5
1.2.1. Anatomy of the inguinal hernia	5
1.2.2. Types of inguinal hernia	5
1.2.2.1. Indirect inguinal hernia	5
1.2.2.2. Direct inguinal hernia	6
1.2.3. Incidence	6
1.2.4. Clinical findings	7
1.2.5. Complications	8
1.2.6. Specific types of inguinal hernia	9
1.2.7. Diagnostic approach	9
1.2.8. Treatment	11
1.2.9. Surgical techniques	12
1.2.9.1. Open surgery	12
1.2.9.2. Laparoscopic surgery	14
2. OBJECTIVES OF RESEARCH	17
3. PATIENTS AND METHODS	19
3.1. Patients	20
3.2. Organization of the study	20
3.3. Place of the study	20
3.4. Methods of data collection and processing	21
3.5. Description of research	21
3.5.1. Primary outcome measures	21
3.5.2. Secondary outcome measures	21
3.6. Compliance with ethical standards	22
3.7. Surgery	22
4. RESULTS	24
5. DISCUSSION	30
6. CONCLUSION	35
7. REFERENCES	37
8. SUMMARY	42
9. SUMMARY IN CROATIAN	44
10. CURRICULUM VITAE	46

Acknowledgments

Thank you

To my parents for their constant prayers and for being great role models,

To my brothers for always pushing and challenging me to become better,

To the rest of my family for their continuous encouragement,

To Mila for being by my side,

To my friends who made medical school fun and adventurous,

To my professors for their patience and constant help.

My journey through medical school has had an immense impact on my life. Not only has it taught me medicine, but It has also molded me into the person I am today. When looking back I do not see the tiring days, I see the success that came out of them. I see that every second was worth it. I have made friends who motivated me after my failures and shared my joy during success. True friends that I can proudly call family. Together we filled our journey with memories that will last a lifetime.

Finally, I would like to express my deepest gratitude to my supervisor Prof. Dr. sc. Zenon Pogorelić, for his patience throughout the completion of this research work. Without his constant support, this would not have been possible.

Thank you.

LIST OF ABBREVIATIONS

ASA – American Society of Anesthesiologists

ASIS – Anterior superior iliac spine

BMI – Body mass index

IQR – Interquartile range

PIRS – Percutaneous internal ring suturing

1. INTRODUCTION

1.1. ANATOMY OF THE INGUINAL REGION

The inguinal region, known as the groin, is located in the lower anterior abdominal wall, with the pubic tubercle medially, the thigh inferiorly, and the anterior superior iliac spine (ASIS) superolaterally. This holds clinical relevance due to the exit and entrance of the inguinal canal being a potential site of herniation (*Figure 1*).

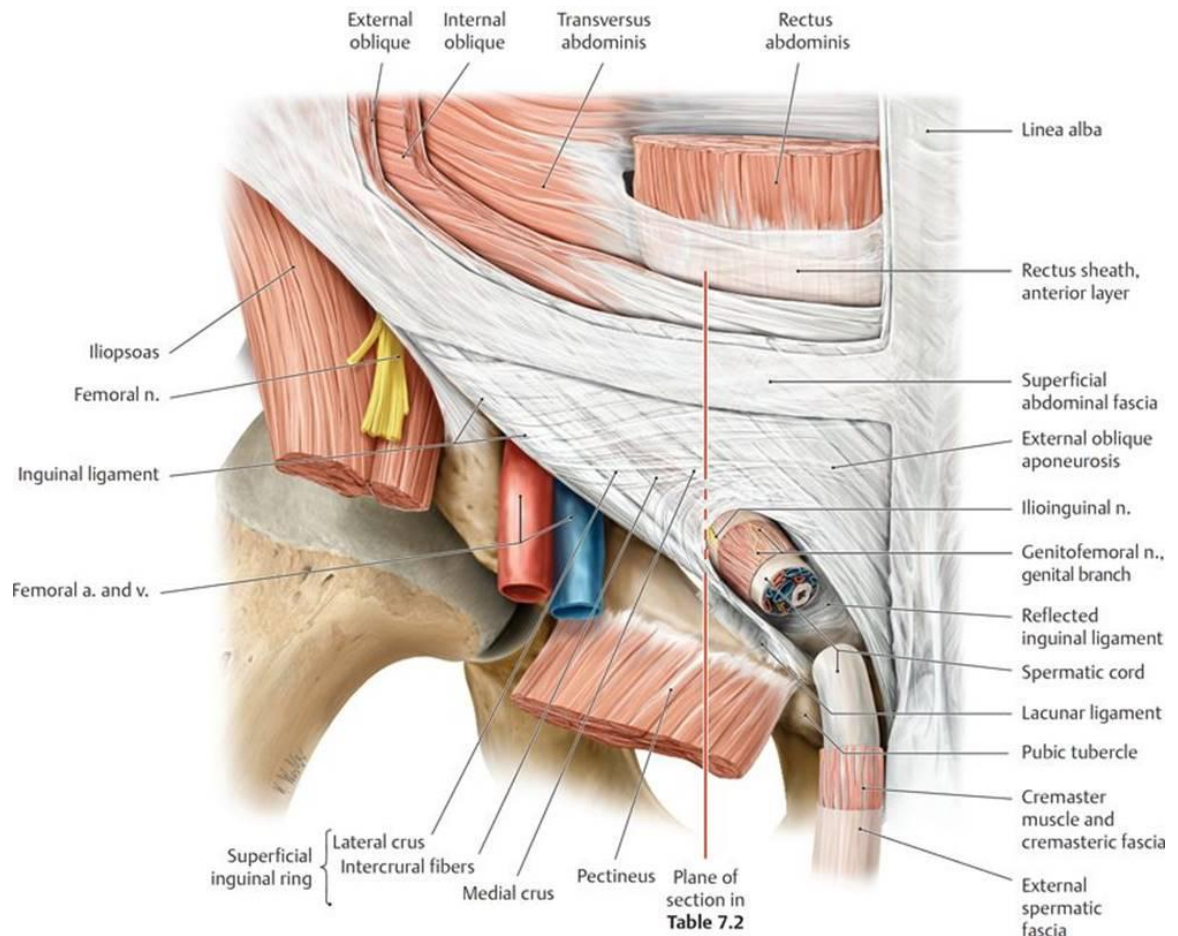


Figure 1. Anatomy of the inguinal region.

Source: <https://doctorlib.info/anatomy/anatomy-essential-textbook/10.html>

The iliopubic tract and inguinal ligament, which extends from the ASIS to the pubic tubercle, constitutes the anterior retinaculum of the hip joint. The space in which the flexor muscles of the hip and neurovascular structures continue to lower limb is known as the subinguinal space. The aponeurosis of the external oblique muscle and the inferior margin of

the transversalis fascia are major landmarks of the inguinal region (1). In an adult, the inguinal canal length is approximately 4 cm. It is positioned between the external (superficial) and internal (profound) inguinal rings approximately 3 cm above the inguinal ligament (2, 3). It lies superior and parallel to the medial half of the inguinal ligament. The inguinal canal consists of the round ligament of the uterus in females and the spermatic cord in males. Alongside these structures is the inguinal nerve and the blood and lymphatic vessels. The inguinal canal has an opening at the superficial (external) and deep (internal) inguinal ring (1).

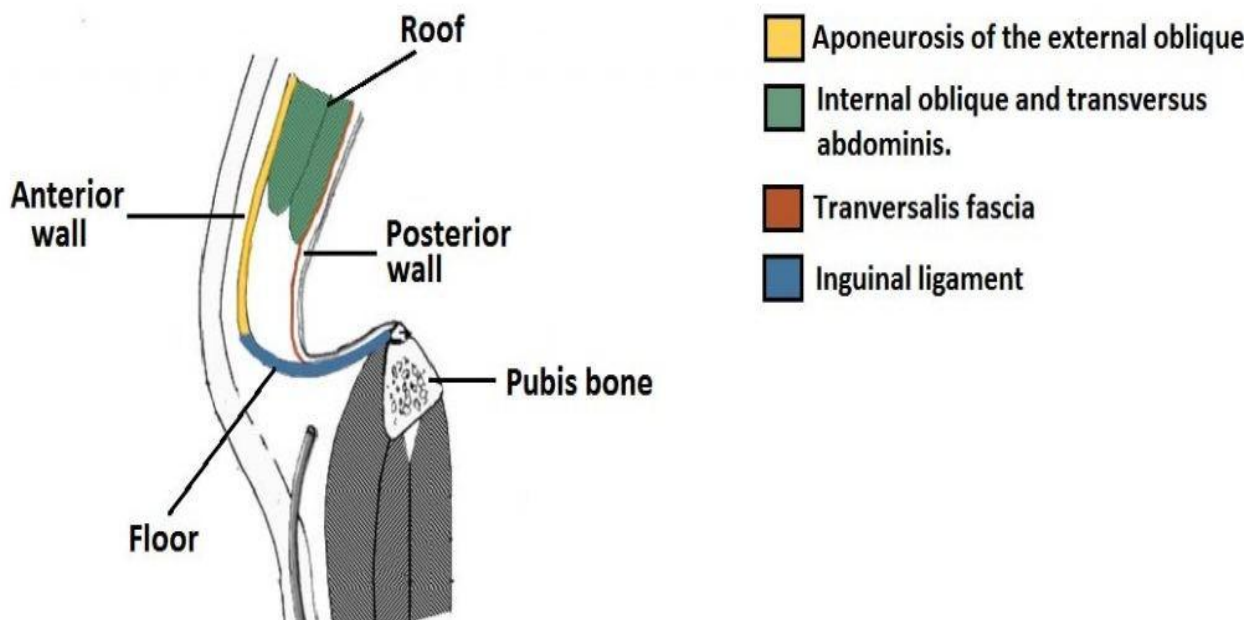


Figure 2. Anatomical walls of the inguinal canal.

Source: <https://teachmeanatomy.info/abdomen/areas/inguinal-canal/>

The core components of the inguinal canal are the anterior and posterior walls, the roof and the floor of the canal. The anterior wall is formed by the aponeurosis of the external oblique muscle throughout the entire canal and the internal oblique muscle supports the lateral part. The posterior wall, surrounded by the transversalis fascia, is medially supported by the internal oblique and aponeuroses of transversus abdominis. The roof is formed centrally by the transversus abdominis and internal oblique, laterally by the transversalis fascia and medially by the aponeurosis of the external oblique. The floor is shaped centrally by the infolded inguinal ligament, medially by the lacunar ligament and laterally by the iliopubic

tract (*Figure 2*). Furthermore, the posterior wall is also the place where the inguinal (Hesselbach's) triangle is positioned. This location is of key clinical significance because it is the weakest point of the abdominal wall and the place of which both inguinal and femoral hernias arise (*Figure 3*) (1).

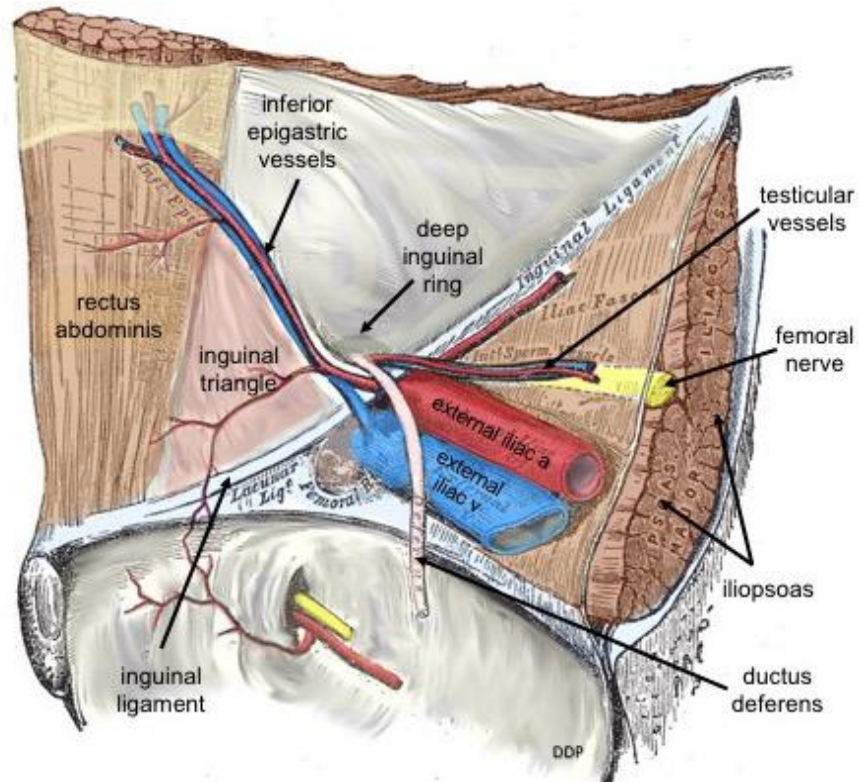


Figure 3. Inguinal (Hesselbach's) triangle.

Source: <https://upload.wikimedia.org/wikipedia/commons/d/d4/>

1.2. INGUINAL HERNIA

1.2.1. Anatomy of the inguinal hernia

A hernia is described simply as a protrusion of preperitoneal contents through the myofascial wall. It pushes on the parietal peritoneum forming the hernial sac. Most groin hernias in males pass superior to the iliopubic tract (inguinal hernias), whereas in females most pass inferiorly (femoral hernias) (2).

1.2.2. Types of inguinal hernia

Inguinal hernias are classified into either direct or indirect hernias based on their anatomical location.

1.2.2.1. Indirect inguinal hernia

Indirect inguinal hernia is formed during embryological development typically because of patency of the processus vaginalis. Approximately two-thirds of all inguinal hernias are of the indirect type and the majority of those patients are male. In the early stage of embryological development, the kidney ascends into its normal position and the testes descend from retroperitoneum to the level of the internal inguinal rings. In the later stages of gestation typically between weeks 28 and 36, the testes descend into the scrotum through the inguinal canal (3). The descent happens inside the processus vaginalis, along with gubernaculum in the direction of the internal ring. In normal embryological development, between weeks 36 and 40 the processus vaginalis closes. In 60% of the children, processus vaginalis closes within the first 2 years of life. If closure does not happen, processus vaginalis creates partway between peritoneal cavity and the scrotum, which allows abdominal contents to descend. In females, the canal of Nuck undergoes closure, which similarly to the processus vaginalis allows inguinal hernias in females to occur (2).

1.2.2.2. Direct inguinal hernia

The location of direct inguinal hernias are through a weakened area in the transversalis fascia known as Hesselbach's triangle, an area defined by the edge of the rectus abdominis muscle, the inferior epigastric artery and the inguinal ligament. Hesselbach's ligament extends from the lower border of the transversus muscle to the pectineal fascia (4). Direct inguinal hernias are a funicular type of hernia, which are more prone to incarcerate due to the borders. Direct inguinal hernias may exit through the external inguinal ring however they are unable to extend into the scrotum. Direct is more prevalent amongst the elderly due to weakening of the abdominal wall with age. Additionally, risk factors such as obesity, constipation, and a positive history of inguinal hernias increases the risk of developing an inguinal hernia (5).

1.2.3. Incidence

The incidence of inguinal hernias is bimodal, meaning it has two peaks, at approximately age 5 and after the age of 70 and it accounts for 75% of all abdominal wall hernias (6). As mentioned previously, approximately two-thirds of these hernias are indirect, meaning it is the most common groin hernia in both males and females. Males are far more likely to develop an inguinal hernia. Male-to-female ratio accounts for approximately 90:10 in all inguinal hernias, which affect nearly 25% of men and less than 2% of women over their lifetime (6). The incidence of indirect hernias present more often on the right. This is likely due to the slower closure of a patent processus vaginalis on the right side compared to the left (6). In the pediatric population, the ages range from premature to 18 years with a mean age of 3.5 years and a male-to-female ratio of 3:1 (7). An incidence of inguinal hernias by location in a recent study on 6826 patients has been shown as 59.5% right, 33.7% left, and 6.8% bilateral hernias, which have almost all presented as being indirect (7). In children, the peak incidence of inguinal hernia was at 0 years of age for males and 5 years of age for females. The ratio of unilateral vs. bilateral repair is 5.54:1 presented with common risk factors such as obesity, cough and constipation with straining during stools (8).

1.2.4. Clinical findings

The main diagnostic finding is a reducible lump in the inguinal region. It can be a unilateral or bilateral enlargement of the scrotum in inguinal hernias. The lump in the groin can be reduced if minimal pressure is applied or if the patient is in a supine position. In general, inguinal hernias cause moderate discomfort that usually increases with activity. Direct hernias are typically present with fewer symptoms and have a lower risk of becoming incarcerated in comparison to indirect hernias. In incarcerated hernias, swelling is hard, swollen, and painful (*Figure 4*). In general, one-third of patients have no pain, and severe pain is uncommon (1.5% at rest and 10.2% on movement) (9). Inguinal hernias are not usually painful unless incarceration or strangulation has occurred (9). These symptoms can occur during activity and disappear when patients are in a supine position. In infants, an inguinal hernia is suspected when unreasonable crying is present for a longer period of time. When the piece of bowel inside the hernial sac becomes incarcerated or strangulated it can result in intestinal obstruction and gradual erythema of the testis (4).

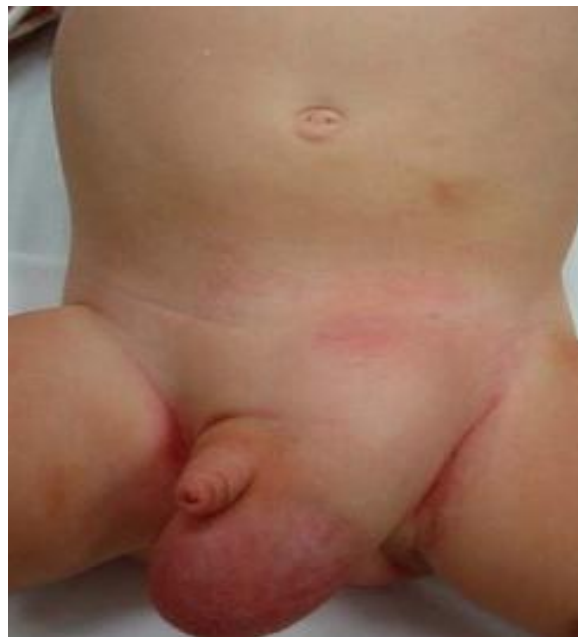

Figure 4. Incarcerated left inguinal hernia in a 2-year-old patient.

Source: Archive of Department of Pediatric Surgery, University Hospital of Split.

1.2.5. Complications

There are several complications associated with inguinal hernias. These are either as a result of untreated inguinal hernias or due to complications associated with surgical intervention. The main complications associated with untreated hernias are incarceration and strangulation (*Figure 5*). Strangulated hernia is often followed by a toxic appearance and pain out of proportion. Incarcerated or irreducible hernia in which content cannot return to the abdomen. In most cases, it is due to entrapment by a narrow neck. This can lead to compression of the spermatic vessels by an incarcerated hernia and cause haemorrhagic infarction of the ipsilateral testicle (10). An incarcerated inguinal hernia can result in testicular ischemia and if hypoperfused for too long can result in testicular necrosis (11). A complication of surgical intervention for an inguinal hernia can be possible damage of nearby nerves or even the vas deferens. Nerve damage followed by chronic pain can be a reason for sexual dysfunction. Passage of sperm will be obstruction by vas deferens damage. Disturbances of testicular circulation can also be affected. It can result in atrophy of the testicles and stop testosterone hormone production (12). In summary some other complications are sexual dysfunction, testicular hormone function, ischemic orchitis, scrotal edema, hematoma, wound infection, and recurrence of hernia.

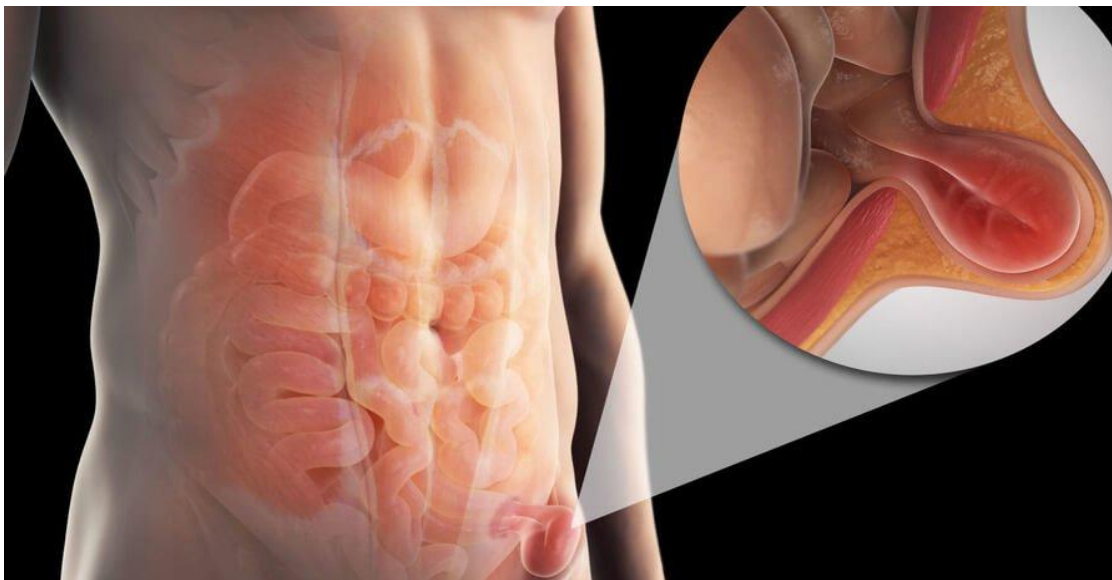


Figure 5. Strangulated and incarcerated inguinal hernia.

Source: <https://www.krenizdravo.rtl.hr>

1.2.6. Specific types of inguinal hernia

The definition of *Richter's hernia* will be herniation of the circumference of the bowel which includes only a portion of a wall through the fascial defect. Richter hernias develop in small fascial defects in the anti-mesenteric portion of the bowel. Many cases show that the segment of the terminal ileum is involved (13).

Littre's hernia is the protrusion of a Meckel diverticulum through the abdominal wall. Littre's hernia begins with the failure of the vitelline sac to close which will lead to Meckel diverticulum formation. This type of hernia present with symptoms such as dyspepsia, abdominal cramps, pain, and. anorexia with malaise (13).

Amyand's hernia is an incarcerated inguinal hernia together with acute appendicitis. Amyand's hernia occurs when the appendix is present in the incarcerated hernial sac. This can lead to further complications such as strangulation and perforation. Symptoms similar to appendicitis may occur (13).

1.2.7. Diagnostic approach

In diagnostics, differentiation has to be done between bilateral and unilateral inguinal hernia in men and women, scrotal and recurrent inguinal hernias, incarcerated, and femoral hernias. During the physical examination, it is hard to differentiate between direct and indirect hernia and most groin hernias should be treated surgically regardless of a type (14).

An anamnesis and a physical examination is the gold standard for the diagnosis of inguinal hernia in children. Recurrence of inguinal hernia in anamnesis is very important information in diagnostics. Physical exam is very useful especially if the patient has a history of an inguinal or a scrotal lump. Examination involves feeling the lump while the patient coughs. The child should be examined in the upright position if the hernia is not shown in the supine position (15). The inguinal region is examined in an infant by holding them in a vertical position. Children are examined while standing. The physician observes and palpates the inguinal region, searching for asymmetry and lump. It is easier to identify hernia if the patient coughs or cries. The physician invaginates the scrotum by palpating the external inguinal ring with a finger to detect hernia. If the lump attends to move laterally or medially in the inguinal canal an indirect hernia can be suspected. If the lump progresses through the inguinal floor from the deep to the superficial, a direct hernia can be suspected (*Figure 6*) (4). Digital imaging diagnosis would be used for difficult cases to demonstrate inguinal hernias.

Ultrasound has been used to identify structures within the hernia. An ultrasound can determine hernial content (the bowel, the omentum, etc), the hernia sac, and the defect. Ultrasonography can be especially helpful with complications such as hydrocele and guidance during surgery (16).

Ultrasound can be also helpful with the examination of superficial swellings and inguinal masses. Sometimes the patient presents with a bulging, firm, and a palpable mass in the groin. If this is the case of an ovarian hernia, reduction of hernia may lead to torsion, necrosis and organ loss. By utilizing ultrasound, the emergency physician has an accurate, fast, and earlier diagnosis of the herniated structures. Today, radiology-performed ultrasound and point-of-care ultrasound for the diagnosis of congenital inguinal hernias containing ovaries, uterus, and fallopian tubes is widely used (*Figure 7*) (17).

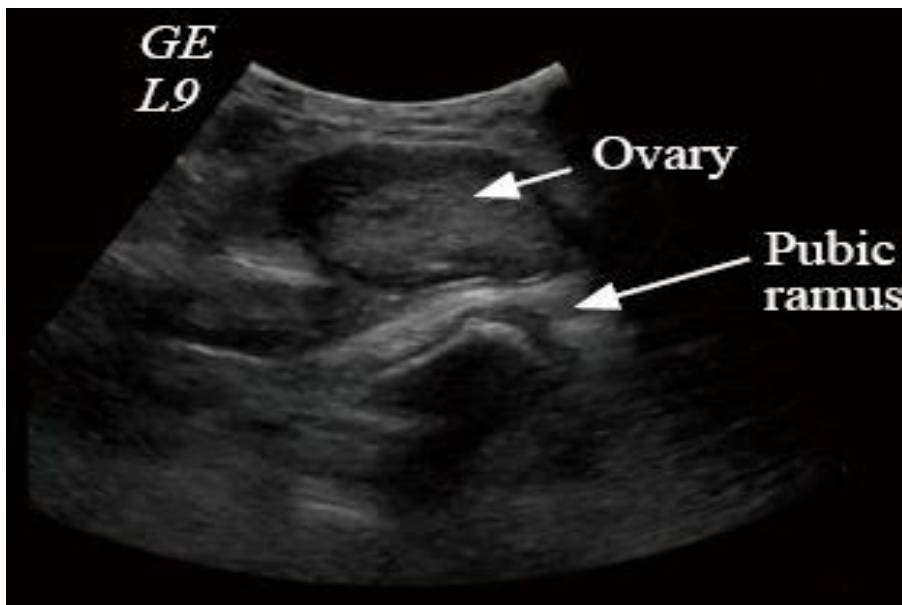


Figure 6. Left inguinal region in sagittal plane.

Source: <https://www.ncbi.nlm.nih.gov/pmc/articles/PMC6117543/figure/F2/>

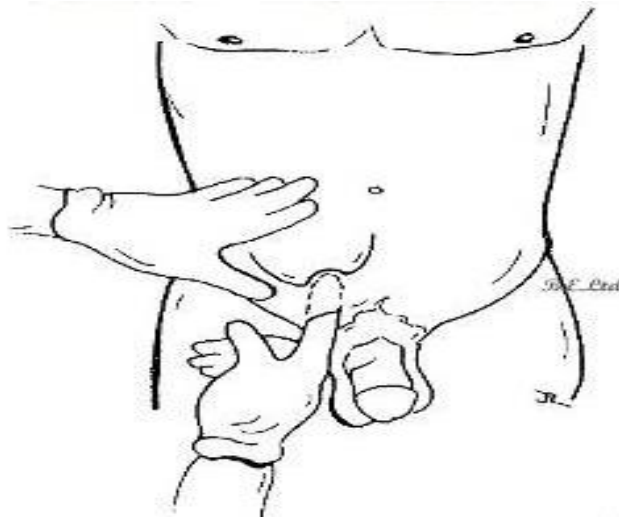


Figure 7. Palpating the external ring of the inguinal canal.

Source: <http://www.clinicalexams.co.uk/examination-techniques-for-hernia/>

1.2.8. Treatment

Surgical treatment is not necessary for asymptomatic inguinal hernias in a male patient, however, in female patients all inguinal hernias require surgical intervention independent of whether they are symptomatic or not. Especially in women and in all bilateral hernias, a laparoscopy is preferable to an open procedure. Patients treated with a mesh-based repair using laparoscopy/endoscopy are less likely to develop chronic pain than those with open surgery (18). Pain is very common in patients with strangulated hernia. Although strangulated inguinal hernia have a low incidence in the younger population it is a frequent cause of acute abdomen in elderly patients. Emergency surgery is the indicated treatment for strangulated inguinal hernia which may present as acute abdomen (10). Surgery is indicated for the common malformation of congenital inguinal hernia in children. With surgical treatment the probability of complications like incarceration or obstruction is decreased. If there is a case of incarceration, nonoperative reduction is indicated. The patient is placed supine with the hips elevated in which after a short period of time the hernia is expected to reduce in size due to gravity. If this fails, manual repositioning is recommended. The Patient will be shortly sedated and the surgeon will push the hernial content towards the external inguinal ring and the other hand will push the inguinal canal downwards (4).

1.2.9. Surgical techniques

The key aim of surgical intervention for inguinal hernias is to repair the weakness in the abdominal wall and reduce the contents that to slip into inguinal canal in the groin region. Presently, laparoscopic or open repair are the mainstay options for inguinal hernia treatment which is typically followed by closure with permanent sutures.

1.2.9.1. Open surgery

Inguinal hernia surgery is a very common procedure in general surgery. High ligation of a patent processus vaginalis and excision of the hernia sac is the standard of surgical care in children. The hernial sac must be separated from structures such as the vas deferens, ilioinguinal nerve, and the gonadal vessels (2). The hernial sac needs to be split, clamped and the contents reduced. With that being done, ligation of the patent processus vaginalis comes next with 3-0 or 4-0 braided absorbable sutures. The procedure is finalized when inguinal tissue is sutured (19). In many centers, a modified Marcy repair, which includes high ligation and excision of the hernia sac, with narrowing of the internal inguinal ring, is very popular for pediatric inguinal hernia repair, because it is associated with the lowest recurrence rates (*Figure 8*) (7). Another surgical technique is called the Ferguson repair, described in 1899. The main features of the Ferguson herniorrhaphy include leaving the cord undisturbed, using the cremaster muscle and the transversalis fascia during the repair, and suturing the internal oblique muscle and the tendon over the spermatic cord to Poupart's ligament (20). The overall reported recurrence rate for Marcy repair was only 0.36 % (7). Open herniotomies include an increased risk of hematomas, blood loss, infections, damaging the vas deferens, and testicular atrophy (21). Although the standard of care for adult inguinal hernia is tension-free repair using mesh, use of a mesh is never required in the pediatric population (22).

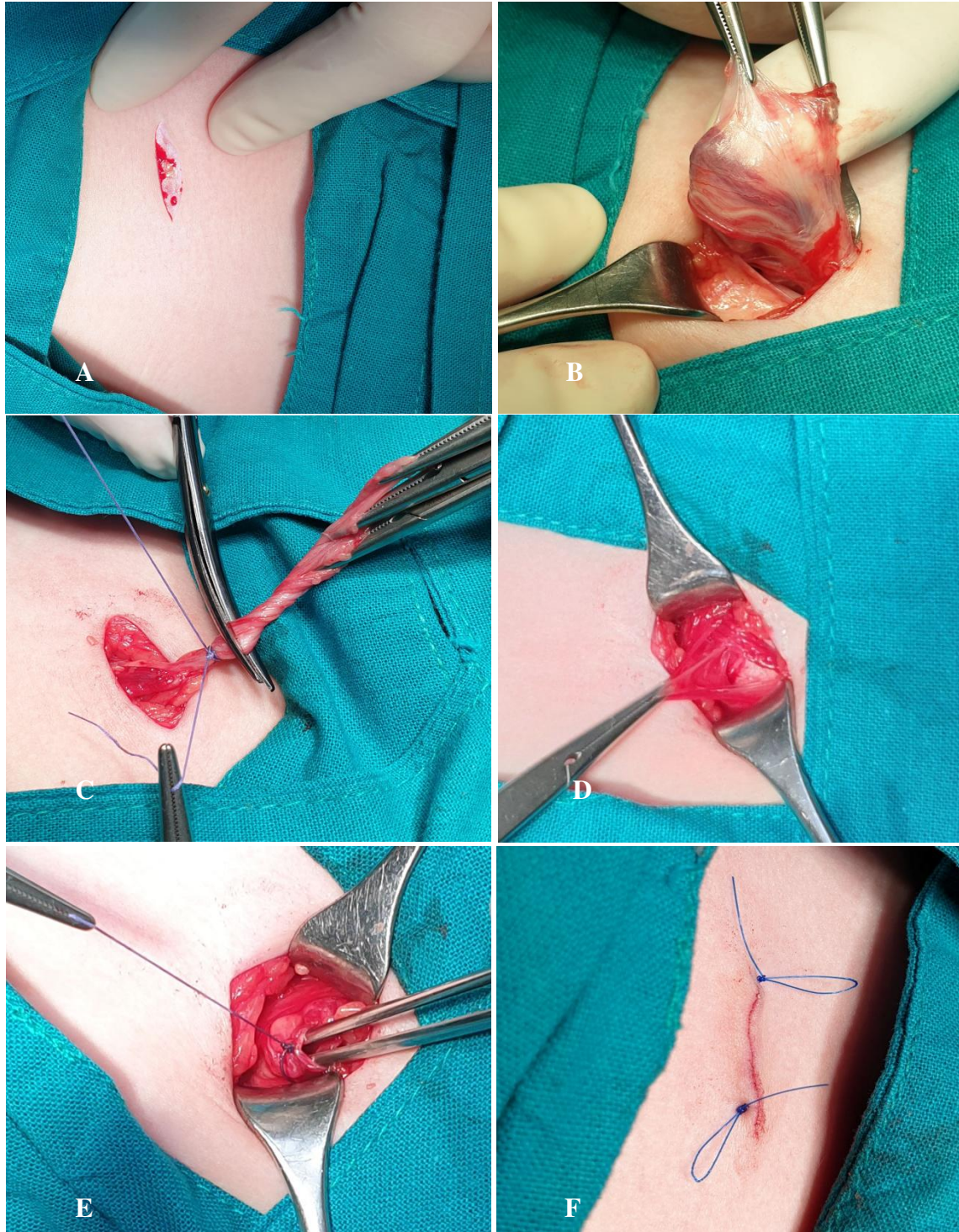


Figure 8. Open surgery (Modified Marcy repair) in 4-year-old patient: **A** – Skin incision; **B** – Hernial sac and cord structures are exposed; **C** – High ligation of the sac; **D** – Open internal ring; **E** – Narrowing of the internal ring; **F** – Closed skin incision. Source: Archive of Department of Pediatric Surgery, University Hospital of Split.

1.2.9.2. Laparoscopic surgery

Open herniectomy has been the gold standard for many years in the treatment of pediatric hernia with excellent results, but it carries the risk of complications of the seminal vesicle and vas deferens, risk of hematoma formation and wound infection, iatrogenic cryptorchidism, testicular atrophy and recurrence (23, 24). In recent years, in most European centers, the minimally invasive approach has largely replaced the open approach that was the gold standard for the treatment of inguinal hernia in children (25-28). Laparoscopic surgery is presented as a new method of surgery with significant advantages. These benefits include better visualization of the peritoneal cavity, the ability to operate on a contralateral hernia, lower complication rates and shortened procedure times, especially in bilateral hernias. The main advantages would be better differentiation of contralateral hernia and excellent cosmetic results with almost no visible scars. Today, laparoscopic treatment of inguinal hernia in children can be performed intraperitoneally or percutaneously (29). In laparoscopic procedures, there is no classic incision in the inguinal region. In the intraperitoneal approach, after reaching the pneumoperitoneum using a Veress needle, three trocars are introduced through the abdominal wall and intraperitoneal suturing of the internal inguinal ring is performed using laparoscopic instruments. In the percutaneous approach the procedure can be performed with only one mini-incision and a needle (30). Dr. Patkowski was the first to introduce percutaneous suturing of the internal inguinal ring for the treatment of pediatric inguinal hernia (PIRS). PIRS is a surgical technique that administers the placement of a laparoscope through the umbilicus and a percutaneously closed internal inguinal ring (31). The technique has gradually become very popular among pediatric surgeons. The complication rate in the hands of a skilled surgeon is very low. At the very beginning, the recurrence rate was 4.5%, but new studies and meta-analyses reported recurrence rates of 0.5 - 0.7%, which reveal almost identical recurrence rates in open surgery (31-33). Also, in the hands of an experienced surgeon, the operative time is shorter compared to open surgery and is about 10 minutes for unilateral hernia and about 15 minutes for bilateral hernia (34). The average operative time in open surgery is 25 to 30 minutes (7).

In girls, the procedure is significantly easier, as in boys should be extremely careful to avoid injuries to the vas deferens, as well as spermatic blood vessels. For beginners, it is recommended to start procedure in girls, and after achieving experience with the method PIRS may be safely performed in boys. Also, smaller children up to two years of age are not suitable for a beginner, due to the extensibility of the peritoneum and difficult manipulation

due to the small space. The learning curve is about 30 surgeries per surgeon. Epigastric blood vessel injuries, hydrocele formation, recurrence, or granuloma formation are most commonly reported complications in the literature (31). In the percutaneous approach, only one incision is used to insert the laparoscope, and after reaching the pneumoperitoneum and visualizing the hernia, it is closed percutaneously by inserting a suture with a spinal needle. This reduces the operative stress on the body, the pain after the procedure is minimal and children usually return to daily activities the next day (31, 34). The advantage of the PIRS is the possibility of simultaneous repair of bilateral hernias (without the need for additional incisions and other surgery), better visualization of the peritoneal cavity, the ability to detect other abdominal abnormalities and contralateral repair of the inguinal hernia, (potential) hidden hernia (*Figure 9*) (31, 33, 34). Also, the rate of testicular atrophy or iatrogenic retention is significantly lower compared to open surgery, it almost does not exist (33). Other benefits relate to the general benefits of minimally invasive surgery, such as decreased pain, faster recovery, less analgesic consumption, faster return to vital functions, and significantly better cosmetic effects (33, 34). This method has been shown not to affect testicular perfusion, which was initially one of the main issues. The conclusions of studies conducted in which testicular blood flow was measured in children in whom percutaneous closure of the internal opening of the inguinal canal was performed do not affect testicular perfusion in boys (30). Also, it has been proven that this method causes significantly less surgical stress, and thus a significantly lower level of postoperative pain compared to the open method of treatment of inguinal hernia in children (34).

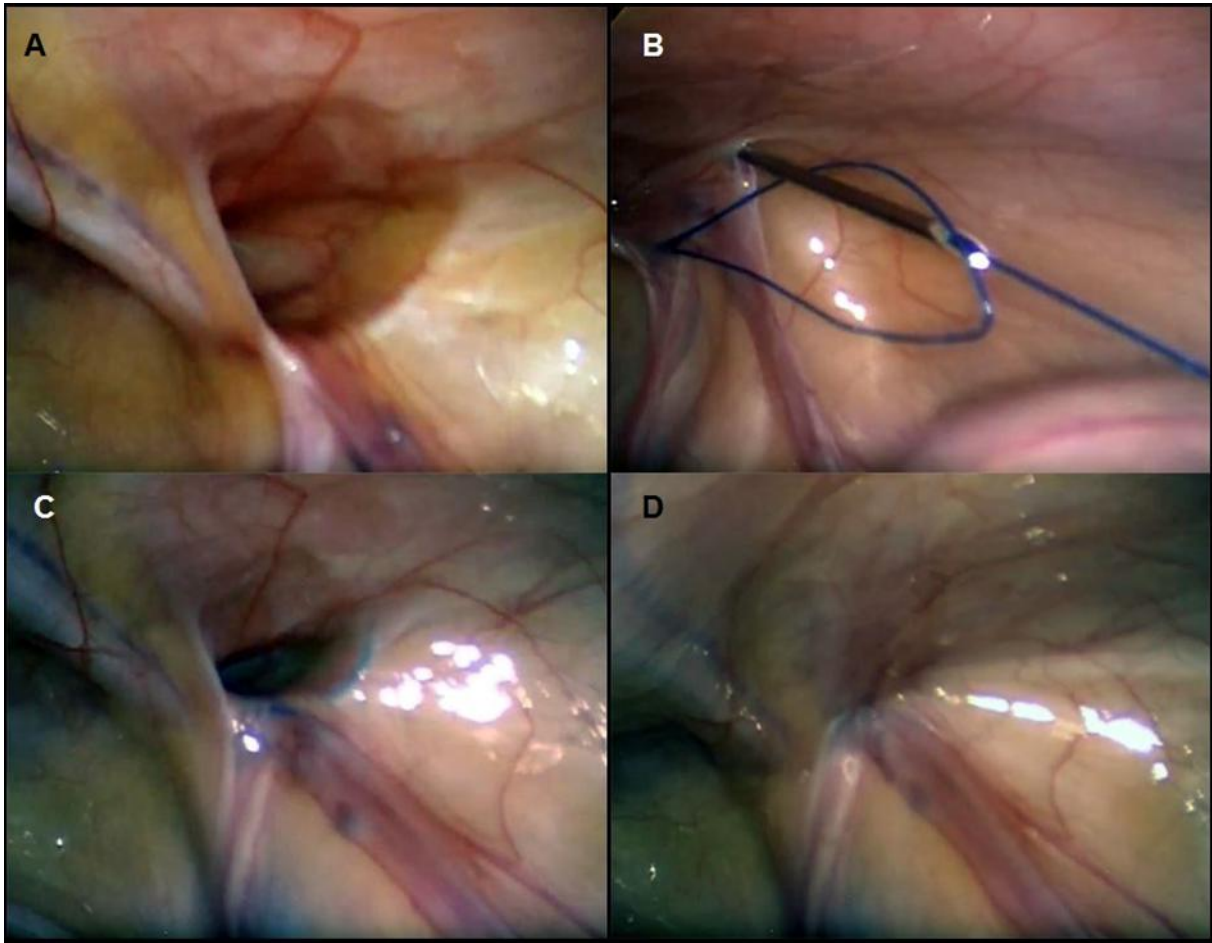


Figure 9. PIRS technique in 3-year-old male patient with a right inguinal hernia: **A** – Open internal inguinal ring; **B** – Through the previously introduced loop suture is pushed through the needle; **C** – After removal of the needle, the loop was drawn out and the knot passed around internal ring; **D** – Closed internal ring. Source: Archive of Department of Pediatric Surgery, University Hospital of Split.

2. OBJECTIVES OF RESEARCH

Surgical repair of inguinal hernia is one of the most common surgical procedures in pediatric patients. All inguinal hernias need to be treated surgically due to the risk of serious complications. At present, laparoscopic repair is presented as a new method of surgery with significant advantages over open surgical repair.

This study aimed to evaluate the safety, efficiency, and postoperative outcomes of children undergoing PIRS for an inguinal hernia within a 5-year period.

Hypotheses:

- 1) PIRS is a simple, safe, and effective technique for inguinal hernia repair in children with excellent outcomes and cosmetic results.
- 2) The incidence of complications and recurrence rates using PIRS technique for inguinal hernia repair in children are very low.

3. PATIENTS AND METHODS

3.1. Patients

All patients who underwent PIRS for an inguinal hernia at the Department of Pediatric Surgery of the University Hospital of Split in the period from October 2015 to April 2020.

Inclusion criteria:

1. Patients of both genders, up to 17 years of age, with an inguinal hernia treated by the PIRS
2. Patients operated in University Hospital of Split by a specialist in pediatric surgery
3. Patients followed-up at least 3 months after surgical procedure

Exclusion criteria:

1. Patients older than 17 years of age
2. Patients with contradiction to laparoscopy
3. Patients who required conversion to an open procedure
4. Patients with follow-up less than 3 months
5. Patients with incomplete data

3.2. Organization of the study

The study was carried out as a prospective cohort study using corresponding quantitative research and descriptively processed data.

3.3. Place of the study

The research took place at the Department of Pediatric Surgery, University Hospital of Split, Croatia.

3.4. Methods of data collection and processing

Demographic and clinical data, intraoperative findings, and outpatient follow-up results were recorded in the Study protocol. The corresponding data was obtained by revising the study protocols and medical records. The data were analyzed using the Microsoft Excel for Windows Version 11.0 (Microsoft Corporation) and SPSS 24.0 (IBM Corp, Armonk, NY) software programs. Distributions of quantitative data were described by medians and ranges, whereas absolute rates and percentages were used to describe categorical data.

3.5. Description of research

The patients were admitted to the hospital on the day of surgery. Medical history and demographic data were recorded in the Study protocol. In the proposed study, the safety, efficacy, and treatment outcomes in children who underwent inguinal hernia repair using PIRS technique, over a five-year period has been evaluated. A postoperative follow-up included duration of hospital stay, pain level, and postoperative complications. All patients were discharged from the hospital the day after surgery. The patients were followed-up at our outpatient clinic in the first- and fourth-week following surgery for any possible complications. A follow-up program also consisted of a physical examination 6 months post-surgery to identify any possible late-onset complications or recurrence of a hernia.

3.5.1. Primary outcome measures

The primary outcome measures included outcomes of treatment, intraoperative and postoperative complications, number of recurrences, conversions to an open procedure, and rate of reoperations.

3.5.2. Secondary outcome measures

The secondary outcome measures include duration of surgery and anesthesia, level of pneumoperitoneum and length of hospital stay.

3.6. Compliance with ethical standards

All procedures performed in studies involving human participants were in accordance with the ethical standards of the institution and/or national research committee and with the 1964 Helsinki declaration and its later amendments or comparable ethical standards. Authors declared that the research was conducted according to the principles of the World Medical Association Declaration of Helsinki “Ethical Principles for Medical Research Involving Human Subjects”. Patients were informed in detail and informed consent was obtained from the parents or legal guardians of the patients to use the data. The study protocol was approved by the Ethics Review Board of University Hospital of Split with reference No. 2181-147-01/06/M.S.-20-9.

3.7. Surgery

Surgery starts with 3-mm supraumbilical incision, a Veress needle is used to reach pneumoperitoneum of 6–12 mmHg, depending on the patients' weight and age. A 3-mm port is inserted through a supraumbilical incision. Visualization of open internal inguinal ring is achieved with a 3-mm laparoscope on side of hernia (*Figure 10 A*). A small skin incision of 2 mm is performed in a preferable position above the internal ring. A 20G spinal needle (ELDOR CSEN 38.4; Quincke Spinal Needle, Z.R.M.I. Co. Ltd. Jerusalem, Israel) is used together with a nonabsorbable monofilament nylon loop (Prolene™ 3-0, polypropylene, Ethicon®, Cincinnati, Ohio, USA) at one side of the internal ring, preventing multiple entrances to peritoneal cavity or damaging spermatic cord and blood vessels and to take as much of the edge of the entered side of the internal ring (*Figure 10 B*). The loop is positioned in the peritoneal cavity while the spinal needle is taken out carefully not to pull the loop out. The same procedure with the same needle was done on the other side of the internal ring (*Figure 10 C*). The needle is then passed through the previously positioned loop and the same suture is passed through the needle (*Figure 10 D*). After the needle has been removed and the loop is withdrawn, holding the second suture, passing it out through the skin incision, tying it, and thus obliterating the internal ring (*Figure 10 E*). Successful hernia repair is done if occlusion of the hernia is visualized with a camera (*Figure 10 F*). A round gauze ball is placed on the umbilical wound with sterile drape above it and a small inguinal wound is closed using braided adhesive sterile strips or sutured.

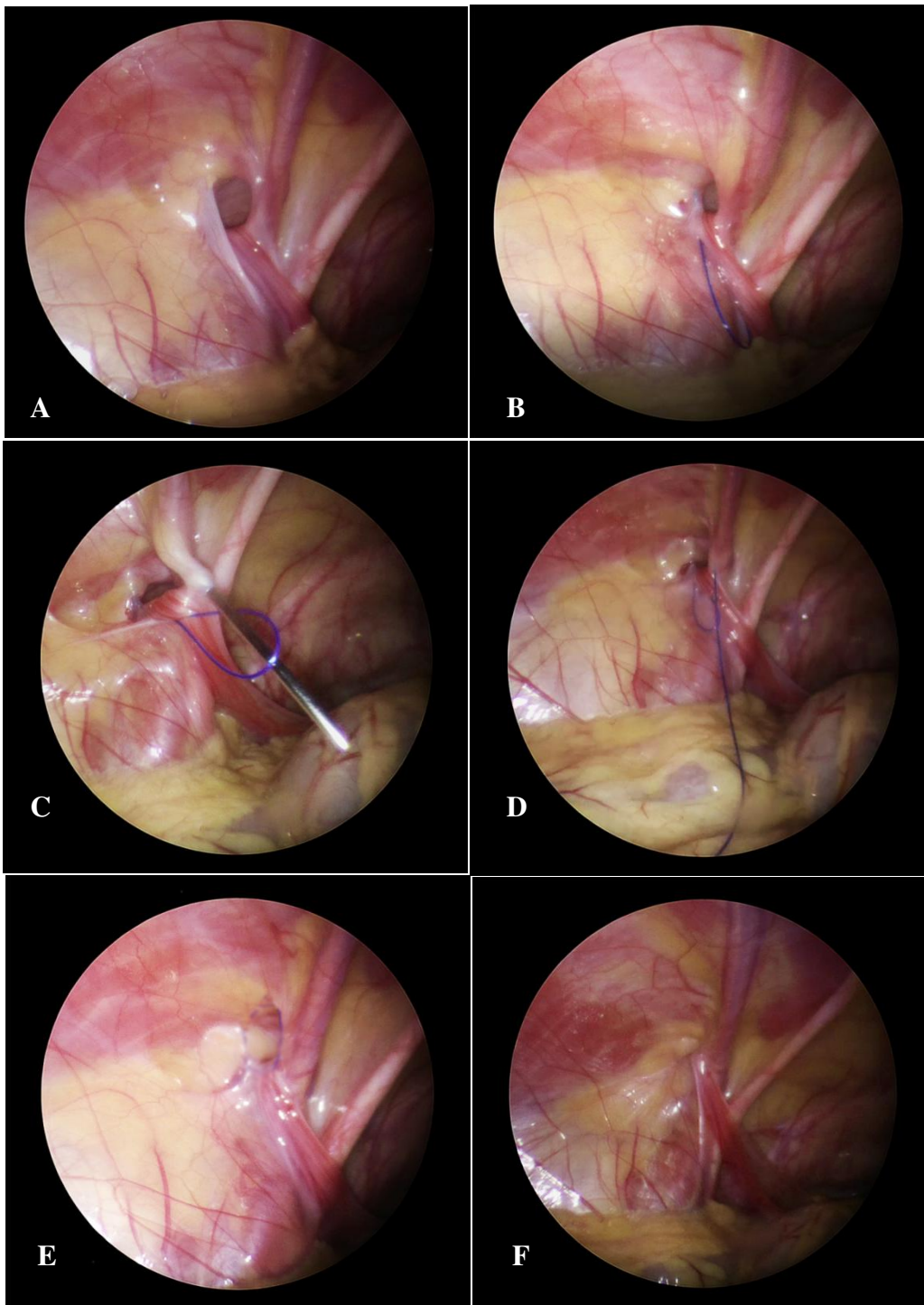


Figure 10. PIRS technique: **A** – Open internal inguinal ring; **B** – Introduction of a nylon loop; **C**– Introduction of the needle on the other side of the internal ring; **D** – Needle and suture passed through the previously introduced loop; **E** – The loop drawn out and the knot passed around internal ring; **F** – Closed internal ring. Source: Archive of Department of Pediatric Surgery.

4. RESULTS

During the 5-year study period, 228 PIRS procedures for the treatment of inguinal hernia were performed on a collective total of 188 children, including 126 (67%) boys and 66 (33%) girls. The median age of the patients was 4 years (IQR 2, 6). The distribution of hernia repairs according to the age of the patients at the time of surgery has been shown in *Figure 11*. Most of the children were 3 years old at the time of surgery (n=34; 18.1%). Most of the children (n=152; 80.8%) were operated on at preschool age, with the lowest number of repairs performed in preteen ages (n=18; 9.6%) and adolescents (n=18; 9.6%).

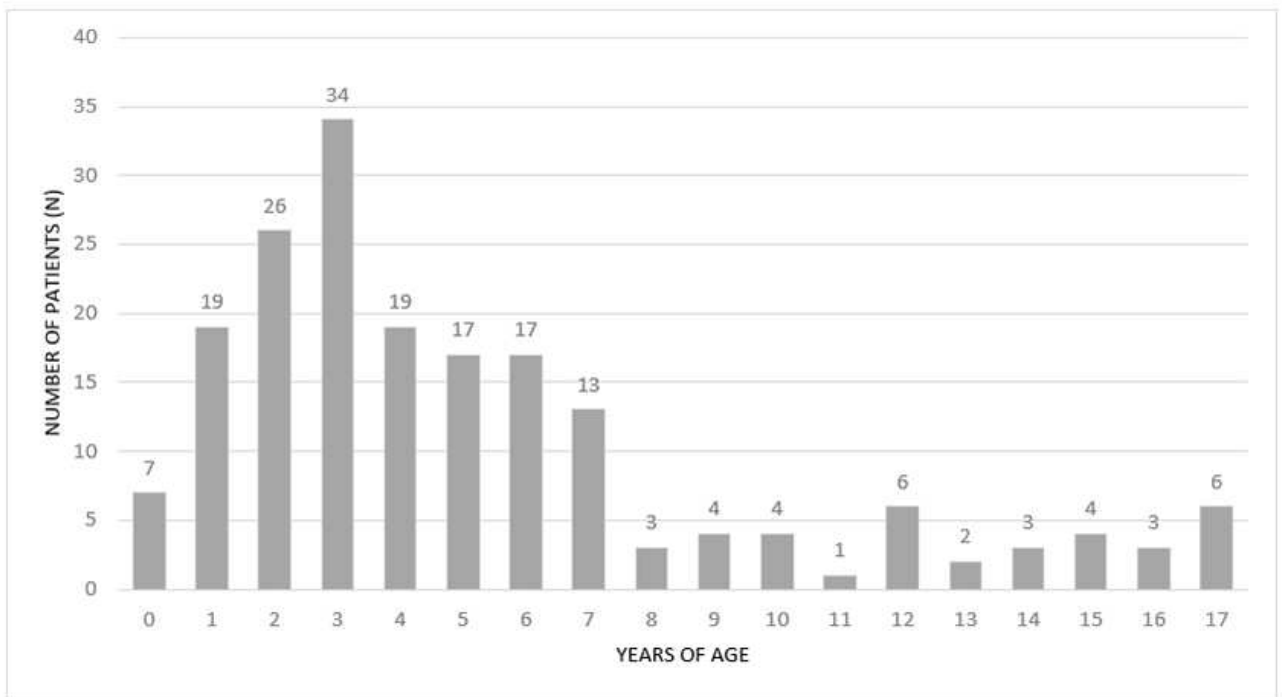


Figure 11. Distribution of hernia repairs according to the age of the patients at the time of surgery.

Table 1 summarizes demographic patient data. There were 99 (52.7%) right hernia repairs, 49 (26.1%) left hernia repairs, and 40 (21.2%) bilateral hernia repairs. All PIRS procedures were completed successfully; there were no conversions to open surgery. All hernia repairs included in this study were elective. Among them, 39 (20.7%) cases were assisted by grasping forceps.

Table 1. Demographic data of the patients

Characteristic	Value
Age (years); Median (IQR)	4 (2, 6)
Gender; n (%)	
Male	126 (67)
Female	62 (33)
Weight (cm); Median (IQR)	109 (95, 128)
Height (kg); Median (IQR)	18 (14, 25)
BMI (kg/m ²); median (IQR)	15.7 (14.5, 17.6)
ASA classification; n (%)	
I	175 (93)
II	13 (7)
Lateralization; n (%)	
Righ	99 (52.7)
Left	49 (26.1)
Bilateral	40 (21.2)

IQR – Interquartile range; *BMI* – Body mass index; *ASA* – American Society of Anaesthesiologists

The median of operative time for unilateral and bilateral inguinal hernias was 10 min (IQR 8, 12) and 16 min (IQR 14, 20), respectively (*Figure 12*). The median anesthesia time was 25 min (IQR 20, 30) for unilateral and 30 min (IQR 25, 35) for bilateral repair. The median postoperative hospital stay was 24 h (IQR 8, 24) and median follow-up was 46 (IQR 35, 51) months. Median level of pneumoperitoneum was 8 mmHg (IQR 7, 8).

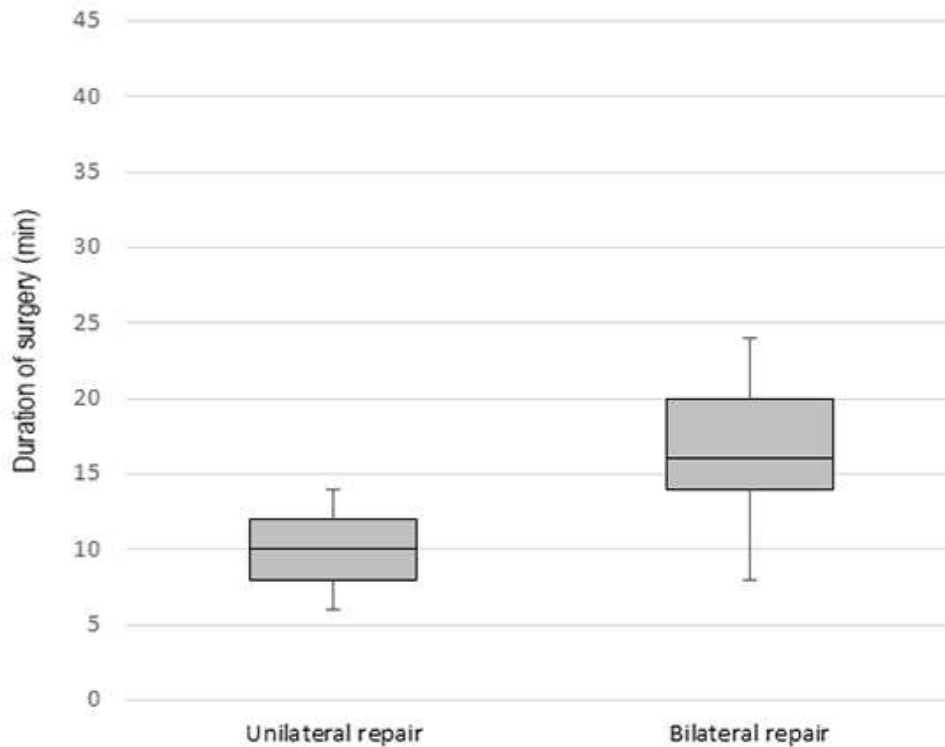


Figure 12. Comparison of operative time for unilateral and bilateral inguinal hernia repair.

Table 2 summarizes treatment outcomes of the patients. During the study period there were three (1.3%) intraoperative complications and three (1.3%) postoperative complications. Regarding intraoperative complications only three (1.3%) inferior epigastric veins injuries were recorded. All of the injuries were treated conservatively without any consequences. During the follow-up period in three male children hydrocele was recorded, in two cases hydrocele resolved spontaneously and one (0.4%) required surgical treatment. In two (0.8%) patients swelling of the tissues around the upper pole of the groin was recorded, which finally resolved up to 6 months after surgery. No cases of suture granuloma, groin traction pain discomfort, deferent duct injury, umbilical hernia, iatrogenic cryptorchidism, testicular atrophy or hernia recurrence were recorded.

Table 2. Treatment outcomes of the patients

Characteristic	Value
Duration of surgery (min); median (IQR)	
Unilateral repair	10 (8, 12)
Bilateral repair	16 (14, 20)
Duration of anesthesia (min); median (IQR)	
Unilateral repair	25 (20, 30)
Bilateral repair	30 (25, 35)
Pneumoperitoneum (mmHg); median (IQR)	8 (7, 8)
Additional trocar introduction; n (%)	39 (20.7)
Hospital stay (h); median (IQR)	24 (8, 24)
Intraoperative complications; n (%)	
Inferior epigastric vein injury	3 (1.3)
Postoperative complications; n (%)	
Hydrocele	3 (1.3)
Swelling in the groin	2 (0.9)
Recurrences	0 (0)
Reoperations; n (%) - hydrocele	1 (0.4)

IQR – Interquartile range

Complication rates (blood vessels injury, hydrocele and swelling in the groin) showed a significant decrease after first 60 patients (*Figure 13*). Operative time achieved plateau after 60–75 patients (*Figure 14*).

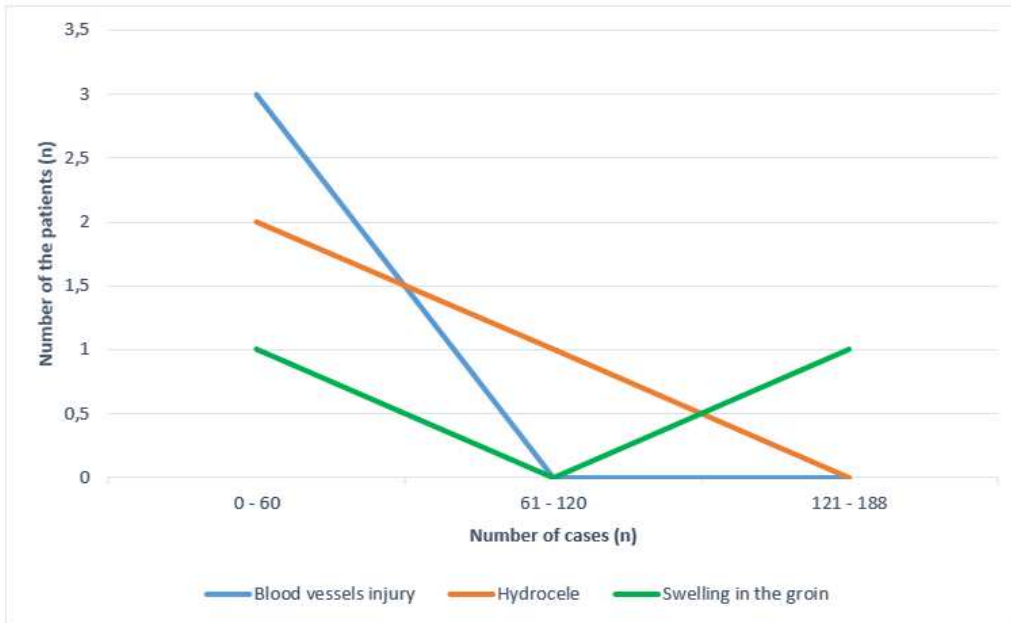


Figure 13. Learning curve: Cumulative complication rates, showing a significant decrease over time.

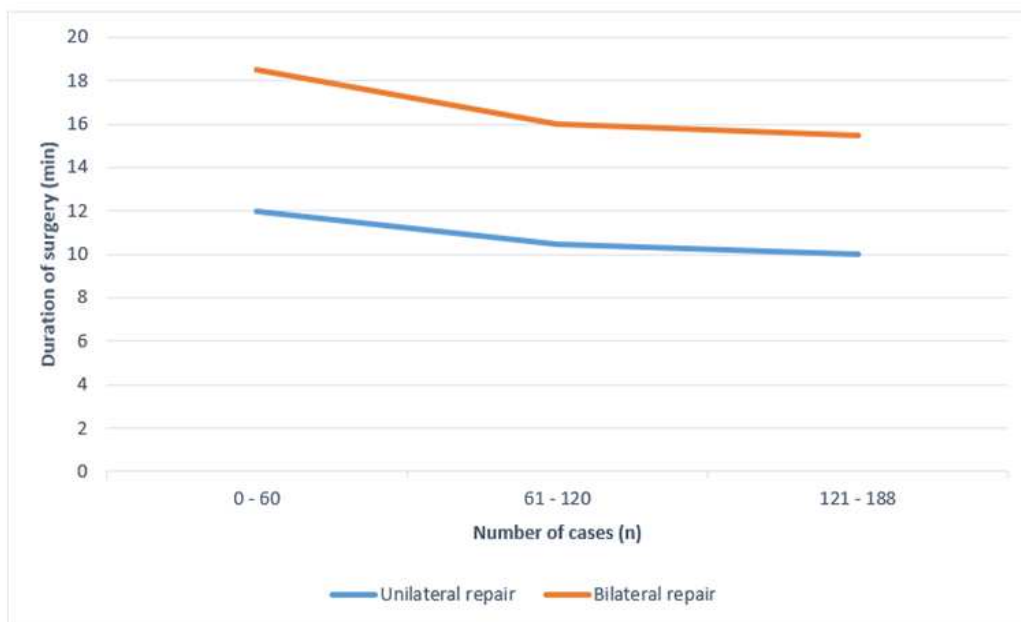


Figure 14. Learning curve: Cumulative operative time, showing a decrease over time, with a plateau after 60 patients.

5. DISCUSSION

In the present study, outcomes of PIRS for the treatment of inguinal hernia in pediatric patients was evaluated. This study provides clear evidence that PIRS for the treatment of inguinal hernia in pediatric patients is associated with excellent outcome, fast recovery, and low incidence of complications and recurrences.

Open surgery was considered the gold standard for treatment of pediatric inguinal hernia and was the most commonly performed surgical procedure in children, recently minimal invasive techniques have become more popular among pediatric surgeons (35-39). Unlike open surgery, a laparoscopic approach has the advantage in regards to the evaluation of contralateral hernias, avoidance of dissecting the vas deferens and spermatic vessels, significantly reduced pain, faster recovery and better cosmetic outcome (27, 35, 40, 41). About fifteen years ago a polish pediatric surgeon Patkowski introduced PIRS for the first time. It involves the percutaneous closure of the internal inguinal ring under the control of a laparoscope placed through the umbilical port (31). When considering the success of an inguinal hernia surgery, one of the most important factors is the number of recurrences. Recurrence rates for open inguinal hernia repair in children range from 0.5 to 4 % (7). Recurrence rates following standard three port laparoscopic hernia repair in pediatric population range from 0.7 to 4.5 % (7, 36).

The first reports of PIRS technique had been associated with higher rates of ipsilateral recurrence and residual hydroceles (31, 32). This had been attributed to several factors such as the inexperience of the surgeons, the use of absorbable suture, the use of a single suture for larger defects. Recently, it has been described that PIRS, as compared with intracorporeal suturing, resulted in a significant reduction of recurrence rates and operative time, and has been attributed with excellent cosmetic results (33-35, 42). Recurrence rate reported by Patkowski was 2.15% (31). Recent published studies reported significantly lower recurrence rates, ranging from 0 to 1.4% (33, 43). Recently, published meta-analysis had shown the rate of recurrence of 0.7%, which is very similar to open surgery (9). In our study there were no recurrences recorded.

Several studies reported development of transient hydroceles in male patients that in most of the cases disappeared spontaneously in a period of 3 to 5 months (31, 39, 44). Our three male patients were found with postoperative hydroceles. In two patients hydroceles resolved by the second or third postoperative month. One patient required surgery due to persistent hydrocele.

Another important parameter on which we may base the success of some surgical technique are complications. As with any surgical technique PIRS is not without

complications. In the hands of an experienced laparoscopic pediatric surgeon, the incidence of complications is very low.

Beside recurrences and hydrocele formation which were discussed above the most commonly reported complications are injury of blood vessels, knot reaction, severe pain, and scrotal swelling (27, 31, 32, 44). Special attention is required while introducing the needle in order to avoid injury of surrounding blood vessels. Patkowski et al reported three children with incidental puncture of the iliac vein that was treated conservatively with gentle pressing from outside (4). Thomas et al in their series also reported three patients who had iliac vessel puncture during PIRS that was controlled by external compression (39). Wolak et al reported two children with incidental puncture of iliac vessels (44). In these situations laparoscopic surgery may be completed only in the absence of further bleeding or growth of retroperitoneal hematoma. If that is not possible conversion to open surgery should be performed. In our study three patients with accidental inferior epigastric vein puncture were identified. In all cases haematoma was self-limited and bleeding stopped spontaneously after short external compression. In all cases surgery was completed by laparoscopy.

Cosmetic results after PIRS are extraordinary. Usually after a short period of time the scar is almost invisible. Rarely, very skinny patients, may complain of palpable subcutaneous suture (39). There are few reports in literature of postoperative reaction to the suture, most commonly formation of suture granuloma. Wang JY et al in their study on 1142 children reported 5 cases (0.44%) of suture granuloma (27). Thomas et al among 250 PIRS procedures reported one patient (0.4%) who developed keloid after surgery (39). Mc Clain et al reported slightly higher incidence of suture granuloma. In their study (1.6%) suture granulomas were recorded in eight patients, with six requiring suture excision and two resolving with steroid injections (43). They also reported nine patients (1.8%) who had wound infections, (four at the umbilical trocar site and five at the inguinal stab incision site) which was not the case in other published studies (43). Baroso C et al reported wound infections and foreign-body reactions in 2.6% of the patients in their study (45). In our study no cases of reaction to the suture or wound infection were reported.

Severe pain and scrotal swelling are rarely reported. Wang JY et al reported three cases (0.26%) of groin traction pain discomfort among 1142 patients (27). In our study, no cases of severe pain after surgery or scrotal swelling were reported. One case of adhesion ileus with bowel strangulation three months postoperatively and one case of omental evisceration were reported in literature (31, 39). Thomas et al reported that both complications and recurrence rates decrease as the surgeons gained experience with the procedure. In their

study, both rates achieved plateau after 50–75 patients (39). Similar findings were noted in our study. Baroso C et al reported that learning curve for perioperative complications, ipsilateral recurrence, and conversion rates is at least 35 cases per surgeon. After this, the laparoscopic repair is a safe and effective approach for pediatric hernia repair (45). Shibuya et al concluded that although there were individual differences, all trainees acquired the skill to perform PIRS adequately within ten months (38).

Many surgeons doubt whether the PIRS technique affects testicular blood perfusion and whether there is any difference compared to conventional open surgery. Oral et al demonstrated that PIRS does not affect testicular vascularization (46). Similar findings were reported in other reports in literature (30, 47).

During PIRS the peritoneum is reached by a blunt needle under direct vision, avoiding the anatomy of the groin structure, causing less trauma, and leaving almost no surgical incision on the abdominal wall (35, 39, 41). Dissection of the sac during open procedure may damage the spermatic cord structure and cause iatrogenic cryptorchidism, or even testicular atrophy (7). To the best of our knowledge, no cases of testicular atrophy or iatrogenic cryptorchidism after PIRS were recorded in literature (33, 35, 42).

However, traditional laparoscopic hernia repair, which includes intracorporeal suturing, requires placement of multiple trocars and has been associated with increased duration of surgery due to intracorporeal suturing, increased postoperative pain and a higher recurrence rates (41, 42). An average duration of pediatric three-port laparoscopic hernia repair ranges from 25-40 min for unilateral and 40-60 min for bilateral hernia (48, 49). Operation time for PIRS is significantly lower than in traditional three port laparoscopic hernia repair. Medians of operative times for unilateral and bilateral repairs are 11 to 19 min and 18 to 24 min, respectively. In our study median of operative time was slightly shorter comparing to reports from the literature, 10 min for unilateral and 16 min for bilateral hernia repair.

The benefit of the PIRS technique, compared to the three port laparoscopic hernia repair, is the possibility of achieving appropriate airway management using laryngeal mask airway with no muscle relaxant as a safe alternative to tracheal intubation. Laryngeal mask airway has proven to be safe and effective for less invasive, short lasting, laparoscopic techniques (PIRS) with the low insufflation pressure of 6–8 mmHg (50).

Zhu H et al reported that PIRS is a reliable and effective minimally invasive technique for the treatment of recurrent inguinal hernia in children after both open and laparoscopic

repair (50). Nowadays there are several modifications of PIRS technique that also proved to be safe, feasible, and reproducible with excellent results (37, 38, 40, 51).

More recent studies suggested that PIRS along with peritoneal injury has resulted in better closure of the internal ring but this findings should be investigated on larger samples of patients (37).

However, limitations of this study are a small population size and relatively short follow-up periods. Results of this study would need to be correlated with further analysis based on more pediatric PIRS cases. PIRS has been shown to be effective mostly in preschool children. Our findings may be the base for the further evaluation of PIRS technique in adolescents with inguinal hernias.

6. CONCLUSION

PIRS is a simple, safe and effective technique for inguinal hernia repair in children with excellent outcomes, cosmetic results and a low incidence of complications and recurrence rates. According to our results and the results of previously published studies, PIRS might be considered to become a gold standard for inguinal hernia repair in the pediatric population.

7. REFERENCES

1. Moore KL, Dalley AF, Agur AMR. Abdomen. In: Moore KL, Dalley AF, Agur AMR, editors. Moore clinically oriented anatomy, 7th ed. Toronto: Lippincott Williams & Wilkins. 2014. p. 201-5.
2. LaPinska M, Blatnik J. Surgical principles in inguinal hernia repair. In: LaPinska M, Blatnik J, editors. Washington: Melissa Phillips LaPinska & Jeffrey A. Blatnik. 2018. p. 7-15.
3. Silvestro C. In: Silvestro C, editor. Inguinal hernia 1st ed. Silvestro Cononico. 2014. p. 1-20.
4. Campanelli G. In: Campanelli G, editor. The art of hernia surgery. Milan: Campanelli Giampiero. 2018. p. 167-93.
5. Beard J, Ohene-Yeboah M, deVries C, Schechter W. Hernia and hydrocele. Disease control priorities, third edition: Essential Surgery. 2015:153-75.
6. Grosfeld JL. Current concepts in inguinal hernia in infants and children. World J Surg. 1989;13:506-15.
7. Pogorelić Z, Rikalo M, Jukić M, Katić J, Jurić I, Furlan D et al. Modified Marcy repair for indirect inguinal hernia in children: a 24-year single-center experience of 6826 pediatric patients. Surg Today. 2016;47:108-13.
8. Chang SJ, Chen JY, Hsu CK, Chuang FC, Yang SS. The incidence of inguinal hernia and associated risk factors of incarceration in pediatric inguinal hernia: a nation-wide longitudinal population-based study. Hernia. 2016;20:559-63.
9. Jenkins J, O' Dwyer P. Inguinal hernias. BMJ. 2008;336:269-72.
10. Hernia Surgery Group. International guidelines for groin hernia management. Hernia. 2018;22:1-165.
11. Ozdamar MY, Karakus OZ. Testicular ischemia caused by incarcerated inguinal hernia in infants: incidence, conservative treatment procedure, and follow-up. Urol J. 2017;14:4030-3.
12. Godbole P, Wilcox D, Koyle M. In: Godbole P, Wilcox D, Koyle M, editors. Guide to pediatric urology and surgery in clinical practice. 2nd ed. Springer International; 2020. p. 173-4.
13. Skandalakis PN, Zoras O, Skandalakis JE, Mirilas P. Richter hernia: surgical anatomy and technique of repair. Am Surg. 2006;72(2):180-4.
14. Köckerling F. TEP for elective primary unilateral inguinal hernia repair in men: what do we know?. Hernia. 2019;23:439-59.
15. LeBlanc K, LeBlanc L, LeBlanc K. Inguinal hernias: diagnosis and management. Am Fam Physician. 2013;87:844-8.

16. Saleem MM. Digital imaging by parents: an aid to the diagnosis of inguinal hernia in infants and children. *Singapore Med J*. 2008;49:145-6.
17. Amini R, Baker N, Woolridge D, Echeverria A, Amini A, Adhikari S. Emergency department diagnosis of an ovarian inguinal hernia in an 11-year-old female using point-of-care ultrasound. *World J Emerg Med*. 2018;9:291-3.
18. Berger D. Evidence-based hernia treatment in adults. *Dtsch Arztebl Int*. 2016;113:150-8.
19. Bowens NM, Morris JB. Inguinal hernia: open surgical repair using mesh. *J Long Term Eff Med Implants*. 2010;20:89-104.
20. Summers J. Classical herniorrhaphies of Bassini, Halsted and Ferguson. *Am J Surg*. 1947;73:87-99.
21. Shalaby R, Ibrahem R, Shahin M, Abdelaziz Y, Abdalrazek M, Alsayaad I, et al. Laparoscopic hernia repair versus open herniotomy in children: a controlled randomized study. *Minim Invasive Surg*. 2012;2012:484135.
22. Hewitt D, Chojnacki K. Groin hernia repair by open surgery. *JAMA*. 2017;318:764.
23. Esposito C, Montinaro L, Alicchio F. Technical standardization of laparoscopic herniorrhaphy in pediatric patients. *World J Surg*. 2009;33:1846-50.
24. Schier F. Laparoscopic inguinal hernia repair-a prospective personal series of 542 children. *J Pediatr Surg*. 2006;41:1081-4.
25. Chong AJ, Fevrier HB, Herrinton LJ. Long-term follow-up of pediatric open and laparoscopic inguinal hernia repair. *J Pediatr Surg*. 2019;54:2138-44.
26. Schukfeh N, Kuebler JF, Dingemann J, Ure BM. Thirty years of minimally invasive surgery in children: Analysis of meta-analyses. *Eur J Pediatr Surg*. 2019; doi: 10.1055/s-0039-1687901.
27. Wang YJ, Zhang QL, Chen L, Lin Y, Zhang JQ, Wu DM, et al. Laparoscopic percutaneous extraperitoneal internal ring closure for pediatric inguinal hernia:1,142 cases. *J Laparoendosc Adv Surg Tech A*. 2019;29:845-51.
28. Bowens NM, Morris JB. Inguinal hernia: open surgical repair using mesh. *J Long Term Eff Med Implants*. 2010;20:89-104.
29. Li Y, Wu Y, Wang C, Wang Q, Zhao Y, Ji Y, et al. Incidence of pediatric metachronous contralateral inguinal hernia and the relationship with contralateral patent processus vaginalis. *Surg Endosc*. 2018;33:1087-90.
30. Pogorelic Z. Effects of laparoscopic hernia repair by PIRS (Percutaneous Internal Ring Suturing) technique on testicular artery blood supply. *J Invest Surg*. 2019;32:348-9.

31. Patkowski D, Czernik J, Chrzan R, Jaworski W, Apoznanski W. Percutaneous internal ring suturing: a simple minimally invasive technique for inguinal hernia repair in children. *J Laparoendosc Adv Surg Tech A*. 2006;16:513-7.
32. Chen Y, Wang F, Zhong H, Zhao J, Li Y, Shi Z. A systematic review and meta-analysis concerning single-site laparoscopic percutaneous extraperitoneal closure for pediatric inguinal hernia and hydrocele. *Surg Endosc*. 2017;31:4888-901.
33. Wang F, Zhong H, Chen Y, Zhao J, Li Y, Chen J, et al. Single-site laparoscopic percutaneous extraperitoneal closure of the internal ring using an epidural and spinal needle: excellent results in 1464 children with inguinal hernia/hydrocele. *Surg Endosc*. 2017;31:2932-8.
34. Jukić M, Pogorelić Z, Šupe-Domić D, Jerončić A. Comparison of inflammatory stress response between laparoscopic and open approach for pediatric inguinal hernia repair in children. *Surg Endosc*. 2019;33:3243-50.
35. Erginel B, Akin M, Yildiz A, Karadag CA, Sever N, Dokucu AI. Percutaneous internal ring suturing as a first choice laparoscopic inguinal hernia repair method in girls: a single-center study in 148 patients. *Pediatr Surg Int*. 2016;32:697-700.
36. Shehata SM, Attia MA, Attar AAE, Ebid AE, Shalaby MM, ElBatarny AM. Algorithm of laparoscopic technique in pediatric inguinal hernia: results from experience of 10 years. *J Laparoendosc Adv Surg Tech A*. 2018;28:755-9.
37. Rao R, Smith M, Markel TA, Gray BW, Landman MP. Modified percutaneous internal ring suturing with peritoneal injury in children: matched comparison to open hernia repair. *Surg Endosc*. 2020; doi: 10.1007/s00464-020-07457-z.
38. Shibuya S, Fujiwara N, Ochi T, Wada M, Takahashi T, Lee KD, et al. The learning curve of laparoscopic percutaneous extraperitoneal closure (LPEC) for inguinal hernia: protocolled training in a single center for six pediatric surgical trainees. *BMC Surg*. 2019;19:6.
39. Thomas DT, Göcmen KB, Tulgar S, Boga I. Percutaneous internal ring suturing is a safe and effective method for the minimal invasive treatment of pediatric inguinal hernia: Experience with 250 cases. *J Pediatr Surg*. 2016;51:1330-5.
40. Li S, Li M, Wong KK, Liu L, Tam PK. Laparoscopically assisted simple suturing obliteration (LASSO) of the internal ring using an epidural needle: a handy single-port laparoscopic herniorrhaphy in children. *J Pediatr Surg*. 2014;49:1818-20.
41. Montupet P, Esposito C. Fifteen years experience in laparoscopic inguinal hernia repair in pediatric patients. Results and considerations on a debated procedure. *Surg Endosc* 2011; 25:450-3.

42. Timberlake MD, Sukhu TA, Herbst KW, Rasmussen S, Corbett ST. Laparoscopic percutaneous inguinal hernia repair in children: review of technique and comparison with open surgery. *J Pediatr Urol.* 2015;11:262.e1-6.
43. McClain L, Streck C, Leshner A, Cina R, Hebra A. Laparoscopic needle-assisted inguinal hernia repair in 495 children. *Surg Endosc.* 2015;29:781-6.
44. Wolak PK, Patkowski D. Laparoscopic inguinal hernia repair in children using the percutaneous internal ring suturing technique - own experience. *Wideochir Inne Tech Maloinwazyjne.* 2014;9:53-8.
45. Barroso C, Etlinger P, Alves AL, Osório A, Carvalho JL, Lamas-Pinheiro R, et al. Learning curves for laparoscopic repair of inguinal hernia and communicating hydrocele in Children. *Front Pediatr.* 2017;5:207.
46. Oral A, Karaca L, Ahiskalioglu A, Yildiz A, Yigiter M, Celikkaya ME, et al. Effects of laparoscopic hernia repair by PIRS (Percutan internal ring suturing) technique on testicular artery blood supply. *J Invest Surg.* 2019;32:343-7.
47. Tanriverdi HI, Senel U, Ozmen Z, Aktaş F. Does the percutaneous internal ring suturing technique impair testicular vascularization in children undergoing inguinal hernia repair? *J Laparoendosc Adv Surg Tech A.* 2015;25:951-3.
48. Bharathi RS, Dabas AK, Arora M, Baskaran V. Laparoscopic ligation of internal ring- three ports versus single-port technique: are working ports necessary? *J Laparoendosc Adv Surg Tech A.* 2008;18:891-4.
49. Neveščanin A, Vickov J, Elezović Baloević S, Pogorelić Z. Laryngeal mask airway versus tracheal intubation for laparoscopic hernia repair in children: Analysis of respiratory complications. *J Laparoendosc Adv Surg Tech A.* 2020;30:76-80.
50. Zhu H, Li J, Peng X, Alganabi M, Zheng S, Shen C, et al. Laparoscopic percutaneous extraperitoneal closure of the internal ring in pediatric recurrent inguinal hernia. *J Laparoendosc Adv Surg Tech A.* 2019;29:1297-301.
51. Shalaby R, Elsaied A, Shehata S, Shehata S, Hamed A, Alsamahy O, et al. Needlescopic assisted internal ring suturing; a novel application of low-cost home-made instruments for pediatric inguinal hernia repair. *Hernia.* 2019;23:1279-89.

8. SUMMARY

Background: Percutaneous internal ring suturing (PIRS) is a minimally invasive surgical technique of laparoscopic hernia repair in children under the control of a laparoscope placed in the umbilicus. The aim of this study was to evaluate the management and postoperative outcomes of PIRS for inguinal hernia repair in children.

Methods: All children who underwent PIRS for an inguinal hernia, between February 2015 and February 2020, were included in a prospective cohort study. Patients' age at the time of surgery, gender, BMI, lateralization of hernia, surgical and anesthesia times, level of pneumoperitoneum, additional trocar introduction, length of hospital stay, intraoperative or postoperative complications and recurrences were recorded.

Results: A total number of 228 inguinal hernia repairs were performed in 188 children (126 (67%) males and 62 (33%) females) with a median age of 4 (IQR 2, 6) years and median follow-up of 46 months. Right-side predominance was noted with 99 (52.7%) right hernia repairs, 49 (26.1%) left hernia repairs, and 40 (21.2%) bilateral hernia repairs. Median surgical time was 10 (IQR 8, 12) min for unilateral and 16 (IQR 14, 20) min for bilateral repair. Median level of pneumoperitoneum was 8 (IQR 7, 8) mmHg. Median hospital stay was 24 (IQR 8, 24) hours. Regarding intraoperative complications only three (1.3%) inferior epigastric veins injuries were recorded, without any consequences. During the follow-up period in three male children hydrocele was recorded, in two cases hydrocele resolved spontaneously and one required surgical treatment. No cases of suture granuloma, groin traction pain discomfort, deferent duct injury, umbilical hernia, iatrogenic cryptorchidism, testicular atrophy or recurrence were recorded.

Conclusion: PIRS is a simple, safe and effective technique for inguinal hernia repair in children with excellent outcomes, cosmetic results and a low incidence of complications and recurrences rates.

9. SUMMARY IN CROATIAN

Naslov rada: Perkutana plastika unutarnjeg otvora preponskog kanala – nova minimalno invazivna metoda liječenja preponske kile u djece: petogodišnje iskustvo jednog kirurga

Cilj istraživanja: Perkutana plastika unutarnjeg otvora preponskog kanala (PIRS) je minimalno invazivna kirurška tehnika liječenja preponske kile u djece, koja se provodi pod nadzorom laparoscopa postavljenog u umbilikalnoj regiji. Cilj ove studije je procijena učinkovitosti i ishoda liječenja preponske kile u djece korištenjem PIRS metode.

Ispitanici i metode: Sva djeca koja su operirana zbog preponske kile PIRS metodom, u razdoblju od 1. veljače 2015. do 1. veljače 2020. godine, uključena su u prospektivno kohortno istraživanje. Svakom djetetu zabilježene su slijedeće varijable: dob, spol, BMI, lateralizacija kile, duljina trajanja operacijskog zahvata i anestezije, razina pneumoperitoneuma, dodatno uvođenje trokara, duljina boravka u bolnici, intraoperacijske i/ili poslijeoperacijske komplikacije i recidivi.

Rezultati: Ukupno je korištenjem PIRS metode operirano 228 kila u 188 djece (126 (67%) dječaka i 62 (33%) djevojčice) sa medijanom dobi od 4 (IQR 2, 6) godine i medijanom praćenja od 46 mjeseci. Desnostrana kila zabilježena je u 99 (52,7%), lijevostrana u 49 (26,1%) i obostrana u 40 (21,2%) djece. Medijan duljine trajanja operacijskog zahvata iznosio je 10 (IQR 8, 12) min za jednostrane i 16 (IQR 14, 20) min za obostrane kile. Medijan razine pneumoperitoneuma bio je 8 (IQR 7, 8) mmHg. Medijan duljine trajanja bolničkog liječenja bio je 24 (IQR 8, 24) h. Zabilježene su tri (1,3%) intraoperacijske komplikacije i to ozljede epigastričnih vena, koje su liječene konzervativno kompresijom, bez posljedica. Tijekom razdoblja praćenja, u troje muške djece zabilježena je hidrokela, u dva dječaka hidrokela se spontano povukla, dok je u jednog bio potreban kirurški zahvat. Nisu zabilježeni slučajevi granuloma u području kirurškog šava, boli u preponi, oštećenja duktusa deferensa, pupčane kile, jatrogenog kriptorhizma, atrofije testisa ili recidiva.

Zaključci: PIRS je jednostavna, sigurna i učinkovita kirurška tehnika liječenja preponske kile u djece s izvrsnim ishodima liječenja i estetskim rezultatima te niskom učestalošću komplikacija i recidiva.

10. CURRICULUM VITAE

PERSONAL INFORMATION

NAME AND SURNAME: Tin Čohadžić

DATE AND PLACE OF BIRTH: August 28th 1994, Split

NATIONALITY: Croatian

CURRENT ADDRESS: Jarušćica 23, 10200 Zagreb, Croatia

E-MAIL: tin.c94@gmail.com

EDUCATION

2001 – 2009. Elementary school „Savski gaj“ Zagreb

2009. – 2012. Private Art Gymnasium Zagreb, language orientation

2012. – 2013. Holland Christian High School, Holland, Michigan, USA

2013. – 2020. Medical Studies in English at the University of Split, School of Medicine

ACCOMPLISHMENTS

Founder and President of Lacrosse Klub Split Legion

Director of Activities (ISA)

Member of MEFST sports committee

Founder of a student tennis league Split

OTHER

Languages: English, German, Croatian

Category „B“ driver

Tennis and guitar player

Lacrosse player (Croatia national team)

Salsa dancer