

Pathohistological findings of pediatric gastrointestinal biopsy at the University Hospital of Split : a three-year retrospective study

Dukić, Jozefina Josipa

Master's thesis / Diplomski rad

2020

Degree Grantor / Ustanova koja je dodijelila akademski / stručni stupanj: **University of Split, School of Medicine / Sveučilište u Splitu, Medicinski fakultet**

Permanent link / Trajna poveznica: <https://um.nsk.hr/um:nbn:hr:171:403693>

Rights / Prava: [In copyright](#)/[Zaštićeno autorskim pravom.](#)

Download date / Datum preuzimanja: **2025-01-28**



Repository / Repozitorij:

[MEFST Repository](#)



**UNIVERSITY OF SPLIT
SCHOOL OF MEDICINE**

JOZEFINA JOSIPA DUKIĆ

**PATHOHISTOLOGICAL FINDINGS OF PEDIATRIC
GASTROINTESTINAL TRACT BIOPSY AT THE UNIVERSITY
HOSPITAL OF SPLIT:
A THREE-YEAR RESTROSPECTIVE STUDY**

Diploma thesis

Academic year:

2019/2020

Mentor:

Assist. Prof. Sandra Zekić Tomaš, MD, PhD

Split, July 2020

TABLE OF CONTENTS:

1. INTRODUCTION	1
1.1. Anatomy of the gastrointestinal system	2
1.1.1. Anatomy of the esophagus	2
1.1.2. Anatomy of the stomach	4
1.1.3. Anatomy of the small intestine	5
1.1.4. Anatomy of the large intestine	7
1.2. Histology of the gastrointestinal system	9
1.2.1. Histology of the esophagus	9
1.2.2. Histology of the stomach	10
1.2.3. Histology of the small and large intestine	11
1.3. Inflammatory Diseases	14
1.3.1. Crohn's disease	14
1.3.2. Ulcerative colitis	18
1.3.3. Focally enhanced gastritis and <i>Helicobacter pylori</i> -negative gastritis	21
1.4. Malabsorption diseases	22
1.4.1. Celiac disease	22
1.5. Infectious disease – <i>Helicobacter pylori</i> -positive gastritis	25
2. OBJECTIVES	28
2.1. Objectives	29
2.2. Hypotheses	29
3. SUBJECTS AND METHODS	30
3.1. Patients	31
3.2. Organization of the study	31
3.3. Place of the study	31
3.4. Methods of data collection and processing	31
3.5. Description of research	32
3.6. Statistical analysis	32
4. RESULTS	33
5. DISCUSSION	39
6. CONCLUSION	42
7. REFERENCES	44
8. SUMMARY	49
9. CROATIAN SUMMARY	51
10. CURRICULUM VITAE	53

ACKNOWLEDGEMENTS

I would like to express my foremost gratitude to my mentor, Assist. Prof. Sandra Zekić Tomaš, MD, PhD, for her consistent support and guidance throughout my thesis. Thank you to Dr. Vanda Žitko and the Department of Pediatrics for supporting me with the collection of my data.

To my family, for always being there with their continuous love and encouragement.

To my parents, for providing me with this opportunity, and for their constant love and support throughout this journey and helping me achieve my dreams.

To my friends, for their endless words of encouragement.

LIST OF ABBREVIATIONS

IBD – Inflammatory bowel disease

UC – Ulcerative colitis

CD – Crohn's disease

FEG – Focally enhanced gastritis

H. pylori – *Helicobacter pylori*

ASCA – anti-*Saccharomyces cerevisiae* antibodies

TNF – Tumor necrosis factor

pANCA – perinuclear anti-neutrophil cytoplasmic antibodies

IgA – Immunoglobulin A

HLA – Human leukocyte antigen

1. INTRODUCTION

1.1. Anatomy of the gastrointestinal system

1.1.1. Anatomy of the esophagus

The esophagus is a hollow, muscular tube of the digestive system, extending approximately twenty-three to twenty-five centimetres as the continuation of the pharynx to the stomach. Beginning at the lower border of the sixth cervical vertebra, it continues downward, anterior to the vertebral column, and travels through the middle mediastinum, entering the abdomen through the esophageal hiatus of the diaphragm at the level of the tenth thoracic vertebra, and ending at the cardia orifice of the stomach (Figure 1) (1,2). Three topographical regions comprise the esophagus: the cervical, thoracic and abdominal esophagus (2,3). The cervical esophagus begins at the cricoid cartilage, at the level of the sixth cervical vertebra, and extends approximately five centimetres to the space in between the suprasternal notch anteriorly and the level of the second thoracic vertebra posteriorly (2). It lies slightly to the left of the midline, surrounded by the larynx and trachea anteriorly and the vertebral column posteriorly, with the carotid sheaths and thyroid gland on each side laterally (1,2). From the thoracic inlet to the esophageal hiatus in the diaphragm is the thoracic esophagus, extending approximately 20 centimetres. As it descends toward the bifurcation of the trachea, the thoracic esophagus is bordered by the membranous wall of the trachea anteriorly and by the prevertebral fascia and spine posteriorly (2). It then passes behind and to the right of the aortic arch, continuing downward to the right of the descending thoracic aorta and posterior to the pericardium and subcarinal lymph nodes (1,2). As it reaches the eighth thoracic vertebra, the thoracic esophagus travels anterior to the aorta, and at the tenth thoracic vertebra, it passes through the esophageal hiatus of the diaphragm and enters the abdomen (2,3). Parietal pleura covers the right lateral surface of the thoracic esophagus, whereas the left lateral surface is enclosed by the left subclavian artery and parietal pleura proximally, and distally by the descending thoracic aorta, until reaching the eighth thoracic vertebra, where it is then, once again, covered with parietal pleura. The abdominal esophagus begins at the esophageal hiatus in the diaphragm, extending approximately two to six centimetres in length, and ends at the cardia of the stomach (2). It becomes enclosed in a fibroelastic sheet of tissue, the phrenoesophageal membrane, as it passes through the hiatus into the abdomen (2). Intra-abdominally, the abdominal esophagus is situated in the esophageal groove, located on the posterior surface of the left liver lobe (1).

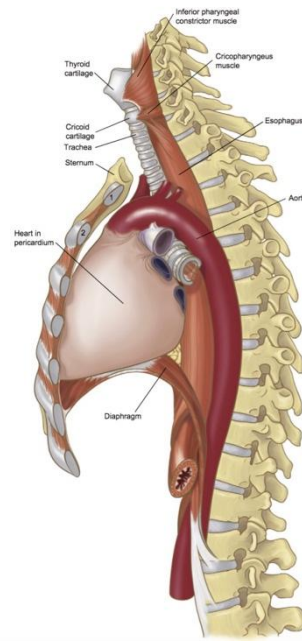


Figure 1. The position of the esophagus (2).

Within the esophagus are two high-pressure zones, the upper and lower esophageal sphincters, which are also regions of the esophagus where the lumen narrows. The narrowest area is the upper esophageal sphincter, which separates the pharynx from the esophagus, and is comprised of several musculocartilagenous structures, including the cricoid cartilage, hyoid bone, as well as the *cricopharyngeus*, cervical esophagus, and inferior pharyngeal constrictor muscles (2,3). The *cricopharyngeus* muscle is an imperative structure of the upper esophageal sphincter, containing both fast- and slow-twitch muscle fibers, with slow-twitch fibers being the most abundant, contributing to its function of maintaining basal tone of the esophagus while also preventing reflux of esophageal contents into the hypopharynx after swallowing. The lower esophageal sphincter is in the region of the distal esophagus, spanning the esophageal hiatus of the diaphragm, therefore consisting of both thoracic and abdominal regions, and functioning to prevent the reflux of gastric contents into the esophagus. Extending from the lower esophageal sphincter are short semi-circular fibers and oblique muscular fibers of various lengths, travelling along the lesser and greater curvatures, respectively (2).

1.1.2. Anatomy of the stomach

The stomach is a hollow, muscular organ, located in the left hypochondriac and epigastric region of the abdomen below the diaphragm, and is preceded by the esophagus and followed by the small intestine (1,4,5). It is generally J-shaped in structure; however, its size and position are variable, depending on certain factors, including the amount of stomach contents, the stage of the digestion process, as well as the position of the body (1,6). It is comprised of four topographical regions: the cardia, fundus, corpus, and pylorus (Figure 2) (7). The esophagus enters the cardia by way of the gastroesophageal junction, making the cardia the first place where food enters the stomach (4,7). Following the cardia is the most superior part of the stomach, the dome-shaped fundus, which functions not only as a reservoir for the incoming bolus of food, but also contains acid-secreting glands to aid in the digestion process (4,7). The largest segment of the stomach, the corpus, follows the fundus, and is responsible for the majority of digestion in the stomach (4). The corpus leads into the final portion of the stomach, the pylorus, which is composed of two segments: the pyloric antrum and the pyloric canal (4,8). The wider pyloric antrum connects to the corpus of the stomach, then narrows toward the right, becoming the pyloric canal and joining the duodenum (8). Additionally, the stomach exhibits two curvatures, the lesser curvature (*curvatura ventriculi minor*) and the greater curvature (*curvatura ventriculi major*) (1,6). The lesser curvature is a concave arch forming the right border of the stomach. It extends from the right of the cardia along the stomach corpus, ending at the superior border of the pylorus (1). Along the lesser curvature, at the junction of the vertical and horizontal parts, is the *incisura angularis*, a distinct notch separating the stomach into left and right portions (1,6). The greater curvature makes the left, convex border of the stomach (1). Being four to five times longer than the lesser curvature, it begins to the left of the cardia, extending along the fundus and left border of the corpus, reaching the inferior border of the pylorus (1,8).

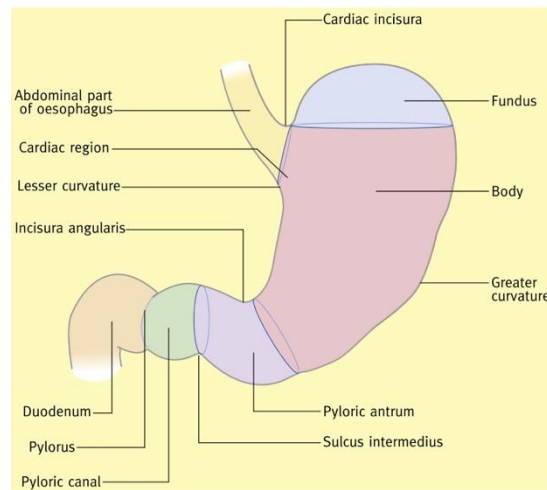


Figure 2. Regions of the stomach (6).

1.1.3. Anatomy of the small intestine

The small intestine is a hollow, convoluted tube, extending six to seven metres from the pylorus to the ileocecal valve, where it joins the large intestine (1,9). It is comprised of three segments: the duodenum, jejunum and ileum (10). The duodenum is the shortest, most proximal part of the small intestine, measuring approximately twenty-five to thirty centimetres in length (9–11). It is composed of four regions, taking the shape of an incomplete circle to surround the pancreas (Figure 3). First is the superior region (*pars superior*), also known as the duodenal bulb, beginning from the pylorus and ending at the neck of the gallbladder (1,11). This is the only region of the duodenum that does not lie retroperitoneally; rather, it is nearly entirely covered with peritoneum and connects to the liver via the hepatoduodenal ligament, which contains the hepatic artery, portal vein, and common bile duct (9,11). Continuing from the neck of the gallbladder is the second or descending portion of the duodenum (*pars descendens*), which continues along the right of the vertebral column from the level of the first lumbar vertebra to as low as the fourth lumbar vertebra (1). The head of the pancreas is situated medial to this descending portion, which is also the site of the major and minor duodenal papilla; the major duodenal papilla houses the entrance for the common bile duct and pancreatic duct, while the minor duodenal papilla is the entrance site for accessory pancreatic ducts (1,9). The horizontal portion (*pars horizontalis*) follows, passing from right to left, anterior to the aorta and inferior vena cava and posterior to the superior mesenteric vessels (1,11). The final portion of the duodenum is the ascending portion (*pars ascendens*), which extends upward along the left side of the aorta

to the level of the second lumbar vertebra; there, it curves sharply to become the next segment of the small intestine, the jejunum, and this forms the duodenojejunal flexure (1,9,11). The jejunum, approximately 2.5 metres in length and located mainly in the left upper quadrant of the abdomen, is a relatively movable portion of the small intestine, as it is joined to the posterior abdominal wall by a thin mesentery (1,9). The luminal surface of the jejunum contains *plicae circulares*, or circular muscular folds, in the mucosa and submucosa to increase the surface area for the absorption of products of digestion (1,9,10). The ileum, approximately three metres in length and located predominantly in the right lower abdomen and pelvis, follows the jejunum (9,10). It, too, is attached to the posterior abdominal wall by a thin mesentery, allowing relatively free movement (1). Although without a clear anatomical demarcation separating the two segments, the ileum differs from the jejunum, as it possesses a thinner lumen and fewer circular folds (1,9). At the end of the ileum resides the ileocecal valve, which is the endpoint of the small intestine (9).

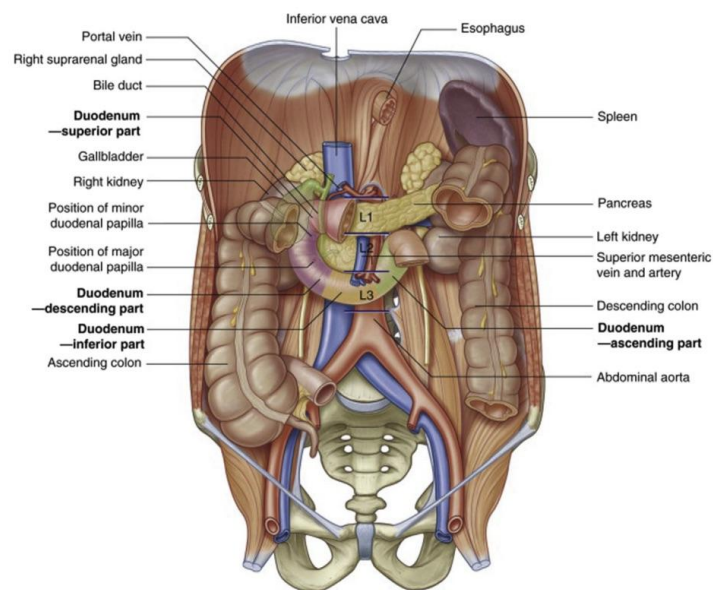


Figure 3. Anatomy of the duodenum (9).

1.1.4. Anatomy of the large intestine

The large intestine is a tubular structure, extending approximately 1.5 metres from the ileocecal valve to the anus (1,12). It is comprised of the cecum, appendix, colon, rectum, and anal canal, with its diameter being the largest at the cecum and gradually decreasing as it continues toward the rectum (Figure 4) (1,13). The large intestine varies from the small intestine in certain characteristics: it is shorter in length but greater in caliber, its position is more fixed, and contains certain appendages, or sacs filled with adipose tissue, on its external surface, the *appendices epiploicae* (1,12,13). Additionally, its outer longitudinal muscle fibers are arranged into three longitudinal bands or taeniae, rather than forming a continuous outer layer. Furthermore, a unique feature of the large intestine is its haustra, or outpouchings, occurring between the taeniae, giving it a saccular appearance (1,12). The commencing segment of the large intestine is the cecum, a blind pouch situated at the level of the ileocecal intersection in the right iliac fossa. It is approximately six to eight centimetres in length and breadth, with its open end directly communicating with the succeeding colon. Arising from the posteromedial apex of the cecum is the vermiform process, or appendix, with its tip most commonly floating freely in a retrocecal position (1,13). Continuing from the cecum is the colon, which is comprised of four segments: the ascending, transverse, descending and sigmoid colon (1). The ascending colon is situated retroperitoneally, and is smaller in diameter than the cecum, extending from the ileocecal valve superiorly along the right side of the abdomen to the inferior surface of the posterior lobe of the liver (1,12,13). There, it curves forward and left, forming the right colic, or hepatic, flexure (1,12). At this hepatic flexure, the colon bends anteriorly and medially becoming the transverse colon, which is the longest and most mobile segment of the colon, extending approximately forty to fifty centimetres (12,13). It extends from the right hypochondriac region of the abdomen with a downward curvature to the left hypochondriac region, where it turns abruptly below the lower pole of the spleen, forming the left colic, or splenic, flexure (1,12). The transverse colon is almost entirely embedded in peritoneum, with its mesentery, the transverse mesocolon, attaching it to the inferior border of the pancreas (1,13). Continuing from the transverse colon is the descending colon, extending twenty-five to forty-five centimetres in length and having a narrower caliber than the preceding colonic segments (12). Its course runs posteriorly then inferiorly through the left hypochondriac region of the abdomen in the retroperitoneum, covered posteriorly with peritoneum (1,12). Emerging into the peritoneum from the descending colon is the terminal segment of the colon, the sigmoid (12). Its length

is variable; however, it extends approximately forty centimetres in length, beginning at the pelvic brim and forming an S-shaped loop as it terminates at the third sacral vertebra as the rectum (1,13). The rectum lies in the sacrococcygeal curve, extending for a total of approximately twelve centimetres to just below the tip of the coccyx, then curving abruptly into the anal canal (1). Being primarily fixed, situated both retroperitoneal and subperitoneal in location, it is most narrow at its junction with the sigmoid colon, becoming wider as it approaches the anus (12,13). The rectum differs from the remainder of the colon, as it does not contain the *appendices epiploicae* nor the saccular appearance due to the lack of taeniae. However, the rectum is unique, as it contains three transverse, semilunar folds, the valves of Houston, on its luminal surface, which function to “support the weight of the fecal matter” (1,12). The rectum leads into the terminal portion of the large intestine, the anal canal, which is situated in the ischiorectal fossa (1,12). In the infant, it extends approximately two centimetres in length, compared to approximately five centimetres in the adult (12). It is not covered with peritoneum; however, it is encircled by the *levator ani*, *coccygeus* and *puborectalis* muscles at the anorectal junction (1,12). Stool is retained in the anorectum by contraction of these muscles, and defecation is allowed with their relaxation. The upper three-quarters of the anal canal is surrounded by a circular smooth muscle layer, the internal anal sphincter, whereas the external anal sphincter is made up of striated muscle, joining the *levator ani* muscle and attaching posteriorly to the coccyx and anteriorly to the perineal body (12). The luminal surface of the anal canal includes a number of longitudinal folds, known as the rectal columns of Morgagni. These columns are separated from one another by rectal sinuses and bound together by small mucosal folds, the anal valves (1,12).

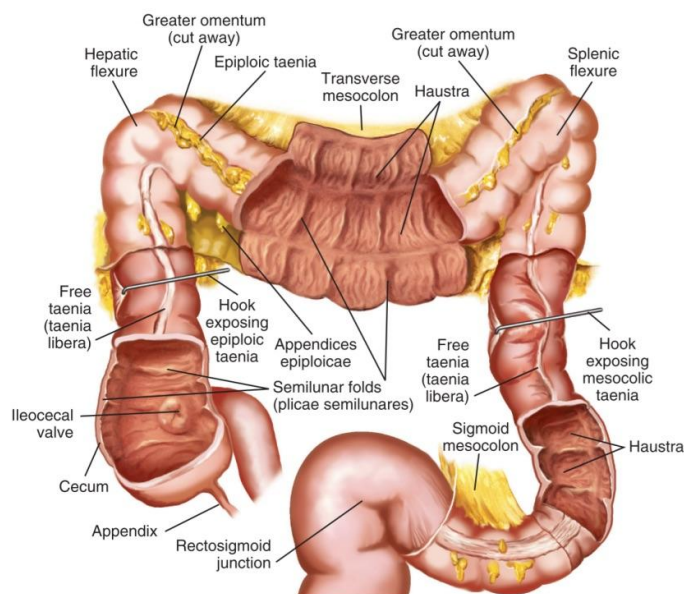


Figure 4. Anatomy of the large intestine (12).

1.2. Histology of the gastrointestinal system

1.2.1. Histology of the esophagus

The wall of the esophagus is comprised of four layers: the mucosa, submucosa, muscular layer and adventitia; unlike the remainder of the gastrointestinal system, it is lacking a serosal layer (2,3). The innermost lining is the mucosa, and is comprised of three layers: epithelium, lamina propria, and *muscularis mucosae* (2). The epithelium is bordered inferiorly by the basement membrane, and is predominantly stratified squamous epithelium, except at the distal one to two centimetres, found at the gastroesophageal junction, where the epithelium transitions to simple columnar epithelium (2,3). Below the basement membrane is a layer of connective tissue, known as the lamina propria. Separating the mucosa from the submucosa is the *muscularis mucosae*, a layer of smooth muscle fibers that are arranged longitudinally and irregularly (2). At the proximal portion of the esophagus, the *muscularis mucosae* is very thin, with only a few scattered muscle fiber bundles, but becomes thicker distally (1,2). The submucosa is a layer of collagen and elastic fibers, separating the mucosal and muscular layers (2). It also contains blood vessels, lymphatic vessels, mucous glands, and nerve networks, including both sympathetic nerves and the parasympathetic Meissner's plexus (1–3). Above the submucosa is the muscular layer, or *muscularis propria*, which is composed of an inner layer of circular muscle fibers and an outer layer of longitudinal muscle

fibers (2,3). The proximal third of the esophageal muscular layer consists of striated muscle, transitioning into smooth muscle at the level of the aortic arch, and consisting of only smooth muscle in the distal two-thirds (1,2). The myenteric, or Auerbach plexus, is situated between the inner and outer muscle layers. The adventitia is the outermost lining of the esophageal wall, which is a layer of loose connective tissue, containing small blood vessels, lymphatic channels and some nerve fibers (2,3).

1.2.2. Histology of the stomach

The wall of the stomach is comprised of four layers: the mucosa, submucosa, muscular layer and serosa (1,14). The mucosa, or mucous membrane, is the smooth inner layer of the stomach that is thin at the cardia and thicker toward the pylorus (Figure 5) (1). When the stomach is contracted, this mucous membrane folds to form coarse, longitudinal rugae, most marked along the greater curvature and toward the pylorus; when the stomach is distended, the rugae are smoothed (1,14). The surface of the mucosa is lined with columnar epithelium (Figure 5), which transitions abruptly at the cardia from stratified squamous epithelium of the esophagus (1,14). Three types of gastric glands are present within the mucosa: pyloric, cardiac, and fundus or oxyntic glands (14). Within the pylorus and cardia are the pyloric and cardiac glands, respectively, which secrete mucus, while throughout the fundus are the acid-secreting oxyntic glands (1,14). Specifically, chief cells that secrete pepsinogen are located in the base of the glands, whereas parietal cells secreting hydrochloric acid are located largely in the middle of the gastric glands (7). Situated between the glands is connective tissue together with lymphoid tissue, which collects into small masses to form the lenticular glands of the stomach. The submucosa is the layer of the stomach consisting of loose connective tissue that connects the mucous and muscular layers (1). The muscular layer is comprised of three sets of smooth muscle fibres: longitudinal fibers in the outermost layer, oblique fibers in the innermost layer, and circular fibers between these two layers. The longitudinal muscle layer is continuous with that of the esophagus, with the circular muscle fibers situated beneath this longitudinal layer (1,14). The circular muscle fibers are most abundant at the pylorus, forming the pyloric sphincter (14). The oblique muscle fibres comprise the innermost layer, and are located solely at the cardia (1,14). The serous layer is derived from peritoneum, and is the outermost covering of the entire organ, lacking only at the attachment of the greater and lesser omenta at the greater and lesser curvatures (1).

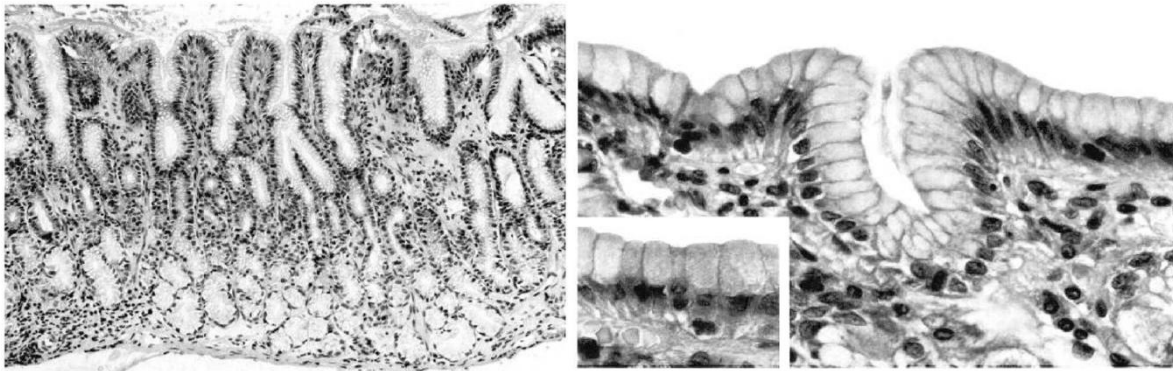


Figure 5. Antral mucosa (left) and surface epithelium (right) of the stomach (14).

1.2.3. Histology of the small and large intestine

The walls of the small and large intestine share similar histological features, and just like the wall of the stomach, are comprised of four layers: mucosa, submucosa, muscular layer, and serosa (1,12).

The mucosa of the small intestine is thick and highly vascularized proximally, becoming thinner and paler distally, and is comprised of glandular epithelium and the *muscularis mucosae* (Figure 6). It is characterized by its concentric folds, the *plicae circulares*, or valves of Kerckring, with their surfaces covered with villi which are lined with enterocytes, goblet cells, and enteroendocrine cells. The enterocytes are columnar epithelial cells, containing a clear oval nucleus and multiple nucleoli, and they form the basement membrane (1,12). Their luminal surface is lined with enzyme-containing microvilli for nutrient absorption, while the apical surface contains brush border transporters and ion exchangers (12). Within the mucosa of the small intestine are the intestinal crypts, or crypts of Lieberkühn, which are tubular glands containing mainly Paneth cells and undifferentiated cells, and extending into the *muscularis mucosae* (1,12). The Paneth cells contain an eosinophilic granular cytoplasm, with a flask-shaped appearance and its wide base against the basement membrane, secreting various proteins and enzymes that are protective against infectious pathogens. Goblet cells are predominantly located in the upper region of the crypts, and they are characteristically oval or round with a flattened basal nucleus, containing a basophilic cytoplasm as well as granules that secrete mucin. Enteroendocrine cells are columnar cells with endocrine function, containing secretory granules and are sporadically

dispersed both throughout the crypts and villi of the small intestine (12). The submucosa is the loose connective tissue layer located between the *muscularis mucosae* and the muscular layer of the intestinal wall, containing various cells, including lymphocytes, plasma cells and mast cells, and also containing blood vessels, lymphatic vessels and the Meissner's nerve plexus, comprised of both nonmyelinated postganglionic sympathetic fibers and parasympathetic ganglion cells (1,12). The submucosa also contains the Brunner's glands, most prominently in the initial segment of the duodenum, whose function is not only to produce an alkaline secretion rich in bicarbonates to neutralize the gastric chyme, but also to secrete a mucinous substance for lubrication of the mucosa, as well as various other substances (12). The muscular layer of the small intestine is comprised of two sets of smooth muscle, the external longitudinal muscle fibers and internal circular muscle fibers, that are responsible predominantly for peristalsis, with the myenteric, or Auerbach's nerve fiber plexus, situated between the two muscle layers (1,12). Within the myenteric plexus of the muscular layer and the submucosa of both the small and large intestine are the spindle-shaped interstitial cells of Cajal, with long ramified processes, functioning as the pacemaker cells of the intestine to regulate peristalsis (12). The serosa, as in the rest of the gastrointestinal tract, is the outermost layer composed of mesothelial cells, connective tissue and is derived from the peritoneum, enveloping the intestine (12).

The mucosa of the large intestine is pale and smooth, without villi yet raised into multiple crescentic folds in the cecum and in the colon, whereas in the rectum it is thicker and more vascularized (1). As with the mucosal layer of the small intestine, the *muscularis mucosae* is also present in the large intestine (1,12). Similarly, the crypts of Lieberkühn are situated in the mucosa, extending into the *muscularis mucosae*, occupied predominantly with goblet cells, producing mucin to aid in the passage of stool, few enteroendocrine and absorptive cells, and scarce Paneth cells (12). The epithelium is comprised of columnar cells, with goblet cells and vascular cells scattered throughout, while tall columnar absorptive cells, known as the principal cells, line mainly the upper third portion of the crypts (12). Tubular extensions of the mucous membrane form the glands of the large intestine, organised perpendicularly over the entire mucosal surface, and secreting mucus to maintain lubrication of the surface. The submucosa is similar to that of the remainder of the gastrointestinal tract (Figure 7), with the additional presence of solitary lymphoid follicles, being most abundant in the cecum and dispersed throughout the rest of the intestine. The muscle layer similarly consists of two sets of smooth muscle, the outer longitudinal muscle fibers and the inner

circular fibers. These longitudinal muscle fibers are not a continuous muscle layer; rather, they form three longitudinal bands, the *taeniae coli* (1,12). In the sigmoid colon, the longitudinal bands are more scattered, while forming a more distinct layer in the rectum to completely encircle it (1). The inner muscular layer is comprised of circular muscle fibers, forming a thin layer in the cecum and the colon, but forming a thicker layer in the rectum and creating the sphincter in the anal canal (1). The outermost serosa envelops the intestine, much like in the remainder of the gastrointestinal tract (12).

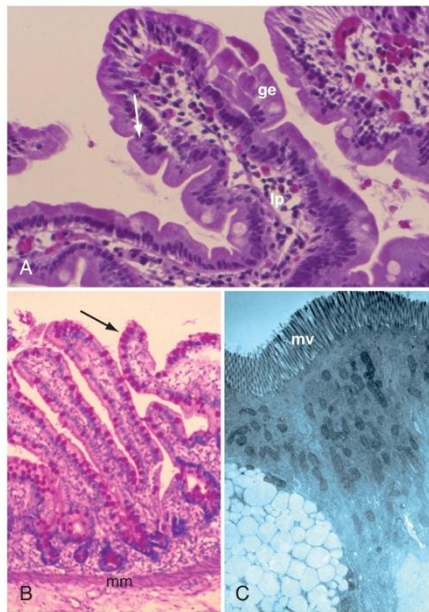


Figure 6. Histology of the small intestine. A: mucosa; ge: glandular epithelium; lp: lamina propria. B: Goblet cells (arrow); mm: *muscularis mucosa*. C: mv: microvilli (12).

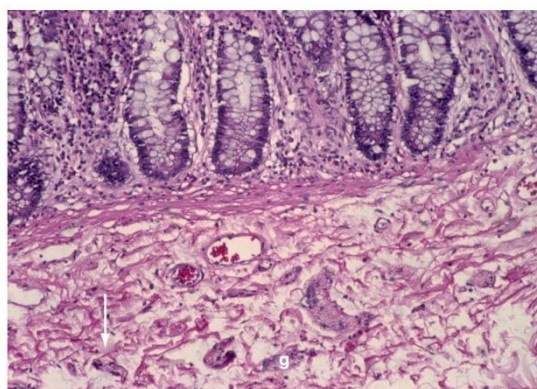


Figure 7. Submucosal plexus of colon. Nerve trunks (arrow), g: ganglia (12).

1.3. Inflammatory Diseases

Inflammatory bowel disease (IBD) encompasses a range of gastrointestinal tract disorders, characterized by a chronic relapsing and remitting pattern of inflammation (15,16). The two major subgroups are ulcerative colitis (UC) and Crohn's disease (CD), which are distinguished from one another primarily by clinical, endoscopic, histological and radiological findings; however, overlap of histological and endoscopic findings are possible, leading more often to a diagnosis of IBD-unspecified (17,18). Although IBD can affect all age groups, there is an increasing incidence in children and young adults, with approximately 20% to 30% of cases being diagnosed in childhood or adolescence (15,16,19). UC is the predominant form of pediatric IBD in children younger than age 6, whereas CD is more predominant in children aged 6 years and older. In comparison to adult-onset IBD, pediatric IBD is typically more extensive and more severe (18). In addition to symptoms of the gastrointestinal tract, such as abdominal pain, diarrhea, and hematochezia, patients with IBD present with systemic manifestations, including weight loss, growth delay, skin changes, depression and anxiety, which are more often seen with the pediatric-age onset (18,19).

1.3.1. Crohn's disease

Crohn's disease is a chronic relapsing inflammatory bowel disease, potentially involving any segment of the gastrointestinal tract, from the mouth to the anus (20). It is the predominant subtype of pediatric IBD, comprising approximately 60% to 70% of pediatric IBD cases with its incidence increasing, particularly at approximately 7 years of age (18,19,21). Children younger than 18 years of age comprise roughly 20% of patients presenting with CD, whereas nearly 80% are in adolescence (21). In the pediatric population, CD demonstrates a male-to-female predominance ratio is up to 1.8:1 (19).

The etiology of CD is unclear; however, it is likely caused by an interplay of genetics, immunological responses to intestinal microbiota, and environmental triggers (16,17,22). Most probably, genetically-susceptible individuals possess a dysregulation of the immune response toward intestinal flora, resulting in inflammation (16,17). Environmental triggers, including antibiotic exposure in early life, Western diet, air pollution, breast feeding and GI infection, have been identified as risk factors for the development of CD (20,22).

In comparison to adult-onset disease, childhood CD presents with a more severe course and more extensive disease (19). The most common presenting complaint among

pediatric patients is abdominal pain, although other bowel symptoms, including diarrhea, rectal bleeding and vomiting, may also be present (19,21). Additionally, pediatric patients more often show systemic manifestations, such as weight loss, anorexia, fever, growth failure and delayed puberty (19,20). Extraintestinal manifestations, particularly aphthous stomatitis, erythema nodosum, ankylosing spondylitis, peripheral arthritis and perianal disease occur more frequently with CD than with ulcerative colitis, with up to 28% of pediatric patients exhibiting these manifestations at diagnosis (18,20).

Diagnosis of CD is mainly based on patient history and physical examination, using laboratory and serologic results as well as radiologic, endoscopic and histological findings to further support the diagnosis (20,21). Although there are no pathognomonic indicators of CD, typical laboratory findings include elevated erythrocyte sedimentation rate and C-reactive protein, anemia, thrombocytosis, fecal calprotectin and in more than half of patients, hypoalbuminemia (20,21). Infectious colitis, as well as non-infectious enteric diseases including neoplasms, chronic granulomatous diseases, and functional bowel disorders, should be excluded (20). Serological features that aid in the diagnosis of CD include the presence of anti-*Saccharomyces cerevisiae* antibodies (ASCA) (18,23). CD most often involves the terminal ileum; however, as any part of the gastrointestinal tract may be involved, both upper and lower endoscopy are performed to visualize the gastrointestinal tract in its entirety (17,21). Multiple tissue biopsies are collected at the time of endoscopy, and together they remain the gold standard for the diagnosis of not only CD, but IBD in general (17). To supplement this, additional imaging is performed using computed tomography and magnetic resonance enterography (18).

Typical endoscopic features of CD include a discontinuous pattern of inflammation, referred to as “skip lesions,” as well as fissures, strictures, and aphthous or linear ulcers separated by non-ulcerated mucosa, creating a characteristic cobblestone appearance (17,20). Histologic findings include transmural inflammation as well as focal chronic inflammation (Figure 8) (20). Histology studies also reveal disruption of crypt architecture and the distinctive microscopic finding of CD, non-caseating granulomas (17,18,20).

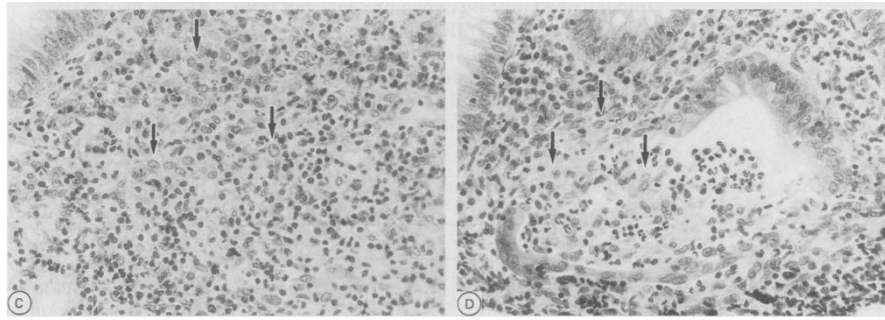


Figure 8. Crohn's disease: excess histiocytes (left), basal histiocytic cryptitis (right) (17).

The clinical features of CD are classified using the Paris pediatric modification of the Montreal classification of phenotypic characteristics of IBD, which is presented in Table 1 (19,24).

Treatment of CD includes both medical and operative therapy (21). Using the Pediatric Crohn's Disease Activity Index, which considers abdominal pain, number of stools per day, level of activity, laboratory values (hematocrit, erythrocyte sedimentation rate, and albumin), weight, height, height velocity, perianal disease and extraintestinal manifestations, the disease severity is determined, and treatment is administered according to disease severity (19,25). Exclusive enteral nutrition is recommended as the first-line therapy for induction of remission (19,21). Aminosalicylates may be administered orally for mild disease; however, they are typically not used (17). Corticosteroids are recommended not only for mild to moderate disease, but are also used for acute exacerbations and are the mainstay therapy of moderate to severe disease (17,25). If perianal disease is present, antibiotics are added as the first-line treatment to the therapy regimen (17,25). Immunomodulators, including 6-mercaptopurine, azathioprine and methotrexate, are predominantly used to maintain remission (25). For refractory moderate to severe CD or when corticosteroids are contraindicated, biologic therapy, that is, TNF inhibitors, are used both for induction and maintenance of remission (17,25). Surgery is performed as treatment when medical management is unsuccessful, when there are complications of disease, such as fistula formation, refractory strictures or perforation, and when perianal disease is persistent and severe (19,25).

Table 1. Paris pediatric modification of Montreal classification of phenotypic characteristics of Crohn's disease.

Age of diagnosis:

A1a: 0 to less than 10 years

A1b: 10 years to less than 17 years

A2: 17 years to 40 years

A3: greater than 40 years

Location of disease:

L1: distal one-third ileal with or without limited cecal disease

L2: colonic

L3: ileocolonic

L4a: upper disease proximal to ligament of Treitz

L4b: upper disease distal to the ligament of Treitz and proximal to distal one-third ileum

L4a and L4b may coexist

Behaviour of disease:

B1: non-stricturing, non-penetrating

B2: stricturing

B3: penetrating

If stricturing and penetrating are present at the same or different times, use B2B3

If perianal disease, add modifier p

Growth:

G0: no evidence of growth delay

G1: growth delay defined by linear impairment

1.3.2. Ulcerative colitis

Ulcerative colitis is another form of chronic inflammatory bowel disease, with a relapsing and remitting pattern, characteristically involving the rectum and extending proximally and continuously to involve the colonic mucosa (18,23,26). It is the dominant subtype of IBD in adults, comprising only 24% to 32% of pediatric IBD cases (18,22). Nonetheless, UC commonly presents in adolescence or young adulthood, with an increasing incidence in younger pediatric patients, particularly in the 11-15-year age group (22,23,26). As with CD, UC shows a slight male predominance; however, there is usually no significant gender difference, affecting both males and females equally (17,23).

The etiology of UC is unclear, yet as with CD, the gastrointestinal inflammation is likely due to impaired immunological responses to intestinal microbiota, with genetics and environmental factors playing a crucial role (17,23). Patients with a positive family history of IBD presented at a younger age compared to individuals without a family history, with this tendency being stronger with UC than with Crohn's disease (17,23). Environmental factors, including early exposure to antibiotics, air pollution, stress, and GI infection, similarly increase the risk for the development of UC; however, although cigarette smoking is a risk factor for the development of CD, it seems to be protective against the development of UC, suggesting different causative pathways in the development of IBD (22,23).

Compared to adult-onset disease, pediatric UC presents with a very extensive disease, as the whole colon is more likely to be involved, with pancolitis presenting in approximately 60% to 90% of pediatric UC patients; additionally, acute severe exacerbations are more frequent (18,19,26). The hallmark symptom of UC is bloody diarrhea, with rectal bleeding occurring more frequently with UC than CD (18,23,27). Further signs and symptoms may include abdominal pain, tenesmus, anemia and fatigue, though systemic manifestations such as weight loss and growth failure, occur less frequently (17,18,26). Extraintestinal manifestations are less common in UC compared to CD, occurring in merely approximately 20% of patients (18). These manifestations include peripheral arthritis, pyoderma gangrenosum, aphthous stomatitis, uveitis, osteoporosis, with a very strong association between primary sclerosing cholangitis and UC (18,26,28).

As with CD, the diagnosis of UC is established by medical history, physical examination, laboratory and serologic results, as well as distinctive radiologic, endoscopic and histological findings (29). Non-specific laboratory findings include the presence of iron deficiency anemia, thrombocytosis, hypoalbuminemia and elevated fecal calprotectin,

whereas markers of inflammation C-reactive protein and erythrocyte sedimentation rate are elevated in severe UC and are often normal in mild to moderate disease (28,30). In order to establish the diagnosis of UC, infective and ischemic causes of colitis must be excluded (28). The presence of perinuclear anti-neutrophil cytoplasmic antibodies (pANCA) is a serological finding that further supports the diagnosis of UC (23,28). Imaging with computed tomography and magnetic resonance imaging may show a thickened colon with the loss of haustral markings, which may further aid in diagnosis (30).

The gold standard of diagnosing and differentiating IBD includes endoscopic examination and histologic analysis of multiple tissue biopsies (17). Macroscopically, diffuse inflammation is visualized in a continuous and circumferential pattern without skip-areas, presenting as erythema, loss of normal vascular pattern, granularity, friability, and superficial ulcerations (26,29,30). This inflammation typically begins in the rectum and continues a variable distance proximally to involve the colon; nevertheless, 5% to 30% of pediatric UC patients show rectal sparing and more often present with pancolitis compared to adult-onset UC (18,28). Although inflammation is typically confined to the colon, pediatric UC may also present with inflammation of the terminal ileum, termed “backwash ileitis” (26). Histological features include inflammation limited to the mucosa and submucosa, distortion of crypt architecture and cryptitis, increased lymphocytes and plasma cells in the lamina propria, depletion of mucin, and Paneth cell metaplasia (Figure 9) (17,26,30).

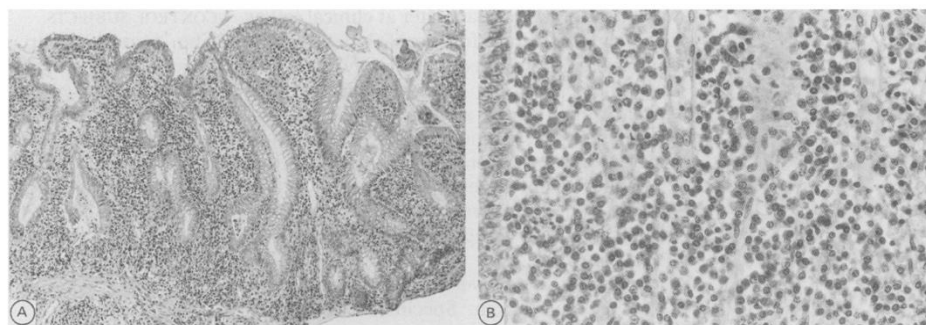


Figure 9. Ulcerative colitis. Villous surface (left), non-histiocytic chronic inflammation (right) (31).

The clinical features of UC are classified using the Paris pediatric modification of the Montreal classification of phenotypic characteristics of IBD (Table 2) (18).

Treatment of UC is based on disease severity, which is determined using the Pediatric Ulcerative Colitis Activity Index, taking into account various features of UC, including abdominal pain, rectal bleeding, consistency of the majority of stools, number of stools per 24 hours and the presence or absence of nocturnal stools, as well as activity level (19). If the disease is mild in severity, the first-line therapy for induction and maintenance of remission is aminosalicylates, administered orally or topically depending on disease location (17,26). Oral corticosteroids are used to induce remission of moderate disease, with the attempted use of aminosalicylates as maintenance therapy (26). Severe disease is also treated with corticosteroids; however, if chronic, steroid-dependent disease is present, immunosuppressants, such as 6-mercaptopurine or azathioprine, are used as maintenance therapy (28). Furthermore, severe disease may be refractory to corticosteroids and therefore requires biological therapy, mainly anti-TNF-alpha monoclonal antibodies, for induction and maintenance of remission (17,28). Patients who are unresponsive to medical management, have developed complications or intolerable side effects of medical therapy, present with fulminant colitis or have developed dysplasia, undergo surgical therapy in the form of colectomy, which is the treatment of choice for these circumstances (26,28).

The risk of colon cancer is increased in patients with UC, particularly in patients with long-standing disease and those with primary sclerosing cholangitis (30). Although pediatric UC has a low absolute risk of cancer, screening with colonoscopy for dysplasia should be initiated 5 to 10 years after diagnosis (19).

Table 2. Paris pediatric modification of Montreal classification of phenotypic characteristics of Ulcerative colitis.

Extent:

E1: ulcerative proctitis

E2: left-sided UC (distal to splenic flexure)

E3: extensive (hepatic flexure distally)

E4: pancolitis (proximal to hepatic flexure)

Severity:

S0: never severe

S1: ever severe

1.3.3. Focally enhanced gastritis and *Helicobacter pylori*-negative gastritis

Focally enhanced gastritis (FEG) is an inflammatory microlesion of the gastric mucosa that, although less common in adults, appears to be predictive of IBD in pediatric patients (32,33). In pediatric IBD, it is recognized in 55% of children with CD and approximately 25% of children with UC; although it is much more frequent in patients with CD, FEG does not consistently differentiate between CD and UC (15,34). Upper gastrointestinal tract symptoms and radiological irregularities are absent in approximately 50% of children with CD, despite having histological changes in the gastric mucosa (34). Although patients may present with upper gastrointestinal symptoms, there is no significant difference between symptomatic and asymptomatic patients in regards to the presence of FEG (15,35). To establish the diagnosis of gastritis, endoscopic examination with histological analysis of biopsies of the stomach is performed as the gold standard diagnostic tool (36). Macroscopic findings upon endoscopic visualization are relatively non-specific, including erythema, aphthoid lesions and ulcerations, being present in approximately 36% of IBD patients (33,36). Histological evaluation reveals focal pit inflammation, involving at least one foveolium or gastric gland, consisting of perifoveolar and periglandular accumulation of lymphocytes and histiocytes, resulting in epithelial injury. Plasma cells, eosinophils and neutrophils may be present in variable amounts, though the background mucosa is rather normal (15,32). In patients with UC, the total number of glands involved in FEG lesions is higher than in patients with CD (15,33). The presence of active ileitis and granulomas in various parts of the gastrointestinal system together with FEG further suggest the diagnosis of CD (15). Additionally, FEG is associated with CD only when *Helicobacter pylori* infection has been excluded; otherwise, the histological findings of the gastric mucosa in *H. pylori*-positive IBD patients are non-specific (36,37).

Although infection with *Helicobacter pylori* is a common infectious cause of gastritis and peptic ulcer disease, gastritis as well as duodenitis in the absence of *H. pylori* infection occur more frequently in IBD patients, occurring in up to 60% of CD patients and 20% of UC patients (38,39). Gastritis without *H. pylori* infection occurs at a higher rate in pediatric IBD patients, in approximately 50% of cases, compared to adult IBD, present in only about 20% of instances (40). Chronic active *H. pylori*-negative gastritis largely occurs in CD patients between the ages of 5 and 9 years, with a decline in incidence in subsequent age groups (38). Histological analysis of gastric biopsies demonstrates focal or diffuse inflammatory infiltrates

of the surface or foveolar epithelium of gastric mucosa with lymphocytes, histiocytes and if active gastritis, neutrophils, in the absence of *H. pylori* organisms (38). When these inflammatory infiltrates are localized around the gastric glands, they then may be referred to as FEG (38).

Even in the absence of endoscopic abnormalities of gastric mucosa, histological visualization of FEG and the absence of *H. pylori* organisms provide additional support for the diagnosis of IBD, particularly CD, in pediatric patients (15,36).

1.4. Malabsorption diseases

Intestinal malabsorption refers to some dysfunction of the gastrointestinal system leading to impaired absorption of one or more nutritive substances by the small intestine (41,42). Common clinical features in children with malabsorption include chronic diarrhea and malodorous stool, abdominal distention, failure to thrive and weight loss; although malabsorption predominantly presents with diarrhea, it may be absent at presentation, with the only apparent sign being poor growth (41,43).

1.4.1. Celiac disease

Celiac disease is an autoimmune disorder characterized by permanent sensitivity to gluten, leading to injury of the small intestine triggered by the ingestion of dietary gluten (44,45). It affects approximately 1% of the general population, with a higher prevalence in children than in adults, affecting approximately 1 in 300 to 1 in 80 children (41,44,46). The prevalence of celiac disease is higher in females, accounting for approximately 60% of patients (47). Celiac disease also occurs more frequently in patients with other autoimmune diseases, with a higher risk of celiac disease in individuals with Turner syndrome, Down syndrome or selective IgA deficiency (41,47). Individuals carrying the HLA class II haplotype DQ2 or DQ8 are genetically predisposed to the development of celiac disease, and these are the most significant genetic susceptibility factors (44). In addition to genetic susceptibility, environmental factors influence the development of celiac disease (44,45). The chief environmental risk factor is the ingestion of dietary gluten, found in cereal grains such as wheat, rye, and barely (42). Additionally, infant feeding patterns, particularly breastfeeding and the introduction of gluten into the diet, are important risk factors for the development of celiac disease (45,48). Breastfeeding seems to be protective, while the

introduction of dietary gluten at 6 months of age or later may increase the risk of celiac disease (48). The amount of gluten introduced is also an important environmental factor, with the risk of developing celiac disease being higher when ingesting a large amount of gluten at introduction (48). Furthermore, alterations in the composition of intestinal microbiota, influenced by mode of birth delivery, gastrointestinal infections, and early antibiotic exposure, are associated with an increased risk of celiac disease development (44,48).

Celiac disease has been divided clinically into three groups: classical, nonclassical, and subclinical; classical disease presents with diarrhea, nonclassical is symptomatic yet without diarrhea, and subclinical is diagnosed during screening in an asymptomatic patient (46). However, the main clinical presentation is better described as intestinal and extraintestinal celiac disease, which can also occur simultaneously (49). The classical, intestinal form is more common in pediatric patients compared to adults, and is most prevalent in children younger than 3 years of age (46,49). These patients present with diarrhea, abdominal distention, loss of appetite, and failure to thrive, with abdominal pain being the most common complaint of patients with celiac disease (44,46,49). Older children and adults may present with similar symptoms; however, the nonclassical form of celiac disease is the more predominant form in older children and adolescents. The nonclassical form presents with a variety of extraintestinal manifestations (46). In adults, iron deficiency anemia is most common, alongside dermatitis herpetiformis cutaneous lesions, whereas in children, short stature is the most common extraintestinal feature together with iron deficiency anemia (46,50). Additional extraintestinal manifestations include fatigue, which is common in all forms of symptomatic celiac disease, headaches, aphthous ulcers and osteopenia or osteoporosis (44,50). Pediatric patients with celiac disease also have a higher incidence of dental enamel hypoplasia compared to adult patients, while one-third of pediatric patients may also have unexplained elevation of aminotransferase levels. Adolescents with celiac disease frequently experience psychiatric symptoms, including depressions, hallucinations and anxiety (50).

The detection of mucosal damage, as demonstrated by intestinal biopsy, together with the presence of anti-tissue transglutaminase antibodies, anti-endomysium antibodies and deaminated gliadin peptide antibodies on serological testing, in combination with the clinical findings, are the current gold standard for the diagnosis of celiac disease (42,49). Upon clinical suspicion, serological testing for the detection of autoantibodies is used as the initial screening tool to select patients for further intestinal endoscopy and biopsy (44,48). Tissue

transglutaminase IgA antibody is the recommended initial test, followed by endomysium IgA antibody detection, which together have nearly 100% sensitivity and specificity for celiac disease (44,45,48). In children younger than 7 years of age, deaminated gliadin peptide IgA antibody has a comparable sensitivity to tissue transglutaminase IgA antibody, and is recommended when celiac disease is suspected, particularly in children younger than 2 years of age (51). Patients with positivity on serologic testing proceed with a duodenal biopsy; however, current guidelines suggest that, if a child or adolescent with clinical symptoms suggestive of celiac disease also present with a consistent HLA haplotype, positive endomysium IgA antibodies and elevated tissue transglutaminase IgA antibodies more than 10 times the upper limit of normal, these elements are nearly 100% predictive of celiac disease and duodenal biopsy is not indicated (44,48). However, histologic analysis of duodenal biopsy, while the patient is still ingesting gluten, remains the gold standard of diagnosing celiac disease, demonstrating characteristic villous atrophy of the small bowel mucosa, crypt hyperplasia, and increased intraepithelial lymphocytes (Figure 10) (45,48,51). This degree of mucosal changes on small intestinal biopsies is categorized according to Marsh-Oberhuber classification system (Table 3) (52). Additional testing includes HLA typing, with which the absence of HLA DQ2 or HLA DQ8 indicates that the likelihood of celiac disease unlikely, making it a useful tool for the exclusion of celiac disease (45,51).

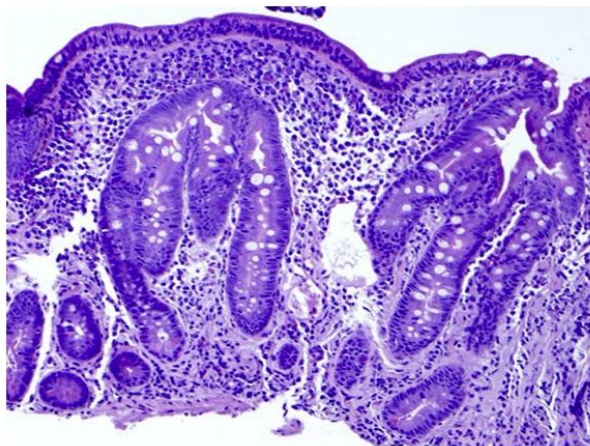


Figure 10. Characteristic histology of celiac disease: villous atrophy, crypt hyperplasia, and increased intraepithelial lymphocytes (51).

Table 3. Marsh-Oberhuber classification of celiac disease.

Grade	Description and components
0	Normal—normal appearing villus architecture
I	Infiltrative—normal mucosal and villus architecture; increased numbers of IEL
II	Hyperplastic—similar to I with enlarged crypts and increased crypt cell division
IIIa	Partial villus atrophy—shortened, blunt villi; mild lymphocyte infiltration, enlarged hyperplastic crypts
IIIb	Subtotal villus atrophy—clearly atrophic villi, enlarged crypts whose immature epithelial cells are generated at an increased rate, influx of inflammatory cells
IIIc	Hypoplastic—total villus atrophy, complete loss of villi, severe crypt hyperplasia, infiltrative inflammatory lesion

The only available treatment for celiac disease is the long-term strict adherence to a gluten-free diet (44,45). This results in the resolution of both intestinal and extraintestinal manifestations, serologic testing of autoantibodies to become negative, as well as regrowth of the intestinal villi (49). Follow-up biopsies are not performed in children after initiation of a gluten-free diet, as the clinical and serological response is an adequate representation of therapeutic benefit (45).

1.5. Infectious disease – *Helicobacter pylori*-positive gastritis

One of the most predominant human pathogens is *Helicobacter pylori*, a gram-negative, spiral, microaerophilic bacterium, with prevalence of 40% in developed countries and 80% in developing countries. It is an important cause of peptic ulcer disease and chronic gastritis, especially in children, with the infection mainly acquired in childhood and, unless appropriately treated, persisting throughout life (53,54). In the Western world, however, the prevalence of *H. pylori* infection is decreasing among both children and adults, whereas low socioeconomic status and poor living conditions in developing countries cause infection rates of *H. pylori* to remain high (53–55). Breastfeeding seems to be protective against *H. pylori* infection, whereas reduced diversity of the gut microbiota is a risk factor (56).

In adults, gastrointestinal manifestations such as abdominal pain and upper gastrointestinal bleeding are very often associated with gastro-duodenal ulcers due to *H. pylori* infection; however, digestive symptoms due to *H. pylori* are relatively non-specific in children. Recurrent abdominal pain in children has been speculated to be associated with *H. pylori* infection; this association, though, is still controversial (53,54). Still, the development of gastritis and peptic ulcer disease is mainly due to infection with *H. pylori* (53). In children, the prevalence of *H. pylori* infection is high in antral gastritis, and is higher in duodenal ulcers than gastric ulcers, demonstrating a strong association between ulcers and *H. pylori* infection (53,55). Extraintestinal manifestations also accompany *H. pylori* infection, most commonly iron deficiency and subsequent anemia, as children infected with *H. pylori* have been shown to have lower serum hemoglobin levels and lower ferritin compared to non-infected children (53,54). Additionally, *H. pylori* infection in childhood may result in a decline in linear growth and even short stature, often as a result of reduced appetite with concomitant infection, leading to a decrease in immunity and recurrent infections (53).

Although the symptoms of *H. pylori* infection are non-specific, children with manifestations of an upper gastrointestinal condition should undergo endoscopic evaluation of the upper gastrointestinal tract (54). A classical finding on endoscopy in children with *H. pylori* infection is nodular gastritis, seen in up to 67% of infected children compared to 10% of infected adults (57). The gold standard, however, for diagnosis includes either a positive tissue culture, which has 100% specificity, or pathohistological visualization of *H. pylori* infection in combination with a positive rapid urease test or detection of *H. pylori* with polymerase chain reaction (53–55). Pathohistological findings of multiple gastric biopsies include chronic inflammatory infiltrate of lymphocytes and plasma cells in children, whereas in adults, active inflammatory infiltrate of neutrophils is more prominent (54,57). Non-invasive tests, including rapid urease test and stool antigen test, are not recommended for the sole purpose of diagnosis of infection in children, although they are useful to evaluate the outcome of *H. pylori* eradication therapy (54,55). The immunological response to *H. pylori* produces antibodies which can be detected with serological testing; however, the rate of false-positive results is high, particularly in children (53). Antibody titres also remain high several weeks after eradication of *H. pylori*, and therefore current guidelines state that serologic tests are unreliable in children of any age group (53,55,57).

Treatment of *H. pylori* infection consists of a proton pump inhibitor in combination with two antibiotics, typically amoxicillin with clarithromycin or metronidazole, for two weeks (54,55). Antimicrobial susceptibility testing should be performed prior to

administration of eradication therapy, as *H. pylori* has an increasing rate of antimicrobial resistance, and therapy should be adjusted accordingly (54,55).

2. OBJECTIVES

2.1. Objectives

The aim of this study is firstly, to investigate and determine the frequency of gastrointestinal biopsies performed at the department of Pediatrics at the University Hospital of Split that were sent for pathohistological analysis to the department of Pathology, Forensic Medicine and Cytology, University Hospital of Split, during a three-year time period, from 2017 to 2019. From this, we aimed to determine the most common clinical diagnosis indicated for biopsy that accompanied the tissue sample. Further, we intended to determine the most common final diagnosis based on pathohistological findings of the biopsy tissue. The average age of diagnosis of pediatric gastrointestinal disorders, as well as whether there was a difference in the frequency of particular diagnoses based on patient gender, were additional investigations.

2.2. Hypotheses

According to previous studies, we hypothesize the most common final diagnosis in pediatric patients, based on pathohistological analysis, to be celiac disease and/or inflammatory bowel disease. In regards to a diagnosis of celiac disease, and because of its autoimmune nature, we anticipate a female predominance. Considering IBD, we presume a male predominance or no significant difference in gender. We predict UC to occur more frequently in children younger than the age of 6 years, and CD to be more frequent in children older than 6 years; however, considering gastrointestinal disorders overall, we predict an average age of diagnosis to be between the ages of 10 and 15 years.

3. SUBJECTS AND METHODS

3.1. Patients

Pathohistological reports of 336 pediatric patients, who underwent gastrointestinal endoscopy with subsequent obtaining of tissue biopsy at the department of Pediatrics of University Hospital of Split, from the first of January 2017 to the thirty-first of December 2019, were retrospectively reviewed. Patients included in the study were all pediatric patients aged up to 18 years, who underwent gastroscopy, colonoscopy, or both, with subsequent tissue biopsy within this three-year time period. Patients excluded were those older than 18 years, as well as those who underwent gastrointestinal endoscopy without subsequent tissue biopsy.

3.2. Organization of the study

The research was conducted as a retrospective study.

3.3. Place of the study

Collection of medical records of pediatric patients took place at the department of Pediatrics of University Hospital of Split, whereas pathohistological reports of tissue biopsies were obtained from the department of Pathology, Forensic Medicine and Cytology of University Hospital of Split.

3.4. Methods of data collection and processing

Data obtained from the archives at the department of Pediatrics and the department of Pathology, Forensic Medicine and Cytology was documented and organized into tables for further analysis using Microsoft Word Processing software and Microsoft Excel. All research and data collection were performed in accordance to the Helsinki Declaration.

3.5. Description of research

Upon collection of medical records and pathohistological reports from the department of Pediatrics and the department of Pathology, Forensic Medicine and Cytology, data that was obtained for further analysis included patient date of birth, gender, clinical diagnosis, type of gastrointestinal endoscopy performed, the number and type of tissue samples obtained by biopsy, and final diagnosis based on histopathological report.

The primary outcome to be achieved from this study was to determine the frequency of gastrointestinal endoscopies with subsequent tissue biopsy performed at the department of Pediatrics at University Hospital of Split during a three-year time period, from the year 2017 to 2019. Secondary outcomes included the most common clinical diagnosis indicating the need for gastrointestinal endoscopy and tissue biopsy, as well as the most common final diagnosis based on results of pathohistological findings. Additional secondary outcomes were average age of diagnosis, as well as differences in the frequency in diagnoses based on gender.

3.6. Statistical analysis

Statistical analysis of collected data was performed using MedCalc Software (MedCalc Software, Mariakerke, Belgium). The data distribution was assessed using the Kolmogorov-Smirnov test. From this, statistical significance was evaluated using the t-test and the Mann-Whitney test. The chi-square test was also used to interpret the statistical significance of the sampling distribution. The statistical significance value was set at $P < 0.05$.

4. RESULTS

Included in this study were 336 pathohistological reports of pediatric patients collected from the time period 01.01.2017 until 31.12.2019. Of these pediatric patients, 155 (46.1%) were boys and 181 (53.9%) were girls. The average age of these patients was 11 years old (Table 4).

Table 4. Age of patient according to gender and year of sample collection.

Year	Boys	Girls
2017.	N=31	N=54
Age (years)	14 (2-18)	13 (3-18)
2018.	N=66	N=68
Age (years)	10 (1-18)	13 (2-18)
2019.	N=58	N=59
Age (years)	13 (0-18)	15 (3-18)

N=number of patients; Age is presented as the median among minimum and maximum value

In the studied period, the following endoscopic procedures of the gastrointestinal tract were performed: 281 gastroscopies (83.6%), 48 colonoscopies (14.3%), and 7 combined gastroscopy and colonoscopy (2.1%) performed in the same act. With this, the most commonly performed procedure was gastroscopy, and the least common was combined gastroscopy and colonoscopy, which is statistically significant ($P < 0.0001$) (Figure 11).

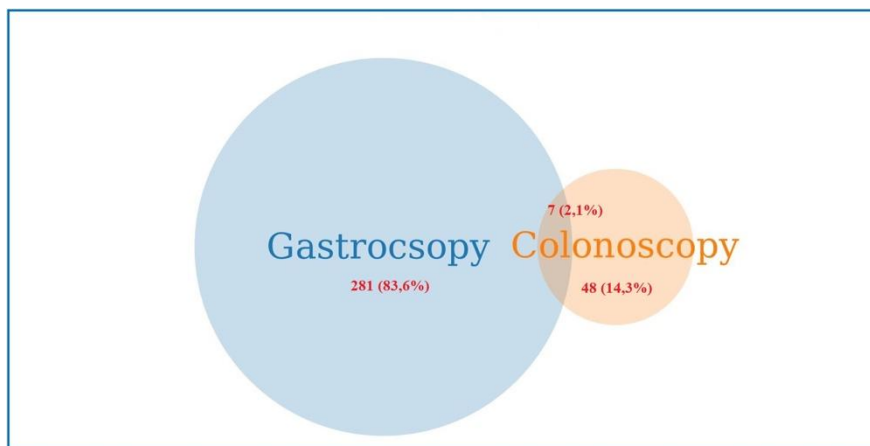


Figure 11. Performed endoscopic procedures of gastrointestinal tract.

During gastroscopy and colonoscopy, one sample of tissue was most commonly collected for pathohistological analysis, whereas the greatest number of tissue samples were collected during simultaneous gastroscopy and colonoscopy, which is statistically significant ($P<0.0001$). The number of samples collected according to type of diagnostic procedure is presented in Table 5.

Table 5. Number of samples according to type of procedure.

Number of samples (N)	Gastroscopy	Colonoscopy	Gastroscopy with colonoscopy
1	187	17	0
2	85	16	1
3	3	8	1
4	0	4	4
5	1	2	0
8	0	0	1
Several tissue samples	5	1	0

The most commonly referred, clinical diagnoses with which material was received for pathohistological analysis were abdominal colic (17.3%) and category “other” (17.6%), which included vomiting, abdominal distention, gastric ulcer and polyp, melena, chronic obstipation, anal bleeding and others, whereas the least common referred diagnoses were chronic gastritis and duodenitis (0.3%), which is statistically significant ($P<0.0001$) (Table 6). 27 samples were collected without a referred diagnosis or clinical data. More than one referred diagnosis accompanied 18 samples, most often being the combination abdominal colic and gastroesophageal reflux disease, as well as gastritis and duodenitis.

Table 6. Referred diagnosis by which sample material was received for pathohistological diagnosis.

Referred diagnosis	N(%)	<i>P</i>
Intestinal malabsorption	47 (14%)	
Abdominal colic	58 (17.3%)	
Dyspepsia	17 (5.1%)	
GERD	18 (5.4%)	
Gluten enteropathy	21 (6.2%)	
Gastropathy	15 (4.5%)	
Ulcerative colitis	7 (2.1%)	<i>P</i> <0.0001*
Gastritis	17 (5.1%)	
Chronic gastritis	1 (0.3%)	
Acute gastritis	3 (0.9%)	
Crohn's disease	17 (5.1%)	
Duodenitis	1 (0.3%)	
IBD	3 (0.9%)	
Other	59 (17.6%)	
Diagnosis unrelated to GI tract	7 (2.1%)	
Without referred diagnosis	27 (8.0%)	
Multiple referred diagnosis	18 (5.4%)	

* χ^2 test; GERD= gastroesophageal reflux disease; IBD= inflammatory bowel disease

The most common final pathohistological result was descriptive (54.5%), whereas the diagnosis of chronic pancolitis appeared only twice, which was statistically significant ($p < 0.0001$) (Figure 12).

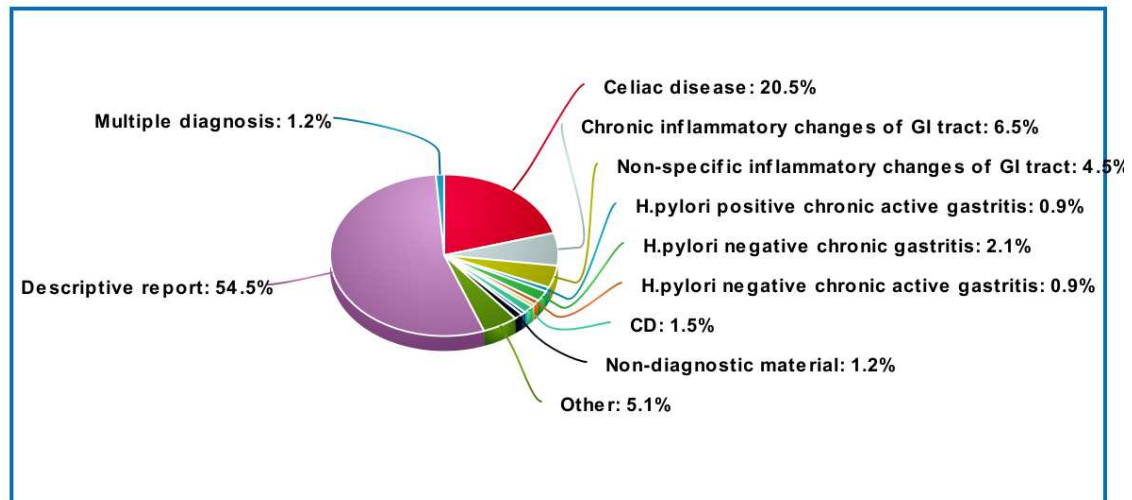


Figure 12. Final diagnoses based on histopathological reports.

Pathology report based on gender is presented in Figure 13. There was no statistical significance in the pathology report between male and female patients ($p = 0.187$).

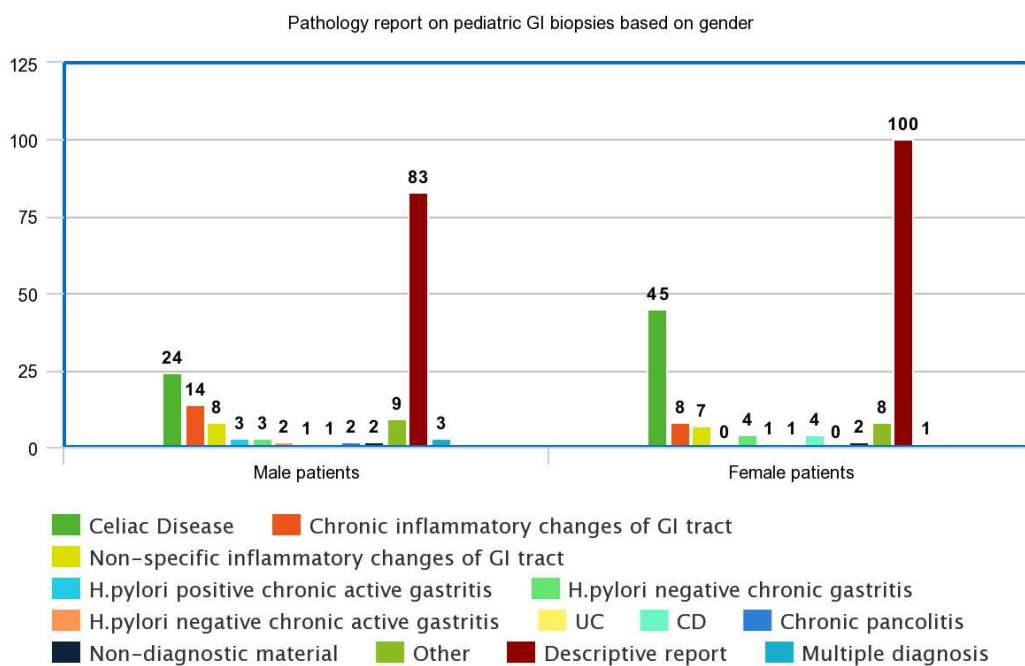


Figure 13. Pathology report based on gender.

Samples received with a clinical diagnosis of celiac disease were classified according to the modified Marsh-Oberhuber classification for celiac disease. The most common classification of the received samples was Marsh 0, whereas Marsh 2 was the least frequent classification, which was statistically significant ($p < 0.0001$) (Table 7).

Table 7. Modified Marsh-Oberhuber classifications of GI samples received with clinical diagnosis of celiac disease.

Modified Marsh-Oberhuber classifications	N (%)	<i>P</i>
Marsh 0	81(52.6%)	
Marsh 1	29 (18.8%)	
Marsh 2	5 (3.2%)	
Marsh 3A	10 (6.5%)	
Marsh 3B	21 (13.6%)	<0.0001*
Marsh 3C	8 (5.2%)	

* χ^2 test

5. DISCUSSION

Gastrointestinal complaints are not uncommon amongst the pediatric population, with many adult-onset gastrointestinal diagnoses, such as ulcerative colitis and Crohn's disease, becoming increasingly prevalent at a younger age (15). In addition to IBD, disorders of malabsorption, particularly celiac disease, has a high prevalence in children, especially in females, relating to its autoimmune nature (41,43). Infections with *H. pylori* are predominantly acquired in childhood, being a common cause of chronic gastritis in pediatric patients; however, the incidence of these infections are decreasing in the Western world, remaining largely prevalent in developing countries (50,51).

Our study investigated epidemiological and pathohistological characteristics of gastrointestinal biopsies among pediatric patients at the University Hospital of Split within a three-year time period, from 2017 until 2019. In this time period, 336 pathohistological analyses were reported, with an average patient age of 11 years. In each year of sample collection, a higher number of females underwent gastrointestinal biopsy and subsequent pathohistological analyses of biopsy material, comprising 53.9% of the total pediatric patients investigated, with 46.1% of the patients being boys. Clinical diagnoses in which patients were referred for gastrointestinal endoscopic procedures were most commonly abdominal colic, accounting for 17.3% of the referrals, as well as clinical symptoms categorized as "other," which included manifestations such as vomiting, abdominal distention, gastric ulcer or polyp, melena, and others, comprising 17.6% of the clinical diagnoses. Based on these clinical referrals, it is expected that gastroscopy is the more commonly performed procedure, which corresponds with our results, as 281 gastroscopies were performed, accounting for 83.6% of the endoscopic procedures performed. Only 7 simultaneous gastroscopies and colonoscopies were performed; however, it was during these combined procedures where the highest number of tissue samples were collected for pathohistological analysis; otherwise, most commonly only one tissue sample was collected during the individual procedures.

The final pathohistological result was most commonly presented as a descriptive report, comprising 54.5% of the final diagnoses. With regards to particular diagnoses, celiac disease was most prevalent, reported in 20.5% of patients. Although there was no statistical significance in the final pathohistological report between male and female patients, there was almost twice as many female patients with celiac disease than male patients, as anticipated based on previous studies (47). The samples diagnosed as celiac disease based on pathohistological analysis were further classified according to the modified Marsh-Oberhuber classification for celiac disease. According to this classification system, Marsh 0 was most commonly reported among the investigated pediatric patients, comprising 52.6% of celiac

patients, with Marsh 1 appearing in 18.8% of cases. Histological findings of intestinal mucosa corresponding to Marsh 0 and Marsh 1 are relatively non-specific, and are therefore suggestive but not unique to celiac disease (41, 46). These histological features may also be found in patients with non-steroid anti-inflammatory drug use, cow's milk or soy protein allergies, Crohn's disease, and infections including *H. pylori* and parasitic gastritis, stressing the importance of incorporating clinical features, serological marker evaluation, and dietary exposure to gluten with pathohistological findings on intestinal biopsy for the diagnosis of celiac disease (41, 46).

Inflammatory bowel disease was an uncommon finding amongst this pediatric population, accounting for only 2.1% of patients within the three-year time period. According to previous studies, patients diagnosed with IBD in the pediatric age group present with a more extensive disease (17, 24); however, chronic pancolitis was diagnosed in only two patients, demonstrating a low prevalence in this pediatric population. However, the sample population of our study over a three-year period is relatively small, as the city of Split and its neighbouring counties do not have a vast population, therefore limiting our study.

The retrospective nature of our study is one of its major limitations, as medical records are prone to bias. As our study investigated a pediatric population, the accuracy of symptoms stated by the children, especially depending on their age, is questionable, which may influence the clinical diagnosis and indication for gastrointestinal endoscopy to be performed.

6. CONCLUSION

Within a three-year time period, from the first of January 2017 until the thirty-first of December 2019, our study demonstrated 336 pathohistological reports from performed gastrointestinal endoscopic procedures at the department of Pediatrics at University Hospital of Split. Females more often underwent these procedures than males. Abdominal colic was among the most frequent complaints, including others, with these clinical manifestations indicating the need for endoscopy and tissue biopsy such that gastroscopy was the most commonly performed procedure. Pathohistological analyses presented a final diagnosis most often as a descriptive report, both in males and females. With regards to specific diagnoses, celiac disease was among the most prevalent in this pediatric population, particularly in females, supporting previous findings stating its high prevalence in children.

One approach as to how diagnostic measures may be improved is the addition of a pathologist to the pediatric diagnostic team. Particularly, having a pathologist that handles solely gastrointestinal biopsies as part of the pediatric team will not only enhance the cooperation between the pediatrician and the pathologist, but will improve diagnostic results, and therefore lead to improved treatment practices for better patient care and long-term outcome.

7. REFERENCES

1. Gray H. Anatomy of the human body. 20th ed. Philadelphia: Lea & Febiger; 1918; Bartleby.com, 2000.
2. Oezcelik A, DeMeester SR. General anatomy of the esophagus. *Thorac Surg Clin*. 2011;21:289–97.
3. Gavaghan M. Anatomy and physiology of the esophagus. *AORN Journal*. 1999;69:370–86.
4. Chaudhry SR, Liman MNP, Peterson DC. Anatomy, abdomen and pelvis, stomach. In: StatPearls. Treasure Island (FL):StatPearls Publishing; 2020 [updated 2020 Apr 14; cited 2020 May 25]. Available from: <https://www.ncbi.nlm.nih.gov/books/NBK430685/>.
5. Burdan F, Rozylo-Kalinowska I, Szumilo J, Zinkiewicz K, Dworzanski W, Krupski W, et al. Anatomical classification of the shape and topography of the stomach. *Surg Radiol Anat*. 2012;34:171–8.
6. Ellis H. Anatomy of the stomach. *Surgery*. 2011;29:541–3.
7. Soybel DI. Anatomy and physiology of the stomach. *Surg Clin North Am*. 2005;85:875–94.
8. Leonard RJ. The abdomen. In: Leonard RJ. *Human Gross Anatomy*. New York: Oxford University Press, Inc.; 2003. p. 92-5.
9. Volk N, Lacy B. Anatomy and physiology of the small bowel. *Gastrointest Endosc Clin N Am*. 2017;27:1–13.
10. Collins JT, Badireddy M. Anatomy, abdomen and pelvis, small intestine. In: StatPearls. Treasure Island (FL):StatPearls Publishing; 2020 [updated 2020 May 17; cited 2020 May 25]. Available from: <https://ncbi.nlm.nih.gov/books/NBK459366/>.
11. Lopez PP, Gogna S, Khorasani-Zadeh A. Anatomy, abdomen and pelvis, duodenum. In: StatPearls. Treasure Island(FL):StatPearls Publishing; 2020 [updated 2019 Jun 28; cited 2020 May 25]. Available from: <https://ncbi.nlm.nih.gov/books/NBK482390>.
12. Bass LM, Wershil BK. Anatomy, histology, embryology, and developmental anomalies of the small and large intestine. In: Sleisenger MH, Feldman M, Friedman LS, Brandt LJ. *Sleisenger and Fordtran’s Gastrointestinal and Liver Disease*. Philadelphia: Saunders/Elsevier; 2015. p. 1649-78.e3.
13. Kahai P, Mandiga P, Wehrle C et al. Anatomy, abdomen and pelvis, large intestine. In: StatPearls. Treasure Island(FL):StatPearls Publishing; 2020 [updated 2020 May 23; cited 2020 May 25]. Available from: <https://ncbi.nlm.nih.gov/books/NBK470577/>.

14. Owen DA. Normal histology of the stomach. *American Journal of Surgical Pathology*. 1986;10:48–61.
15. Abuquteish D, Putra J. Upper gastrointestinal tract involvement of pediatric inflammatory bowel disease: A pathological review. *World J Gastroenterol*. 2019;25:1928–35.
16. Chauhan N, Khan HH, Kumar S, Lyons H. Clinical variables as predictors of first relapse in pediatric Crohn's disease. *Cureus*. 2019;11:4980.
17. Sairenji T, Collins KL, Evans D V. An update on inflammatory bowel disease. *Prim Care - Clin Off Pract*. 2017;44:673–92.
18. Yu YR, Rodriguez JR. Clinical presentation of Crohn's, ulcerative colitis, and indeterminate colitis: Symptoms, extraintestinal manifestations, and disease phenotypes. *Semin Pediatr Surg*. 2017;26:349–55.
19. Fuller MK. Pediatric inflammatory bowel disease: Special considerations. *Surg Clin North Am*. 2019;99:1177–83.
20. Laass MW, Roggenbuck D, Conrad K. Diagnosis and classification of Crohn's disease. *Autoimmun Rev*. 2014;13:467–71.
21. Von Allmen D. Pediatric Crohn's disease. *Clin Colon Rectal Surg*. 2018;31:80-8.
22. Wilson DC, Russell RK. Overview of paediatric IBD. *Semin Pediatr Surg*. 2017;26:344–8.
23. Da Silva BC, Lyra AC, Rocha R, Santana GO. Epidemiology, demographic characteristics and prognostic predictors of ulcerative colitis. *World J Gastroenterol*. 2014;20:9458–67.
24. Levine A, Griffiths A, Markowitz J, Wilson DC, Turner D, Russell RK, et al. Pediatric modification of the Montreal classification for inflammatory bowel disease: The Paris classification. *Inflamm Bowel Dis*. 2011;17:1314–21.
25. Zimmerman L, Bousvaros A. The pharmacotherapeutic management of pediatric Crohn's disease. *Expert Opin Pharmacother*. 2019;20:2161–8.
26. Regan BP, Bousvaros A. Pediatric ulcerative colitis: A practical guide to management. *Pediatr Drugs*. 2014;16:189–98.
27. Flood E, Silberg DG, Romero B, Beusterien K, Erder MH, Cuffari C. Development of the pediatric daily ulcerative colitis signs and symptoms scale (DUCS): Qualitative research findings. *BMC Res Notes*. 2017;10:1–10.
28. Conrad K, Roggenbuck D, Laass MW. Diagnosis and classification of ulcerative colitis. *Autoimmun Rev*. 2014;13:463–6.

29. Magro F, Langner C, Driessen A, Ensari A, Geboes K, Mantzaris GJ, et al. European consensus on the histopathology of inflammatory bowel disease. *J Crohn's Colitis*. 2013;7:827–51.
30. Ungaro R, Mehandru S, Allen PB, Peyrin-Biroulet L, Colombel JF. Ulcerative colitis. *Lancet*. 2017;389:1756–70.
31. Seldenrijk CA, Morson BC, Meuwissen SGM, Schipper NW, Lindeman J, Meijer CJLM. Histopathological evaluation of colonic mucosal biopsy specimens in chronic inflammatory bowel disease: Diagnostic implications. *Gut*. 1991;32:1514–20.
32. McHugh JB, Gopal P, Greenson JK. The clinical significance of focally enhanced gastritis in children. *Am J Surg Pathol*. 2013;37:295–9.
33. Ushiku T, Moran CJ, Lauwers GY. Focally enhanced gastritis in newly diagnosed pediatric inflammatory bowel disease. *Am J Surg Pathol*. 2013;37:1882–8.
34. Sharif F, McDermott M, Path MRC, Dillon M, Drumm B, Rowland M, et al. Focally enhanced gastritis in children with Crohn's disease and ulcerative colitis. *Am J Gastroenterol*. 2002;97:1415–20.
35. Oberhuber G, Puspok A, Oesterreicher C, Novacek G, Zauner C, Burghuber M, et al. Focally enhanced gastritis: A frequent type of gastritis in patients with Crohn's disease. *Gastroenterology*. 1997;112:698–706.
36. De Magalhães-Costa MH, Dos Reis BR, Chagas VLA, Nunes T, De Souza HSP, Zaltman C. Focal enhanced gastritis and macrophage microaggregates in the gastric mucosa: Potential role in the differential diagnosis between Crohn's disease and ulcerative colitis. *Arq Gastroenterol*. 2014;51:276–82.
37. Putra J, Ornvold K. Focally enhanced gastritis in children with inflammatory bowel disease: a clinicopathological correlation. *Pathology*. 2017;49:808–10.
38. Genta RM, Sonnenberg A. Non- *Helicobacter pylori* gastritis is common among paediatric patients with inflammatory bowel disease. *Aliment Pharmacol Ther*. 2012;35:1310–6.
39. Sierra D, Wood M, Kolli S, Felipez LM. Pediatric gastritis, gastropathy, and peptic ulcer disease. *Pediatr Rev*. 2018;39:542–9.
40. Elitsur Y. Helicobacter-negative gastritis: The pediatric perspective. *Am J Gastroenterol*. 2013;108:1182–3.
41. Ammourey RF, Croffie JM. Malabsorptive disorders of childhood. *Pediatr Rev*. 2010;31:407–16.

42. Pietzak MM, Thomas DW. Childhood malabsorption. *Pediatr Rev.* 2003;24:195–204.
43. Nikaki K, Gupte GL. Assessment of intestinal malabsorption. *Best Pract Res Clin Gastroenterol.* 2016;30:225–35.
44. Guandalini S, Assiri A. Celiac disease: A review. *JAMA Pediatr.* 2014;168:272–8.
45. Lindfors K, Ciacci C, Kurppa K, Lundin KEA, Makharia GK, Mearin ML, et al. Coeliac disease. *Nat Rev Dis Prim.* 2019;5. doi: 10.1038/s41572-018-0054-z.
46. Poddar U. Pediatric and adult celiac disease: Similarities and differences. *Indian J Gastroenterol.* 2013;32:283–8.
47. Ludvigsson JF, Murray JA. Epidemiology of celiac disease. *Gastroenterol Clin North Am.* 2019;48:1–18.
48. Lee GJ, Kao JY. Recent advances in pediatric celiac disease. *Expert Rev Gastroenterol Hepatol.* 2017;11:583–92.
49. Caio G, Volta U, Sapone A, Leffler DA, De Giorgio R, Catassi C, et al. Celiac disease: A comprehensive current review. *BMC Med.* 2019;17:1–20.
50. Jericho H, Guandalini S. Extra-intestinal manifestation of celiac disease in children. *Nutrients.* 2018;10. doi: 10.3390/nu10060755.
51. Hujoel IA, Reilly NR, Rubio-Tapia A. Celiac disease: Clinical features and diagnosis. *Gastroenterol Clin North Am.* 2019;48:19–37.
52. Adelman DC, Murray J, Wu TT, Mäki M, Green PH, Kelly CP. Measuring change in small intestinal histology in patients with celiac disease. *Am J Gastroenterol.* 2018;113:339–47.
53. Sabbagh P, Javanian M, Koppolu V, Vasigala VKR, Ebrahimpour S. Helicobacter pylori infection in children: An overview of diagnostic methods. *Eur J Clin Microbiol Infect Dis.* 2019;38:1035–45.
54. Kotilea K, Kalach N, Homan M, Bontems P. Helicobacter pylori infection in pediatric patients: Update on diagnosis and eradication strategies. *Pediatr Drugs.* 2018;20:337–51.
55. Mišak Z, Hojsak I, Homan M. Review: Helicobacter pylori in pediatrics. *Helicobacter.* 2019;24:1–6.
56. Kotilea K, Bontems P, Touati E. Epidemiology, diagnosis and risk factors of Helicobacter pylori infection. *Adv Exp Med Biol.* 2019;1149:17–33.
57. Kalach N, Bontems P, Raymond J. Helicobacter pylori infection in children. *Helicobacter.* 2017;22:1–7.

8. SUMMARY

Objectives: The aim of this study is to investigate the frequency of gastrointestinal biopsies performed on pediatric patients at University Hospital of Split during a three-year time period, from 2017 to 2019. From this investigation, we aimed to determine both the most common clinical and final diagnosis accompanying the biopsy tissue. Further, average age of diagnosis and differences in frequency of particular diagnoses according to patient gender were explored.

Materials and methods: A retrospective analysis was conducted on medical records of pediatric patients, up to the age of 18 years, who underwent gastrointestinal endoscopy with subsequent obtaining of tissue biopsy from the beginning of January 2017 to the end of December 2019 at the Pediatrics Department of University Hospital of Split. Data obtained from the archives of these patients included patient date of birth, gender, clinical diagnosis, type of gastrointestinal endoscopy performed, the number and type of tissue samples obtained by biopsy, and final diagnosis based on pathohistological report. Statistical analysis was performed using MedCalc.

Results: 336 pathohistological reports were collected from this three-year time period. Of these pediatric patients, 155 (46.1%) were boys and 181 (53.9%) were girls, with the average age of the patient being 11 years. 281 gastroscopies (83.6%), 48 colonoscopies (14.3%), and 7 combined gastroscopy and colonoscopy (2.1%) performed in the same act were performed, which shows statistical significance ($P < 0.0001$). The most common clinical diagnoses indicating endoscopy and pathohistological analysis were abdominal colic (17.3%) and category “other” (17.6%), with the least common clinical diagnoses being chronic gastritis and duodenitis (0.3%), which is statistically significant ($P < 0.0001$). The most common final pathohistological result was descriptive (54.5%). There was no statistical significance in the pathology report between male and female patients ($p = 0.187$).

Conclusion: During this three-year time period, pediatric patients undergoing gastrointestinal endoscopic procedures were more often females. Among the most frequent complaints were abdominal colic, as well as others, with these being indications for endoscopy and tissue biopsy, such that gastroscopy was the most commonly performed procedure. Pathohistological analyses presented a final diagnosis most often as a descriptive report.

9. CROATIAN SUMMARY

Ciljevi: Cilj ovog istraživanja je odrediti učestalost gastrointestinalnih biopsija u pedijatrijskoj populaciji u KBC Split u trogodišnjem razdoblju, od 2017 do 2019. Također, cilj je bio ustanoviti najučestalije kliničke uputne dijagnoze, te konačne patohistološke dijagnoze, i utvrditi prosječnu dob prilikom postavljanja dijagnoze, te postoje li razlike u učestalosti kliničkih i patohistoloških dijagnoza obzirom na spol pacijenata.

Materijali i metode: Istraživanje je retrospektivno i opservacijsko. Podatci su dobiveni pregledom patohistoloških nalaza Odjela Patologije, Kliničkog zavoda za patologiju, sudsku medicinu i citologiju KBC Split, i medicinske dokumentacije pedijatrijskih pacijenata Odjela Pedijatrije iste bolnice, kojima je u razdoblju od siječnja 2017. do prosinca 2019. godine uzeta biopsija tkiva prilikom endoskopske pretrage gastrointestinalnog trakta. Zabilježeni su sljedeći podaci: datum rođenja, spol, klinička dijagnoza, vrsta endoskopske pretrage, broj i vrsta uzetih uzoraka tkiva, a iz patohistoloških nalaza konačna dijagnoza i histološke karakteristike uzoraka.

Rezultati: U trogodišnjem razdoblju pregledano je 336 patohistoloških nalaza pedijatrijskih pacijenata od kojih je bilo 155 (46,1%) dječaka i 181 (53,9%) djevojčica, prosječna dob je bila 11 godina. Učinjena je 281 gastroskopija (83,6%), 48 kolonoskopija (14,3%), i 7 gastroskopija i kolonoskopija u istom aktu (2,1%) što je bilo statistički značajno ($P < 0,0001$). Abdominalne kolike (17,3%) i kategorija “ostalo” (17,6%) su bile najčešće uputne kliničke dijagnoze, dok su najrjeđe uputne dijagnoze bile kronični gastritis i duodenitis (0,3%), što je bilo statistički značajno ($P < 0,0001$). Konačna patohistološka dijagnoza je najčešće bila opisna (54,5%). Nije bilo statistički značajne razlike u patohistološkoj dijagnozi obzirom na spol pacijenata ($p = 0,187$).

Zaključak: U trogodišnjem istraživanom razdoblju pedijatrijski pacijenti koji su podvrgnuti endoskopskim pretragama gastrointestinalnog trakta su češće bile djevojčice. Najčešća uputna dijagnoza i razlog upućivanja pacijenta na pretragu su bile abdominalne kolike i skupina “ostalih” dijagnoza. Gastroskopija je najučestalija pretraga, a konačni patohistološki nalaz je u većini slučajeva bio opisne prirode.

10. CURRICULUM VITAE

PERSONAL INFORMATION:

Name and surname: Jozefina Josipa Dukić

Date of birth: 22nd July 1991

Place of birth: Vancouver, Canada

Citizenship: Canadian and Croatian

Email: josipa.duk@gmail.com

EDUCATION:

October 2014 – September 2020	Doctor of Medicine - University of Split School of Medicine, Split, Croatia
September 2009 – May 2014	Bachelor of Science in Cognitive Systems - University of British Columbia, Vancouver, BC, Canada
September 2004 – June 2009 Canada	St. Thomas More Collegiate, Burnaby, BC, Canada

ACADEMIC ACHIEVEMENTS AND WORKS:

October 2019 – July 2020	Class vice-representative
October 2018 – September 2019	Class representative
October 2018	Publication in Nephrology Dialysis Transplantation Journal
July 2016 – October 2016	Research internship – Department of Anatomy, Histology and Embryology, University of Split School of Medicine, Split, Croatia
April 2016 – June 2016	Anatomy demonstrator

Languages: English, Croatian