

# Sex estimation of Croatian population based on CT scans of the craniums

---

**Radman, Carolane**

**Master's thesis / Diplomski rad**

**2020**

*Degree Grantor / Ustanova koja je dodijelila akademski / stručni stupanj:* **University of Split, School of Medicine / Sveučilište u Splitu, Medicinski fakultet**

*Permanent link / Trajna poveznica:* <https://um.nsk.hr/um:nbn:hr:171:299378>

*Rights / Prava:* [In copyright](#)/[Zaštićeno autorskim pravom.](#)

*Download date / Datum preuzimanja:* **2024-07-24**



*Repository / Repozitorij:*

[MEFST Repository](#)



**UNIVERSITY OF SPLIT  
SCHOOL OF MEDICINE**

**CAROLANE RADMAN**

**SEX ESTIMATION OF CROATIAN POPULATION BASED ON CT  
SCANS OF THE CRANIUMS**

**Diploma Thesis**

**Academic Year:**

**2019/2020**

**Mentor:**

**Assoc. Prof. Ivana Kružić, PhD, anthropologist**

**Split, July 2020**

# TABLE OF CONTENTS

1. INTRODUCTION .....	1
1.1. Similarities and Differences Between Biological and Forensic Anthropology .....	2
1.2. Development of Science.....	3
1.3. Sex Estimation of Skeletal Remains.....	6
1.3.1. Morphology .....	8
1.3.2. Osteometric Analysis.....	8
1.3.3. DNA Analysis.....	9
1.4. Biological Profile Going Wrong.....	10
1.5. Skull Sex Determination .....	10
1.5.1. Skull Morphology in Sex Assessment .....	11
1.5.2. Skull Metric Analysis in Sex Estimation .....	11
1.6. Other Researches .....	12
1.7. Forensic Significance of Researches.....	13
2. OBJECTIVES AND HYPOTHESIS .....	15
3. METHODS .....	17
3.1. Inclusion Criteria.....	18
3.2. Exclusion Criteria .....	18
3.3. Osteometric and Morphological Analysis .....	18
3.4. Statistical Analysis .....	21
4. RESULTS.....	22
5. DISCUSSION .....	29
6. CONCLUSION .....	34
7. REFERENCES .....	36
8. SUMMARY .....	41
9. CROATIAN SUMMARY .....	43
10. CURRICULUM VITAE .....	45

*I would like to express my gratitude towards my amazing mentor associate professor Ivana Kružić and my equally amazing co-mentor associate professor Željana Bašić. Without your help, this would have never been possible. It was a delight working with you on this interesting project.*

*I would also like to express my gratitude towards the Medicinski Fakultet u Splitu and all professors, assistants, and doctors that shared their knowledge with me over the past six years. A special thanks to our dear secretaries, from both English and Croatian programs, for their time, dedication, and help.*

*A grateful thank you to all my family members and friends for their support during my medical studies.*

## **List of Abbreviations**

16L - Orbital breadth of the left side

17L - Orbital Height of the left side

16R - Orbital breadth of the right side

17R - Orbital height of the right side

18 - Biorbital breadth

19 - Interorbital breadth

27 - Bimaxillary breadth

28 - Zygoorbitale breadth

2D/3D - two dimensional/three dimensional

BPNN - Back-propagation neural network

CCT - Cranial computed tomography

CT - Computed tomography

DCP - Data Collection Procedures

DFA - Discriminant function analysis

DICOM - Digital Images and Communication in Medicine

FDB - Forensic Data Bank

MDCT - Multi-detector computed tomography

MR - Magnetic resonance

MSCT - Multi-slice computed tomography

PACS - Picture Archiving and Communication System

PMCT - Post-mortem computed tomography

R - Coefficient of reliability

rTEM - Relative technical error of measurement

SPPSS - Statistical Package for the Social Sciences

TEM - Technical error of measurement

## **1. INTRODUCTION**

Forensic anthropology is a discipline that has been around for centuries with its main goal being the determination of cause of death, which can be natural, accidental, homicidal, suicidal, or unknown. It can be described as the identification of human remains that are either in a state of decomposition or that are bare bones. The first known autopsy was in the 13th century at the University of Bologna in Italy by the surgeon William of Saliceto, but the discipline's relation to the judicial system was introduced around the 16th century (1). Over the years, many definitions have been elaborated, but a complete one has yet to be fully inclusive of all the aspects of forensic anthropology. This is because forensic anthropology has evolved over the years; the professional aspect is not the same as it was 30 years ago and now also involves the study of the living, not only the dead (2). Skeletal remains can provide a lot of information regarding a human's sex, age at the time of death, race, height, possible evidence of the cause of death, specific individual characteristics, and even estimation of time-lapse since death, all of which constitute a biological profile that can be helpful in a criminal investigation (3).

Considering the fact that forensic anthropology relies on the collection of a large amount of data in order to evolve, the Data Collection Procedures (DCP) manual was created in 1986 as a mean to collect a centralized database of skeletal data of the modern population, called the Forensic Data Bank (FDB). It allows forensic anthropologists to derive standards for determination of age, sex, ancestry, and stature of unknown human remains worldwide and, as of 2016, contained more than 4000 cases (4).

### **1.1. Similarities and Differences Between Biological and Forensic Anthropology**

Anthropology is concerned with the study of the human being, involving all aspects of human life, which is separated into four branches: cultural anthropology, archeology, linguistic archeology, and physical (also called biological) anthropology. The physical/biological branch is the study of all aspects of biological evolution and variation in the human being, its life, and its relatives, which is affected by both genetic and environmental conditions. It analyzes both actual body parts and its function in the process of life, thus also includes social sciences because of the involvement of biology within culture and behavior (5).

When considering forensic anthropology as being the sub-discipline of biological anthropology (i.e. forensic anthropology is the sub-discipline of biological anthropology and

forensic science), it is obvious that they have many similarities in their processes and applications as they both use genetic and empirical information to describe human specimens. Both fields also use anthropometry in their analysis of human remains, although physical anthropology apply it more to study variation and evolution in a population, whereas forensic anthropology applies it more for identification purposes (6).

The main difference between the two disciplines relates to the fact that, in general, biological anthropology deals more with older specimens, whereas forensic anthropology tends to deal with more recent ones and is involved with the medico-legal system. The association with the law introduces differences in the procedures for evidence collection and documentation in comparison to physical anthropology since remains have to be secured, protected from any possible contamination, and analyzed within a short delay and with limitations as to who is allowed to access the remains, whereas physical anthropology does not have to deal with all this (i.e. specimens can be left unattended for days amongst other specimens and be accessible to even volunteers and students). Another point to note is that forensic anthropology has a large contribution in the investigations of human rights abuses, natural disasters, and any other circumstances that involve mass casualties (ex. war fatalities). The main goal is to be able to not only identify the cause of death, but also identify the actual human being which is often helped by the availability to compare ante-mortem records like radiographies, something that physical anthropology does not have (6).

## **1.2. Development of Science**

Analysis of skeletal specimens for identification of sex, age, heritage, and general stature are the mainstay in forensic anthropology. The first step in the scientific evaluation was the examination of the bones where the measurements as well as the shape, size, and any particular details were analyzed in order to create a biological profile. As time passed, complementary sciences like chemistry, toxicology, histology, and photography came to use in forensic medicine by simplifying and increasing the accuracy of the identification process (7). With the development of science, new methods came to be employed to further help in the identification process, like facial approximation and superimposition (8). As medicine also evolved, radiographs started being considered due to the availability of ante-mortem records that could be compared to the skeletal remains, like dental, vertebral column, nasal accessory sinuses or mastoid process radiography (8). Post-mortem radiographs then started to be used as well with remains in the decomposed state where the fragility of the bone or the importance



of remaining tissue made it more appropriate to use imaging techniques in order to visualize the hidden structural bones to help in the identification process instead of having to remove any remaining tissue. However, this radiographic method of identification can be highly subjective, depending on the positioning of the specimens, and can be difficult to replicate at a different point and time. Therefore, another imaging technique that came to be valuable in forensic medicine was computed tomography (CT). Due to its high definition and ability to visualize more than one type of tissue, CT imaging has become the modality of choice in autopsies requiring an alternative from the original invasive autopsy. It is able to document fractures, pathologic gas collections (ex. subcutaneous emphysema, air embolism, decomposition effects, etc.), and gross internal tissue injury. The first project demonstrating the use of imaging techniques is "virtopsy" (virtual autopsy) as explained by Dirnhofer *et al.* and corresponds to all autopsies documented, analyzed and processed with the use of CT and MR imaging techniques which is of major scientific significance as it provides a non-invasive, objective and investigator independent way for forensic investigations (9).

With the arrival of modern imaging techniques based on cross-sections of the body, forensic medicine is again able to define itself at a new level. With the help of magnetic resonance (MR) imaging and multi-detector computed tomography (MDCT), post-mortem examinations are more easily shared amongst forensic anthropologists (9,10). Forensic institutes all over the world have now been using computed tomography (CT) systems (11). The Institute of Forensic Medicine of the University of Lausanne is even currently working on an "anthropological database" in order to compile data from cadavers examined via CT scans. The data will be visualized as "virtual skeletons" linked with their biological profiles (sex, age, illnesses, etc.) to facilitate further anthropological studies (10).

Forensic anthropology is always evolving because it is constantly faced with new issues from new casework. One aspect that helped in the advancement of the field was the use of molecular analysis. The use of DNA provides a very accurate method of identification (12). Although undeniably useful, DNA analysis is a comparative process and thus, not only depends on the integrity, type, and amount collected from a specimen, but also on the possibility to actually compare the DNA retrieved from the remains to the DNA from a suspect or probable victim. Molecular analysis is also a quite expensive procedure and requires some level of destruction of the specimen, which must be taken into account during the legal procedure (7).

Many researches attempt to explore different options to help in the identification process. Some of them include decomposition research, bone microscopy, isotope analysis (can help determine specific diet types and geographic area), and facial imaging. Decomposition researches lead to the discovery of many factors that affect tissue decomposition and alteration; those factors include temperature, location (mountain, ground, surface; i.e. changes in air composition and humidity), soil conditions, moisture, body composition and condition, presence of clothing, funerary treatment, etc. Bone microscopy is done by involving the examination of osteons, whether primary, secondary, or fragmented, and the amount of circumferential lamellar bone present. Facial imaging can help approximate certain facial features in order to sketch or estimate the physical appearance and is usually used to show the public in the hope of finding new leads in a missing person case. Craniofacial photography superimposition involves the comparison between a photograph and an unidentified skull (12).

It is often impossible to accurately determine the biological profile of a specimen based solely on one method or indicator, thus multiple ones should be used when applicable in order to increase the accuracy of the identification process. This implies that constant research is valuable in the field of forensic anthropology. Many new methods and research focus on taphonomic impact, different areas of the skeleton with possibly unique characteristics, histology, new technology, mathematical advances, etc (13).

Described by Dirkmaat *et al.* in 2008, four major developments happened in the field of forensic anthropology over the last twenty years (14). These four are the utilization of improved quantitative methods through analysis of modern comparative specimens, re-emphasis on forensic contexts, the use of forensic taphonomy in obtaining evidence, and forensic skeletal trauma analysis (2,14).

New challenges encountered in forensic anthropology is the current global propagation of ethnicities around the world, especially undocumented ones (12). This can be problematic in the event of a mass disaster or mass murders where many remains have to be identified, separated, and categorized from one another. However, with new researches, more and more documentation of population variation can be used to differentiate between specimens.

As previously mentioned, forensic anthropology is constantly evolving. One of its newest addition is its use in age estimation of living human beings. Basically, with the

knowledge of human variation, growth, and anatomy of the human body, it is possible for forensic anthropologists to estimate the age, gait and stature of a human being based on 3D imagery (2). It is often used in cases related to child pornography, illegal migration, age progression of missing persons (possibility to age a photograph of a missing person in order to increase the chances of recognition many years later), etc (13). However, a certain aspect to take into consideration is the resolution of the photograph, video, or radiograph being analyzed (2). Depending on the light or angle, there can be a certain level of distortion that can lead to inaccurate identification or comparison. Since it involves the observation of living human beings, mostly underage, legal, jurisdictional, professional, and ethical aspects must be taken into account before using any photograph or video as evidence in a criminal case.

With databases like the Forensic Data Bank (FDB) and manuals for standardized identification like the Data Collection Procedures (DCP) manual, the accumulation of osteometric reference samples increases regularly and allows forensic experts to obtain information and pursue specific researches in a more efficient way (4).

Yang *et al.* research study is an example of research done specifically to improve forensic anthropology analysis of skeletal remains. It implicates the use of a back-propagation neural network (BPNN) to have computer software measuring skull features as input and sex classification as output, thus analyzing the sample to approximate a function relationship between the input and output resulting in sex classification. This type of method is very helpful since no professional qualification is needed, there is a complete approximation of the complex non-linear relationship of skull data, and there is a high recognition rate (15).

### **1.3. Sex Estimation of Skeletal Remains**

Before explaining how examination and analysis of skeletal remains can provide sex determination, it is important to understand the difference between sex and gender. Gender represents the social identity of a human being, whereas sex represents the biological identity and is thus one of the traits in biological profiling. Sex is therefore determined through the analysis of the skeleton, whereas the gender could be determined by forensic anthropologists based on the artifacts (objects representing culture) and context of where the remains were found (16).

Sex determination of skeletal remains is extremely important in forensic anthropology and is the first biological characteristic determined since sex is closely associated with other

characteristics like age, height, and weight (17). The skeletal morphology of males and females is the basis of sex estimation and they differ from one another in shapes and sizes, which is called sexual dimorphism. It is done by using both morphological and metric analysis of the bones. In general, males have bigger and more defined attachment muscle sites, whereas females have a generally smaller skeleton with specific traits in certain bones due to specific physiology (ex. wider pelvic due to childbirth) (2).

During fetal development, hormones are released which causes sexual dimorphic properties on the skeletons. This means that distinguishing sex characteristics of bones is very minimal before puberty and thus adults and children cannot be evaluated with the same methods and scales/scoring systems. It is actually not possible in infants and children to determine sex accurately based on remains due to the lack of significant bone sexual dimorphisms (17).

Bones that have a higher morphological complexity and unique features have a better discriminatory value when it comes to sex determination or any other biological characteristics. The human body usually consists of 206 bones and most have the potential to help in sex identification, however some have a higher morphological complexity (ex. the pelvis, frontal sinuses, dentition, etc.). On the other hand, some bones have a complex morphology but, in remains where tissue is still present and not up for maceration, the radiographic process loses details that could be useful. This type of situation can happen in remains where the vertebral column has to be examined without the removal of any tissue. Indeed, the vertebral column has a high morphological complexity, but, since it is viewed in an A-P (anterior-posterior) chest radiograph, there is a decrease in the ability to observe it because it is visualized through the thoracoabdominal organs, sternum, and anterior ribs (8).

Usually, the most accurate morphological bone in the human body for sex estimation is the pelvis, mainly due to the child-bearing properties in females as mentioned earlier, but also because of the common pattern of sexual dimorphism amongst the whole human race (7). The cranium is considered one of the most variable and less accurate from all the bones used, although some traits are very unique and useful during sex assessment.

It is important to remember that variations in standard morphology of bones for sex estimation exist in different populations. For example, some populations may have generally more robust, larger and heavier individuals regardless of their sex and others can have the complete opposite situation (16).

### **1.3.1. Morphology**

The two main bones with the most sexually dimorphic morphology are the skull and the pelvis and thus, when available, have the utmost importance in sex determination (18).

Morphological assessment tends to be subjective since it analyzes the shape or trait of a bone and can thus be interpreted differently by different observers. Although some bones like the pelvic bone tend to appear more obviously as male or female, other bones or a degraded or fragmented pelvis would be less defined in its morphological appearance (2).

It is important to note that hormonal changes in post-menopausal females can change the sexual dimorphic properties of the bone as the lack of estrogen tend to cause the development of a more masculine morphology, mainly affecting the cranium (18). The pubic bone can show a range of variation leading from a typical male appearance to a typical female appearance, which is determined by the increase in the length of the pubic bone in relation to the overall robusticity, a shift from a ventral arc to a ridge running through the pubic symphysis, and a thinning of the inferior pubic ramus. Another bone that can show sexual dimorphic property is the mandible; its profile varies in size, robusticity, and shape depending on the sex, being "classic" male or "classic" female.

### **1.3.2. Osteometric Analysis**

Metric analysis is more objective than morphology since it uses measurements between landmarks and thus the chance of inter-observer variability is decreased (if the landmarks are correctly identified). Many landmarks are present on each bone and, depending on the bone, can help in the determination of sex when morphological characteristics are too ambiguous or when the bones are fragmented. Metric analysis includes a variety of statistical approaches using single or multiple measurements to classify remains as male or female (19). In general, the accuracy is higher when using more than one measurement variable per bone which will maximize sex estimation and is available as discriminant function statistics. Other methods are logistic regression and neural networking, although the latter is less commonly used since it still requires some inquiring regarding its efficacy and accuracy (2).

The pelvic bone is readily apparent as female or male due to its high sexual dimorphism, but metric analysis can also be used in cases where the morphology is uncertain or when confirmation of the sex is required. Many parts of the pelvis can be examined and

each part has its own sections that differ from person to person based on age, erosion (from illness, trauma, decomposition, etc.), and even sex. When examining the sacral portion of the pelvis, it is important to note the number of segments and to disregard the coccyx (4).

In regards to the skull, cranial sutures are most often used for age (obliteration) and the landmarks for measurement of sex and population affinity. There is a total of 26 cranial landmarks that were selected for examination purposes, usually used for skeletal measurements that can then be compared within and in between populations in metric analysis (4).

Other bones that use specific landmarks for measurements in aid of sex determination and, most often, age assessment are the long bones and what are called the postcranial bones. Postcranial bones are bones below the cranium, but does not include the vertebral column nor long bones. When recording postcranial specimens, it is important to indicate whether epiphyses are present or absent (it helps determine whether the bone is from a child or an adult) (4). Postcranial and long bones include the clavicle, scapula, humerus, radius, ulna, femur, tibia, fibula, calcaneus, etc.

One of the long bone, the humerus, demonstrated potential for sex determination of the skeleton, at least in the Croatian population, with no significant disparity between the medieval and contemporary samples as presented by Bašić *et al.* (20). However, as demonstrated in the Bašić study, the humerus is not the best long bone for sex assessment; it is actually the femur and tibia (21). This study also displayed the fact that not all standard skeletal measurements reflected significant sexual dimorphism, which enforces the idea that more than one bone and more than one measurement needs to be taken into account in the analysis of human remains (21).

### **1.3.3. DNA Analysis**

DNA analysis is considered the gold standard and most precise method to determine the sex of skeletal specimens, but the procedure is very expensive, time-consuming and dependent on the preservation of the bones, the amount of DNA obtained during extraction, and possible inhibitors interfering with the analysis (19). Sex identification using DNA is simply done by analyzing the sex chromosomes X and Y; Y chromosome being most often used since it contains unique genes particular for male identification (2).

Many DNA analysis methods have been developed over the years with uses in many different fields for data collection and information. Considering the fact that DNA can be extracted from human bones even post-mortem (if specimen samples are not degraded passed a certain level), DNA analysis in forensic anthropology can procure important information for identification in more than one way. It can be utilized for determination of a specimens' sex, possible affiliation with cancer genes, comparison of the DNA with the DNA of family members in cases of missing person, determination of ethnicity, and even actual identification of the victim when DNA samples were collected before death (3).

#### **1.4. Biological Profile Going Wrong**

Since sex is closely associated with other biological characteristics like age, height and weight (17), its inaccurate estimation can lead to a completely wrong biological profile. This leads to the wrongful identification of remains and thus the inability to link it to a legal case or a missing person. A situation where this is particularly important is in casualties of mass disasters since just the sheer destruction and amount of remains already make it extremely difficult to correctly identify all specimens. In that regard, misinterpreting the age can also lead to misidentification. When a large scale disaster occurs and causes multiple deaths, it is important to be careful when assessing the remains, both for the legal process and the emotional aspect to help families in their grievances.

#### **1.5. Skull Sex Determination**

Human skulls are essential for sex determination which is based on both morphological and metric analysis. A limitation is due to subjectivity since the shape, size and measurement of anatomical landmarks depend on the opinion and experience of the forensic expert analyzing the skull and thus can differ from another expert. Another limitation is the variation in shape and size of the skull, not only between populations, but within a population itself seeing as the skull differs from individuals to individuals (22).

With the skull being one of the most sexually dimorphic body parts, it is often hard to have a high level of accuracy for sex estimation when it is not present (23). Acsàsi and Nemeskéri (24) and Buikstra and Ubelaker (25) scored and diagramed the nuchal crest, orbit, glabella, mastoid process and mandible of the skull as well as its overall appearance in sexual dimorphism (17).

Limitations of morphology and metric analysis comprise the subjective interpretation of the observer, the inter-observer variability, and the inaccurate and incomplete landmarks (22).

### **1.5.1. Skull Morphology in Sex Assessment**

The morphology of the skull is based on the visual examination of regions of the cranium. Male and female skulls differ in many parts, i.e. the glabella, mastoid, nuchal crest, orbital eminence, etc (22).

The general appearance of human skulls show visible differences when comparing the sex. The female skull is usually smooth and gracile because it retains some pre-pubertal traits into adulthood, whereas the male skull has a more robust quality with larger muscle attachment, brow ridges that are more pronounced, squarer lower jaw, etc. (3).

There are five main anatomical sites on the skull that can help in the assessment of sexually dimorphic characteristics (25). These sites have specific traits which include: "the robusticity of the nuchal crest, size of the mastoid process, sharpness of the supra-orbital margin, prominence of the glabella, and projection of the mental eminence" (22).

The glabella and mastoid process were reported many times as being the most accurate for discrimination of sex. In general, the male glabella has a larger projection, wider surface, and greater volume than the female glabella (17).

Other structures of the cranium also demonstrate specific traits that help in the analysis of sex determination, like the frontal and parietal eminences which are of smaller size in males and of larger size in females, the forehead which is steeper and less rounded in males and rounded, full, and infantile in females, etc. Another trait is the cranial capacity which tends to be around 200 cc more in males than in females and the cranial index about two to three times greater since the male skull is generally large, whereas the female one is generally small (2).

### **1.5.2. Skull Metric Analysis in Sex Estimation**

The metric analysis for sex estimation of the cranium relies on the linear or geometrical measurements of anatomical landmarks and other structures (22). Different literature and researches use different measurements in their analysis of bones, which



demonstrates all the possible characteristics that can be used on the human skeleton for biological profiling purposes. For example, Franklin *et al.* used eight measurements in their studies and obtained a high level of sexual dimorphism with the facial width (bizygomatic breadth) as well as the height and length of the cranial vault, whereas Bigoni *et al.* used seven sub-regions and 82 landmarks; the configuration of the neuro-cranium, cranial base, mid-sagittal curve of vault, upper face, orbital region, nasal region, and palatal region of the skull (26,27).

As previously mentioned, 26 cranial landmarks were selected in the Data Collection Procedures (DCP) manual. Although not all of them are significant or specific for sex determination, it is still important to know them. Cranial measurements are calculated from one specific landmark to another and help in the examination of the size and volume of the cranium. A total of 28 cranial measurements can be observed and measured (4).

## **1.6. Other Researches**

The Cooper *et al.* research wanted to demonstrate the level of efficacy and feasibility in using CT and the potential of MDCT in estimation of skeletal sex and age (10). They used 22 cases from the Institute of Forensic in Bern which were examined by three anthropologists. They investigated different parts of the skeleton using Nemeskéri method which includes four parameters: endocranial obliteration of the sutures, structure of the spongiosa of the proximal humerus, the proximal femur, and the texture of the symphyseal surface of the pubic bone. The results of their research demonstrated that the estimation of sex and age of remains can be performed using MDCT. Thus, the use of a virtual skeleton in 2D and/or 3D allows for investigation of the bones without having to sample or macerate (10).

The Arigbabu *et al.* research wanted to demonstrate the possibility of sex determination from human skull based on computer vision (CV) methods (22). Their framework was based on four main stages: 3D data pre-processing, 3D feature representation, multi-region feature representation, and classification. They used 100 post-mortem computed tomography (PMCT) scans, where 54 were males and 46 were females varying from 5 to 85 years in the South East Asia population. Their study demonstrated that CV methods can be suitable for sex estimation with a best prediction rate of 86% (22).

The Dereli *et al.* study explored the use of three-dimensional (3D) modeling of volumetric cranial computed tomography (CCT) images for sex estimation from skull

morphology (17). They used 85 scans from the archives of the Department of Radiology from 2017, 36 were females and 49 were males. These scans were analyzed by three observers and scored on a scale of 1-5 points according to the "Standards for Data Collection from Human Skeletal Remains" for the skull nuchal crests, mastoid processes, supra-orbital margins, glabellas, and mental eminences. Their results showed an accurate sex estimation rate of over 90% for each observer, with the glabella as the most effective morphological trait. Thus, volume-rendered CCT 3D images allowed for sex estimation from morphological features. Their scans were from patients of 18 years and older obtained from the radiology department in 2017 (17).

The Sierp and Henneberg study tried to evaluate the consistency and performance of sex determination in twenty skeletal remains of varied provenance using 15 methods of forensic anthropology (7 metric and 8 morphological) (28). Their results showed that even by using multiple methods, some skeletal bones still remained of ambiguous sex, but the overall combination of both morphologic and metric techniques resulted in greater levels of consistency (28).

The Yang *et al.* research study tried to propose an improved back-propagation neural network (BPNN) for sex determination of the skull which would improve the convergence speed and avoid falling into local minimum (15). They used a total 267 skulls, 153 females and 114 males, and measured six characteristics via computer-aid. Their results demonstrated that the BPNN has a stronger learning ability, faster convergence speed, and higher classification accuracy (15).

The Bašić *et al.* study tried to demonstrate discriminant functions for sex estimation from the medieval Croatian population and then test the possible application for the contemporary population (19). They used a total of 84 adults skeletons in excellent condition without any ante- or post-mortem changes and took all standard measurements. The results were able to demonstrate that some discriminant functions are sufficiently accurate to estimate the sex of Croatian populations from both periods (19).

## **1.7. Forensic Significance of Researches**

Forensic anthropologists exert their expertise by considering the overall bone morphology and contour of skeletal remains, trabecular bone patterns, sinus morphology, and

the presence of non-biological elements in the specimen like orthopedic or surgical devices (8).

Maceration is a time-consuming process and can possibly diminish the integrity of bone and DNA during sampling procedures which lead to imaging methods being a great alternative for accurate measuring techniques in cases where flesh is still present, in charred remains, or even in highly decomposed or degraded specimens. The possibility of a global database of CT data also eliminates the financial aspect related to the transfer of remains to specialist laboratories, the risk of physical damage or the loss of specimens during both transport to special facility and analysis, as well as jurisdiction permission and diplomatic procedures (17). The PACS (Picture Archiving and Communication System) and the DICOM (Digital Imaging and Communication in Medicine) serve to store CT data which is used in almost all hospitals in the world and can produce, manage, and distribute images (17).

A major disadvantage of using virtual images in the determination of sex estimation is the inability to physically feel for margins and crests that can be lost in the 3D reconstruction process and thus possibly providing inaccurate landmarks (17).

A significant breakthrough in the evolution of forensic anthropology due to researches is the involvement of the field in living individuals by estimation of age, gait, and stature from images and videos (2).

## **2. OBJECTIVES AND HYPOTHESIS**

The objectives of this research is to determine:

1. If sex estimation is possible in the Croatian population based on morphological and metric analysis of orbital dimensions.
2. If measurements of orbits are accurate and reproducible using computed tomography.
3. If the results obtained from the Croatian population differ from the results obtained in other studies, leading to addition of Croatian data to the worldwide database for population variation.

This study hypothesizes that the Croatian population will show sexual dimorphism based on the orbital morphology and osteometry and will demonstrate a slight difference in results compared to other populations.

### **3. METHODS**

This experimental research study was performed at the Laboratory for forensic and biological anthropology at the University Department of Forensic Sciences, University of Split, Croatia between April 2019 and July 2020. This project was in association with the Department of Radiology in Clinical Hospital Center Split and was approved by the Hospital's Ethics Committee and the Ethics committee of University Department of Forensic Sciences. The CT scans were anonymized so that only the sex and age were known and, for the purpose of this study, the observers were blinded when analyzing the CT scans. A total of 200 MSCT scans were used (100 females and 100 males; ages 18 and older) who had intact orbital margins for metric and morphological analysis.

### **3.1. Inclusion Criteria**

CT scans of patients, both male and female, of 18 years and older showing intact orbital margins were used. The CT scans were first analyzed then anonymized for a double-blinded study. Only scan slices from interval 0.700-1.400 mm were included in the analysis.

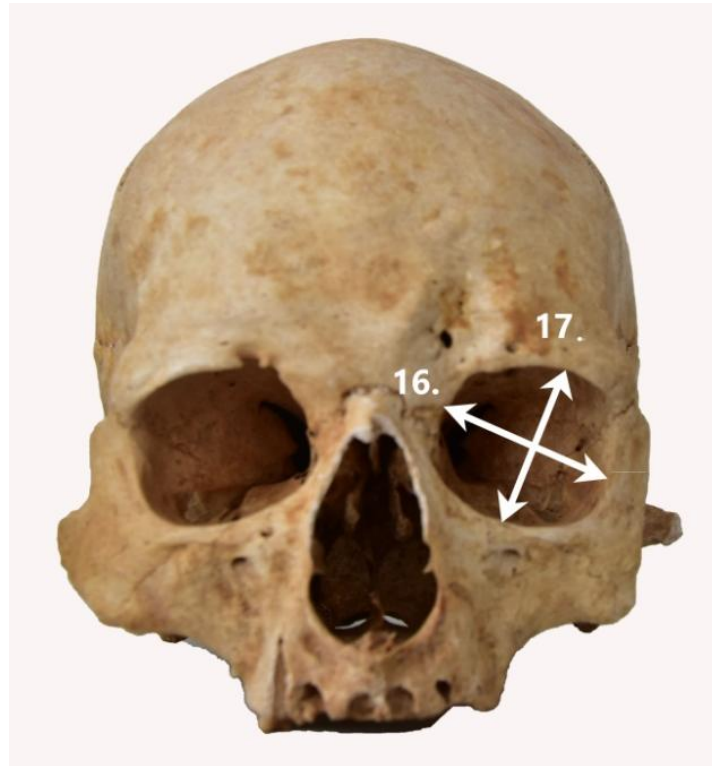
### **3.2. Exclusion Criteria**

CT scans of patients younger than 18 years old were discarded in the preliminary selection because of the lower sexual dimorphism in pre-pubertal ages. Any scans of different thickness than 7-14mm slices or without intact orbital margins were not included.

### **3.3. Osteometric and Morphological Analysis**

Data analysis was performed using the Osirix Program Osirix v.3.9.4 (Pixmeo, Geneva, Switzerland), using in the 3D viewer tab the 3D Volume Rendering mode of visualization. The CT scan was enlarged with the zoom tool and centered with the rotation around a focal point tool. The measurement tool was then used for orbital measurements and data obtained were recorded on an excel sheet. Morphology of the orbit was viewed with the cranium filling the page using the zoom tool. Osteometric analysis was based on the measurement of six different cranial measurements, four related to the orbits, one related to the zygomatic arches and one related to the maxilla (see Figures 1 and 2). The orbital measurements used were the right and left orbital breadth, right and left orbital height, biorbital breadth, interorbital breadth, and the zygomatic arches and maxilla related measurements used were the zygoorbitale and bimaxillary breadths, respectively, making it a total of eight measurements per cranial CT scans. Morphological analysis was based on the overall shape of the orbit scored from hyperfeminine to hypermasculine shape based on

Ascádi and Nemeskéri's scoring system (see Figure 3) (24). Osteometric data are reported in centimeters and expressed as means and standard deviations.

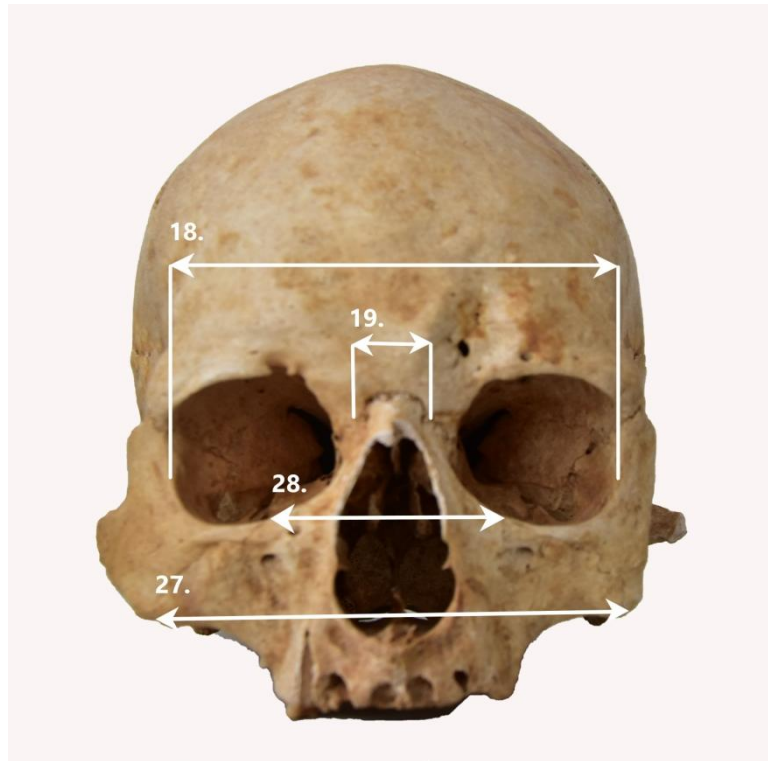


**Figure 1.** Measurements of the orbital region

16. Orbital breadth (from dacryon to ectoconchion); 17. Orbital height (from superior to inferior orbital margins, perpendicular to orbital breadth, bisecting orbit into equal halves).

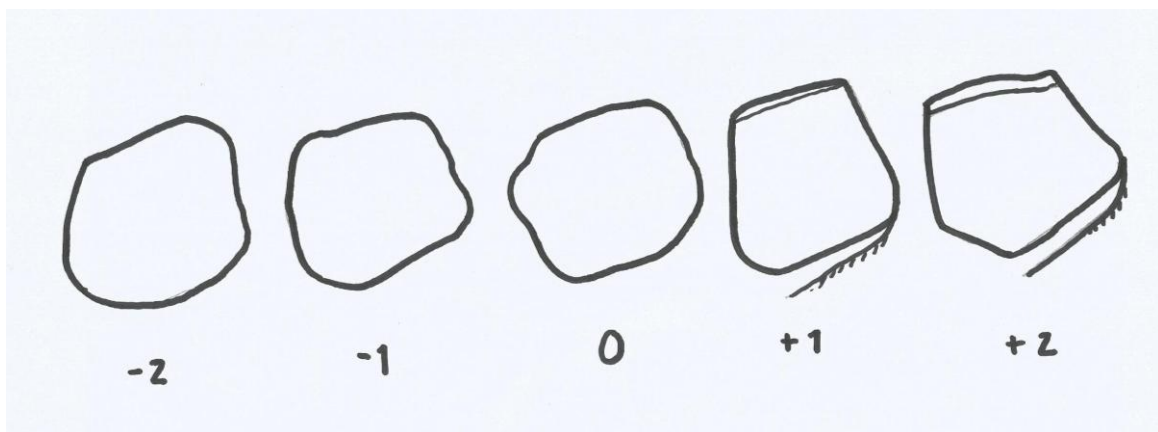
Based on Langley *et al.* manual (5).





**Figure 2.** Measurements of biorbital, interorbital, bimaxillary, and zygoorbitale breadths  
 18. Biorbital breadth (from left to right ectoconchion); 19. Interorbital breadth (from left to right dacryon); 27. Bimaxillary breadth (from left to right zygomaxillare anterior); 28. Zygoorbital breadth (from left to right zygoorbitale).

Based on Langley *et al.* manual (5).



**Figure 3.** Morphological shape of the orbit

*Key to the numbers:* -2: hyperfeminine; -1: feminine; 0: neutral/undeterminate; +1: masculine; +2: hypermasculine. Drawing by Carolane Radman.

Based on Ascádi and Nemeskéri manual (24).

### **3.4. Statistical Analysis**

Normality of distribution was tested with the Shapiro-Wilk test. The analyses were performed in SPSS, version 17 (SPSS Inc., Chicago, IL, USA) with the statistical significance set at  $P \leq 0.05$ . The precision of the discriminant functions and sectioning points was calculated on the basis of standardized and unstandardized coefficients, as well as the structural matrix. The accuracy of the discriminant functions was evaluated in the original and cross-validated sample (only cross-validated results using leave-one-out rule are shown). Inter-observer precision was evaluated by calculating the technical error of measurement (TEM), the relative technical error of measurement (rTEM) and the coefficient of reliability (R).

## **4. RESULTS**

A total of 200 CT scans were analyzed, with an equal amount of females and males (100 each), ages ranging from 18 to 92 years old. The eight measurements used and analyzed are the orbital breadth, left and right side (number 16-Figure 1), the orbital height, left and right side (number 17-Figure 1), the biorbital breadth (number 18-Figure 2), the interorbital breadth (number 19-Figure 2), the bimaxillary breadth (number 27-Figure 2), and the zygoorbitale breadth (number 28-Figure 2). The bimaxillary breadth was only measured in a total of 141 scans (79 males and 62 females) since 59 of the CT scans used were cut off under the orbit and thus the measurements could not be obtained.

A total of 20 CT scans were used to evaluate each measurements and morphology, of which 5 of them were missing the lower part of the cranium and thus only 15 values for the bimaxillary breadth measurements were compared. When taking only measurements with an rTEM less than 5 and an R value more than 0.75, only the right and left orbital breadths and heights (number 16R and 17R) would be considered precise based on inter-observer error (see Table 1). When looking only at rTEM values, then measurements of left orbital breadth (16L), bimaxillary breadth (27), and zygoorbitale breadth (28) should be excluded.

**Table 1.** Inter-observer error from metric analysis quantified by TEM, rTEM, and R values

<b>Measurements</b>	<b>N</b>	<b>TEM</b>	<b>rTEM</b>	<b>R</b>
16L	20	0.25	6.21	0.30
17L	20	0.08	2.75	0.84
16R	20	0.08	1.94	0.93
17R	20	0.06	1.89	0.95
18	20	0.32	3.31	0.45
19	20	0.06	3.32	0.98
27	15	0.64	7.13	0.38
28	20	0.75	0.54	0.37

N: number of Ct scans; TEM: technical error of measurement; rTEM: relative technical error of measurement; R: coefficient of reliability; 16L: left orbital breadth; 17L: left orbital height; 16R: right orbital breadth; 17R: right orbital height; 18: biorbital breadth; 19: interorbital breadth; 27: bimaxillary breadth; 28: zygoorbitale breadth.

Inter-observer error for the morphological aspect of the orbit was also analyzed and demonstrated a weighted kappa value of 0.41520 (Calculated from Table 2). In regards to weighted Cohen kappa, this can be interpreted as being of moderate agreement between

observers as values  $\leq 0$  indicates no agreement, 0.01-0.20 indicated none to slight, 0.21-0.40 indicates fair agreement, 0.41-0.60 indicates moderate, 0.61-0.80 indicates substantial, and 0.81-1.00 indicates almost perfect agreement. This value was calculated based on morphology of the orbit using scoring system of hyperfeminine being -2, feminine being -1, indeterminate being 0, masculine being 1, and hypermasculine being 2 (Figure 3). Due to statistical analysis, numbers of 1 to 5 were assigned to the scoring system (-2 is 1, -1 is 2, 0 is 3, 1 is 4, and 2 is 5) and were each reported by both observer with the frequency for each as demonstrated in Table 2.

**Table 2.** Inter-observer error in the morphological analysis of the orbit (kappa).

Observer 2	Observer 1					
	1	2	3	4	5	
1	3	2	0	1	0	6 (30.0%)
2	1	1	2	0	0	4 (20.0%)
3	1	0	1	0	0	2 (10.0%)
4	0	1	0	1	0	2 (10.0%)
5	1	0	0	4	1	6 (30.0%)
	6 (30.0%)	4 (20.0%)	3 (15.0%)	6 (30.0%)	1 (5.0%)	20

Observer 1: Carolane Radman; Observer 2: Mentor Ivana Kružić.

*Key to numbers:* 1: hyperfeminine (-2 in the scoring system); 2: feminine (-1 in the scoring system); 3: indeterminate (0 in the scoring system); 4: masculine (1 in the scoring system); 5: hypermasculine (2 in the scoring system).

A paired sample t-test was used in order to determinate possible bilateral asymmetry of orbital measurements, which could be useful with the exclusion of the left orbital breadth (16L) due to inter-observer error as explained previously. Table 3 demonstrates that neither the orbital breadth nor the orbital height had a significant statistical difference between the left and the right side measurements ( $P$  value set as  $P \leq 0.05$ ).

**Table 3.** Bilateral asymmetry of orbital measurements using paired samples t-test.

Measurements		N	Mean	Standard Deviation	Bilateral difference t-value	P*
Pair 1	16L	200	4.0093	0.31035	1.129	0.260
	16R	200	3.9896	0.21363		
Pair 2	17L	200	3.1032	0.24620	-1.660	0.098
	17R	200	3.1160	0.2487		

N: number of CT scans; 16L: left orbital breadth; 16R: right orbital breadth; 17L: left orbital height; 17R: right orbital height.

All 200 values for each of the eight measurements (141 for number 27) were analyzed using t-test in order to determinate if sexual dimorphism is present based on metric analysis. As seen in Table 4, all measurements have a significant statistical difference, except for the interorbital breadth (number 19) which has a *P* value of 0.114.

**Table 4.** Sexual dimorphism in the metric analysis using independent samples t-test.

Measurements	Male			Female			t-Value	P*
	N	Mean	±SD	N	Mean	±SD		
16L	100	4.1330	0.17712	100	3.8855	0.36235	6.137	P<0.001
17L	100	3.1416	0.27357	100	3.0648	0.20982	2.228	0.027
16R	100	4.0831	0.19527	100	3.8960	0.18954	6.875	P<0.001
17R	100	3.1567	0.25535	100	3.0754	0.22801	2.375	0.019
18	100	9.8420	0.31649	100	9.4463	0.37918	8.012	P<0.001
19	100	2.0389	0.24973	100	1.9767	0.30192	1.587	0.114
27	79	9.4642	0.54381	62	8.9671	0.43615	5.866	P<0.001
28	100	5.0992	0.54433	100	4.9376	0.61173	1.974	0.05

N: number of CT scans; SD: Standard Deviation; 16L: left orbital breadth; 17L: left orbital height; 16R: right orbital breadth; 17R: right orbital height; 18: biorbital breadth; 19: interorbital breadth; 27: bimaxillary breadth; 28: zygoorbitale breadth.

Sexual dimorphism based on the morphological aspect of the orbit was calculated using chi-squared test and demonstrated a significant statistical difference with a *P* value of <0.001 meaning that there are differences between the morphology of males and females orbital margins ( $\chi^2=166.780$ ,  $P<0.001$ ), as presented in Table 5. This data also demonstrates that more than 73% of the skulls viewed that had a morphological scoring of 3 (scoring system value 0:indeterminate) are of male sex and thus 100% of the male craniums were correctly identified as being of the male sex. About 89% of female craniums were correctly identified as being of the female sex based on the morphology of the orbital margins with scores of 2 and 1 (or -1 and -2 meaning feminine and hyperfeminine, respectively) and thus only a small percentage (11%) tend to be misidentified as males. Thus, it can be said that a morphology of 3 and above (0 and above) based on the orbital scoring system indicates male sex, whereas values less than 3 (less than 0) can be identified as being of the female sex.

**Table 5.** Sexual dimorphism in morphology of orbital margins using Chi-square test.

Morphology	Sex*		Total	Value	P*
	1	2			
1	0 (0.0%)	63 (63.0%)	63 (31.5%)	166.780	P<0.001
2	0 (0.0%)	26 (26.0%)	26 (13.0%)		
3	22 (22.0%)	9 (9.0%)	31 (15.5%)		
4	64 (64.0%)	1 (1.0%)	65 (32.5%)		
5	14 (14.0%)	1 (1.0%)	15 (7.5%)		
<b>Total</b>	100	100	200		

\*Sex of 1 represents male and Sex 2 represents female.

Discriminant functions were calculated for sex estimation and accuracies for each measurement. Cut off values represent the point at which a measurement falls into the male sex or the female sex based on the metric analysis of this study and are represented in Table 6. For example, the cut off value for the right orbital breadth (16R) is 3.99 which would indicate that measurements taken of values 3.99 cm and over would determine male sex and values under would indicate female sex with an overall accuracy of 68.5%. Each measurement has its own overall percentage for accuracy which represents the probability of accurately estimating the sex of the cranium when using the cut off points of measured orbits. Moreover, with discriminant function analysis (DFA), equations can be obtained and used for further

studies or measures on other skulls to facilitate and shorten the sex estimation process. Values obtained are simply plotted into the equation and result would indicate the sex. A total of five functions were obtained in this study based on the exclusion from inter-observer errors for both metric analysis and morphology. As seen in Table 7, all cut off values for the discriminant functions are of 0 since all measurements used have an equal number of data collected. Table 7 also provides classification rates for each function and demonstrates that they are not of high enough significant value/accuracy for metric analysis (overall percentages of 69 for functions 1 to 3 and of 70.5 for function 4). However, the overall classification rate of 94.5% for the morphological discriminant function provides high accuracy and importance.

**Table 6.** Cut off values for sex estimation and cross-validated accuracies for univariate discriminant functions of orbital measurements - Single variables.

Measurements	Mean (cm)		Cut off (cm)	Accuracy					
	Male	Female		N	Male, n(%)	Females, n(%)	N	Overall, n(%)	
16L	4.133	3.8855	4.01	100	73 (73)	100	74 (74)	200	73.5
17L	3.1416	3.0648	3.10	100	53 (53)	100	60 (60)	200	56.5
16R	4.0831	3.896	3.99	100	67 (67)	100	70 (70)	200	68.5
17R	3.1567	3.0754	3.12	100	54 (54)	100	60 (60)	200	57
18	9.842	9.4463	9.64	100	75 (75)	100	70 (70)	200	72.5
19	2.0389	1.9767	2.01	100	53 (53)	100	61 (61)	200	57
27	9.4642	8.9671	9.22	79	50 (63.3)	62	43 (69.4)	141	66
28	5.0992	4.9376	5.02	100	56 (56)	100	54 (54)	200	55

16L: left orbital breadth; 17L: left orbital height; 16R: right orbital breadth; 17R: right orbital height; 18: biorbital breadth; 19: interorbital breadth; 27: bimaxillary breadth; 28: zygoorbitale breadth.6. Discriminant functions



**Table 7.** Discriminant functions for orbital measurements and indices with classification rates - All variables.

Discriminant function	Cut off	Classification rates, %		
		Male	Female	Overall
<b>F=16R*1.858 + 17R*0.530 + 18*2.06 + 19*0.025 - 28.982</b>	0	70	68	69
<b>F2=16R*1.831 + 17R*0.533 + 18*2.076 - 28.988</b>	0	70	68	69
<b>F3=16R*5.062 + 017R*0.350 - 21.287</b>	0	68	70	69
<b>F4=16R*2.07 + 18*2.049 - 28.021</b>	0	72	69	70.5
<b>F5= Score*1.434 + 0.409</b>	0	100	89	94.5

F: all non-excluded variables from inter-observer error (16R, 17R, 18, and 19); F2: variables 16R, 17R, and 18; F3: orbit combination for the right side; F4: function using stepwise analysis (16R and 18); F5: discriminant function for morphology.

## **5. DISCUSSION**

In regards to metric analysis, the results demonstrated that the selected measurements of the orbital region and bimaxillary and zygoorbitale breadth have a statistically significant sexual dimorphism with  $P$  values  $\leq 0.05$  (Table 4), but that sex estimation based on these results have an overall accuracy of 73.5%, for left orbital breadth, 72.5% for biorbital breadth and less than 70% for all other measurements which means that the measures of orbital area are not reliable as a sex indicator in a forensic context (Table 6). Moreover, the measurements with the overall accuracy are actually two of the four measurements that should be excluded based on inter-observer error with  $R$  values of 0.30 and 0.45, respectively (Table 1). Also, although the interorbital breadth showed somewhat good  $r$ TEM (3.32) and a very good  $R$  value (0.98), it was demonstrated that there is no significant statistical difference between measurements in males and females as seen in Table 4 with a  $P=0.114$ .

Overall, this study demonstrated with inter-observer error that the only two measurements that could be considered of value for sex estimation were the RIGHT side of orbital breadth and height (Table 1). These two measurements demonstrated good values for technical error of measurement with TEM of 0.08 and 0.06,  $r$ TEM of 1.94 and 1.89 (lower than 2%), and  $R$  values of 0.93 and 0.95 (higher than 0.75). When considering that bilateral asymmetry was showed to not be of significant statistical difference for the right and left side with  $P=0.260$  for orbital breadth (16R and 16L) and  $P=0.098$  for orbital height (17R and 17L), it is possible to assume that sex estimation can be estimated using only those two orbital measurements from the right orbit, although with only an overall accuracy of 68.5% for 16 and of 57% for 17 (Table 6) and a discriminant function with an overall classification rate of only 69% (Table 7).

On the other hand, with morphological analysis, this study demonstrated a sexual dimorphism of significant statistical significance ( $P<0.001$ ) meaning that there is valuable differences in the shape of the orbit for males and females. It was shown that 100% of males were correctly identified when using the scoring system of 0 and above as male sex (Table 5). Moreover, the discriminant function related to morphology scoring has an overall classification rate of 94.5% which implies a very valuable way to discriminate sex based on the general shape of the orbit (Table 7). However, Table 2 for inter-observer error demonstrated that agreement between observers was only moderate with a weighted kappa value of 0.41520 (Table 2) when it comes to morphology and thus proves the quite high level of subjectivity present.

The main result of our study was the indication that the orbital breadth and orbital height provide a significant statistical difference between sexes. This corresponds to the same results as Kaya *et al.* where these two variables were the most confident for discriminant functions and thus could be used for sex estimation (29). Moreover, their breadth and height accuracies values were similar to ours with ranges from 59.8 to 75%, also suggesting that, although orbital width and height could help in sex identification, it is not sufficiently successful as the only parameter. The comparability of the results could indicate a possible similarity between the Croatian and Turkish populations at the level of the orbit. On this line of thought, Marinescu study showing high sexual dimorphism in the Romanian population with moderate accuracy of around 75% (orbital breadth of 77.5% and orbital height of 57%) could imply the same thing (30). This assumption could be tested in a future research project by comparing the three populations in a similar way as Kranjoti *et al.* did for the Cretan, Greeks, and Turkish (31).

Other studies that showed comparable results was Rossi *et al.* based on radiographs of the orbital aperture in the Brazilian population and Adel *et al.* based on multi-detector computed tomography (MDCT) in the Egyptian population (32,33). Rossi's results also showed no significant statistical difference between left and right side and a significant statistical difference in the interorbital distance. However, it differs with results of no significance with orbital height between sexes, whereas it did in our study. Adel's results compare in the significance and cross-validated accuracy for orbital height and width (62.7 and 61.3%, respectively), but differ in their inter-observer error values proving the reliability of their measurements with  $rTEM < 1.5\%$  and  $R > 0.95$ .

Results from Kranjoti *et al.* demonstrated a significant statistical difference in cranial features between Cretans, Greeks, and Turkish population with classification rates of 72%, 82%, and 94%, respectively (31). Their study showed that measurements with the most error in both intra- and inter-observer were the orbital height and the biorbital breadth with  $R = 0.70$  which differs from our results since those two values represented the ones with less error. They compared physical and virtual measurements and concluded based on  $rTEM$  and  $R$  that the bizygomatic diameter, orbital height, and interorbital breadth were not significantly reliable (31).

On the other hand, the Walker study showed similar results as our study in relation to the correct classification of sex with an overall percentage of 68.8% (ours was around 69-

70.5%) (34). However, his study added other cranial traits like the glabella, nuchal lines, and mastoid which showed an increase in correct classification to 88.5%, and to 87.5% if also adding mental trait. This implies that our results could have been better expressed for the Croatian population if traits other than orbital margins were used (34).

Another study, this one by Franklin *et al.* demonstrated that all their measurements were significantly larger in males than in females and with greatest sexual dimorphism in the bizygomatic breadth, basion-nasion and glabello-occipital lengths and non-significant measurements for frontal breadth and orbital height (35). This differs from our findings as the orbital height showed promises for sex estimation in the Croatian population which could indicate a certain degree of variation between Croatians and Western Australians. This study illustrated that the bizygomatic breadth is the most sexually dimorphic in the human cranium in diverse populations (South African, Northern Indian, Cretan, Japanese, and Brazilian) with an accurate single variable of 85%. Other studies also demonstrated the importance of the bizygomatic breadth in sex estimation like the Mahakkanukrah *et al.* study from physical skulls (36). This brings the following question: is the bizygomatic breadth similarly of high sexual dimorphic value in the Croatian population and thus should have been included in this study for a better accuracy of sex assessment?

Based on Ramamoorthy *et al.* which assessed sex with physical skulls in the South Indian population and Ghorai *et al.* that did the same but with radiography, it is possible to compare results and level of validity when using imaging studies for analysis (37,38). The physical skulls were reported to have orbital height, orbital breadth and interorbital breadth of no significant statistical difference between sex (which is the complete opposite to the results that we obtained), but a biorbital breadth of significant value. However, within the same population, the radiographic study proved to be in agreement with our results and not on the results from physical skull analysis. Indeed, their orbital width and interorbital variables showed great significance for sexual dimorphism with interorbital distance being the most valuable in predicting gender with a correct classification of 86.1%. This just proves to show that not only can result differ with different methods of analysis, but also within a same population, demonstrating the possible variations present but not reported in studies.

Overall, based on the data collected from our study with both metric and morphologic analysis, it seems clear that the use of orbital measurements from virtual craniums (CT scans) does not demonstrate enough reliability for sex estimation when analyzed on its own, except

maybe to a certain degree for morphologic analysis. It proved that it performs better than osteometry, possibly because it is easier to observe a general shape than to locate and measure from specific landmarks, especially on a virtual skeleton. This also proves that morphology is still a subjective measurement since, even with a high classification rate of 94.5%, the inter-observer error provided only a moderate level of agreement. Dereli *et al.* also shared similar results for morphological analysis as their sex estimation accuracy were of 91.8-92.8%, but their inter-observer error produced a Kappa value of 0.763, putting them at a higher level of agreement than our study (substantial vs. moderate) (17). Considering that accuracy represents the percentage of a specimen being correctly assigned to the right sex based on the elaborated method and reliability involves testing said method on an independent population with classification rates of 85% (95% if involved in the medico-legal system), any continuation in measurements of orbital margins for sex estimation should be accompanied by other traits and measurements (7).

In the future, inclusion of variables that were proven to be highly sexually dimorphic in other studies, like bizygomatic breadth or mastoid process, should be included and these measurements should be compared to other populations that demonstrated a certain level of similarity in other researches.

Possible limitations of this studies are: (1) the CT scans used were from patients of the Firule Hospital and not specifically done for this study, thus part of the cranium was missing for some of them which reduced the number of data for some measurements, (2) all measurements were only analyzed once, thus there was no intra-observer error that could be calculated and possibly indicate if the measurements were more precise and useful than when solely based on inter-observer error, meaning that more measurements could have been used and compared, and (3) the resolution of some CT scans proved very difficult to correctly identify the specific landmarks needed for analysis.

## **6. CONCLUSION**

According to these results, we conclude that metric analysis of orbital measurements on CT scans in the Croatian population is not accurate enough by itself to allow for sex estimation even though orbital breadth and orbital height are two of the measurements that proved to be significantly different between males and females and provided a reliable inter-observer tabulation. This study conclusively shows that other orbital measurements like biorbital breadth could also be included in an upcoming study, but attention should be paid when measuring in order to satisfy the criteria for intra- and inter-observer error. Morphological analysis was demonstrated to perform better than metric analysis and is of considerable value in sex determination, especially in the male Croatian population.



## **7. REFERENCES**

1. Saukko P, Knight B. Knight's Forensic Pathology. Third edition. United Kingdom. 2004. p.1.
2. Iscan MY, Steyn MB. The human skeleton in forensic medicine. 3rd edition. Pretoria, South Africa. p. 3-10, 143-194, 393-406, 407-438.
3. Lundy JK. Forensic anthropology: What bones can tell us. Lab Med. 1998. V29:N7.
4. Langley NR, Jantz LM, Ousley SD, Jantz RL, Milner G. Data collection procedures for forensic skeletal material 2.0. Knoxville, Tennessee. 2016. p. 61-82.
5. Larsen CS. Essentials of physical anthropology: Discovering our origins. First edition. United States of America; New York. 2010. p. 4-9.
6. Larsen CS. A companion to biological anthropology. First edition. United Kingdom. 2010. p.88-103; 412-426.
7. Schmitt A, Cunha E, Pinheiro J. Forensic anthropology and medicine. First edition. New Jersey. 2006. p.3-53; 225-242.
8. Wiersema JM. Evolution of forensic anthropological methods of identification. Acad Forensic Pathol. 2016; 6(3):361-369
9. Dirnhofer R, Jackowski C, Vock P et al. VIRTOPSY: minimally invasive, imaging-guided virtual autopsy. Radiographics. 2006; 26:1305-1333.
10. Grabherr S, Cooper C, Ulrich-Bochsler S, Uldin T, Ross S, Oesterhelweg L, et al. Estimation of sex and age of "virtual skeletons"-a feasibility study. Eur Radiol. 2008. doi:10.1007/s00330-008-1155-y.
11. Grabherr S, Stephan BA, Buck U et al. Virtopsy-radiology in forensic medicine. Imaging Decis MRI. 2007; 11:2-9.
12. Ubelaker DH. Recent advances in forensic anthropology. Forensic Sci Res. 2018. Vo. 3;No.4; 275-277.
13. Ubelaker DH, Khosrowshahi H. Estimation of age in forensic anthropology: historical perspective and recent methodological advances. Forensic Sci Res. 2019. Vol. 4;No. 1; 1-9.

14. Dirkmaat D, Cabo LL, Ousley SD, Symes SA. New perspectives in forensic anthropology. *Yearbook Phys Anthropol.* 2008. 51:33-52.
15. Yang W, Liu X, Wang K, Hu J, Geng G, Feng J. Sex determination of three-dimensional skull based on improved backpropagation neural network. *Comput Math Method M.* 2019. doi:10.1155/2019/9163547.
16. White TD, Black MT, Folkens PA. *Human osteology.* 3rd edition. Berkley, California. 2012. p. 379-428.
17. Dereli AK, Zeybek V, Sagtas E, Senol H, Ozgul HA, Acar K. Sex determination with morphological characteristics of the skull by using 3D modeling techniques in computerized tomography. *Forensic Science, Med and Pathol.* 2018. 14:450-459.
18. Brickley M, McKinley JI, Connell B, O'Connell L, Brothwell D, Zakrzewski S, et al. *Guidelines to the standards for recording human remains.* 1st edition. Southampton, Highfield. 2004. p. 5, 23-25.
19. Basic Z, Kruzic I, Jerkovic I, Andelinovic D, Andelinovic S. Sex estimation standards for medieval and contemporary Croats. *Forensic Science, Croat Med J.* 2017. 58; 222-230.
20. Basic Z, Anteric I, Vilovic K, Petaros A, Bosnar A, Madzar T, et al. Sex determination in skeletal remains from the medieval Eastern Adriatic coast-discriminant function analysis of humeri. *Croat Med J.* 2013. 54; 272-280.
21. Bašić Ž. Determination of anthropological measurements and their ratios that are significant for sex determination on skeletal remains from medieval population of Eastern Adriatic Coast. PhD Thesis. 2005.
22. Arigbabu OA, Liao IY, Abdullah N, Noor MHM. Computer vision methods for cranial sex estimation. *IPSJ.* 2017. 9; 19.
23. Kranioti EF, Iscan MY, Michalodimitrakis M. Craniometric analysis of modern Cretan population. *Forensic Sci Int.* 2008;180:1101-5.
24. Ascadi G, Nemeskeri J. *History of human life span and mortality.* Budapest: Akademiai Kiado; 1970. p.346.

25. Buikstra JE, Ubelaker DH. Standards for data collection from human skeletal remains. In: Proceedings of a seminar at the Field Museum of Natural History. 1994. Ark Archeol Sur Rese Series 44.
26. Franklin D, Freedman L, Milne N. Sexual dimorphism and discriminant function sexing in indigenous South African crania. *HOMO-J Comparative Hum Biol.* 2005;55(3):213-228.
27. Bigoni L, Velemínska J, Bruzek J. Three-dimensional geometric morphometric analysis of cranio-facial sexual dimorphism in a Central European sample of known sex. *HOMO-J Comparative Hum Biol.* 2010;61(1):16-32.
28. Sierp I, Henneberg M. The difficulty of sexing skeletons from unknown populations. *J Anthropol.* 2015. doi:10.1155/2015/908535.
29. Kaya A, Uygun S, Eraslan C, Coskun Akar G, Kocak A, Aktas E, *et al.* Sex estimation: 3D CTA-scan based on orbital measurements in Turkish population. *Rom J Leg Med.* 2014. 22; 257-262.
30. Marinescu M. Sexual dimorphism of crania in a Romanian population: Discriminant function analysis approach for sex estimation. *Rom J Leg Med.* 2014. 22; 21-26.
31. Kranioti EF, García-Donas JG, Can IO, Ekizoglu O. Ancestry estimation of three Mediterranean populations based on cranial metrics. *For Sci Int.* 2018. doi:10.1016/j.forsciint.2018.02.014.
32. Rossi AC, Humberto de Souza Azevedo F, Freire AR, Groppo FC, Daruge Junior E, Ferreira Caria PH, *et al.* Orbital aperture morphometry in Brazilian population by postero-anterior Caldwell radiographs. *J Forensic Leg Med.* 2012. 19; 470-473.
33. Adel R, Ahmed HM, Hassan OA, Abdelgawad EA. Assessment of craniometric sexual dimorphism using multidetector computed tomographic imaging in a sample of Egyptian population. *Am J Forensic Med Pathol.* 2019. 40; 19-26.
34. Walker PL. Sexing skulls using discriminant function analysis of visually assessed traits. *Am J Phys Anthropol.* 2008. 136; 39-50.
35. Franklin D, Cardini A, Flavel A, Kuliukas A. Estimation of sex from cranial measurements in a Western Australian population. *For Sci Int.* 2013. 229; 158.e1-158.e2.

36. Mahakkanukrah P, Sinhubua A, Prasitwattanaseree S, Ruengdit S, Singsuwan P, Praneatpolgrang S, *et al.* Craniometric study for sex determination in a Thai population. *Anat Cell Biol.* 2015. 48; 275-283.
37. Ramamoorthy B, Pai MM, Prabhu LV, Muralimanju BV, Rai R. Assessment of craniometric traits in South Indian dry skulls for sex determination. *J Forensic Leg Med.* 2016. 37; 8-14.
38. Ghorai L, Asha ML, Lekshmy J, Rajarathnam BN, Mahesh Kumar HM. Orbital aperture morphometry in Indian population: A digital radiographic study. *J Forensic Dent Sci.* 2017. 9(2); 61-64.

## **8. SUMMARY**

**Objectives:** The purpose of this study is to determine if it is possible to estimate the sex of skeletal remains in the Croatian population using morphological and osteometric analysis of orbital measurements from CT imaging. Additionally, this study aims to determine if orbital measurements are accurate and reproducible with virtual representation as well as to compare results from the Croatian population to other populations in order to improve the information in the worldwide database.

**Methods:** Two hundred CT scans of the craniums of Croatian patients were included, with equal proportion of male and female (each 100) and ages ranging from 18 to 92. Intact orbital margins were used for measurements based on a total of six different variables (orbital breadth, orbital height, biorbital breadth, interorbital breadth, bimaxillary breadth, and zygoorbitale breadth) for metric and morphological analysis. Normality of distribution was tested with Shapiro-Wilk test and performed in SPSS with the statistical significance set at  $P \leq 0.05$ . The precision of the discriminant functions and sectioning points was calculated on the basis of standardized and unstandardized coefficients, as well as the structural matrix. The accuracy of the discriminant functions was evaluated in the original and cross-validated sample (only cross-validated results using leave-one-out rule are shown).

**Results:** Inter-observer error produced values of  $r_{TEM}$  and  $R$  that caused the exclusion of interorbital breadth, bimaxillary breadth, zygoorbitale breadth, and the left-sided orbital breadth. Weighted Kappa (0.41520) was calculated for inter-observer error morphology and demonstrated a moderate agreement. No significant statistical differences were calculated between the right and the left side of orbital width and height. All measurements tabulated proved to be of significant statistical difference between males and females except for interorbital breadth ( $P=0.114$ ). Morphology demonstrated high sexual dimorphism ( $P < 0.001$ ) and classification rate (94.5%). The orbital measurements varied in their overall accuracy ranging from 55% (zygoorbital breadth) to 72.5% (biorbital breadth) and 73.5% (left orbital breadth), but with discriminant functions of classification rates 69-70.5%.

**Conclusion:** The more valuable orbital measurements for sex estimation in the Croatian population are the orbital width and height as well as the biorbital breadth, whereas the interorbital breadth does not show a significant difference in Croatian males and females. However, these measurements provide a classification rate/accuracy with the highest value amongst all of 70.5% which is not sufficiently reliable for the orbit to be used alone in sex determination analysis.

## **9. CROATIAN SUMMARY**



## **Naslov:** PROCJENA SPOLA NA HRVATSKOJ POPULACIJI S POMOĆU CT SNIMAKA KRANIJA

**Ciljevi:** Svrha ove studije je utvrditi je li moguće procijeniti spol kosturnih ostataka na hrvatskoj populaciji korištenjem morfološke i metričke analize orbitalnih dimenzija s pomoću CT snimaka. Uz to, ova studija ima za cilj utvrditi jesu li mjerenja orbita točna i ponovljiva na virtualnom prikazu, kao i usporedbu rezultata hrvatske populacije s drugim populacijama radi poboljšanja podataka u svjetskoj bazi podataka.

**Metode:** Uključeno je dvjesto CT snimaka kranija hrvatskih pacijenata, s jednakim udjelom muškaraca i žena (svaki 100) i dobi u dobi od 18 do 92. Netaknuti orbitalni rubovi korištene su za mjerenja na temelju ukupno šest različitih varijabli (orbitalna širina, orbitalna visina, biorbitalna širina, interorbitalna širina, bimaksilarna širina and ziggorbitalna širina) za metričku i morfološku analizu. Normalnost raspodjele ispitana je testom Shapiro-Wilk u SPSS-u sa statističkom značajnošću postavljenom na  $P \leq 0.05$ . Preciznost diskriminantnih funkcija i točaka presjeka izračunata je na temelju standardiziranih i nestandardiziranih koeficijenata, kao i strukturne matrice. Točnost diskriminirajućih funkcija procijenjena je u izvornom i unakrsnom vrednovanom uzorku (prikazani su samo unakrsno vrednovani rezultati korištenjem pravila izostavljanja).

**Rezultati:** Međumjeriteljska pogreška proizvela je vrijednosti  $r_{TEM}$  i  $R$  što je uzrokovalo isključenje interorbitalne širine, bimaksilarne širine, ziggorbitalne širine i orbitalne širine lijevo. Za međumjeriteljsku pogrešku izračunana je Kappa (0,41520), koja pokazuje umjereno slaganje. Nije bilo statistički značajne statistička razlike između desne i lijeve strane za mjere orbitalne širine i visine. Sva mjerenja pokazala su značajnu statističku razliku između muškaraca i žena, osim interorbitalne širine ( $P = 0,114$ ). Morfološke značajke pokazuju visok spolni dimorfizam ( $P < 0,001$ ) i stopu klasifikacije (94,5 %). Orbitalna mjerenja varirala su u njihovoj ukupnoj točnosti u rasponu od 55 % (zigoorbitalna širina) do 72,5 % (biorbitalna širina) i 73,5 % (lijeva orbitalna širina), a s diskriminantnim funkcijama stope klasifikacije 69-70,5 %.

**Zaključci:** Najbolje mjere za procjenu spola na hrvatskoj populaciji su orbitalna širina i visina, kao i biorbitalna širina, dok interorbitalna širina ne pokazuje značajnu razliku u hrvatskim muškarcima i ženama. Međutim, ove mjere daju stopu / točnost klasifikacije s najviše 70,5 %, što nije dovoljno pouzdano da bi se orbita mogla sama koristiti za procjenu spola.

## **10. CURRICULUM VITAE**

**Personal Data:**

Name and Surname: Carolane Radman

Date and Place of birth: November 5, 1992; Repentigny, Qc.

Nationality: Canadian

Address: 133 Rue Santerre, Repentigny, Quebec, J5Y 2V9, Canada

E-mail: caroradman@gmail.com

**Education:**

2014-2020: University of Split, School of Medicine (USSM), Split

2012-2014: Concordia University, Montreal

2010-2012: Vanier College, Montreal

2005-2010: École secondaire Paul-Arseneau, L'Assomption

**Extracurricular:**

Vice-representative for the English program class of 2014/2015 (2 years).

Volunteer in the Skills Competition Event from USSM, 2018-2020 (3 years).

**Languages:**

French (mother tongue)

English (C2)      Croatian (B2)      Spanish (A1)