

Learning curve for laparoscopic repair of pediatric inguinal hernia using percutaneous internal ring suturing

Huskic, Dario

Master's thesis / Diplomski rad

2021

Degree Grantor / Ustanova koja je dodijelila akademski / stručni stupanj: **University of Split, School of Medicine / Sveučilište u Splitu, Medicinski fakultet**

Permanent link / Trajna poveznica: <https://um.nsk.hr/um:nbn:hr:171:281312>

Rights / Prava: [In copyright](#)/[Zaštićeno autorskim pravom.](#)

Download date / Datum preuzimanja: **2024-12-26**



Repository / Repozitorij:

[MEFST Repository](#)



**UNIVERSITY OF SPLIT
SCHOOL OF MEDICINE**

DARIO HUSKIC

**LEARNING CURVE FOR LAPAROSCOPIC REPAIR OF
PEDIATRIC INGUINAL HERNIA USING PERCUTANEOUS
INTERNAL RING SUTURING**

DIPLOMA THESIS

Academic year:

2020/2021

Mentor:

Assoc. Prof. Zenon Pogorelić, MD, PhD

Split, July 2021

CONTENT

1. INTRODUCTION	1
1.1. Inguinal Region Anatomy	2
1.2. Inguinal hernia	5
1.2.1. Inguinal hernia anatomy	5
1.2.2. Types of inguinal hernia.....	5
1.2.3. Incidence	6
1.2.4. Clinical findings	7
1.2.5. Complications.....	8
1.2.6. Types of hernias	10
1.2.7. Diagnostic approach.....	11
1.2.8. Treatment	12
1.2.9 Surgical techniques	13
1.3. Learning Curves	17
1.3.1 Learning curves in laparoscopic surgery.....	19
2. OBJECTIVES OF RESEARCH	20
3. PATIENTS AND METHODS	22
3.1. Patients.....	23
3.2. Organization of the study	23
3.3. Place of the study.....	23
3.4. Methods of data collection and processing.....	23
3.5. Description of research	24
3.6. Outcome measures.....	24
3.7. Compliance with ethical standards	24
3.8. Surgery.....	25
4. RESULTS	27
5. DISCUSSION	34
6. CONCLUSION	38
7. REFERENCES	39
8. SUMMARY	44
9. SUMMARY IN CROATIAN	46
10. CURRICULUM VITAE	48
11. SUPPLEMENTS	50

I want to thank my parents and close friends for all of the support and care over all these years.

Additionally, many thanks and appreciation for my mentor, Prof. Dr. Zenon Pogorelić for his patience and valuable advice throughout the course of this work

LIST OF ABBREVIATIONS

ANOVA – Analysis of variance

ASA – American Society of Anesthesiologists

ASIS – Anterior superior iliac spine

BMI – Body mass index

CT – Computed tomography

IQR – Interquartile range

MRI – Magnetic resonance imaging

PIRS – Percutaneous internal ring suturing

1. INTRODUCTION

1.1. Inguinal Region Anatomy

The inguinal region also known as the groin, is located in the lower anterior abdominal wall, with the thigh located inferiorly, the pubic tubercle medially, and the anterior superior iliac spine (ASIS) superolaterally. The inguinal canal is located just above the inguinal ligament in the area of the lower anterior abdominal wall. The inguinal ligament provides the canal with a strong floor and enables passage of the spermatic cord and vessels (1). This area has clinical relevance because the exit and entrance of the inguinal canal are located here, which are potential sites of hernia formation (*Figure 1*).

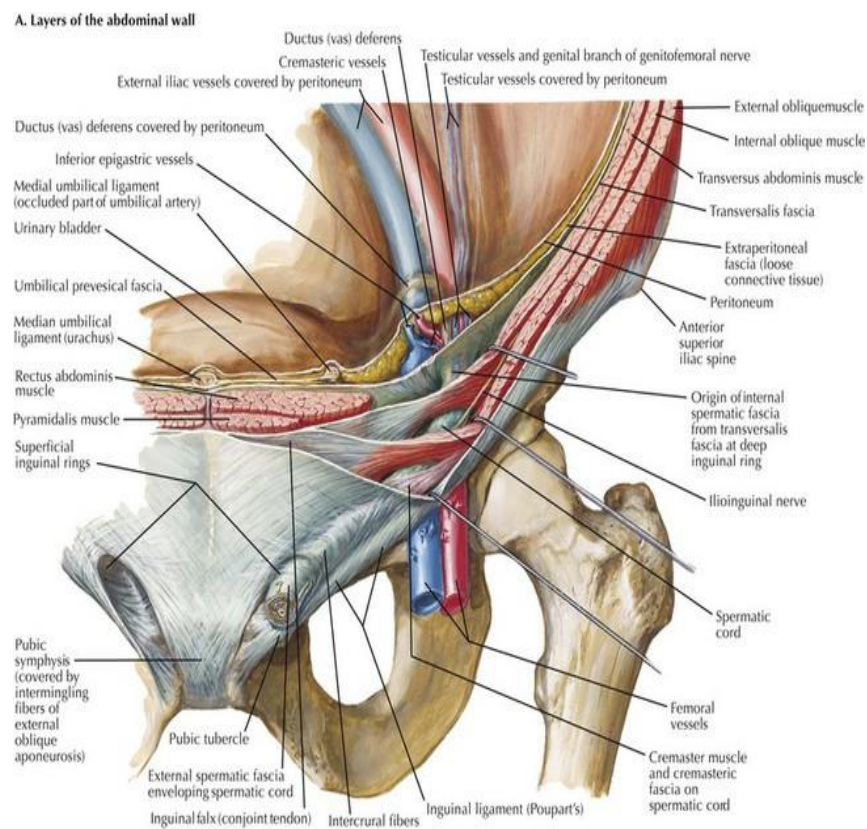


Figure 1. Anatomy of the inguinal region.

Source: <https://basicmedicalkey.com/wp-content>

The iliopubic tract and inguinal ligament, which extend from the ASIS to the pubic tubercle, constitute the anterior retinaculum of the hip joint. The space that the flexor muscles of the hip and neurovascular structures continue to the lower limb is known as the subinguinal space (2). The anterolateral abdominal wall contains three muscles which have more prominent aponeurosis anteriorly; the external oblique, internal oblique and the transversus abdominis. A triangular defect in the external oblique aponeurosis, which is above and medial to the pubic tubercle is known as the superficial inguinal ring (3). The lower border of the external oblique aponeurosis is folded on itself between the pubic tubercle and the ASIS this forms the inguinal ligament (3). The transversalis fascia is a thin layer of fascia located between the abdominal wall muscles and the parietal peritoneum (3). At the midpoint between the symphysis pubis medially and the ASIS laterally, the spermatic cord in males and round ligament in females pierces the transversalis fascia and forms the deep inguinal ring (3).

In adults the inguinal canal is approximately 4 to 6 cm long and it extends from the deep inguinal ring to the superficial inguinal ring. The internal ring is located laterally to the epigastric vessels and is formed by the transversalis fascia, while the external ring is located the end of the canal and superior to the pubic tubercle (4). The canal is superior and parallel to the inguinal ligament (3). The canal transmits the spermatic cord in males and the round ligament of the uterus in females (4). The inguinal nerves the ilioinguinal and genitofemoral plus the blood and lymphatic vessels are positioned beside these structures within the inguinal canal. Furthermore, the mid inguinal point is the area between the ASIS superolaterally and the pubic tubercle medially (4). The inguinal canal is formed by the anterior, posterior, superficial (roof) and inferior (floor) walls. The anterior wall is formed by the external oblique aponeurosis and is supported laterally by the internal oblique muscle where it originates from the inguinal ligament (4). The posterior wall or floor is formed by the transversalis fascia laterally, the conjoint tendon medially and the deep inguinal ring (4). The inferior wall or floor is shaped centrally by the inguinal ligament, medially by the lacunar ligament and laterally by the iliopubic tract (*Figure 2*). The superior wall or roof is formed by the combined fibers of the internal oblique and the transversus abdominis muscle and aponeurosis (3). Furthermore, the posterior wall is also the place where the inguinal (Hesselbach's) triangle is positioned.

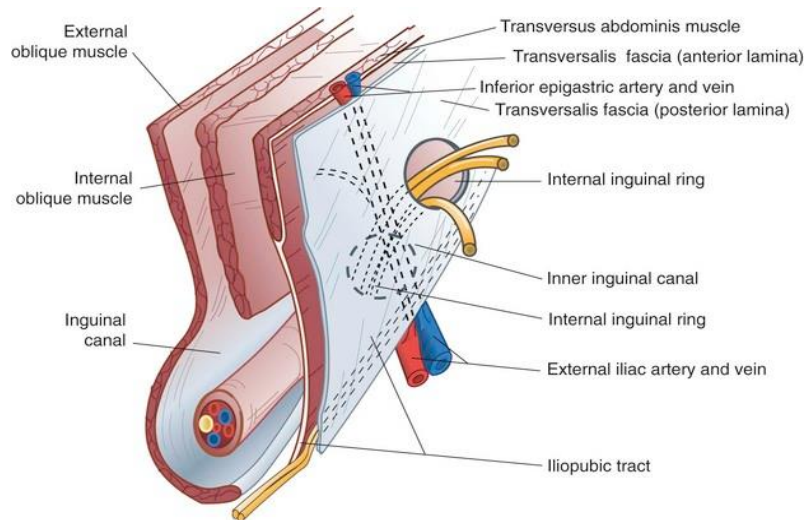


Figure 2. Anatomical walls of the inguinal canal.

Source: <https://thoracickey.com/wp-content/>

The Hesselbach triangle is bounded by the inguinal ligament, the inferior epigastric vessels, and the lateral border of the rectus abdominis muscle (5). This location has major clinical significance as it is the weakest point of the abdominal wall and is the site where both inguinal and femoral hernias arise (Figure 3) (2). It is also the site where inguinal hernias are classified as either direct or indirect depending on their relation to the inferior epigastric vessels.

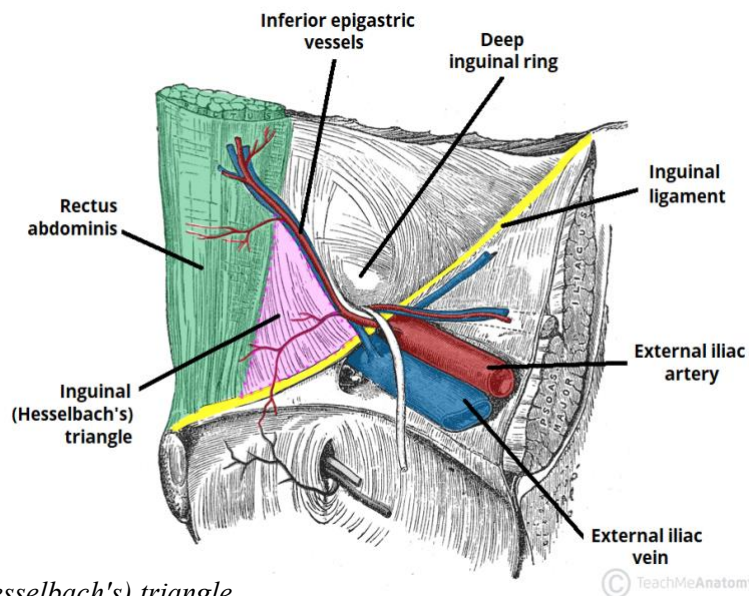


Figure 3. Inguinal (Hesselbach's) triangle.

Source: <https://teachmeanatomy.info/wp-content>

1.2. Inguinal hernia

1.2.1. Inguinal hernia anatomy

The inguinal canal begins at the internal inguinal ring and extends to the superficial ring and it fosters the round ligament in females and the spermatic vessels in males. The stability of the abdominal wall is dependent on a few factors, namely, the transversalis fascia, the direction of the inguinal canal, and the integrity of the sphincter of the internal ring (6). Hernia is a general term that describes a bulge or protrusion of tissue or an organ through a defect in an anatomical structure (7). An inguinal hernia is described as an out-pouching of peritoneum through the muscles of the anterior abdominal wall in the groin at the level of the inguinal canal, which may or may not contain preperitoneal contents (8).

1.2.2. Types of inguinal hernia

Inguinal hernias can be classified as either direct or indirect based on their anatomical location in relation to the inferior epigastric vessel. Direct hernias pass medially to the inferior epigastric vessel, whereas indirect hernias pass lateral to it.

1.2.2.1. Direct inguinal hernia

The main risk factors for the development of indirect hernias are accumulative mechanical exposure and a patent processus vaginalis (6). The processus vaginalis is formed by peritoneal protrusion during the descent of the testes which occurs between the 28th and 36th week of development, where after following the descent it normally extirpates between 36–40 weeks of gestation (8, 9). When this self-obliteration fails to occur, a pathway between the abdominal and scrotum is created resulting in a hernia sac that passes through the internal inguinal ring. The hernia runs within the inguinal canal and can exit through the superficial inguinal ring. Most indirect inguinal hernias are found in male children with an increased incidence in premature infants (6). The majority of all inguinal hernias in the pediatric population are indirect due to late or incomplete closure of the processus vaginalis. In 60% of children, it is closed within the first two years of life (5). The right testis descends at a slower rate than the left making right sided hernias more common in the male pediatric population (6). The equivalent of the processus vaginalis in females is the

canal of Nuck, which normally closes within the first year of life (10). The failure to close allows for the herniation of abdominal contents to occur in females (10).

1.2.2.2. Indirect inguinal hernia

The main risk factors for the development of indirect hernias are accumulative mechanical exposure and a patent processus vaginalis (6). The processus vaginalis is formed by peritoneal protrusion during the descent of the testes which occurs between the 28th and 36th week of development, where after following the descent it normally extirpates between 36–40 weeks of gestation (8, 9). When this self-obliteration fails to occur, a pathway between the abdominal and scrotum is created resulting in a hernia sac that passes through the internal inguinal ring. The hernia runs within the inguinal canal and can exit through the superficial inguinal ring. Most indirect inguinal hernias are found in male children with an increased incidence in premature infants (6). The majority of all inguinal hernias in the pediatric population are indirect due to late or incomplete closure of the processus vaginalis. In 60% of children, it is closed within the first two years of life (5). The right testis descends at a slower rate than the left making right sided hernias more common in the male pediatric population (6). The equivalent of the processus vaginalis in females is the canal of Nuck, which normally closes within the first year of life (10). The failure to close allows for the herniation of abdominal contents to occur in females (10).

1.2.3. Incidence

The lifetime risk of developing an inguinal hernia is around 27% for men and 3% for women (6). An inguinal hernia will affect almost 25% of men and less than 2% of women over their respective lifetimes with these percentages increasing in the case of a positive family history (11). In childhood, the numbers vary with the incidence ranging from 0.8–4.4% (9). The likelihood of hernia development is significantly higher in premature infants, especially those weighing less than 1000 g at 30% (9). Inguinal hernias account for 75% of all abdominal wall hernias and thus constitute the majority encountered in clinical practice (11). The incidence of inguinal hernias has a bimodal distribution, with peaks at age 5 and after age 70, respectively. Males account for the vast majority of inguinal hernias at 90% whilst females contribute about 10%, making it a male pre-dominance of 9:1 (11). The majority of hernias are indirect, making them the most common

hernia in both genders and almost all hernias in children are indirect. Although indirect hernias are more common, direct hernias have a higher likelihood of recurrence after surgical repair (6). Indirect hernias occur more often on the right and this is thought to be attributed to the slower closure of the processes vaginalis and the slower descent of the testes on the right side compared to the left side (11). In children the development of hernias occurs from prematurity to 18 years of age, with an average age of 3.5 years and a male-to-female ratio of 3:1 (12). The incidence of hernia location in a recent study on 6 826 pediatric patients, revealed that 59.5% are right sided, 33.7% left sided, and 6.8% bilateral hernias, almost all of which presented as indirect hernias (12). Inguinal hernias seem to be clustered amongst families pointing to a multi factorial inheritance pattern (6). Other possible etiological factors are; high intra-abdominal pressure, smoking, age, connective tissue alteration, connective tissue disorders, low body mass index, and male gender (6).

1.2.4. Clinical findings

Inguinal hernias can present with a multitude of symptoms or none at all. The majority of patients will present with a unilateral bulge or pain in the groin area that gets worse as it enlarges. This lump may or may not be reducible depending on if it is incarcerated. In general, inguinal hernias cause moderate discomfort that usually increased with physical activity. The onset of symptoms may be slow or sudden in the case of incarceration and strangulation (7). Some patients may describe a sudden pain that appears while lifting or straining (5). The pain associated with the hernia may be reproduced or worsened with activity or Valsalva maneuvers and may radiate downwards to the leg or scrotum (11). Direct hernias typically produce fewer symptoms than indirect hernias and are less likely to become incarcerated or strangulated (5). If there is tenderness, redness, nausea or vomiting then strangulation should be suspected, which is a surgical emergency and requires immediate treatment (7). Incarcerated hernias are swollen and painful and can result in obstipation or erythema of the testis (*Figure 4*). In general, one-third of patients have no pain, and severe pain is uncommon (1.5% at rest and 10.2% on movement) (7). Inguinal hernias are not usually painful unless incarceration or strangulation has occurred (7). These symptoms can occur during activity and disappear when patients are in a supine position. In infants and children, the diagnosis of inguinal hernia is suggested when crying persists for an extended period and when there is history of a bulge.

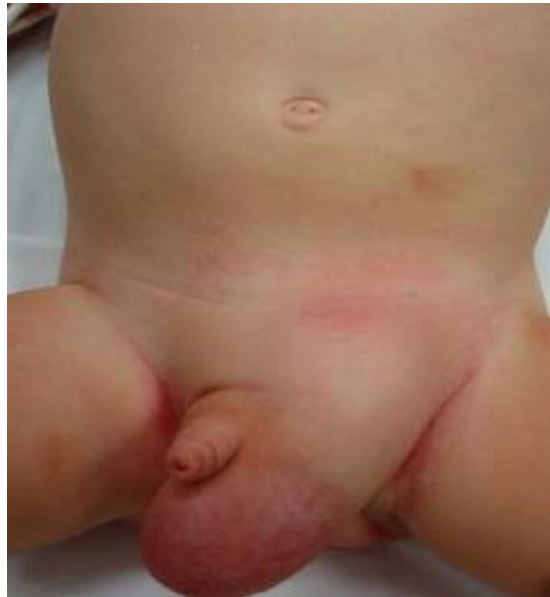

Figure 4. Incarcerated left inguinal hernia in a 2-year-old patient

Source: Archive of Department of Pediatric Surgery, University Hospital of Split

1.2.5. Complications

A multitude of complications can be associated with inguinal hernias. Complications can arise from surgical intervention or from an untreated hernia. Risk factors for acute complications are more common in the elderly population and in individuals suffering from a longer duration of both hernia and irreducibility (8). The major complications associated with untreated hernias are incarceration and strangulation usually caused by entrapment due to a narrow neck. Hernias are considered reducible if the contents can be pushed intra-abdominally. Failure to reduce the contents of a hernia means that is classified as incarcerated. Strangulation occurs once the hernial contents become ischemic due to insufficient blood flow (13). The overall risk of a hernia becoming either strangulated or incarcerated is 1–3% over an individual's lifetime (13). Although normal hernias present with mild symptoms and as a bulge an incarcerated hernia may present with symptoms of bowel obstruction such as nausea, vomiting and constipation. Any redness or tenderness at the bulge is suspect for strangulation and surgical consultation should be sought. Furthermore, if the hernia becomes strangulated the patient will have severe pain out of proportion and is at risk of

sepsis due to intestinal contents entering the bloodstream, which would ultimately lead to hypotension and tachycardia making this a medical emergency (13).

1.2.5.1 Complications of surgical invention

The rate of complications that follow an elective hernia repair are 10% in total (11). The most reported complications include seroma, hematoma, urinary retention, sexual dysfunction, reoccurrence, chronic pain and surgical site infection (11). Overall hernial repair is associated with a relatively low reoccurrence rate. Recurrence is associated with technical factors and comorbidities. Comorbidities that increase the chance of recurrence are smoking, steroid use, diabetes, malnutrition, and chronic cough. The primary complication following hernia repair is the persistence of chronic pain due to damage of the ilioinguinal, genitofemoral, or iliohypogastric nerves (11). Chronic pain persists after the normal healing process has occurred which is normally three months post-surgery and is the most common long-term complication of hernial repair (8). Risk factors for the development of chronic pain include young age, female gender, preoperative chronic pain syndromes like fibromyalgia, preoperative pain, and the failure to identify nerves during operation (14). Moreover, any structures in the vicinity of the hernia can be injured during the operation including, the bladder, intestine, testes and vas deferens. Infertility can occur following hernia repair as injury to the vas deferens is estimated to be about 0.3% for adults and 0.8–2% in children (15). Moreover, an incarcerated hernia can also lead to testicular hypoperfusion and result in injury to the testis that leads to atrophy. This may occur in up to 0.5% of all primary repairs with a ten-fold increase in the repair of recurrent hernias (15). Blood vessel injury to the epigastric and iliac blood vessels is also a common complication, requiring special attention throughout the operation to avoid injury. Out of these intra-operative complications epigastric vein puncture was the most common complication associated with laparoscopic surgery.

1.2.6. Types of hernias

Inguinal hernias are the most common and several classifications are possible. The most common of these being the Aachen hernia classification and the Nyhus classification (16).

The definition of a *Richter hernia* is a herniation of a circumference of the bowel which includes only a portion of a wall through the fascial defect (5). Richter hernias develop in small fascial defects in the anti-mesenteric portion of the bowel. Many cases show that the segment of the terminal ileum is involved (5).

Littré hernia is the protrusion of a Meckels diverticulum through the abdominal wall. Littre hernias begin with the failure of the vitelline sac to involute which will lead to the formation of Meckels diverticulum. Littre hernias present with symptoms such as dyspepsia, abdominal cramps, pain, and anorexia with malaise (5).

Amyand's hernia is an incarcerated inguinal hernia and acute appendicitis. Amyand's hernia occurs when the appendix is present within the incarcerated hernial sac. This can lead to further complications such as strangulation and appendiceal perforation, which could lead to peritonitis and abscess formation. Moreover, Symptoms similar to appendicitis may also occur in these patients (5).

Incisional hernias occur in scar tissue located at sites of previous surgical interventions. Scar tissue is functionally weaker than normal tissue and is therefore more likely to produce a hernia (17). Moreover, any factor that impairs normal wound healing like diabetes or malnutrition will contribute to the formation of an incisional hernia (16).

Umbilical hernias arise at weaknesses located near the belly button which is a natural hernial opening in the abdominal wall (16). They are most commonly found in premature infants and obese adults (17). Umbilical hernias tend to spontaneously resolve in children especially if they are less than 1.5cm in size (16). Larger hernias in adults and children should be repaired to prevent the development of complications.

Femoral hernias are less frequent than inguinal hernias and occur in the femoral canal typically presenting as a bulge below the inguinal ligament more commonly on the right side (18). These types of hernias have the highest risk of strangulation at up to 30% (15). Although inguinal hernias have a strong male predominance, femoral hernias have a female-to-male ratio of 10:1 making

them significantly more common in women (18). The prevalence of femoral hernias and the risk of complications both increase with age. Therapy of femoral hernias is operative management.

1.2.7. Diagnostic approach

The majority of inguinal hernias can be diagnosed by a proper physical examination and history. One report has the sensitivity and specificity of physical examinations at 75% and 96%, respectively (19). Physical exams are the mainstay of diagnosis and are considered the best way to diagnose hernias (11). The inguinal and femoral areas should be closely examined for bulges while the patient is standing and a Valsalva maneuver should be performed to observe for worsening of symptoms or the appearance of a bulge. The examiners finger should start at the scrotum and follow the spermatic cord into the external inguinal ring and follow the course of it through the inguinal canal. While the examiners finger is in the canal the patient coughing or straining will enable the physician to feel a palpable mass if present (*Figure 5*). In children too small to cough on demand, the alternative approach is holding their limbs until they cry, which results in increased intra-abdominal pressure (9). If a mass or bulge is detected the diagnosis of inguinal hernia is established. In females it is often more difficult to diagnose a hernia with physical examination but palpating the groin area with an open hand may reveal an impulse or bump upon the patient straining or performing a Valsalva maneuver (7). Examination of the opposite side is of utmost importance as this allows the physician to compare and contrast the two. Differentiating between direct and inguinal hernias is often unnecessary and has no impact of further decision making since surgery is the ultimate outcome regardless if symptomatic. If a bulge is not present the silk glove sign has been considered an alternative in the pediatric population (9). This sign can be evoked by rolling the spermatic cord structures along the pubic tubercle, wherein the sensation of the sac moving on itself is a positive sign (9). Diagnostic investigation is rarely needed to diagnose a hernia but it can be useful in certain situations like recurrent hernias, severe pain, swelling, hydrocele or in difficult cases when the diagnosis is uncertain (7). Modalities that can be of use are ultrasound, Computer Tomography (CT) and Magnetic Resonance Imaging (MRI). Ultrasonography for groin hernia detection has a sensitivity that is greater than 90% and a specificity of 82-86% (19, 20). Ultrasound can delineate large hypoechoic structures within the inguinal canal, which can point to the diagnosis of a hernia. CT scans are of use when the diagnosis is in question as they have a sensitivity of 80% and a specificity of 65% (11). The role of CT is limited but it can be done in the

case of urinary bladder involvement and for the evaluation of intra-abdominal pathologies that could be responsible for an increase in intra-abdominal pressure (5). Furthermore, MRI can also be used as it has the highest sensitivity and specificity at 95% and 96%, respectively, although it is costly and rarely done (11). Additionally, MRI can be useful in the differentiation of soft tissue and sports injuries (5).

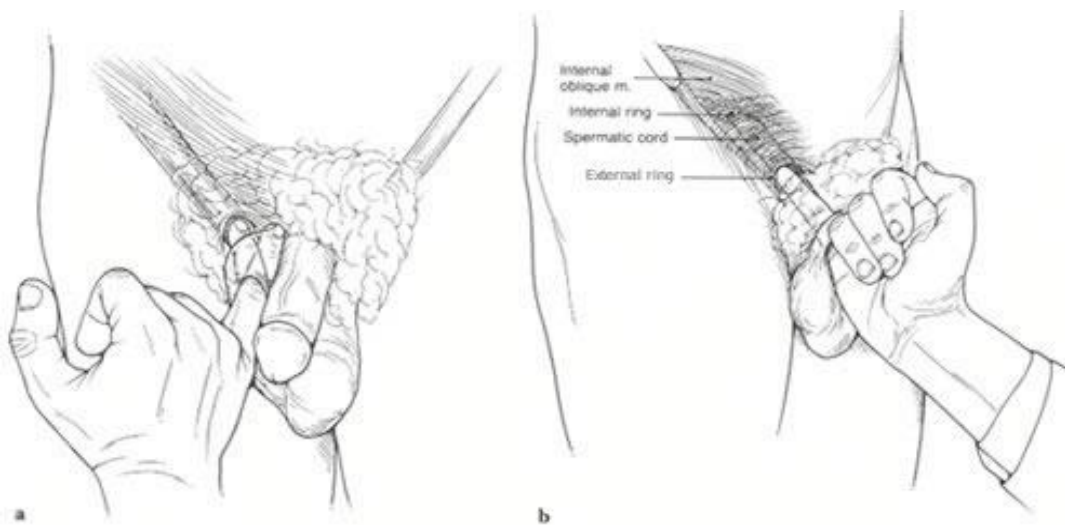


Figure 5. Palpating the external ring of the inguinal canal.

Source: <https://www.sportshernia.com/sports-hernia-approach/sports-hernia-examination>

1.2.8. Treatment

The ultimate end goal of inguinal hernia treatment is surgical repair. Surgical repair alleviates symptoms, improves quality of life, decreases recurrence rates and prevents the appearance complications such as strangulation or incarceration. A general rule of thumb is that any symptomatic hernia should be repaired, especially those that present with significant pain or discomfort (7). In adult males, if the hernia is asymptomatic or minimally symptomatic watchful waiting can be an option until the hernia becomes bothersome, since the chance of incarceration is relatively low at 0.3–3% per year (5). Strangulated hernias may present as acute abdomen and are a medical emergency requiring urgent intervention. Consequently, in children the situation is a bit

different because all hernias whether symptomatic or not should be repaired to prevent complications, especially in those under 12 months of age (18). A watch and wait approach is not indicated in children to prevent the possible advent of infertility due to incarceration and ischemic damage to the testes. There are very few contraindications for the repair of inguinal hernia, pregnancy and active infection being the two major ones. Furthermore, incarcerated hernias in children can be reduced manually using a technique called taxis assuming there is no peritonitis or bowel compromise (9). In these situations, recurrence is high and these children should be enlisted for surgery within a couple of days of performing the maneuver (9).

1.2.9 Surgical techniques

Inguinal hernia repair is one of the most common procedures encountered within general surgery. The goals of surgical intervention include repairing the weakness in the abdominal wall and reducing the hernial contents. There are currently two types of operations in use, these being the open and laparoscopic methods.

1.2.9.1. Open surgery

Open repair with high ligation of the hernial sac is the gold standard in children and is known as open herniorrhaphy (18). Once incised and revealed the hernial sac is separated from the spermatic cord structures and nerves then dissected to the level of the internal inguinal ring where it is ligated (12, 18). The most commonly used approaches in pediatric population are the Marcy and Ferguson techniques (21). Henry Marcy, a Boston surgeon reported two cases of inguinal hernia repair in which high ligation and excision of hernia sac were performed, with narrowing of the internal inguinal ring achieved by two carbolized catgut sutures. During this procedure, plication of the transversal fascia was performed, and enough space was left for the spermatic cord (21). Ferguson's technique does not change the position of spermatic cord, but in this technique, transverse and internal oblique abdominal muscles are fused with the inguinal ligament (12). A modified version of the Marcy repair is now the optimal repair technique for inguinal hernias, being associated with the lowest incidence of recurrence. During narrowing of the internal ring, the surgeon must be careful to avoid strangulation of the spermatic vessels. A Marcy repair, which entails narrowing of the dilated internal ring can be done alongside the high ligation. The recurrence

rate of open repair with high ligation is around 0.3–1% (12, 18). Unlike adults, mesh repair is not indicated in children and can even be contraindicated.

1.2.9.2. Laparoscopic surgery

Although open repair with high ligation is considered the gold standard by many surgeons, laparoscopy is gaining popularity and is becoming an alternative approach to open herniorrhaphy. Although being the gold standard, open herniorrhaphy has the potential to injure the spermatic vessels, vas deferens, and testes. The advantages of laparoscopy include, exceptional visualization, minimal tissue damage, fewer complications, low wound infection rates, improved cosmetic results, and in experienced surgeon's comparable recurrence rates (22). Furthermore, laparoscopic exploration allows evaluation of the contralateral side in unilateral hernias with a low risk of injury to the vas deferens and spermatic vessels. The downfall to this approach is the difficulty in differentiating between a patent process vaginalis and a true hernia, expenses, and a greater learning curve compared to open herniectomy (9, 23). Furthermore, laparoscopic repair takes longer compared to open herniectomy, although this time is reduced with increased experience (24). There are various techniques and methods with laparoscopic surgery, but the trend is going toward extracorporeal suturing and the single-port access techniques (23). The main laparoscopic techniques are the extracorporeal and intracorporeal approach consisting of either a three or single port procedure (23). The extracorporeal technique is being increasingly employed because of its safety, simplicity and feasibility. It also has a low recurrence rate since the sac is entirely ligated (23).

1.2.9.3. Percutaneous Internal Ring Suturing (PIRS)

Dariusz Patkowski is the individual responsible for the introduction of PIRS. This is a technique that is now commonly used in pediatric centers throughout the world (25-29). This is a single port technique requiring only one 3 or 5-mm port for achieving pneumoperitoneum and for the introduction of the laparoscope. Furthermore, this technique involves the closure of the internal inguinal ring using a spinal needle that is controlled with a laparoscope (25-29) (*Figure 6*). PIRS is less technically demanding in comparison to the tradition three port laparoscopic procure that requires intracorporeal suturing (25-27). The benefits to PIRS are the excellent cosmetic results because it only requires a single port and few operative complications in the hands of an

experienced surgeon (27). After the introduction of the PIRS technique first published reports had been associated with higher recurrence rates and residual hydroceles (25). New studies have reported recurrence rates of 0.5–0.7%, which is very similar to those in open surgery (25, 26, 29). Additionally, operative time was reported to be lower than open surgery, with unilateral hernias averaging 10 minutes and bilateral 15 minutes (27, 30). Furthermore, the single port requirements along with the spinal needle suturing, reduces the operative stress on the body, thereby reducing postoperative pain with children usually returning to daily activities the very next day (25, 27, 31). As with any surgical technique, PIRS is not without complications. An incidence of complications in hands of experienced laparoscopic pediatric surgeon is very low. The most common reported complications are injury of blood vessels, recurrence, hydrocele formation, knot reaction, severe pain, and scrotal swelling (30). Care should be taken to not injure the spermatic cord or vessels, although the risk is significantly higher in traditional open surgeries (30). In a case of vascular structure injuries, laparoscopic surgery may be completed only in the absence of further bleeding and growth of retroperitoneal hematoma. If that is not possible, conversion to open surgery should be performed (27). Many surgeons doubt whether the PIRS technique has a negative effect on testicular blood perfusion. As the internal ring is not closed with circular suturing as in intracorporeal laparoscopic techniques, and closed by suspending to the abdominal wall, the potential risks may be impaired testicular blood flow resulting in strangulation of the testicular vessels by percutaneous sutures. Several studies confirmed that PIRS is a safe technique for inguinal hernia repair in children with respect to testicular vascularization (32, 33). PIRS also allows the visualization and repair of a contralateral hernia without the need to introduce additional trocars or incisions.

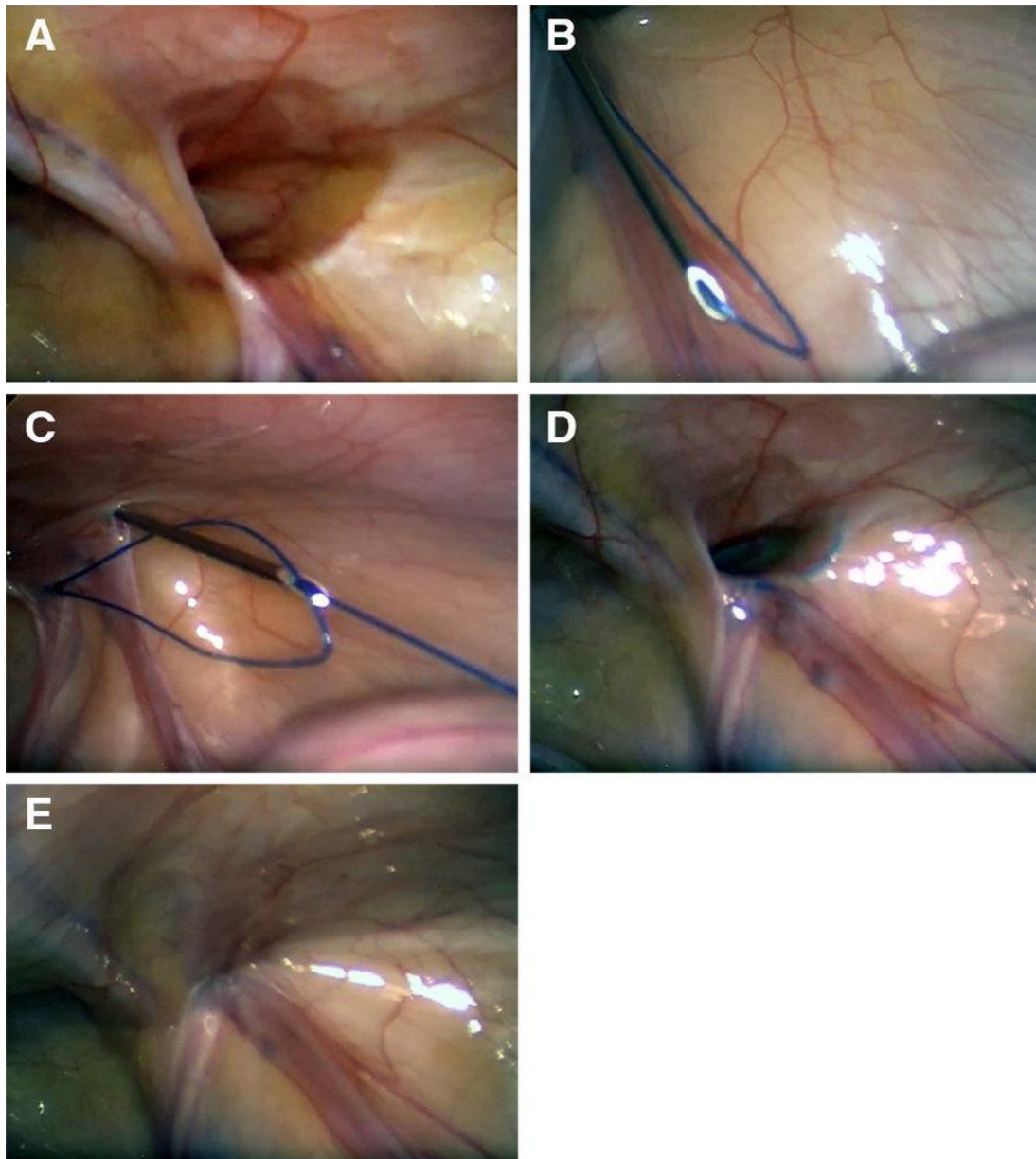


Figure 6. PIRS technique in 3-year-old male patient with a right inguinal hernia: A – Open internal inguinal ring; B – Introduction of a non-absorbable monofilament nylon loop through half of the inguinal canal. C – Through the previously introduced loop the suture is pushed through the needle; D – After removal of the needle, the loop was drawn out and the knot passed around internal ring; E – Closed internal ring (31).

Therefore, PIRS maintains the advantages associated with laparoscopic surgeries, but minimizes port placement, and gets rid of the need for intracorporeal suturing, which is both difficult and time consuming (30). Cosmetic results after PIRS are extraordinary. Usually, after a short period of time, the scar is almost invisible. Rarely, very skinny patients may complain of a palpable subcutaneous suture (25-27). Another benefit of the PIRS technique using a single umbilical port, comparing with 3 port techniques, is the possibility of achieving appropriate airway management using a laryngeal mask airway with no muscle relaxant as a safe alternative to tracheal intubation. Laryngeal mask airway has proven to be safe and effective for less invasive, short-lasting, laparoscopic techniques (PIRS) with a low insufflation pressure of 6 to 8 mmHg (34).

1.3. Learning Curves

In general, learning curves compare the relationship between experience and outcome. The first use of these curves in medicine came in the 1980s to describe the attainments of new surgical skills in minimally invasive surgeries such as laparoscopy (35). Nowadays, the use of these curves is steadily increasing in research, randomized control trial design, competency assessment, healthcare education, and for the designs of various training programs (35). Learning curves in surgery are related to training and the attainment of medical education. When a surgeon learns a new procedure they generally improve with experience and plotting experience versus performance as a graph results in the creation of a learning curve (36). The outcomes related to learning a new surgical method can be measured as surgical process and patients' outcomes. Factors involved in the surgical process can include; operative length, blood loss, re-operation rate, conversion to open procedure in minimally invasive surgeries, extent of resection, margin involvements and lymph node yield (36). Furthermore, factors for patient outcomes include; analgesia requirements, transfusion requirements, length of hospitalization, side effect incidence, cosmetics results, morbidity and mortality rates, and overall survival (36). Learning curves are complex functions and as a result contain various stages (*Figure 7*). The beginning stage is known as the initial curve, where there is generally a stepwise improvement in learning that can be applied across all medical specialties and procedures (35). There is a theory that states that learning occurs slower when an operator becomes more competent at a skill. This inevitably leads to reaching an expert plateau (35). Some factors that may affect the rate of learning are related to the individual at hand, such as previous experience, motivation, natural talent and the ability to acquire new skills. The plateau

that is inevitably reached does not necessarily indicate an expert level but instead signifies when retardation of learning has occurred. The last stage is the redirection of performance. After the plateau has been reached there is usually a slight decline in performance, this can usually be attributed to overconfidence and the ascertainment of more difficult operations (35). The second decline is attributed to aging and the process of forgetting. This decline can be related to the physiological effects of aging, which include; decreased dexterity, eyesight, memory and cognition (36). Learning curves can be applied to medical training, as newly appointed physicians must recognize the need to continue post accreditation training to facilitate continued medical education.

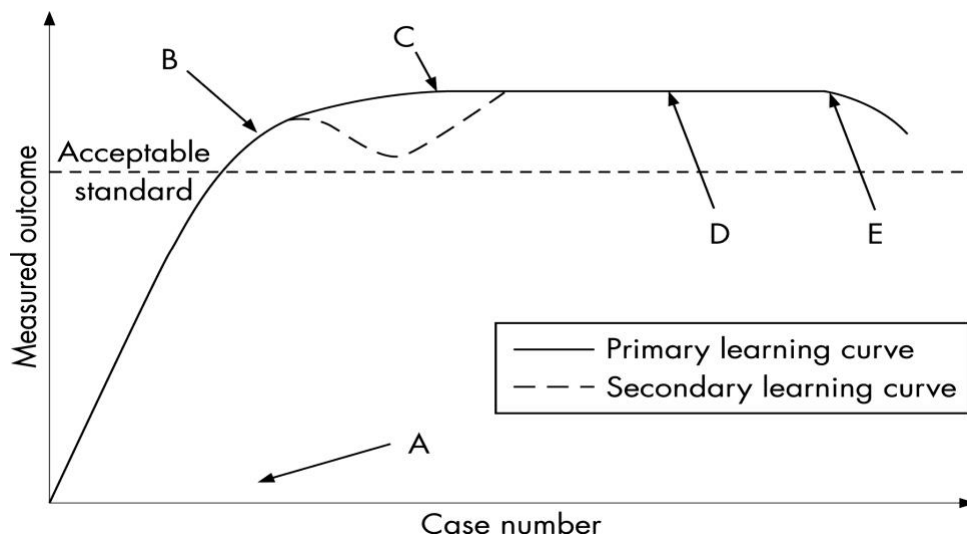


Figure 7. Illustrated is a learning curve: *A* – First stage - the initial rise; *B-D* – expert plateau; *E* – Decline associated with aging (36).

1.3.1 Learning curves in laparoscopic surgery

Laparoscopic surgery skills are not a natural behavior and need to be learned through hands-on experience and training (37). There is a general trend amongst studies that shows a decrease in the rate of complications with an increased number of procedures performed. Traditional surgical learning is through direct tactile feedback and tissue visualization (38). Laparoscopy removes three-dimensional visualization, tactile sensation and has the drawback of set port sites, which ultimately limits surgeon mobility (37). These limitations create a different learning curve than that of traditional open surgery. Thus, skills acquired through open surgeries cannot be directly transferred to minimally invasive surgery as they have their own skill requirements and require a vastly different approach to training and mentorship (37). Studies show that the post and peri-operative complications of PIRS eventually reach a nadir. Following the nadir PIRS becomes a safe and effective approach to the treatment of inguinal hernias. Recent studies showed that each surgeon reached the plateau of the learning curve after at least 30–35 cases performed, measuring peri-operative complications, ipsilateral recurrence, and conversion rates (38). Operative time was reduced after about 25–30 procedures per surgeon (39). Furthermore, surgeons with an elevated level of experience with minimally invasive procedures adopted the technique more easily and had significantly lower operative times and peri/post-operative complications (39).

2. OBJECTIVES OF RESEARCH

The surgical repair of inguinal hernias is one of the most commonly performed surgical procedures in the pediatric population. All inguinal hernias ultimately need to be treated surgically to prevent the occurrence of serious complications. Presently, PIRS for hernia repair is a new type of surgical technique with significant advantages in comparison to the current gold standard of open surgical repair.

This study aimed to analyze the learning curves during the implementation of PIRS in the Department of Pediatric Surgery at University Hospital of Split. The aim was to investigate the amount of experience needed to acquire the skills to perform PIRS safely.

Hypotheses:

- 1) PIRS is a simple, safe, and effective technique for inguinal hernia repair in children with excellent outcomes and cosmetic results given adequate surgeon experience.
- 2) Each surgeon reached the plateau of the learning curve after at least 30 cases performed, measuring peri-operative complications, ipsilateral recurrence, and conversion rates.
- 3) The incidence of complications and recurrence rates using PIRS technique for inguinal hernia repair in children are significantly lower in hands of experienced surgeons, compared to surgeons with lesser experience in laparoscopic surgery.
- 4) Operative time was reduced after about 25–30 procedures per surgeon.

3. PATIENTS AND METHODS

3.1. Patients

A total of 318 patients who underwent hernia repair using the PIRS technique in the period between October 2015 and January 2021 were included in study.

Inclusion criteria: Patients of both genders, up to 17 years of age, with an inguinal hernia treated by the PIRS; patients operated in University Hospital of Split by one of the three surgeons included in the study and the patients followed-up at least 3 months after the surgical procedure.

Exclusion criteria: Patients older than 17 years of age; patients lost from the follow-up; patients who required conversion to an open procedure; patients with a follow-up less than 3 months and the patients with incomplete data.

3.2. Organization of the study

The study was carried out as a prospective cohort study using corresponding quantitative research and descriptively processed data.

3.3. Place of the study

The research took place at the Department of Pediatric Surgery, University Hospital of Split, Croatia.

3.4. Methods of data collection and processing

Demographic and clinical data, intraoperative findings, level of pneumoperitoneum, surgical and anesthesia time, intraoperative time, intra and post-operative complications, and outpatient follow-up results were recorded in the Study protocol (*Supplement 1*). The corresponding data was obtained by revising the study protocols and medical records. The data were analyzed using the Microsoft Excel for Windows Version 11.0 (Microsoft Corporation) and SPSS 24.0 (IBM Corp, Armonk, NY) software programs. The significances in the difference between the quantitative variables between of the surgeons was assessed using the analysis of variance (ANOVA). The chi-square test was used for the differences in the distribution of categorical data unless the frequency of events was low in which case the Fischer exact test was used. All the tests were double-sided and a significance level of 0.05 was used throughout.

3.5. Description of research

All the surgeries were performed by three surgeons with different levels of experience in laparoscopic surgery. The first surgeon (Surgeon A) was 28 years of age with basic laparoscopic experience, the second surgeon (Surgeon B) was 35 years of age with advanced experience in laparoscopic surgery, and the third surgeon (Surgeon C) was 53 years of age with moderate experience in laparoscopic surgery. The patients were admitted to the hospital on the day of surgery. Medical history and demographic data were recorded in the Study protocol. The patients were followed-up in the out-patient clinic. Braided adhesive skin sutures were removed at seven days after their first visit. A postoperative follow-up program consisted of a physical examination after one, six and twelve months, in order to assess the presence of post-operative complications or hernial recurrence.

3.6. Outcome measures

The primary outcome was to evaluate the learning curve of PIRS. The secondary outcome was to determine if age or level of previous experience of the surgeons had any influence upon the learning curve.

3.7. Compliance with ethical standards

All procedures performed in studies involving human participants were in accordance with ethical standards of the institution and/or national research committee and with the 1964 Helsinki declaration and its later amendments or comparable ethical standards. Authors declared that the research was conducted according to the principles of the World Medical Association Declaration of Helsinki “Ethical Principles for Medical Research Involving Human Subjects”. Patients were informed in detail and informed consent was obtained from the parents or legal guardians of the patients to use the data. The study protocol was approved by the Ethics Review Board of University Hospital of Split with reference No. 2181-147-01/06/M.S.-20-9 (Supplement 2).

3.8. Surgery

The surgery starts with a 3-mm supraumbilical incision, where after a Veress needle is used to reach a pneumoperitoneum of 6–10 mmHg, depending on the patients' weight and age. A 3-mm port is inserted through the supraumbilical incision. Visualization of the open internal inguinal ring is achieved with a 3-mm laparoscope on the same side as the hernia (*Figure 8A*). A small skin incision of 2 mm is performed in a position above the internal ring. A 20G spinal needle (ELDOR CSEN 38.4; Quincke Spinal Needle, Z.R.M.I. Co. Ltd. Jerusalem, Israel) is used together with a non-absorbable monofilament nylon loop (Prolene™ 3-0, polypropylene, Ethicon®, Cincinnati, Ohio, USA) at one side of the internal ring, preventing multiple entrances to the peritoneal cavity and decreasing the likelihood of damaging the spermatic cord and blood vessels and to take as much off of the edge on the entered side of the internal ring (*Figure 8B*). The loop is positioned in the peritoneal cavity while the spinal needle is taken out, with care not to pull the loop out simultaneously. The same procedure with the same needle was done on the other side of the internal ring (*Figure 8C*). The needle is passed through the previously positioned loop and the same suture is passed through the needle (*Figure 8D*). After the needle has been removed and the loop withdrawn, the second suture is held passing it out through the skin incision and then tying it, thus obliterating the internal ring (*Figure 8E*). Successful hernia repair is achieved if occlusion of the hernia is visualized through a camera (*Figure 8F*). A round gauze ball is placed on the umbilical wound with a sterile drape above it and the small inguinal wound is closed using braided adhesive sterile skin closures (3M™ Steri-Striptm, Neuss, Germany).

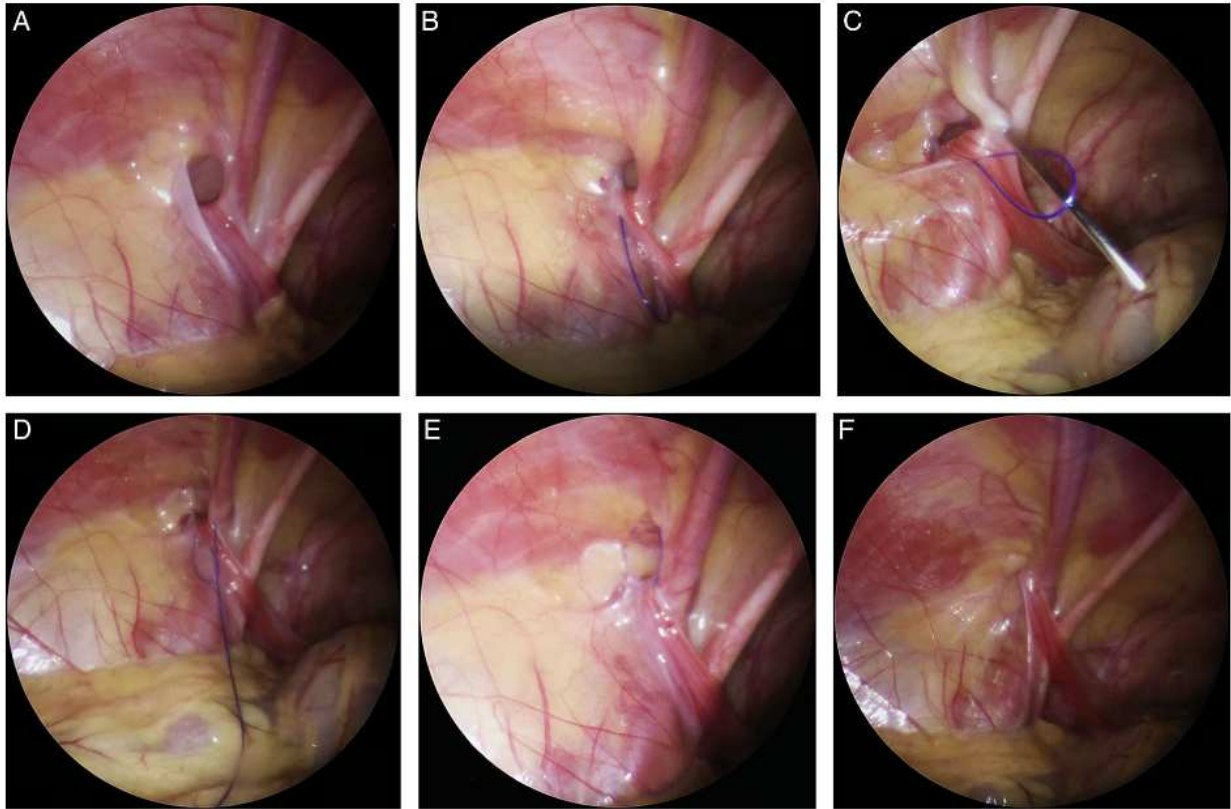


Figure 8. PIRS technique: A – Open internal inguinal ring; B – Introduction of a nylon loop; C– Introduction of the needle on the other side of the internal ring; D – Needle and suture passed through the previously introduced loop; E – The loop drawn out and the knot passed around internal ring; F – Closed internal ring (27).

4. RESULTS

4.1. Demographic and clinical data

A total number of 372 PIRS procedures in 314 children (126 (67%) males) with median age of 4.5 years (IQR 2, 6.5) were performed. There were 181 (57.6%) right, 75 (23.9%) left, and 58 (18.5%) bilateral hernia repairs. Among all performed PIRS procedures there were three conversions to open surgery. The median duration of surgery (time between first incision to completion of the skin closure) for unilateral and bilateral inguinal hernias was 16.5 min (IQR 15, 25) and 21.2 min (IQR 20.8, 23.8), respectively. The median postoperative hospital stay was 1 (IQR 1, 1) day and median follow-up was 44 (IQR 32, 50) months.

4.2. Complications

During the study period there were four (1.3%) intraoperative complications and seven (2.2%) postoperative complications. Regarding intraoperative complications four (1.3%) inferior epigastric vein injuries were recorded, injuries were treated conservatively without any consequences. During the follow-up period in five male children hydrocele was recorded, in four cases hydrocele resolved spontaneously within three months while one (0.3%) required surgical treatment. In two (0.6%) patients swelling of the tissues around the upper pole of the groin was recorded, which finally resolved up to six months after surgery. One case (0.3%) of hernia recurrence was recorded.

4.3. Individual learning curve

Three surgeons in our department adopted PIRS as the technique of choice for treatment of pediatric inguinal hernia. Each of these performed a minimum of 74 surgeries. Demographic characteristics of the patients were similar among the surgeon's (Table 1).

Table 1. Comparison of demographic data and treatment outcomes among surgeons.

	Surgeon A (n=90)	Surgeon B (n=150)	Surgeon C (n=74)	P
Demographic data of the patients				
Age (years)	5	4.5	4.5	0.571*
Median (IQR)	(2, 6.5)	(2, 6)	(1.5, 7)	
Gender Male	62 (69)	101 (67)	46 (62)	0.636†
n (%) Femele	28 (31)	49 (33)	28 (38)	
Weight (cm)	111	109	109	0.441*
Median (IQR)	(92, 123)	(94, 130)	(97, 128)	
Height (kg)	18	18	18.5	0.801*
Median (IQR)	(14, 25)	(14, 26.5)	(13, 26)	
BMI (kg/m ²);	17	18	17.5	0.684*
Median (IQR)	(14, 17.7)	(14.5, 18.1)	(14.9, 18.6)	
ASA classification, n (%)				
ASA I	84 (93)	139 (93)	68 (92)	0.891†
ASA II	6 (7)	11 (7)	6 (8)	
Lateralization, n (%)				
Left	21 (23.5)	35 (23)	19 (25.5)	
Right	49 (54.5)	90 (60)	42 (57)	0.839†
Bilateral	20 (22)	25 (17)	13 (17.5)	
Outcomes of treatment				
Duration of surgery (min)				
Unilateral repair	21 (16.5, 25)	12 (10.5, 16.5)	25 (21.5, 30)	0.002*
Bilateral repair	28 (25, 33)	19 (14, 21)	31 (24, 36)	0.0001*
Hospital stay (days)	1	1	1	>0.999*
Median (IQR)	(1, 1)	(1, 1)	(1, 1)	
Conversions, n (%)	1 (1.1)	0	2 (2.7)	0.432‡
Complications, n (%)	4 (4.4)	2 (1.4)	4 (5.4)	
Hydrocele	2 (2.2)	1 (0.7)	2 (2.7)	
Blood vesels injury	2 (2.2)	1 (0.7)	1 (1.4)	0.190‡
Recurrence	0	0	1 (1.4)	

*ANOVA; †Chi square test; ‡Fisher exact test

IQR – Interquartile range; BMI – Body mass index; ASA – American Society of Anesthesiologists

Regarding operative time, significant differences among the surgeons was found. Operative time decreased significantly after 25–30 procedures per surgeon. The surgeon with advanced experience in laparoscopic surgery had significantly fewer operative times for hernia repair, compared to the other two surgeons (*Figure 9*).

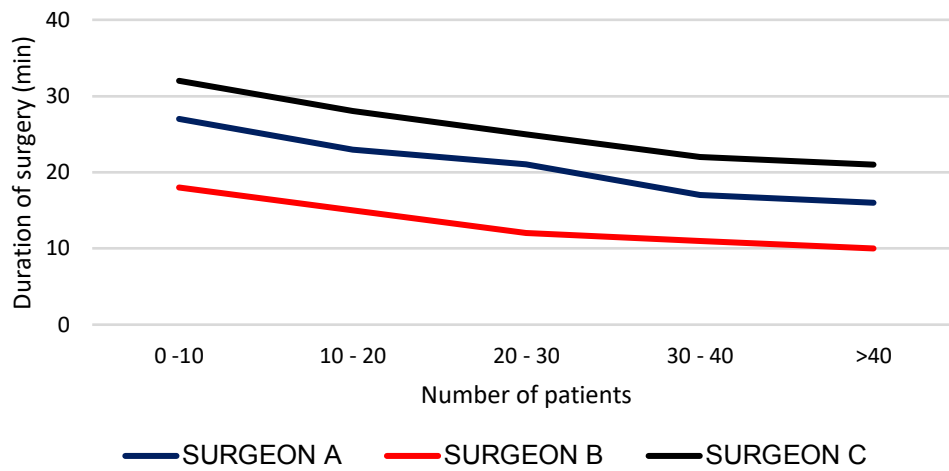


Figure 9. Individual learning curve - duration of surgery

A decline of the intraoperative complications was observed along the accumulated individual experience (Figure 10).

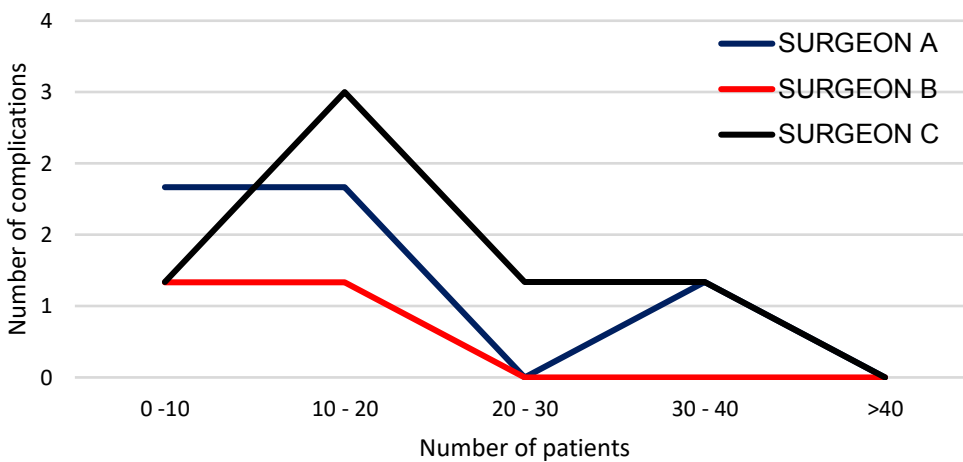


Figure 10. Individual learning curve - complication rates

Blood vessel injuries reached their nadir at the 20th surgery. No hydrocele and recurrence occurred after each surgeon's 33rd and 22nd case, respectively (Table 2).

Table 2. Individual learning curve – outcomes of the treatment

	Number of the patients				
	0–10	10–20	20–30	30–40	>40
Duration of surgery - unilateral repair (min)					
SURGEON A	27	23	21	17	16
SURGEON B	18	15	12	11	10
SURGEON C	32	28	25	22	21
Blood vessels injury (n)					
SURGEON A	1	1	0	0	0
SURGEON B	1	0	0	0	0
SURGEON C	0	1	0	0	0
Complications - Hydrocele / Recurrence (n)					
SURGEON A	0	1	0	1	0
SURGEON B	0	1	0	0	0
SURGEON C	0	1	1	1	0
Conversion rate (n)					
SURGEON A	1	0	0	0	0
SURGEON B	0	0	0	0	0
SURGEON C	1	1	0	0	0

There were no conversions after the 17th case of each surgeon. Individual differences between the surgeons regarding complications was also seen. The most experienced surgeon had the lowest number of complications (1.4%) and needed a fewer number of cases to reach the plateau, while the other two surgeons with less experience in laparoscopic surgery had higher rates of complications (4.4% and 5.4%) and needed a higher number of cases to reach the plateau, but this difference was not statistically significant ($P=0.190$). Similar findings were found regarding the conversion rates. The most experienced surgeon had a conversion rate of 0% while the other two surgeons had conversion rates of 1.1% and 2.7%, respectively ($P=0.432$) (Table 1).

4.4. Department learning curve

In the department-centered analysis, operative time for both unilateral and bilateral repair was significantly higher at the beginning of the study and achieved plateau after 45–60 patients ($P<0.001$) (Figure 11).

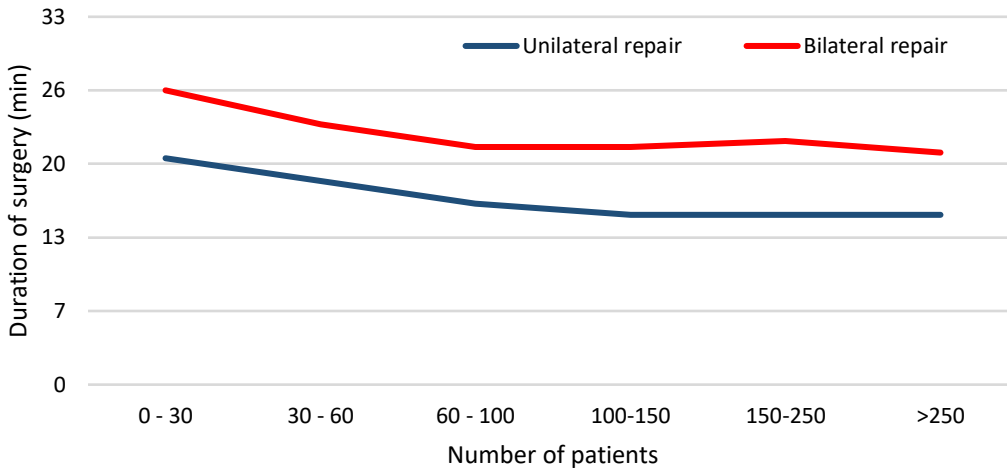


Figure 11. Department learning curve - duration of surgery

Complication rates were significantly greater in the first 30 patients and following that number the amount of complications significantly decreased (Figure 12).

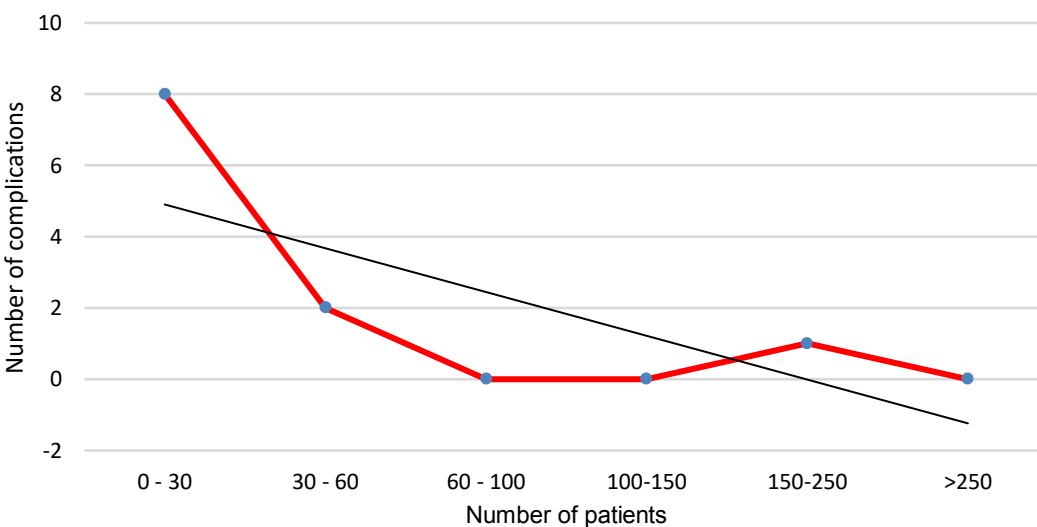


Figure 12. Department learning curve - complications

Conversion and recurrence rates decreased to zero after the first 30 patients (Table 3).

Table 3. Department learning curve – outcomes of the treatment

Outcome	Number of the patients					
	0–30	30–60	60–100	100–150	150–250	>250
Duration of surgery (min)						
Unilateral repair	20	18	16	15	15	15
Bilateral repair	26	23	21	21	21.5	20.5
Complications (n)						
Blood vessels injury	4	0	0	0	0	0
Hydrocele	4	1	0	0	0	0
Swelling in the groin	1	0	0	0	1	0
Recurrence (n)	1	0	0	0	0	0
Conversion rate (n)	2	1	0	0	0	0

5. DISCUSSION

This study assessed the learning curves of three surgeons from the same department with different levels of experience in minimally invasive pediatric surgery. The selected procedure was PIRS for the treatment of indirect inguinal hernias in the pediatric population. This study provided clear evidence that the duration of surgery was significantly reduced after 60–75 operated children independent on operating surgeon, or 25–30 subjects per operating surgeon. Also, the overall number of intraoperative and postoperative complications significantly decreased after 30–45 operated patients (independent on operating surgeon) and reached a minimum point after 60 total procedures. After 25–30 procedures per surgeon, the number of complications decreases to a minimum. The most common intraoperative complication was puncture of the epigastric veins and the most common postoperative complication was hydrocele formation, most of which resolved spontaneously. Conversion rates were low and there were no conversions after the 17th operative case for each surgeon. The surgeon with the most advanced experience in laparoscopic surgery had significantly fewer complications and shorter operative times compared to the other two surgeons. In general, 30 PIRS procedures per surgeon were required for perioperative complications, conversion rate and ipsilateral recurrence to reach the benchmark. Moreover, for surgeons with advanced experience in minimally invasive pediatric surgery 15–20 procedures per surgeon are adequate enough to reach the benchmark. The drawback in operative time was evident after 20 procedures per surgeon and reaches plateau after 30 procedures.

Open repair through inguinal incision including high ligation and resection of the hernia sac has been the standard of treatment for pediatric hernia for a long duration of time (22). With the development of minimally invasive surgery numerous laparoscopic techniques for pediatric inguinal hernia repair have been developed including intracorporeal suturing and an extracorporeal approach (23, 24, 25-29). According to recently published literature PIRS for pediatric inguinal hernia repair has been proven to be a safe and effective method (25-31). Although, the question on how much experience a surgeon needs to have to be able to perform this method safely without significant complications remains. Controversy regarding whether it is adequate for pediatric surgeons or trainees with a low level of experience to perform the procedure safely persists. Shibuya et al concluded that although there were individual differences, all trainees acquired the skill to perform PIRS adequately within ten months (40). Likewise, our study showed similar findings. One resident of pediatric surgery was included in this study. He showed significant improvement after the first 25–30 cases, and after reaching a plateau his results were better than

the results of the older surgeon with mild experience in laparoscopic surgery. Traditional laparoscopic hernia repair is time-consuming due to the need for intracorporeal suturing and the placement of multiple trocars. It has also been associated with increased postoperative pain and a higher recurrence rate (25-27). PIRS has been associated with a decreased level of pain due to decreased surgical stress and inflammatory response (25-27). Medians of surgical times for unilateral and bilateral repairs using PIRS technique are 10 min and 15 min, respectively (27, 30). Although operative time does not reflect the operative skill, smoothly performing the procedure is essential for the overall safety of the surgery. Taking extended time to perform the procedure causes edema and bleeding in the retroperitoneal space. Furthermore, distinguishing the testicular vessels and the vas deferens becomes increasingly difficult. In this study the operative time significantly decreased after 25–30 procedures per surgeon, and the surgeon with advanced experience in laparoscopic surgery had significantly less operative times. Similar findings were reported in recent literature (39, 40).

In the pediatric population the incidence of recurrence rates following open inguinal hernia repair is 0.5–4% (12, 18). Recurrence rates following standard three port laparoscopic hernia repair is slightly higher and ranges between 0.7–4.5% (25, 26, 29). After the introduction of the PIRS technique the first published reports had been associated with higher recurrence rates and residual hydroceles (25). This had been influenced by the inexperience of the surgeons, the use of absorbable sutures, and the use of a single suture for larger defects (33). Recently, it has been described that PIRS resulted in a significant reduction of recurrence rates and operative time (26, 28, 29). In this study postoperative hydrocele formation and recurrence rates were significantly greater in the first 30 patients. Subsequently, after the first 30 patients the number of complications significantly decreased. Barroso et al. reported similar findings in their study (39). Many pediatric surgeons selected female patients to start with as their anatomy appears more favorable (41). Barroso et al reported that most recurrences, in procedures performed by less experienced surgeons, occurred in females, because in many of them there is a fold of peritoneum under the round ligament that can easily be overlooked (40). We agree with this observation. Our most experienced surgeon supervised many of the cases of the less experienced surgeons and found a similar situation a few times during the surgeries, when a less experienced surgeon overlooked a fold of peritoneum. This was corrected during the surgery without any subsequent consequences. The most common

intraoperative complication is injury of the epigastric or iliac blood vessels (25, 26, 30, 40). Special attention is required while introducing or manipulating the needle around the internal inguinal ring in order to avoid injury of surrounding blood vessels. In this study epigastric vein puncture was the most common intraoperative complication, which reached its plateau at the 20th surgery. The more experienced surgeon had a lower incidence of this complication. This study demonstrates that independent of previous surgical experience in minimally invasive surgery, pediatric surgeons easily adhere to the implementation of a minimally invasive program to repair inguinal hernias. However, some limitations of this study are a relatively small population size and a short follow-up period. Results of this study would need to be correlated and compared with further analysis on more pediatric PIRS cases.

6. CONCLUSION

A PIRS learning curve for perioperative and postoperative complications, recurrences, and conversion rates reached the plateau after each surgeon performed at least 30 cases. Following the attainment of that number PIRS is a safe and effective approach for the repair of pediatric hernias. Surgeons with an advanced level of experience in pediatric laparoscopic surgery adopted the technique more easily and had significantly shorter operating times as well as a lower number of perioperative and postoperative complications.

7. REFERENCES

1. Lytle WJ. Inguinal anatomy. Royal Infirmary, Sheffield. *J. Amat.* 1979. p. 581–94.
2. Moore KL, Dalley AF, Agur A. Abdomen. In: Moore KL, Dalley AF, Agur A, editors. *Moore clinically oriented anatomy*, 7th ed. Toronto: Lippincott Williams & Wilkins. 2014. p. 201–5.
3. Lawrence E. Wineski LE. *Snells clinical anatomy by regions*, tenth edition: Wolters Kluwer. 2019. p. 698–725.
4. Tuma F, Lopez RA, Varacallo M. Anatomy, Abdomen and Pelvis, Inguinal Region (Inguinal Canal). 2020 Aug 23. In: *StatPearls [Internet]*. Treasure Island (FL): StatPearls Publishing; 2021.
5. Gerard MD. *Current diagnosis and treatment surgery*, fourteenth edition: McGraw Hill Education. 2015. p. 768–81.
6. Öberg S, Andresen K, Klausen TW, Rosenberg J. Chronic pain after mesh versus nonmesh repair of inguinal hernias: A systematic review and a network meta-analysis of randomized controlled trials. *Surgery*. 2018;163(5):1151–9.
7. LeBlanc KE, LeBlanc LL, LeBlanc KA. Inguinal hernias: diagnosis and management. *Am Fam Physician*. 2013;87(12):844–8.
8. Purkayastha S, Chow A, Athanasiou T, Tekkis P, Darzi A. Inguinal hernia. *BMJ Clin Evid*. 2008;2008:0412.
9. Brandt ML. Pediatric hernias. *Surg Clin North Am*. 2008;88(1):27–43.
10. Prodromidou A, Paspala A, Schizas D, Spartalis E, Nastos C, Machairas N. Cyst of the canal of Nuck in adult females: A case report and systematic review. *Biomed Rep*. 2020;12(6):333–8.
11. Köckerling F, Simons MP. Current concepts of inguinal hernia repair. *Visc Med*. 2018;34(2):145–50.
12. Pogorelić Z, Rikalo M, Jukić M, Katić J, Jurić I, Furlan D, et al. Modified Marcy repair for indirect inguinal hernia in children: a 24-year single center experience of 6826 pediatric patients. *Surg Today*. 2017;47(1):108–13.
13. Pastorino A, Alshuqayfi AA. Strangulated Hernia. In: *StatPearls [Internet]*. Treasure Island (FL): StatPearls Publishing; 2021.

14. Chiow AKH, Chong CK, Tan SM. Inguinal hernias: A current review of an old problem. *Proc Singapore Healthc.* 2010;19(3):202–11.
15. Jenkins JT, O'Dwyer PJ. Inguinal hernias. *BMJ.* 2008;336(7638):269–72.
16. Ravikumar V, Rajshankar S, Kumar HR, Nagendra Gowda MR. A clinical study on the management of inguinal hernias in children on the general surgical practice. *J Clin Diagn Res.* 2013;7(1):144–7.
17. Berger D. Evidence-based hernia treatment in adults. *Dtsch Arztebl Int.* 2016;113(9):150–8.
18. Družijanić N, Sršen D, Pogorelić Z, Mijaljica G, Juričić J, Perko Z, et al. Preperitoneal approach for femoral hernia repair. *Hepatogastroenterology.* 2011;58(110-111):1450–4.
19. Van den Berg JC, De Valois JC, Go PM, Rosenbusch G. Detection of groin hernia with physical examination, ultrasound, and MRI compared with laparoscopic findings. *Invest Radiol.* 1999;34(12):739–43.
20. Korenkov M, Paul A, Troidl H. Color duplex sonography: diagnostic tool in the differentiation of inguinal hernias. *J Ultrasound Med.* 1999;18(8):565–8.
21. Marcy HO. A new use of carbolized catgut ligatures. *Boston Med Surg.* 1871;85:315–7.
22. Abd-Alrazek M, Alsherbiny H, Mahfouz M, Alsamahy O, Shalaby R, Shams A, et al. Laparoscopic pediatric inguinal hernia repair: a controlled randomized study. *J Pediatr Surg.* 2017;52(10):1539–44.
23. Lurking SC. Surgical techniques of laparoscopic inguinal hernia repair in childhood: A Critical Appraisal. *J Surg Tech Case Rep.* 2012;4(1):1–5.
24. Shalaby R, Ibrahim R, Shahin M, Yehya A, Abdalrazek M, Alsayaad I, et al. Laparoscopic hernia repair versus open herniotomy in children: A controlled randomized study. *Minim Invasive Surg.* 2012;2012:484135.
25. Patkowski D, Czernik J, Chrzan R, Jaworski W, Apoznański W. Percutaneous internal ring suturing: a simple minimally invasive technique for inguinal hernia repair in children. *J Laparoendosc Adv Surg Tech A.* 2006;16:513–7.

26. Thomas DT, Göcmen KB, Tulgar S, Boga I. Percutaneous internal ring suturing is a safe and effective method for the minimal invasive treatment of pediatric inguinal hernia: Experience with 250 cases. *J Pediatr Surg.* 2016;51:1330–5.
27. Pogorelić Z, Čohadžić T, Jukić M, Neveščanin Biliškov A. Percutaneous internal ring suturing for the minimal invasive treatment of pediatric inguinal hernia: A 5-year single surgeon experience. *Surg Laparosc Endosc Percutan Tech.* 2021;31(2):150–4.
28. Chen Y, Wang F, Zhong H, Zhao J, Li Y, Shi Z. A systematic review and meta-analysis concerning single-site laparoscopic percutaneous extraperitoneal closure for pediatric inguinal hernia and hydrocele. *Surg Endosc.* 2017;31:4888–901.
29. Wang F, Zhong H, Chen Y, Zhao J, Li Y, Chen J, et al. Single-site laparoscopic percutaneous extraperitoneal closure of the internal ring using an epidural and spinal needle: excellent results in 1464 children with inguinal hernia/hydrocele. *Surg Endosc.* 2017;31:2932–8.
30. Timberlake MD, Sukhu TA, Herbst KW, Rasmussen S, Corbett ST. Laparoscopic percutaneous inguinal hernia repair in children: review of technique and comparison with open surgery. *J Pediatr Urol.* 2015;11(5):262.e1–6.
31. Jukić M, Pogorelić Z, Šupe-Domić D, Jerončić A. Comparison of inflammatory stress response between laparoscopic and open approach for pediatric inguinal hernia repair in children. *Surg Endosc.* 2019;33(10):3243–50.
32. Tanriverdi HI, Senel U, Ozmen Z, Aktas F. Does the percutaneous internal ring suturing technique impair testicular vascularization in children undergoing inguinal hernia repair? *J Laparoendosc Adv Surg Tech A.* 2015;25:951–3.
33. Pogorelic Z. Effects of laparoscopic hernia repair by PIRS (Percutaneous Internal Ring Suturing) technique on testicular artery blood supply. *J Invest Surg.* 2019;32(4):348–9.
34. Neveščanin A, Vickov J, Elezović Baloević S, Pogorelić Z. Laryngeal mask airway versus tracheal intubation for laparoscopic hernia repair in children: analysis of respiratory complications. *J Laparoendosc Adv Surg Tech A.* 2020;30(1):76–80.
35. Valsamis EM, Chouari T, O'Dowd-Booth C, Rogers B, Ricketts D. Learning curves in surgery: variables, analysis and applications. *Postgrad Med J.* 2018;94(1115):525–30.

36. Hopper AN, Jamison MH, Lewis WG. Learning curves in surgical practice. *Postgrad Med J.* 2007;83(986):777–9.
37. Emken JL, McDougall EM, Clayman RV. Training and assessment of laparoscopic skills. *JLS.* 2004;8:195–9.
38. Kumar U, Gill IS. Learning curve in human laparoscopic surgery. *Curr Urol Rep.* 2006;7(2):120–4.
39. Barroso C, Etlinger P, Alves AL, Osório A, Carvalho JL, Lamas-Pinheiro R, et al. Learning curves for laparoscopic repair of inguinal hernia and communicating hydrocele in children. *Front Pediatr.* 2017;5:207.
40. Shibuya S, Fujiwara N, Ochi T, Wada M, Takahashi T, Lee KD, et al. The learning curve of laparoscopic percutaneous extraperitoneal closure (LPEC) for inguinal hernia: protocolled training in a single center for six pediatric surgical trainees. *BMC Surg.* 2019;19:6.
41. Erginel B, Akin M, Yildiz A, Karadag CA, Sever N, Dokucu AI. Percutaneous internal ring suturing as a first choice laparoscopic inguinal hernia repair method in girls: a single-center study in 148 patients. *Pediatr Surg Int.* 2016;32:697–700.

8. SUMMARY

Background: Percutaneous internal ring suturing (PIRS) is a simple and popular technique for the treatment of inguinal hernia. The aim of this study was to analyze the learning curves during implementation of PIRS in our department.

Methods: A total of 318 pediatric patients underwent hernia repair using the PIRS technique, by three pediatric surgeons with different levels of experience in laparoscopic surgery. These patients were enrolled in a prospective cohort study during the period of October 2015 until January 2021. Surgical times, intraoperative and postoperative complications plus outcomes of treatment were compared between the three surgeons with different levels of experience in laparoscopic surgery.

Results: Regarding operative time a significant difference among the surgeons was found. Operative time significantly decreased after 25–30 procedures per surgeon. The surgeon with advanced experience in laparoscopic surgery had significantly less operative times for both unilateral ($P=0.002$) and bilateral ($P=0.0001$) hernia repair, compared to the other two surgeons. Perioperative complications, conversion, and ipsilateral recurrence rates were all higher in the beginning, reaching the benchmarks when each surgeon performed at least 30 PIRS procedures. The most experienced surgeon had the lowest number of complications (1.4%) and needed the fewest number of cases to reach the plateau. The other two surgeons with less experience in laparoscopic surgery had higher rates of complications (4.4% and 5.4%) and needed a higher number of cases to reach the plateau ($P=0.190$).

Conclusion: A PIRS learning curve for perioperative and postoperative complications, recurrences, and conversion rates reached the plateau after each surgeon performed at least 30 cases. After that number was achieved, PIRS was shown to be a safe and effective approach for pediatric hernia repair. A Surgeon with an advanced level of experience in pediatric laparoscopic surgery adopted the technique more easily and had a significantly faster learning curve compared to the surgeons with less experience.

9. SUMMARY IN CROATIAN

Naslov rada: Krivulja učenja laparoskopske operacijske tehnike korištenjem perkutano uvedenog šava za zatvaranje unutarnjeg otvora preponskog kanala u liječenju preponske kile u djece

Ciljevi: PIRS (*eng. Percutaneous internal ring suturing*) je relativno jednostavna i popularna kirurška tehnika za liječenje preponske kile u djece. Cilj ovog istraživanja bio je analizirati krivulju učenja tijekom implementacije PIRS-a u našoj Klinici.

Metode: Ukupno 318 djece s prepskom kilom koja su operirana PIRS tehnikom, uključeno je u prospektivno kohortno istraživanje u razdoblju od listopada 2015. do siječnja 2021. godine. Duljina trajanja operacijskog zahvata, intraoperacijske i poslijeoperacijske komplikacije, kao i ishodi liječenja uspoređeni su između tri dječja kirurga s različitim razinama iskustva u laparoskopskoj kirurgiji.

Rezultati: Duljina trajanja operacijskog zahvata značajno se razlikovala između dječjih kirurga uključenih u studiju te se značajno smanjila nakon što je svaki kirurg izveo 25–30 operacijskih zahvata. Duljinu trajanja operacijskog zahvata u djece s jednostranom ($P=0,002$) i obostranom ($P=0,0001$) prepskom kilom bila je značajno kraća u kirurga s naprednim iskustvom u laparoskopskoj kirurgiji, u usporedbi s ostala dva kirurga. Intraoperacijske komplikacije, stopa konverzija, kao i stopa recidiva bili su veći u početku studije, da bi dosegli plato kada je svaki kirurg izveo najmanje 30 zahvata. Najiskusniji kirurg imao je najmanji broj komplikacija (1,4%) i trebao je manji broj operacijskih zahvata da bi dosegao plato. Ostala dva kirurga, s manje iskustva u laparoskopskoj kirurgiji, imala su veću stopu komplikacija (4,4% i 5,4%) i bio im je potreban veći broj operacijskih zahvata da bi dosegli plato ($P=0,190$).

Zaključci: Krivulja učenja po pitanju prijeoperacijskih i poslijeoperacijskih komplikacija, stope recidiva i konverzija za PIRS tehniku dosegla je plato nakon što je svaki kirurg izveo najmanje 30 operacijskih zahvata. Nakon što je svaki kirurg uključen u studiju dosegnuo taj broj, pokazalo se da je PIRS siguran i učinkovit operacijski pristup u liječenju preponske kile dječje dobi. Kirurg s naprednom razinom iskustva u dječjoj laparoskopskoj kirurgiji lakše je usvojio tehniku i imao je značajno bržu krivulju učenja u usporedbi s kirurzima koji su imali manju razinu iskustva u dječjoj laparoskopskoj kirurgiji.

10. CURRICULUM VITAE

PERSONAL INFORMATION:

NAME AND SURNAME: Dario Huskic

DATE AND PLACE OF BIRTH: Hagen, Germany November 14, 1997

NATIONALITY: Croatian-Canadian

CURRENT ADDRESS: Put Znjana 39 Split, Croatia

E-MAIL: dariohuskic@gmail.com

EDUCATION:

2015-2021 University of Split, School of Medicine, MD / Degree of Medical Doctor.

2011-2015 St Martins Secondary School, Mississauga, Canada

AWARDS:

Dean's Award for highest Academic GPA in 2018 school year

RELEVANT EXPERIENCE:

Summer Volunteer Placement 3 week Medical Internship, 2019

Keta Municipal Government Hospital, Ghana, Africa

Gained perspective experience of third world medicine while volunteering at a local hospital in the Volta region of Ghana.

Performed progressive measurement of village children based on age, height, weight and nutrition levels. This established baseline for general health and ensured growth amongst kids.

OTHER

Languages: English, Croatian, German

11. SUPPLEMENTS

Supplement 1 – Study protocol

ANAMNESTIC INFORMATION	
First and last name:	Date of birth: Sex: M / F
Date of operation:	MBO:
Location: A- left B- right C- both sides	Height and weight (BMI):
Previous operations in the abdominal cavity:	Phone number:
OPERATIVE DATA	
Duration of anesthesia (min):	Duration of surgery (min):
Diameter (mm) of trocar used: A- 3.5 B- 5	Number of hernial sutures: A- 1 suture B- 2 sutures
Needle Gauges: A – 18 G; B – 20 G; C – 22 G; D – 24 G	Anesthesia : Drugs: Type of anesthesia : A- OET B- LM Relaxants: A- YES B- NO ASA Classification: A- I B- II C- III D- IV
Retractor: YES NO	Pneumoperitoneum: A- 6 mmHg B- 7 mmHg C- 8 mmHg D- 9 mmHg E- 10mmHg F- 12mmHg
Intraoperative complications: SURGICAL: ANESTHESIA:	
POST-OPERATIVE FOLLOW-UP	
Post-operative complications: SURIGCAL: ANESTHESIA:	
Follow-up: 1. control (): 2. control (): 3. control (): 4. control (): 5. control ():	
Length of hospitalization (days):	
Reminders:	
Surgeon:	Anesthesiologist:

Supplement 2 – Ethics review board approval

**KLINIČKI BOLNIČKI CENTAR SPLIT
ETIČKO POVJERENSTVO**

Klasa: 500-03/20-01/09
Ur.br.: 2181-147-01/06/M.S.-20-9
Split, 13.05.2020.

**IZVOD
IZ ZAPISNIKA SA SJEDNICE ETIČKOG POVJERENSTVA KBC SPLIT**

Prof.dr.sc. Zenon Pogorelić iz Klinike za dječju kirurgiju KBC-a Split, uputio je Etičkom povjerenstvu zamolbu za odobrenje provedbe istraživanja:

**" PERKUTANA PLASTIKA UNUTARNJEG OTVORA PREPONSKOG KANALA –
NOVA MINIMALNO INVAZIVNA METODA U LIJEČENJU PREPONSKE KILE U
DJECE "**

Istraživanje u svrhu izrade diplomskog rada i publikacije u međunarodnom časopisu će se provesti u Klinici za dječju kirurgiju KBC-a Split.

Nakon razmatranja zahtjeva, donijet je sljedeći

Z a k l j u č a k

Iz priložene dokumentacije razvidno je da je Plan istraživanja usklađen s odredbama o zaštiti prava i osobnih podataka ispitanika iz Zakona o zaštiti prava pacijenata (NN169/04, 37/08) i Zakona o provedbi Opće uredbe o zaštiti podataka (NN 42/18), te odredbama Kodeksa liječničke etike i deontologije (NN55/08, 139/15) i pravilima Helsinške deklaracije WMA 1964-2013 na koje upućuje Kodeks.

**PREDSJEDNIK ETIČKOG POVJERENSTVA
KLINIČKOG BOLNIČKOG CENTRA SPLIT
PROF. DR. SC. MARIJAN SARAGA**

KLINIČKI BOLNIČKI CENTAR SPLIT
Etičko povjerenstvo