

# Abnormalities of the umbilical cord according to pathohistological reports : a one year retrospective study

---

**Mangelsen, Luise**

**Master's thesis / Diplomski rad**

**2021**

*Degree Grantor / Ustanova koja je dodijelila akademski / stručni stupanj:* **University of Split, School of Medicine / Sveučilište u Splitu, Medicinski fakultet**

*Permanent link / Trajna poveznica:* <https://um.nsk.hr/um:nbn:hr:171:216939>

*Rights / Prava:* [In copyright](#)/[Zaštićeno autorskim pravom.](#)

*Download date / Datum preuzimanja:* **2024-08-27**



*Repository / Repozitorij:*

[MEFST Repository](#)



**UNIVERSITY OF SPLIT  
SCHOOL OF MEDICINE**

**LUISE MANGELSEN**

**ABNORMALITIES OF THE UMBILICAL CORD ACCORDING  
TO PATHOHISTOLOGICAL REPORTS, A ONE YEAR  
RETROSPECTIVE STUDY**

**DIPLOMA THESIS**

**Academic year:**

**2020/2021**

**Mentor:**

**Assist. Prof. Sandra Zekić Tomas, MD, PhD**

**Split, September 2021**

## TABLE OF CONTENTS:

<b>1. INTRODUCTION</b> .....	1
1.1 Development and structure of the human placenta and the umbilical cord .....	2
1.2 Physiology of the placenta and the umbilical cord .....	8
1.3 Macroscopic abnormalities of the umbilical cord .....	12
1.3.1. Developmental abnormalities .....	12
1.3.1.1 Congenital absence of the cord .....	12
1.3.1.2 Abnormal cord length .....	13
1.3.1.3 Abnormal cord coiling .....	13
1.3.1.4 Embryonic remnants .....	14
1.3.2. Abnormalities of the umbilical vessels and vascular lesions .....	15
1.3.3. Abnormalities of insertion .....	15
1.3.4. Mechanical lesions.....	17
1.3.5. Cord masses .....	20
1.4 Pathohistological abnormalities of the umbilical cord and fetal vascular malformations .....	21
<b>2. OBJECTIVES</b> .....	24
2.1 Objectives .....	25
2.2 Hypothesis .....	25
<b>3. SUBJECTS AND METHODS</b> .....	26
3.1 Study design.....	27
3.2 Materials .....	27
3.3 Methods of data collection and processing .....	27
3.4 Statistical analysis .....	28
3.5 Ethical committee approval .....	28
<b>4. RESULTS</b> .....	29
<b>5. DISCUSSION</b> .....	34
<b>6. CONCLUSION</b> .....	37
<b>7. REFERENCES</b> .....	39
<b>8. SUMMAR</b> .....	44
<b>9. CROATIAN SUMMARY</b> .....	46
<b>10. CURRICULUM VITAE</b> .....	48

## **ACKNOWLEDGEMENTS**

I would like to thank my mentor Assist. Prof. Sandra Zekić Tomas, MD, PhD for her constant help and support during the process of writing my thesis. She helped me immensely and without her it would have not been imaginable.

I cannot put into words how much I have learned during the last six years in Split and how living in Croatia formed me to the person I always aspired to be. Without the support of my family, friends and all the people I met on this journey this would have been impossible.

Split became my home and will always have a special place in my heart.

## **LIST OF ABBREVIATIONS**

CI - Coiling index

CNS - Central nervous system

FGR - Fetal growth restriction

FO - Foramen ovale

HCG - Human chorionic gonadotropin

HGF - Human growth factor

HPL - Human placental lactogen

IGF - Insulin-like growth factor

IUGR - Intrauterine growth retardation

PDA - Patent ductus arteriosus

SGA - Small for gestational age

SUA - Single umbilical artery

UC - Umbilical cord

US - Ultrasound

UV - Umbilical vein

## **1. INTRODUCTION**

## **1.1 Development and structure of the human placenta and the umbilical cord**

The placenta and the umbilical cord, together with the fetal membranes and amniotic fluid, are highly specialized organs during pregnancy that aid the fetus to grow and develop normally. Changes in the placental and umbilical cord development and function have a significant impact on the fetus' ability to adapt to the intrauterine environment.

Therefore, its growth and action are meticulously controlled and coordinated to work as efficient as possible (1).

The pregnancy and the process of implantation starts with the production of a zygote by fertilization and continues with its mitotic cleavage. The zygote is moved together with its cells, the blastomeres, towards the uterus and forms a solid complex, also known as the morula.

About five days after fertilization the blastomeres have proceeded to form a central cavity in the morula and the embryo reaches the uterine cavity and enters the blastocyst stage of development.

The peripheral layer, the trophoblast, is then formed by the blastomere arrangement around the cavity of the morula. The remaining cells inside form the inner cell mass, also called embryoblast. The blastocyst resides in the uterus approximately for two days, encircled by the mucosa and the endometrial glands' secretion. After that, the process of implantation, called nidation, occurs. It takes the blastocyst about three days to attach to the surface of the epithelial cells of the endometrium and to perforate into the underlying stroma (2, 3).

The implantation is maintained by the cells of the trophoblast, that coordinate the rearrangement of embryoblast to form two new cavities: the amnion and the yolk sac.

A bilaminar embryonic disc develops where the cells that line the cavities interfere, with the epiblast layer being continuous with the amnion and the hypoblast layer with the yolk sac. This early embryonic disc is the first milestone in the development of a human being and later gives rise to all the components of the embryo. By the ninth day after ovulation the process of implantation is completed and the embryo is totally embedded into the endometrium (4).

These interactions between maternal and embryonic cells during implantation and placental formation are extremely coordinated and an overall complex process (1).

It includes the development of feto-placental units, that facilitate nutrient, gas, and waste exchange between the maternal and fetal compartments (3).

The units are formed by fetal tissue originating from the chorionic sac and endometrial maternal tissue (1). The fetal tissue that forms the chorionic plate is derived from the trophoblast and the extraembryonic mesoderm (3).

After implantation, the trophoblast differentiates into cytotrophoblast and syncytiotrophoblast. The cytotrophoblast consists of mitotically active cells that surround the amnion and yolk sac, whereas the syncytiotrophoblast is located more superficially and does not contain mitotically active cells. It forms a mass of multinucleated cytoplasm, occupying the surrounding stroma (4).

The basal plate refers to the placenta's maternal side (1). The intervillous space that is located between these two zones originates from the lacunae in the syncytium and is lined by fetal syncytium (1, 4). It contains the placenta's primary functional components, consisting of massively branched and densely packed villous structures, harboring fetal blood arteries (1). Due to the formation of decidual septa, that project into the intervillous spaces, adequate oxygenation is maintained (4). However, a syncytial layer at all time separates the maternal blood flow in intervillous lakes from fetal tissue of the villi. The placenta is furthermore divided into compartments, or cotyledons (4). These are wedge-shaped and bulge into the maternal side of the basal plate (5).

The first primary villi appear two days after implantation as simple cords and are followed by the development of secondary and tertiary villi. These begin to form after 15 days and assemble capillary loops (4).

Approximately at the beginning of the second month the increase of secondary and tertiary villi causes the trophoblast layer to become more and more radially shaped (3).

The majority of maternal fetal exchange occurs at the terminal portions of these chorionic villi (2). As before mentioned, the surface of the villi is formed by the syncytium, laying on a layer of cytotrophoblastic cells which cover a center of vascular mesoderm (3).

In the center of the villous stems the growing capillary network develops, by encountering the capillaries of the chorionic plate and connecting stalk and thus enabling the development of the extraembryonic vascular system.

The process of endovascular invasion enables the maternal vessels to supply the intervillous spaces with blood. At the end of each anchoring villi cytotrophoblast cells are released and conquer the terminal ends of spiral arteries, causing replacement of maternal endothelial vessel cells by formation of hybrid vessels, containing both fetal and maternal cells. The newly formed vessels are larger in diameter and have a lower resistance, thus permit increased maternal blood flow to the intervillous spaces.



With the time more and more small additionally primitive villi grow and become free villi that expand into the lacunar or intervillous spaces. The fetal demands for nutritional and other factors tremendously increase during the ninth week of development, causing significant placental changes. The biggest one being the overall increase in placental surface to enhance and facilitate the exchange between the fetal and maternal compartments.

After the fourth month maternal and fetal circulation are only separated by the thin layer of syncytium and the endothelial wall of the blood vessel due to regression of cytotrophoblastic cells and loss of some connective tissue.

Often the syncytium becomes so thin that pieces break off and drop into the intervillous blood lakes. The so-called syncytial knots can emerge and enter maternal blood circulation. They usually degenerate without causing any problems (3). Due to their increase in number with gestational age of the placenta they can even be used to evaluate villous maturity (5).

During the first weeks of fetal development the entire surface of the chorion is covered by villi. Progressively, with growth continuation and further expansion, the fetal component of the placenta, known as the chorion frondosum, gets shaped (3, 5). Around the third month a smooth side at the chorion, the so-called chorion laeve, arises by degeneration of villi at the abembryonic pole. The anatomy of the decidua, the functional layer of the endometrium that is shed after parturition, reflects the difference between the embryonic and abembryonic poles of the chorion (3).

Above the chorion frondosum the decidua basalis is located, consisting of an immense amount of large decidual cells. They contain lipids and glycogen that form the compact maternal component of the placenta (3, 5). These decidual cells form a decidual plate that is strongly attached to the chorion. However, the decidual plate gets stretched due to the chorionic vesicle growth and degenerates. This enables the chorion to directly encounter the uterine wall on the opposite side (decidua parietalis) in order to fuse and close the uterine lumen. The merging of the chorion frondosum and the decidua basalis forms the placenta (3).

At the onset of the fourth month the placenta has two main components, consisting of the fetal part, known as the chorionic plate, and the maternal part, known as the decidua basalis.

A placental barrier that mainly consists of layers of fetal tissue separates the two compartments, to maintain the separation of maternal and fetal blood (5).

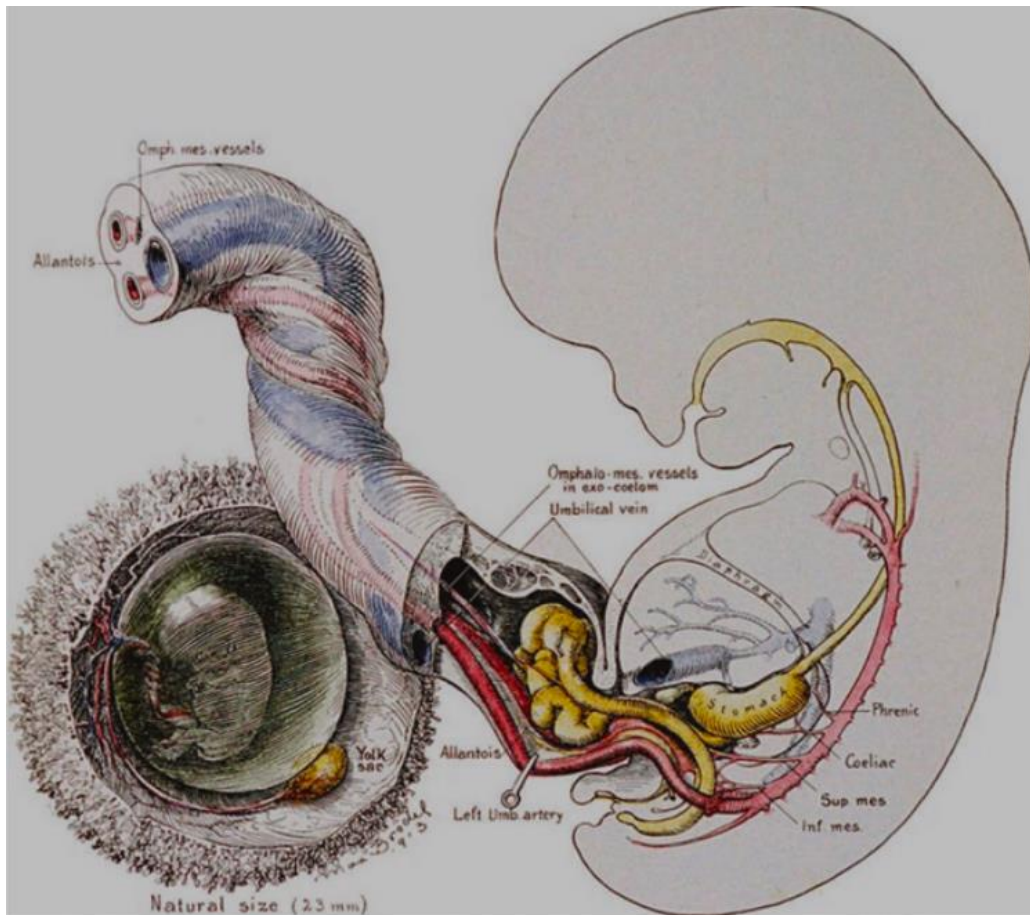
Throughout the pregnancy the fetal membranes keep the fetus safe and eventually burst during the first stage of labor (1). They are made up of the amnion that faces the fetus and the chorion that faces the maternal side.

The amnion is made up of five layers of which the innermost layer is the amniotic epithelium. The amniotic epithelium is in direct touch with the amniotic fluid on one side and the basement membrane on the other. The compact layer, the fibroblast layer and the spongy, also called intermediate layer, form the other layers of the amnion. On the other hand, the chorion is made up of three layers: the reticular layer, the basement membrane, and the trophoblast cell area, which is strongly attached to the maternal decidual tissue at term.

Fetal membranes, like the placenta, play an important role in fetal development and the overall progression of pregnancy. They have the ability to act autocrine regulatory and release compounds into the amniotic fluid, therefore affecting its balance. They can also act directly on the uterus and even regulate the maternal cellular physiology. Moreover, by acting like a barrier, they protect the fetus from ascending reproductive tract infections (1).

While the embryonic disk changes its shape and becomes cylindrical after four to six weeks, the umbilical cord begins to form (6). Later it will contain the umbilical vessels, which transport blood between the embryo and the placenta. The umbilical arteries and veins will become the unbearable connection between the growing fetus and the placenta and are thus responsible for its blood supply (7). Without the placental connection the fetus would be deprived of oxygen and other nutrients and would not be able to filter out waste products like carbon dioxide and urea (7, 8). The development of the proximal part of the umbilical cord starts at the lower third of the embryo as a small outpouching (6). The upper portion of this sac contains the fetal gut until the tenth week of gestation. At the beginning, the umbilical cord is usually short in length and does not allow the embryo yet to rotate. Mostly, it is even shorter than the head-to-tail (crown-rump) length of the embryo, controversially, its diameter is relatively large in size. The development of the initial stalk at the center of the implantation side is responsible for the cord presenting at the center of the placenta. Redisposition of the embryonal intestines from the proximal cord into the abdominal cavity after ten weeks causes the elongation of the umbilical cord and the positioning of the umbilicus in the middle third of the embryo. Concurrently, the umbilical vein and arteries lengthen and the umbilical cords connective tissue, the Wharton's jelly, appears. It consists of a gelatin-like tissue and protects the umbilical vessels and prevents their compression by fetal movements (7).

The umbilical cord emergence and the amnion development are closely related and happen simultaneously (6).



**Figure 1.** Diagram of early structures of the UC, the cord is thick and short with a herniated hindgut (6).

During the second week postcoitus the embryoblast consists of the amniotic vesicle and the primary yolk sac. It is surrounded by a loose meshwork of mesoderm cells that also fill the blastocystic cavity and are called extraembryonic mesoblast. A few days later, these two primary vesicles fuse and the double-layered embryonic disc arises.

Due to further rearrangement of the extraembryonic mesoderm they change into the chorionic mesoderm by lining the inner surface of the trophoblastic shell and covering the surface of the two embryonic vesicles. The exocoelom cavity starts to form between the two mesodermal layers and separates the embryo and its mesodermal cover from the chorionic mesoderm. Only basally to the amniotic vesicle, the mesoderm crosses the exocoelom once and forms a mesenchymal connection known as the connecting stalk.

Due to this, the embryo becomes fixed to the membranes and a primitive umbilical cord has established. Around 18 days postcoitus, at the future caudal region of the embryo, a duct starts to extend from the yolk sac into the connecting stalk. By then, the primitive extraembryonic urinary bladder, the transitory allantois has formed (6).

In the upcoming three weeks, the embryo rotates and causes the yolk sac to turn and face the implantation pole. Furthermore, the amniotic vesicle enlarges and surrounds the embryo. Due to the formative changes of the embryonic disc, that consist of anteroposterior bending and lateral rolling, the disc breaches into the amniotic vesicle. Additional bending of the embryo causes subdivision of the yolk sac into an intraembryonic duct (the intestines) and an extraembryonic part (omphalomesenteric duct). The omphalomesenteric duct further dilates peripherally to shape the extraembryonic yolk sac vesicle. Subsequent extension of the allantois and the extraembryonic yolk sac into the mesenchyme of the connecting stalk causes the almost complete surrounding of the embryo and the compression of the connecting stalk, the urachus and the yolk sac into a slim cord (9, 10).

By the 28th day, the cord is covered by amniotic epithelium and the umbilical cord has been successfully formed. Further subsiding of the embryo backward into the amniotic sac causes lengthening of the cord and enables the touch of the amniotic mesenchyme with the chorionic mesoderm. After the first trimester the amniotic and chorionic mesenchyme have completely fused and the exocoelomic cavity is closed and engaged by the amniotic cavity.

As mentioned earlier, starts the process of vascularization during the third postcoital week and the extraembryonic yolk sac, the omphalomesenteric duct and the allantois begin to acquire their blood supply from the fetal vessels. The allantois and the yolk sac vessels are indispensable in the vascularization of the placenta and due to their participation and entry into the placental circulation, the term chorioallantoic placenta can be used. The allantoic arteries emerge from the internal iliac arteries and carry the deoxygenated blood, whereas the allantoic vein returns the oxygenated blood to the embryo and drains into the hepatic vein (6).

## 1.2 Physiology of the placenta and the umbilical cord

The weight of a full-term placenta is around 500 to 600 grams, it has a discoidal shape with a diameter of 15 to 25 cm and is around 3 cm thick. At the process of birth, it gets pulled off the uterine wall and comes out as the afterbirth approximately 30 minutes after the baby is born. The maternal placental side can be easily distinguished from the fetal side, due to its cotyledons that form around 15 to 20 bulging areas and are covered by a small amount of decidua basalis (6).

In comparison to which the fetal side is relatively smooth and is covered totally by the chorionic plate. It contains the chorionic vessels, consisting of large arteries and veins that converge on their way to the umbilical cord. Additionally, the chorion is covered by the amnion. The umbilical cord attachment is typically central or marginal or paracentral and paramarginal. However, it can also be velamentous and thereby inserting into the chorionic membranes outside of the placenta, predisposing it to cord tears (3, 6).

The cotyledons of the placenta become supplied with blood by 80 to 100 spiral arteries that in regular intervals penetrate the decidual plate and join the intervillous spaces. Due to high arterial pressure the intervillous spaces are deeply supplied and the numerous small villi become drained by oxygenated blood. Decreasing pressure causes backflow of the blood from the intervillous lakes into direction of the decidua and back into the maternal circulation, the endometrial veins (6).

A mature placenta contains an overall blood amount of around 150 mL, that is replenished around three to four times per minute and the villis' surface area can range from 4 to 14 m<sup>2</sup> (3). Nevertheless, occurs the placental exchange only in those villi that are in close proximity to fetal vessel and their covering syncytial membrane, which is made up of numerous microvilli. These microvilli enormously increase the surface area and therefore the exchange between the maternal and fetal compartments. Apart from the elimination of metabolic and gaseous products, the placenta also enables the exchange of nutrients, gases and electrolytes, the transmission of maternal antibodies and hormone production. A well-developed fetus requires around 20 to 30 mL of oxygen per minute and any interruption in blood supply can have serious or fatal consequences. The placental blood flow to the fetus is essential, hence the oxygen gets supplied via delivery and not diffusion (3).

The fetal circulation begins around day 22 of pregnancy when the fetal heart beats for the first time. Initially, both the yolk sac and the placenta are responsible for the gas exchange but after 10 weeks of pregnancy the placenta is the main provider.

Due to poor mixing of oxygenated maternal blood within the placental space, the fetal blood contains less oxygen than the maternal uterine arterial blood. As a consequence, the fetus lives in a hypoxemic environment. Hence the fetal lungs do not contribute to intrauterine oxygenation, the fetal circulation consists of several intrauterine shunts to redirect the blood away from the fetal lungs (11).

The placenta additionally mediates the fetal supply with nutrients and electrolytes, such as amino acids, free fatty acids, carbohydrates and vitamins, which are vital for the fetus (3, 12). The fetal immune system begins to evolve at the end of the first trimester with the development of the complement system. At around 14 weeks of gestation the fetus maternal IgG immunoglobulins are able to reach the fetus and provide passive immunity against a variety of infectious diseases (3).

Towards the end of the fourth month the placenta starts to become a major endocrine organ and its hormones have a significant effect on the maternal physiology and behaviour (13, 14). At the beginning of the pregnancy they increase the maternal food intake and energy storage whereas towards the end of pregnancy they utilize the last reserves to support the growing of the fetus and prepare the maternal body for lactation (15, 16).

The most important hormones that do so are the placental lactogens (hPL) and placental growth hormone (hGH). They are released by the syncytiotrophoblast (17).

The hPL, also called somatomammotropin, not only supports fetal growth but also prioritizes the fetal demands on maternal blood glucose and encourages breast development for adequate milk production (3). hGH is of extreme importance since it aids in the regulation of insulin-like growth factor (IGF) (16, 18). Despite the fact that IGF cannot cross into the fetal circulation, it has enormous effects on the fetal growth. Its concentration in the maternal blood corresponds with the fetal birthweight and it further acts via alternating the maternal metabolism, stimulating placental changes and increasing the overall amount of maternal blood flow to the placenta (19, 20).

The syncytiotrophoblast as well produce progesterone and estriol to maintain the pregnancy, just in case that the corpus luteum regresses or fails to function. The estriol amount increases towards the end of pregnancy because high estrogen levels are mandatory to maintain uterine growth and mammary gland development.

The syncytiotrophoblast continue producing human chorionic gonadotropin (hCG) during the first two months of the pregnancy. Since hCG is early in gestation excreted in the urine it can be detected and is used as an indicator of pregnancy (3).

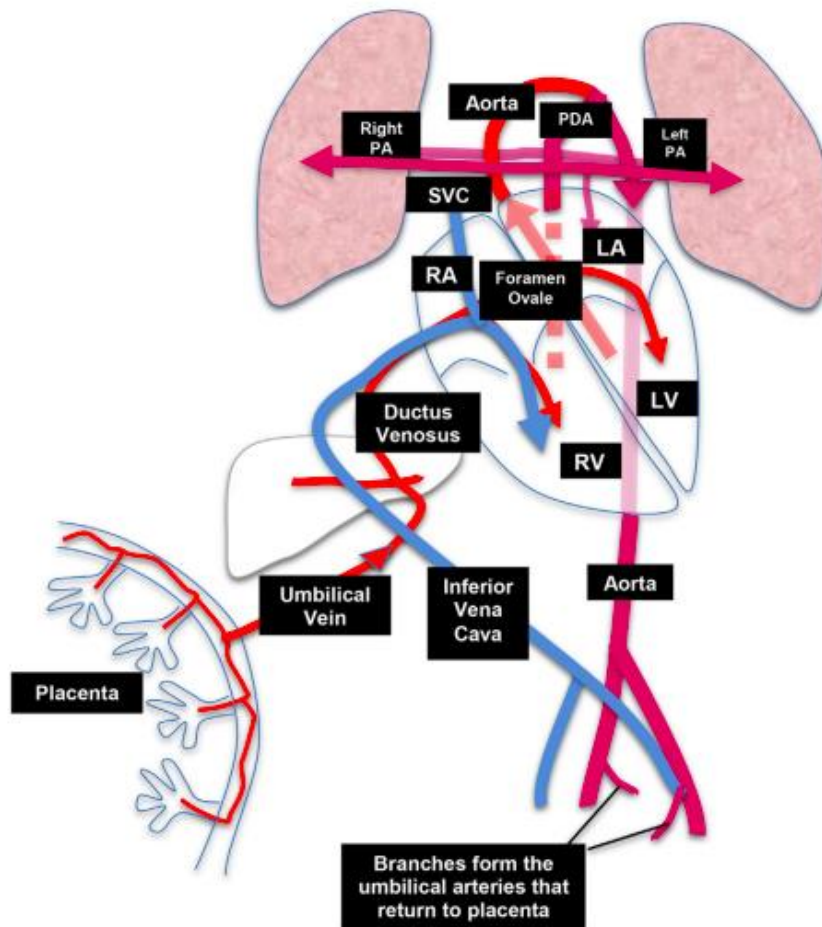
Incidences like insulin resistance and preeclampsia, gestational hypertension, and eclampsia point out how much placental shape and function can affect the mother's health (21-26). Of course, the fetus also suffers if any placental malfunction exists, which can result in pretermaturity, as well as fetal growth and neurological problems (27, 28).

The fetus's ability to develop and survive is determined by the anatomy and function of the umbilical vessels and the entire umbilical cord (10). The physiology of the cord is quite different and is unique, hence its blood vessels are without branches, in comparison to other large blood vessels of the human body (6).

The cord anatomy should be examined during the first trimester by ultrasound (US). It requires confirming the exact number of umbilical vessels and their intra-abdominal path, as well as examining the abdominal and placental attachment sites (10). During the second trimester a complete evaluation of the umbilical cord includes using gray scale and color Doppler US is performed, to determine the number of vessels in the cord, cord thickness and cord coiling (7). Assessing the function of the fetal-placental vessels, provides crucial information about the fetal health and Doppler assessment of the umbilical cord blood flow pattern is indicated in cases of suspected fetal or umbilical cord disorders (7, 10).

The umbilical cord usually holds two arteries that are positioned around the single vein and contain the deoxygenated blood that the fetal heart pumps away. Whereas the umbilical vein (UV) returns the blood from the placenta, that was oxygenated and refreshed with nutrients to the fetus (6). The UV divides itself at the level of the liver with some blood, perfusing the hepatic circulation and the rest entering the ductus venosus. Almost all fetal blood originates from the ductus venosus. From there the fetal blood flow is directed across the foramen ovale to the left atrium, where it finally enters the right atrium.

Right ventricular output is maintained across the patent ductus arteriosus into the descending aorta and left ventricular output supplies blood flow to the preductal vessels nourishing the brain, coronary arteries, and upper body of the fetus. Intrauterine pulmonary blood flow is extremely limited and almost nonexistent due to the high pulmonary vascular resistance and the right-to-left shunting across the patent foramen ovale and PDA (11).



**Figure 2.** Fetal circulation (11).

In 99% three vessels are present in the umbilical cord and in 1% only two (6). Due to the low oxygen saturation in the umbilical venous blood low, that is around 70 to 80%, the fetus has to adapt to the hypoxemic environment (11, 12).

The fetus grows at an exponential rate and simultaneously the umbilical cord elongates and expands in diameter. The rising resistance at the placental end forces the fetus to tolerate and accommodate and increased blood volume and tissue resistance (6).

The umbilical cords' normal diameter is less than 2 cm. Until the end of the second trimester the umbilical cord grows to a length of 50–60cm and produces up to 40 helical turns.

Usually, these twists occur more to the left than to the right side and it is assumed that the helical muscle fibers in the umbilical cord vessels are responsible for that (7).



Coiling is supposed to protect the cord by strengthening it and preventing vascular compression. The length and twists of the cord are determined by the tensile stresses exerted on it by fetal movements. To ensure normal cord length and coiling, there must be enough fluid space and fetal activity (21). Decreased coiling is associated with a higher increase in perinatal mortality and other problems and the usage of the umbilical coiling index is advised. The umbilical coiling index (CI) consists of the number of coils divided by the length of cord. The average is about 0.21/cm and alterations can identify the fetus that are at risk (6). The umbilical attachment of the cord varies greatly and can lead later in the infant life to umbilical hernias and cord constrictions.

The length of the cord has an effect on blood flow dynamics, but the blood flow must encounter some resistance in order for the circulation to function. As a result, four layers of smooth muscle surround the umbilical arteries to maintain a certain level of muscular tone. The umbilical vein only contains a small amount of smooth muscle cells. The system is usually fully dilated, however it can be influenced by chemical or hormonal stimuli that cause its constriction. Some vessel-active substances are released by the placenta to mediate vessel constriction, which is of major importance at birth to prevent blood loss. Severe circumstances that cause the reduction of blood flow and alteration of placental circulation the growth rate of the fetus and a intrauterine growth retardation (IUGR) can develop. Early detection is essential to prevent potential fetal harm and stillbirth. Complications like IUGR can have an effect on the fetal heart function later in life and even predispose to adult heart attacks or elevations of blood pressure (6).

### **1.3 Macroscopic abnormalities of the umbilical cord**

#### 1.3.1 Developmental abnormalities

##### 1.3.1.1 Congenital absence of the cord

The total absence of the umbilical cord, also known as the body stalk anomaly, is immensely rare and almost never occurring hence its' incompatibility with life. The anomaly can be present in grossly malformed and aborted fetuses and comes along with a large anterior wall defect and extravasation of abdominal viscera. Usually, the viscera is covered by a sac that is covered by amnion, which is directly connected to the placenta without the presence of the umbilical cord.

The reason for this fatal anomaly is most likely an error in embryonic folding and the absent development of the body stalk (29). It can be associated with multiple congenital defects (30).

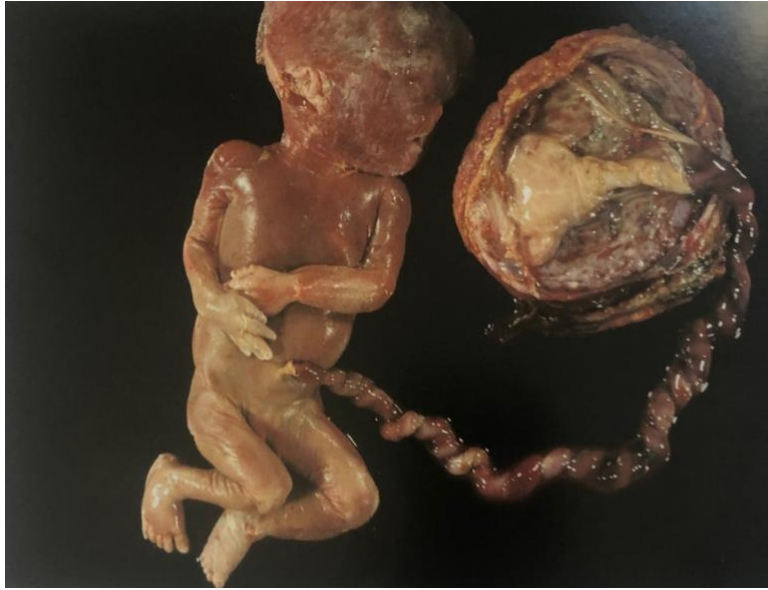#### 1.3.1.2 Abnormal cord length

The normal umbilical cord length is around 55 to 65cm. Less than 35cm is termed short cord, whereas those more than 70 to 80cm are long umbilical cords (2). As mentioned earlier, the length of the cord is related to the fetal mobility and therefore proportional to the tensile forces that are being placed on it. Genetic predispositions can also affect the cord length and it should be noted that males usually have longer cords than females.

Short cords can be furthermore caused by conditions that restrict or decrease fetal movements, such as amniotic bands, uterine malformations, skeletal dysplasias and oligohydramnios. Also, infants with Down syndrome tend to be less active in utero and therefore can be associated with shorter cords (29). Extremely short cords are often associated with excess traction during delivery, which can lead to premature placental separation, cord hemorrhage, cord rupture, uterine inversion and failure of descent. All of these can lead to fetal distress with low Apgar scores and a decrease in mental capacity. In contrast to that, abnormal long cords can lead to cord entanglement, cord prolapse, cord knots, excessive cord coiling, constriction and even cord thrombosis. Long-term neurologic impairment, IUGR, fetal demise and fetal distress can be the consequences (2).

#### 1.3.1.3 Abnormal cord coiling

As before mentioned, the umbilical cord consists normally of 40 twists in the left, counterclockwise direction in a 4:1 ratio. Alterations of the CI which is normally 0.21/cm, can be seen in hypocoiled cords that make up 7,5% and in hypercoiled cords that occur in around 20% of all cords. Noncoiled cords occur less often and are only present in 4 to 5%. Insufficient or excessive coiling are both associated with adverse perinatal outcome and can result in perinatal mortality, IUGR, and fetal distress. Reduced fetal activity reduces coiling, whereas fetal hyperactivity can cause hypercoiling. Sometimes localized areas with less or more coiling are present and form so called strictures or torsions, that can lead to fetal demise (2).



**Figure 3.** Preterm stillborn infant and placenta with hypercoiled cord (2).

#### 1.3.1.4 Embryonic remnants

Embryonic vestiges of the umbilical cord are common findings and can be remnants of the allantoic or the omphalomesenteric ducts (2, 31).

Allantoic duct remnants can be present in 15% and are located in the proximal part of the umbilical cord. They are much more common in males (2). Usually, they are located centrally between the two umbilical arteries and contain cuboidal epithelial cells and occasionally a bit of mucus (2, 29). Mostly the allantoic remnants do not have any clinical significance, but in a few patients the duct can be patent and can cause urination from the clamped stump or a cyst formation. With a patent duct common complications later in life can be abscess formation and pyelonephritis (2). Remnants of the omphalomesenteric duct are usually asymptomatic and occur mostly near the outer edge of the cord and are also more present in males. They often contain columnar epithelium and muscular coats and are of endodermal origin. Sometimes they occur with atresia of the small intestine and Meckel's diverticulum (2).

### 1.3.2 Abnormalities of the umbilical vessels and vascular lesions

Single umbilical artery (SUA) is one of the most common congenital anomalies, affecting 1% of all babies. The absence of the left umbilical artery is more prevalent than the absence of the right artery (2, 32). Several maternal risk factors, including advanced maternal age, white ethnicity, multiparity, smoking, diabetes, hypertension, preeclampsia, maternal medication use, and epilepsy, have been linked to fetal SUA (33). SUA is three to seven times more common in multiple gestations than in singleton pregnancies (34).

In 33 % of fetuses with SUA, structural abnormalities of the cardiovascular, gastrointestinal, central nervous, and genitourinary systems are present.

The genitourinary and cardiovascular being the most frequent anomalies. 10% of the babies have additional chromosomal abnormalities, including trisomies 13, 18, and 21 (35). A fetus with SUA can be small for gestational age (SGA) with its birth weight being below the tenth percentile or suffering under IUGR (36). Isolated SUA are being associated with a higher rate of stillbirth, prematurity, and neonatal mortality (37). Additionally, they are frequently linked to placental abnormalities, abnormal cord length, polyhydramnios, and oligohydramnios (33).

Thrombosis of umbilical vessels is more common in veins than in arteries and most frequently occurs close to the term. It can be linked to velamentous cord insertion, inflammation, varices, entanglement and torsion of the umbilical cord. Cord thrombosis leads to decreased circulation that can end in IUGR, neurologic injury or even fetal death. Moreover, thrombi can break off and embolize, causing local infarction in the fetal or placental vessels. Maternal coagulation defects are associated with massive fetal central nervous system (CNS) lesions, strokes and neonatal thrombosis (2).

### 1.3.3 Abnormalities of insertion

In most pregnancies the umbilical cord inserts on the placental surface into or close to the center (2, 38). Improper cord insertion can lead to IUGR, fetal heart rate irregularities, placental abruption, premature labor, low Apgar scores, and infant death. Consequently, obstetric ultrasound (US) examinations should include a routine evaluation of the umbilical cord insertion location (38).

In around 5 to 7% the placenta inserts marginal and is also called "Battledore" placenta due to its racket resemblance (2, 39). As the pregnancy proceeds, marginal cord insertion might turn into velamentous cord insertion.

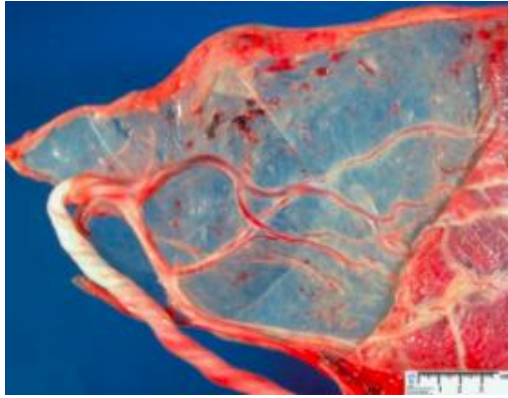
The reason for that is most likely the placental tissue atrophy at the cord attachment location sides due to a decreased blood supply (39, 40).

Multiple gestations are more likely to have marginal cord insertion, which might result in unequal placental tissue sharing and growth discordance (41). However, marginal cord insertion is not linked to an increased risk of fetal IUGR or preterm delivery in singleton pregnancies (42).

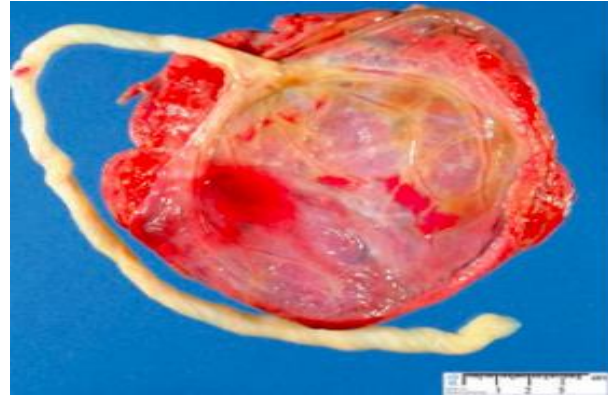
The velamentous cord insertion occurs in 1–2% of pregnancies and it occurs more frequently in multiple gestations. The umbilical veins diverge and pass between the chorion and the amnion and enter into these membranes, but do not reach the placenta.

As a result, neither the placenta nor Wharton jelly maintain the umbilical vessels, making them vulnerable to injuries (2, 43, 44). Velamentous cord insertions are linked to cord compression, IUGR, congenital abnormalities, premature labor, placental abruption, vasa previa, low Apgar scores, and aberrant intrapartum fetal heart rate patterns are. Patients should be evaluated with successive US examinations, if velamentous cord insertion is discovered during regular obstetric US assessment (44). Velamentous vessels that pass the membranes in the lower uterine segment are called vasa previa and are one of the most common complication of velamentous cord insertion (2, 38). They are usually without the support of Wharton jelly or placental tissues and present in 0.04% of the population.

Also, low-lying placenta, in vitro fertilization and multiple gestations increase the risk of vasa previa (38). If vasa previa is not diagnosed antenatally, it can result in fetal exsanguination by rupture of the umbilical vessels with or without rupture of the membranes. The mortality rate from intrapartum rupture is above 50% and more than 70%, if the hemorrhage occurs before delivery (2). During labor, the umbilical veins are also vulnerable to direct traumatic injury (45). Because the relationship between the placenta and the cord insertion site might alter as uterine size rises, a repeat US examination in the third trimester is recommended in cases of vasa previa (46). The chance of fetal survival increases from 44% to 97%, when vasa previa is diagnosed before the membranes rupture. To avoid any negative fetal outcome and prevent rupturing of the membranes, it is the best to deliver the baby via cesarean section (47).



**Figure 4.** Velamentous cord insertion (6).



**Figure 5.** Marginal cord insertion (6).

Furcate cord insertion is really rare and occurs when the umbilical vessels split and separate from the cord before reaching the surface of the placenta. Due to the deficient protection by the Wharton's jelly they become prone to thrombosis and injury. Most infants are normal, but nevertheless can stillbirth, fetal hemorrhage, varices and IUGR be consequences of furcate cord insertion (2).

#### 1.3.4 Mechanical lesions

Umbilical cord knots are knots that form in the fetal umbilical cord. They can be divided into so called true and false knots. A true knot in the UC is present when the UC loops upon itself and can be physically released or untied. True knots are clinically significant and occur in 1-2% of all pregnancies (48). Due to the compression of the umbilical vessels when the knot tightens, they increase the likelihood of hypoxic-ischemic encephalopathy and their associated fetal mortality can reach up to 10% (6, 48).

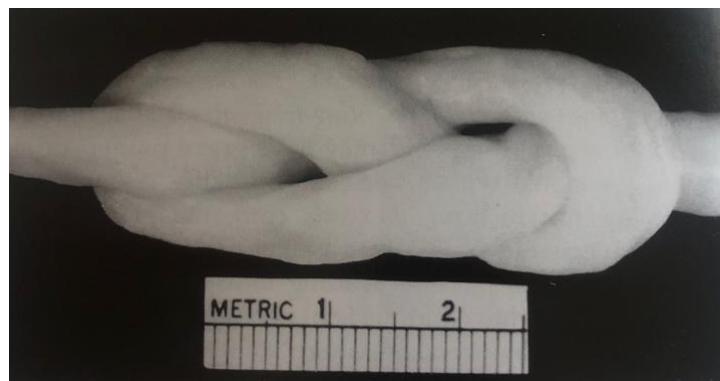
Whereas false knots, also called pseudoknots, are more likely to be a varicosity of an umbilical vessel, mostly the vein, or the focal accumulation of Wharton's jelly (48, 2). In comparison to true knots they cannot be manually untied. Pseudoknots occur much more often than true knots and are a common phenomena in most pregnancies. They usually do not have any clinical significance or long-term consequences for the fetus. It is believed that true knots develop early in pregnancy from week nine to twelve of gestation due to the relatively high amount of amniotic fluid and intrauterine space that can promote excessive fetal movements. As the fetus grows, a true knot may tighten or even form during the process of labor, when the UC undergoes traction. Monoamniotic twins, polyhydramnios, abnormal long UC, small size fetuses and advanced maternal age are all factors that can increase the incidence of having a true knot of the UC (48).



**Figure 6.** UC with tight true knot (2).



**Figure 7.** False knots, representing vascular redundancies (2).

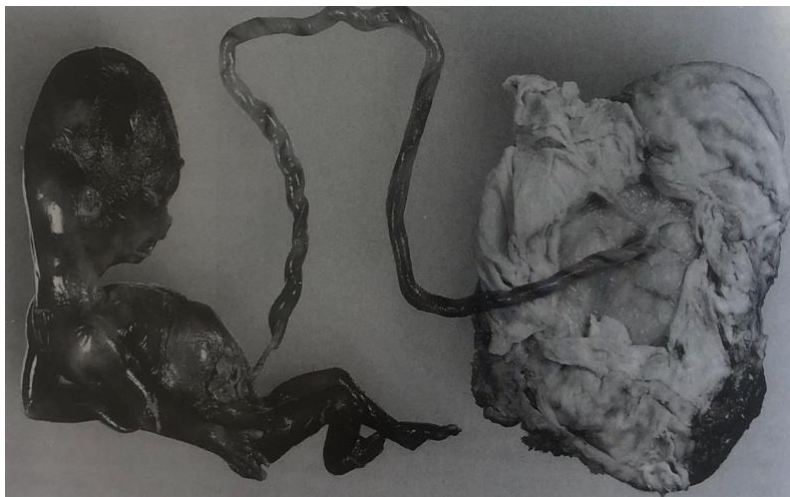

**Figure 8.** Loose true knot in an infant without sequelae (2).

Rupture of the umbilical cord can be either partial or complete. Incomplete rupture depicts the tearing of, or damage to, an umbilical vessel with the resulting formation of an UC hematoma. The hematoma is usually limited to the UC but if bleeding into the amniotic sac occurs then it is rather classified as "rupture of an umbilical vessel". Complete UC rupture is exceptionally rare and rarely occurs. Its actual incidence is nevertheless unknown (29).

Cord torsion can affect the whole cord but is generally more localized and characteristically located at the fetal end of the UC. Twists can be single or multiple and their extreme occurrence can lead to intrauterine fetal death. Their incidence is unknown but they can be linked with multigravid pregnancies due to the increased size of the abdomen and the uterus that promote fetal movements. Torsion seems to predominate in male infants and it is believed that they are more active and stronger and hence are prone to twist their UC. As mentioned earlier, excessively long cords and the occurrence of reduced Wharton's jelly are promoting the UC torsion and reduce the lumen of the UC vessels, therefore leading to intrauterine fetal demise.

Cord stricture is an uncommon but fatal condition, almost always leading to intrauterine fetal death. It is usually well defined, short and single, occurring mostly at the fetal end of the UC. Strictures are often accompanied by cord torsion and are sometimes described as coarctations due to the marked constriction of the umbilical vessels at the site of narrowing. They can cause the total obliteration of blood flow at the affected area. Like in cord torsions an extreme Wharton's jelly deficiency can often be found, as well as marked fibrosis at affected segments. The majority of infants does not survive with UC stricture leading to stillbirths (29).



**Figure 8.** Spontaneous abortion at 14 weeks gestation with hypercoiled UC and severe UC stricture near the fetal surface that lead to death (2).



### 1.3.5 Cord masses

Nodular bulges or masses of the umbilical cord are rare occurrences that can be detected prenatally by ultrasound examination. Due to their polymorphous presentation and their linked occurrence with a variety of other conditions, a further ultrasound investigation of the lesion is advised, as well as the referral of the newborn to a pediatric surgery clinic for additional evaluation and, if possible, surgical correction. The clinical significance is dependent on the size of the defect (49).

As stated before, umbilical cord tumors are quite uncommon but if they occur, then they are mostly of hemangiomic origin and are often located at the insertion side of the cord (50). They can contain well-defined clusters of thin-walled capillaries originating from the umbilical arteries, vein or vitelline capillaries. Due to the edematous degeneration of the Wharton's jelly they are of myxoid appearance (49).

Their etiology is still unknown, but they can occur as a true neoplasm or due to a developmental abnormality, a so-called hamartoma. Hemangiomas never metastasize but they can be associated with other hemangiomas occurring in the skin, liver, intra-abdominal or placental. They can be present as an isolated anomaly or if occurring massively they can be allied with polyhydramnios, IUGR, elevated maternal alpha-fetoprotein and other fetal malformations. Further evidence suggests its coexistence with premature delivery and in the worst case, with fetal death due to insufficient umbilical circulation, leading to nonimmune hydrops fetalis (49). Hemangiomas can be visualized by US but due to their fusiform, echogenic or multicystic origin they cannot be easily distinguished from umbilical cord teratoma or hematoma. Their vascular flow can also be demonstrated by US (50).

However, umbilical cord teratomas are mostly derived from more than one germ layer and contain different cellular and organoid components. They can be polymorphous and congenital and their consistency varies from soft and adipose to firm and solid. Depending on the embryonic layer they originate from, they can also contain cartilaginous or bony structures with distinct calcifications. Teratomas can be present at any level of the umbilical cord and they are usually considered benign, nevertheless one half of all teratomas is associated with other malformations (49).

Umbilical cord cystic lesions mostly originate from remaining embryonic vestiges that arise due to insufficient obliteration of the urachus and the omphalomesenteric duct.

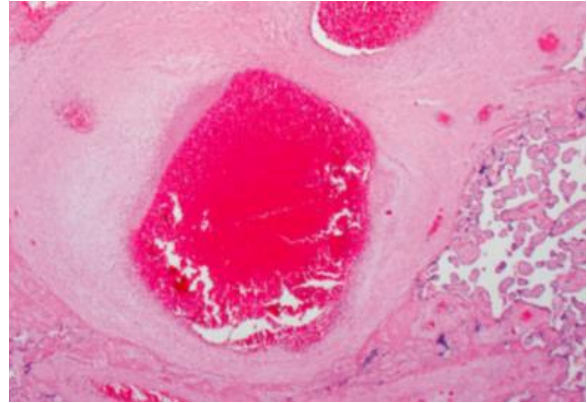
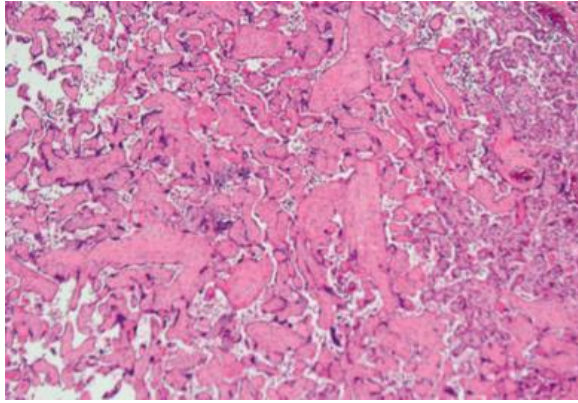
They usually occur isolated, however, they can be associated with other congenital anomalies. Multiple umbilical cord cysts increase the likelihood of miscarriage, aneuploidy and congenital anomalies (51). Further degeneration of Wharton's jelly secondary due to a persistent patent urachus, urachus cysts or abdominal wall defects, can lead to the formation of umbilical cord pseudocysts (49).

#### **1.4 Pathohistological abnormalities of the umbilical cord in fetal vascular malperfusion, maternal vascular malperfusion and inflammatory lesions**

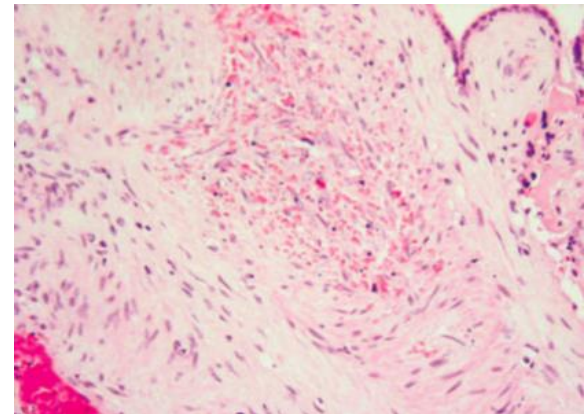
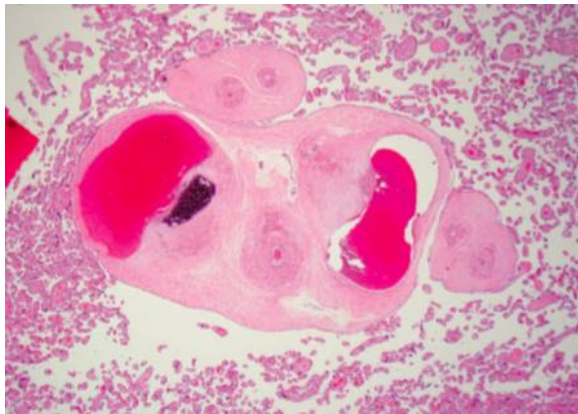
Fetal vascular malperfusion (FVM) stands for a group of placental lesions that indicate reduced or absent perfusion of the villous parenchyma by the fetus. The lesions mostly happen due to the obstruction in fetal blood flow that can be due to several conditions, most commonly causing stasis, ischemia and thrombosis. Maternal diabetes, fetal cardiac insufficiency and hyperviscosity, as well as inherited or acquired thrombophilia's are other factors that enhance the development of FVM (52). UC lesions, vascular intramural fibrin deposition, stem vessel obliteration, fibromuscular sclerosis, vascular ectasia and villous-stromal vascular karyorrhexis are all pathologies that are part of the FVM. They can affect the placenta globally and in worst cases cause placental insufficiency.

FVM can be differentiated into low grade or high grade. Low grade depicts the segmental FVM, mostly indicating the thrombotic occlusion of chorionic or stem villous vessels, or the stem vessel obliteration. Despite the lesions being segmental, the thrombus or obstruction would most possibly lead to the complete obstruction of the downstream villi.

The second type, the so called global FVM, describes the partial obstruction of the umbilical blood flow with venous ectasia, intramural fibrin deposition in larger vessels or smaller foci (<5 villi per focus) of avascular villi. Global FVM can be partial or intermittent but the lesions can be present all over the placenta. In cases of severe FVM, the term high-grade fetal vascular malperfusion can be used. It is indicated if more than one focus of avascular villi with or without a thrombus, or two or more occlusive or nonocclusive thrombi in the chorionic plate or major stem villi, or multiple nonocclusive thrombi, exist (53).



**Figure 9a.** A large focus of avascular villi (53). **Figure 9b.** Intramural fibrin deposition in a large main stem vessel (53).



**Figure 9c.** Intramural fibrin deposition and calcification, within a wall of a large fetal vessel (53). **Figure 9d.** Villous stromal-vascular karyorrhexis of fetal cells (53).

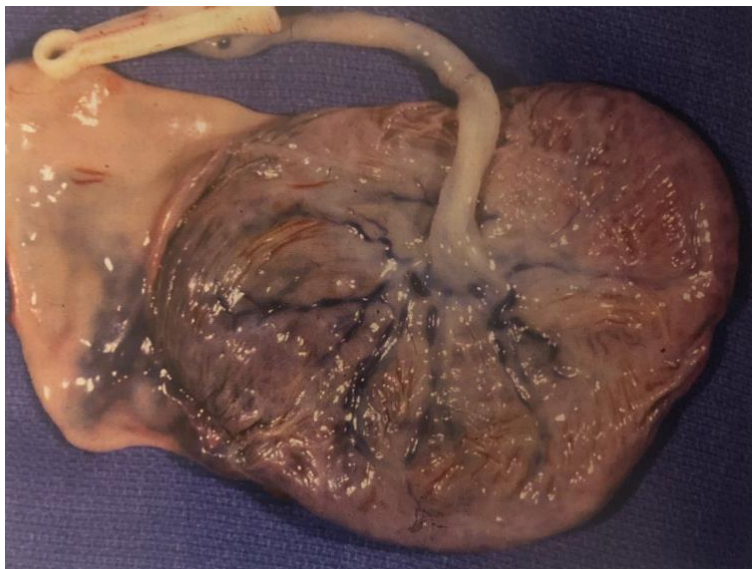
Placental hypoplasia, distal villous hypoplasia and accelerated villous maturation are all part of the maternal vascular malperfusion (MVM) pathologies. Placental hypoplasia can be diagnosed, if the placenta weights less than appropriate for its gestational age. A placenta is hypoplastic by definition, if the placental weight is below the tenth percentile and/or a thin umbilical cord is present. All these can lead to placental insufficiency that can finally cause fetal growth restrictions (FGR) and other complications during pregnancy (53).

Acute inflammatory lesions of the placenta include acute chorioamnionitis, funisitis, and chorionic vasculitis and represent a host response to a foreign substance, that can be maternal or fetal origin (54).

Chorioamnionitis is common, with an incidence of 20% to 24% of live births and up to 67% of preterm deliveries. It is often the result of an ascending bacterial infection and describes the maternal host response causing the acute inflammation of the chorion and amnion. Chorioamnionitis can cause preterm labors and preterm deliveries, which are leading causes of perinatal morbidity and mortality (2). One of its earliest histological signs is the polymorphonuclear infiltration of the extraplacental membranes (29).

When the inflammation accesses the amniotic cavity, a fetal response to the infection may occur, also called funisitis. During the process of inflammation, the inflammatory cells migrate towards the amnion and adhere at the vascular intima. They start to infiltrate the muscle fibers of the umbilical vein and arteries and subsequently infiltrate the Wharton's jelly (2).

A severe inflammation can change the placenta's macroscopic appearance, causing the fetal surfaces to lose their usual blue sheen and the membranes and fetal surface to become whitish and opaque, due to the inflammatory exudate of the polymorphonuclear leukocytes.



**Figure 10.** Term placenta with severe chorioamnionitis (2).

## **2. OBJECTIVES**

## **2.1 Objectives**

With the conduction of this study we aimed to determine the most common abnormalities of the UC and their relation to other placental pathologies.

Our secondary outcome was to determine UC morphological characteristics in placentas with UC abnormalities and to compare them with the UC morphological characteristics of placentas without UC abnormalities. Likewise, we aimed to determine gestational age, fetal birth weight, placental weight, placental diameter and thickness of the placentas with UC abnormalities and without UC abnormalities and to compare them.

## **2.2 Hypothesis**

Based on the findings of previously conducted studies we hypothesize that the most common umbilical cord pathology would be combined inflammatory lesion- fetal and maternal inflammatory response, rather than single occurring pathology. We also hypothesize that placentas with UC abnormalities in comparison to those without UC abnormalities have lower gestational age, shorter UC and velamentous UC insertion.

### **3. MATERIALS AND METHODS**

### **3.1 Study Design**

This retrospective study was conducted in the department of Pathology, Forensic and Cytology at the University Hospital of Split. The data were collected from the period of January 1<sup>st</sup> 2020 until the 31<sup>st</sup> of December 2020.

### **3.2 Materials**

The study included 202 placentas with various pathologies according to pathohistological reports. In 76 (37.65%) of those placentas an umbilical cord pathology was present. The data were collected from the Pathology Department's database using the following inclusion criteria: placental pathohistological reports from the time span between January 1<sup>st</sup> 2020 until the 31<sup>st</sup> of December 2020, that had the following International classification of disease codes (ICD code) for placental abnormalities: O41, O43, O45, O69, and Q27.0. Exclusion criteria were all of the placentas with insufficient data or misplaced ICD codes. From the placental pathohistological reports we noted descriptive information regarding gestational age (in weeks) and fetal birth weight (in grams), followed by morphological findings (placental weight, diameter (in cm) and thickness (in cm). Additionally, data about the UC length and diameter, number of blood vessels, insertion site of the UC and the coiling index were obtained. Likewise, any abnormal histological finding, consisting of FVM, MVM and inflammatory lesions, was also noted.

### **3.3 Methods of data collection and processing**

After the data from the Pathology Department's database was collected, it was further processed into tables. Additional analysis was made with the use of Microsoft Excel and Microsoft Word processing software.



### **3.4 Statistical analysis**

The MedCalc Software (MedCalc Software, Ostend, Belgium; [medcalc.org](http://medcalc.org); 2019, RRID:SCR\_015044) was used for the statistical analysis of the data previously collected.

To interpret the statistical significance of the sampling distribution the chi-square test, as well as the Mann-Whitney U test were used and  $p < 0.05$  was determined as the statistical significance value.

### **3.5 Ethical committee approval**

The Hospital ethical committee approval number for the study from the University Hospital of Split is the following: 500-03/21-01/117

## **4. RESULTS**

From January 1<sup>st</sup> till December 31<sup>st</sup> of 2020, there were 202 placentas with various pathologies according to pathohistological reports, 76 (37.65%) of those placentas had an umbilical cord pathology. Descriptive information for studied placentas, as well as the fetal weight, are presented in Table 1.

**Table 1.** Descriptive information

<b>Descriptive parameters</b>	<b>Placental with UC abnormalities</b>	<b>Placentas without UC abnormalities</b>	<b><i>P</i></b>
Gestational age (weeks)	34 (13-41)	35 (11-40)	0.027*
Fetal birthweight (grams)	2142 ± 1218	2376 ± 973	0.182†
Placental weight (grams)	418 (34-902)	417 (20-1178)	0.849*
Largest placental diameter (cm)	17 (1-27.5)	16 (5-29)	0.461*
Placental thickness (cm)	2.5 (0.5-6)	2.5 (1-7)	0.436*
Umbilical cord length (cm)	33 ± 15.17	38 ± 14.93	0.053†
Umbilical cord diameter (cm)	1 (0.1-2.5)	1 (0.5-2)	0.096*
Umbilical cord diameter (cm)	0.23 (0.01-0.94)	0.20 (0.07-3)	0.129*
Coiling index Umbilical cord insertion	15 (19.73%)	23 (18.25%)	
- Central	21 (27.63%)	65 (51.58%)	0.0005††
- Paracentral	26 (34.21%)	34 (26.98%)	
-Paramarginal	3 (3.94%)	4 (3.17%)	
- Marginal	11 (14.45%)	0	
- Velamentous			

Values are presented as arithmetic mean with minimum and maximum value, median values with ± standard deviations and absolute numbers with percentages

\*Mann-Whitney U test; † Students t-test; †† Chi-squared test

Placentas with UC abnormalities had statistically significant lower gestational age than placentas without UC abnormalities (P=0.027). There were no statistically significant differences between the studied groups regarding fetal birthweight (P=0.182), placental weight (P=0.849), largest placental diameter (P=0.46), placental thickness (P=0.436)

UC diameter (P=0.096) or UC coiling index (P=0.129).

Placentas with UC abnormalities had a statistically significant shorter UC length than placentas without UC abnormalities (P=0.053). The most common UC site insertion among placentas with UC abnormalities was paramarginal, while paracentral insertion was the most common UC insertion site among placentas without UC abnormalities.

None of the placentas without UC abnormalities had velamentous UC insertion, unlike 11 placentas with UC abnormalities, which was statistically significant (P=0.0005).

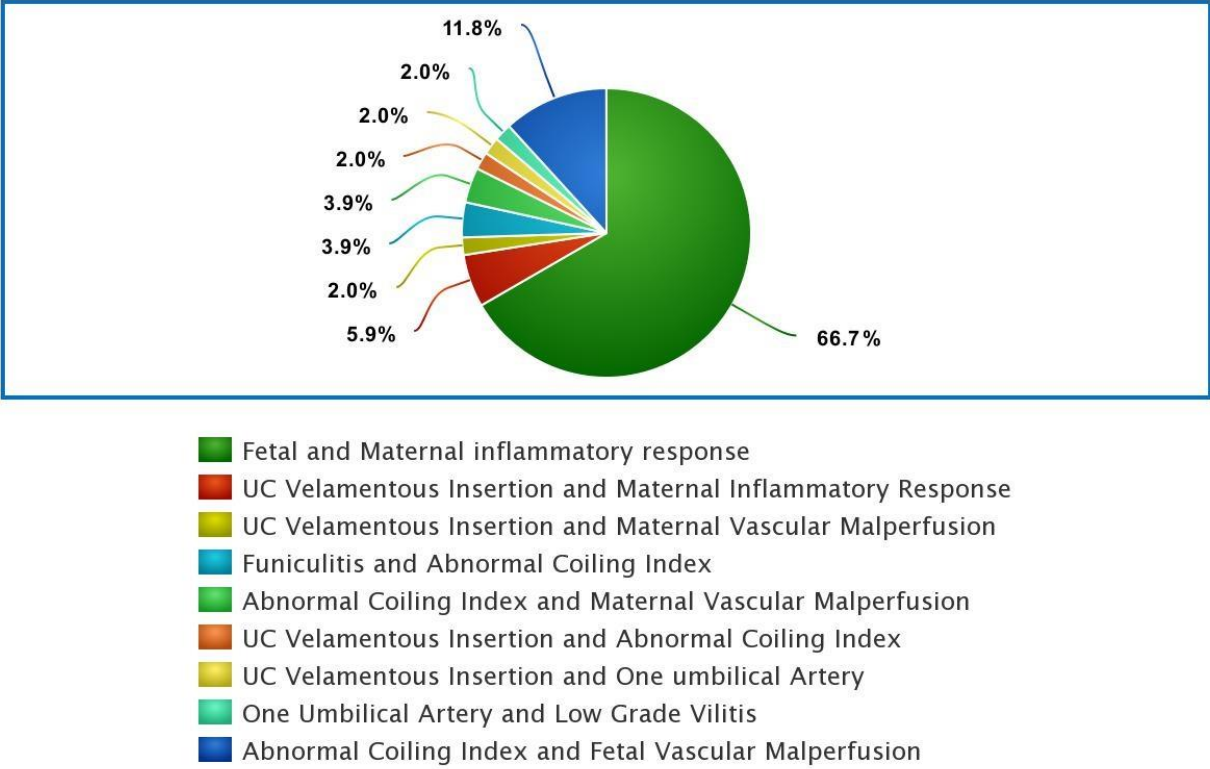
The most common umbilical cord abnormalities are presented in Table 2.

**Table 2.** Umbilical cord abnormalities

<b>Pathology</b>	<b>N (%)</b>	<b>P</b>
UC abnormality joined with other placental abnormalities	51(67.1%)	
Abnormal coiling index	15 (19.7%)	<0.001†
Funiculitis	4 (5.3%)	
One umbilical artery	3 (3.9%)	
Fetal vascular malperfusion	1 (1.3%)	
Velamentous UC insertion	1 (1.3%)	
True UC knot	1 (1.3%)	

† Chi-squared test

UC abnormalities combined with other placental abnormalities were the most common finding, which was statistically significant ( $P < 0.001$ ). The most common multiple abnormalities are presented in Figure 1.



**Figure 11.** UC abnormality joined with other placental abnormalities

The most common UC abnormalities joined with other placental abnormalities were the joined fetal and maternal inflammatory response, noted in 34 (66.7%) placentas, while the least common multiple abnormalities in placentas with UC abnormalities were velamentous insertion with abnormal CI, velamentous insertion with one umbilical artery and one umbilical artery with low grade villitis, all noted in one placenta respectively, which was statistically significant ( $P < 0.001$ ).

The most common placental abnormalities among placentas without UC abnormalities are presented in Table 3.

**Table 3.** Placental abnormalities of placentas without umbilical cord abnormalities

<b>Pathology</b>	<b>N(%)</b>	<b>P</b>
Maternal Vascular Malperfusion	59 (46.8%)	
Maternal Inflammatory response	24 (19%)	<0.0001*
Intervillous Thrombosis	19 (15.1%)	
Multiple placental abnormalities	15 (11.9%)	
High Grade Villitis	3 (2.4%)	
Plasma Cell Deciduitis	3 (2.4%)	
Villitis Basalis	1 (0.8%)	

\* Chi-squared test

The most common placental abnormality among placentas without UC abnormalities was maternal vascular malperfusion, noted in 59 (4.8%) of placentas, while villitis basalis was noted in just one placenta, which was statistically significant ( $P < 0.0001$ ).

In the group of multiple placental abnormalities without the UC abnormality, the most common one was maternal inflammatory response joined with maternal vascular malperfusion in 6 (40%) placentas, followed by maternal vascular malperfusion with low grade villitis in 4 (26.6%) placentas, plasma cell deciduitis with vilitis basalis in 3 (20%) placentas and plasma cell deciduitis with low grade villitis and low grade villitis with villitis basalis, each in one placenta.

## **5. DISCUSSION**

The umbilical cord is mandatory for a normal pregnancy to function and should make the stable interconnection between the fetus and the mother. Nevertheless, any UC abnormality can influence the perinatal outcome and therefore the health of the fetus and the mother.

In the last decades it has become more evident that UC abnormalities can be various, and the most common ones are being related to its morphology, UC insertion site, number of vessels and tumors (7).

In our study we investigated the presence of UC abnormalities in placental pathohistological reports from the database of the Pathology Department at the University Hospital of Split, in a one-year time span from January 1<sup>st</sup> 2020 to December 31<sup>st</sup> 2020.

There were 202 placentas with various pathologies according to pathological reports, 76 (37.65%) of those placentas had an umbilical cord pathology.

The most common UC pathology was UC abnormality, joined with other placental pathologies, that was noted in 51 cases. Among those the most common one being the fetal inflammatory response, also known as funisitis, combined with the maternal inflammatory response (chorioamnionitis) that was noted in 34 cases. This result is in accordance with our finding that placentas with UC abnormality had statistically significant lower gestational age than placentas without UC abnormality, since the most common cause of preterm delivery is chorioamnionitis with or without funisitis (55).

Furthermore, this finding suggests that when chorioamnionitis is present, one should meticulously conduct UC histological examination, since funisitis is a known companion and its presence indicates adverse perinatal outcomes. As anticipated before and corresponding to the significant lower gestational age of placentas with UC abnormality, the significantly shorter UC was more common in placentas with UC pathology than without UC abnormality.

However, there were no statistically significant differences between the studied group regarding fetal birth weight, placental weight, largest placental diameter, placental thickness, UC diameter or UC CI. Although one would expect statistically significant lower birth and placental weight regarding lower gestational age in placentas with UC abnormalities, our findings showed no such difference. Possible explanation could be the wide percentiles range for placental weight and fetal birth weight according to gestational age.

The second most common umbilical cord abnormality was the presence of abnormal coiling, that was evident in 15 placentas. The abnormal coiling index was only recently recognized as a potential source of fetal adverse outcome, and in such cases, it is often combined with histological signs of FVM (53).



However, the presence of abnormal coiling index does not indicate FVM per se.

This can be proven by our results, since we found only one case of FVM and 15 cases of abnormal coiling index. The other isolated UC abnormalities were funisitis in 4 placentas and the SUA in 3 samples. The least common abnormalities other than FVM, were the velamentous UC cord insertion and the true UC knot, each accounting for 1.3%.

In 11 placentas velamentous UC insertion was noted, and since velamentous insertion is the only UC insertion considered pathological, there was none in the placentas without UC abnormalities (2).

Furthermore, we also investigated the most common placental abnormalities among placentas without UC abnormalities. Most frequently, we noted the maternal vascular malperfusion, present in 59 placentas. Followed by the maternal inflammatory response that was evident in 24 placentas and the intervillous thrombosis that has been detected in 19 placentas.

In 15 placentas multiple placental abnormalities were detected. Those could further be divided into maternal inflammatory response joined with maternal vascular malperfusion, accounting for 6 placentas. They were followed by maternal vascular malperfusion and low grade villitis in 4 placentas. Plasma cell deciduitis with villitis basalis in 3 placentas and plasma cell deciduitis with low grade villitis and low grade villitis with villitis basalis, accounted each for one placenta. Our findings are in accordance with other studies that investigated morphological placental characteristics (53).

Our studies major limitation is its retrospective nature and sample size. Moreover, it is possible that a lot of stillbirths do not even get diagnosed with an umbilical cord pathology, as well as not all placentas become pathohistologically checked after birth. Another limitation is that a retrospective study relies on accurate record keeping which is prone to bias due to possible imprecision and mistakes.

## **6. CONCLUSION**

According to pathohistological reports the most common finding was the umbilical cord abnormality combined with other placental pathologies.

The most prominent being the combined fetal and maternal inflammatory response.

The least common abnormalities were the fetal vascular malperfusion, the velamentous UC insertion and the true UC knot. As earlier mentioned, the umbilical cord is essential in the whole process of pregnancy and any abnormality of it should be diagnosed as early as possible.

Further research is required to reveal the exact reason of umbilical cord abnormalities and to improve their detection, in order to decrease their potential harm on the fetus and the mother.

## **7. REFERENCES**

1. Gude NM, Roberts CT, Kalionis B, King RG. Growth and function of the normal human placenta. *Thrombosis Research*. 2004;114:397-407.
2. Baergen RN. *Manual of Benirschke and Kaufmann's pathology of the human placenta*. New York: Springer; 2005. p. 240-76.
3. Sadler TW. *Langman's medical embryology*. 14th ed. Philadelphia: Wolters Kluwer; 2019. p. 117-47.
4. Mescher AL. *Junqueira's basic histology text & atlas*. 15th ed. New York: Lange; 2018. p. 478.
5. Ross MH, Wojciech P. *Histology text and atlas with correlated cell and molecular biology*. 7th ed. Philadelphia: Wolters Kluwer; 2015. p. 858-60.
6. Fahmy M. *Umbilicus and umbilical cord*. Cairo: Springer; 2018. p. 47-85.
7. Moshiri M, Zaidi SF, Robinson TJ, Bhargava P, Siebert JR, Dubinsky TJ, Katz DS. Comprehensive imaging review of abnormalities of the umbilical cord. *Radiographics*. 2014;34:179-96.
8. Kapila V, Chaudhry K. *Physiology, Placenta* [Internet] StatPearls Publishing: Treasure Island (FL); 2021 [updated 2021 January; cited 2021 July 26]. Available from: <https://pubmed.ncbi.nlm.nih.gov/30855916>
9. Muniraman H, Sardesai T, Sardesai S. Disorders of the umbilical cord. *Pediatric review*. 2018;39:332-41.
10. Krzyżanowski A, Kwiatek M, Gęca T, Stupak A, Kwaśniewska A. Modern ultrasonography of the umbilical cord: Prenatal diagnosis of umbilical cord abnormalities and assesment of fetal wellbeing. *Med Sci Monit*. 2019;25:3170-180.
11. Morton SU, Brodsky D. Fetal physiology and the transition to extrauterine life. *Clin Perinatol*. 2016;43:395-407.
12. Finnemore A, Groves A. physiology of the fetal and transitional circulation. *Semin Fetal Neonatal Med*. 2015;20:210–6.
13. Petraglia F, Florio P, Torricelli M. Placental endocrine function. *Knobil and Neill's physiology of reproduction*. 3<sup>rd</sup> ed. Amsterdam: Elsevier; 2006. p. 2847-97.
14. Brunton PJ, Russell JA. 2010 Endocrine induced changes in brain function during pregnancy. *Brain Res*. 2010;1364:198-215.
15. Freemark M. Regulation of maternal metabolism by pituitary and placental hormones: roles in fetal development and metabolic programming. *Hormone Research*. 2006;653:41-9.
16. Newbern D, Freemark M. Placental hormones and the control of maternal metabolism and fetal growth. *Curr Opin Endocrinol Diabetes Obes*. 2011;18:409-16.

17. Burton GJ, Fowden AL, The placenta: a multifaceted, transient organ. *Philos Trans R Soc Lond B Biol Sci.* 2015;370:20140066.
18. Caufriez A, Frankenne F, Hennen G, Copinschi G. Regulation of maternal IGF-I by placental GH in normal and abnormal human pregnancies. *Am J Physiol.* 1993;265:E572-7.
19. Sferruzzi-Perri AN, Owens JA, Pringle KG, Roberts CT. The neglected role of insulin-like growth factors in the maternal circulation regulating fetal growth. *J Phy.* 2011;589:7-20.
20. Fowden AL, Sferruzzi-Perri AN, Coan PM, Constancia M, Burton GJ. Placental efficiency and adaptation: endocrine regulation. *J Physiol.* 2009;587:3459-72.
21. De Laat MW, Van Alderen ED, Franx A, Visser GH, Bots ML, Nikkels PG. The umbilical coiling index in complicated pregnancy. *Eur J Obstet Gynecol Reprod Biol.* 2007;130:66-72.
22. Lacroix M, Kina E, Hivert MF. Maternal/fetal determinants of insulin resistance in women during pregnancy and in offspring over life. *Curr Diab Rep.* 2013;13:238e44.
23. McMaster MT, Zhou Y, Fisher SJ. Abnormal placentation and the syndrome of preeclampsia. *Semin Nephrol.* 2004;24:540e7.
24. Fisher SJ. The placental problem: linking abnormal cytotrophoblast differentiation to the maternal symptoms of preeclampsia. *Reprod Biol Endocrinol* 2004;2:53.
25. Zhou Y, Gormley MJ, Hunkapiller NM, Kapidzic M, Stolyarov Y, Feng V, et al. Reversal of gene dysregulation in cultured cytotrophoblasts reveals possible causes of preeclampsia. *J Clin Invest.* 2013;123:2862e72.
26. Silasi M, Cohen B, Karumanchi SA, Rana S. Abnormal placentation, angiogenic factors, and the pathogenesis of preeclampsia. *Obstet Gynecol Clin North Am.* 2010;37:239e53.
27. Norwitz ER. Defective implantation and placentation: laying the blueprint for pregnancy complications. *Reprod Biomed Online.* 2006;13:591e9.
28. Rees S, Inder T. Fetal and neonatal origins of altered brain development. *Early Hum Dev.* 2005;81:753e61.
29. Fox H, Sebire NJ. *Pathology of the placenta.* 3<sup>rd</sup> ed. Manchester, UK: Saunders Elsevier; 2007. p. 303-39.
30. Giacoia GP. Body stalk anomaly: congenital absence of the umbilical cord. *Obstet Gynecol.* 1992;80:527-9.
31. Jauniaux E, De Munter C, Vanesse M, Wilkin P, Hustin J. Embryonic remnants of the umbilical cord: morphologic and clinical aspects. *Hum Pathol.* 1989;20:458-62.
32. Kellow ZS, Feldstein VA. Ultrasound of the placenta and umbilical cord: a review. *Ultrasound Q.* 2011;27:187-97.

33. Murphy-Kaulbeck L, Dodds L, Joseph KS, Van den Hof M. Single umbilical artery risk factors and pregnancy outcomes. *Obstet Gynecol.* 2010;116:843-50.
34. Martínez-Payo C, Gaitero A, Tamarit I, García-Espantaleón M, Iglesias Goy E. Perinatal results following the prenatal ultrasound diagnosis of single umbilical artery. *Acta Obstet Gynecol Scand.* 2005; 84:1068-74.
35. Lubusky M, Dhaifalah I, Prochazka M. Single umbilical artery and its siding in the second trimester of pregnancy: relation to chromosomal defects. *Prenat Diagn.* 2007;27:327-31.
36. Mu SC, Lin CH, Chen YL, Sung TC, Bai CH, Jow GM. The perinatal outcomes of asymptomatic isolated single umbilical artery in full-term neonates. *Pediatr Neonatol.* 2008;49:230-3.
37. Peregrine E, O'Brien P, Jauniaux E. Ultrasound detection of nuchal cord prior to labor induction and the risk of cesarean section. *Ultrasound Obstet Gynecol.* 2005; 25:160-4.
38. Marino T. Ultrasound abnormalities of the amniotic fluid, membranes, umbilical cord, and placenta. *Obstet Gynecol Clin North Am.* 2004;31:177-200.
39. Kellow ZS, Feldstein VA. Ultrasound of the placenta and umbilical cord: a review. *Ultrasound Q.* 2011;27:187-97.
40. Di Salvo DN, Benson CB, Laing FC, Brown DL, Frates MC, Doubilet PM. Sonographic evaluation of the placental cord insertion site. *AJR Am J Roentgenol.* 1998;170:1295-8.
41. Abramowicz JS, Sheiner E. Ultrasound of the placenta: a systematic approach. II. Functional assessment (Doppler). *Placenta.* 2008;29:921-9.
42. Liu CC, Pretorius DH, Scioscia AL, Hull AD. Sonographic prenatal diagnosis of marginal placental cord insertion: clinical importance. *J Ultrasound Med.* 2002; 21:627-32.
43. Hasegawa J, Matsuoka R, Ichizuka K, Sekizawa A, Farina A, Okai T. Velamentous cord insertion into the lower third of the uterus is associated with intrapartum fetal heart rate abnormalities. *Ultrasound Obstet Gynecol.* 2006;27:425-9.
44. Sepulveda W, Rojas I, Robert JA, Schnapp C, Alcalde JL. Prenatal detection of velamentous insertion of the umbilical cord: a prospective color doppler ultrasound study. *Ultrasound Obstet Gynecol.* 2003;21: 564-9.
45. Elsayes KM, Trout AT, Friedkin AM, et al. Imaging of the placenta: a multimodality pictorial review. *RadioGraphics.* 2009;29:1371-91.
46. Baulies S, Maiz N, Muñoz A, Torrents M, Echevarría M, Serra B. Prenatal ultrasound diagnosis of vasa praevia and analysis of risk factors. *Prenat Diagn.* 2007;27:595-9.
47. Oyelese Y. Placenta, umbilical cord and amniotic fluid: the not-less-important accessories. *Clin Obstet Gynecol.* 2012;55:307-23.

48. American baby and child law center [Internet] Bloomfield Hills: Reiter and Walsh; 2020. True knot causing hypoxic-ischemic encephalopathy and cerebral palsy; 2020 [cited 2021 Jul 21]. Available form: <https://abclawcenters.com/true-knot-causing-hypoxic-ischemic-encephalopathy-and-cerebral-palsy>
49. Natalucci G, Wisser J, Weil R, Stallmach T, Bucher HU. Your diagnosis? Umbilical cord tumor. *Eur J Pediatr.* 2007;166:753-6.
50. Papadopoulos VG, Kourea HP, Adonakis GL, Decavalas GO. A case of umbilical cord hemangioma: doppler studies and review of the literature. *Eur J Obstet Gynecol Reprod Biol.* 2009;144:8-14.
51. Grezzi F, Raio L, Di Naro E, Franci M, Cromi A, Durig P. Single and multiple umbilical cord cysts in early gestation: two different entities. *Ultrasound Obstet Gynecol.* 2003;21:215-9.
52. Redline RW, Ravishankar S. Fetal vascular malperfusion, an update. *Apmis.* 2018; 126:561-9.
53. Khong Yee T, Mooney EE, Ariel I, Balmus NCM, Boyd TK, Brundler MA et al. Amsterdam sampling and definitions of placental lesions: Amsterdam placental workshop group consensus statement. *Arch Pathol Lab Med.* 2016;140:698-713.
54. Kim JC, Romero R, Chaemsathong, Chaiyasit N, Yoon HB, Kim MY. Acute chorioamnionitis and funisitis: definition, pathologic features, and clinical significance. *Am J Obstet Gynecol.* 2015;213:S29-52.
55. Galinsky R, Polglase GR, Hooper SB, Black MJ, Moss TJM. The consequences of chorioamnionitis: preterm birth and effects on development. *J pregnancy.* 2013;2013:412831.



## **8. SUMMARY**

**Objectives:** to determine the most common abnormalities of the UC and their relation to other placental pathologies. Secondary outcome was to determine UC morphological characteristics in placentas with UC abnormalities and to compare them with the placentas without UC abnormalities. Likewise, we aimed to determine gestational age, fetal birth weight, placental weight, placental diameter and thickness of the placentas with UC abnormalities and without UC abnormalities and to compare them with each other.

**Materials and methods:** retrospective study within the time span from January 1<sup>st</sup> 2020 to December 31<sup>st</sup> 2020 was conducted at the department of Pathology, Forensic Medicine and Cytology, University Hospital of Split. Placental pathohistological reports that had following International classification of diseases codes (ICD code) for placental abnormalities: O41, O43, O45, O69, and Q27.0 were included in the study. Exclusion criteria were all of the placentas with insufficient data or misplaced ICD codes.

**Results:** From the 202 pathohistological reports of placentas with various pathologies, 76 (37.65%) placentas had an umbilical cord pathology. The most common umbilical cord abnormality was the presence of UC abnormality combined with other placental abnormalities found in 51 placentas, of which the combined fetal and maternal inflammatory response, found in 34 (66.7%) placentas was the most common one and therefore statistically significant ( $P < 0.0001$ ).

The least common UC abnormalities in placentas with UC abnormality were the fetal vascular malperfusion, velamentous insertion and true knot. The most common placental abnormality among placentas without UC abnormalities was maternal vascular malperfusion, that was noted in 59 (4.8%) placentas, while villitis basalis was noted in just one placenta, which was statistically significant ( $P < 0.0001$ ).

**Conclusion:** The most common finding according to pathohistological reports was the abnormality of the UC joined with other placental abnormalities. In order to understand the pathology of UC better and its effect on perinatal morbidity and mortality further studies are necessary.

## **9. ZAKLJUČCI**

**Ciljevi:** utvrditi najučestaliju abnormalnost pupčane vrpce (PV) i odnos prema drugim patološkim lezijama posteljice. Sekundarni cilj je bio utvrditi morfološke karakteristike PV posteljica s abnormalnostima PV i rezultate usporediti s posteljicama koje su imale uredne PV. Također, odrediti gestacijsku dob, porođajnu masu djeteta, masu posteljice, dijametar i debljinu posteljice u skupini posteljica s abnormalnostima PV i rezultate usporediti s posteljicama urednih PV.

**Materijali i metode:** retrospektivna jednogodišnja studija, u razdoblju od 1. siječnja 2020. godine do 31. prosinca 2020. godine, provedena je na Odjelu Patologije, Kliničkog zavoda za Patologiju, Sudsku medicinu i Citologiju, KBC Split. U studiju su uključeni svi patohistološki nalazi posteljica sa sljedećim šiframa Međunarodne Klasifikacije Bolesti (MKB): O41, O43, O45, O69 i Q27.0. Iz studije su isključeni svi patohistološki nalazi posteljica čiji su podaci bili nepotpuni ili su MKB šifre bile pogrešno dodijeljene.

**Rezultati:** U studiju je uključeno 202 patohistološka nalaza posteljica s bilo kojom patologijom, od čega je bilo 76 (37,65%) posteljica koje su imale PV abnormalnosti. Najučestalija abnormalnost PV je abnormalnost PV udružena s drugim abnormalnostima posteljice, što je zabilježeno u 51 posteljici, od čega je najučestalija abnormalnost bila udruženi fetalni i majčin upalni odgovor zabilježen u 34 posteljice ( $P < 0,0001$ ). Najrjeđa izolirana abnormalnost PV je bila fetalna vaskularna malperfuzija, velamentozna insercija i pravi čvor pupkovine. Najučestalija lezija posteljice u skupini posteljica bez abnormalnosti PV je bila maternalna vaskularna malperfuzija, zabilježena u 59 posteljica, a najrjeđa bazalni vilitis zabilježen u jednoj posteljici ( $P < 0,0001$ ).

**Zaključak:** Prema patohistološkim nalazima najučestalija abnormalnost PV je bila abnormalnost PV udružena s drugim posteljičnim lezijama. U svrhu boljeg razumijevanja patologije PV te njenog utjecaja na perinatalni morbiditet i mortalitet potrebno je provesti daljnja istraživanja.

## **10. CURRICULUM VITAE**

**PERSONAL INFORMATION:**

Name and surname: Luise Mangelsen

Date of birth: 14.09.1995

Country of birth: Germany

Email: luisemangelsen@outlook.com

**EDUCATION:**

August 2008 - July 2014                      High School - Arndt - Gymnasium Dahlem, Berlin,  
Germany

October 2014 - September 2021            Doctor of medicine - University of Split School of  
Medicine, Split, Croatia

**LANGUAGES:**

German, English, Croatian, Latin