

Evaluation of one day discharge after the laparoscopic appendectomy in children operated for uncomplicated appendicitis at Department of pediatric surgery, University hospital of Split

Tesch, Alexander

Master's thesis / Diplomski rad

2022

Degree Grantor / Ustanova koja je dodijelila akademski / stručni stupanj: **University of Split, School of Medicine / Sveučilište u Splitu, Medicinski fakultet**

Permanent link / Trajna poveznica: <https://urn.nsk.hr/urn:nbn:hr:171:124612>

Rights / Prava: [In copyright](#)/[Zaštićeno autorskim pravom.](#)

Download date / Datum preuzimanja: **2024-12-28**



Repository / Repozitorij:

[MEFST Repository](#)



**UNIVERSITY OF SPLIT
SCHOOL OF MEDICINE**

ALEXANDER TESCH

**EVALUATION OF ONE DAY DISCHARGE AFTER LAPAROSCOPIC
APPENDECTOMY IN CHILDREN OPERATED FOR UNCOMPLICATED
APPENDICITIS**

Diploma thesis

Academic year

2021/2022

Mentor:

Miro Jukić, MD, PhD

Split, July 2022

**UNIVERSITY OF SPLIT
SCHOOL OF MEDICINE**

ALEXANDER TESCH

**EVALUATION OF ONE DAY DISCHARGE AFTER LAPAROSCOPIC
APPENDECTOMY IN CHILDREN OPERATED FOR UNCOMPLICATED
APPENDICITIS**

Diploma thesis

Academic year

2021/2022

Mentor:

Miro Jukić, MD, PhD

Split, July 2022

TABLE OF CONTENT

1. INTRODUCTION.....	1
1.1. Vermiform appendix	2
1.1.1. Embryology	2
1.1.2. Anatomy	2
1.1.3. Histology	3
1.2. Acute appendicitis	4
1.2.1. Historic review	4
1.2.2. Epidemiology of acute appendicitis	5
1.2.3. Etiology of acute appendicitis	6
1.2.4. Pathophysiology of acute appendicitis	6
1.2.5. Complications.....	8
1.3. Diagnostics	8
1.3.1. Anamnesis	8
1.3.2. Physical examination.....	9
1.3.3. Laboratory workup	10
1.3.4. Radiological workup	11
1.3.4.1. Ultrasonography	11
1.3.4.2. Computed tomography	12
1.3.4.3. Magnetic resonance imaging	12
1.3.5. Scoring system for acute appendicitis	12
1.3.6. Differential diagnosis	15
1.4. Treatment options.....	16
1.4.1. Nonoperative management.....	16
1.4.2. Surgical treatment	16
1.4.2.1. Open appendectomy	17
1.4.2.2. Laparoscopic appendectomy	17
1.5. Fast track surgeries.....	17
1.5.1. One day discharge after appendectomy	18
1.5.2. Effects of hospitalization in pediatric population	18
1.5.3. Parent education and home management	19
2. OBJECTIVES OF RESEARCH.....	20
3. PATIENTS AND METHODS.....	22
3.1. Patients	23
3.2. Type of study.....	23
3.3. Place of study	23
3.4. Methods of data collection and processing	23
3.5. Description of research.....	23
3.6. Primary outcome measure	24
3.7. Secondary outcome measure	24
3.8. Compliance with ethical standards.....	24
3.9. Surgery	24

4. RESULTS.....	26
4.1. Demographic and clinical data.....	27
4.2. Outcomes of treatment	28
4.3. Complications.....	29
4.4. Parental satisfaction.....	30
5. DISCUSSION	32
6. CONCLUSION.....	37
7. REFERENCES	39
8. ENGLISH SUMMARY	49
9. CROATIAN SUMMARY	51
10. CURRICULUM VITAE	53
11. SUPPLEMENTS	55

ACKNOWLEDGEMENT

First, and foremost, I want to thank my mentor Miro Jukić, MD, PhD for the great support and trust conducting this clinical study for my diploma thesis. Thank you to the staff at the surgical emergency department for the patience and knowledge transfer over the last 2 years, my parents without them I could not pursue my dream and my brother believing in me.

LIST OF ABBREVIATIONS

AA – Acute appendicitis

AIR – Appendicitis inflammatory response score

BMI – Body mass index

CRP – C-reactive protein

CT – Computed tomography

IQR – Interquartile range

LOS – Length of stay

MRI – Magnetic resonance imaging

NOM – Nonoperative management

NPV – Negative predictive value

PPV – Positive predictive value

PAS – Pediatric appendicitis score

RLQ – Right lower quadrant

SARS-CoV-2 – Severe acute respiratory syndrome coronavirus type 2

SDD – Same day discharge

US – Ultrasound

VAS – Visual analogue scale

WBC – White blood count

1. INTRODUCTION

1.1. Vermiform appendix

Due to its clinical importance, the vermiform appendix (lat. *appendix vermiformis*) has been thoroughly investigated both anatomically and histologically.

1.1.1. Embryology

By the eight week of gestation the appendix is visible only histologically. Around the 12th week of gestation, the midgut reduces back into the abdomen, elongation of the colon continues, and formation of the mesenteries finalizes. During this time the vermiform appendix develops as a small diverticulum (lat. *diverticulum*) from the cecum (lat. *caecum*). As the appendix becomes more visible it arrests at various position around the cecum. Congenital malformations like agenesis or hypoplasia have been reported but seem to be rather rare. In some children a mucosal fold called Gerlach's valve, will partially cover the appendiceal orifice (1).

1.1.2. Anatomy

The appendix arises posteromedial and inferior to the ileocecal valve (lat. *valva ileocaecalis*) and lies intraperitoneal. As previously stated during development the appendix may arrest in different positions in relation to the cecum. The following are usually found in anatomy books: retrocecal around 65%, pelvic up to 30% leaving ileal with around 3% (2). However, a recent metanalysis performed by Kacprzyk *et al.* from 2020 found a slightly different distribution: a retrocecal location 32.1% followed by a pelvic, 28.5%, and ileal, 14.5%, position. Without known appendiceal pathologies the appendix is around 5.8 mm in diameter. The length of the appendix was found to be on average 8 cm long (3). In the pediatric population this can be further divided into age group. Except in very young, those below the age of 3 for whom the appendix was 3.7 mm in diameter and 4 cm long in average, the appendix measured around 6 – 7 mm in diameter and mean lengths up to 6.6 cm (4). As an intraperitoneal organ it has its own mesentery (lat. *mesenterium*), which is short and triangular, called the mesoappendix. Running within this mesentery is the appendicular artery (lat. *a. appendicularis*) which arises from the ileocecal artery (lat. *a. ileocaecalis*) a terminal branch of the superior mesenteric artery (lat. *a. mesenterica superior*) (Figure 1). Blood from the appendix is drained by the appendicular vein (lat. *v. appendicularis*) which is a tributary to the superior mesenteric vein (lat. *v. mesenterica superior*). Innervation to the appendix consist of sympathetic fibers from the lower thoracic sympathetic chain, parasympathetic

fibers derived from the vagal nerve (lat. *n. vagus*), and afferent fibers which end at the T10 segment. Lymphatic drainage flows into the ileocolic lymph nodes (lat. *nodi lymphoidei ileocolici*) found along the superior mesenteric artery (1).

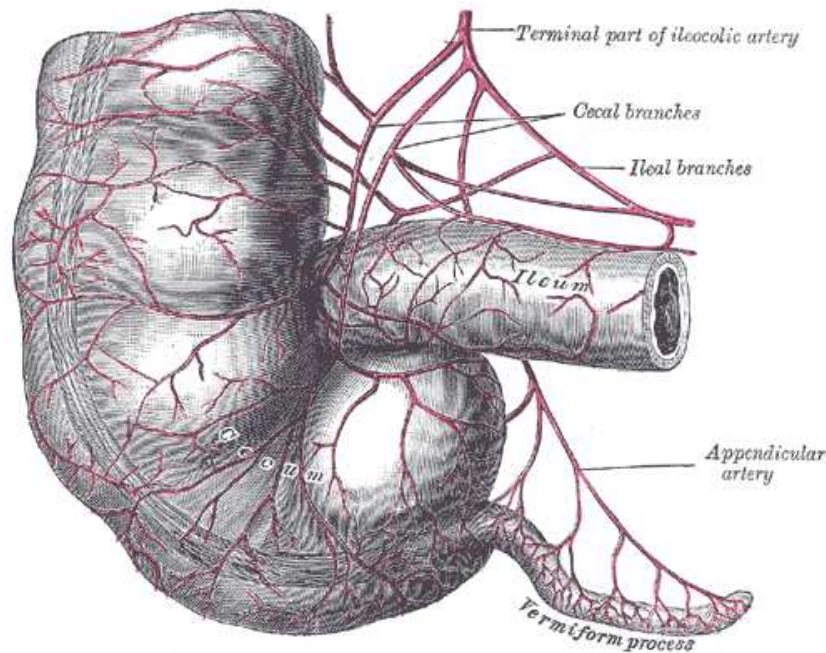


Figure 1. Anatomy of vermiform appendix

Source: <https://www.bartleby.com/107/Images/large/image1073.gif>

1.1.3. Histology

Histologically, most impressive, looking at the vermiform appendix is the dense abundance of lymph follicles (Figure 2). Due to this the appendix is considered a secondary lymphoid organ and as such is a part of the mucosa associated lymphoid tissue. Besides the tonsils the appendix comprises a significant collection of lymphoid tissue condensed in a small area (5). These aggregates generally increase in number from birth throughout childhood into adolescence before progressively decreasing again through adult life. The structure of the appendix mimics the one of the colons with some exceptions. An outer serosa (lat. *tunica serosa*) completely envelopes the appendix. The muscle layer (lat. *tunica muscularis*) does not consist of three longitudinal muscle bands (lat. *taenia coli*) typically found along the colon but instead of a closed circular and a longitudinal muscular layer. The mucosal lining (lat. *tunica mucosa*) is similar to the colon but shows only minimal absorptive

function. Appendiceal crypts are irregular in depth and structure. Lamina propria (lat. *lamina propria mucosae*) runs between individual crypts containing a high abundance of lymphoid nodules and a well-developed plexus composed of neuroendocrine cells, Schwann cells, unmyelinated never fibers, and neurons (6).

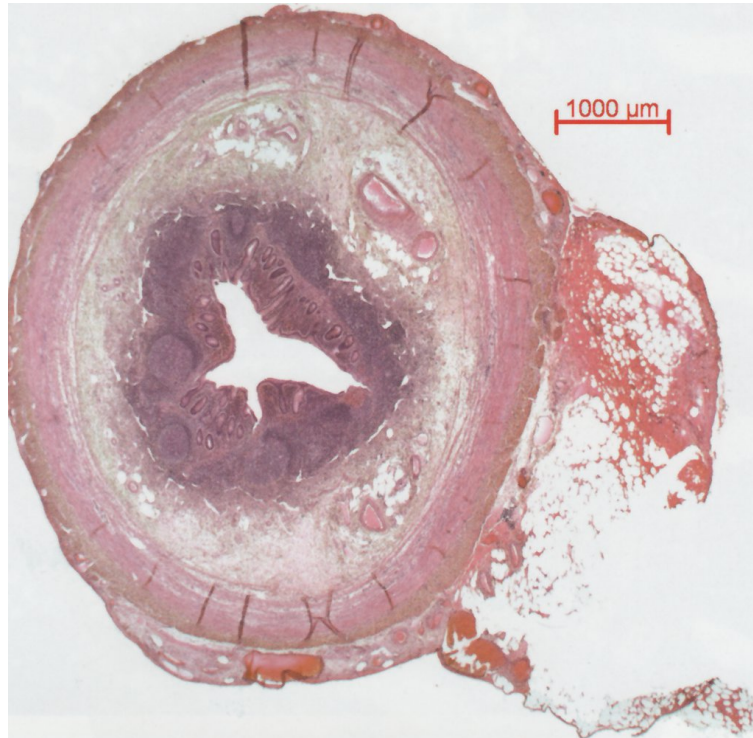

Figure 2. Vermiform appendix in cross section in histologic hematoxylin/eosin staining
Source: https://media-de.amboss.com/media/thumbs/big_57062185247a5.jpg

1.2. Acute appendicitis

Acute appendicitis (AA) (lat. *appendicitis acuta*) is an inflammatory process developing within the appendix and mostly arises from a combination of obstruction, decreased blood flow, ischemic mucosal and bacterial infection (7).

1.2.1. Historic review

First documentation of a successful appendectomy dates back to 1735. Von Claudius Amyand performed an operation on a 11-year-old due to a scrotal Hernia. The content

consisted of purulent greater omentum (lat. *omentum maius*) together with the appendix. This pathology is known as Amyand Hernia. The young patient survived the surgical procedure (8). In 1886 for the first time von Reginald Heber Fritz published indications for the surgical appendectomy procedure. In this publication he presented 257 cases of perforated appendicitis and advised for a lifesaving operation within 24h after first symptoms started. This would prevent the perforation and the development of a peritonitis (9). Only 3 years later in 1889 Charles McBurney published another sensational front in New York. In this publication he further characterized the symptomatology of the AA during clinical examination: a painful pressure point in the right lower quadrant (RLQ) of the abdomen which is now commonly known as McBurney point. Not long after this in 1894 McBurney presented an operative technique to perform an appendectomy. With this advance, McBurney and Fritz, formed the foundations for therapeutic principles which are still valid today that changed the diagnosis of AA from an often-deadly outcome to a well treatable disease with low mortality. Moreover, the surgical approach depicted in the same publication through the McBurney incision is still used today worldwide when open appendectomies are performed (10). It took 90 years for the next big breakthrough in surgical treatment strategies for AA. The German gynecologist Kurt Semm performed the first laparoscopic appendectomy which he published in 1983. Although his German colleagues criticized his approach, Semm's new operative technique was warmly welcomed in North America. He taught numerous American colleagues his approach and held presentations throughout the USA (11).

There is still an ongoing debate whether to use an open technique or a laparoscopic approach to perform an appendectomy, however, laparoscopic appendectomy shows to be superior in children especially regarding wound infection and length of hospital stay (12). Surgeons undergo a steep learning curve during their training for the laparoscopic approach which is necessary for success. In pediatric surgery it seems to be the safer technique (13). Within the laparoscopic approach a movement to achieve better cosmetic result using a suprapubic or single incision access is developing over the past years (14, 15).

1.2.2. Epidemiology of acute appendicitis

Acute appendicitis is one of the most common causes of abdominal pain in children and as such it belongs to the high-volume disease entities causing hospitalization. In fact, it is the most common surgical emergency in children (16). Compared to the adult form, in children

there is an increased risk for the presentation of a complicated appendicitis which will lead to a prolonged hospital stay. The peak of incidence is estimated between 15 and 19 years of age (17). The lifetime risk of an AA is estimated to be 8.6% in males and 6.7% in females with a lifetime probability of appendectomy of 12% for males and 23% for females (18, 19). Recently published studies have revealed that the incidence of AA varies considerably according to sex, race, socioeconomic and immigrant status of the general population (20, 21). While rural areas report a slightly smaller incidence data from newly industrialized countries suggests a rapid rise in the incidence of AA. The incidence of uncomplicated AA is progressively declining worldwide while the incidence of complicated AA seems more constant in numbers (22). In children if the diagnosis of AA is undetected and untreated it will lead to perforation in 35 – 47% of cases (23).

1.2.3. Etiology of acute appendicitis

The etiology of AA varies by age. While in the pediatric age group lymphoid hyperplasia is a common histopathologic finding for adults fecalith has been identified as the main reason causing AA (24). Small fragments of the feces are remaining in the appendix, they will be covered by calcium salts over time forming a hard sealing of the orifice (25). An appendicitis may also arise from wide variety of infectious causes. The role of gut bacteria is subject of discussion in development and sequelae of AA. Microbiological cultures normally reveal a mixture of anaerobes and aerobes, *Bacteroides species* and *Escherichia Coli* being the single most common isolated bacterial cause (16). Moreover, viral infections can trigger an AA, especially *Adenovirus* and *Cytomegalovirus* being the common representatives in this group. *Adenovirus* is usually described with ileocecal intussusception and produces lymphoid hyperplasia in the appendix. In a variable proportion of appendectomies *Enterobius Vermicularis* may be found. It is believed that the worms and their ova can block the appendiceal orifice similar to a fecalith (26). Appendiceal tumors are a rare cause of AA mostly because they do not arise around the orifice causing obstruction and leading to the pathophysiological process. Appendiceal carcinoid tumor is the most common type (27).

1.2.4. Pathophysiology of acute appendicitis

As described in the previous section an AA often starts with an obstruction of the orifice. Once the orifice of the appendix is blocked continuous secretion and collection of fluids and mucus from epithelial cells leads to increase in intraluminal pressure and distention of the

appendix. This provides an optimal environment for intestinal bacteria within the appendix to multiply and the edematous wall to precipitate to bacterial invasion (25). Intraluminal increase in pressure will exceed venous pressure and results in tissue hypoxia. This in turn leads to damage of the appendiceal wall. Because the appendiceal artery is a functional end artery thrombosis due to stasis or unmatched increased oxygen demand by the inflamed appendix produces ischemic changes leading to necrosis (28). The patients may present themselves at different stages of AA. More precisely speaking, AA encompasses a range of disease which is called uncomplicated in its earliest and complicated AA in later stage which is often characterized by perforation or abscess. During early uncomplicated AA an appendix may present macroscopically without inflammatory signs. In general, a complicated AA warrants a longer hospital observation and treatment (29), and further will not be a topic in this study and thesis. In 2015 Gomes *et al.* proposed an intraoperative scoring system grading the appendicitis into 5 groups. Table 1 outlines the comprehensive staging according to intraoperative findings (29).

Table 1. Intraoperative appendicitis grading

Uncomplicated acute appendicitis	
Grade 0	Macroscopically normal/histological endoappendicitis
Grade I	Inflamed Appendix (Hyperemia, Edema ± Fibrin)
Complicated acute appendicitis	
Grade II	Necrosis
	<ul style="list-style-type: none"> a) Segmental b) Involving the base
Grade III	Perforated - Inflammatory tumor
	<ul style="list-style-type: none"> a) With phlegmon b) With <5cm abscess c) With >5cm abscess
	Grade IV

1.2.5. Complications

Complications may include perforation - with or without fecal matter - within the peritoneal cavity, periappendicular abscess formation or peritonitis elicited secondary to the infection of the appendix (30). Young children have the greatest risk of presenting with a complicated appendicitis (31). A diffuse peritonitis is more common in the younger children due to a less developed greater omentum. In adolescence a well-developed greater omentum walls off the inflammation and forms an appendiceal mass (25). The incidence of macroscopic appendiceal perforation is estimated to be between 20-30% (32). In 2015 Atema *et al.* developed a scoring system to distinguish preoperatively uncomplicated from complicated appendicitis using clinical and imaging features as well as laboratory values with great success (33). Several studies carried out during the severe acute respiratory syndrome coronavirus type 2 (SARS-CoV-2) pandemic showed increased rates of children presenting with complicated appendicitis (34, 35).

1.3. Diagnostics

Besides the clinical examination the diagnosis of AA encompasses laboratory workup and imaging. Final pretherapeutic Diagnosis of AA shows to be most accurate by combining findings of different diagnostic techniques and the use of scoring systems (36). Although there are significant advancements in diagnostic algorithm, diagnosing AA in young children can still be challenging for younger doctors (37).

1.3.1. Anamnesis

Depending on the time of presentation during the course of the disease the patient may present at the emergency room commonly describing a pain that is radiating throughout the abdomen or periumbilical in the beginning and over time migrates to the RLQ. In general, pain precedes vomiting and nausea. Moreover, the patient might complain about increased body temperature, changes in stool or anorexia (38). These classic symptoms have been studied but show relative weak predictive value especially in the pediatric population. Becker *et al.* found that classic symptoms like migrating pain or rebound tenderness were often absent in children with proven appendicitis (37). Besides the course of symptoms, questions regarding previous operations or similar episodes of pain are important to ask. Moreover, in

female patients especially if they already reached childbearing age, gynecological reasons, such as periodic pain or pregnancy, must be excluded (39).

1.3.2. Physical examination

During physical examination there is a variety of typical signs that can be elicited. Pain over the *McBurney point* which is localized at the lateral third on a line between right anterior superior iliac spine and the umbilicus (10). The *Lanz point* which is found between lateral and middle third on a line between both anterior superior iliac spines (40). If pain is elicited in the RLQ upon removing pressure on the contralateral side this is called rebound tenderness or Blumberg sign (41). In a recent study Benabbas *et al.* found the *psoas sign*, the *obturator sign*, the *Rovsing sign* and absence of bowel movements to have the highest positive likelihood ratio for children in diagnosing AA. The *psoas sign* is positive if pain in the RLQ can be elicited by telling the patient to lift the right leg against resistance. By internal or external rotation of the flexed hip the *obturator sign* is positive if pain in the RLQ is elicited. If the patient feels pain during deep palpation of left lower quadrant on the RLQ side the *Rovsing sign* is said to be positive (42). Table 2 outlines an extended list of appendicitis signs during physical examination (7).

Table 2. Clinical signs for acute appendicitis

	Sign	Explanation
1	Blumberg I	Pain on palpation of McBurney point
2	Blumberg II	Pain on releasing pressure from McBurney
3	Psoas	Lifting the right leg against resistance elicits pain in RLQ
4	Obturator	Internal or external rotation in the flexed right hip elicits pain
5	Rovsing	Pain in RLQ during deep palpation of left lower quadrant
6	Grassman	Pain by percussion or jumping
7	Dunphy	Coughing increases pain
8	Lenz	Axillorectal Temperature difference > 0.5°C
9	Horn	Increased pain when pulling testicles down
10	Hedri	Percussion-induced pain at a slight distance from the expected localization of the worm
11	Krüger	Increased pain when the examiner keeps the arm pressed in the ileocecal area while the patient raises the right leg outstretched at the knee
12	Permann	Pressure on the left side and a sudden release of the same lower abdomen intensifies the pain on the right

RLQ – right lower quadrant, C – Celsius

1.3.3. Laboratory workup

The increase white blood count (WBC) and typical inflammatory markers belong to the standard laboratory findings in diagnosing AA. These markers lack individual accuracy but when used together with results from medical history and radiological workup can help in clinical decision making. This is especially true for the combination of ultrasound (US) and laboratory markers. Anandalwar *et al.* showed a possible reduction in CT scans and hospitalizations when using US and Laboratory results together (43). Andersson found a

positive likelihood ratio for WBC $10 \times 10^9/L$ of 2.5, increasing to 3.0 if there are over $14 \times 10^9/L$. In the same study C-Reactive Protein (CRP) values over 20 mg/L had a positive likelihood ratio of 2.4 (36). Urine status and sediment is important to exclude cystitis or urolithiasis. In case of a retrocaecal appendicitis a concomitant inflammatory reaction of the right ureter with erythro- and leukocyturia is possible (38).

1.3.4. Radiological workup

Ultrasonography (US), computed tomography (CT), and magnetic resonance imaging (MRI) are options for further evaluation of patients with suspected AA. When selecting an imaging modality, physicians should consider the availability of experienced sonographers, potential radiation exposure, cost, length of stay in the emergency department, and diagnostic accuracy (44).

1.3.4.1. Ultrasonography

Sonography is a well-established component for diagnosing AA. Especially in the hands of a trained radiologist or surgeon US can provide information for surgical indications. Additionally with this technique other abdominal pathologies can be excluded (45). Positive US finding for appendicitis include a fluid filled, noncompressible appendix, a maximal outer diameter exceeding 6 mm, a maximal mural thickness above 3 mm, a visible appendicolith, periappendicular or pericecal fluid and increased periappendiceal echogenicity which is a sign of inflammation (46, 47). Evaluations of sensitivity and specificity using US as a diagnostic tool for AA come to different conclusions. A metaanalysis based on 7448 patients resulted sensitivity and specificity of US were 88% and 94%, respectively (48). More recently in 2016, Glass and Rangel found a wider range of sensitivity, 44 – 88%, and specificity, 90 – 97%, when examining the results of multiple pooled studies (49). Two studies obtained increased sensitivity and specificity results regarding the use of US by changing the parameters of thickness of the appendix to > 7 mm, using skilled pediatric ultrasonographers, an increase duration of abdominal pain to > 48 h and by increasingly utilizing US (50, 51). The use of standardized categories for reporting results improved the reliability in reporting as well as interpreting results. This can further enhance US-investigations during diagnostic algorithm. Diagnostic protocols which include US decrease the use of CT scans in children and result in overall cost savings (52).

1.3.4.2. Computed tomography

Computed tomography imaging provides a 3D picture of the entire abdomen and pelvis. This imaging technique is not operator dependent and has the added benefit of being generally accurate. CT scan findings underlining the diagnosis of AA include an enlarged appendix (>6 mm), appendiceal wall thickening (>1 mm), periappendiceal fat stranding, and appendiceal wall enhancement (53). In 2018 Hwang found in a systematic literature review a sensitivity of 95% and a specificity of 94% when using CT scans for diagnosing AA (54). While widely used in adults, in children the exposure to ionizing radiation is of greater concern which makes a strong argument for the use of US as a first-choice imaging device in diagnosing AA (55). Moreover, children presenting to a general adult hospital are more likely to undergo a CT scan with lower rate of concordance between imaging and pathology in comparison to US use in hospitals with pediatric care departments (56).

1.3.4.3. Magnetic resonance imaging

Magnetic resonance imaging is an extremely accurate diagnostic tool for AA. Unlike a CT scan it does not expose the pediatric patient to ionizing radiation. Results of a recent Cochrane study showed sensitivity and specificity of 96% (57). Suggestive findings for AA using MRI scans are a dilated appendix with intraluminal fluid or air-fluid level, periappendiceal and pelvic free fluid, and a hypointensity in the proximal part of the appendix which is mostly consistent with an appendicolith (58). The main disadvantages are high cost, the lack of availability, the duration of the scan with the potential need for sedation (59). Covelli *et al.* used a MRI protocol that reduced the acquisition time to 11 minutes. Furthermore, they reported no need for sedation of the young patients during the scans (58). Cobben *et al.* showed in their study that the use of MRI to exclude an AA and therefore prevent a negative appendectomy could lead to a net saving for the institution (60).

1.3.5. Scoring system for acute appendicitis

Appendicitis risk scores are a good clinical tool to evaluate the probability of an individual patient to have appendicitis. The underlying assumption is that the combined predictive value is greater than the value of each finding individually (49). In 1986 Alvarado showed in his study that a scoring system he developed based on symptoms, signs, and laboratory findings helps in decision making during everyday clinical practice. This score is now known as Alvarado Score (61). In 2002 Samuel designed a score focusing on children

between the age of 4 – 15 years, the Pediatric appendicitis score (PAS), which includes similar values to the Alvarado score (62). The last score to mention is the Appendicitis Inflammatory Response Score (AIR). Unlike the previous ones this score calculates variables based on a weighted ordered logistic regression analysis (63). De Castro *et al.* found that an advantage compared to the Alvarado score might be observed during the evaluation of very young children because the AIR score does not require children to identify nausea, anorexia, and the typical migration of pain (64). The different scoring systems are compared and comprised in Table 3. Although initially these scoring systems showed good results regarding specificity, sensitivity, NPV and PPV over 90%, later large validation studies conducted between 2007 and 2015 reported different results. They reproduced sensitivities and specificities in the range from 70 – 90% (65-67). In conclusion these scoring systems are not solely reliable enough for clinical decision making but helpful in setting up further diagnostic evaluation because they can put patients into categories of different risk probability groups according to the final total score (66). None can be used as an exclusive standard in setting the diagnosis of AA in children because they lack adequate predictive values (67). Glass *et al.* concluded that the implementation of a structured diagnostic protocol using risk scores to group patients and laboratory as well as imaging studies is key to streamline diagnostic process, safe cost, and lower radiation exposure (49).

Table 3. Comparing clinical scores for acute appendicitis

Parameters	Alvarado Score	PAS	AIR
Vomiting/Nausea	1	1	1*
Anorexia	1	1	
Pain in RLQ	2	2	1
Migration of pain to RLQ	1	1	
Rebound pain/tenderness	1	2†	
Light			1
Medium			2
Strong			3
Temperature			
>37.5°C	1	1	
>38.5°C			1
Leukocytosis			
>10 x 10 ⁹ /L	2	2	
10-14.9 x 10 ⁹ /L			1
≥15 x 10 ⁹ /L			2
Left shift of WBC	1	1	
70-84%			1
≥ 85%			2
CRP			
10-49 g/L			1
≥ 50 g/L			2

* Vomiting only; † Including pain from coughing/Hopping/percussion

PAS - Pediatric appendicitis score; AIR - Appendicitis Inflammatory Response Score; RLQ – Right lower quadrant; WBC – White blood count; CRP – C-reactive protein, C – Celsius

1.3.6. Differential diagnosis

During the workup towards a diagnosis of AA there are several other underlying causes arising from the RLQ which are at least partly overlapping in symptomatic presentation. These can arise from other pathologies within the gastrointestinal tract. The two most common missed diagnoses in the pediatric population are viral gastroenteritis and mesenteric lymphadenitis (68). Another major group of differential diagnoses develop from the genitourinary tract (69). Among a single patient group young women possess the lowest accuracy in diagnosing AA. Gynecological conditions in young female children can cause lower abdominal pain (38). Table 4 outlines differential diagnoses of AA which should be considered during the clinical workup of each patient (69).

Table 4. Differential diagnosis for acute appendicitis

Gastrointestinal	
	Mesenteric adenitis
	Viral gastroenteritis
	Regional bacterial enteritis
	Meckel diverticulitis
	Cecal diverticulitis
	Crohn disease
	Cholecystitis
	Pancreatitis
Genitourinary	
	Urinary tract infection
	Hydronephrosis
	Testicular torsion
	Ureteral calculi
	Ruptured ovarian cyst
	Ovarian torsion
	Salpingitis
	Wilms tumor
Other	
	Pneumonia
	Omental torsion
	Henoch-Schoenlein purpura
	Kawasaki disease
	Lymphoma

1.4. Treatment options

Debate about the treatment is often linked to the stage of appendicitis. Since this study investigates on noncomplicated AA the following chapters focus on surgical and nonsurgical treatment options.

1.4.1. Nonoperative management

Nonoperative Management (NOM) consists of a broad-spectrum antibiotic therapy over a course of 10 days along with a short hospital stay. In adults, success rates have been reported that reached 88% with a recurrence of symptoms within 1 year of 15% (70). Over the past few years this treatment strategy gained in interest as it can avoid unnecessary operations especially regarding negative appendectomies (71). Several negative indicators for NOM have been defined. These include radiographic signs of complicated appendicitis, an appendicolith, abdominal pain >48 hours, WBC >18 x 10⁹/L, CRP >40 mg/dL. Comparing nonoperative and operative treatment strategies the literature concluded that a nonsurgical treatment can in fact lead to fewer days of disability and lower health care cost (72). Minneci *et al.* reported an initial success rate using nonoperative management of 67.1% and fewer disability days within one year compared to urgent laparoscopic appendectomy (73). Podda *et al.* concluded in a recent study nonoperative management to be a feasible treatment option in noncomplicated AA but they also reported that more than 20% of patients need a second hospitalization due to recurrent appendicitis (74). Patkova *et al.* found readmission rates of 46% after initial nonoperative management by extending the follow up period to five years (75). At the Department of Pediatric surgery as well as Department of Surgery, of the University Hospital of Split, the accepted approach for all suspected or proven AAs is operative management. Up to date this is also correct for all other hospitals in Croatia treating AA.

1.4.2. Surgical treatment

Nowadays surgical treatment for uncomplicated AA comprises laparoscopic or small incision open appendectomy. In both strategies intravenous fluids and preoperative antibiotic are administered preoperatively (69).

1.4.2.1. Open appendectomy

With this technique the surgeon cuts transversely or obliquely through the McBurney point in the RLQ. The muscles of the abdominal wall are usually split and after mobilizing the appendix, it is brought out through the incision. The stump is managed using a purse string or Z-stitch suture or simple ligation. For uncomplicated appendicitis no drains are necessary, and the patient may be discharged after a short hospital stay (38).

1.4.2.2. Laparoscopic appendectomy

This technique is commonly performed using 3 ports or as single incision laparoscopic surgery (76). Usually, the operation starts with positioning of the 5 or 10 mm optical trocar sub- or supraumbilical. Depending on weight and height of the patient a pneumoperitoneum of 6-12 mmHg is established and under visual control two working trocars, a bigger 10 - 12 mm and a 5 mm, are installed in the left lower quadrant and right mid part of the abdomen. Next follows an exploration of small and large intestine as well as pelvic organs. The mesoappendix is cut towards the origin of the appendix. Bleeding from the appendiceal artery is halted using harmonic scalpel, electrocautery or clips. To supply the appendiceal base several techniques have been described. Those include the use of a polymeric clip, a ligation or suture, or suturless using a harmonic scalpel. Now it can be safely cut off and extracted through bigger 10 - 12 mm port (77, 78). Single port or suprapubic approach have been described to better cosmetic outcome (15, 14). Current evidence shows that for children with uncomplicated non perforated appendicitis additional doses of antibiotics are not necessary and a preoperative prophylactic therapy is sufficient (79). A patient who underwent laparoscopic appendectomy for uncomplicated AA may be discharged after 1-2 days (80, 81). As previously mentioned, the laparoscopic technique is nowadays the treatment option favored by pediatric surgeons (14). Jaschinski *et al.* found in their systematic review a longer operative time, lower postoperative pain scores, a shorter hospital stay, comparable costs, and a decrease in postoperative wound infection comparing laparoscopic to open appendectomy (82).

1.5. Fast track surgeries

During the late 20th century implementing the laparoscopic technique into the operating room to treat AA heralded a new era of approaching the disease (11). Since then, hospitalization after laparoscopic appendectomies shortened to only 2 days (80, 81). Over the

past years a variety of surgeries including laparoscopic interventions have been performed in an outpatient manner which could be translated to laparoscopic appendectomies (83). Against this background and due to good experience with fast-track surgery protocols the idea of same day discharge (SDD) after laparoscopic appendectomy for AA in children was born (83, 84). In this study SDD or one day discharge is defined as release from hospital within 24 hours after laparoscopic surgery.

1.5.1. One day discharge after appendectomy

One day discharge protocols for laparoscopic appendectomy have been evaluated since the start of the 2010s yet the exact definition may differ. Implementation of such protocols will affect all levels of hospital care and demands a well communicated pathway from admission to release of the patient. Once applied SDD may minimize inpatient resources for a high-volume disease entity, decrease nosocomial infections and show positive outcome for patient and family satisfaction (84). Cash *et al.* reported in their retrospective study in 2012 already the safety of outpatient laparoscopic appendectomy for selected patients (85). During the same year Alkhoury *et al.* showed similar results in a what they said was the first prospective study in this field (84). Cheng *et al.* concluded in their retrospective study comparing same day discharge to the usual postoperative hospitalization that there is no significant difference in complication rates, postoperative revisits at ER or readmission rates (86). De Wijkerslooth *et al.* published a meta-analysis in 2021 which suggests the safety, cost reduction, parental satisfaction and encourages implementation of a fast-track treatment protocol for selected patients (87).

1.5.2. Effects of hospitalization in pediatric population

Stress, in children, due to hospitalization has been thoroughly investigated. Postoperative behavioral changes including separation anxiety, tantrums, fear of strangers, eating problems, nightmares, night terrors and enuresis were observed. These changes may last as long as a full year. Young age, prior negative experience with hospitals or medical care, hospitalization, postoperative pain, parental anxiety, and certain personality traits of the child make up major risk factors for postoperative behavior problems (88). Shortening of visiting hours and a stricter policy for visitors to hospitals around the world due to the SARS-CoV-2 pandemic may further enhance these effects.

1.5.3. Parent education and home management

Parental anxiety has an effect on distress levels of the hospitalized child, which may continue into the post hospitalization period, and on occasion may even increase postoperative recovery time (89). It has been described that parent as well as their children report not feeling educationally and emotionally well prepared for an outpatient surgical setting (90). The parental counselling should be performed thorough as this is a newer approach and parents may be misled by other health care professionals about the safety of this protocol (84). Standardizing instructions via trained staff members improve parent understanding (91). Child life specialists may play a key role here preparing families for the surgical experience. This way parents may be reassured about the treatment strategy, and they will be equipped with knowledge to support their child through the surgical and recovery process (92). For same day discharge laparoscopic appendectomy Aguyao *et al.* described 3 phases of consulting with the parents. First time upon the moment a diagnosis of AA is on hand, the second time in the preoperative holding area and the last time immediately postoperatively by the attending surgeon (93). For home management pain control using acetaminophen alternating with scheduled ibuprofen was successfully shown in two studies investigating on parental satisfaction (94, 95). Ngo *et al.* additionally pointed out the need to educate the parents about possible postoperative constipation of the child and how to prevent it (95).

2. OBJECTIVES OF RESEARCH

Laparoscopic appendectomy is one of the most common emergency interventions in pediatric surgery. Over the last decade a protocol for one day discharge after laparoscopic appendectomy was established. The aim of this study was to determine the safety, which is evaluated using rates of complication, readmissions and return into operating room. Additionally, parental satisfaction was investigated for discharge to home within 24 hours after laparoscopic appendectomy for uncomplicated AA.

Hypotheses:

- 1) One day discharge after laparoscopic appendectomy for uncomplicated AA is safe and reproducible.
- 2) Parental satisfaction for one day discharge after laparoscopic appendectomy for uncomplicated AA is high.
- 3) The cost of one day discharge after laparoscopic appendectomy for uncomplicated AA is notably and significantly less.

3. PATIENTS AND METHODS

3.1. Patients

This study was conducted from March 2021 to May 2022 at the Department of Pediatric surgery, University Hospital of Split in Croatia.

Inclusion Criteria: Patients of both genders, between 6 to 17 years of age, who underwent laparoscopic appendectomy and were discharged within 24 hours after surgery.

Exclusion Criteria: Patients younger than 6 and older than 17 years of age, operated due to complicated AA; patients with prolonged hospital stay, more than 24 hours after surgical treatment for any reason – surgeon choice, intraoperative complications, additional pathology; patients undergoing conventional open operating technique for AA.

3.2. Type of study

Single-center prospective non-randomized cohort study.

3.3. Place of study

All patients included were operated by three surgeons at the Department of Pediatric surgery, University Hospital of Split in Croatia.

3.4. Methods of data collection and processing

The data was collected from the study protocol (Supplement 1) which is completed from the medical history data and operative list. Additionally, a two-page questionnaire (Supplement 2) is handed out to the parents which they fill out immediately after discharge, every postoperative day until the first outpatient control appointment and directly before the appointment. The corresponding data was obtained by revising the study protocols and medical records. The data were analyzed using the Microsoft Excel for Windows Version 11.0 (Microsoft Corporation) and SPSS 24.0 (IBM Corp, Armonk, NY) software programs.

3.5. Description of research

Patients presenting with the clinical picture of AA to the surgical emergency admission of the University Hospital of Split went through the diagnostical algorithm and were evaluated using the AIR score. Intraoperative decision of inclusion was made by the surgeon and parents were informed about possibility of participation in this study postoperatively.

Before discharge the parents were counselled about pain management and home child care. The two-page questionnaire was handed to the parents with instruction of use. The questionnaire was designed to investigate on possible changes in behavior and the pain level of the child by using visual analogue scale (VAS) measuring from 0 to 10. With this questionnaire, homebased pain management was recorded. Parents returned to the outpatient check-up on 7th postoperative day and handed in the filled-out questionnaires. Complication was defined as any postsurgical condition requiring emergency visit, readmission, or return to operating room. Patients were evaluated for surgical related complications using the Clavien-Dindo classification (96).

3.6. Primary outcome measure

Primary outcome measures were the safety of laparoscopic appendectomy due to uncomplicated AA and discharge within 24 hours and parental satisfaction.

3.7. Secondary outcome measure

Secondary outcome measures included the rate of readmission and return to operating room, the complication rate and cost reduction.

3.8. Compliance with ethical standards

All procedures performed in studies involving human participants were in accordance with ethical standards of the institution and/or national research committee and with the 1964 Helsinki declaration and its later amendments or comparable ethical standards. Authors declared that the research was conducted according to the principles of the World Medical Association Declaration of Helsinki “Ethical Principles for Medical Research Involving Human Subjects”. Patients were informed in detail and informed consent was obtained from the parents or legal guardians of the patients to use the data. The study protocol was approved by the Ethics Review Board of University Hospital of Split with reference Number 2181-147/01/06/M.S.-21-02 (Supplement 3).

3.9. Surgery

The standard of procedure at the Department of Pediatric surgery, University Hospital of Split comprises a laparoscopic 3-port approach. Depending on the age and weight of the

young patient a pneumoperitoneum using CO₂ of 6-12 mmHg is established. A 5 mm trocar is placed supraumbilical through which the laparoscope (Olympus, Tokyo, Japan) will be inserted, and a first inspection of the abdominal cavity is performed. Another 5 mm trocar is placed under the right costal arch and a third working 10 mm trocar is placed either in the left lower quadrant or suprapubically. Preparation of the appendix is performed using a longitudinal (Ultracision™, Ethicon Endo-surgery, Cincinnati, OH, USA) or torsional harmonic scalpel (Lotus™, BOWA-electronic GmbH, Gomaringen, Germany). Appendiceal base was secured using a polymeric clip (Ligating Clips XL, Grena, Brentford, UK) or repeated applications of harmonic scalpel in stepwise manner (78). With this technique the appendiceal base is sealed by repeatedly using the harmonic scalpel to obliterate the lumen of the appendix. The specimen is then retrieved through the 10 mm trocar. The abdominal cavity is rinsed with normal warm saline solution and the stump is checked for leakage before retracting all trocars and closing the skin by nylon interrupted closing suture.

4. RESULTS

4.1. Demographic and clinical data

A total of 180 patients were included, 65 were female (46.2%) and 115 were male (63.8%). Median age was 11 years of age (IQR 10, 14). Median value for Body Mass Index (BMI) was 18.2 (IQR 15.5, 20.6). Median for symptoms duration prior to presentation at the surgical emergency room was 24 hours (IQR 18, 32.5). AIR score median was 8 (IQR 7, 9). Abdominal US was performed in 119 patients (66.1%). 90 patients (75.6%) had positive findings on US examination. In 29 cases (24.4%) there were false negative ultrasound findings. The demographic data is summarized in Table 5.

Table 5. Demographic and clinical data of the patients

Demographic data	Value
Age (years); median (IQR)	11 (10, 14)
Gender; n (%)	
Male	115 (63.8)
Female	65 (46.2)
BMI (kg/m ²) (IQR)	18.2 (15.5, 20.6)
Symptom duration (h); median (IQR)	24 (18, 32.5)
AIR score; median (IQR)	8 (IQR 7, 9)
US total; n (%)	119 (100)
US positive; n (%)	90 (75.6)
US negative; n (%)	29 (24.4)

IQR - Interquartile range; BMI – Body mass index; AIR – Appendicitis inflammatory risk; US – Ultrasound

4.2. Outcomes of treatment

Intraoperative finding was positive for AA in majority of the cases (n=164, 91.1%). Most of the operated patients had a phlegmonous appendicitis (n=126, 70%), followed by gangrenous type (n= 50, 27.8%). There were four cases with initially inflamed-catarrhal appendices (2.2%). Gupta technique was mostly used for supplying the appendiceal base (n=155, 86.1%) while for the rest a polymeric clip was used (n= 25, 13.9%). Median of operative time was 20 min (IQR 16, 25). Median length for postoperative stay (LOS) was 15 hours (IQR 12, 19). Treatment outcome data is summarized in Table 6.

Table 6. Treatment outcomes

Outcome	Value
Duration of surgery (min); median (IQR)	20 (16, 25)
Length of stay (h); median (IQR)	15 (12, 19)
Appendiceal base closure; n (%)	
Harmonic scalpel	155 (86.1)
Polymeric clip	25 (13.9)
Complications; n (%)	
Intraoperative	0
Postoperative	4 (2.2)
Readmissions; n (%)	4 (2.2)

IQR – interquartile range

4.3. Complications

There were no immediate intraoperative complications registered. Four patients (2.2 %) had an unplanned readmission prior the 7th postoperative day. All four were graded II on Clavien-Dindo classification and were treated conservatively with antibiotics due to minimal formation of abscess (Table 7). None of the patients had an unplanned return to operating room. No other emergency visits were registered.

Table 7. The Clavien-Dindo classification for postoperative complications

Grade	n (%) (n=4)	Total (n=180)
I	0	0
II	4 (100)	4 (2.2)
III a	0	0
III b	0	0
IV a	0	0
IV b	0	0
V	0	0

4.4. Parental satisfaction

A total of 155 parents (86.1%) graded the highest satisfaction score at the time of discharge and only 25 parents (13.8%) reported mediocre satisfaction (Table 8). Out of the 25 parents with mediocre score on the day of outpatient appointment 20 parents (80%) changed to the highest satisfaction and only 5 parents (20%) kept the mediocre score.

Table 8. Parental satisfaction evaluation

Parental satisfaction	n (%)
Time of discharge	
Highest	155 (86.1)
Mediocre	25 (13.8)
Bad	0
Outpatient appointment	
Highest	175 (97.2)
Mediocre	5 (2.8)
Bad	0

Medians of pain level by VAS for all postoperative days were low: 4 (IQR 4, 6), 2 (IQR 2, 5), 2 (IQR 0, 4), 1 (IQR 0, 2), 0 (IQR 0, 2), and 0 (IQR 0, 0) for 1st, 2nd, 3rd, 4th, 5th, and 6th-7th postoperative day, respectively (Figure 3). Paracetamol was mainly used by the parents on the first postoperative day. No additional pain management was necessary the following days until the outpatient appointment.

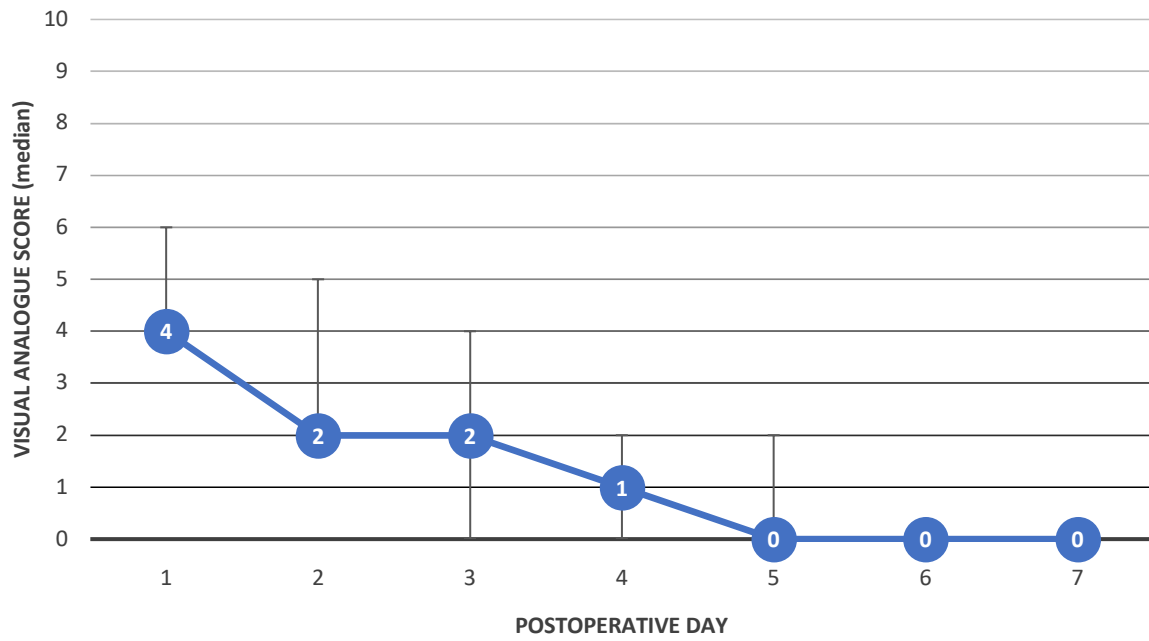


Figure 3. Postoperative pain assessment
Data are presented as median \pm interquartile range.

5. DISCUSSION

Acute appendicitis is one of the leading causes of emergency surgery in the pediatric population (16). While there is still an ongoing debate about the gold standard therapeutic approach the outcomes of the laparoscopic operative treatment have been shown to have superior results. Children recover and are discharged after a short hospital stay (97). Hospitalization is coupled with the separation from the parents which may add additional stress not only to the child but the whole family (89, 92). During the SARS-CoV-2 pandemic hospital visits were even more limited which leads to possible unnecessary separation of children and their parents at a young age. Already before the SARS-CoV-2 pandemic treatment protocols for laparoscopic appendectomies for uncomplicated AA and same day discharge were implemented showing promising results regarding safety and cost efficiency (94). The primary aim of this study was to investigate the safety for a treatment protocol constituting a discharge within 24 hours after laparoscopic appendectomy for uncomplicated AA and evaluate its parental satisfaction.

Sample size and median age of patients are comparable to existing prospective literature (84, 94, 98). Of foremost importance when implementing a new treatment protocol is to rule out any possible new adverse effects for the patient compared to the established standard of procedure. In this study only four patients, or 2.2%, had an unplanned readmission to the hospital within the first seven postoperative days. All four patients in our study were treated for minimal formation of periappendicular abscess with antibiotics. These children were between 6 and 9 years of age and after further evaluation with the parents a possible explanation may be that the children did not follow the instructions given by the surgeon for postoperative care but instead immediately returned to a very active daily routine with running and playing including blunt and soft traumas to the abdomen. Previous evaluation over a three-year period for the quality of surgery of the Department of Pediatric surgery at our institution found unplanned returns to the operating room of 0.47% and readmission rates below 1%. These results include elective surgeries and the authors found rates for unplanned return to operating room for emergency operations to be 4.5 times higher as well as readmissions for emergency cases to be 3.2 times higher. Most common reason was appendectomy (99, 100). This result is consistent with previous studies showing readmission rates of up to 2.5% for discharged patient groups (84, 85, 93). Cairo *et al.* reported in a large retrospective cohort study readmission for one-day discharge treatment protocols to be up to 1.89%. They also found that there was no difference in reason for readmission compared to the conventional hospitalization group (101). Most recently in 2022, Lo *et al.* indicated no

difference in readmission or emergency visits in a 30 postoperative period after implementing an early discharge protocol for appendectomy in children (102). Compared to the literature, the results of this study show safety in implementing a one-day discharge protocol.

To the author's knowledge there have been only a few investigations about parental satisfaction and discharge within 24 hours after laparoscopic appendectomy for uncomplicated AA up to now. The outcomes of this study go along with previous findings showing high satisfaction after conducting good parental consultation for home management after hospital discharge within 24 hours of surgery. Evaluation of the two-page questionnaire revealed that a greater majority of parents expressed highest satisfaction for this treatment protocol already at time of discharge. Only a minority reported a mediocre satisfaction. At time of outpatient appointment highest parental satisfaction increased to 97.2%. In the literature to this point data collection was performed using questionnaires or a follow-up telephone call (84, 94, 95, 98). Critical part of success for this type of treatment protocol depends on good parental education and reassurance (84, 85, 95, 98). Ngo *et al.* reported that 81.6% of the parents were satisfied with the early discharge and only 7% of parents would not choose for an early discharge again (95). Alkhoury *et al.* reported 87% of parents being satisfied postoperatively with the expeditious discharge. They observed a further increase up to 92% of parents when asked again in retrospect (84). Yu *et al.* reported high parental satisfaction of 88% (98). Gee *et al.* reported in their study a slight increase in call consultations regarding pain control in the discharge group compared to their comparison group (94). This study shows median of postoperative pain using VAS were as high as 4 out of 10 at the first day and quickly declined to 0 at the fifth postoperative day with minimal necessity of pain medication.

Hospitalization has been related to several negative psychological outcomes for children which include separation anxiety, tantrums, fear of strangers, eating problems, nightmares, and enuresis. Shortening of LOS may prevent children to experience these negative effects (88). The median LOS in this study was 15 hours. In the setting for this study children were admitted to the pediatric ward after they had recovered at the postsurgical anesthetic care unit. Discharge was permitted when the child was drinking clear fluids and eating the first postoperative meal, without vomiting or nausea, and was able to walk to bathroom with normal urination. Comparable studies showed a mean LOS after surgery of 5-8.8 hours (84-86, 93). LOS of this study was found to be twice as long than previously reported in the

literature. The longer LOS may be attributed to the fact that some studies reported release from the ambulatory setting without ever admitting the patient to pediatric surgical ward (84). Moreover, patients in our study who had their appendectomy performed within earlier hours of the day show comparable postoperative LOS while it was unlikely for patients presenting during evening hours to be released at the same day. This was previously described in the literature (93). Nighttime discharges from hospitals are not feasible at this moment and in Department where the study was conducted.

Acute appendicitis is a high-volume entity and as such effective resource allocation is warranted. Shortening hospital stay can reduce costs for care providers. The exact cost for this institution is not possible to calculate, but the Croatian Health Insurance Fund pays a sum of 73,05 Euros (€) to the Hospital for a trim day after appendectomy. Khan *et al.* published in 2013 a cost comparison study in which they meticulously listed costs for the surgical intervention and hospital stay. This was found to be comparable to our institution giving an average cost for laparoscopic appendectomy of 1183,27 € (479 Omani Rial) and cost for hospital stay per day of 29,64 € (12 Omani Rial) (103). In accordance with hospital policy and policy of the Department of Pediatric surgery and a median LOS of 3 days (104), cost reduction per patient is estimated to be at least 146,10 € when using a one-day discharge protocol. When taking this into a one-year model for the Department of Pediatric surgery with an estimated 160 laparoscopic appendectomies for uncomPLICATE AA a total reduction of approximately 23.372,62 € may be achieved. Yu *et al.* enrolled 185 patients into their discharge protocol and reported reduction in cost for their facility of 351\$ per case and an estimated total cost reduction during the one-year period of the study of 64.584\$ (98). Gee *et al.* found in their one-year study of 2016 significantly lower median cost of stay for the 382 patients discharged home of 5.677\$ per patient which can be calculated to a yearly median cost saving of more than 2 million \$ (94). Cheng *et al.* found in their study conducted over 28 months overall higher hospital charges for the 75 patients of the non-discharge group of up to 4000\$ per patient (86). In Croatia, laparoscopic appendectomy is still mandatorily related with hospitalization of more than 24 hours. Results of this study, both in medical safety and economical benefit, may be a cornerstone in reorganizing standard of procedure for uncomplicated AA treated by laparoscopic appendectomy.

This study shows success implementing a same day discharge protocol but shows several limitations. Results of a single institution-based investigation usually are limited for

general applicability. More clinical research and a multicenter type of study protocol are needed to better interpret the correlation of outcomes in larger cohorts. Nevertheless, the results may represent the general population as the findings build on existing evidence that a one-day discharge protocol after laparoscopic appendectomy is safe in daily clinical practice. Moreover, the sample size shows sufficient patients to be general applicable. Although the findings reflect results of other studies the lack of a comparison group harbors the risk of making erroneous conclusions about the outcomes of this study. Additionally, a seven-day postoperative follow-up period may be too short to establish the total amount of surgical related complications although all immediate and early complications should be shown within the first six days of surgery. Lastly, the decision to use the 24-hour treatment protocol implemented with this study was made by one of three surgeons intraoperatively. This bares the risk of increasing selection bias. Other surgeons of the department were skeptical about safety of this treatment protocol and decided not to be included for now. Nonetheless, inclusion was clearly defined with standardized intraoperative appendicitis grading and there was no drop out observed in the patient group during follow up which strengthens the consistency of the results of this study.

6. CONCLUSION

This prospective cohort study showed that discharge within 24 hours after laparoscopic appendectomy for uncomplicated AA in children is safe and feasible. Parental satisfaction is high with this treatment protocol. By early discharge hospitalization rates and potential psychological problems of children and parents are reduced. Additionally, reduction of cost for institution is likely. With proper algorithm and parent's education, especially in COVID-19 pandemic days, uncomplicated AA should be addressed this way.

7. REFERENCES

1. Schumpelick V, Dreuw B, Ophoff K. Appendix and cecum: embryology, anatomy, and surgical applications. *Surgl Clin North Am.* 2000;80:295-318.
2. Paulsen F, Waschke J. Sobotta: Atlas der Anatomie des Menschen, innere Organe. 23rd ed. München: Urban & Fischer; 2010. 93 p.
3. Kacprzyk A, Droś J, Stefura T, Krzysztofik M, Jasińska K, Pędziwiatr M, et al. Variations and morphometric features of the vermiform appendix: A systematic review and meta-analysis of 114,080 subjects with clinical implications. *Clin Anat.* 2020;33:85-98.
4. Searle A, Ismail KA, Macgregor D, Hutson JM. Changes in the length and diameter of the normal appendix throughout childhood. *J Pediatr Surg.* 2013;48:1535-39.
5. Mescher A. Junqueira's basic histology: Text and atlas. 15th ed. New York: Lange; 2018. 282 p.
6. Norman J, Sobin L. Appendix. In Weidner N, Cote R, Suster S, Weiss L. *Modern surgical pathology.* Philadelphia: Elsevier; 2009. p. 837-54.
7. Gehring A, Schneider-Koriath S, Förster S, Ludwig K. Akute Appendizitis. *Allg- Visz up2date.* 2014;8:343-54.
8. Williams R, Myers P. Pathology of the appendix and its surgical treatment. 1st ed. London: Chapman & Hall Medical; 1994. p. 1-10.
9. Ellis H. The 100th birthday of appendicitis. *Br Med J.* 1986;293:1617-8.
10. Hontschik B. Kurze Geschichte der Appendektomie: Mythen, Fakten, Perspektiven. 1st ed. München: Marseille Verlag; 2012. p. 6-21.
11. Bhattacharya K. Kurt Semm: A laparoscopic crusader. *J Minim Access Surg.* 2007;3:35-6.
12. Jaschinski T, Mosch C, Eikermann M, Neugebauer E, Sauerland S. Laparoscopic versus open surgery for suspected appendicitis. *Cochrane Database Syst Rev.* 2018;11:CD001546.
13. Liu Y, Cui Z, Zhang R. Laparoscopic versus open appendectomy for acute appendicitis in children. *Indian Pediatr.* 2017;54:938-41.
14. Esparaz JR, Jeziorczak PM, Mowrer AR, Chakraborty SR, Nierstedt RT, Zumpf KB, et al. Adopting single-incision laparoscopic appendectomy in children: Is it safe during the learning curve? *J Laparoendosc Adv Surg Tech A.* 2019;29:1306-10.

15. Singh M, Kumar M, Mohan L. Suprapubic approach for laparoscopic appendectomy. *J Nat Sci Biol Med.* 2013;4:389-92.
16. Bhangu A, Søreide K, Di Saverio S, Assarsson J, Drake F. Acute appendicitis: modern understanding of pathogenesis, diagnosis, and management. *Lancet.* 2015;386:1278-87.
17. Wickramasinghe, DP, Xavier, C, Samarasekera, DN. The worldwide epidemiology of acute appendicitis: An analysis of the global health data exchange dataset. *World J Surg.* 2021;45:1999-2008.
18. Snyder M, Guthrie M, Cagle S. Acute appendicitis: Efficient diagnosis and management. *Am fam physician.* 2018;98:25-33.
19. Wente M, Waleczek H. Strategien zur Vermeidung negativer Appendektomien. *Chirurg.* 2009;80:588-93.
20. Ponsky T, Huang Z, Kittle K, Eichelberger M, Gilbert J, Brody F, et al. Hospital- and patient-level characteristics and the risk of appendiceal rupture and negative appendectomy in children. *JAMA.* 2004;292:1977-82.
21. Smink D, Fishman S, Kleinman K, Finkelstein J. Effects of race, insurance status, and hospital volume on perforated appendicitis in children. *Pediatrics.* 2005;115:920-5.
22. Ferris M, Quan S, Kaplan B, Molodecky N, Ball C, Chernoff G, et al. The global incidence of appendicitis: A systematic review of population-based studies. *Ann Surg.* 2017;266:237-41.
23. Hellberg A, Rudberg C, Enochsson L, Gudbjartsson T, Wenner J, Kullman E, et al. Conversion from laparoscopic to open appendectomy: a possible drawback of the laparoscopic technique? *Eur J Surg.* 2001;167:209-13.
24. Pathan NA, Shaikh AA, Shaikh MA. Appendectomy; unusual incidental histopathological findings in appendectomy specimens. *Professional Med J.* 2018;25:1301-5.
25. Pogorelić Z, Domjanović J, Jukić M, Poklepović Peričić T. Acute appendicitis in children younger than five years of age: Diagnostic challenge for pediatric surgeons. *Surg Infect (Larchmt).* 2020;21:239-45.
26. Lamps L. Infectious causes of appendicitis. *Infect Dis Clin North Am.* 2010;24:995-1018.

27. Teixeira F, do Couto Netto S, Akaishi E, Utiyama E, Menegozzo C, Rocha MC. Acute appendicitis, inflammatory appendiceal mass and the risk of a hidden malignant tumor: a systematic review of the literature. *World J Emerg Surg.* 2017;12:12.
28. Telford G, Wallace J. Appendix. In Yeo C, Dempsey D, Klein A, Pemberton J, Peter J. *Surgery of the alimentary tract.* 6th ed. Philadelphia: Saunders; 2006. p. 2141-51.
29. Gomes C, Sartelli M, Di Saverio S, Ansaloni L, Catena F, Coccolini F, et al. Acute appendicitis: proposal of a new comprehensive grading system based on clinical, imaging and laparoscopic findings. *World J Emerg Surg.* 2015;10:60.
30. Mariage M, Sabbagh C, Grelpois G, Prevot F, Darmno I, Regimbeau J. Surgeon's definition of complicated appendicitis: A prospective video survey study. *Euroasian J Hepatogastroenterol.* 2019;9:1-4.
31. Fluke L, McEvoy C, Peruski A, Shibley C, Adams B, Stinnette S, et al. Evaluation of disparity in care for perforated appendicitis in a universal healthcare system. *Pediatr Surg Int.* 2020;36:219-25.
32. Stinger M. Acute appendicitis. *J Paediatr Child Health.* 2017;53:1071-6.
33. Atema J, Van Rossem C, Leeuwenburgh M, Stoker J, Boermeester M. Scoring system to distinguish uncomplicated from complicated acute appendicitis. *Br J Surg.* 2015;102:979-90.
34. Orthopoulos G, Santone E, Izzo F, Tirabassi M, Pérez-Caraballo A, Corriveau N, et al. Increasing incidence of complicated appendicitis during COVID-19 pandemic. *Am J Surg.* 2021;221:1056-60.
35. Pogorelić Z, Anand S, Žuvela T, Singh A, Križanac Z, Krishnan N. Incidence of complicated appendicitis during the COVID-19 pandemic versus the pre-pandemic period: A systematic review and meta-analysis of 2782 pediatric appendectomies. *Diagnostics (Basel).* 2022;12(1):127.
36. Andersson R. Meta-analysis of the clinical and laboratory diagnosis of appendicitis. *Br J Surg.* 2004;91:28-37.
37. Becker T, Kharbanda A, Bachur R. Atypical clinical features of pediatric appendicitis. *Acad Emerg Med.* 2007;14:124-9.
38. Dunn J. Appendicitis. In Coran A, Caldamone A, Adzick S, Krummel T, Laberge J, Shamberger R. *Pediatric surgery.* 7th ed. Philadelphia: Elsevier; 2012. p. 1255-63.

39. Bhangu A, Søreide K, Di Saverio S, Assarsson J, Drake F. Acute appendicitis: Modern understanding of pathogenesis, diagnosis, and management. *Lancet*. 2015;386:1278-87.
40. Van Gulik T, Brummelkamp W. Otto Lanz, surgeon and art collector. *Neth J Surg*. 1988;40:31-6.
41. Rastogi V, Singh D, Tekiner H, Ye F, Mazza JJ, Yale SH. Abdominal physical signs and medical eponyms: Part II physical examination of palpation, 1907-1926. *Clin Med Res*. 2019;17:47-54.
42. Benabbas R, Hanna M, Shah J, Richard Sinert R. Diagnostic accuracy of history, physical examination, laboratory tests, and point-of-care ultrasound for pediatric acute appendicitis in the emergency department: A systematic review and meta-analysis. *Acad Emerg Med*. 2017;24:523-51.
43. Anandalwar S, Callahan M, Bachur R, Feng C, Sidhwa F, Karki M, et al. Use of white blood cell count and polymorphonuclear leukocyte differential to improve the predictive value of ultrasound for suspected appendicitis in children. *J Am Coll Surg*. 2015;220:1010-7.
44. Snyder M, Cagle S. Acute appendicitis: Efficient diagnosis and management. *Am Fam Physician*. 2018;98:25-33.
45. Sahm M, Pross M, Lippert H. Akute Appendizitis - Wandel in Epidemiologie, Diagnostik und Therapie. *Zentralbl Chir*. 2011;136:18-24.
46. Sivit C, Applegate K. Imaging of acute appendicitis in children. *Semin Ultrasound CT MR*. 2003;24:74-82.
47. Ashjaei B, Mehdizadeh M, Alizadeh H, Najm N, Moghtaderi M. Evaluating the value of different sonographic findings in diagnosis of acute appendicitis in children. *Afr J Paediatr Surg*. 2022;19:13-7.
48. Doria A, Moineddin R, Kellenberger C, Epelman M, Beyene J, Schuh S, et al. US or CT for diagnosis of appendicitis in children and adults? A meta-analysis. *Radiology*. 2006;241:83-94.
49. Glass C, Rangel S. Overview and diagnosis of acute appendicitis in children. *Semin Pediatr Surg*. 2016;25:198-203.

50. Mittal M, Dayan P, Macias C, Bachur R, Bennett J, Dudley N, et al. Pediatric emergency medicine collaborative research committee of the american academy of pediatrics: Performance of ultrasound in the diagnosis of appendicitis in children in a multicenter cohort. *Acad Emerg Med.* 2013;20:697-702.
51. Trout A, Sanchez R, Ladino-Torres M, Pai D, Strouse P. A critical evaluation of US for the diagnosis of pediatric acute appendicitis in a real-life setting: how can we improve the diagnostic value of sonography?. *Pediatr Radiol.* 2012;42:813-23.
52. Nielsen J, Boomer L, Kurtovic K, Lee E, Kupzyk K, Mallory R, et al. Reducing computed tomography scans for appendicitis by introduction of a standardized and validated ultrasonography report template. *J Pediatr Surg.* 2015;50:144-8.
53. Choi D, Park H, Lee Y, Kook S, Kim S, Kwag H, et al. The most useful findings for diagnosing acute appendicitis on contrast-enhanced helical CT. *Acta Radiol.* 2003;44:574-82.
54. Hwang M. Sonography and computed tomography in diagnosing acute appendicitis. *Radiol Technol.* 2018;89:224-37.
55. Brenner D. Estimating cancer risks from pediatric CT: Going from the qualitative to the quantitative. *Pediatr Radiol.* 2002;32:228-31.
56. Kotagal M, Richards M, Flum D, Acierno S, Weinsheimer R, Goldin A. Use and accuracy of diagnostic imaging in the evaluation of pediatric appendicitis. *J Pediatr Surg.* 2015;50:642-6.
57. D'Souza N, Hicks G, Beable R, Higginson A, Rud B. Magnetic resonance imaging (MRI) for diagnosis of acute appendicitis. *Cochrane Database Syst Rev.* 2021;12:CD012028.
58. Covelli J, Madireddi S, May L, Costello J, Lisanti C, Carlson C. MRI for pediatric appendicitis in an adult-focused general hospital: A clinical effectiveness study-challenges and lessons learned. *AJR Am J Roentgenol.* 2019;212:180-7.
59. Mervak B, Wilson S, Handly B, Altun E, Burke L. MRI of acute appendicitis. *J Magn Reson Imaging.* 2019;50:1367-76.
60. Cobben L, Groot I, Kingma L, Coerkamp E, Puylaert J, Blickman J. A simple MRI protocol in patients with clinically suspected appendicitis: Results in 138 patients and effect on outcome of appendectomy. *Eur Radiol.* 2009;19:1175-83.

61. Alvarado A. A practical score for the early diagnosis of acute appendicitis. *Ann Emerg Med.* 1986;15:557-64.
62. Samuel M. Pediatric appendicitis score. *J Pediatr Surg.* 2002;37:877-81.
63. Andersson M, Andersson R. The appendicitis inflammatory response score: A tool for the diagnosis of acute appendicitis that outperforms the Alvarado score. *World J Surg.* 2008;32:1843-9.
64. de Castro S, Ünlü C, Steller E, van Wagenveld B, Vrouwenraets B. Evaluation of the appendicitis inflammatory response score for patients with acute appendicitis. *World J Surg.* 2012;36:1540-5.
65. Mandeville K, Pottker T, Bulloch B, Liu J. Using appendicitis scores in the pediatric ED. *Am J Emerg Med.* 2011;29:972-7.
66. Schneider C, Kharbanda A, Bachur R. Evaluating appendicitis scoring systems using a prospective pediatric cohort. *Ann Emerg Med.* 2007;49:778-84.
67. Pogorelić Z, Rak S, Mrklič I, Jurić I. Prospective validation of alvarado score and pediatric appendicitis score for the diagnosis of acute appendicitis in children. *Pediatr Emerg Care.* 2015;31:164-8.
68. Chandrasekaran T, Johnson N. Acute appendicitis. *Surgery.* 2014;8:413-7.
69. St. Peter S, Wester T. Appendicitis. In Holcomb G, Murphy J, St Peter S. *Ashcraft's pediatric surgery.* 7th ed. Philadelphia: Elsevier; 2020. p. 664-678.
70. Styrud J, Eriksson S, Nilsson I, Ahlberg G, Haapaniemi S, Neovius G, et al. Appendectomy versus antibiotic treatment in acute appendicitis. A prospective multicenter randomized controlled trial. *World J Surg.* 2006;30:1033-7.
71. Hartwich J, Luks F, Watson-Smith D, Kurkchubasche A, Muratore C, Wills H, et al. Nonoperative treatment of acute appendicitis in children: A feasibility study. *J Pediatr Surg.* 2016;5:111-6.
72. Nepomuceno H, Pearson E. Nonoperative management of appendicitis in children. *Transl Gastroenterol Hepatol.* 2021;6:47.
73. Minneci P, Hade E, Lawrence A, Sebastião Y, Saito J, Mak G, et al. Association of nonoperative management using antibiotic therapy vs laparoscopic appendectomy with treatment success and disability days in children with uncomplicated appendicitis. *JAMA.* 2020;324:581-93.

74. Podda M, Gerardi C, Cillara N, Fearnhead N, Gomes C, Birindelli A, et al. Antibiotic treatment and appendectomy for uncomplicated acute appendicitis in adults and children: A systematic review and meta-analysis. *Ann Surg.* 2019;270:1028-40.
75. Patkova B, Svenningsson A, Almström M, Eaton S, Wester T, Svensson J. Nonoperative treatment versus appendectomy for acute nonperforated appendicitis in children: Five-year follow up of a randomized controlled pilot trial. *Ann Surg.* 2020;271:1030-5.
76. Largiadèr F, Saeger H, Keel M. *Checkliste Chirurgie.* 11th ed. Stuttgart: Thieme; 2016. p. 733.
77. Pogorelić Z, Beara V, Jukić M, Rashwan H, Šušnjar T. A new approach to laparoscopic appendectomy in children-clipless/sutureless harmonic scalpel laparoscopic appendectomy. *Langenbecks Arch Surg.* 2022;407:779-87.
78. Gupta V, Singh S, Singh S, Bansal M, Pandey A. Sutureless appendectomy by using harmonic scalpel: Is it possible? *J Laparoendosc Adv Surg Tech.* 2020;30:429-432.
79. Nadler E, Gaines B, Therapeutic Agents Committee of the Surgical Infection Society. The surgical infection society guidelines on antimicrobial therapy for children with appendicitis. *Surg Infect.* 2008;9:75-83.
80. Ingraham A, Cohen M, Bilimoria K, Ko C, Hall B, Russell T, et al. Effect of delay to operation on outcomes in adults with acute appendicitis. *Arch Surg.* 2010;145:886-92.
81. Stilling N, Fristrup C, Gabers T, Qvist N, Rasmussen L. Acceptable outcome after laparoscopic appendectomy in children. *Dan Med J.* 2013;60:A4564.
82. Jaschinski T, Mosch C, Eikermann M, Neugebauer E. Laparoscopic versus open appendectomy in patients with suspected appendicitis: A systematic review of meta-analyses of randomised controlled trials. *BMC Gastroenterol.* 2015;15:1-10.
83. Wilmore D, Kehlet H. Management of patients in fast track surgery. *BMJ Br Med J.* 2001;322:473-6.
84. Alkhoury F, Burnweit C, Malvezzi L, Knight C, Diana J, Pasaron R, et al. A prospective study of safety and satisfaction with same-day discharge after laparoscopic appendectomy for acute appendicitis. *J Pediatr Surg.* 2012;47:313-6.
85. Cash C, Frazee R, Smith R, Davis M, Hendricks J, Childs E, et al. Outpatient laparoscopic appendectomy for acute appendicitis. *The American Surgeon.* 2012;78:213-5.

86. Cheng O, Cheng L, Burjonrappa S. Facilitating factors in same-day discharge after pediatric laparoscopic appendectomy. *J Surg Res.* 2018;229:145-9.
87. de Wijckerslooth E, Bakas J, van Rosmalen J, van den Boom A, Wijnhoven B. Same-day discharge after appendectomy for acute appendicitis: A systematic review and meta-analysis. *Int J Colorectal Dis.* 2021;36:1297-309.
88. Cohen-Salmon , D. Perioperative psychobehavioural changes in children. *Ann Fr Anesth Reanim.* 2010;29:289-300.
89. Kampouroglou G, Velonaki V, Pavlopoulou I, Drakou E, Kosmopoulos M, Kouvas N, et al. Parental anxiety in pediatric surgery consultations: The role of health literacy and need for information. *J Pediatr Surg.* 2020;55:590-6.
90. Frisch A, Johnson A, Timmons S, Weatherford C. Nurse practitioner role in preparing families for pediatric outpatient surgery. *Pediatr Nurs.* 2010;36:41-7.
91. Isaacman D, Purvis K, Gyuro J, Anderson Y, Smith D. Standardized instructions: Do they improve communication of discharge information from the emergency department? *Pediatrics.* 1992;89:1204-8.
92. Brewer S, Gleditsch S, Syblik D, Tietjens M, Vacik H. Pediatric anxiety: Child life intervention in day surgery. *J Pediatr Nurs.* 2006;21:13-22.
93. Aguayo P AH, Desai A, Fraser J, St Peter S. Initial experience with same day discharge after laparoscopic appendectomy for nonperforated appendicitis. *J Surg Res.* 2014;190:93-7.
94. Gee K, Ngo S, Burkhalter L, Beres A. Same-day discharge vs. observation after laparoscopic pediatric appendectomy: A prospective cohort study. *Transl Gastroenterol Hepatol.* 2021;6:45.
95. Ngo SGK, Burkhalter L, Beres A. Parental satisfaction with same-day discharge after laparoscopic appendectomy for uncomplicated appendicitis. *Paediatr Child Health.* 2019;24:318-22.
96. Dindo D, Demartines N, Clavien P. Classification of surgical complications: A new proposal with evaluation in a cohort of 6336 patients and results of a survey. *Ann Surg.* 2004;240:205-13.
97. Esposito C, Calvo A, Castagnetti M, Alicchio F, Suarez C, Giurin I, et al. Open versus laparoscopic appendectomy in the pediatric population: A literature review and analysis of complications. *J Laparoendosc Adv Surg Tech A.* 2012;22:834-9.

98. Yu Y, Smith C, Ceyanes K, Naik-Mathuria B, Shah S, Vogel A, et al. A prospective same day discharge protocol for pediatric appendicitis: Adding value to a common surgical condition. *J Pediatr Surg.* 2018;53:36-41.
99. Jukić M, Antišić J, Pogorelić Z. Incidence and causes of 30-day readmission rate from discharge as an indicator of quality care in pediatric surgery. *Acta Chir Belg.* 2021;1-5.
100. Jukić M, Biuk I, Pogorelić Z. The incidence and causes of unplanned reoperations as a quality indicator in pediatric surgery. *Children.* 2022;9:106.
101. Cairo S, Raval M, Browne M, Meyers H, Rothstein D. Association of same-day discharge with hospital readmission after appendectomy in pediatric patients. *JAMA Surg.* 2017;152:1106-12.
102. Lo H, Yang C, Rettig R, Chung J, Shaul D, Sydorak R. Same day discharge after pediatric laparoscopic appendectomy in community hospitals. *J Pediatr Surg.* 2022;57:1242-8.
- 103 Khan SY, Al-Balushi ZN, Bhatti KM, Ehsan T, Mandhan, P. Cost comparison between laparoscopic and open appendectomies in children. *Sultan Qaboos Univ Med J.* 2013;13:275-9.
104. Pogorelić Z, Buljubasic, M, Susnjar, T, Jukić M, Pericic TP, Juric I. Comparison of open and laparoscopic appendectomy in children: A 5-year single center experience. *Indian Pediatr.* 2019;56:299-303.

8. ENGLISH SUMMARY

Objectives: The aim of this study was to determine the safety and parental satisfaction of discharge home within 24 hours after laparoscopic appendectomy for uncomplicated acute appendicitis (AA).

Patients and Methods: From March 1st, 2021, to May 1st, 2022, a total of 180 patients were included in the study. All patients, ages 6 to 17, who underwent laparoscopic appendectomy for uncomplicated AA and were discharged to home care within 24 hours of the procedure, performed by three pediatric surgeons, were included in this prospective non-randomized cohort study. Demographic data, input characteristics, duration of surgery, intraoperative and postoperative complications, treatment outcomes as well as parental satisfaction and pain levels were recorded.

Results: The median age was 11 years (IQR 10, 14). Slightly male predominance 63.8% (n = 115) was recorded. The median postoperative hospital stay was 15 hours (IQR 12, 19). The majority of parents (n = 155, 86.1%) expressed the highest satisfaction at the day of discharge, while the remaining 25 (13.8%) expressed moderate satisfaction. Median pain levels according to VAS for all postoperative days were low, counting: 4 (IQR 4, 6), 2 (IQR 2, 5), 2 (IQR 0, 4), 1 (IQR 0, 2), 0 (IQR 0, 2) and 0 (IQR 0, 0) for 1st, 2nd, 3rd, 4th, 5th, and 6th-7th postoperative day, respectively. Four patients (2.2%) had an unplanned readmission to hospital treatment before the 7th postoperative day because of postoperative abscess and were treated conservatively. Almost all parents (n = 175, 97.2%) expressed the highest level of satisfaction during the outpatient follow-up examination on day 7.

Conclusion: Discharge, for home care, within 24 hours after laparoscopic appendectomy due to uncomplicated AA in children is safe and feasible, and parental satisfaction is high. With the right algorithm and parent education, especially in the days of the COVID-19 pandemic, uncomplicated AA may be treated in this way.

9. CROATIAN SUMMARY

Naslov: Evaluacija otpusta djece, operirane laparoskopskim putem zbog nekomplikiranog akutnog apendicitisa (AA), s bolničkog liječenja na kućnu njegu, unutar jednog dana od zahvata.

Ciljevi: Cilj ovog istraživanja bio je utvrditi sigurnost i zadovoljstvo roditelja otpustom kući unutar 24 sata nakon laparoskopske apendektomije zbog nekomplikirane akutne upale crvuljka.

Materijali i metode: Od 1. ožujka 2021. do 1. svibnja 2022., u studiju uključeno je ukupno 180 bolesnika. Svi bolesnici, od 6 do 17 godina, kojima je učinjena laparoskopska apendektomija, izvedena od strane tri dječja kirurga, zbog nekomplikiranog AA, a koji su otpušteni na kućnu njegu unutar 24 sata od zahvata, uključeni su u ovo prospektivno nerandomizirano kohortno istraživanje. Demografski podatci, ulazne karakteristike, duljina trajanja operacijskog zahvata, intraoperacijske i poslijeoperacijske komplikacije, ishodi liječenja te zadovoljstvo roditelja i razina boli su zabilježene.

Rezultati: Medijan dobi iznosio je 11 godina (IQR 10, 14). Zabilježena je blaga predominacija 63,8% (n=115) muškog spola. Medijan poslijeoperacijskog boravka u bolnici iznosio je 15 sati (IQR 12, 19). Većina roditelja (n=155, 86,1%) iskazala je najviše zadovoljstvo danom otpusta, dok je ostatak 25 (13,8%) iskazalo osrednje zadovoljstvo. Medijani razine boli prema VAS-u za sve poslijeoperacijske dane bili su niski, brojeći: 4 (IQR 4, 6), 2 (IQR 2, 5), 2 (IQR 0, 4), 1 (IQR 0, 2), 0 (IQR 0, 2) i 0 (IQR 0, 0) za 1., 2., 3., 4., 5. i 6.-7. poslijeoperacijski dan. Četiri bolesnika (2,2 %) su neplanirano ponovno primljena na bolničko liječenje zbog poslijeoperacijskog apscesa, prije 7. poslijeoperacijskog dana te su liječeni konzervativno. Gotovo svi roditelji (n=175, 97,2%) iskazali su najvišu razinu zadovoljstva prilikom ambulantnog kontrolnog pregleda (7. dan).

Zaključci: Otpust, na kućnu njegu, unutar 24 sata nakon laparoskopske apendektomije zbog nekomplikiranog AA u djece je siguran i izvediv, a zadovoljstvo roditelja je visoko. Uz odgovarajući algoritam i edukaciju roditelja, posebno u vrijeme pandemije COVID-19, preporuča se otpust unutar 24 sata za djecu s nekomplikiranim apendicitisom.

10. CURRICULUM VITAE

Alexander Tesch
+49 (0) 152 010 473 96
tesch.alexander@web.de

Personal data

Birthday 23. April 1990
Place of Birth Graefelfing, Munich, Germany
Adress Maistrasse 13, 82237, Wörthsee

Education

October 2016- **University of Split School of Medicine**
today Degree of Medical Doctor

November- **Rheinisches Bildungszentrum Köln**
March 2016 Presemester Medicine

October 2012- **Universität Hamburg, Hamburg**
Sep. 2015 Bachelor of Science in business administration

Sept. 2001- **Max-Born-Gymnasium Germering,**
Mai 2009 later **Carl-Spitzweg-Gymnasium Germering**
Abitur

Working Experience

January- **BG Unfallklinik Murnau**
March 2022 Clinical rotation Surgery – practical year student

July- **BG Unfallklinik Murnau**
August 2021 Internship at the surgical department - Famulus

March- **University of Split**
June 2018/19 Demonstrator of Anatomy

July **Chirurgisches MVZ Landsberg**
2017/18/19 Doctors assistant

March- **Klinikum Starnberg**
Juli 2011 Doctors assistant at emergency department

Languages

Deutsch C2

English C1

French B2

Croatian A2

11. SUPPLEMENTS

Supplement 1. Study Protocol

Evaluation of the discharge of children from hospital treatment to home care operated on for acute appendicitis Protocol number _____

CLINICAL AND DEMOGRAPHIC DATA

Datum _____ MB _____
Name and Surname _____; Age _____; Sex M / F;
Height _____ cm; Weight _____ kg; Duration of Symptoms _____ h;
Body Temperature _____ °C; Duration of surgery _____ min;
Operation Starting Time _____ h; Exact discharge time (date and hour) _____

LABORATORY AND RADIOLOGIC REPORTS

Leukocytes _____ x10⁹/L CRP _____ mg/L Neutrophils _____ %

ULTRASOUND:

INTRAOPERATIVE REPORT

Medical report: a) catarrhal b) phlegmonous c) gangrenous
d) perforated – local peritonitis e) perforated – diffuse peritonitis
f) without pathological findings g) other _____

Appendiceal Base Management:

a) polymeric clip b) endoscopic loop c) harmonic scalpel (Gupta) ULTRACISION / LOTUS

INTRAOPERATIVE COMPLICATIONS:

EARLY POSTOPERATIVE COMPLICATIONS:

PATHOLOGICAL REPORT

a) catarrhal b) phlegmonous c) gangrenous d) without pathological findings

AIR SCORE		
Vomiting	1	
Pain in the RLQ	1	
Rebound tenderness 1 – light; 2 – medium; 3 – strong	0 - 3	
Elevated Body Temperature > 38.5 °C	1	
Neutrophils: 0 ≤70%; 1 70 – 84%; 2 ≥85%	0 - 2	
Leukocytes: 0 ≤10; 1 10 – 14.9; 2 ≥15	0 - 2	
CRP: 0 ≤10; 1 10 – 49; 2 ≥50	0 - 2	
AIR SCORE	12	

KOMPLICATION:

SATISFACTION ON DISCHARGE: 1 / 2 / 3

SATISFACTION AT FIRST POSTOPERATIVE APPOINTMENT: 1 / 2 / 3

SURGEON _____

Supplement 2. Parental Questionnaire

CHILD'S NAME: DATE & HOUR OF SURGERY: PROTOCOL NUMBER:
PARENTS' NAME: DATE & HOUR OF DISCHARGE: ORDERING PEDIATRIC SURGEON:

**SATISFACTION OF PARENTS ABOUT DISMISSAL WITHIN 24 HOURS
FROM SURGICAL TREATMENT OF CHILD DUE TO ACUTE
INFLAMMATION OF APPENDIX
(TO BE COMPLETED ON DAY OF DISCHARGE)**

Immediately after the surgery and getting detailed information about the past procedure from the pediatric surgeon, how did you feel about being discharged to home care within 24 hours?

1. Angry about the child's short hospital stay, unhappy, very nervous and scared, completely unprepared.
2. Moderately nervous and unprepared and averagely satisfied.
3. Good, lucky, prepared, maximally satisfied.

Comment:

**PARENTAL MEASUREMENT OF POSTOPERATIVE PAIN AT HOME
(To be completed at home until the first outpatient check-up)**

Children sometimes have behavioural changes when recovering from surgical treatment. The attached questionnaire consists of a list of behavioural changes that your child may or may not show during recovery in home care. Please answer yes or no for each symptom:

- | | |
|---|----------|
| 1. Complains and ask for more than usual | YES / NO |
| 2. Cries more than usual | YES / NO |
| 3. Plays less than usual | YES / NO |
| 4. Does not do things he/she usually does | YES / NO |
| 5. Seems more worried than usual | YES / NO |
| 6. Quieter than usual | YES / NO |
| 7. Has less energy than usual | YES / NO |
| 8. Refuses to eat (more than usual) | YES / NO |
| 9. Eats less than usual | YES / NO |
| 10. Holds on to the painful part of the body | YES / NO |
| 11. Is careful not to hit the painful part of the body | YES / NO |
| 12. Moans, sighs, and painfully whines more than usual | YES / NO |
| 13. Redder in the face than usual | YES / NO |
| 14. Wants to be close to you more than usual without separating | YES / NO |
| 15. Agrees to take medication without discussion or refusal | YES / NO |

Additional comments on the child's condition and behaviour:




































POSTOPERATIVE PAIN I (CHILD INFORMATION)

Weight: _____ kg; Height: _____ cm; Sex: M / F; Allergies to medication: _____

What does your child normally take for pain or fever? _____

POSTOPERATIVE PAIN II (HOME CARE AND THERAPY)

Please indicate by postoperative day how you alleviated pain and lowered your child's temperature and how often per day (indicate the name of the drug, the amount of one dose and how many times a day she/he received the drug) and the child's pain rating on the same days. up to 10; (0-without pain; 10-unbearable intense pain)

I. P.O. day: _____	Child's rating:					
		0	2	4	6	8
II. P.O. day: _____	Child's rating:					
		0	2	4	6	8
III. P.O. day: _____	Child's rating:					
		0	2	4	6	8
IV. P.O. day: _____	Child's rating:					
		0	2	4	6	8
V. P.O. day: _____	Child's rating:					
		0	2	4	6	8
VI. P.O. day: _____	Child's rating:					
		0	2	4	6	8
VII. P.O. day: _____	Child's rating:					
		0	2	4	6	8

Comment:

PARENTAL ASSESSMENT AND SATISFACTION ONE WEEK AFTER SURGICAL TREATMENT AND RELEASE WITHIN 24 HOURS OF SURGERY

(Fill in just before coming to the outpatient check-up and take the above with you and hand it over to the attending physician)

Looking back at it how do you feel and what do you think now about the child being discharged from hospital within 24 hours of surgery?

1. I think it was a good choice and the best thing that could be done.
2. I am not sure if it was a good choice and the best thing that could be done.
3. I think it was a bad decision releasing the child from hospital this early and that he has this condition/disease again. I would like her/him to be discharged to home care later and to stay in the hospital longer.

Parents' comments on this type of discharge:

Supplement 3. Ethical review board approval



KLINIČKI BOLNIČKI CENTAR SPLIT
ETIČKO POVJERENSTVO

Klasa: 500-03/21-01/151
Urbroj: 2181-147/01/06/M.S.-21-02

Split, 30.09.2021.

IZVOD IZ ZAPISNIKA SJEDNICE ETIČKOG POVJERENSTVA KBC SPLIT 16/2021

11.

Dr.sc. Miro Jukić, dr.med. iz Klinike za dječju kirurgiju KBC-a Split je uputio Etičkom povjerenstvu zamolbu za odobrenje provedbe istraživanja:

" Evaluacija otpusta djece operirane zbog nekompliciranog akutnog apendicitisa s bolničkog liječenja na kućnu njegu "

Istraživanje za potrebe izrade diplomskog rada i publikacije rada u znanstvenom časopisu će se provesti u Klinici za dječju kirurgiju KBC-a Split u trajanju od 2 godine dana.
Suradnik u istraživanju je Aleksander Tesch, student Medicinskog fakulteta u Splitu i liječnici Klinike za dječju kirurgiju KBC-a Split.

Nakon razmatranja zamolbe, donijet je sljedeći

Zaključak

Iz priložene dokumentacije razvidno je da je Plan istraživanja usklađen s odredbama o zaštiti prava i osobnih podataka ispitanika iz Zakona o zaštiti prava pacijenata (NN169/04, 37/08) i Zakona o provedbi Opće uredbе o zaštiti podataka (NN 42/18), te odredbama Kodeksa liječničke etike i deontologije (NN55/08, 139/15) i pravilima Helsinške deklaracije WMA 1964-2013 na koje upućuje Kodeks.

Etičko povjerenstvo je suglasno i odobrava provođenje istraživanja.

KLINIČKI BOLNIČKI CENTAR SPLIT
ETIČKO POVJERENSTVO
PREDSJEDNIK ETIČKOG POVJERENSTVA
KLINIČKOG BOLNIČKOG CENTRA SPLIT
PROF. DR. SC. MARIJAN SARAGA