

# Morphological characteristics of placentas from in vitro fertilization and embryo transfer pregnancies

---

**Bagnacani, Sara**

**Master's thesis / Diplomski rad**

**2022**

*Degree Grantor / Ustanova koja je dodijelila akademski / stručni stupanj:* **University of Split, School of Medicine / Sveučilište u Splitu, Medicinski fakultet**

*Permanent link / Trajna poveznica:* <https://um.nsk.hr/um:nbn:hr:171:376346>

*Rights / Prava:* [In copyright](#)/[Zaštićeno autorskim pravom.](#)

*Download date / Datum preuzimanja:* **2024-08-27**



*Repository / Repozitorij:*

[MEFST Repository](#)



**UNIVERSITY OF SPLIT**

**SCHOOL OF MEDICINE**

**SARA BAGNACANI**

**MORPHOLOGICAL CHARACTERISTICS OF PLACENTAS FROM IN VITRO  
FERTILIZATION AND EMBRYO TRANSFER PREGNANCIES**

**Diploma thesis**

**Academic year:**

**2021-2022**

**Mentor:**

**Assist. Prof. Sandra Zekić Tomas, MD, PhD**

**Split, July 2022**

## TABLE OF CONTENTS

1. INTRODUCTION .....	1
1.1 Infertility .....	2
1.1.2 Causes of infertility.....	3
1.1.3 Female Infertility .....	4
1.2 Assisted Reproductive Technologies (ART) .....	7
1.2.1 In Vitro Fertilization and Embryo Transfer.....	7
1.2.2 Assisted Reproductive Technology major adverse outcome.....	10
1.3 Placenta .....	12
1.3.1 Development of Human Placenta .....	13
1.3.2 Pathological characteristics of placenta.....	16
1.3.2.1 Maternal vascular malperfusion.....	16
1.3.2.2 Fetal vascular malperfusion.....	19
1.3.2.3 Villitis of unknown etiology.....	19
1.3.2.4 Acute inflammatory lesions.....	20
1.4 Placental morphological characteristics of IVF + ET pregnancies.....	21
2. OBJECTIVES.....	23
2.1 Objectives .....	24
2.2 Hypothesis.....	24
3. MATERIALS AND METHODS.....	25
3.1 Study Design.....	26
3.2 Materials and data collection .....	26
3.3 Methods of data processing .....	26
3.4 Statistical analysis.....	26
3.5 Ethical committee approval .....	26
4. RESULTS .....	27
5. DISCUSSION .....	31
6. CONCLUSION.....	35
7. REFERENCES.....	37
8. SUMMARY.....	43
9. CROATIAN SUMMARY.....	46
10. CURRICULUM VITAE.....	48

## ACKNOWLEDGEMENTS

*I would like to express my sincere gratitude to my mentor Assistant Professor Sandra Zekić Tomas, MD, PhD for her constant support throughout the entire process of writing my diploma thesis. Her exceptional guidance and mentorship have positively impacted the final part of this journey.*

*To my family, thank you for the opportunity to study medicine. I will always be grateful for your unwavering support and for believing in me. This journey without your constant encouragement would have been unimaginable.*

*My profound gratitude goes to my close friends from Split and all over the world that motivated me throughout the entire studies and showed me their unconditional support for my aspirations and dreams.*

*Words can't express how grateful I am to the city of Split. I will always cherish the memories and the great experiences made here in the past six years.*

*Split will always have a special place in my heart.*

## **LIST OF ABBREVIATIONS**

AMH - Antimullarian hormone

ANA - Antinuclear antibodies

ART - Assisted reproductive technologies

ASRM- American society of reproductive medicine

BMI - Body mass index

CDC - American Center for Disease Control

DHEAS - Dehydroepiandrosterone

DVH - Distal villous hypoplasia

E2 - Estradiol

FET - Frozen embryo transfer

FIR - Fetal inflammatory response;

FSH - Follicle stimulating hormone

FVM - Fetal vascular malperfusion;

GnRH - Gonadotropin releasing hormone

HLA-DR - Human leukocyte antigen –DR isotype

ICSI - Intracytoplasmic sperm injection

IVF - In vitro fertilization

LBW - Low birth weight

LH - Luteinizing hormone

MAP - Medical assisted reproduction

MIR - Maternal inflammatory response;

MVM - Maternal vascular malperfusion;

OD - Oocyte donation

OHSS - Ovarian hyperstimulation syndrome

POI - Primary ovarian insufficiency

PPH - Postpartum hemorrhage

PRL - Prolactin

PTB - Premature birth

T3 - Triiodothyronine

TRH - Thyroid releasing hormone

TSH - Thyroid stimulating hormone

UCA - Umbilical cord abnormalities.

VEGF - Vascular endothelial growth factor

VUE - Villitis of unknown etiology;

WHO - World Health Organization

hCG - Human chorionic gonadotropin

## **1. INTRODUCTION**

## 1.1 Infertility

The World Health Organization (WHO) defines infertility as a disease characterized by the inability to conceive after a period of twelve or more months of unprotected sexual intercourse. This condition is a worldwide health problem that has a significant impact on millions of people of reproductive age. According to available data, infertility affects 186 million people globally, or 15-20% of couples of childbearing ages in industrialized countries (1).

Infertility is classified into two types, based on how it is manifested. Primary infertility is defined as a condition in which conception has never occurred, while secondary infertility occurs when the inability to procreate follows a period of fertility, documented by one or more pregnancies (1). The World Health Organization and the American Fertility Society also emphasize the distinction between infertility and sterility. A couple in which one or both individuals are affected by a permanent physical condition which serves as an obstacle to fertilization, and results in a lack of reproductive capacity, would be considered sterile (1). The term sterility, therefore, refers to a serious case of an absolute condition of infertility concerning the couple as a whole, rather than one single member of it. The rapid evolution of Medically Assisted Reproduction (MAP) for the treatment of infertile couples was one of the most extraordinary achievements of modern medicine (2). The percentage of couples who visit Medically Assisted Reproduction (MAP) centers ranges between 4 and 17 percent, and at the end of their reproductive period, only 3-4% of all couples are unable to have children (2).

From the Middle Ages to modern history infertile women have always been subjected to societal and self-stigma (3). Despite the fact that infertility affects both sexes equally, women are the ones that are most frequently blamed and, as a result, they experience a greater psychological stress and sense of guilt (4). Only within the Renaissance period a progress was made in the field of modern medicine, including infertility treatment. While the ancient Greeks believed in traditional therapeutic procedures based on magic, religion and superstitions, the famous physician Hippocrates developed the philosophy of scientific reasoning, which recognized infertility as a proper medical issue requiring its diagnosis and treatment. Despite the fact that modern medicine places a greater emphasis on pharmacological and surgical techniques, Hippocratic therapies were mostly centered on changes in lifestyle. However, the evolution of infertility treatment procedures can be traced back to the time when physicians began to think rationally about the causes of infertility.

Antonie Philips van Leeuwenhoek was the first to detect spermatozoa using a microscope in 1677 (5). He named them “animalcules” and thought they were crucial in the development of embryos. Modern medicine has made strides in understanding reproductive physiology, gamete interaction, and treating and resolving infertility issues since the discovery of spermatozoa (5).



### **1.1.2 Causes of infertility**

Unlike other pathological conditions in which the causative agent is known, infertility is the expression of different male or female factors, most often asymptomatic from a clinical point of view. There are several factors that predispose to the difficulty of obtaining a conception. There is a strong association between lower fertility rate and the increase in the age of the two partners. In particular, in women aged 35 years and older, the possibility of conception does not exceed 30% and further declines to 10% above the age of 40. The age-related decline in female fertility may also be due to a constant decline in the supply of oocytes at the ovarian level. Nevertheless, recent evidence shows that also male fertility undergoes an age-related decrease. In addition, genetic defects affecting sperm and oocytes increase with age, which can decrease the functionality of gametes and embryonic development (6,7).

Moreover, couples with a long-lasting infertility condition have a worse reproductive prognosis. Generally, about 85% of couples conceive spontaneously after one year; if the infertility period is less than 3 years, the probability of conception is 1.7 times greater than for couples who have been infertile for longer periods of time. However, the statistics differ in the case of secondary infertility, in which the probability of conception is still higher than that of those couples affected by primary infertility (8).

Furthermore, it is important to note that infections of the female genital tract could also be associated with lower fertility rates. In women, bacterial vaginosis, pelvic inflammatory disease, and endometritis can cause a variety of health problems which may also include infertility. Inflammation, immunological targeting of sperm antigens, the presence of bacterial toxins, and an increased risk of sexually transmitted diseases are all likely factors in bacterial vaginosis and endometritis-related infertility. Therefore, Treatment of genital tract infections, before attempting conception, would improve outcomes of natural and assisted reproduction (9).

Lack of exercise, poor diet and changes in body weight are often associated with menstrual irregularities in women and changes in seminal parameters in men. Early onset of obesity in women favors the development of menstrual irregularities, chronic oligo-anovulation, and infertility in adulthood. It has been studied that when the body mass index exceeds 30 kg/m, the risk of miscarriage is increased and the outcomes of assisted reproductive technologies are impaired (10). The main factors involved could possibly be insulin excess or insulin resistance. In addition, obesity is correlated to low testosterone levels in men. Reduced spermatogenesis associated with severe hypotestosteronemia may favor infertility in severely obese individuals. Moreover, the frequency of erectile dysfunction rises with increasing BMI (10).

According to the American society of reproductive medicine (ASRM), cigarette smoking appears to negatively affect the ovarian reserve. As a consequence, menopause appears to occur one to four years earlier in smokers than in non-smokers: this is most likely due to an acceleration of follicular loss (11). Additionally, when compared to non-smokers, smoking women that undertake assisted reproductive technology procedures have a 50% reduction in implantation rates and evolving pregnancies.

Evaluating the impact of the various infertility factors serve as a challenge, due to the fact that infertility affects men and women equally. In couples experiencing infertility, approximately 35% of cases are due to male factors, 35% are due to female factors, 20% of cases have a combination of both male and female factors, and the last 10% are unexplained causes. Consequently, it is imperative that both the male and female are evaluated during the infertility work-up (12).

### **1.1.3 Female Infertility**

Female infertility, among couples, occurs at a comparable percentage to that of male infertility. Nevertheless, due to a variety of reasons related to lifestyle changes, the causes of female infertility today are, in part, different than those in the past. Infertility may depend on both genital and extra genital causes that have damaged the reproductive function. In this sense, the endocrine, tubal, uterine, endometrial, cervical, vaginal and immunological factors are considered.

Menstrual disorders and infertility can be caused by severe thyroid dysfunction, via direct and indirect interactions with the hypothalamo-pituitary-ovarian axis and the reproductive organs. The synergistic interaction between follicle-stimulating hormone (FSH) and T3 exerts direct stimulatory effects on granulosa cell functions, LH/hCG receptor formation and apoptosis suppression (13,14). Thyroid hormones may reduce granulosa cell aromatase activity and impair the pre-antral follicle development. Untreated or undiagnosed thyroid disorders can cause subfertility or infertility, which can be associated with high prolactin (PRL) levels, anovulatory cycles, and sex hormone defects (15). Increased Thyroid releasing hormone (TRH) in hypothyroidism causes an increase in PRL levels, which can lead to galactorrhea. Hyperprolactinemia reduces the levels of LH and FSH by inhibiting GnRH neurons in hypothalamus, through the inhibitory action. Impaired pulsatile secretion of GnRH and its interference with ovulation are the reasons why fertility might be affected (16).

Almost 30% of infertile women across the globe have associated fallopian tube pathology (17). About one third of cases of female infertility are due to congenital or acquired changes in the uterine tubes. Alterations at this level disturbs the normal transport and function of oocytes, spermatozoa or embryos along them. Nevertheless, anatomic tubal changes of congenital nature are very rare. In most cases, tubal sterility is a consequence of inflammatory and/or infectious phenomena

of the surrounding peritoneum, which leads to anatomical changes at the tubal level. As a consequence, partial or complete closure of the tubes can take place at any point, making conception even more challenging (17).

Untreated sexually transmitted diseases, which are capable of ascending along the reproductive tract and cause tubal inflammation, damage or scarring, are the cause of the majority of tubal factor infertility cases. The effects of *Chlamydia trachomatis* and *Neisseria gonorrhoeae* as pathogenic bacteria involved in reproductive tract morbidities such as tubal factor infertility and pelvic inflammatory diseases, have also been consistently demonstrated. Furthermore, the voluntary termination of pregnancy or the presence of intra-uterine contraceptive devices can also cause tubal infections (17,18).

Endometriosis is a medical condition that affects 6-10% of women of reproductive age, causing symptoms such as dysmenorrhea, dyspareunia, irregular uterine bleeding, chronic pelvic pain and infertility (19). It is represented by the presence of endometrial cells in sites other than the internal surface of the uterine cavity. These cells can be present in the ovary, in the fallopian tubes and in the intestine, where they could form fluid-filled cysts. Ectopic implants are most commonly found in the pelvis, but they have also been observed in the upper abdomen, lungs, diaphragm and peripheral or axial skeleton (19,20). The lesions involve an inflammatory process with the consequent formation of adhesions that could interfere at the ovarian level with the expulsion of the oocyte and at the tubal level with its transport. Between all the possible theories that try to explain the pathogenesis of endometriosis, retrograde menstruation is among the most accepted. Researchers discovered that tissue from the endometrium is transported through the patent fallopian tubes into the peritoneal cavity in a retrograde fashion (21). Endometrial cells then attach to the peritoneum, establishing a blood supply, proliferate and form a proper endometrial implant. Besides the retrograde menstruation theory, coelomic metaplasia and metastatic spread might be the cause of endometriosis. Peritoneal cells have the capacity to differentiate into endometrial cells (21). Furthermore, women affected by endometriosis are thought to have an altered immunity, preventing them from trying to clear the refluxed endometrial cells (21,22).

Several uterine or cervical factors can disrupt an egg implantation, preventing the onset or continuation of pregnancy (23). In the uterus, benign polyps or tumors (fibroids or myomas) are common. In some cases, they can block fallopian tubes or disrupt implantation, reducing fertility. Problems with the uterus that take place at birth, such as an unusually shaped uterus, can make conception very challenging. Furthermore, cervical stenosis, or cervix narrowing, caused by an inherited malformation or cervical damage, can be the reason for infertility. Sometimes, even the inability to produce cervical mucus could be the cause for infertility (23).

The phenomenon of autoimmunity, which tends to have a higher occurrence in women than in men, underlies various pathological conditions and can contribute to infertility and poliabortivity. In the last 20 years, a subpopulation of infertile women has developed aspecific auto-immunity, defined as the presence of auto-antibodies in blood samples without clinical or biological criteria for a specific disease. Certain autoantibodies appear to be more prevalent in women with fertility disorders than in fertile women. Among them, researchers have paid particular attention to nonspecific anti-nuclear antibodies (ANA). In the context of IVF, a retrospective study found that women who tested positive for ANA, had a lower rate of embryo implantation (25). The same principle applies to positive Anti-tissues antibodies and positive antiphospholipid antibodies women. Furthermore, it has been proved that women presenting with condition such as autoimmune dysthyroidy have a significant lower rate of fertilization (26). Moreover, the finding of anti-sperm antibodies is a fairly frequent occurrence in the evaluation of couples with infertility problems: the female reproductive tract's mucosal immune system can mount an effective immune response against foreign and infectious antigens and, on rare occasions, sperm cells (27).

Chromosomal alterations, in number or structure, affecting the autosomes or sex chromosomes can cause problems in reproductive function, as they often interfere with the normal formation of male and/or female gametes (28). The genetic alterations can in fact arise during the formation of gametes in meiosis. Female gametes are more exposed to errors than male gametes, but errors in female gametogenesis lead to a decrease in the number of oocytes produced. In a rare condition called Turner syndrome (45,X0), women present with short stature, delayed onset of puberty, and ovarian dysgenesis. This condition is also characterized by primary amenorrhea, and for this reason women affected by this pathology are infertile (28). Primary ovarian insufficiency (POI) is characterized by ovarian function loss before the age of 40 and it is a major cause of female infertility. POI is a highly heterogeneous condition that can manifest as ovarian dysgenesis and primary amenorrhea, as well as secondary amenorrhea, and it can be associated with other congenital or acquired abnormalities. POI is still classified as idiopathic in the majority of cases. The age of menopause, on the other hand, is an inheritable trait, and POI has a strong genetic component. The X chromosome-linked defects are the most common genetic contributors to POI (29).

## **1.2 Assisted Reproductive Technologies (ART)**

On July 25, 1978, the world's first baby conceived via in vitro fertilization, Louise Joy Brown, was born in Manchester, England (30). Since its inception in 1978, the number of IVF cycles around the world has significantly increased (31). Over 8 million children have been born since then, with 2,5 million cycles performed every year resulting in over 500 000 deliveries annually (32).

The American Center for Disease Control (CDC) defines the assisted reproductive technologies as any fertility-related procedures that manipulate eggs or embryos. ART is a group of in vitro techniques used to treat moderate and severe infertility, including in vitro fertilization (IVF), intracytoplasmic sperm injection (ICSI), frozen embryo transfer (FET), oocyte donation (OD), blastocyst culture and intrauterine insemination. Among all fertility treatments, in vitro fertilization is the main type (33).

### **1.2.1 In Vitro Fertilization and Embryo Transfer**

Secondary to infertility, in vitro fertilization is the most common procedure performed worldwide. This type of assisted reproductive technology has been used in the laboratory of the University Hospital of Split to assist women in conceiving and, as a result, it will be the one more extensively considered for the purposes of this diploma thesis. This medical procedure involves the removal of oocytes from the ovary and the subsequent in vitro fertilization by culturing eggs with several mobile sperm (33). The process is completed with the transfer of the resulting embryo into the uterus (Figure 1).

In the initial phase, the doctor who evaluates a couple with reproductive difficulties has a fundamental role in starting the diagnostic procedures by collecting a very structured anamnesis, not only by taking into account the general physical and psychological well-being of the couple, but also by acquiring a personal, gynecological, obstetrical and sexual anamnesis (34). It must be assumed that the problem can be caused by several factors attributable to both components of the couple and, for this reason, a global evaluation must be performed simultaneously.

Infertility evaluation can also begin after six months of infertility in females that are older than 35 years old, or in cases where there are known potential impediments, such as male infertility or uterine and tubal diseases. The Basic vital signs, thyroid evaluation, BMI, and pelvic examination are all part of the physical exam that should always be considered by the caregiver along with menstrual and pregnancy history and infertility duration (34).

In order to determine the cause of anovulation, if present, while evaluating the female partner it is important to obtain a complete blood work to assess the levels of follicle-stimulating hormone

(FSH), estradiol (E2) and Anti Mullerian Hormone (AMH). Thyroid-stimulating hormone (TSH) levels, together with prolactin and dehydroepiandrosterone sulfate (DHEAS) levels, testosterone, and 17 hydroxy-progesterone are all tested in patients with ovulatory dysfunction. The uterus and pelvic cavity are also assessed using a baseline transvaginal ultrasound, frequently in conjunction with a hysterosalpingogram or sonohysterogram. The ultrasound examination aids in the evaluation of the basal anatomy of the uterus, ovarian reserve and signs of previous pelvic inflammation. It may also be possible to identify any additional uterine conditions, such as polyps, uterine malformations or submucosal fibroids, that could have an impact on fertility. On the other hand, a seminal fluid analysis is part of the male infertility workup. Furthermore, a basic infectious disease workup, including syphilis, human immunodeficiency virus, or hepatitis is usually performed on both male and female patients (34).

Before the beginning of the IVF treatment, the health care provider might be willing to prescribe combined estrogen and progesterone birth control pill or estrogen alone to prevent the formation of ovarian cysts and to regulate the timing of the menstrual cycle (35). For a controlled stimulation purpose, exogenous gonadotropins such as follicle-stimulating hormone (FSH) and luteinizing hormone (LH) are regularly used. The final goal is to increase the number of follicles that develop during a single cycle. The most widely used gonadotropin therapeutic interventions at this moment are those that are listed below.

There are two different types of injections used for mixed gonadotropin medications in GnRH Antagonist cycles: one with FSH activity and one with both FSH and LH activity. A GnRH antagonist prevents the premature LH surge from occurring. After normal baseline parameters, which need to be confirmed with ultrasound and normal FSH and estradiol levels, the cycles can be started with menstruation. In many cases, the cycle starts after 2-4 weeks of pretreatment with oral contraceptives (35).

In the GnRH antagonist cycles the mixed gonadotropins are also used in two types of injections, one with FSH activity (Recombinant FSH) and one with both FSH and LH activity. A GnRH agonist prevents the premature LH surge from occurring. The GnRH agonist is started before the gonadotropins in the luteal phase of the cycle. When the gonadotropins are started, the GnRH agonist dose is cut in half until a trigger for final maturation before egg retrieval is administered (35).

Transvaginal ultrasound monitoring is used to count and monitor the growth of follicles. Furthermore, serum lab testing is made to track ovarian response by measuring estradiol (E2) levels. Final maturation is induced artificially by the administration of exogenous human chorionic gonadotropin (hCG) or a GnRH agonist once ovarian follicles have matured, usually when two to three follicles are 18mm in size.

Initially, oocyte retrieval was performed through laparotomy and then through laparoscopy. Nowadays, it is routinely performed vaginally under general anesthesia or conscious sedation under ultrasound guidance. To aspirate the follicular fluid, which frequently contains an oocyte, a needle is placed transvaginally and guided under the ultrasound aid into every follicle. A higher number of retrieved oocytes, usually up to 15, is associated with better live birth outcomes. Even if laparoscopic and abdominal egg retrievals have largely fallen out of favor, they are still used to collect oocytes in cases of vaginal agenesis or also when the ovaries are not in the pelvis (35).

Fertilization occurs in vitro by combining retrieved oocytes with spermatozoa in a specific culture medium. Spermatozoa are isolated using density centrifugation after being extracted from an ejaculation sample. Intracytoplasmic sperm injection (ICSI) is performed for people with a positive history of fertilization failure or in male factor infertility. ICSI involves injecting a single sperm directly into the cytoplasm of the oocyte. Subsequently, day 3 (cleavage stage) or day 5 (blastocyst stage) embryos are incubated for transfer. Evaluation of the appearance of embryos on day 5, at the blastocyst stage, is more predictive of success rather than on 2-3 day at the cleavage stage, when the embryos are only 4 or 8 cells (36,37). Once fertilization has taken place, there are several options available for embryo transfer.

During a fresh embryo transfer (ET), the embryo is transferred back into the uterus 3 to 7 days after the egg retrieval, without ever being frozen. (38). On the other hand, a frozen embryo transfer (FET) is a cycle in which the frozen embryos from a prior IVF or donor egg cycle are thawed and placed into the woman's uterus. This procedure can be completed the month after the retrieval cycle or, if needed for a future use, even decades after. Moreover, another procedure known as blastocyst embryo transfer can be used: if many healthy embryos develop after fertilization, it is frequent to wait and see if the embryos develop into blastocysts, and then transfer the latter in the uterus (38).

In daily practice, there are still differences in how many embryos are transferred into a woman's uterus. Despite the fact that many doctors believe that more than one fertilized embryo transfer at the time enhances the chance of a successful pregnancy, in several cases, only just one embryo is transferred into the woman's uterus. According to the guidelines established by the International Journal of Gynecology and Obstetrics, the number of transferred embryos should vary depending on the woman's age and outlook (39). Consequently, for women that are younger than 35 years old and have an excellent chance of pregnancy, doctors will consider using just one embryo. According to a recent study published in *Fertility and Sterility*, single embryo transfer in women under the age of 38 reduces the risk of multiple births while having no effect on live birth rates. This is noteworthy because many health care providers recommend using multiple embryos to ensure a successful pregnancy. This research suggests that multiple embryos may not be required. When a

woman's chances of becoming pregnant appear to be low, doctors may adopt a technique known as heavy load transfer (HLT), in which three or more embryos are transferred into the uterus. HLT should be recommended in patients with a poor natural prognosis because it is likely to boost pregnancy rates to an acceptable level (38,40).

### **1.2.2 Assisted Reproductive Technology major adverse outcome**

Ovarian Hyperstimulation Syndrome (OHSS) is one of the most critical side effects of ART. The reported incidence of ovarian hyperstimulation syndrome varies according to several diagnostic criteria, but it is estimated to be between 1-5% in moderate and severe cases. It is known that the exogenous administration of gonadotropin followed by the administration of hCG may contribute to OHSS (41). During the process of medically assisted reproduction, several follicles recruited in a single cycle excessively produce vascular endothelial growth factor (VEGF) which results in subsequent neovascularization. Edema, ascites, pleural and pericardial effusion, renal injury and thromboembolism are all consequences of significant fluid shifts to the third compartment after extreme follicular growth and fluid and vascular development. Supportive care, such as fluid resuscitation, therapeutic paracentesis, and prophylactic anticoagulation, is provided to patients with moderate to severe OHSS. Patients at risk of OHSS should avoid fresh embryo transfers and keep all embryos frozen until their ovarian stimulation has stopped. If possible, the final maturation trigger should be switched from hCG to a GnRH agonist. To further protect the patient from OHSS, cabergoline, a long-acting dopamine agonist, can be administered every day for eight days following retrieval or the trigger. When the ovarian stimulation has subsided, patients can safely proceed with a frozen embryo transfer one to two months later (41).

Multiple births are also considered as part of the most frequent IVF complications. Transferring more than one embryo increases the likelihood of pregnancy compared to single-embryo transfer, but it also increases the risk of multiple gestations. Multiple pregnancies are related to a wide range of negative outcomes for both the mother and the fetus. For instance, pregnancy-induced hypertension, pre-eclampsia, polyhydramnios, gestational diabetes, postpartum hemorrhage and postpartum depression are all examples of maternal complications. Moreover, multiple pregnancies put babies at risk for early death, prematurity, and low birth weight, as well as mental and physical disabilities associated with prematurity (42).

The World Health Organization (WHO) defines preterm birth (PTB) as a premature birth that occurs before 37 completed weeks of gestation. Preterm births are more significant in pregnancies conceived by in vitro fertilization, as compared to those conceived naturally.

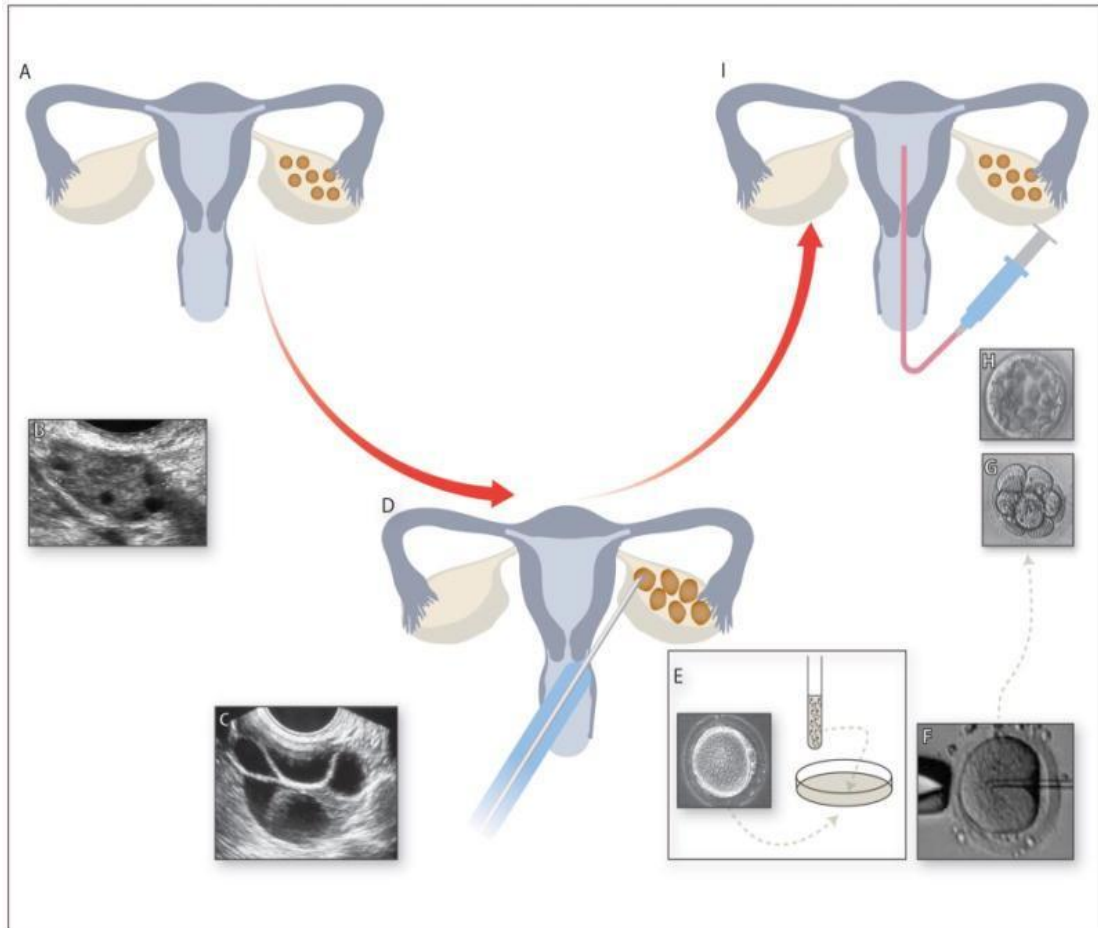


A meta-analysis of 22 studies involving 27,819 IVF/ICSI pregnancies revealed that there is a higher risk of delivery prior to 37 weeks of gestation in medically assisted pregnancies (MAP) rather than children conceived without any medical assistance (43). On the other hand, a significant difference has not been found in the rate of premature births between twin pregnancies conceived with IVF/ICSI and preterm births of non-medical assisted pregnancies. This is most likely due to the higher risk of preterm delivery in twin pregnancies in general, making it difficult to recognize the real cause (42).

Low birth weight, defined by the WHO as a newborn weighing less than 2500 grams or 5.5 pounds, has also been strongly associated with in vitro fertilization. As potential etiologies for LBW in ART, several mechanisms have been proposed. Subfertility, ovarian stimulation or maternal characteristics might act through an impairment of the embryo or endometrium. The impairment of the endometrial quality might lead to placental associated defects. The embryo quality may be influenced by the culture medium and the stage of development at the time of transfer. The embryo's quality impairment can negatively affect its implantation or its development potential (43,44).

Birthweight differences in ART pregnancies may be linked to placental-mediated growth restriction mechanisms. Pathologic studies of ART placentas, for example, have revealed that ART singletons have thicker placentas and a higher prevalence of anomalous umbilical cord insertion than controls, while ART twin placentas were thinner, weighed less, and had more infarctions than non-ART-conceived twin pregnancies. Furthermore, when compared to the general population, pre-eclampsia, placenta previa, and other placental-associated defects such as peripartum hemorrhage, placental abruption, and placenta accreta have been reported in pregnancies after ART (44). Conversely, a study conducted in Japan compares the sizes of the umbilical cord and placentas in women undergoing in vitro fertilization (n=157) versus those with a natural pregnancy (n=1453). The researchers have observed that there was not a significant difference in size of the placenta and umbilical cord between the two study groups, but the incidence of velamentous insertion of the umbilical cord was markedly higher in women with IVF pregnancy (45).

A further significant complication of IVF pregnancies is thought to be atonic bleeding. The loss of muscular tone of the uterus, and its failure to contract after the baby's delivery, can lead to a potentially life-threatening condition also known as post-partum hemorrhage (PPH). Abnormal obstetric PPH is defined as bleeding of over 800 ml within 24 hours, while, severe PPH takes place when bleeding of over 1000ml occurs. A study conducted at the Yanaihara Women's Clinic of Japan revealed that there is a strong association between IVF pregnancies and atonic bleeding, with a 2.7 times higher risk than that of spontaneous pregnancies (46).



**Figure 1.** The IVF + ET process (42). (A) Normal female reproductive system. (B) Transvaginal ultrasound image of unstimulated ovary showing small antral follicles. (C) Transvaginal ultrasound image of stimulated ovary with multiple growing follicles. (D) When follicles reach a certain size, eggs are retrieved from the follicles under transvaginal ultrasound guidance under sedation. Eggs and sperm are combined in the laboratory either by (E) conventional insemination by combining the sperm and eggs in a dish in the laboratory or by (F) intracytoplasmic sperm injection (ICSI). Embryos are cultured for 3 days (eight-cell embryo - G) to 5 days (blastocyst-stage embryo - H). (I) A selected embryo is then transferred into the uterus and excess good-quality embryos are cryopreserved.

### 1.3 Placenta

The placenta is a life-supporting organ for the fetus that develops in the uterus during pregnancy. At 10 weeks of gestation, the placenta weighs about 20 grams, while at 20 weeks of gestation, its weight can reach 150 to 170 grams. Furthermore, a placenta at full term weighs between 500-600 grams, it is about 3 cm thick and has a discoidal shape with a diameter of 15-25 cm. Throughout labor, the placenta is pulled off from the uterine wall and emerges about 30 minutes after the baby is born. A mature placenta consists of 18 to 28 “cotyledons” or lobes (47). Each cotyledon

is a perfusion chamber that is partially or completely separated from neighboring chambers by a connective tissue wall that may be lined by trophoblast cells. Blood flows into the chamber by one or more maternal spiral arteries. The fetal cotyledons are made up of one or more fetal villous trees containing a fetal artery and a vein that are suspended into the maternal cotyledon. The cotyledons and a small amount of decidua basalis covering the maternal placental side distinguish it from the foetal side. The placenta, in addition to removing metabolic and gaseous waste, allows for the exchange of nutrients, gases, and electrolytes, as well as the transmission of maternal antibodies and hormone production. A fetus that is fully developed requires approximately 20 to 30 mL of oxygen per minute, and any interruption in blood supply can have serious consequences. Because placental blood flow to the baby is extremely important, oxygen is delivered rather than diffused (48).

### **1.3.1 Development of Human Placenta**

The human placenta is a highly specialized temporary organ that begins developing from the blastocyst in the uterus. The blastocyst is constituted of an outer layer named trophoblast, known as the placenta's precursor, and an inner cell mass layer called embryoblast which forms the umbilical cord, the amnion and the embryo (49). The process by which the embryo adheres to the endometrial surface of the uterus and invades the epithelium and then the maternal circulation to form the placenta is known as "implantation". The uterus should be structurally and functionally remodeled in order to achieve a successful implantation; the master hormones mediating these changes are estrogen and progesterone (50).

Implantation, or nidation, is a process that lasts about 3 days and occurs in three stages: apposition, adhesion and invasion. In the first stage the blastocyst contacts the endometrial implantation site, while, in the second stage the trophoblast cells of the blastocyst attach to the receptive endometrial epithelium. It is only in the final stage that the invasive trophoblast cells cross the maternal epithelial basement membrane and invade the endometrial stroma (49,50).

The trophoblast cells drive the event of implantation during which time, cells of the embryoblast rearrange around two cavities, the yolk sac and the amnion (51). They both will form extraembryonic structures, but it is only the amnion that will persist throughout the duration of pregnancy. Furthermore, the trophoblast differentiates into cytotrophoblast and syncytiotrophoblast during implantation. The first one is a layer of mitotically active cells immediately around the yolk sac and the amnion; the latter is a non-mitotic mass of multinucleated cytoplasm which invades, during implantation, the surrounding stroma (51). Proteases activation digests the stromal components and allows the developing embryo to embed itself in the endometrium. By about the ninth day after ovulation, lacunae or spaces form within the syncytiotrophoblast, allowing the

implanted embryo to absorb nutrients and oxygen. Thus, the maternal blood provides nourishment for the developing embryo.

With further development and growth, the placenta, mostly known as the hemochorioendothelial placenta, begins to be formed with the resultant separation between the blood of the mother and the blood of the developing embryo (51). The reason why it is referred as hemochorioendothelial placenta is because only three layers are interposed between the maternal and the fetal blood: the fetal endothelial vessel of the placenta, the embryonic connective tissue and lastly the layer of trophoblasts.

In addition, the remaining trophoblast cells give rise to the chorion, the embryonic part of the placenta, which develops into the chorionic plate and lastly evolves into chorionic villi. Following implantation, the whole endometrium attains the term decidua due to endometrial histological changes. The developing trophoblasts induce changes in the endometrium, altering it to form the maternal portion of the placenta. Fibroblasts become more polygonal, enlarged and more active in protein synthesis and are now called “decidual cells”. The decidua develops into three different regions: decidua basalis, capsularis and parietalis. Chorionic villi develop most profusely from the decidua basalis, which becomes the placenta’s major portion (50,51). Exchange of nutrients, wastes, oxygen and carbon dioxide occurs between the embryonic blood in the chorionic villi outside the embryo, and maternal blood in the lacunae of the decidua basalis.

Chorionic villi of the developing placenta go through three different stages. The primary villi appear 2 days after implantation and are solid outgrowths of cytotrophoblasts that protrude into the syncytiotrophoblast and extend into lacunae containing maternal blood. Secondary chorionic villi begin to form after 15 days of embryonic development and grow into primary chorionic villi. They have a core of loose connective tissue which becomes vascularized by extensive capillary beds. Tertiary chorionic villi contain embryonic blood vessels that develop from mesenchymal cells in the loose connective tissue core. These blood vessels, after the third week of development, connect up with the vessels that developed in the chorion and begin to circulate embryonic blood. By the end of the first month of pregnancy, the placenta is formed by thousands of tertiary chorionic villi, each branching several times, providing an exceedingly large surface area for metabolite exchanges (50,51).

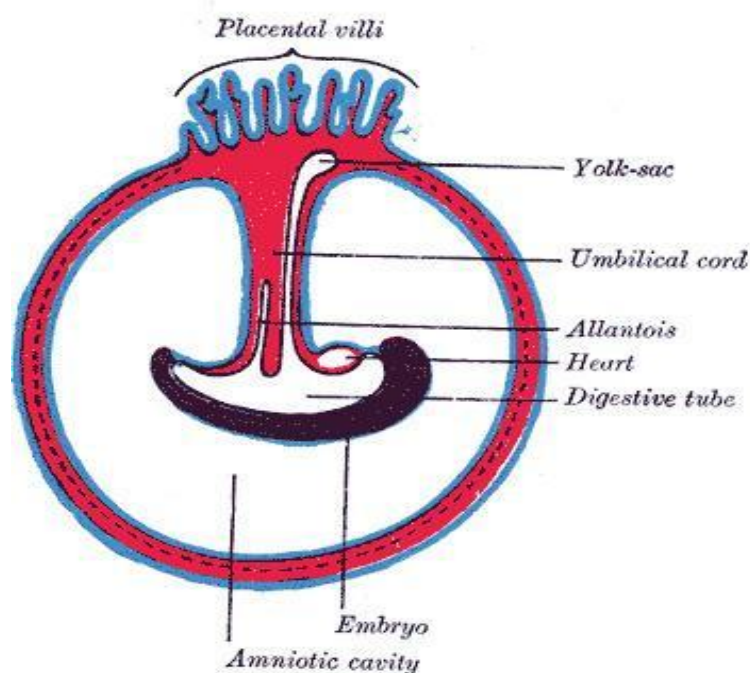
Consequently, maternal and fetal blood don’t intermix. Nutrients and oxygen from the maternal blood in the hemochorioendothelial placenta, diffuse through the cytotrophoblasts, connective tissue and endothelial cells of the capillaries of the villi to reach the fetal blood. These structures, together, make the placental barrier. Only certain substances such as water, oxygen, carbon dioxide, some proteins, some antibodies, some hormones and some lipids can penetrate the placental

barrier, whereas most of macromolecules cannot.

The placenta, in addition, serves as endocrine organ. Human chorionic gonadotrophin is the first hormone to be released from the developing placenta, along with estrogen and progesterone. Furthermore, the placenta is responsible for the production of human chorionic somatomammotropin hormone (also known as lactogenic hormone), prostaglandins, relaxin and various growth factors (50,51).

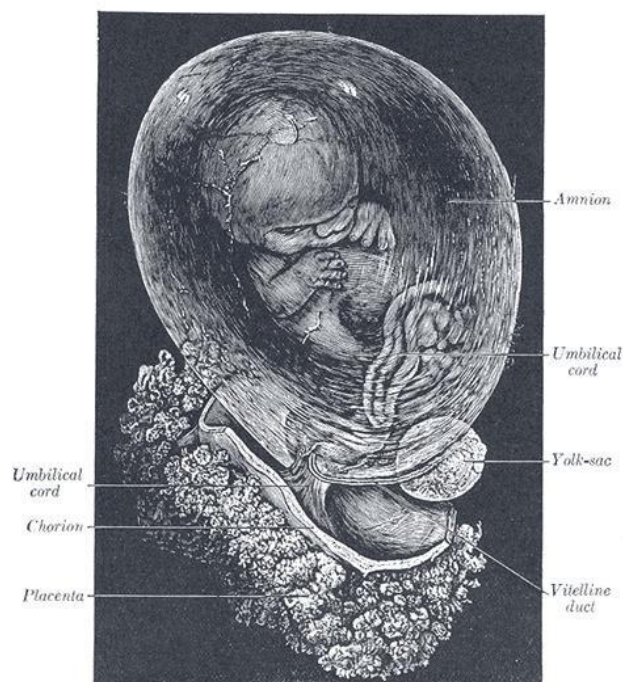
The formation of the umbilical cord starts in the 3<sup>rd</sup> week of embryologic development. The embryo that is slowly developing is composed of a trilaminar disc that is linked to the decidua basalis by a connecting stalk known as the primitive umbilical cord (52). The body folding process occurs in the fourth week of embryonic development, with the rapid growth of the amnion and the embryonic disc compared to the yolk sac.

Between the fourth and eighth weeks, the production of the amniotic fluid increases, as a result of which the amniotic cavity swells and fills the chorionic space (Figure 2). The increased amniotic fluid causes the connecting stalk to elongate, and the yolk sac is compressed down within the connecting stalk to form the omphalomesenteric or vitelline duct. The amniotic cavity expands, bringing the amnion and chorion together, and the extraembryonic mesoderm that covers these two layers fuses. Because of that, the chorionic cavity disappears, leaving the umbilical cord, which is made up of connecting stalk and vitelline duct and is surrounded by the amnion, floating in the amniotic fluid (52).



**Figure 2.** The formation of the Fetal membrane and the Placenta (52).

By the seventh week of development, the umbilical cord has fully formed. The umbilical vessels transport fetal blood back and forth to the placenta, with the umbilical vein carrying oxygenated blood with nutrients from the placenta to the fetus and the umbilical arteries carrying deoxygenated blood containing waste products from the fetus to the placenta (52). Close to the end of the first trimester, embryonic structures regress, leaving the umbilical cord characterized by two umbilical arteries and one umbilical vein surrounded by a gelatin-like extracellular matrix named as “Wharton's jelly”. This gelatinous substance, derived from extraembryonic mesoderm, keeps the umbilical cord from constricting and allows fetal movement within the amniotic cavity (Figure 3). Most of the umbilical cord's growth occurs in the second trimester. The average length of the umbilical cord measures 50 to 60 centimeters, and it is usually 2 centimeters wide, with up to 40 helical turns (52).



**Figure 3.** Development of the fetal membranes and placenta. Eight weeks old fetus, enclosed in the amnion, umbilical cord, chorionic, and placenta (52).

### 1.3.2 Pathological characteristics of placenta

Many of the following pathologies could appear in healthy and IVF + ET placentas.

#### 1.3.2.1 Maternal vascular malperfusion of the Placental Bed

Maternal vascular malperfusion (MVM) is a distinct pattern of placental injury caused by

changes in uterine and intervillous blood flow. MVM is a group of pathologic findings in the maternal decidual vessels that reflect abnormal spiral artery remodeling, as well as in the villous parenchyma, reflecting abnormalities in oxygenation in the intervillous space. Placental characteristics known to be indicative of MVM could include gross and microscopic findings (Figure 4). Placenta hypoplasia, infarction and retroplacental hemorrhage are part of the gross findings, while microscopic findings include distal villous hypoplasia and accelerated villous maturation (53).

Placental hypoplasia is characterized by a placental weight that is low for the stated gestational age and context (<10<sup>th</sup> centile) and/or a thin umbilical cord (<10<sup>th</sup> centile or <8mm diameter at term).

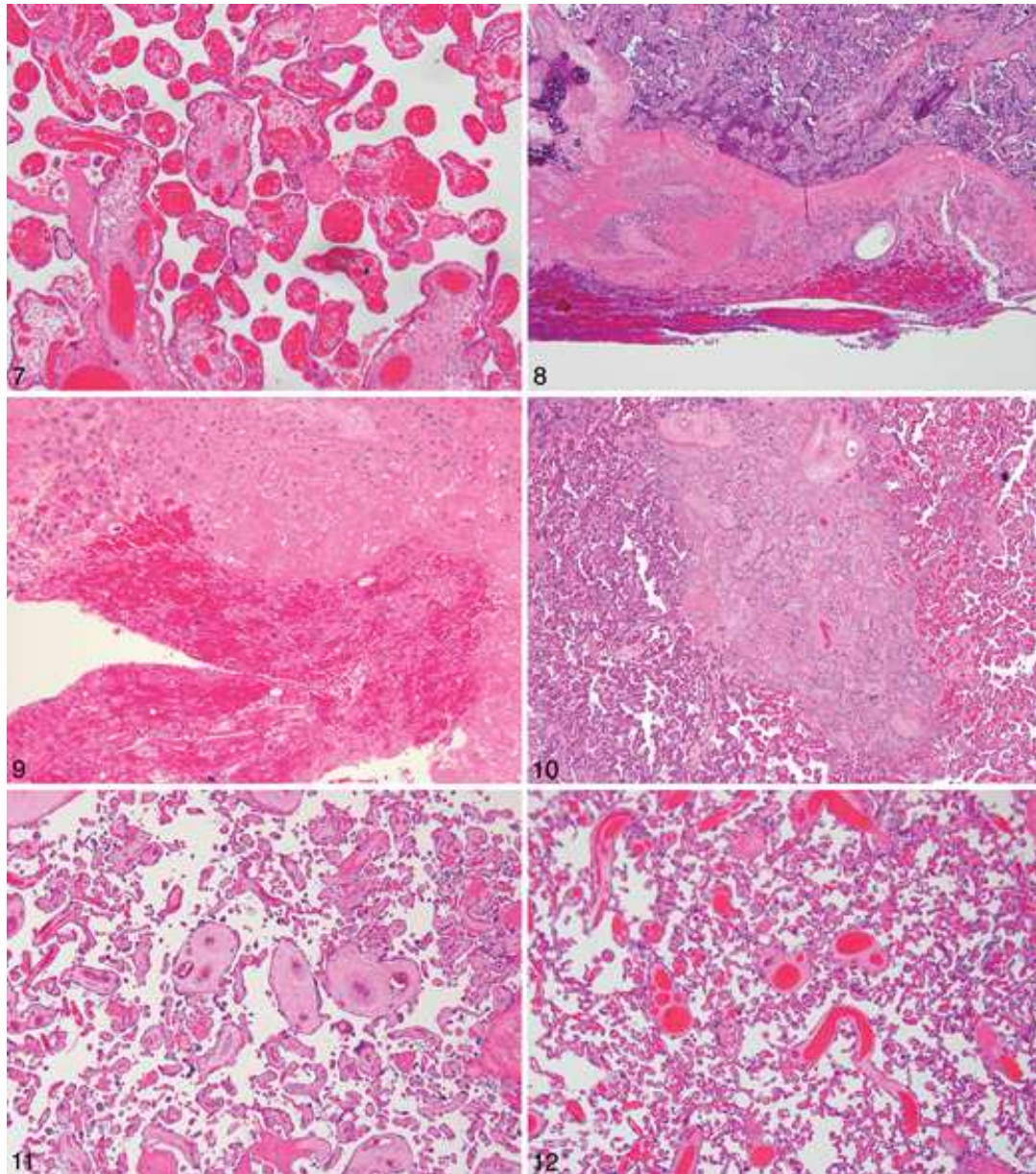
When the maternal decidual arterioles become occluded, most commonly by a thrombotic mass, placental infarction occurs. Placental infarction can take place in healthy term placentas with less than 5% parenchyma but also in severely diseased placentas with more parenchyma. Fetal hypoxia and even intrauterine fetal death have been associated with severe placental infarction. Infarcts can be recognised by their typical pyramidal shape and by the placenta's basal parenchyma involvement. A recent infarct is seen as crowding and congestion of villi, accompanied by early loss of stromal nuclear staining, while a remote infarct is distinguished by harder, brown-yellowish or white lesions (53).

Retroplacental hemorrhage occurs when there is perigestational hemorrhage that is confined to the retroplacental space. It is also part of the gross placental lesions and it is often associated with indentation of the placental parenchyma. Grossly, it is possible to observe accumulation of blood on the maternal surface, along with hemorrhage and/or congestion of the overlying parenchyma. Whereas, microscopically, it is possible to find accumulation of blood beneath and dissecting the decidua, compression of the intervillous space, and pale appearance of syncytiotrophoblast nuclei. Preeclampsia, hypertension, thrombophilia, cocaine, and cigarette smoking are the most common risk factors (54).

The paucity of villi in relation to the surrounding stem villi is known as distal villous hypoplasia (DVH). It is a type of placental villous maldevelopment that can result in significant intrauterine growth restriction, compromising fetal viability, neurodevelopmental outcomes, and adult cardiovascular health. The villi appear thin and elongated, with an increased number of syncytial knots. DVH is most often seen during early stage of pregnancy, before 32<sup>nd</sup> week of gestation. Thinning of the villous trophoblast layer, reduction in cytotrophoblast numbers, evidence of widespread increase in syncytiotrophoblast nuclear senescence, and wave-like syncytial knots are all common trophoblast abnormalities in distal villous hypoplasia (55).

Accelerated villous maturation, on the other hand, consists of a greater number of syncytial

knots and the presence of small or short hypermature villi for the gestational period. It could usually be present in mild, moderate or severe forms of placental insufficiency such as fetal growth restriction, preeclampsia and preterm labor. At the microscope, accelerated villous maturation, is recognized by the presence of term-appearing villi with increased number of syncytial knots and intervillous fibrin, alternating with areas of paucity (55).



**Figure 4.** Maternal vascular malperfusion (53). 7-Intravillous hemorrhage accompanying retroplacental hemorrhage. 8- Basal plate dissection in retroplacental haemorrhage. 9- As a crucial response to the retroplacental haemorrhage, neutrophils are produced. 10- The intervillous space in the centre of an early infarction is crowded and compressed, and the villi around its edge are congested. 11- Distal villous hypoplasia: the villi are thin and elongated. 12- Increased syncytial knots and intervillous fibrin deposition are present in areas with accelerated villous maturation.



### **1.3.2.2 Fetal vascular malperfusion (FMV)**

Fetal vascular malperfusion is the latest term used to describe a class of placental lesions characterized by diminished or absent fetal perfusion of the villous parenchyma. Fetal vascular malperfusion has been associated to a number of serious and sometimes fatal clinical outcomes, including intrauterine growth restriction, poor perinatal outcome, fetal death, and neurodevelopmental sequelae (56). The lesions described under this term are probably caused by obstruction in fetal blood flow, which could be brought on by a particular condition such as lesions in the umbilical cord, hypercoagulability and complication of fetal cardiac dysfunction. Pathological findings that can be observed are thrombosis, villous stromal vascular karyorrhexis and segmental avascular villi (56). Along with them, it is possible to observe vascular intramural fibrin depositions, vascular ectasia and stem vessel obliteration.

Umbilical cord lesions include abnormal insertion, length, hypertorsion, presence of true knots and velamentous umbilical cord insertion. Thrombosis of large fetal vessels in the placenta leads to the downstream formation of avascular villi and stem vessels obliteration. For this reason, the location of the thrombosis, and whether it is arterial or venous, must always be specified (53).

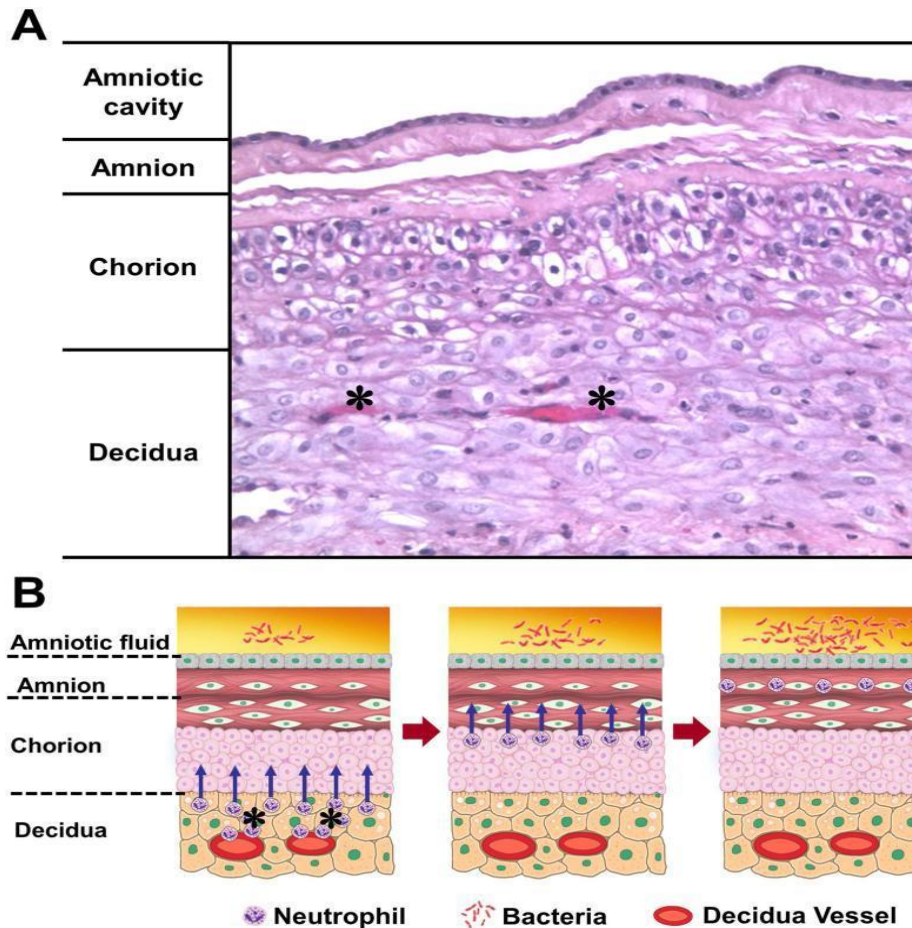
### **1.3.2.3 Villitis of unknown etiology (VUE)**

Villitis of unknown etiology is a common pattern of placental injury that occurs mostly in term placentas and it is a leading cause of intrauterine growth restriction and recurrent reproductive failure. By definition, cases with a known etiology, such as viral or acute infections, are excluded from VUE. Histological examination is used to make the diagnosis of VUE. Inflammatory cells, particularly histiocytes and lymphocytes, are identified microscopically. Inflammatory cell infiltration damages the villi vasculature, resulting in blood flow obliteration. Although similar to infectious villitis, VUE has distinct clinical and histologic features. It is a common lesion that affects 5% to 15% of all placentas and can be graded as low grade VUE whenever less than 10 contiguous villi are involved, or high grade VUE whenever multiple foci are present, showing inflammation in more than 10 contiguous villi. High grade VUE is usually associated with fetal growth restriction and neurodevelopmental impairment. Furthermore, low grade lesions could be referred as focal or multifocal whether the lesions are present in one slide or more slides, all foci affecting less than 10 contiguous villi. In addition, high grade lesions could also be categorized as patchy or diffuse (53).

#### **1.3.2.4 Acute inflammatory lesions**

The placenta consists of three major components: the placental disc, the chorioamniotic membranes, and the umbilical cord (57). Acute inflammatory lesions of the placenta are identified by neutrophil infiltration in each of these structures (Figure 5). When the inflammatory process affects the chorion and amnion, it is referred to as acute chorioamnionitis; when it affects the villous tree, it is referred to as acute villitis. On the other hand, funisitis, the histological counterpart of the fetal inflammatory response syndrome, occurs when the inflammatory process involves the umbilical cord (umbilical vein, umbilical artery, and Wharton's jelly).

While chorioamnionitis is evidence of a maternal host response, funisitis and chorionic vasculitis are part of the fetal inflammatory responses (57). The most common diagnosis in placental pathology reports is chorioamnionitis, which is thought to be an intrauterine infection or an amniotic fluid infection syndrome/sequence. Acute histologic chorioamnionitis and funisitis were previously thought to be caused only by intra-amniotic infection. However, new evidence suggests that "sterile" intra-amniotic inflammation, which occurs in the absence of demonstrable microorganisms, can be induced by "danger signals" and is frequently associated with these lesions. Furthermore, the fetal inflammatory response syndrome is characterized by an increase in fetal plasma interleukin-6 concentrations, which is associated with the impending onset of preterm labor, a higher rate of neonatal morbidity and multi-organ fetal involvement. This syndrome is similar to the systemic inflammatory response syndrome in adults. Nevertheless, it is a risk factor for short- and long-term complications in fetuses such as neonatal sepsis, bronchopulmonary dysplasia, periventricular leukomalacia, and cerebral palsy (57).



**Figure 5.** Migration of the neutrophils from decidual vessels into the chorioamniotic membranes (57). A-Normal histology of the chorioamniotic membranes, which are composed of amnion and chorion laeve. The decidua is adjacent to the chorion and contains maternal capillaries (black asterisk). Neutrophils migrate from the maternal circulation in the presence of chemotactic gradient (increased amniotic fluid neutrophil chemokine concentrations). B-Progression of neutrophils from the decidual vessels (in red) towards the amnion. The location of bacteria is within the amniotic cavity. Initially, neutrophils accumulate in the choriodecidual interface (B; left); however, in subsequent stages, invade the chorion (B, center) and amnion (B, right).

#### 1.4 Placental morphological characteristics of IVF + ET pregnancies

To this day, it is still unclear which extent of the observed placental alterations is due to ART and which originates from infertility. These two factors are most likely affecting together the morphological and histopathological characteristics of placentas from ART pregnancies. Data show that mechanisms of inappropriate trophoblast invasion and subsequent altered vascular remodeling sustain several clinical conditions common in in vitro fertilization pregnancies, including preeclampsia, fetal growth restriction, and placenta previa or accrete (58). Even in couples who

conceive naturally after a period of infertility, abnormal placentation is a frequent finding in the infertile population. These pregnancies have been found to have a higher risk of preterm birth (PTB) and low birth weight (LBW).

Furthermore, it is well known that ART can be linked to alterations in the morphology and structure of the placenta, as well as growth dynamics, imprinted and non-imprinted genes, and other factors affecting placentation. Several studies demonstrate that placentas from in vitro fertilization presented with a significantly greater weight and higher placental weight-to-birth weight ratio. Moreover, according to some observations, ART-achieved pregnancies result in placentas that are thicker and more likely to develop hematomas (58).

Pregnancies that result from IVF-ET carry a significantly higher risk of adverse outcomes compared to spontaneous conceived pregnancies due to suboptimal placentation (59). According to a number of meta-analyses and animal model studies, this phenomenon has been linked to both IVF-ET and the infertility diagnosis. Early trophoblast migration, cell fusion, tissue remodeling, immune tolerance, metabolism, and extracellular matrix degradation are significant events that contribute to early placental implantation. Studying the effects of IVF-ET on first-trimester placental gene expression is especially important because these trophoblast properties vanish at the end of pregnancy (59).

The interpretation of ARTs' effects on pregnancy and any associated pathologies is complicated by the recipient's supraphysiological hormonal levels as a result of the ovarian stimulation therapy. Increased hormone blood levels may influence the timing of endometrial receptivity, which could result in suboptimal embryo implantation and development. Additionally, studies using animal models raised the possibility that high estrogen levels have a negative impact on the trophoblast's ability to remodel the spiral artery (58).

Furthermore, a study conducted on 26 women patients whose pregnancies resulted from IVF with a donor egg (surrogate motherhood), showed major placental morphological changes (60). Histological examination of the placenta revealed a high prevalence of central ischemic infarctions (69% of cases), dissociated cotyledon development (61%), pathological villus immaturity (46%), and massive perivillous fibrin deposition (73%). Along with an apparent inflammatory process at the placental sites, this group also had a marked lymphoplasmacytic deciduitis which was 2 times higher than in the control group. In addition, the immune pathogenesis is associated with an increase in the number of HLA-DR positive cells, defects in spiral arteries remodeling, development of areas of chronic inflammation in perivascular regions, and a decrease in the number of multinucleated cells (60).

## **2. OBJECTIVES**

## **2.1 Objectives**

The purpose of this study was to identify the most common features and morphological characteristics of placentas from assisted reproductive technology (IVF + ET) pregnancies.

## **2.2 Hypothesis**

Based on the findings of previous conducted studies we wanted to hypothesize that low placental weight, together with fetal and maternal inflammatory response, would be one of the most common characteristics of placentas from assisted reproductive technology. Furthermore, we expected an increased number of preterm deliveries and reduced birth weight.

### **3. MATERIALS AND METHODS**

### **3.1 Study Design**

This retrospective observational cohort study was conducted at the Pathology department of the University Hospital Center of Split. The data were collected from the period of January 1<sup>st</sup> 2016 until December 31<sup>st</sup> 2020.

### **3.2 Materials and data collection**

The study included placentas from IVF+ET pregnancies that were delivered at the Department of Gynecology and Obstetrics at University Hospital center of Split, and pathohistological analysis was done at the Pathology department of the same hospital. From the database of the Gynecology department, the following was noted: maternal age, gestational week, newborn gender and birth weight. From the Pathology department database, morphological characteristics of studied placentas were noted. Inclusion criteria were all of the placentas from IVF+ET pregnancies in the above-mentioned time period. Exclusion criteria were placentas from pregnancies that weren't IVF+ET and with insufficient data.

### **3.3 Methods of data processing**

After the data from the Gynecology and Pathology department was collected, it was processed into tables. Additional analysis was made with the aid of Microsoft Excel and Microsoft Word processing software.

### **3.4 Statistical analysis**

The normality of distributions was tested using a Kolmogorov-Smirnov test. The mean and standard deviation were used as the measures of central tendency and variance for normally distributed data, whereas the median and interquartile range were used for data that was not normally distributed. All data were analyzed using MedCalc Statistical Software version 19.1.2 (MedCalc Software, Ostend, Belgium; [medcalc.org](http://medcalc.org); 2019, RRID:SCR\_015044).  $P < 0.05$  was considered to indicate a statistically significant difference.

### **3.5 Ethical committee approval**

The present study was approved by the Hospital Ethics Committee of the University Hospital Center in Split, Croatia (approval no. 2181-147-01/06/M.S.-22-02), and was performed in accordance with the ethical standards described in the 1964 Declaration of Helsinki and its later amendments.



## **4. RESULTS**

The study included 54 placentas from IVF+ET pregnancies that were analyzed at Pathology Department, University Hospital Center Split, in the time period from January 1<sup>st</sup> 2016 until December 31<sup>st</sup> 2020.

There were 36 (66.7%) twin placentas, all of them were dichorionic diamniotic placentas, and 18 (33.3%) placentas from singleton pregnancies. The average age of the mother at the time of delivery was 34 years. Most of the placentas were from preterm delivery with the median of 36 gestational weeks. 77.8% of newborns were males, which was statistically significant ( $\chi^2=5.5$ ;  $P=0.019$ ). The median of birth weight was 2370 grams. Demographic data are demonstrated in Table 1.

**Table 1.** Demographic data

Parameters	Measurements
Maternal age (years)	34 ± 3.5
Gestational age (weeks)	36 (27-40)
Gender M:F	42:12
Birth weight (grams)	2370 (1410-3410)

On gross examination median placental weight was 406 grams with diameter of 16.7 cm, while average placental thickness was 2.5 cm. The most common site of umbilical cord insertion was eccentric (79.6%), followed by central (14.8%) and velamentous insertion (5.6%), which was statistically significant ( $\chi^2=52.778$ ;  $P<0.001$ ). Average umbilical cord length was 35.5 cm with median diameter of 1.1 cm.

Gross morphological placental characteristics are presented in Table 2.

**Table 2.** Gross morphological findings of studied placentas

Parameters	Measurements
Placental weight (grams)	406 (201-793)
Largest placental diameter (cm)	16.7 (10-27)
Placental thickness (cm)	2.5 ± 0.6
Umbilical cord insertion:	
Central	8 (14.8%)
Eccentric	43 (79.6%)
Velamentous	3 (5.6%)
Umbilical cord length (cm)	35.5 ± 11.7
Umbilical cord diameter (cm)	1.1 (1-2)
Umbilical cord coiling index	0.21 (0-1.5)

Histological analysis revealed several placental lesions that were grouped into seven categories as demonstrated in Table 3.

**Table 3** Placental pathology in studied placentas

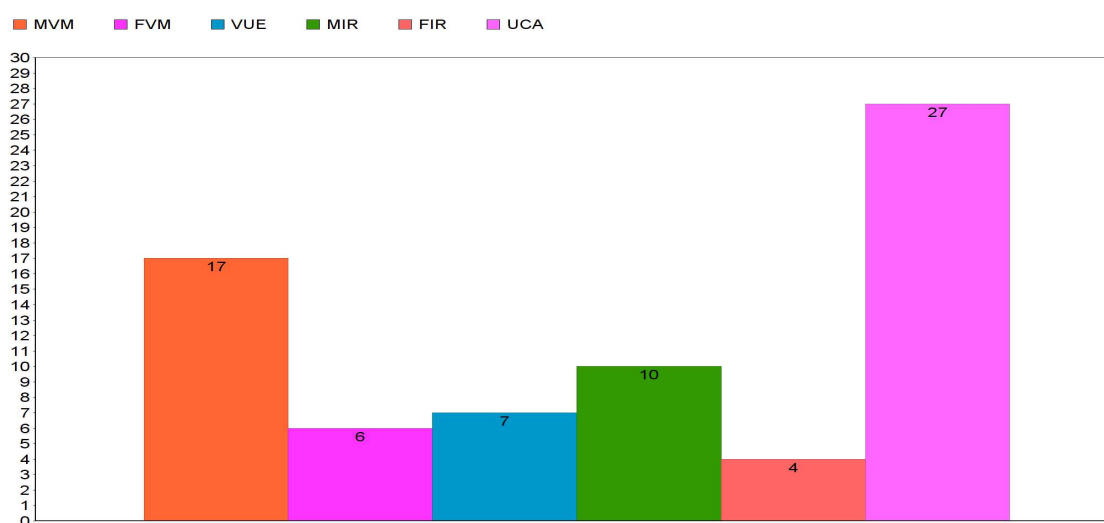
Pathology	N (%)	<i>P</i>
Maternal vascular malperfusion*	7 (13%)	
Fetal vascular malperfusion*	0	
Villitis of unknown etiology*	2 (3.7%)	0.001†
Maternal inflammatory response*	3 (5.6%)	
Fetal inflammatory response*	0	
Umbilical cord abnormalities*	9 (16.7%)	
Multiple lesions	20 (37%)	
No placental lesions	13 (29.1%)	

\*Isolated lesions without other placental lesions

†Chi-square test

The most common placental findings in studied placentas were multiple placental lesions which were noted in 20 placentas, isolated fetal vascular malperfusion or fetal inflammatory lesions weren't noted. The multiple placental lesions were statistically significant ( $\chi^2=25.111$ ;  $P=0.001$ ). Among the multiple lesions, the most common were a combination of inflammatory lesions and umbilical cord abnormalities, or umbilical cord abnormalities with maternal vascular malperfusion.

Detailed analysis of each placental lesion, whether it occurred as an isolated event, or as a part of multiple pathologies was also done (Figure 6).



**Figure 6.** The frequency of placental lesions.

MVM= Maternal vascular malperfusion; FVM= Fetal vascular malperfusion; VUE= villitis of unknown etiology; MIR= Maternal inflammatory response; FIR= fetal inflammatory response; UCA= umbilical cord abnormalities. Maternal vascular malperfusion was noted in 17 (31.5%) placentas, the most common type of MVM was abnormal villous maturation (78.9%), followed by retroplacental hematoma (10.5%), placental infarction and intervillous thrombosis (5.3%). Fetal vascular malperfusion was found in 6 (11.1%) placentas, 4 (66.7%) were of high grade. There were 7 (13%) placentas with villitis of unknown etiology, 4 were VUE low grade, and 3 had VUE high grade. Maternal inflammatory response was found in 10 (18.5%) placentas. In 4 of them MIR was classified as mild, 3 placentas had moderate MIR, and the same number had severe MIR. Fetal inflammatory response in 4 (7.4%) placentas, 3 of them had mild FIR, and one had severe FIR. Umbilical cord abnormalities were noted in 27 (50%) placentas, there were 21 hypertorsions, 4 hypotorsions and 2 true knots.

## **5. DISCUSSION**

Secondary to infertility, In Vitro Fertilization is the most common procedure performed worldwide. This specific kind of assisted reproductive technology, along with fresh embryo transfer, has been used to help women conceive in the University Hospital of Split. In our study we investigated the morphological characteristics of 54 placentas from IVF + ET pregnancies delivered at the Department of Gynecology and Obstetrics of the University Hospital center of Split, in a four years span from January 1<sup>st</sup> 2016 until December 31<sup>st</sup> 2020.

According to the findings of our study there is a preponderance of dizygotic placentas (66.7%), with all of them belonging to the dichorionic and diamniotic type. In the last decades, the average age at which women decide to have children has increased. Because of that, the average age of women undergoing IVF using their own eggs or embryos is 36 years old. Women who use donated eggs or embryos are on average 40.8 years old (61). According to our findings, the average age of the mothers at the time of birth is less than the above-mentioned values, since women gave birth at an average age of 34 years old. In addition, while our findings show that the majority of newborns (77,8 %) belonged to male gender, none of the studies conducted by researchers can provide precise information regarding a male gender predominance in IVF+ET pregnancies.

Existing literature and researches concluded that women that become pregnant through in vitro fertilization and embryo transfer technique, compared to those that conceive spontaneously, have a significantly higher risk for spontaneous pre-term delivery (42). Correspondingly, our findings suggest that the majority of placentas that were taken into consideration in our study belong to pre-term births, with a median of 36 gestational weeks. Furthermore, literature claims that spontaneous twin pregnancies account for 2% of all pregnancies and, due to uterine over distension, they are associated with prematurity (62). Generally, mothers having twins give birth before the 37<sup>th</sup> week of pregnancy. Considering the prevalent number of multiple pregnancies in our study, it is difficult to determine whether the real cause of pre-term delivery is due to twin pregnancies in general or to in vitro fertilization in particular.

Additionally, low birth weight, defined by the WHO as a newborn weighing less than 2500 grams or 5.5 pounds, has also been strongly associated with in vitro fertilization. Along with pre-term delivery, a further relevant outcome from our demographic data shows that the birthweight median value corresponds to 2370 grams, indicating a prevalence of low-birth-weight-infants. Nevertheless, there is insufficient evidence to determine whether the neonates have a low birth weight value without considering if at the time of birth, they weigh less than the 10<sup>th</sup> percentile for their gestational age. Additionally, the usual term placenta is about 22 cm in diameter and 2.0 to 2.5 cm thick. It generally weighs approximately 470 grams (63). On the contrary, the gross examination of our placentas

revealed a reduced average placental weight (406 grams) and diameter (16,7cm). However, the average placental thickness (2,5cm) was in line with the usual term placental values mentioned above.

The most common site of umbilical cord insertion was eccentric (76%), followed by central and velamentous insertion. Furthermore, an interesting finding of our study, which was also unexpected and not yet assessed nor reflected in previous studies, was the reduced average length of the umbilical cord. Literature states that the ideal average umbilical cord length is 55 cm long, with a 1-2 cm diameter. On the contrary, our results show an average umbilical cord length of 35,5 cm with median diameter of 1,1 cm, which can pose a risk for numerous delivery complications and birth injuries. The most serious complication of a short umbilical cord is placental abruption, a condition in which the mother's placenta pulls away from the uterus resulting in a severe life-threatening maternal bleeding (64). This condition usually necessitates an emergency C-section to save the child from experiencing dangerous oxygen deprivation and permanent brain damage. Short umbilical cords have also been related with decreased utero fetal movement, fetal distress, depressed Apgar scores, low birth weight and psychomotor abnormalities (64).

Placental characteristics considered to be indicative of MVM could include gross and microscopic findings. Each placental lesion was thoroughly examined, regardless of whether it appeared as an individual and per se lesion or as a result of multiple pathologies. A wide range of placental lesions were identified through histological analysis, with multiple lesions being the most common among the classified categories. The results show that there was not a significant finding when looking at the isolated maternal vascular malperfusion lesions.

On the other hand, with further results investigation, it is possible to assert that whenever combined with multiple lesions, MVM was noted in 31.5% of the samples (17 placentas). The most common type of MVM was abnormal villous maturation (78,9%), followed by retroplacental hematoma (10,5%), placental infarction and intervillous thrombosis (5, 3%). As a consequence, the most common multiple lesions identified during the pathohistological analysis were maternal vascular malperfusion combined with umbilical cord abnormalities or inflammatory lesions and umbilical cord abnormalities. Thereby, it was observed that 50% of the placentas presented with abnormalities of the umbilical cord, 21 being UC hyperstorsions, 4 hypotorsions and 2 true knots.

Likewise, when looking and the isolated fetal vascular malperfusion there was not a significant finding, but when combined to multiple lesions, FVM was observed in 6 placentas (11.1%), 4 of which presented with a high-grade pattern.

Villitis of unknown etiology, a common pattern of placental injury that mostly affects term placentas, is an etiologically unknown condition that is a major contributor to intrauterine growth

restriction and recurrent reproductive failure. VUE, by definition, excludes all cases with a known etiology, such as viral or acute infections. In our study, VUE is noted in 7 placentas, 4 of which are characterized by high grade VUE and the remaining 3 were low grade ones.

Maternal and fetal inflammatory responses are important findings that can lead to fetal and neonatal morbidity and mortality. While chorioamnionitis is evidence of a maternal host response, funisitis and chorionic vasculitis are part of the fetal inflammatory responses. Results indicate that 10 placentas (18.5 %) presented with maternal inflammatory response. In particular, 4 samples had mild MIR, 3 placentas had moderate MIR, and the same remaining number had severe MIR. In addition, there appears to be a fetal inflammatory response in 4 placentas, 3 of them having mild FIR, and one having severe FIR.

Despite the fact that our findings were in accordance with other researches that had the purpose to investigate the morphological features of IVF+ET placentas, our study presented some limitations. As a matter of fact, we didn't have at our disposal a great sample size, which might have reduced the power of our study by making it difficult to determine if a particular outcome is a true finding. Moreover, the inclusion of a control group would have strengthened the outcomes of our study and would have improved the ability to draw conclusions. Unfortunately, since the majority of ARTs pregnancies have pre-term delivery as an adverse outcome, finding healthy women with idiopathic pre-term delivery as a control group was very complicated, giving the limited amount of participants in the population. For this reason, all of the idiopathic pre-term delivered placentas, which could match in gestational age, could be collected and used for the purpose of a brand new prospective study.



## **6. CONCLUSION**

The mechanism underlying the potential risks of in vitro fertilization and embryo transfer has been investigated by different researchers but remains to be fully elucidated. The current findings of our study highlight that assisted reproductive technologies can ultimately affect the placental development and its function in utero.

According to the pathohistological analysis, the most important and relevant finding in the IVF+ET placentas was the presence of multiple lesions. The most prominent were combined umbilical cord abnormalities and maternal vascular malperfusion. Additionally, results suggest that the most common type of MVM observed was abnormal villous maturation. Another noteworthy finding was a reduced umbilical cord length average, which could be associated with fetal distress and delivery complications. Further research is required to reveal the exact reasons for morphological abnormalities in the IVF+ET placentas, in order to reduce their potential harm on the mother and the baby.

## **7. REFERENCES**

1. Infertility [Internet]. Who.int. [cited 2022 Jun 7]. Available from: <https://www.who.int/news-room/fact-sheets/detail/infertility>
2. Sharma R. S., Saxena R., Singh R. Infertility & assisted reproduction: A historical & modern scientific perspective. *Indian J Med Res.* 2018;148:10-4.
3. Taebi M, Kariman P, Montazeri A, Majd H A. Infertility Stigma: A Qualitative Study on Feelings and Experiences of Infertile Women. *Int J Fertil Steril.* 2021;15:189-96.
4. Fu B, Qin N, Cheng L, Tang G, Cao Y, Yan C, et al. Development and validation of an infertility stigma scale for chinese women. *J Psychosom Res.* 2015;79:69-75.
5. van Leeuwenhoek A, Observationes D, Leeuwenhoek A. *de natis e` semine genital animalculis. Philos Trans R Soc Lond* 1678; 12:1040-3.
6. Crawford NM, Steiner AZ. Age-related Infertility. *Obstetrics and Gynecology Clinics of North America.* 2015;42:15–25.
7. George K, Kamath M. Fertility and age. *Journal of Human Reproductive Sciences.* 2010;3:121.
8. Dunson DB, Colombo B, Baird DD. Changes with age in the level and duration of fertility in the menstrual cycle. *Hum Reprod.* 2002;17:1399–403.
9. Ravel J, Moreno I, Simón C. Bacterial vaginosis and its association with infertility, endometritis, and pelvic inflammatory disease. *Am J Obstet Gynecol.* 2021;224(3):251–7.
10. Pasquali R, Patton L, Gambineri A. Obesity and infertility. *Curr Opin Endocrinol Diabetes Obes.* 2007;14:482–7.
11. Van Voorhis B, Dawson J, Stovall. The effects of smoking on ovarian function and fertility during assisted reproduction cycles. *Obstet Gynecol* 88,785;1996.
12. Male Infertility Statistics and fast Facts [Internet]. RMA Network - Fertility Clinic. 2019 [cited 2022 Jun 14]. Available from: <https://rmanetwork.com/blog/male-infertility-cases-and-statistics/>
13. Poppe K. Management of endocrine disease: Thyroid and female infertility: more questions than answers?! *European Journal of Endocrinology.* 2021 Apr;184(4): R123–35.
14. Verma I, Sood R, Juneja S, Kaur S. Prevalence of hypothyroidism in infertile women and evaluation of response of treatment for hypothyroidism in infertility. *Int J Appl Basic Med.* 2012;2:17.
15. Orsu P, Koyyada A. Role of hypothyroidism and associated pathways in pregnancy and infertility: Clinical insights. *Tzu Chi Medical Journal.* 2020;32(4):312.
16. Zollner U, Lanig K, Steck T, Dietl J. Assessment of endocrine status in patients undergoing in-vitro fertilization treatment. *Archives of Gynecology and Obstetrics.* 2001 Mar 13;265(1):16–20.

17. Briceag I, Costache A, Purcarea VL, Cergan R, Dumitru M, Briceag I, et al. Fallopian tubes--literature review of anatomy and etiology in female infertility. *Journal of Medicine and Life* [Internet]. 2015 Apr 1;8(2):129–31.
18. Briceag I, Costache A, Purcarea VL, et al. Fallopian tubes--literature review of anatomy and etiology in female infertility. *J Med Life*. 2015;8(2):129-131.
19. Burney RO, Giudice LC. Pathogenesis and pathophysiology of endometriosis. *Fertil Steril*. 2012;98(3):511-519.
20. Macer ML, Taylor HS. Endometriosis and infertility: a review of the pathogenesis and treatment of endometriosis-associated infertility. *Obstet Gynecol Clin North Am*. 2012;39(4):535-549.
21. Ferguson BR, Bennington JL, Haber SL. Histochemistry of mucosubstances and histology of mixed mullerian pelvic lymph node glandular inclusions. Evidence for histogenesis by mullerian metaplasia of coelomic epithelium. *Obstetrics and gynecology*. 1969;33(5):617–625.
22. Steele RW, Dmowski WP, Marmar DJ. Immunologic aspects of human endometriosis. *American journal of reproductive immunology: AJRI : official journal of the Americans Society for the Immunology of Reproduction and the International Coordination Committee for Immunology of Reproduction*. 1984;6(1):33–36.
23. Mayo Clinic. Female infertility - Symptoms and causes [Internet]. Mayo Clinic. 2018. Available from: <https://www.mayoclinic.org/diseases-conditions/female-infertility/symptoms-causes/syc-20354308>
24. Tsevat DG, Wiesenfeld HC, Parks C, Peipert JF. Sexually transmitted diseases and infertility. *American Journal of Obstetrics and Gynecology* [Internet]. 2017 Jan;216(1):1–9. Available from: <https://www.sciencedirect.com/science/article/pii/S0002937816305737>
25. Kikuchi K, Shibahara H, Hirano Y, Kohno T, Hirashima C, Suzuki T, Takamizawa S, Suzuki M (2003) Antinuclear antibody reduces the pregnancy rate in the first IVF-ET treatment cycle but not the cumulative pregnancy rate without specific medication. *Am J Reprod Immunol* 50:363–367.
26. Deroux A, Dumestre-Perard C, Dunand-Faure C, Bouillet L, Hoffmann P. Female Infertility and Serum Auto-antibodies: a Systematic Review. *Clin Rev Allergy Immunol*. 2016 Sep 14;53(1):78–86.
27. Naz RK, Menge AC. Antisperm antibodies: origin, regulation, and sperm reactivity in human infertility. *Fertil Steril*. 1994 Jun;61(6):1001-13.
28. Gravholt CH, Viuff MH, Brun S, Stochholm K, Andersen NH. Turner syndrome: mechanisms and management. *Nat Rev Endocrinol*. 2019 Oct;15(10):601-14.

29. Rudnicka E, Kruszewska J, Klicka K, Kowalczyk J, Grymowicz M, Skórska J, et al. Premature ovarian insufficiency–aetiopathology, epidemiology, and diagnostic evaluation. *Menopausal Review*. 2018;17(3):105–8.
30. Nugent C. What It Was Like to Grow Up as the World’s First “Test-Tube Baby” [Internet]. *Time*. Time; 2018. Available from: <https://time.com/5344145/louise-brown-test-tube-baby/>
31. Van Voorhis B J. In Vitro Fertilization. *N engl j med*. 2007;356:379-86.
32. Fauser BCJM. Towards the global coverage of a unified registry of IVF outcomes. *RBMO*.2019;38:133-7.
33. CDC. ART Success Rates (ART) Data [Internet]. Centers for Disease Control and Prevention. 2019. Available from: <https://www.cdc.gov/art/artdata/index.html>
34. Jain M, Singh M. Assisted Reproductive Technology (ART) Techniques. [Updated 2021 Dec 4]. In: *StatPearls* [Internet]. Treasure Island (FL): StatPearls Publishing; 2022. Available from: <https://www.ncbi.nlm.nih.gov/books/NBK576409/>
35. IVF (In Vitro Fertilization): Procedure & How It Works [Internet]. Cleveland Clinic. Available from: <https://my.clevelandclinic.org/health/treatments/22457-ivf>
36. Gardner DK, Schoolcraft WB, Wagley L, Schlenker T, Stevens J, Hesla J. A prospective randomized trial of blastocyst culture and transfer in in-vitro fertilization. *Hum Reprod*. 1998 Dec;13(12):3434-40.
37. Embryo Transfer. 29 november 2016, [Internet]. [www.ivf-embryo.gr](http://www.ivf-embryo.gr). 2016. Available from: <http://www.ivf-embryo.gr/en/ivfassisted-reproduction/embryo-transfer>
38. Fertility CNY. Fresh and frozen embryo transfers [Internet]. CNY Fertility. 2021 [cited 2022 Jun 7]. Available from: <https://www.cnyfertility.com/fresh-vs-frozen-embryo-transfer/>
39. Johnson J. Embryo transfers: What you need to know [Internet]. *Medicalnewstoday.com*. 2016 [cited 2022 Jun 7]. Available from: <https://www.medicalnewstoday.com/articles/314571>
40. Kahnberg A, Enskog A, Brännström M, Lundin K, Bergh C. Prediction of ovarian hyperstimulation syndrome in women undergoing in vitro fertilization. *Acta Obstet Gynecol Scand* [Internet]. 2009;88(12):1373–81
41. Medical Advisory Secretariat. In vitro fertilization and multiple pregnancies: an evidence-based analysis. *Ont Health Technol Assess Ser* [Internet]. 2006 [cited 2022 Jun 7];6(18):1–63. Available from: <https://pubmed.ncbi.nlm.nih.gov/23074488/>
42. Sullivan-Pyke CS, Senapati S, Mainigi MA, Barnhart KT. In Vitro fertilization and adverse obstetric and perinatal outcomes. *Semin Perinatol* [Internet]. 2017;41(6):345–53. Available from: <http://dx.doi.org/10.1053/j.semperi.2017.07.001>

43. Kondapalli LA, Perales-Puchalt A. Low birth weight: is it related to assisted reproductive technology or underlying infertility? *Fertil Steril* [Internet]. 2013 [cited 2022 Jun 7];99(2):303–10. Available from: <http://dx.doi.org/10.1016/j.fertnstert.2012.12.035>
44. Yanaihara A, Hatakeyama S, Ohgi S, Motomura K, Taniguchi R, Hirano A, et al. Difference in the size of the placenta and umbilical cord between women with natural pregnancy and those with IVF pregnancy. *J Assist Reprod Genet* [Internet]. 2018 [cited 2022 Jun 7];35(3):431–4. Available from: <http://dx.doi.org/10.1007/s10815-017-1084-2>
45. Gorgui J, Bérard A. Medically Assisted Reproduction and the Risk of Adverse Perinatal Outcomes [Internet]. [www.intechopen.com](http://www.intechopen.com). IntechOpen; 2018 [cited 2022 Jan 27]. Available from: <https://www.intechopen.com/chapters/63784>
46. Baergen RN. *Manual of Benirschke and Kaufmann's Pathology of the Human Placenta*. New York: Springer; 2005.
47. Fahmy M. *Umbilicus and umbilical cord*. Cairo: Springer; 2018. p. 47-85.
48. Sadler TW. *Langman's medical embryology text & atlas*. 15<sup>th</sup> ed. Philadelphia: Wolters Kluwer 2019. p.117-47
49. Kim S-M, Kim J-S. A Review of Mechanisms of Implantation. *Development & Reproduction* [Internet]. 2017 Dec;21(4):351–9. Available from: <https://www.ncbi.nlm.nih.gov/pmc/articles/PMC5769129/>
50. Mescher A.L. *Junqueira's Basic Histology Text and Atlas*. 13<sup>th</sup>ed. New York City: Mc Graw Hill Education, 2016. 467-470p.
51. Gartner L.P. *Textbook of Histology*. 14<sup>th</sup>ed. Philadelphia: Elsevier, 2017. 549-551p.
52. Heil JR, Bordoni B. *Embryology, Umbilical Cord* [Internet]. PubMed. Treasure Island (FL): StatPearls Publishing; 2022. Available from: <https://www.ncbi.nlm.nih.gov/books/NBK557490/>
53. Khong TY, Mooney EE, Ariel I, Balmus NCM, Boyd TK, Brundler MA, et al. Sampling and definitions of placental lesions Amsterdam placental workshop group consensus statement. *Arch Pathol Lab Med*. 2016; 140:698-713.
54. Bendon RW. Retroplacental Haemorrhage and Marginal Haemorrhage. *Pathology of the Placenta*. 2018 Dec 22;83–90.
55. Fitzgerald B, Kingdom J, Keating S. Distal villous hypoplasia. *Diagnostic Histopathology*. 2012 May;18(5):195–200.
56. Heider A. Fetal Vascular Malperfusion. *Archives of Pathology & Laboratory Medicine*. 2017 Nov;141(11):1484–9.

57. Kim C, Romero R, Chaemsaihong P, Chaiyasit N, Yoon B, Kim Y. Acute chorioamnionitis and funisitis: definition, pathologic features, and clinical significance. *American Journal of Obstetrics and Gynecology*. 2015;213(4): S29-S52
58. Manna, C., Lacconi, V., Rizzo, G., De Lorenzo, A. and Massimiani, M., 2022. Placental Dysfunction in Assisted Reproductive Pregnancies: Perinatal, Neonatal and Adult Life Outcomes. *International Journal of Molecular Sciences*, 23(2), p.659.
59. Zhao, L., Zheng, X., Liu, J. *et al.* The placental transcriptome of the first-trimester placenta is affected by in vitro fertilization and embryo transfer. *Reprod Biol Endocrinol* 17, 50 (2019). <https://doi.org/10.1186/s12958-019-0494-7>
60. Kogan, E., Rudenko, E., Demura, T., Zharkov, N., Trifonova, N., Zhukova, E., Aleksandrov, L. and Bayanova, S., 2019. Structural, immunohistochemical and molecular features of placentas and placental sites after in vitro fertilization with donor eggs (surrogate motherhood). *European Journal of Obstetrics & Gynecology and Reproductive Biology*, 238, pp.68-72.
61. OBGYN M. Gynaecologist Brisbane [Internet]. Gynaecologist Brisbane 2018. Available from: <https://www.my-obgyn.com.au/blog/2018/10/23/am-i-too-old-for-ivf>
62. Franca, M. S., Hamamoto, T. E. N. K., Moron, A. . Preterm Birth in Twins. In: Jr., J. E. editor. *Multiple Pregnancy - New Challenges* [Internet]. London: IntechOpen; 2018.
63. Joseph F. Yetter I. Examination of the Placenta. *American Family Physician* [Internet] 1998 Mar 1;57(5):1045–54. Available from: <https://www.aafp.org/pubs/afp/issues/1998/0301/p1045.html>
64. Short Umbilical Cord causes and LongTerm Effects [Internet]. Reiter & Walsh



## **8. SUMMARY**

**Objectives:** the purpose of this study was to identify the most common features and morphological characteristics of placentas from assisted reproduction technology (IVF + ET) pregnancies. We hypothesize that low placental weight, together with fetal and maternal inflammatory response, would be one of the most common characteristic of placentas from assisted reproductive technology. Furthermore, we expected an increased number of preterm deliveries and reduced birth weight.

**Materials and methods:** This retrospective observational cohort study was conducted at the pathology department of the University Hospital Center of Split. The data were collected from the period of January 1<sup>st</sup> 2016 until December 31<sup>st</sup> 2020. The study included placentas from IVF+ET pregnancies that were delivered at the Department of Gynecology and Obstetrics at University Hospital center of Split, and pathohistological analysis was done at the Pathology department of the same hospital. From the database of Gynecology department, the following was noted: maternal age, gestational week, newborn gender and birth weight. From the Pathology department database, morphological characteristics of studied placentas were noted. Inclusion criteria were all of the placentas from IVF+ET pregnancies in the above-mentioned time period. Exclusion criteria were placentas from pregnancies that weren't IVF+ET and with insufficient data.

**Results:** From the 54 placentas from IVF+ET pregnancies that were analyzed, 36 appeared to be of the dichorionic diamniotic kind. The average age of the mother at the time of delivery was 34 years and most of the placentas were from preterm delivery with a median of 36 gestational weeks. Furthermore, a predominance of male gender was noted (77.8% male newborns). On gross examination median placental weight was 406 grams with a diameter of 16,7 cm, while average placental thickness was 2,5 cm. The most common site of umbilical cord insertion was eccentric (79.6%), followed by central and velamentous insertion. An interesting finding of our study was the reduced average length of the umbilical cord. In addition, the results show that there was not a significant finding when looking at the isolated maternal or fetal vascular malperfusion. On the other hand, with further results investigation, it is possible to assert that whenever combined with multiple lesions, MVM was noted in 31.5% of the samples (17 placentas). The most common type of MVM was abnormal villous maturation (78.9%), followed by retroplacental hematoma (10.5%), placental infarction and intervillous thrombosis (5.3%).

**Conclusion:** According to the pathohistological analysis, the most important and relevant finding in the IVF+ET placentas was the presence of multiple lesions. The most prominent were combined umbilical cord abnormalities and maternal vascular malperfusion. Additionally, results suggest that

the most common type of MVM observed was abnormal villous maturation. Another noteworthy finding was a reduced umbilical cord length average and low placental weight. Further research is required to reveal the exact reasons for morphological abnormalities in the IVF+ET placentas, in order to reduce their potential harm on the mother and the baby.

## **9. CROATIAN SUMMARY**

**Ciljevi:** odrediti najčešće morfološke karakteristike posteljica iz trudnoća potpomognute oplodnje (IVF+ET). Očekujemo da će niska masa posteljice, majčin i fetalni upalni odgovor, kao i niska porođajna masa djeteta i prijevremeno dovršenje poroda biti najučestaliji nalaz.

**Materijali i metode:** retrospektivna opservacijska kohortna studija provedena je na Odjelu patologije KBC Split i Klinici za ženske bolesti i porode iste bolnice. Istraživanje je obuhvatilo sve posteljice IVF+ET trudnoća u razdoblju od 1. siječnja 2016. do 31. prosinca 2020. godine, s dostupnim patohistološkim nalazom. Iz baze podataka Klinike za ženske bolesti i porode zabilježeni su: dob majke, gestacijski tjedan, spol novorođenčeta i porođajna masa djeteta. Iz baze podataka Odjela za patologiju zabilježene su morfološke karakteristike proučavanih posteljica. Kriteriji uključenja u studiju su bili sve posteljice iz IVF+ET trudnoća u gore navedenom vremenskom razdoblju. Kriteriji isključenja iz studije su bili posteljice iz trudnoća koje nisu bile IVF+ET i/ili nisu imale sve potrebne podatke.

**Rezultati:** Od 54 IVF+ET analizirane posteljice, 36 su blizanačke, i to biamnijalne bikorijalne. Prosječna dob majke u vrijeme poroda bila je 34 godine, a većina posteljica bila je iz prijevremenog poroda s medijanom od 36 gestacijskih tjedana. 77.8% novorođenčadi je bilo muškog spola. Medijan mase posteljice je bio 406 grama s promjerom od 16.7 cm, dok je prosječna debljina posteljice bila 2,5 cm. Najčešće mjesto insercije pupkovine bilo je ekscentrično (79.6%), a zatim središnje i velamentozno. Zanimljiv nalaz našeg istraživanja bila je smanjena prosječna duljina pupkovine. Najčešći patohistološki nalaz IVF+ET posteljica su bile višestruke lezije, i to kombinacija maternalne vaskularne malperfuzije (MVM) i fetalne vaskularne malperfuzije (FVM) s upalnim lezijama posteljice i lezijama pupčane vrpce.

**Zaključak:** Prema patohistološkoj analizi, najučestaliji nalaz IVF+ET posteljica su višestruke lezije, smanjena prosječna duljina pupkovine i mala masa posteljice. Potrebna su daljnja istraživanja morfoloških karakteristika IVF+ET posteljica, te njihova usporedba s posteljicama normalnih trudnoća. Bolje razumijevanje istih može doprinjeti boljem razumijevanju IVF+ET trudnoća.

## **10. CURRICULUM VITAE**

**Personal information:**

Name and Surname: Sara Bagnacani

Date of Birth: 09/04/1996

Place of Birth: Reggio nell'Emilia, Italy

E-Mail: [bagnacanisara@gmail.com](mailto:bagnacanisara@gmail.com)

**Education:**

Liceo Classico- Scientifico Ariosto Spallanzani, Reggio nell'Emilia, Italy – Italian high-school diploma (2010-2015)

Hartselle Highschool, Alabama, USA- American high-school diploma (2013-2014)

University of Split School of medicine, Split, Croatia - doctor of medicine (2016-2022)

**Internships:**

*Ente Ospedaliero Cantonale, Locarno, Switzerland, Obstetrics and Gynecology. (February 2022)*

*Ente Ospedaliero Cantonale, Lugano, Switzerland, Ophthalmology. (January 2022)*

*Careggi University Hospital, Florence, Italy, Gynecology, Surgery and Internal Medicine Internship (March 2021 - June 2021)*

**Languages:** Italian, English, French