

# Hyponatremia - A new diagnostic marker for complicated acute appendicitis in children: a systematic review and meta-analysis

---

**Birley, Jana Ros**

**Master's thesis / Diplomski rad**

**2023**

*Degree Grantor / Ustanova koja je dodijelila akademski / stručni stupanj:* **University of Split, School of Medicine / Sveučilište u Splitu, Medicinski fakultet**

*Permanent link / Trajna poveznica:* <https://um.nsk.hr/um:nbn:hr:171:927229>

*Rights / Prava:* [In copyright](#)/[Zaštićeno autorskim pravom.](#)

*Download date / Datum preuzimanja:* **2024-07-04**



*Repository / Repozitorij:*

[MEFST Repository](#)



**UNIVERSITY OF SPLIT  
SCHOOL OF MEDICINE**

**Jana Rós Birley**

**HYPONATREMIA – A NEW DIAGNOSTIC MARKER FOR COMPLICATED  
ACUTE APPENDICITIS IN CHILDREN: A SYSTEMATIC REVIEW AND META-  
ANALYSIS**

**Diploma thesis**

**Academic year:**

**2022/2023**

**Mentor:**

**Assoc. Prof. Zenon Pogorelić, MD, PhD**

**Split, July 2023**

## TABLE OF CONTENTS

<b>1. INTRODUCTION.....</b>	<b>1</b>
1.1. <i>THE APPENDIX</i> .....	2
1.1.1. EMBRYOLOGY.....	2
1.1.2. HISTOLOGY.....	2
1.1.3. ANATOMY.....	3
1.1.4. PHYSIOLOGY AND FUNCTION.....	4
1.2. <i>ACUTE APPENDICITIS</i> .....	5
1.2.1. EPIDEMIOLOGY.....	5
1.2.2. PATHOGENESIS AND PATHOPHYSIOLOGY.....	5
1.2.3. CLINICAL PICTURE.....	6
1.2.4. PHYSICAL EXAMINATION AND CLINICAL SIGNS.....	8
1.2.5. COMPLICATIONS.....	9
1.3. <i>DIAGNOSIS OF ACUTE APPENDICITIS</i> .....	10
1.3.1. LABORATORY FINDINGS.....	10
1.3.2. IMAGING.....	11
1.3.3. SCORING SYSTEMS.....	13
1.4. <i>TREATMENT OF ACUTE APPENDICITIS</i> .....	17
1.4.1. SURGICAL MANAGEMENT.....	17
1.4.2. NON-OPERATIVE MANAGEMENT.....	18
1.4.3. MANAGEMENT OF COMPLICATED APPENDICITIS.....	18
1.4.4. POST-OPERATIVE COMPLICATIONS.....	20
1.5. <i>DIFFERENTIAL DIAGNOSIS</i> .....	20
1.6. <i>HYPONATREMIA IN CHILDREN WITH ACUTE APPENDICITIS</i> .....	22
<b>2. OBJECTIVES.....</b>	<b>23</b>
2.1. <i>AIM OF STUDY</i> .....	24
2.2. <i>HYPOTHESIS</i> .....	24
<b>3. PATIENTS AND METHODS.....</b>	<b>25</b>
3.1. <i>STUDY DESIGN</i> .....	26
3.2. <i>SEARCH STRATEGY</i> .....	26
3.3. <i>ELIGIBILITY CRITERIA</i> .....	27
3.4. <i>DATA EXTRACTION</i> .....	27
3.5. <i>METHODOLOGICAL QUALITY ASSESSMENT</i> .....	28
3.6. <i>STATISTICAL ANALYSIS (QUANTITATIVE SYNTHESIS)</i> .....	30
<b>4. RESULTS.....</b>	<b>31</b>
4.1. <i>STUDY CHARACTERISTICS</i> .....	32
4.2. <i>SUMMARY OF THE INCLUDED STUDIES</i> .....	34
4.3. <i>METHODOLOGICAL QUALITY ASSESSMENT</i> .....	37

4.4. <i>OUTCOME ANALYSIS</i> .....	37
<b>6. DISCUSSION</b> .....	<b>38</b>
<b>6. CONCLUSION</b> .....	<b>42</b>
<b>7. REFERENCES</b> .....	<b>44</b>
<b>8. SUMMARY</b> .....	<b>53</b>
<b>9. CROATIAN SUMMARY</b> .....	<b>55</b>

## **ACKNOWLEDGEMENT**

*First, I would like to express my appreciation to my mentor Prof. Zenon Pogorelić, MD, PhD, for his invaluable advice and guidance in writing my diploma thesis. His dedication to his work will continue to inspire me as I start my professional career.*

*I would also like to thank my mother and two sisters, for their endless support and encouragement throughout Medical School.*

*To my dearest friends and boyfriend, I am deeply grateful for the unforgettable memories we have created together in Split the past six years.*

## **LIST OF ABBREVIATIONS**

AA – Acute Appendicitis

AIR – Acute Inflammatory Response Score

CRP – C-Reactive Protein

IV – Inverse Variance

IQR – Interquartile Range

MD – Mean Difference

PAS – Pediatric Appendicitis Score

PID – Pelvic Inflammatory Disease

RLQ – Right Lower Quadrant

SD – Standard Deviation

WBC – White Blood Cell

WMD – Weighted Mean Difference

## **1. INTRODUCTION**

## 1.1. THE APPENDIX

### 1.1.1. EMBRYOLOGY

During embryonic development, the appendix develops from the midgut. As the intestinal loops grow too fast for the abdominal cavity to accommodate, the intestinal loop herniates through the umbilicus at around 8 weeks of gestation. During this physiological umbilical herniation, the intestines undergo its first 90 degrees of rotation, with the remaining 180 degree rotation occurring when reentering the abdomen from the 10th week (1). The base of the cecum is the last part to reenter the abdominal cavity. The cecal bud is initially positioned in the right upper quadrant before it descends into the right lower quadrant (RLQ) as the colon elongates. The appendix develops during this elongation of the colon and appears as a narrow outgrowth at the distal end of the cecum. As the appendix develops in parallel with this descent of the colon, it often settles behind the cecum, referred to as the retrocecal position. However, its final position can be in the right lower quadrant, pelvis or retroperitoneally (1, 2).

### 1.1.2. HISTOLOGY

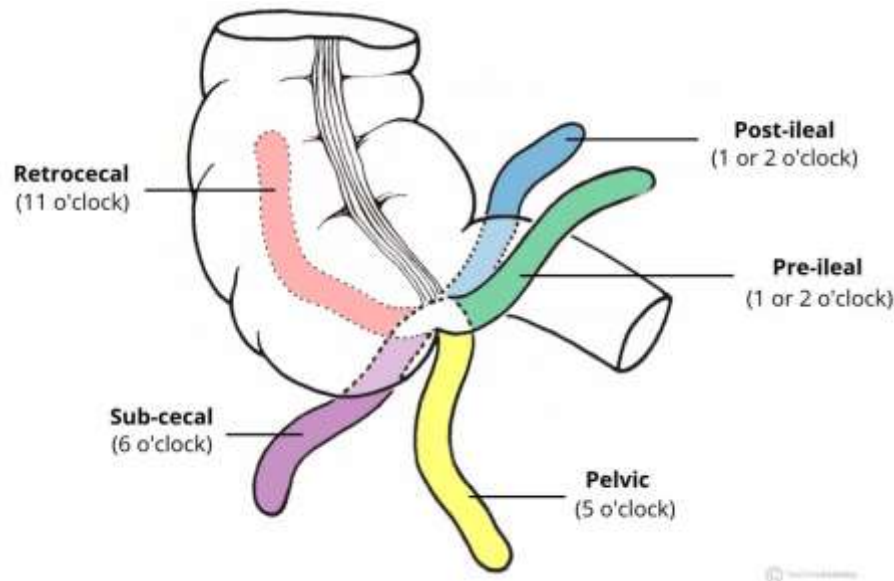
Histologically, the appendix is similar to the rest of the large intestine, but it has some unique features that distinguish it from other parts of the digestive system. The appendix is composed of four layers: the mucosa, submucosa, a muscular layer and serosa. The mucosal layer is the innermost layer of the appendix and is characterized by the presence of intestinal glands, also known as crypts of Lieberkühn. These glands are lined with columnar epithelial cells, which secrete mucus that helps lubricate the appendix and prevent the accumulation of fecal matter and other debris (3). The characteristic feature of the appendicular mucosa and submucosa is that it has abundant lymphoid tissue and follicles with the presence of B and T lymphocytes, in addition to IgA and IgG (4, 5). Overall, the histological structure of the appendix reflects its role as a secondary lymphoid organ and an important component of the immune system (5).



### 1.1.3. ANATOMY

The appendix is a worm-shaped, hollow organ located at the tip of the cecum, hence the name vermiform appendix or vermix (6). It is located approximately 2 centimeters below the ileocecal valve and has an average length of 8–10 cm (2, 7). The triangular part of the mesentery which connects the appendix to the ileum and cecum is called the mesoappendix. The mesoappendix provides the appendix with vascular supply, lymphatic drainage and innervation, and extends towards the tip of the appendix. The appendix is supplied by the appendicular artery, a branch of the ileocolic artery. The ileocolic artery is a terminal branch of the superior mesenteric artery (6). Branches from the anterior and posterior cecal arteries provide additional vascularisation of the base of the appendix (8). The appendicular vein drains the appendix to the superior mesenteric artery via the ileocolic vein, and accompanies the appendicular artery within the mesoappendix. Lymphatic drainage is provided by lymph nodes within the mesoappendix, which is connected to the superior mesenteric nodes via the ileocolic lymph nodes. The innervation of the initial part of the large intestine, including the appendix, arises from the superior mesenteric plexus (6).

The location of the appendix relative to nearby structures is subject to anatomical variation, as briefly mentioned in the section of embryologic development. The positions of the appendix are commonly described in relation to the ileum, cecum or pelvis, with the most common position being retrocecal, as demonstrated in Figure 1 (8). This refers to cases where the appendix is positioned posterior to the ascending colon. Other anatomical variations include a pelvic position; below the cecum in the subcecal position; in front of the terminal ileum in a preileal position; or behind the terminal ileum in a postileal position. In addition to these, there are cases of agenesis and duplications mentioned in literature, but these are considered rare. The different anatomical locations give rise to different clinical presentations of an inflamed appendix (8). Knowledge about embryology and anatomy aids clinicians in the understanding of anatomical variations of the appendix and hereby guide us in the diagnosis of acute appendicitis.



**Figure 1.** Anatomical variations in position of the appendix. Source: Teach Me Anatomy. Jones O. Anatomical Structure and Relations; 2018 Dec 10 [cited 2023 June 7]. Available from: <https://teachmeanatomy.info/>

#### 1.1.4. PHYSIOLOGY AND FUNCTION

The appendix was until recently regarded a vestigial organ, with no particular function (9). Recent research suggests that the appendix plays a more complex role, and is linked to immunology, development of the gut microbiome and maintenance of beneficial bacterial flora in the intestines (5). The gut microbiome is a complex ecosystem of microorganisms that live in the digestive tract and play a crucial role in digestion, metabolism, and immune function. The appendix's potential role in maintaining gut health has been explained by the "safe house" theory, working to maintain and reintroduce commensal bacteria in case of gastrointestinal disease (5). Appendiceal biofilm consists of mucus and commensal gut bacteria and has also proved beneficial for the gut system by working as a protecting barrier for the gut wall. Parts of the bacteria-containing biofilm sheds and allows bacteria to recolonize after disruption of the mucus layer of the intestines after a diarrheal illness (9, 10). The appendix contains abundant lymphoid tissue, which produces antibodies, especially immunoglobulin A. It is thought to play a role in the immune response to certain types of bacteria, such as those found in the gut (5).

## 1.2. ACUTE APPENDICITIS

### 1.2.1. EPIDEMIOLOGY

Acute appendicitis is one of the most common causes of acute abdomen in both children and adults. The incidence of acute appendicitis in the pediatric population varies by region and age group, but is generally more common in boys than in girls (11). The yearly incidence is estimated to be close to 100 per 100,000 per year (12, 13). It is more common in children between 12 and 18 years of age, but is seen occurring at any age (11). The mortality rate is relatively low, but morbidity is still an issue, especially among pediatric patients presenting with complicated appendicitis (11, 12). Compared to the adult population, children more often present with complicated appendicitis with an estimated 40% of cases (14). Studies show that the rate of perforation in acute appendicitis is inversely proportional to the patient's age. The reported incidence is even higher in preschool children (100% <1 year; 100% 1-2 years; 83.3% 2-3 years; 71.4% 3-4 years; 78.6% 4-5 years and 47.3% 5 years). The highest rate occurs in children <2 years, with a perforation rate of 100% (14). However, diagnosing acute appendicitis in younger children can be challenging, with an initial misdiagnosis rate of 28–57% in children <12 years (15).

### 1.2.2. PATHOGENESIS AND PATHOPHYSIOLOGY

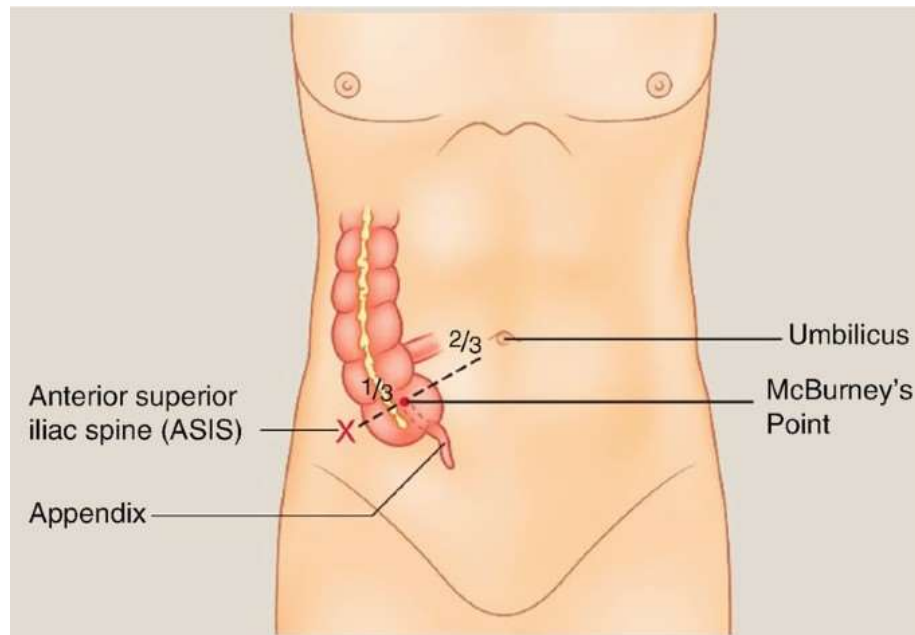
The pathophysiology of acute appendicitis, while not completely understood, is believed to be connected to obstruction of the appendiceal lumen (11, 16). The cause of the obstruction varies among age groups, but is typically caused by fecal matter, mucus, lymphoid tissue hyperplasia, foreign bodies or in rare cases malignancy or parasites. Fecalith is found to be the cause of obstruction in 40% of uncomplicated acute appendicitis (12). In younger children the obstruction is commonly caused by hyperplasia of lymphoid tissue (15). The obstruction sets off a cascade of events beginning with an accumulation of mucus and other substances that are normally produced by the organ, causing pressure to build up inside the appendix. An increase in intraluminal pressure of the inflamed appendix compromises the vascular supply and lymph drainage, leading to ischemia and eventually tissue necrosis. As the inflammation progresses, the risk of perforation increases (11). However, not all patients follow the same course of progression to perforation. Some patients recover spontaneously and others form abscesses.

Although obstruction is the most widely accepted theory explaining acute appendicitis, studies have shown that obstruction is only found in 50% of cases (11).

Initially the pain in patients with acute appendicitis is dull, diffuse pain typically in the umbilical region. This is due to inflammation and distention of the appendix, stimulating visceral afferent nerve fibers. As the inflammation progresses, it affects the serosa of the appendix and surrounding parietal peritoneum, which causes the characteristic shift in location of the pain to the lower right quadrant. Further progression of inflammation often leads to gangrene and subsequently perforation (11, 16).

### 1.2.3. CLINICAL PICTURE

Children with acute appendicitis present with a wide variety of symptoms, ranging from mild symptoms and good general condition to life-threatening septic shock. The presenting symptoms in children vary due to factors such as age, time since onset of disease, atypical symptoms and signs, anatomical location of appendix and the course of the inflammatory process. The disease usually starts gradually, characterized by a brief period of general malaise and loss of appetite. The child does not seem very ill and therefore the family is unlikely to seek medical help during this phase (11). The typical clinical picture of acute appendicitis is an initial periumbilical pain. The initial pain is dull and poorly localized due to innervation by visceral nerve fiber. During the following 12–24 hours the pain intensifies and migrates to the right lower quadrant. This is caused by progression of inflammation to involve the parietal peritoneum, innervated by somatic nerve fibers. The pain becomes more localized in the right lower quadrant (RLQ), known as the McBurney's point (Figure 2). The most common patient complaints, in addition to pain, include anorexia, nausea/vomiting, fever, diarrhea and generalized malaise (11, 12, 16, 17). The order in which symptoms appear plays a major role in establishing a diagnosis, and in most cases loss of the appetite is the first symptom, followed by abdominal pain, and then by all other symptoms like nausea and vomiting. Often the child will have a mild to moderate increase in body temperature ( $<38\text{ }^{\circ}\text{C}$ ), which presents later than the initial symptoms (16). Mild tachycardia is a common finding. However, appendicitis presents with atypical symptoms in 30–50% of cases (11).



**Figure 2.** McBurney's point. Science Direct. Sellars H, Boorman P. Acute Appendicitis; 2017 Aug [cited 2023 June 7]. Available from: <https://www.sciencedirect.com/>

Within 48 hours of onset of symptoms, the disease is likely to progress to perforation. In fact, if the diagnosis is not made within 36-48 hours, the rate of perforation surpasses 65% (11). Patients with perforation of the appendix more often present with gastrointestinal symptoms such as vomiting and diarrhea, while constipation is a more common finding in uncomplicated appendicitis (14). The duration of symptoms also tends to be longer in perforated cases (18). Following perforation of the appendix, some patients experience a period characterized by reduced abdominal pain and acute symptoms, which is believed to occur due to the release of pressure within the appendix. The perforation can cause widespread peritonitis with intensifying diffuse abdominal pain, and progress to dehydration and septic shock with circulatory collapse, decreased urine output and high fever (11, 17).

As mentioned in the section on Anatomy, there are anatomical variations that affect the presentation of acute appendicitis. The appendix is positioned retroceally in the majority of the population, which may lead to atypical symptoms and delayed diagnosis. A retrocecal position of the appendix can lead to slower progression of appendicitis, and the pain is described to be localized laterally and towards the patients back (11, 15). A pelvic position, on the other hand, may cause suprapubic pain (19).

#### 1.2.4. PHYSICAL EXAMINATION AND CLINICAL SIGNS

In most patients the diagnosis is based on clinical findings and anamnestic data, without the need for diagnostic imaging (19). The physical examination includes monitoring of the child's behavior and appearance of the abdomen. The external abdomen is usually flat, and distension would indicate late phase of acute appendicitis or suggest other conditions such as Hirschsprung disease or small bowel obstruction. Children presenting in the early phase of disease may have little symptoms and not appear very ill. When lying down, a child with acute appendicitis will often flex the right knee to avoid stretching the abdomen which elicits pain. Findings on auscultation are typically normal or increased bowel sounds, but quieter sounds are associated with progression of disease (11, 16). When it comes to diagnosing acute appendicitis, the presence of localized abdominal pain is considered the most reliable indication. Abdominal pain may not only be diffuse and vague initially, but also in perforated cases of AA. In case of perforation, peritonitis may cause voluntary or involuntary spasm and rigidity of the overlying rectus muscle. Rebound tenderness can be tested to check for peritonitis, and is elicited by deep palpation of the abdomen followed by the abrupt release of pressure (16, 19). However, this procedure is often highly painful for the child and has shown limited correlation with peritonitis, and should therefore be avoided (11). Psoas and obturator signs demonstrate pain upon passive stretch of the muscles (19). If a mass is detectable during physical examination, it may indicate the presence of an inflammatory phlegmon surrounding the appendix or a localized abscess (20).

There are several clinical signs that may help clinicians identify acute appendicitis. Some of the most important and well-known include (16, 17, 19, 20):

1. McBurney's point: Tenderness or pain in the right lower quadrant of the abdomen at a point about two-thirds of the way from the umbilicus to the anterior superior iliac spine.
2. Rovsing's sign: Pain felt in the RLQ of the abdomen when pressure is applied to the left lower quadrant, also called referred rebound tenderness.
3. Psoas sign: Pain felt in the RLQ of the abdomen when the patient's right thigh is extended backwards. This sign is typically positive in retrocecal position of the appendix.

4. Obturator sign: Pain located in the RLQ of the abdomen when the patient's right thigh is flexed and internally rotated. This sign can be positive in case of a pelvic appendix.
5. Dunphy's sign: An increase in pain felt in the RLQ of the abdomen when the patient coughs or performs a jarring movement.
6. Blumberg's sign: This is rebound tenderness, meaning pain that is felt when pressure is released from the RLQ of the abdomen after it has been palpated.

It's important to note that these clinical signs are not always present in acute appendicitis and their absence does not rule out the condition. Therefore, a combination of clinical assessment, laboratory investigations, and imaging studies may be required to establish a diagnosis (19).

#### 1.2.5. COMPLICATIONS

A key objective in the management of acute appendicitis is to prevent progression to serious complications. Appendicitis is considered complicated in the event of abscess formation, phlegmon, perforation and subsequently peritonitis. Since complicated appendicitis is associated with higher rates of mortality and morbidity, differentiating complicated from uncomplicated appendicitis is an important step in the management of AA in children. Several predictive factors for complicated appendicitis have been referred to in research, with the main ones including age <5 years, symptom duration >24h, leukocytosis  $>12 \times 10^3$ , hyponatremia  $<135$  (13, 21).

As the inflammation of the appendix progresses to cause ischemia and necrosis, the risk of perforation increases. If the appendix ruptures, the fecal contents of the appendix may spill into the abdominal cavity, causing inflammation of the lining of the abdominal cavity. Patients with advanced appendicitis and peritonitis can potentially lead to life-threatening sepsis and multi-organ failure. Children overall present with perforation rates between 20% and 74%, with rates approaching 100% for children <2 years (14, 22). However, not all perforations end up with peritonitis. The body's local defense mechanisms will try to wall off and contain the content of the burst appendix, forming an abscess. Both abscess formation and perforation increase the risk of fistula formation in surrounding organs. Untreated appendicitis can also lead to abscess and fistula formation. The main goal of diagnosis and management should be to avoid these complications (17).

### 1.3. DIAGNOSIS OF ACUTE APPENDICITIS

#### 1.3.1. LABORATORY FINDINGS

The evaluation of acute abdomen in children is guided by various diagnostic tools, including clinical examination, biochemical testing, scoring systems and imaging modalities. Measurement of complete blood count, C-reactive protein (CRP) and urinalysis is routinely performed in patients with acute abdomen in most hospitals. The current laboratory tests are non-specific and non-sensitive separately, but have an important role as objective markers combined (23). Measurements must always be considered in concordance with the clinical picture and course of disease.

C-reactive protein is an acute phase reactant commonly measured if infection or inflammation is suspected. It has a half-life of 19 hours, and reaches peak serum levels around 48 hours. It can be increased in conditions such as infection, inflammatory disease and trauma, and the rise is proportional to the degree of inflammation and progression of AA (24). In acute appendicitis the sensitivity and specificity reported is 95.4% and 24.5%, respectively (25). A value of CRP  $\geq 10$ mg/L predicts the diagnosis of acute appendicitis in children younger than 6 years of age (26). Not all patients with acute appendicitis measure an increased CRP level and white blood cells (WBC). However, it is highly unlikely that a patient with AA demonstrates normal values of both, and one can exclude acute appendicitis in 98% of such cases (25).

Most patients with AA show a moderate leukocytosis with values  $>10 \times 10^9$ , but this is a common and nonspecific finding which can be linked to other conditions with right lower quadrant pain. Elevated WBC in acute appendicitis has a sensitivity of 69.6% and specificity of 43.1% (17, 27). A normal leukocyte count cannot rule out the condition, as up to 1/3 of patients can present with a normal white blood cell count (WBC). In most cases, the WBC shows a left shift, which points in the direction of a bacterial infection, with an increased neutrophil percentage (17). Complicated appendicitis is connected to increasing levels of both CRP and WBC. Combined with CRP the sensitivity increases to 97.5%. A very high leukocyte count ( $>17 \times 10^9$ ) can indicate the likelihood of complicated appendicitis (17, 25).

Urinalysis can aid in the diagnosis of acute appendicitis, or rule out other conditions such as urinary tract infections. Its benefits include being a fast, available and low-cost test. A study conducted by Chen et al., suggest that elevated urine ketones and nitrates could be a



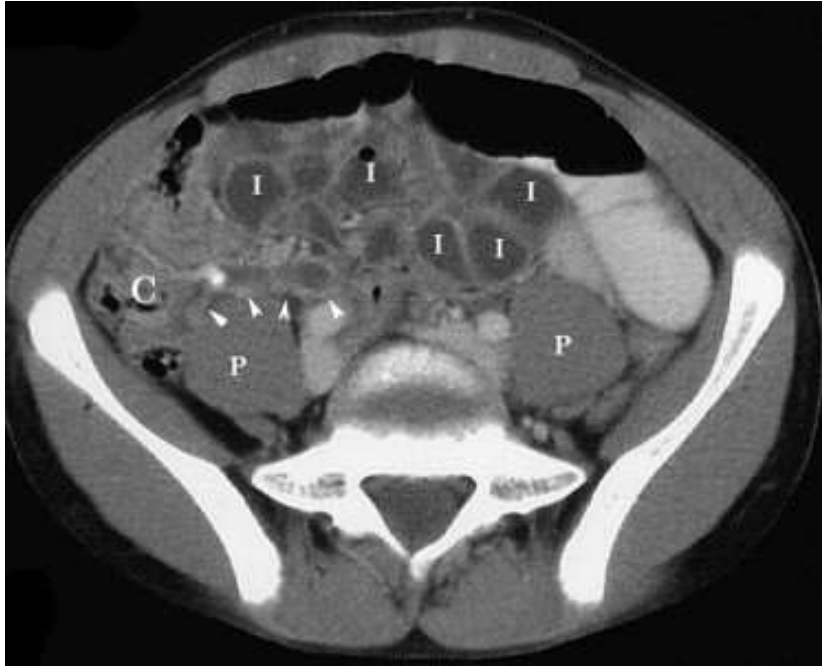finding in perforated appendicitis and hereby aid in distinguishing uncomplicated from complicated cases (28).

With high perforation rates in children, there is need for additional reliable laboratory markers. Markers including procalcitonin, calprotectin, serum amyloid, hyponatremia and bilirubin have been investigated the past few years (20). Procalcitonin is a biomarker associated with infections and sepsis, and starts rising and reaches its peak earlier than CRP. In a study by Pian et al, procalcitonin, together with CRP, was found to be significantly increased in infants and young children with complicated appendicitis (29). Other potential biomarkers include serum amyloid A, which seems to have higher sensitivity and equal specificity in comparison with CRP (30). Further research is needed to conclude what role these markers can have in the diagnosis of AA.

### 1.3.2. IMAGING

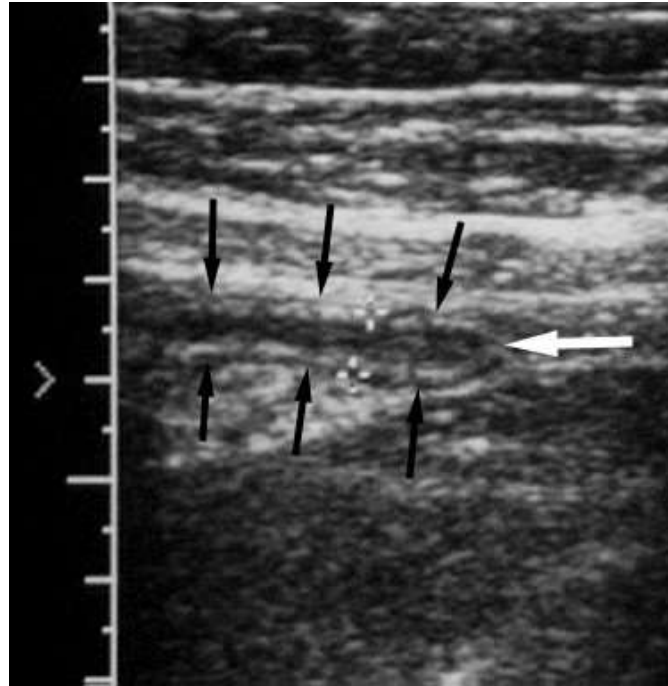
Although the diagnosis of acute appendicitis commonly is based on history and physical examination, several imaging modalities have proven useful in the diagnosis of appendicitis in children (22).

The gold standard is CT scan with a sensitivity and specificity of over 95% for acute appendicitis (11). Findings on CT scans typically include thickened appendiceal wall (> 2mm), distended appendix (> 6mm in diameter), inflammatory changes in the surrounding mesenteric fat, a pericecal phlegmon or abscess (17). The main disadvantage of a CT scan is radiation exposure, as well as the potential need of sedation and higher cost. Appendicoliths are more easily visible on CT scans than on plain radiographs, and can be seen in 25% of patients (31). In cases of advanced appendicitis, CT scans can also help identify and guide the drainage of fluid collections and locate inflammatory masses, which may require initial nonoperative management. CT imaging is also useful in detecting other causes of abdominal pain that are not related to the appendix (17).



**Figure 3.** Axial CT image of a 13-year old boy with suspected acute appendicitis. The image shows a fluid-filled, dilated appendix (arrows), calcified appendicolith and fluid-filled ileal loops (I). Source: Loyola University Chicago, <https://www.lumen.luc.edu/>

Ultrasound is recommended as the initial imaging modality used to evaluate acute appendicitis due to its low risk profile, but has shown variable sensitivity and specificity (22, 30). In experienced pediatric centers, the sensitivity and specificity has been found to be >90% (11). Ultrasound criteria for appendicitis include wall thickness of at least 6 mm, luminal distention, lack of compressibility, a complex mass in the right lower quadrant, or a fecalith (7, 11). Since increased wall thickness can be attributed to other causes than AA, some studies suggest using 7mm as a threshold to increase specificity (32). Advanced appendicitis may be suggested by asymmetric wall thickening, abscess formation, free intraperitoneal fluid, peri-appendiceal edema, or decreased local tenderness to compression. Ultrasound is advantageous due to its availability, low cost and lack of need for patient preparation. It may eliminate the need for a CT scan and hereby unwanted ionizing radiation in the child (22). Factors that can affect the reliability and sensitivity include doctors experience with the device, obesity, bowel distention and pain. A recent study assessed the practical application of abdominal ultrasound in children presenting with suspected acute appendicitis showed sensitivity and accuracy being significantly higher using high-frequency ultrasound compared to low-frequency ultrasound (11, 31).



**Figure 4.** Ultrasound imaging of a 14-year old boy with RLQ pain. The image shows a mildly dilated appendix (arrows), with no signs of perforation. Uncomplicated appendicitis was confirmed during surgery. Source: Loyola University Chicago, <https://www.lumen.luc.edu/>

Plain abdominal x-rays can reveal several signs of acute appendicitis, such as sentinel loops of bowel, localized ileus, scoliosis from psoas muscle spasm, a colonic air-fluid level above the right iliac fossa (colon cutoff sign), or a fecalith (found in 10–20% of cases). However, they have low sensitivity for appendicitis and are not typically recommended. These x-rays can be useful in complex cases involving suspected small bowel obstruction or free air (22).

### 1.3.3. SCORING SYSTEMS

Several clinical scoring systems have been developed to assist in the diagnosis of acute appendicitis, with the Alvarado scoring system and Pediatric Appendicitis Score (PAS) being the most widely used among children. They are predominantly based on physical findings and

clinical examination. Symptoms of acute appendicitis may overlap with other conditions and consequently yield a high score. Therefore the diagnosis of acute appendicitis in children cannot be based exclusively on scoring systems in children, and one must always consider the whole clinical picture together with other diagnostic tools (27).

The Alvarado scoring system is a clinical tool consisting of 8 components with a total score of 10 (Table 1). This includes migration of pain, anorexia, nausea, tenderness in right lower quadrant, rebound pain, elevated temperature, leukocytosis, left shift of white blood cell count, with each criteria giving 1 point with the exemption of RLQ pain and leukocytosis, which give 2 points each (33, 34). The Alvarado score is also known by its acronym MANTRELS. A score between 0-4 is considered low risk for acute appendicitis, a score of 5-6 suggests an intermediate risk, while a score of 7-10 is high risk. In children, the Alvarado score has a sensitivity of 89% and specificity of 59%, with a positive predictive value of 93.1% (16).

**Table 1.** The Alvarado scoring system.

<b>Alvarado score</b>	
<b><i>Signs</i></b>	<b><i>Score</i></b>
RLQ tenderness	+2
Temperature $\geq 37.3$	+1
Rebound tenderness	+1
<b><i>Symptoms</i></b>	
Migration of pain to RLQ	+1
Anorexia	+1
Nausea or vomiting	+1
<b><i>Laboratory values</i></b>	
Leukocytosis $> 10 \times 10^9$	+2
$>75\%$ neutrophils	+1
<b>Total</b>	<b>10</b>

Source: MdCalc. Alvarado Score for Acute Appendicitis. Available from: Mdcalc.com

The Pediatric Appendicitis Scoring system (PAS) predicts the likelihood of acute appendicitis in children and adolescents in the age group 3-18 years, presenting with abdominal pain of  $\leq 4$  days duration. It is similar to the Alvarado score, and the score is based on history, physical examination and lab data (Table 2). The following criteria give 1 point each: Anorexia, fever  $>38.0$ , nausea or vomiting, leukocytosis ( $WBC >10 \times 10^9$ ), neutrophilia ( $>75\%$ ) and migration of pain. The following two criteria give 2 points each: RLQ tenderness (to cough, percussion or hopping) and tenderness over right iliac fossa (36). The sensitivity and specificity in children is 86% and 50% respectively. The positive predictive value is 90.1% (27).

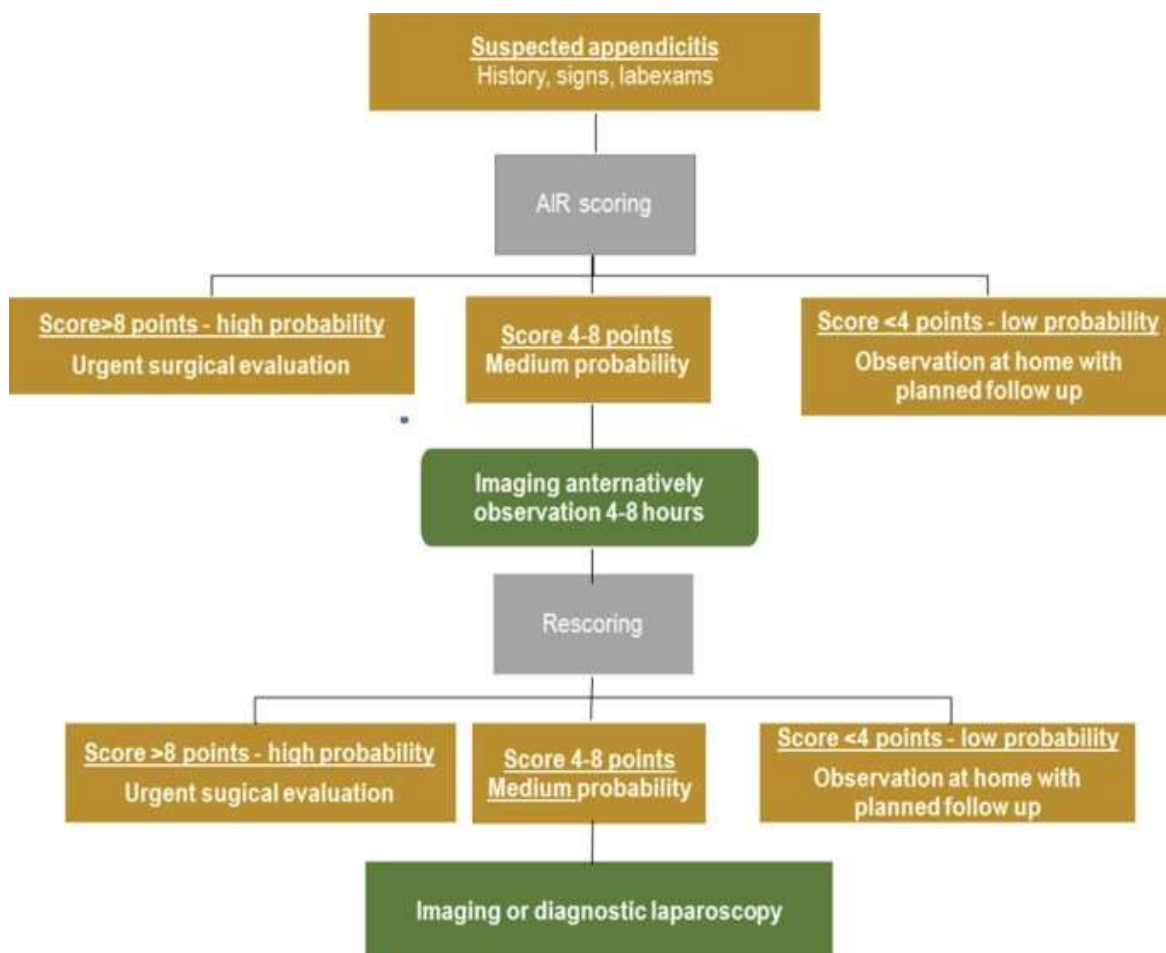
**Table 2.** The Pediatric Appendicitis Scoring system.

<b>The Pediatric Appendicitis Scoring system</b>	
<i>Signs</i>	<i>Score</i>
RLQ tenderness	+2
Cough / percussion / hopping tenderness	+2
Temperature $\geq 38$	+1
<i>Symptoms</i>	
Migration of pain to RLQ	+1
Anorexia	+1
Nausea or vomiting	+1
<i>Laboratory values</i>	
Leukocytosis $> 10 \times 10^9$	+1
$>75\%$ neutrophils	+1
<b>Total</b>	<b>10</b>

Source: MdCalc. Pediatric Appendicitis Score. Available from: [Mdcalc.com](http://Mdcalc.com)

A study investigated the validation of the Alvarado score and PAS. It concluded that there was no significant difference in sensitivity and specificity between the observed scoring systems and therefore also none of them can be used as an exclusive standard in setting the diagnosis. The scoring systems can aid in the diagnosis, but do not have the adequate predictive values to diagnose acute appendicitis in children (27).

Due to the shortcomings of the Alvarado score and PAS, a scoring tool called Appendicitis inflammatory response (AIR) was established in 2008 (18). It has an estimated sensitivity and specificity of 89.5% and 71.9%, respectively (37). Unlike the Alvarado score and PAS, AIR requires C-reactive protein (38). Figure 5 displays the suggested management algorithm based on the utilization of the AIR score. This scoring system has outperformed the Alvarado score and PAS in several studies, with an estimated higher sensitivity and specificity (37, 38). Additionally, a newer study looked at the value of AIR in complicated and uncomplicated appendicitis in children, and concluded that the scoring tool has a high value in the distinguishing the two. Further research is required to validate these findings, especially in children (37).



**Figure 5.** Algorithm for suspected appendicitis using the AIR scoring system. Source: Andersson M, Kolodziej B, Andersson RE. Validation of the appendicitis inflammatory response (AIR) score. World J Surg. 2021;45:2081–91.

## 1.4. TREATMENT OF ACUTE APPENDICITIS

### 1.4.1. SURGICAL MANAGEMENT

Acute appendicitis in children is a medical emergency and requires prompt diagnosis and treatment to prevent complications such as perforation and peritonitis. The treatment typically involves surgical removal of the appendix (appendectomy), which can be performed either through an open incision or using minimally invasive laparoscopic techniques (11). Surgery, both open and laparoscopic, is regarded as low risk and highly effective, but is not without risks and complications (41). There is not an increased risk of perforation or other complications as long as appendectomy is performed within the first 24 hours from presentation (42). Appendectomy is a highly successful procedure with a mortality rate ranging from 0.09% to 0.24% and a morbidity rate of 5% to 7% (43). In the case of complicated appendicitis, specifically perforation, the complication rate rises to 5% to 30% (11). These numbers vary according to patient's age, underlying health conditions, and other considerations. Failure to timely recognize the disease and delay in surgical intervention contribute to increased mortality and morbidity rates (44).

The choice of surgical technique depends mostly on the experience and preference of the surgeon. Laparoscopic technique appears to be safer compared to open surgery for acute appendicitis in children, and most surgeons opt for this treatment approach today (39, 43). Laparoscopic surgery is less invasive than open surgery, and allows for smaller incisions, shorter recovery time and less postoperative pain and therefore also decreases the postoperative analgesic need (39, 44). Today there are different approaches during laparoscopic appendectomy such as traditional three-port appendectomy, transumbilical with two ports in which the appendix is removed through the umbilicus and single-incision appendectomy in which both the instruments and the camera are introduced into the abdomen through the same incision. Laparoscopic appendectomy is performed under general anesthesia in a supine position, and a single dose of preoperative broad-spectrum antibiotics are recommended (42, 46). The post-operative recovery time is expected to be within 24 to 48 hours for uncomplicated cases (17).

#### 1.4.2. NON-OPERATIVE MANAGEMENT

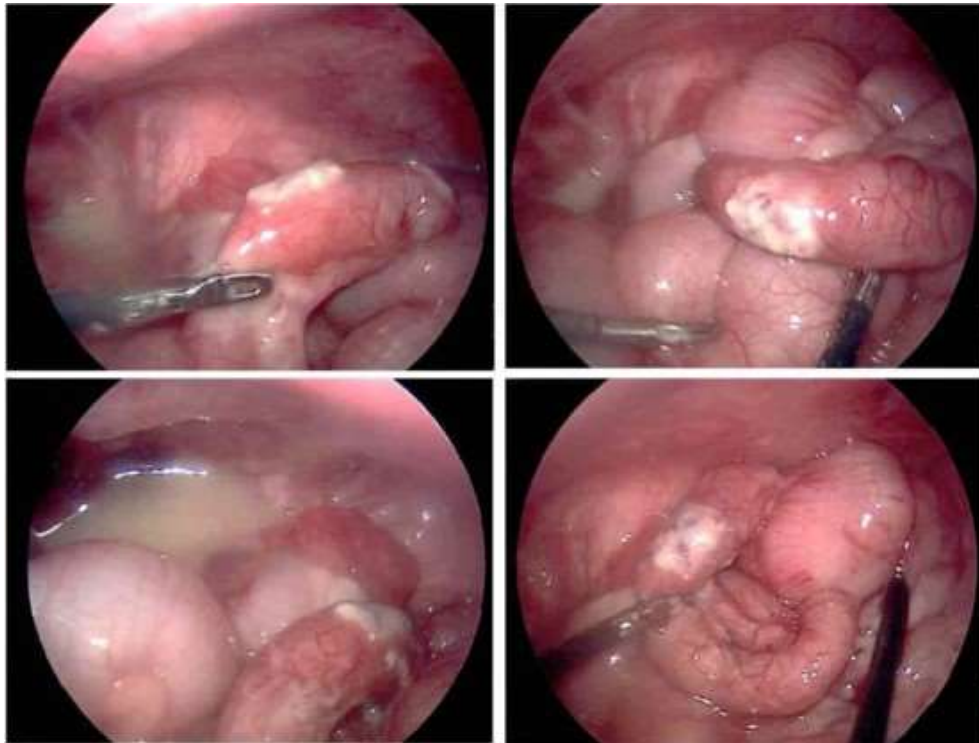
Although appendectomy has long been considered the gold standard of treatment for acute appendicitis, studies conducted the past years have challenged this management. Management with antibiotics, also referred to as the conservative approach, is an alternative to appendectomy, and several studies have investigated its safety and efficacy (47–52). According to a meta-analysis conducted by Maita et al., symptoms resolved with NOM in 92% of patients with an additional 16% undergoing appendectomy at a later time (52). This approach is typically reserved for children who are too ill to undergo surgery or who have a small, uncomplicated abscess (51). Another study reported a higher complication-free treatment success rate (82.3% vs 67.2%) and treatment efficacy based on 1-year follow-up rate (93.1% vs 72.6%) for uncomplicated appendicitis managed surgically (47). Non-operative management of non-perforated appendicitis is safe and efficient in children, but there is need for further research with larger RCTs to compare the outcomes of the different treatment options (46, 47).

#### 1.4.3. MANAGEMENT OF COMPLICATED APPENDICITIS

Management of complicated AA is more complex and there is no consensus among surgeons regarding the superior treatment option (52, 53). In patients presenting with perforated appendicitis, the majority of surgeons will give antibiotics preoperatively and perform an appendectomy (45). Figure 3 depicts an intraoperative image of a perforated appendix in an infant. Many surgeons will also perform extensive irrigation of the abdomen with saline to drain any pus or fecal matter after removal of the appendix (11, 44). However, the WSES (World Society of Emergency Surgery) Jerusalem guidelines stated in 2020 that peritoneal irrigation is not superior to suction alone in complicated appendicitis and therefore recommend suction alone (42). In case of abscess formation and phlegmon, 75% will opt for conservative management initially with interval appendectomy several weeks later (45). A meta-analysis from 2019 looked at early appendectomy vs. conservative management in complicated acute appendicitis in children, specifically for the different subtypes of complicated appendicitis. The study concluded that children with appendicular abscess or phlegmon tend to result in improved outcomes if treated non-operatively, showing lower complication rates and readmission rates.



Patients presenting with perforated appendicitis on the other hand, had lower complication rates and readmission rates when treated surgically (53). The WSES Jerusalem guidelines have concluded that early appendectomy (within 8 hours) should be the preferred management option for patients with complicated appendicitis, including children. If laparoscopic surgery is not an option, the suggested management is antibiotics and percutaneous drainage, if possible, in the case of an abscess (42). There is a necessity for conducting randomized controlled trials (RCTs) in order to further explore safe approaches for managing complicated appendicitis in children.



**Figure 6.** Intraoperative image of a perforated appendix in an infant (55).

Early initiation of rehydration, correction of electrolyte imbalance and restoration of acid-base status is also a crucial part of the management (16). The typical microbial composition found in the appendix and colon consists of gram-negative aerobic bacteria like *Escherichia coli* and anaerobic bacteria such as *Bacteroides* species (11, 56). Suitable antibiotic options include second-generation cephalosporins or a combination of antibiotics effective against gram-negative bacteria and anaerobes, such as gentamicin and metronidazole (57).

#### 1.4.4. POST-OPERATIVE COMPLICATIONS

Patients undergoing appendectomy for complicated appendicitis are more prone to postoperative complications compared to uncomplicated cases of AA (22, 58). The most common post-operative complications include surgical wound infection, intra-abdominal abscess formation, and paralytic ileus. In the case of wound infection, the early signs of infection are pain and elevated body temperature and occur within three days after surgery (59). Laparoscopic appendectomy is associated with lower rates of post-appendectomy complications such as wound infection and bowel obstruction compared to open appendectomy, but with higher rates of intraabdominal abscess formation. In cases of laparoscopic appendectomy, infection at the site where the appendix was extracted is most frequently observed. The occurrence of intra-abdominal abscess is a result of preoperative contamination and/or inadequate abdominal cavity irrigation during surgery (42, 60). Typically, abscesses manifest about a week after surgery and may present with fever, leukocytosis, abdominal pain, malaise, and reduced bowel movements. Diagnosis is typically made through ultrasound or CT scans. Smaller abscesses can be treated with antibiotics, while larger abscesses often require drainage, usually through percutaneous drainage guided by ultrasound (45). Less frequently seen complications are hematoma, wound dehiscence and fistula formation. Fecal fistula is a rare complication, and can occur due to necrosis of the base of the cecum caused by an abscess, a drain, or inappropriate ligation of the appendix during appendectomy (57).

#### 1.5. DIFFERENTIAL DIAGNOSIS

Despite the fact that acute appendicitis is the leading cause of acute abdomen in children, there are several other conditions that can cause similar symptoms and duration (61). Conditions that should be considered in the differential diagnosis of acute appendicitis in children include gynecological, urological, abdominal and inflammatory conditions. In childhood, acute appendicitis is frequently misdiagnosed as gastrointestinal conditions such as gastroenteritis, acute mesenteric adenitis, and sometimes constipation, intussuseption or inflammatory bowel disease. In addition to promptly diagnose AA, it is essential to accurately diagnose other diseases that require urgent surgical intervention (17, 61, 62). The medical history with the

duration and progression of disease is a crucial component to help clinicians distinguish the diseases from one another (63).

The most common misdiagnosis in patients <5 years is gastroenteritis (64). Patients with acute appendicitis primarily experience abdominal pain, while the presence of general symptoms like headache, chills, and myalgia suggests gastroenteritis as a possible differential diagnosis (61). Additionally, most patients with acute appendicitis report multiple episodes of vomiting within the initial 24 to 48 hours of the disease, whereas vomiting may be the predominant symptom in the early stages of gastroenteritis (11). Mesenteric adenitis is inflammation of the lymph nodes in the mesentery that links the intestine to the abdominal wall, and can present with abdominal pain, fever, and diarrhea (65). Meckel's diverticulum, the most common congenital defect of the gastrointestinal system, is a remnant of the vitelline duct which forms an outpouching of the intestine. It can present with gastrointestinal bleeding, abdominal pain, inflammation or even perforation. Distinguishing Meckel's diverticulitis from acute appendicitis is exceedingly challenging, and the diagnosis is typically made during surgery (16).

Diseases related to the female reproductive system can frequently be misdiagnosed as acute appendicitis. Conditions to consider include pelvic inflammatory disease (PID), rupture or torsion of an ovarian cyst or tumor, endometriosis, and ectopic pregnancy (66). PID commonly present with bilateral symptoms, but in cases limited to the right side, they can mimic acute appendicitis but with pain localized slightly lower in the suprapubic region (12). Rupture of ovarian follicles is associated with ovulation and frequently results in lateralized pain during the middle of the menstrual cycle, but without progression or systemic signs of the disease. Ovarian torsion is characterized by the twisting of the ovary on its blood supply, leading to abrupt and intense pain in the lower abdomen, frequently accompanied by symptoms of nausea and vomiting (16).

Symptoms involving the urinary tract can mimic symptoms of AA. Urinary tract infection can result in lower abdominal pain, fever, and urinary symptoms including urgency, frequency, and dysuria. In uncertain cases of acute abdomen, imaging modalities such as CT and ultrasound is helpful in reaching the accurate diagnosis (67).

## 1.6. HYPONATREMIA IN CHILDREN WITH ACUTE APPENDICITIS

The measurement of serum sodium is a low cost lab test routinely performed in patients. Hyponatremia has already been linked to other severe inflammatory conditions such as cholecystitis, ischemic bowel and perforation of bowel and intraabdominal (68, 69). Recent studies have investigated the potential role of hyponatremia as a diagnostic biomarker in complicated acute appendicitis, and found a significant correlation between hyponatremia and complicated AA. These studies conclude that low sodium level can supplement the preoperative risk assessment and hereby aid in the diagnosis of complicated appendicitis (18, 21, 70–74). Although the exact pathophysiological mechanism behind hyponatremia in complicated AA remains unknown, there is data to support pro-inflammatory cytokines, such as IL-6, have a role in the non-osmotic release of ADH. The circulating cytokines have the ability to cross the blood brain barrier, where they act on neurons involved in water and electrolyte homeostasis. This results in ADH release, which acts on the kidneys to increase free water reabsorption and causes dilutional hyponatremia due to expansion of the plasma volume. Although several studies has been conducted to investigate the association between hyponatremia and other severe inflammatory reactions, the exact pathophysiological mechanism behind it remains to be known (75–77).

Patients with AA often present with various degrees of dehydration, which again activates ADH release (78). The same mechanism as mentioned earlier will cause the kidneys to retain water, and the result is dilutional hyponatremia. Based on this, isotonic solutions should be preferred over hypotonic solutions to avoid further reduction in blood sodium levels (79).

## **2. OBJECTIVES**

## 2.1. AIM OF STUDY

Acute appendicitis is the most common cause of acute abdomen in pediatric patients, and yet it remains a diagnostic challenge to clinicians worldwide. Children present with high rates of initial misdiagnosis and subsequent complications including perforation. The purpose of this study is to create a meta-analysis which investigates all available data on hyponatremia as a diagnostic marker of complicated appendicitis in the pediatric population, and its potential role as a novel biomarker.

## 2.2. HYPOTHESIS

We propose a hypothesis that there is a correlation between hyponatremia and complicated presentation of acute appendicitis in children, which may have potential to aid in the diagnostic process.

### **3. PATIENTS AND METHODS**

### 3.1. STUDY DESIGN

This diploma thesis was designed as a meta-analysis consisting of seven studies, five of which had a retrospective study design and the remaining two being prospective studies. This study design did not require an approval from the Ethics Committee of the University of Split, School of Medicine. The study was executed under the Department of Pediatric Surgery, University Hospital of Split in Croatia in collaboration with the Department of Pediatric Surgery, All India Institute of Medical Sciences, New Delhi.

### 3.2. SEARCH STRATEGY

The literature search was carried out in accordance with the PRISMA (the Preferred Reporting items for Systematic Reviews and Meta-Analyses) guidelines (80). On May 5th 2022, two investigators independently performed the systematic search in the following databases: PubMed, EMBASE, Web of Science, and Scopus (Table 3). The search keywords (hyponatremia) AND (appendicitis) AND (children) were utilized. The total search records underwent analysis, and duplicate entries were excluded. The eligibility criteria were then applied to the remaining research studies to identify the relevant articles to be included in the meta-analysis.

**Table 3.** Detailed search strategy.

<b>Database</b>	<b>Studies</b>
PubMed	11
EMBASE	25
SCOPUS	26
Web of Science	13
Additional records from other sources	01
<b>Total</b>	<b>76</b>
<b>Duplications</b>	<b>33</b>
<b>After duplications removal</b>	<b>43</b>

EMBASE: Excerpta Medica dataBASE



### 3.3. ELIGIBILITY CRITERIA

To identify the relevant studies to be included in this meta-analysis, a set of inclusion criteria were utilized in the literature search. The eligible studies were selected using the following inclusion criteria:

- 1. Patient population:** All patients under the age of 18 with complicated acute appendicitis.
- 2. Intervention:** Surgical treatment, including open or laparoscopic appendectomy, or conservative management of acute appendicitis.
- 3. Comparison:** Children <18 years with non-complicated acute appendicitis.
- 4. Outcome:** The outcome of interest is the serum sodium levels in children with complicated acute appendicitis.
- 5. Study Design:** All comparative studies with exact serum sodium levels in children under the age of 18 with complicated acute appendicitis were included. The definition of complicated appendicitis was perforated or gangrenous appendix, intra-abdominal abscess and/or fecal peritonitis. The patients without these features were grouped into the non-complicated group. Studies showing incomplete data or where the outcomes of interest were not reported were excluded. Articles to be excluded were case reports, literature reviews, commentaries, editorials, conference abstracts and expert opinion articles (Table 3).

### 3.4. DATA EXTRACTION

Following the retrieval of the search results, data synthesis was carried out by two independent investigators using Microsoft Excel spreadsheets. Included in the extracted data from each study was the first author, publication year, study design, sample size, average age of the cohort, and the average  $\pm$  standard deviation serum sodium levels in each patient group. In the event of disagreements, they were resolved by discussions and reaching a consensus with the involvement of the senior author. During the process of data extraction, children diagnosed with complicated appendicitis were allocated to group A, while those with non-complicated appendicitis were assigned to group B.

### 3.5. METHODOLOGICAL QUALITY ASSESSMENT

Two investigators independently assessed the methodological quality using the Downs and Black checklist. This is a validated scale consisting of 27 assessment points that address the following four components: reporting, external validity, internal validity and power. This yields a score between 0 and 32, and based on these scores the risk of bias was categorized as high (0–15), moderate (16–23), or low (>23) (81). Subsequently, kappa statistics were used to identify the level of inter-rater agreement regarding the risk of bias (82). The degree of agreement was classified as slight (0.00–0.20), fair (0.21–0.40), moderate (0.41–0.60), significant (0.61–0.80) and almost perfect (0.81–1.00) Table 4 displays the evaluation by the two observers. The inter-observer agreement in this meta-analysis was in the highest ranking.

**Table 4.** Independent methodological quality assessment by two observers utilizing the Downs and Black scale.

<b>Study</b>	<b>Reporting</b>	<b>External Validity</b>	<b>Internal Validity- Bias</b>	<b>Internal Validity- Confounding</b>	<b>Power</b>	<b>Total Scores</b>
<i>Methodological assessment by Observer 1</i>						
Pham et al., 2016	7	3	5	3	5	23
Besli et al., 2019	9	3	4	3	5	24
Lindestam et al., 2019	10	3	5	3	5	26
Yang et al., 2019	10	3	4	3	5	25
Pogorelić et al., 2021	11	3	5	4	5	28
Duman et al., 2022	9	3	5	3	5	25
Walsh et al., 2022	9	3	5	3	5	25
<i>Methodological assessment by Observer 2</i>						
Pham et al., 2016	9	3	5	3	5	25
Besli et al., 2019	9	3	5	3	5	25
Lindestam et al., 2019	11	3	4	4	5	27
Yang et al., 2019	11	3	4	4	5	27
Pogorelić et al., 2021	11	3	4	4	5	27
Duman et al., 2022	9	3	5	3	5	25
Walsh et al., 2022	9	3	4	3	5	24
<i>Total score and inter-observer agreement</i>						
<b>Study</b>	<b>Observer 1</b>	<b>Observer 2</b>	<b>Mean</b>	<b>Kappa value</b>	<b>P</b>	
Pham et al., 2016	23	25	24	0.91	<0.0001	
Besli et al., 2019	24	25	24.5			
Lindestam et al., 2019	26	27	26.5			
Yang et al., 2019	25	27	26			
Pogorelić et al., 2021	28	27	27.5			
Duman et al., 2022	25	25	25			
Walsh et al., 2022	25	24	24.5			

### 3.6. STATISTICAL ANALYSIS (QUANTITATIVE SYNTHESIS)

All extracted data was expressed as mean  $\pm$  standard deviation (SD). The quantitative analysis in the meta-analysis was performed using the Cochrane Collaboration system RevMan 5.4. The mean difference (MD) was calculated for each of the studies included.

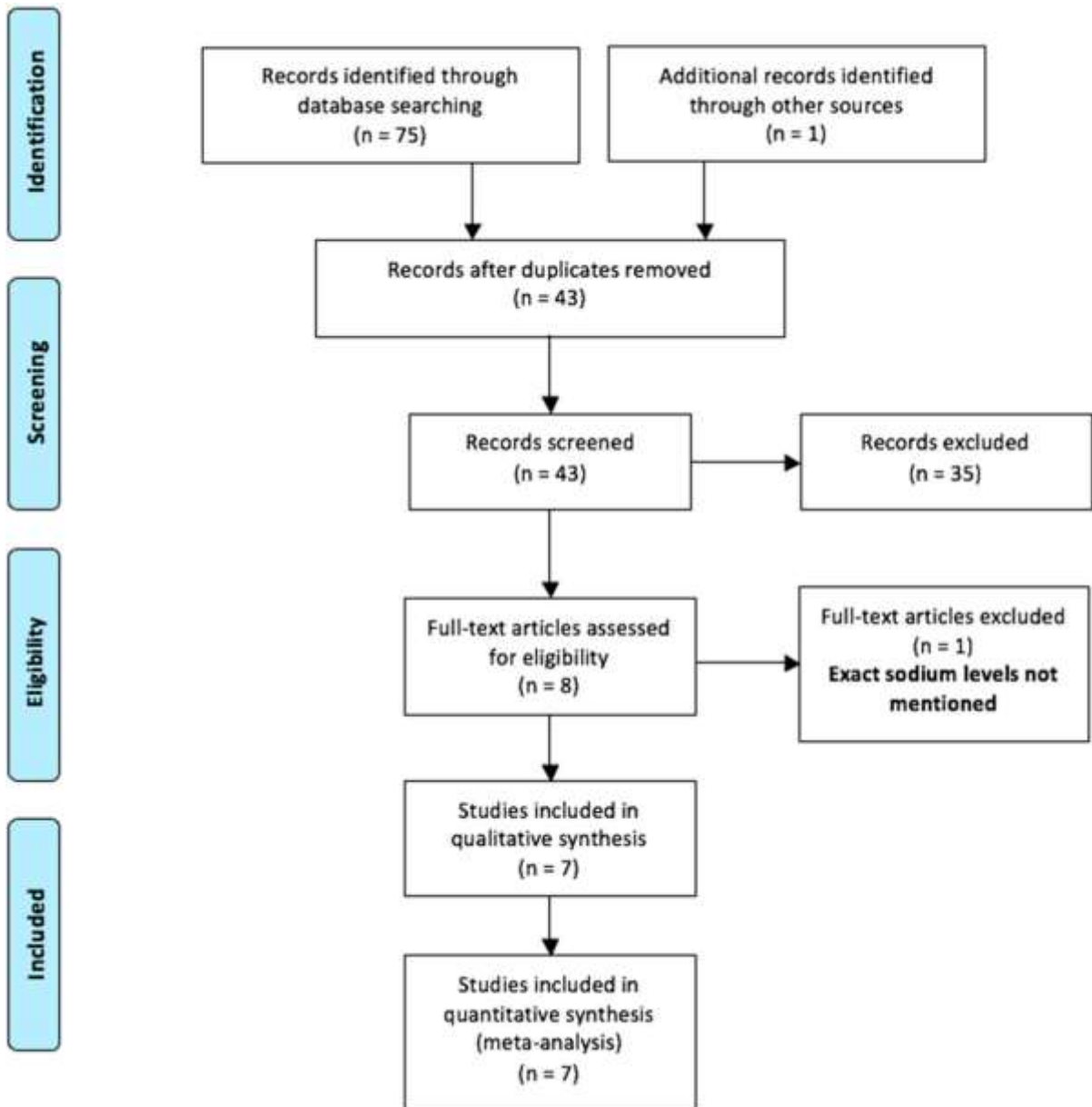
Subsequently, the inverse variance (IV) method was utilized to estimate the weighted mean difference (WMD). To assess the level of heterogeneity among the included studies,  $I^2$  statistics were employed. Heterogeneity was considered substantial if the  $I^2$  value exceeded 50%, and in the event of substantial heterogeneity, a random-effects model was utilized. Statistical significance was defined as a  $P$ -value  $<0.05$ .

## **4. RESULTS**

#### 4.1. STUDY CHARACTERISTICS

The database search resulted in the identification of 76 publications in total (Figure 1). 33 of these were duplicate articles and therefore eliminated. Another 35 of the 43 remaining records were rejected. 8 full texts were evaluated for eligibility. After full text evaluation, another study was removed due to imprecise serum sodium levels (22). Thus, the final meta-analysis included a total of 7 studies (18, 21, 70–74). Retrospective research designs were used in 5 of these 7 studies (18, 21, 70, 72, 73). A total of 4423 subjects were included in the meta-analysis, with 1615 patient in group A and 2808 patients in group B respectively.

Baseline characteristics from each study are demonstrated in Table 5, including the study design, gender of the patients, number of patients, and the proportion of complicated and non-complicated cases of acute appendicitis. In all included studies, there were disproportionately more male subjects, with a male to female ratio of 2:1. Table 5 additionally lists other biomarkers that were investigated in each research, including WBC, CRP, glucose, bilirubin, among other various biomarkers.



**Figure 7.** The method of screening for relevant studies using PRISMA (Preferred Reporting Items for Systematic Review and Meta-Analysis) flow diagram.

**Table 5.** Baseline characteristics of the included studies.

Author	Study Design	Sample size		Gender (% Males)		Other Biomarkers Investigated
		Gp A	Gp B	Gp A	Gp B	
Pham et al., 2016 (21)	Retro	179	213	63%	69%	WBC
Besli et al., 2019 (70)	Retro	245	158	70%	64%	WBC, NP, CRP
Lindestam et al., 2019 (74)	Pro	15	65	80%	63%	CRP, WBC, plasma glucose, BE, plasma AVP
Yang et al., 2019 (83)	Retro	613	1282	54%	52%	CRP, WBC, NP, PC, PCT, DLAC, Bilirubin, AST, ALT
Pogorelić et al., 2021 (71)	Pro	38	146	71%	63%	WBC, CRP, NP, potassium, chloride, glucose
Duman et al., 2022 (73)	Retro	82	254	2:1 *		CRP, WBC, NP, MLR, NLR, PLR, MPV
Walsh et al., 2022 (72)	Retro	443	690	60%	61.4%	-

**Abbreviations:** Retro—retrospective study; Pro – prospective study; Gp A – (group A), acute complicated appendicitis; Gp B – (group B), acute non-complicated appendicitis; CRP – C-reactive protein; WBC – white blood cell count; BE – Base excess; NP – neutrophil percentage; MLR – monocyte-to-lymphocyte ratio; NLR – neutrophil-to-lymphocyte ratio; PLR – platelet-to-lymphocyte ratio; MPV – mean platelet volume; AVP – arginine vasopressin; PC – platelet count; PCT– procalcitonin; DLAC – D-lactate; AST – aspartate aminotransferase; ALT – alanine aminotransferase.

\* Group-wise gender distribution was not included. In this study, M:F ratio was 2:1.

#### 4.2. SUMMARY OF THE INCLUDED STUDIES

##### **Pham et al., 2016 (21)**

A retrospective study with a total of 392 patients <12 years of age with acute appendicitis were examined, of which whom 46% of them were complicated cases. The median age of the patients was 8 and 9 years for complicated and uncomplicated appendicitis, respectively. In this study, hyponatremia (OR=3.1, 95% CI=2.0–4.9,  $P<0.01$ ) was demonstrated to be an independent diagnostic marker of complicated appendicitis. When compared to patients with non-complicated appendicitis, patients with difficult appendicitis had substantially lower serum sodium levels (134 mEq/L vs. 137 mEq/L,  $P<0.01$ ). In addition, the study found symptom duration >24h and leukocytosis to be predictors of complicated acute appendicitis.



**Besli et al., 2019 (70)**

This retrospective study included 403 patients with acute appendicitis in total. 39.2% of individuals presented with non-complicated appendicitis and the remaining 60.8% had complicated AA. The mean age for the groups of uncomplicated and complicated appendicitis were 11.3 and 11.4 years, respectively. Regarding hyponatremia, leukocytosis, and neutrophilia, there was no reported difference between the two groups ( $P>0.05$ ). The baseline serum sodium levels of individuals with complicated appendicitis were lower ( $P=0.004$ ;  $P<0.05$ ). The cut-off value for sodium was  $\leq 138$  mEq/L for the diagnosis of complicated appendicitis (sensitivity = 82.5%, specificity = 31.1%).

**Lindestam et al., 2019 (74)**

A prospective study with a total of 80 children with histopathological confirmed AA, of which 12% of subjects were in the group of complicated appendicitis. The reported median age in the complicated appendicitis group was 7.5 years, and 9.2 years for the group with uncomplicated appendicitis. Upon admission, the median plasma sodium level was significantly lower (134 mmol/L, IQR 132–136) in patients with complicated cases of appendicitis, compared with the serum sodium levels of the non-complicated group (139 mmol/L, IQR 137–140). A cutoff value of serum sodium of  $\leq 136$  mmol/L gave the best sensitivity (82%) and specificity (87%). This study also investigated levels of AVP, which was found to be higher in children with perforated appendicitis (8.6 pg/mL) when compared to non-complicated cases (3.4 pg/mL).

**Yang et al., 2019 (18)**

This is a retrospective study with 1892 pediatric patients in the age group 3-18 years with confirmed AA. Significantly lower serum sodium levels were demonstrated in complicated appendicitis when compared to patients with non-complicated appendicitis (133 mEq/L vs. 137 mEq/L,  $P=0.001$ ). The median age of the individuals allocated to the group with complicated appendicitis was 5 years. The mean age in the other group with non-complicated appendicitis was 9 years. The study also emphasized the importance of WBC count, C-reactive protein, and neutrophils percentage in identifying complicated from non-complicated appendicitis.

**Pogorelić et. al., 2021 (71)**

This is a prospective study which was conducted to investigate the potential of hyponatremia as a new biochemical marker for complicated appendicitis in children. 184 patients were included and histopathologically confirmed. A total of 79.3% children had non-complicated appendicitis and 20.7% had complicated appendicitis. The group of complicated appendicitis had a median age of 10.4 years and the group with non-complicated appendicitis had a median age of 11.6 years. The serum sodium levels were found to be significantly lower in the patients with complicated appendicitis compared with non-complicated cases (132.2 mmol/L vs. 139.2 mmol/L,  $P < 0.001$ ). A cut-off value of  $\leq 135$  mmol/L of serum sodium levels demonstrated the best sensitivity, 94.7% (95% CI: 82.2–99.3) and specificity, 88.5% (95% CI: 88.2–93.2) ( $P < 0.001$ ).

**Duman et al., 2022 (73)**

A total of 683 subjects were included in this retrospective study, of which 82 patients had complicated appendicitis and 254 had non-complicated acute appendicitis. Of the remaining patients in the cohort, 197 had nonspecific abdominal pain and 150 subjects were controls. The median age reported was 10.2 years in the non-complicated group and 9.4 years in the group of individuals with complicated appendicitis. According to this study, individuals with acute appendicitis had significantly lower serum levels levels ( $P < 0.05$ ). With a sensitivity of 72% and a specificity of 42%, appendicitis could be detected using a cut-off serum sodium of 137 mmol/L. On the other hand, there was no significant difference between the groups with acute appendicitis and complicated appendicitis.

**Walsh et al., 2022 (72)**

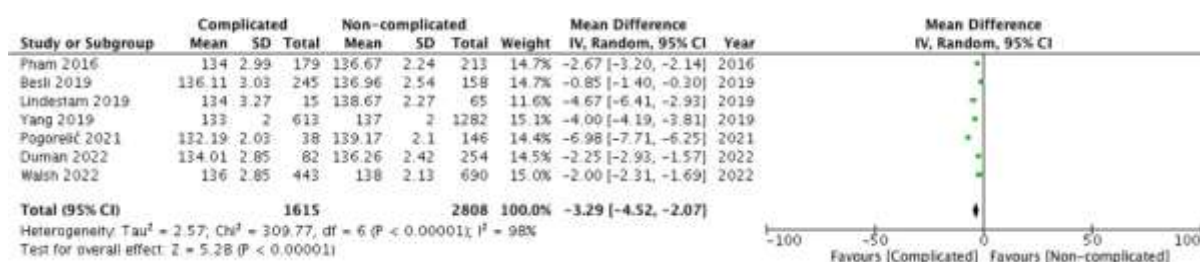
A retrospective study including 1283 pediatric patients  $\leq 15$  years of age that underwent appendectomy. About 35% of these patients had complicated appendicitis, 54% had non-complicated appendicitis, and 3.8% had no appendicitis at all. Patients with complicated appendicitis had a median age of 10 years, whereas those with non-complicated appendicitis had a median age of 11.5 years. Between the three patient groups, there was a considerable disparity in the levels of serum sodium. 31.4% of the complicated group, 3.8% of the non-complex group, and 10.7% of the group without appendicitis were reported to have hyponatremia. The study suggest that complicated appendicitis can be 36iagnose dusing a cut-off blood sodium level of 135 mmol/L with a sensitivity and a specificity of 31.4% and 95.7%, respectively.

### 4.3. METHODOLOGICAL QUALITY ASSESSMENT

Table 4 displays the thorough assessment of quality performed by two independent observers. The average ratings given to the included studies on the Downs and Black scale varied from 24 to 27.5. All included studies had a low risk of bias. The lowest scoring study was the retrospective study by Pham et al., with a score of 24, whereas the study by Pogorelić et al. Had the lowest risk of bias with a score of 27.5. Subsequently, the inter-observer agreement was assessed by using kappa statistics and found to be nearly excellent (Kappa = 0.91,  $P < 0.0001$ ).

### 4.4. OUTCOME ANALYSIS

Seven studies reporting hyponatremia in children with complicated AA were included in this meta-analysis. In total, 1615 and 2808 patients were allocated to group A and B, respectively. The results of this study concluded that children in group A had considerably lower serum sodium levels compared to those in group B (WMD: -3.29, 95% CI=-4.52 to -2.07,  $P < 0.00001$ ). The estimated heterogeneity among the included research was statistically significant and substantial ( $I^2=98\%$ ,  $P < 0.00001$ ).



**Figure 8.** Forest plot comparing the serum sodium levels of group A (children with complicated appendicitis) and group B (non-complicated acute appendicitis).  
 Abbreviations: SD – standard deviation; IV – inverse variance; CI – H interval

## **6. DISCUSSION**

The results of this meta-analysis strongly suggest that hyponatremia could be a new predictive biomarker of complicated appendicitis in pediatric patients. Patients with perforated acute appendicitis had significantly lower serum sodium concentrations compared to patients with non-perforated appendicitis. This finding can aid clinicians and surgeons in regard to diagnostic procedures, decision-making and management of children with complicated appendicitis.

This meta-analysis included seven studies that investigated if there is an association between hyponatremia and complicated appendicitis in pediatric patients (21, 70–74, 83). Among these studies, statistically significant results were found in five of them (21, 71, 72, 74, 83). Furthermore, five out of the seven studies had a retrospective design, while the remaining two were prospective studies. The total number of patients among all seven studies was 4423, ranging from 1895 subjects in the largest study and 80 subjects in the smallest study. The largest sample size was in the study by Yang et al, with a total of 1895 patients. In addition to serum sodium levels, it investigated a range of biomarkers, hereby confirming the association between complicated appendicitis and former known markers, including increased CRP levels, leukocytosis and prolonged duration of symptoms. The study found that CRP levels above 8mg/dL, together with elevated neutrophils >74%, increased the likelihood of complicated appendicitis by more than 5 times (18). Although some studies have suggested that hyponatremia considered together with WBC and CRP can enhance sensitivity and specificity and is therefore more accurate in the differentiation of complicated and uncomplicated appendicitis, the studies by Pham et al. And Walsh et al. challenge this (21, 25, 72). Pham et al. provided significant findings in numerous logistic regression analysis (OR=3.1, 95% CI=2.0–4.9,  $p<0.01$ ) to support the role of hyponatremia as an independent predictor of complicated appendicitis, further supported by Walsh et al. (21, 72).

The studies by Lindestam et al. and Pogorelić et al. were prospective studies. These offered a larger contribution by consolidating previously determined reports of statistically significant levels of hyponatremia in subjects with complicated AA, in comparison to non-complicated presentations of appendicitis. The study by Pogorelić et al., reported the most significant differences in serum sodium levels between group A and B among the included studies, with mean sodium levels of 132.2 mmol/L and 139.2 mmol/L, respectively. Both the prospective studies reported that the patients whom were initially sampled at the emergency department and later eliminated from the study if they were not verified histopathologically, measured mean sodium levels similar to those with non-complicated appendicitis (71, 74).

Two of the studies included in this meta-analysis did not demonstrate a correlation between hyponatremia and complicated appendicitis in children, and the literature is therefore inconsistent. Duman et al. had a cut-off value for serum sodium of  $<137$  mmol/L, in addition to investigating a variation of biomarkers. Besli et al. had a cutoff value of  $\leq 138$  mmol/L. As for the other markers investigated, a correlation with complicated appendicitis was not established.

There are certain limitations in this meta-analysis to consider. Hyponatremia as a biomarker for complicated appendicitis in children is a relatively new topic in research, with a limited amount of available studies to this date. Most of the included articles are single-center studies of retrospective study design. The cut-off value for hyponatremia also varied among the included studies. Three of them used  $\leq 135$  mmol/L as the definition, while the remaining four studies used cut-off values of  $<135$  mmol/L,  $\leq 136$  mmol/L,  $<137$  mmol/L, and  $\leq 138$  mmol/L. Since 135 mmol/L is considered the lower normal range for serum sodium levels, it is proposed to be the cut-off value for hyponatremia in complicated appendicitis, but further studies are required to recommend this. Several of the studies included only the serum sodium levels at admission, without follow-up laboratory test, and therefore does not include information regarding the development of sodium levels as the condition progresses. Additionally, the included studies focused on the association between hyponatremia and macroscopic pathological findings, without investigating the relationship between the severity of hyponatremia and histopathological changes. Finally, the study by Walsh et al. had incomplete data and solely included patients undergoing appendectomy for suspected acute appendicitis, rather than the total sample of children who were admitted with a clinical suspicion of AA.

Although acute appendicitis is the most common cause of acute abdomen in the pediatric population, it still poses a diagnostic challenge to clinicians worldwide. The diagnosis of acute appendicitis is based on a combination of anamnesis, physical findings, scoring systems and laboratory markers, with the most commonly measured biomarkers in patients with suspected acute appendicitis being WBC and CRP (23). Young children, especially  $<5$  years, often present with atypical symptoms and have a longer total duration of symptoms before the accurate diagnosis is set. Additionally, young children lack or have limited language to vocalize their symptoms and course of disease (15). Initial misdiagnosis rates in children are as high as 28%-57% in children between 2-12 years, which causes significant diagnostic delays (15). Children  $<1$  year of age with acute appendicitis are often suspected to suffer from acute gastroenteritis, and are therefore misdiagnosed in up to 100% of cases, which is reflected in the rate of perforated presentations (64). Delayed diagnosis can lead to complications such as perforation,

abscess formation, peritonitis and bowel obstruction. Consequently children have high rates of perforation upon presentation. To this day, there is no single symptom or sign reliable in predicting perforation (22). When patients experience perforation of the appendix due to delayed or missed diagnosis, as well as delayed presentation, their hospital stays tend to be prolonged. In such cases, additional invasive procedures like percutaneous drainage of abscesses are often required, along with extended courses of antibiotics (42). This mandates a need for more reliable diagnostic tools to aid in the diagnosis of acute appendicitis and to predict perforation.

Hyponatremia has been linked to severe inflammatory conditions ranging from cholecystitis to intraabdominal sepsis (68, 76). Although the exact mechanism behind lower sodium levels in severe disease has yet to be fully understood, there are several proposed theories. There is data to support the theory of non-osmotic release of ADH in patients with acute appendicitis. Circulating pro-inflammatory cytokines including IL-6, cross the blood-brain barrier where it acts on the paraventricular and the supraoptic nucleus. Subsequently, ADH is released via non-osmotic stimulation. ADH causes the kidneys to increase its free water reabsorption and hereby cause dilutional hyponatremia (75–77). Patients with acute appendicitis are frequently dehydrated, which also activates the secretion of ADH (78).

Not only is serum sodium demonstrated to be a predictive biomarker for distinguishing perforated from non-complicated acute appendicitis in this meta-analysis, it is also a readily available, low cost test in emergency health care facilities. This can be a valuable addition to the diagnostic tools already in use in the management of children with acute appendicitis.

## **6. CONCLUSION**



To conclude, the results of this meta-analysis demonstrate that hyponatremia is a predictor of complicated appendicitis in pediatric patients. Patients with perforated acute appendicitis had significantly lower serum sodium concentrations compared to patients with non-perforated appendicitis. The measurement of serum sodium is a low-cost, easily performed and readily available test, and these findings may aid clinicians and surgeons in terms of diagnostic procedures, decision-making and management of pediatric patients with complicated appendicitis. However, further prospective studies are required to investigate the association between hyponatremia and complicated acute appendicitis.

## **7. REFERENCES**

1. Sadler TW. Digestive system. In: Sadler TW, editors. Langman's medical embryology. 14th ed. Philadelphia: Wolters Kluwer; 2019. p. 244–8.
2. Ali Malas M, Sulak O, Gökcimen A, Sari A. Development of the vermiform appendix during the fetal period. *Surg Radiol Anat.* 2004;26:202–7.
3. Mescher AL, Junqueira LCU. Digestive tract. In: Mescher AL, Junqueira LCU, editors. Junqueira's basic histology. 14th ed. Mcgraw-Hill Education; 2016. p. 295-328.
4. Hodge BD, Kashyap S, Khorasani-Zadeh A. Anatomy, abdomen and pelvis: appendix. In: StatPearls [Internet]. Treasure Island (FL): StatPearls Publishing; 2023 [cited 2023 Jun 8]. Available from: <http://www.ncbi.nlm.nih.gov/books/NBK459205/>
5. Kooij IA, Sahami S, Meijer SL, Buskens CJ, Te Velde AA. The immunology of the vermiform appendix: a review of the literature. *Clin Exp Immunol.* 2016;186:1–9.
6. Moore KL, Dalley AF, Agur AMR. Abdomen. In: Moore KL, Dalley AF, Agur AMR, editors. Clinically oriented anatomy. 7th ed. Philadelphia: Lippincott Williams and Wilkins; 2017. p. 249–50.
7. Park NH, Oh HE, Park HJ, Park JY. Ultrasonography of normal and abnormal appendix in children. *World J Radiol.* 2011;3:85–91.
8. Deshmukh S, Verde F, Johnson PT, Fishman EK, Macura KJ. Anatomical variants and pathologies of the vermiform appendix. *Emerg Radiol.* 2014;21:543–52.
9. Vitetta L. The vermiform cecal appendix, expendable or essential? A narrative review. *Curr Opin Gastroenterol.* 2022;38:570–6.
10. Vitetta L, Chen J, Clarke S. The vermiform appendix: an immunological organ sustaining a microbiome inoculum. *Clin Sci.* 2019;133:1–8.
11. Kliegman R, Nelson WE. Acute appendicitis. In: Aiken JJ, Oldham KT, editors. Nelson Textbook of Pediatrics. 19th ed. Philadelphia: Elsevier/Saunders; 2011. p. 1349–55.
12. Liang MK, Andersson RE, Jaffe BM, Berger DH. Schwartz's Principles of Surgery. 10th ed. New York: Mcgraw-Hill Education; 2014.

13. Téoule P, Laffolie J de, Rolle U, Reissfelder C. Acute appendicitis in childhood and adulthood. *Dtsch Arzteblatt Int.* 2020;117:764–74.
14. Pogorelić Z, Domjanović J, Jukić M, Poklepović Peričić T. Acute appendicitis in children younger than five years of age: diagnostic challenge for pediatric surgeons. *Surg Infect.* 2020;21:239–45.
15. Almaramhy HH. Acute appendicitis in young children less than 5 years: review article. *Ital J Pediatr.* 2017;43:15.
16. Sinha CK, Davenport M, editors. *Handbook of Pediatric Surgery* [Internet]. London: Springer London; 2010 [cited 2023 Jun 12]. Available from: <http://link.springer.com/10.1007/978-1-84882-132-3>
17. Jones MW, Lopez RA, Deppen JG. Appendicitis. In: *StatPearls* [Internet]. Treasure Island (FL): StatPearls Publishing; 2023 [cited 2023 Jun 12]. Available from: <http://www.ncbi.nlm.nih.gov/books/NBK493193/>
18. Yang J, Liu C, He Y, Cai Z. Laboratory markers in the prediction of acute perforated appendicitis in children. *Emerg Med Int.* 2019;2019:1–4.
19. Gadiparthi R, Waseem M. Pediatric Appendicitis. In: *StatPearls* [Internet]. Treasure Island (FL): StatPearls Publishing; 2023 [cited 2023 Jun 14]. Available from: <http://www.ncbi.nlm.nih.gov/books/NBK441864/>
20. Echevarria S, Rauf F, Hussain N, Zaka H, Farwa UE, Ahsan N, et al. Typical and atypical presentations of appendicitis and their implications for diagnosis and treatment: a literature review. *Cureus.* 2023;15:e37024.
21. Pham XBD, Sullins VF, Kim DY, Range B, Kaji AH, de Virgilio CM, et al. Factors predictive of complicated appendicitis in children. *J Surg Res.* 2016;206:62–6.
22. Howell EC, Dubina ED, Lee SL. Perforation risk in pediatric appendicitis: assessment and management. *Pediatr Health Med Ther.* 2018;9:135–45.
23. Yang HR, Wang YC, Chung PK, Chen WK, Jeng LB, Chen RJ. Laboratory tests in patients with acute appendicitis. *ANZ J Surg.* 2006;76:71–4.

24. Pepys MB, Hirschfield GM. C-reactive protein: a critical update. *J Clin Invest.* 2003;111:1805–12.
25. Withers AS, Grieve A, Loveland JA. Correlation of white cell count and CRP in acute appendicitis in paediatric patients. *South Afr J Surg Suid-Afr Tydskr Vir Chir.* 2019;57:40.
26. Zouari M, Louati H, Abid I, Ben Abdallah AK, Ben Dhaou M, Jallouli M, et al. C-reactive protein value is a strong predictor of acute appendicitis in young children. *Am J Emerg Med.* 2018;36:1319–20.
27. Pogorelić Z, Rak S, Mrklič I, Jurić I. Prospective validation of Alvarado score and pediatric appendicitis score for the diagnosis of acute appendicitis in children: *Pediatr Emerg Care.* 2015;31:164–8.
28. Chen CY, Zhao LL, Lin YR, Wu KH, Wu HP. Different urinalysis appearances in children with simple and perforated appendicitis. *Am J Emerg Med.* 2013;31:1560–3.
29. Pian P, Chang Q, Zhou G, Li L, Wang W, Mu Y. Diagnostic value of serum procalcitonin in appendicitis in infants and young children: retrospective cohort study. *Clin Lab [Internet].* 2021;67(11/2021). Available from: <http://www.clin-lab-publications.com/article/3927>
30. Abbas MH, Choudhry MN, Hamza N, Ali B, Amin AA, Ammori BJ. Admission levels of serum amyloid a and procalcitonin are more predictive of the diagnosis of acute appendicitis compared with C-reactive protein. *Surg Laparosc Endosc Percutan Tech.* 2014;24:488–94.
31. Debnath J, George RA, Ravikumar R. Imaging in acute appendicitis: What, when, and why? *Med J Armed Forces India.* 2017;73:74–9.
32. Tong L, Nataraja RM, VanHaltren K, Sulaksana TH, Vinycomb TI, Pacilli M. The utility of sonographic signs to diagnose simple and complicated appendicitis in children. *Pediatr Surg Int.* 2023;39:114.
33. Xu X, Ye J. Clinical value of abdominal ultrasonography in the diagnosis of acute abdomen in children. *Contrast Media Mol Imaging.* 2022;2022:2681543.

34. Awayshih MMA, Nofal MN, Yousef AJ. Evaluation of Alvarado score in diagnosing acute appendicitis. *Pan Afr Med J.* 2019;34:15.
35. Alvarado A. A practical score for the early diagnosis of acute appendicitis. *Ann Emerg Med.* 1986;15:557–64.
36. Lovell J. Calculated decisions: Pediatric appendicitis score (PAS). *Pediatr Emerg Med Pract.* 2019;16:CD1–2.
37. Pogorelić Z, Mihanović J, Ninčević S, Lukšić B, Elezović Baloević S, Polašek O. Validity of appendicitis inflammatory response score in distinguishing perforated from non-perforated appendicitis in children. *Child Basel Switz.* 2021;8:309.
38. De Castro SMM, Ünlü Ç, Steller Eph, Van Wagenveld BA, Vrouwenraets BC. Evaluation of the appendicitis inflammatory response score for patients with acute appendicitis. *World J Surg.* 2012;36:1540–5.
39. Gudjonsdottir J, Marklund E, Hagander L, Salö M. Clinical prediction scores for pediatric appendicitis. *Eur J Pediatr Surg Off J Austrian Assoc Pediatr Surg Al Z Kinderchir.* 2021;31:252–60.
40. Andersson M, Kolodziej B, Andersson RE. Validation of the appendicitis inflammatory response (AIR) score. *World J Surg.* 2021;45:2081–91.
41. Liu Y, Cui Z, Zhang R. Laparoscopic versus open appendectomy for acute appendicitis in children. *Indian Pediatr.* 2017;54:938–41.
42. Di Saverio S, Podda M, De Simone B, Ceresoli M, Augustin G, Gori A, et al. Diagnosis and treatment of acute appendicitis: 2020 update of the WSES Jerusalem guidelines. *World J Emerg Surg WJES.* 2020;15:27.
43. Nguyen A, Lotfollahzadeh S. Appendectomy. In: StatPearls [Internet]. Treasure Island (FL): StatPearls Publishing; 2023 [cited 2023 Jun 16]. Available from: <http://www.ncbi.nlm.nih.gov/books/NBK580514/>
44. Snyder MJ, Guthrie M, Cagle S. Acute appendicitis: efficient diagnosis and management. *Am Fam Physician.* 2018;98:25–33.

45. Zani A, Hall NJ, Rahman A, Morini F, Pini Prato A, Friedmacher F, et al. European paediatric surgeons' association survey on the management of pediatric appendicitis. *Eur J Pediatr Surg Off J Austrian Assoc Pediatr Surg Al Z Kinderchir*. 2019;29:53–61.
46. Veziat J, Slim K. Laparoscopic appendectomy. *J Visc Surg*. 2014;151:223–8.
47. Podda M, Gerardi C, Cillara N, Fearnhead N, Gomes CA, Birindelli A, et al. Antibiotic treatment and appendectomy for uncomplicated acute appendicitis in adults and children: a systematic review and meta-analysis. *Ann Surg*. 2019;270:1028–40.
48. Vaos G, Dimopoulou A, Gkioka E, Zavras N. Immediate surgery or conservative treatment for complicated acute appendicitis in children? A meta-analysis. *J Pediatr Surg*. 2019;54:1365–71.
49. Perez Otero S, Metzger JW, Choi BH, Ramaraj A, Tashiro J, Kuenzler KA, et al. It's time to deconstruct treatment-failure: A randomized controlled trial of nonoperative management of uncomplicated pediatric appendicitis with antibiotics alone. *J Pediatr Surg*. 2022;57:56–62.
50. Jumah S, Wester T. Non-operative management of acute appendicitis in children. *Pediatr Surg Int*. 2022;39:11.
51. Armstrong J, Merritt N, Jones S, Scott L, Bütter A. Non-operative management of early, acute appendicitis in children: is it safe and effective? *J Pediatr Surg*. 2014;49:782–5.
52. Maita S, Andersson B, Svensson JF, Wester T. Nonoperative treatment for nonperforated appendicitis in children: a systematic review and meta-analysis. *Pediatr Surg Int*. 2020;36:261–9.
53. Fugazzola P, Coccolini F, Tomasoni M, Stella M, Ansaloni L. Early appendectomy vs. conservative management in complicated acute appendicitis in children: A meta-analysis. *J Pediatr Surg*. 2019;54:2234–41.
54. Gorter RR, Eker HH, Gorter-Stam MAW, Abis GSA, Acharya A, Ankersmit M, et al. Diagnosis and management of acute appendicitis. EAES consensus development conference 2015. *Surg Endosc*. 2016;30:4668–90.

55. Gonzalez KW, Dehmer JJ, Hendrickson RJ. Infantile perforated appendicitis: A forgotten diagnosis. *J Pediatr Surg Case Rep.* 2015;3:158–9.
56. Wu T, Yang Y, Wu Y, Lu L, Dong S. Complications after appendectomy in patients with treated appendicitis: results from a retrospective study. *Ann Palliat Med.* 2021;10:12546–53.
57. Pogorelić Z, Silov N, Jukić M, Elezović Baloević S, Poklepović Peričić T, Jerončić A. Ertapenem Monotherapy versus Gentamicin Plus Metronidazole for Perforated Appendicitis in Pediatric Patients. *Surg Infect.* 2019;20:625–30.
58. Blanco Verdú MD, Peláez Mata DJ, Gómez Sánchez A, Costa I Roig A, Carazo Palacios E, Proaño S, et al. Re-interventions following appendectomy in children: a multicenter study. *Cirugia Pediatr Organo Of Soc Espanola Cirugia Pediatr.* 2022;35:70–4.
59. Yang L, Zheng R, Li H, Ren Y, Chen H. The burden of appendicitis and surgical site infection of appendectomy worldwide. *J Infect Dev Ctries.* 2023;17:367–73.
60. Zhang S, Du T, Jiang X, Song C. Laparoscopic appendectomy in children with perforated appendicitis: a meta-analysis. *Surg Laparosc Endosc Percutan Tech.* 2017;27:262–6.
61. Raymond M, Marsicovetere P, DeShaney K. Diagnosing and managing acute abdominal pain in children. *JAAPA Off J Am Acad Physician Assist.* 2022;35:16–20.
62. McCollough M, Sharieff GQ. Abdominal pain in children. *Pediatr Clin North Am.* 2006;53:107–37.
63. Marin JR, Alpern ER. Abdominal pain in children. *Emerg Med Clin North Am.* 2011;29:401–28.
64. Marzuillo P, Germani C, Krauss BS, Barbi E. Appendicitis in children less than five years old: A challenge for the general practitioner. *World J Clin Pediatr.* 2015;4:19–24.
65. Otto M, Nagalli S. Mesenteric adenitis. In: StatPearls [Internet]. Treasure Island (FL): StatPearls Publishing; 2023 [cited 2023 Jun 12]. Available from: <http://www.ncbi.nlm.nih.gov/books/NBK560822/>



66. Pepper VK, Stanfill AB, Pearl RH. Diagnosis and management of pediatric appendicitis, intussusception, and meckel diverticulum. *Surg Clin North Am.* 2012;92:505–26.
67. Bundy DG, Byerley JS, Liles EA, Perrin EM, Katznelson J, Rice HE. Does this child have appendicitis? *JAMA* [Internet]. 2007;298. Available from: <http://jama.jamanetwork.com/article.aspx?doi=10.1001/jama.298.4.438>
68. Falor AE, Zobel M, Kaji A, Neville A, De Virgilio C. Admission variables predictive of gangrenous cholecystitis. *Am Surg.* 2012;78:1075–8.
69. O’Leary MP, Neville AL, Keeley JA, Kim DY, de Virgilio C, Plurad DS. Predictors of ischemic bowel in patients with small bowel obstruction. *Am Surg.* 2016;82:992–4.
70. Besli GE. Predictive value of serum sodium level in determining complicated appendicitis risk in children. *Haydarpasa Numune Train Res Hosp Med J* [Internet]. 2019 [cited 2023 Jun 13]; Available from: <http://hnhtipdergisi.com/jvi.aspx?un=HNHJ-16013>
71. Pogorelić Z, Lukšić B, Ninčević S, Lukšić B, Polašek O. Hyponatremia as a predictor of perforated acute appendicitis in pediatric population: A prospective study. *J Pediatr Surg.* 2021;56:1816–21.
72. Walsh A, Lala S, Wells C, Upadhyay V. Hyponatremia an indicator of complicated appendicitis in children: Starship experience. *ANZ J Surg.* 2022;92:747–52.
73. Duman L, Karaibrahimoğlu A, Büyükyavuz Bİ, Savaş MÇ. Diagnostic value of monocyte-to-lymphocyte ratio against other biomarkers in children with appendicitis. *Pediatr Emerg Care.* 2022;38:e739–42.
74. Lindestam U, Almström M, Jacks J, Malmquist P, Lönnqvist PA, Jensen BL, et al. Low plasma sodium concentration predicts perforated acute appendicitis in children: a prospective diagnostic accuracy study. *Eur J Pediatr Surg.* 2020;30:350–6.
75. Papanicolaou DA. The pathophysiologic roles of interleukin-6 in human disease. *Ann Intern Med.* 1998;128:127.
76. Alsaleh A, Pellino G, Christodoulides N, Malietzis G, Kontovounisios C. Hyponatremia could identify patients with intrabdominal sepsis and anastomotic leak after colorectal surgery: a systematic review of the literature. *Updat Surg.* 2019;71:17–20.

77. Swart RM, Hoorn EJ, Betjes MG, Zietse R. Hyponatremia and inflammation: the emerging role of interleukin-6 in osmoregulation. *Nephron Physiol.* 2010;118:p45–51.
78. Thornton SN. Thirst and hydration: physiology and consequences of dysfunction. *Physiol Behav.* 2010;100:15–21.
79. McNab S, Duke T, South M, Babl FE, Lee KJ, Arnup SJ, et al. 140 mmol/L of sodium versus 77 mmol/L of sodium in maintenance intravenous fluid therapy for children in hospital (PIMS): a randomised controlled double-blind trial. *Lancet Lond Engl.* 2015;385:1190–7.
80. Moher D, Liberati A, Tetzlaff J, Altman DG, PRISMA Group. Preferred reporting items for systematic reviews and meta-analyses: the PRISMA statement. *PLoS Med.* 2009;6:e1000097.
81. Downs SH, Black N. The feasibility of creating a checklist for the assessment of the methodological quality both of randomised and non-randomised studies of health care interventions. *J Epidemiol Community Health.* 1998;52:377–84.
82. Landis JR, Koch GG. The measurement of observer agreement for categorical data. *Biometrics.* 1977;33:159–74.
83. Yang J, Liu C, He Y, Cai Z. Laboratory markers in the prediction of acute perforated appendicitis in children. *Emerg Med Int.* 2019;4608053.

## **8. SUMMARY**

**Objectives:** In the search for new biomarkers in the diagnosis of complicated appendicitis in children, this meta-analysis aimed to investigate all available data on hyponatremia as a marker of complicated appendicitis in the pediatric population, and compare the levels of sodium in patients with non-complicated appendicitis.

**Materials and Methods:** A total of 4 databases were searched for relevant articles, using the search keywords (hyponatremia) AND (appendicitis) AND (children). All children with complicated acute appendicitis were eligible by inclusion criteria. The sodium levels in a group of patients with perforated appendicitis and a control group of patients with non-complicated acute appendicitis were obtained and compared. The Downs and Black scale was utilized to assess for methodological quality assessment.

**Results:** A total of seven studies were included in this meta-analysis, of which five studies were of retrospective study design and the remaining two were prospective studies. In total, 1615 subjects had complicated appendicitis and were allocated to group A, while 2808 subjects had non-complicated acute appendicitis and were allocated to group B. The goal was to compare sodium level among the two groups. Pooling the data from the included studies revealed significantly lower serum sodium levels in the pediatric patients with complicated appendicitis compared to the patients with non-complicated appendicitis (WMD: -3.29, 95% CI=-4.52 to -2.07,  $P<0.00001$ ). The estimated heterogeneity among the included research was statistically significant and substantial ( $I^2=98%$ ,  $P<0.00001$ ).

**Conclusion:** The results of this meta-analysis demonstrate that serum sodium levels are significantly lower in children with complicated appendicitis, in comparison to children in the control group with non-complicated appendicitis. It has a potential role as a biochemical marker in the diagnosis of complicated acute appendicitis.

## **9. CROATIAN SUMMARY**

**Cilj rada:** U potrazi za novim biomarkerima u dijagnozi kompliciranog apendicitisa u djece, ova je meta-analiza imala za cilj istražiti sve dostupne podatke o hiponatrijemiji kao markeru kompliciranog apendicitisa u pedijatrijskoj populaciji te usporediti razine natrija u bolesnika s nekompliciranim akutnim apendicitisom.

**Materijali i metode:** Pretražene su 4 baze podataka za relevantne članke, koristeći ključne riječi za pretraživanje (hiponatremija) I (akutni apendicitis) I (djeca). Sva djeca s kompliciranim akutnim apendicitisom bila su uključena u analizu. Dobivene su i uspoređene razine natrija u skupini bolesnika s perforiranim apendicitisom i kontrolnoj skupini bolesnika s nekompliciranim akutnim apendicitisom. Za procjenu metodološke kvalitete korištena je Downsova i Black ljestvica.

**Rezultati:** Ukupno sedam studija uključeno je u ovu meta-analizu, od čega je pet retrospektivnih studija, a preostale dvije su prospektivne studije. Ukupno je 1615 ispitanika imalo komplicirani apendicitis i svrstani su u skupinu A, dok je 2808 ispitanika imalo nekomplicirani akutni apendicitis i svrstani su u skupinu B. Cilj je bio usporediti razinu natrija u dvije skupine. Objedinjavanjem podataka iz uključenih studija nađena je značajno niža razina natrija u serumu u pedijatrijskih bolesnika s kompliciranim akutnim apendicitisom u usporedbi s bolesnicima s nekompliciranim akutnim apendicitisom (WMD: -3,29, 95% CI=-4,52 do -2,07,  $P<0,00001$ ). Procijenjena heterogenost među uključenim istraživanjima bila je statistički značajna ( $I^2=98\%$ ,  $P<0,00001$ ).

**Zaključak:** Rezultati ove meta-analize pokazuju da su razine natrija u serumu značajno niže u djece s kompliciranim apendicitisom u usporedbi s djecom u kontrolnoj skupini s nekompliciranim apendicitisom. Natrij u serumu ima potencijalnu ulogu kao biokemijski marker u dijagnozi kompliciranog akutnog apendicitisa.

