

Elastic stable intramedullary nail fixation for displaced fractures of the neck of the radius in children in the Department of pediatric surgery, University hospital of Split between 2011 - 2017 : a retrospective study

Capitain, Andre Nikolai

Master's thesis / Diplomski rad

2017

Degree Grantor / Ustanova koja je dodijelila akademski / stručni stupanj: **University of Split, School of Medicine / Sveučilište u Splitu, Medicinski fakultet**

Permanent link / Trajna poveznica: <https://um.nsk.hr/um:nbn:hr:171:848112>

Rights / Prava: [In copyright](#) / [Zaštićeno autorskim pravom.](#)

Download date / Datum preuzimanja: **2025-01-03**



Repository / Repozitorij:

[MEFST Repository](#)



UNIVERSITY OF SPLIT

SCHOOL OF MEDICINE

André Capitain

**ELASTIC STABLE INTRAMEDULLARY NAIL FIXATION FOR DISPLACED
FRACTURES OF THE NECK OF THE RADIUS IN CHILDREN IN THE
DEPARTMENT OF PEDIATRIC SURGERY, UNIVERSITY HOSPITAL OF SPLIT
BETWEEN 2011 - 2017: A RETROSPECTIVE STUDY**

Diploma thesis

Academic year:

2016./2017.

Mentor:

Ass. Prof. Zenon Pogorelić, MD, PhD

Split, July 2017

UNIVERSITY OF SPLIT

SCHOOL OF MEDICINE

André Capitain

**ELASTIC STABLE INTRAMEDULLARY NAIL FIXATION FOR DISPLACED
FRACTURES OF THE NECK OF THE RADIUS IN CHILDREN IN THE
DEPARTMENT OF PEDIATRIC SURGERY, UNIVERSITY HOSPITAL OF SPLIT
BETWEEN 2011 - 2017: A RETROSPECTIVE STUDY**

Diploma thesis

Academic year:

2016./2017.

Mentor:

Ass. Prof. Zenon Pogorelić, MD, PhD

Split, July 2017

CONTENT

1. INTRODUCTION	1
1.1. ANATOMY OF THE RADIUS	2
1.2. CLASSIFICATION OF GROWTH PLATE INJURIES.....	5
1.3. FRACTURES OF THE PROXIMAL RADIUS (HEAD AND NECK)	5
1.3.1. CLASSIFICATION	6
1.3.1.1. JUDET CLASSIFICATION	6
1.3.2. PROBLEMS AND COMPLICATIONS	8
1.3.2.1. GROWTH DISTURBANCES.....	9
1.3.3. POSTTRAUMATIC DEFORMITIES OF THE PROXIMAL RADIUS.....	9
1.4. CLINICAL PRESENTATION	10
1.5. TREATMENT.....	11
1.5.1. CONSERVATIVE TREATMENT.....	11
1.5.2. SURGICAL TREATMENT	13
1.5.2.1. ELASTIC STABLE INTRAMEDULLARY NAIL FIXATION	14
1.5.2.1.1. MÉTAIZEAU TECHNIQUE.....	16
2. OBJECTIVES OF RESEARCH	20
3. MATERIAL AND METHODS	22
3.1. PATIENTS	23
3.2. ORGANIZATION OF THE STUDY.....	23
3.3. PLACE OF THE STUDY	23
3.4. METHODS OF DATA COLLECTION AND PROCESSING	23
3.5. DESCRIPTION OF RESEARCH.....	24
3.6. FOLLOW-UP.....	24
4. RESULTS	26
5. DISCUSSION	34
6. CONCLUSSION	39
7. LIST OF LITERATURE	41
8. SUMMARY	46
9. SUMMARY IN CROATIAN.....	48
10. CV.....	50

“Twenty years from now you will be more disappointed by the things that you didn’t do than by the ones you did do. So throw off the bowlines. Sail away from the safe harbor. Catch the trade winds in your sails. Explore. Dream. Discover!”

Mark Twain

Foremost I truly want to thank my mentor Ass. Prof. Zenon Pogorelič, MD, PhD, for suggesting the theme, professional help and advising me during the making of the diploma thesis.

I also want to thank Vanja Žufić, MD, for collecting all the data and calculating the scores.

To all the colleagues, friends, professors and assistants. Thank you for making this period nice and memorable!

To Bjørnes and all my roommates. You all know why!

And to the ones with whom I went to parties, who were holding my arms while I was resting on my way home!

And to my family who was always supporting me throughout my life, school and university. You were always there for me and believed in me!

And last but definitely not least to Zrinka, for always being there for me, for supporting me and making my study so much more enjoyable! I love you!

1. INTRODUCTION

1.1. ANATOMY OF THE RADIUS

Of the two forearm bones, the radius is the short and lateral one. On its proximal end it has a short head, neck and medially pointed tuberosity. The smooth superior aspect of the discoid head of the radius is concave for the articulation with the capitulum of the humerus during flexion and extension of the elbow joint. On its medial side the head of the radius also articulates with the radial notch of the ulna; thus, it is enclosed with articular cartilage.

The constriction distal to the head is the neck of the radius. The oval radial tuberosity delineates the proximal end (head and neck) of the radius from the shaft. It lies distal to the medial part of the neck (1) (**Fig. 1**).

The anatomy of the proximal radius also affects injury (2). The discoid-shaped head of the radius is always of greater width than the neck (even during fetal growth). The head and neck of the radius are well-defined, the head is greater than the neck, and a radial notch appears in the ulna. Although not as discrete during the fetal stage, the radial head, even throughout the first year, shows the same eccentric concavity and distinct anterolateral rim as in the adult (3).

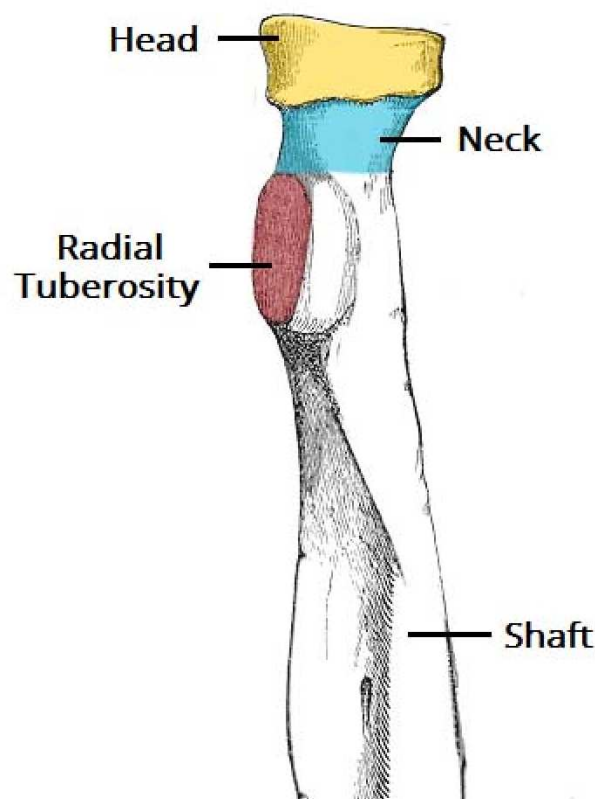


Fig. 1. Anatomy of the proximal radius. Taken from: <http://teachmeanatomy.info/upper-limb/bones/radius/>.

The plane of the articular surface is tilted in relation to the longitudinal axis of the radius. This tilt differs depending on the rotation. The exact degree of tilting and shifting may be measured only on X-rays obtained at proper angles to the level of angulation. Changing the tilt influences the up-and-down sliding motion of the annular ligament. During reduction one should memorize that there is normally a mild tilt, because one of the difficulties of proximal radial fractures is increased angulation. The concavity within the proximal radius that articulates with the capitellum may be eccentric (**Fig. 2**), which affects rotational dynamics and the rigidity within the annular ligament.

The epiphysis of the radial head is covered broadly by articular cartilage. It is present not just over the end of the radius but circumferentially throughout the sides to allow radioulnar movement. There is no perichondrium on this specific epiphysis. The epiphyseal blood supply has a short intraarticular course along the metaphysis, which is enclosed by the annular ligament. This situation creates a vulnerable intracapsular epiphyseal blood supply comparable to that of the capital femoral epiphysis (**Fig. 3**). The blood supply may be injured by epiphyseal or metaphyseal separation. Because the typical level of injury through the metaphysis is near the entry point of the vessels, ischemic necrosis must be thought of as a potential complication. Nevertheless, there is often hyperemia of the fracture site, causing overgrowth of the radial head, rather than substantial growth limitation.

The proximal radial epiphysis may not ossify until a child is 5–7 years old and it usually unites between 12 and 15 years of age. It generally ossifies symmetrically. Ossification may be asymmetric and may resemble a triangle rather than an ellipse in certain positions, because of the epiphyseal tilt (3-5). An angular shape may also imply a problem of atypical radiohumeral joint stress, such as a radioulnar synostosis or Panner's disease. Because these conditions are not detected in many children until an episode of trauma, the physician should be aware of these potential complications of differential diagnosis as related to normal anatomic growth and maturation.

The biceps tendon inserts onto the radial tuberosity. This osseous prominence becomes increasingly larger as the child grows. Evans emphasized its potential use for evaluating the relative rotation of the proximal fragments in forearm fractures (6). By the time a child is 5 years of age, the tuberosity begins to have enough prominence to be visible on X-rays.

The sagittal and coronal cross-sectional diameters of the radius and ulna change with age and anatomic level. Although for much of the diaphysis the two bones have a cam (pear) shape, proximally, both have a circular appearance. As such, rotational malformations often are detected by the variances in the widths of the apposed fragments (7).




Fig. 2. Sagittal section through the radial head and bicipital tuberosity. The radial head concavity is eccentric and slightly tilted relative to the longitudinal axis of the radial shaft. Taken from: Ogden JA. Skeletal Injury in the child.

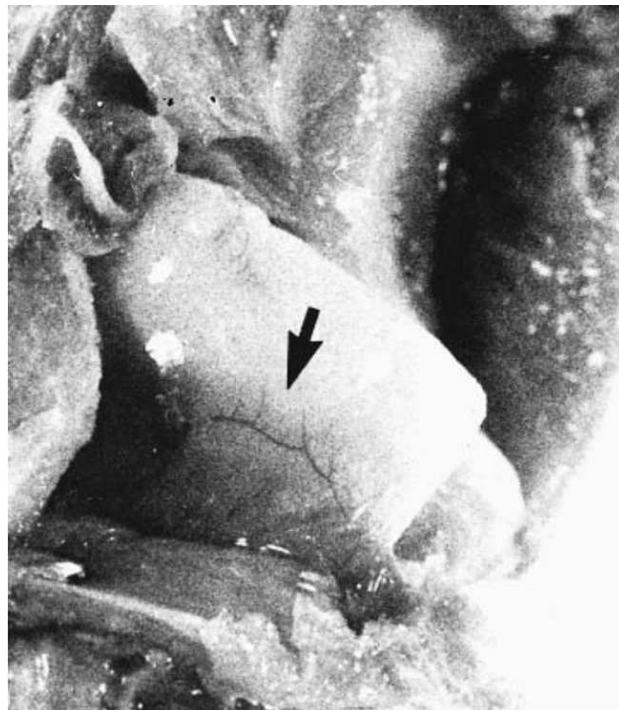


Fig. 3. Intraarticular blood supply of the proximal radius. Several small vessels (arrow) extend transversely and longitudinally under the annular ligament, which has been pulled down. Taken from: Ogden JA. Skeletal Injury in the child.

1.2. CLASSIFICATION OF GROWTH PLATE INJURIES

Salter and Harris defined the most commonly used classification for epiphyseal fractures. The fractures are divided into 5 types. A type I injury is a simple transverse fracture through the physis. Type II injuries are the most common, particularly in older children (more than 10 years of age) and comprise a component of fracture through the growth plate in connection with a fracture of the metaphysis. They are frequently accompanied by a fracture through the ulnar styloid. A type III injury takes place across the physis and exits through the growth plate. While a Salter-Harris type IV fracture line goes through the physis from the metaphysis into the epiphysis, a Salter-Harris type V fracture crushes the physis itself (**Fig. 4**).

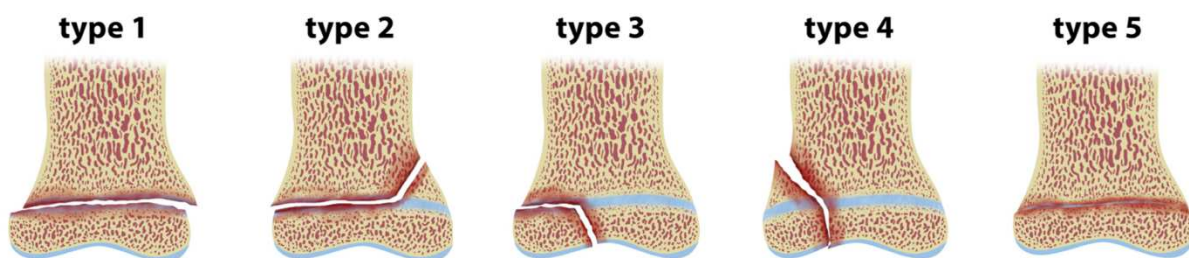


Fig. 4. Salter Harris Classification. Taken from: <https://radiopaedia.org/articles/salter-harris-classification>.

The Salter-Harris fractures may be associated with a greenstick fracture of the ulnar metaphysis, separation of the distal ulnar epiphysis, or a fracture of the ulnar styloid process. Management of growth plate fractures necessitates anatomic reduction of the fragments. To reduce the chance of premature growth plate closure, internal fixation avoids placing hardware across the growth plate (8).

1.3. FRACTURES OF THE PROXIMAL RADIUS (HEAD AND NECK)

At the proximal forearm the radial head and the radial collum fractures are prevailing in respect to olecranon fractures (9). Radial head and neck fractures account for 5-10 per cent of injuries to the elbow region (10). Most are minimally displaced or no displaced (11). Fractures through the head of the radius are less common (12). They are therefore not an infrequent fracture; neither are they common. With the range beginning at about 5 years, fractures commonly occur when the children are 10-13 years of age, when the ossification center first appears. Whether these injuries occur previous to that time is problematic to ascertain because

of the absence of the ossification center. Approximately 75 per cent of the cases happen in children 9 years of age or older (13).

This fracture is caused by both direct and indirect violence. In children it is about evenly divided, while in adults direct violence is more common (14). Fractures of the proximal radius classically occur after a fall on an outstretched arm, driving the capitellum against the outside of the head of the radius, tilting and displacing it (7, 15). The direction of tilting of the displaced head of the radius in relation to the shaft of the radius differs with the rotational position of the radius at the time of injury. Thus, if the forearm is supinated at the moment of injury, the displacement of the capital epiphysis is lateral. This displacement is shown in the usual anteroposterior radiograph obtained in supination. The adjacent posterior quadrant of the radial head is subjected to the maximum violence, if the forearm is in midposition; and when the forearm is returned to a position of full supination, the head may be tilted backward in relation to the radial shaft (7). One third of the fractures have separated epiphyses as a result and two thirds in subcapital fractures of the radial neck.

1.3.1. CLASSIFICATION

Fractures vary from growth mechanism involvement to injuries across the metaphysis with angular deformity. The fracture line is usually a compression of the epiphyseal head into the metaphyseal expansion of the narrow neck, even though it may seem to be through the epiphysis. Thus these fractures tend to be impaction or greenstick injury patterns. With either injury pattern the fragment may be entirely displaced.

A fracture of the metaphyseal neck of the radius should be distinguished from a true physeal or epiphyseal fracture of the head of the radius, which occurs less frequently during childhood.

1.3.1.1. JUDET CLASSIFICATION

The Judet classification describes fractures of the neck of the radius based on the degree of angulation (**Table 1**). A type I fracture is an undisplaced fracture. Type II fractures have an angulation of less than 30°. They can both be treated non-operatively with good long-term results (16, 17). A type III fracture has an angulation ranging from 30° to 60° and a type IV fracture is further divided into a) angulation from 60° to 80° and b) angulation more than 80°.

Type III and IV fractures can be treated initially by closed manipulation to improve the position of the fracture, followed by elastic stable intramedullary nail fixation (ESIN) (18) (**Fig. 5**).

Table 1. Judet's classification of fractures of the neck of the radius.

Type	Description
I	Undisplaced
II	Angulation $< 30^\circ$
III	Angulation 30° to 60°
IV	a) Angulation 60° to 80° b) Angulation $> 80^\circ$

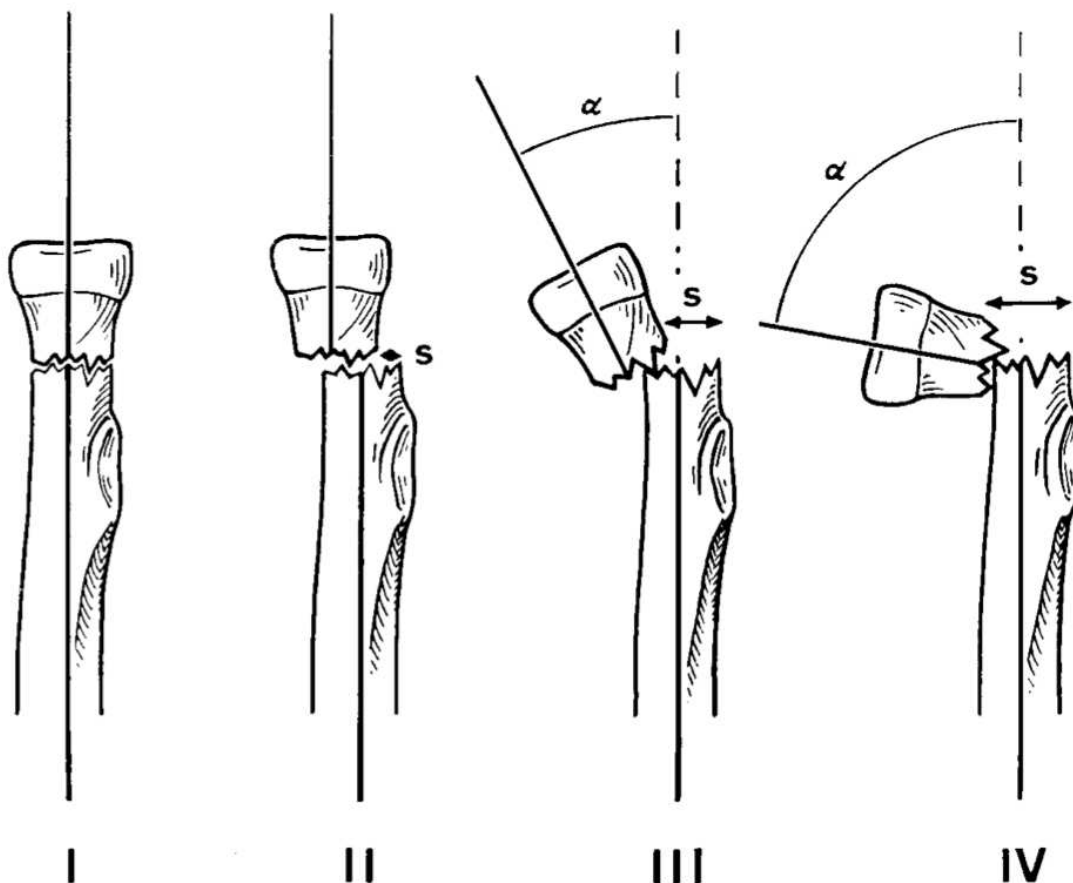


Fig. 5. Schematic drawing illustrating the classification of fractures of the radial neck by Judet: type I, undisplaced fracture; type II, $<30^\circ$ (angulation of radial neck); type III, 30° to 60° ; type IV, 60° to 80° . Taken from: Stiefel D, Meuli M, Altermatt S. Fractures of the neck of the radius in children.

1.3.2. PROBLEMS AND COMPLICATIONS

Fractures of the neck of the radius in children may cause significant permanent limitation of elbow and forearm movement (19). Retrospective studies in the past found that open reduction of radial neck fractures generally had poor results and that open reduction with internal fixation was even worse (20).

The most important set of problems that can happen in this fracture involves the blood supply to the radial head. The radial head is supplied by periosteal vessels in the neck. As a result, any trauma to the proximal end of the radius (with or without a fracture) will produce an aseptic necrosis of the radial neck and head of varying severity (21-23). This can precipitate a slight shortening of the proximal end of the radius with a propensity toward slight valgus deviation of the elbow axis. However, the concurrent widening and thickening of the radial head and neck are more significant; in extreme cases, this can restrict pronation and supination.

Functional impairment is less likely to be a complication of such deformities than additional soft-tissue injuries from prior trauma (13). Such prior trauma also comprises iatrogenic trauma such as closed and open reduction (21, 22). Failure to correct displacement or angulation may disturb the rotation of the radial head in the ulnar notch, creating a cam effect, rather than a rotation (7).

The severity of this thickening appears to rely largely on the gravity of the primary and secondary trauma. The thickening is less prominent following contusions such as can occur in elbow dislocations (24) and more pronounced following fractures of the proximal end of the radius. Because of this the proximal end of the radius basically responds to any trauma with deformation of varying severity (13).

Trauma comprises not only accidents but also iatrogenic trauma. Iatrogenic trauma includes the transarticular Kirschner wire fixation, which often leads to wire fractures and invariably represents chronic traumatization of the radial growth plate, head, and neck. Iatrogenic trauma also includes the “triad of errors” applied by most nonpediatric surgeons: incorrect indication, incorrect technique, and incorrect aftercare. Especially this last error in the form of prolonged immobilization followed by excessive physical therapy, is one of the toughest sorts of trauma to which the radial head can be exposed (25, 26). Synostosis between the proximal radius and ulna has been described (27). Fibrous adhesions between the radius and ulna were also reported (19). Such adhesions block rotation of the forearm similar to synostosis. Nonunion is rare. It results from failure to achieve adequate reduction and maintain it (7).

1.3.2.1. GROWTH DISTURBANCES

The transient stimulation of the proximal radial growth plate or its sequela that may be anticipated after shaft fractures is mostly compensated for by the shortening effect of the radial head aseptic necrosis (28).

The growth disturbance of partial premature closure of the growth plate is possible, but extremely rare (29). It does not happen as a result of an epiphyseal fracture. It results from interference of epiphyseal vascular supply, usually in the medial region, and occurs secondary to separated epiphyses and subcapital fractures. The physeal bridge that then follows leads to increasing medial shortening with a corresponding malformation of the radial head. The result is a functional impairment of pronation and supination.

1.3.3. POSTTRAUMATIC DEFORMITIES OF THE PROXIMAL RADIUS

Where angulation of the radial head has not been “spontaneously” improved in patients beyond age 10–12 and a functional damage has resulted, a subcapital osteotomy should be attempted to reestablish correct position as timely as possible. The result will be a matter of luck. Postponing the operation until growth has stopped poses a different problem.

Where thickening of the radial head is responsible for a limited range of motion (ROM), the radial head may be resected after growth has finished to correct severe cases of limited motion (30). However, care must be taken to ensure that the distal radial growth plate is also certainly closed. Otherwise, even a resection performed on the proximal end of the radius could lead to severe abnormal development in the stump of the radius with damage to the elbow joint, such as would appear with an open proximal growth plate.

Chronic divided epiphyses with secondary displacement or massive secondary thickening with corresponding functional impairments are consistently attributable to mistakes on the part of the physician in planning and performing treatment and aftercare (incorrect indication, incorrect technique, and incorrect aftercare), in other words, to severe iatrogenic traumatization (13).

1.4. CLINICAL PRESENTATION

The pediatric patient with a proximal radius fracture usually presents with a malformation at the fracture site with a swelling of the elbow. The patient will have pain at the outside of the elbow and a severely decreased ROM.

The injured elbow is typically held in moderate flexion, with the forearm in neutral rotation. There may be local swelling and ecchymosis over the lateral part of the elbow. Palpation of the radial head and neck may provoke tenderness. There may be sporadic crepitation of the fragments when motion is attempted. Pain may be referred distally to the wrist. Flexion and extension are limited; pronation and supination are painful and restricted.

X-rays initially are acquired in anterior and lateral views. When clinical findings are indicative, but the standard X-rays are indecisive, it is advisable to observe several views of the proximal radius in several degrees of rotation or assess the proximal radius under fluoroscopy. Sometimes small metaphyseal fragments are evident. A dislocated proximal fragment may be projected into the shadow of the ulna. As a result, the structural changes may be missed on regular films. In such cases, oblique or tangential projections may be worthwhile. The maximal degree of the tilting of the radial head should be determined, which, again, may require nonstandard views or fluoroscopy. Fat pad signs may be the only sign of an undisplaced injury (7).

A child with a fracture of the radial head may present with further distally referred pain, even in the wrist (31). It is important to radiograph the entire involved bone, as with any injury in which there is rather diffuse or even selective pain in a child. As many as 50% of patients with a fracture of the radial head or neck have an associated injury, such as fracture of the olecranon, avulsion of the medial epicondyle, or dislocation of the elbow (7).

The degree of angulation may be precisely determined only by an anteroposterior radiograph obtained with the forearm in the position of rotation at the moment of impact (32). Jeffery has advocated obtaining radiographs in various degrees of forearm rotation (33). A more practical method is to assess the child with fluoroscopy by pronating and supinating the forearm to find the maximal extent of angulation. Alternatively, if a well-formed secondary ossification center is present, it appears as a rectangle when the bone is in the maximal degree of angulation. Comparison views are less appropriate, as there are normal variations in the radiographic appearance of the proximal radius (7).

1.5. TREATMENT

The basic aim of treatment is to restore the normal range of forearm supination and pronation and to protect the radial head against all unnecessary traumatization in the interest of preserving function yet also to avoid leaving intolerable deformities uncorrected (7, 13).

Problems of treatment vary considerably with the age of the patient and the level and displacement of the fracture. Generally, there is less comminution, union is more rapid, and residual deformities tend to be corrected by subsequent growth, compared with similar injuries in an adult (34, 35).

The anatomical complexity of the elbow and its blood supply makes treatment difficult (36). The head of the radius and its blood supply can be damaged by the injury itself and by surgical manipulation such as in open reduction (22, 37). As a result, closed techniques using percutaneous Kirschner (K-) wires have been developed (38, 39). The use of percutaneous K-wire leverage was first described in 1950 by Bohler, and Pseudo described it in 1982 with some modification (40). This gives good results but has the disadvantages of intraoperative difficulties in testing forearm rotation, due to fixation of the extensor muscle group, and the possibility of injuring the posterior interosseous nerve (41).

The management of fractures of the neck of the radius in children is controversial (36). There is little agreement as to what may be accepted as a satisfactory reduction. Minor degrees of angulation can be accepted and treated conservatively, but advice on the maximum acceptable angulation varies widely, up to as much as 45° (20).

Many studies (17, 42, 43) agreed that for fractures with moderate or severe angulation, reduction of the displaced head should be performed before casting. Once it is reduced, it can be difficult to retain and secondary displacement can happen resulting in malunion and diminished ROM (16). Open reduction permits anatomical reduction but gives high risk of avascular necrosis and the risk of radioulnar synostosis (41).

1.5.1. CONSERVATIVE TREATMENT

Pediatric radial neck fractures with angulation of less than 30° do not need reduction and will heal with good functional results (41). For the undisplaced or minimally displaced fracture of the radial head or neck, treatment consists of immobilizing the elbow with a posterior splint in 90° of flexion and neutral rotation of the forearm for approximately 10–14 days. Movement should be started when the injury is no longer painful (44). Early mobilization is

recommended but is not used if there is residual pain at the fracture site on either motion or direct palpation. Initial movements include flexion-extension and pronation-supination exercises; the arm should be protected in a sling because of the normal state of activity of a child.

Every attempt should be made to achieve an optimal degree of angular correction. Lateral tilting of up to 30° is probably acceptable, as there is usually spontaneous correction through remodeling. This correction is less likely with the older child (over 10 years) because the proximal radius has much less growth potential than does the distal physis. Furthermore, with a crushing metaphyseal injury one cannot be certain there is no concomitant physeal injury that may lead to growth slowdown or arrest and that may cause further angular deformity and tilting of the radial head. Permanent malunion may result.

Closed reduction is usually accomplished by partial to complete extension of the elbow to provide some fixation of the ulna relative to the humerus, followed by adduction of the forearm to correct or overcorrect the carrying angle and widen the radiohumeral articulation, a maneuver designed to create a space into which the displaced radial head may be reduced (41). This position is held, and the forearm is rotated to bring the radial head into a position from which it may be pushed by direct pressure into correct alignment. As a prelude to manipulation it is important to determine the direction of displacement of the radial head. Manipulative reduction is carried out with the forearm in the degree of rotation that brings the most prominent part of the displaced head farthest laterally. If it is done under image intensification, it is often possible to determine the position of supination or pronation that best emphasizes the fracture in such a way that the thumb may be applied to produce a correction force. Firm digital pressure is applied in an upward and inward direction to complete the reduction. If X-ray proves that the reduction is satisfactory, the arm is immobilized in a posterior splint.

Closed reduction under anesthesia is appropriate and successful, if the angulation is between 30°–60°. Some accept an initial angulation of less than 30°, but even this should be treated with an attempted reduction (7).

If satisfactory reduction is achieved, a long arm cast is applied with the elbow held at 70°–90° of flexion, neutral rotation, and three-point fixation with the medial elbow as the fulcrum; a slight varus stress is then applied to the cast to lessen pressure at the radiohumeral joint. Usually, a period of 3–4 weeks is sufficient to achieve healing. It should be remembered that this area does not normally have a dense cortex and is not accustomed to assuming significant joint reaction forces, so it might collapse if the arm is used and pronation-supination

movement is started. Repeat roentgenograms during the first 2 weeks ensure that reduction is maintained (7).

1.5.2. SURGICAL TREATMENT

If the angulation is more than 60°, closed reduction is usually unsuccessful and open reduction or the toggle maneuver is indicated. The proximal humerus of the affected limb is stabilized by an assistant. The elbow is flexed to 90°. The forearm is held by the surgeon's ipsilateral hand (i.e., the left hand for the left forearm and vice versa) in maximum possible supination. No varus strain is applied. Pressure is then applied by the thumb of the surgeon's other hand over the anterolateral aspect of the head of the radius, just distal and lateral to the cubital fossa. At the same time the affected forearm is gradually but steadily rotated to a neutral position and then into a position of full pronation. This maneuver rotates the displaced and tilted radial head under the external pressure; and with the elbow flexion providing a lax capsule, the radial head is usually reduced. Reduction and stability may be confirmed fluoroscopically.

Open reduction may be undertaken when the radial epiphysis is displaced completely from the shaft or when manipulative reduction has been unsuccessful. It should be done as soon as possible after the injury, as extended periods are sometimes associated with a higher incidence of myositis ossificans and ischemic necrosis (45, 46).

Even if it is completely separated, the radial head should be replaced anatomically, as revascularization may occur (but is unlikely after 24 hours). The head and neck of the radius normally are relatively poorly vascularized (i.e., dependent on only a few vessels), so ischemic change is a likely complication. In cases with major dislocation of the fragments, the periosteum may be completely severed. Extensive stripping of the periosteum should not be undertaken. Removal may result in significant relative differences of growth rates between the radius and ulna (47). Silastic spacers should be avoided in children. The annular ligament is not sectioned unless it is absolutely necessary to achieve reduction. Every effort should be made to protect the annular ligament; if it is damaged, it should be repaired. The forearm should be fully pronated and supinated to test the stability of the reduction.

When necessary, fixation may be accomplished by angular placement of wires through the margin of the radial head into the metaphysis. Placing the wire through the capitellum into the center of the radial head and along the radial shaft with the elbow flexed at 90° and the forearm in midrotation is less desirable and rarely necessary if it is possible to achieve fixation without involving the articular surfaces.

Care must be taken to protect the posterior interosseous nerve. This nerve may be exposed by separating the fibers of the supinator muscle. Wide exposure may prevent neuropraxia of the posterior interosseous nerve and facilitates positioning of the radial head on its neck (7).

With type 3 or 4 growth mechanism injuries, closed reduction should be attempted first, although open reduction is frequently necessary. Most of these injuries result in premature closure of the epiphysis and may accentuate valgus angulation, depending on the amount of remaining growth.

The type 4 physeal injury produces a dilemma. The displaced fragment is often too small to be fixed effectively. In some cases it can be excised. The result may not be good, but the loss of motion after this fracture may be due to other factors because the injury is usually produced by considerable violence.

When treating markedly displaced and fragmented fractures, many authors believe that only two methods are likely to give satisfactory results: excision of the capital fragment or open reduction. However, the radial head usually should not be excised in a child because marked growth disturbance can occur. A Madelung-type deformity may also develop at the wrist, with radial deviation of the hand, depending on the amount of growth remaining. In a patient close to skeletal maturity, with a severely comminuted injury of the proximal radius, it is probably best to treat the adolescent as an adult and excise the radial head.

If the fracture is diagnosed late, radial head tilting may be corrected by an osteotomy and, if necessary, bone graft. If the patient is skeletally mature, the radial head may be excised. Immobilization following open reduction is as described for closed treatment and should be continued for 2–4 weeks. If K-wires have been used, they should be removed before active rehabilitation (7).

1.5.2.1. ELASTIC STABLE INTRAMEDULLARY NAIL FIXATION

The ESIN method (Elastic stable intramedullary nailing) was developed by Jean Prevot and Paul Métaizeau in the late 1970s at the children's hospital in Nancy, France (48). The original method was called Embrochage centromedullaire elastique stable or abbreviated as the French term ECMES – the method of elastic stable intramedullary osteosynthesis. However, in today's literature, the English abbreviation ESIN has been honored. The values of this method are related to the physical properties of the nails made out of stainless steel or titanium alloy, which according to the author are called Prévot-Nancy nail or just Nancy nail. ESIN, with the

Titanium Elastic Nail (TEN) or Stainless Steel Nail (STEN) is indicated for the management of diaphyseal and certain metaphyseal/-epiphyseal fractures of long bones in children and young adults.

The biomechanical principles of elastic-stable intramedullary osteosynthesis are based on the symmetrical support of two elastic nails embedded in the metaphysis, each of which opposes the inner part of the bone at three points. It produces the following four biomechanical properties necessary to achieve optimal results: flexural, axial, translational and rotational stability (49). This, so-called, trifocal support of each nail within the medullary channel will give maximum stability to fixation. Despite stability, it is still far from rigid, and healing is characterized by the early generation of a lumpy calf associated with microinjuries (50).

ESIN has the advantage of early implant stability of the involved bone segment, which allows early mobilization and recovery of patients with daily activities at a very low rate of complications (51). In pediatric use, the flexibility of the titanium elastic nail allows insertion in a way that avoids the epiphysal bone growth disorder. The goal of this biological, minimally invasive treatment technique is to achieve the degree of repositioning and stabilization appropriate to the child's age.

Elastic stable intramedullary osteosynthesis with titanium elastic nails is used to fix the long bone fracture where the intramedullary channel is narrow or the implant's flexibility is most important. The ideal fracture for this technique is a transverse or short hair fracture of long bone. However, the versatility of this method is such that the indications significantly expanded over time and experience. Elastic stable intramedullary osteosynthesis with titanium elastic nails is nowadays primarily used for the treatment of diaphyseal and metaphyseal fractures in children. The use of an intramedullary agent is indicated by open fractures, unstable fractures or irreducible fractures (51). Whether this method is indicated or not, depends on the age of the patient and the type and location of the fracture. All three factors must be considered together. The age limit depends on the biological development of the child. Experience has shown that the lower limit is 3-4 years and the upper limit is 13-15 years, however, these limits are very variable. The most important contraindications for this technique are intraarticular fractures and complex femoral fractures, especially associated with increased body weight and / or age.

There is a general agreement that displaced radial neck fractures with more than 30° angulations (Judet type III and IV fractures) should be surgically treated (52). There are several treatment possibilities for Judet type III and IV fractures, including percutaneous pin reduction (20), elastic stable intramedullary nailing (ESIN) (18), and open reduction with or without internal fixation (53).

1.5.2.1.1. MÉTAIZEAU TECHNIQUE

In 1980, Métaizeau proposed intramedullary nailing as a surgical option for the treatment of radial neck fractures. The main advantage of intramedullary nailing is that it simultaneously allows accurate and stable reduction without disturbing the blood supply (54).

In this technique described by Métaizeau a single nail is used. Its length is measured from the subchondral area of the head to the distal radial growth plate using an image intensifier, with an extra 5 cm added to facilitate a secure hold on the T handle during rotation of the nail. The diameter of the nail is 2 mm or 2.5 mm, the former being used in children under ten years of age and the latter in older children. The implant can either be made out of stainless steel or titanium. A sharp tip helps penetrate the cancellous bone of the proximal epiphysis. The terminal 3 to 4 mm of the nail is bent to approximately 45° to catch the displaced epiphysis and the rest is pre-bent as a gentle curve of 20° to obtain three-point fixation. Under a general anaesthetic, the patient lies supine with the upper limb draped and placed on a hand table. A lateral skin incision of 2 to 3 cm extends proximally from the distal radial physis, carefully protecting the superficial branch of the radial nerve. Using a drill 1 mm wider than the chosen nail, an entry point is made 2 cm proximal to the physis. The nail is attached to a T handle, introduced (**Fig. 6a**) and, using the image intensifier, advanced proximally with gentle rotational movements until it reaches the fracture. Displacement needs to be assessed by the image intensifier and the tip of the nail directed towards the maximum tilt of the epiphysis. External manipulation is used to try and reduce the fracture as much as possible. The nail is advanced with gentle taps across the fracture and up to the subchondral bone (**Fig. 6b**), avoiding penetration of the joint. Displacement of the radial head is usually lateral or posterolateral, and therefore the nail is rotated anteriorly (**Fig. 6c**) and then medially (**Fig. 6d**). After successful reduction is accomplished, the elbow is immobilised in a cast mainly to control pain. The nail is removed after 2-3 months when the radiological healing is evident (**Fig. 7, Fig. 8**) (18).

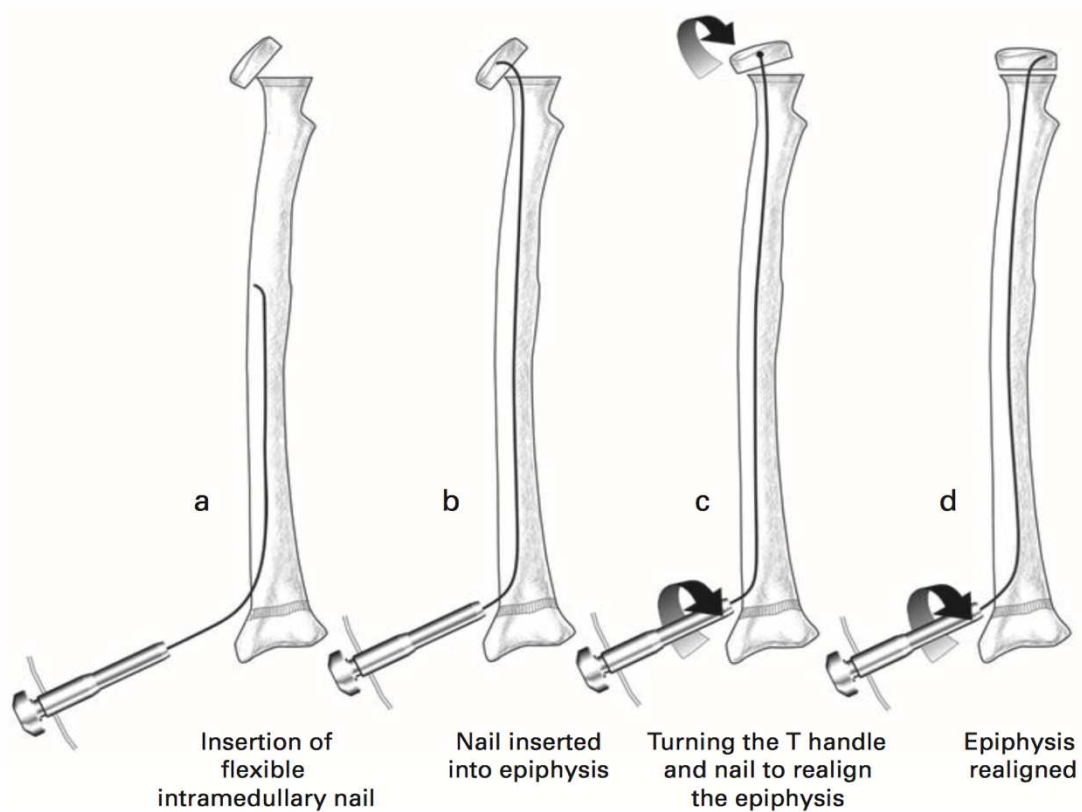


Fig. 6. Surgical technique of elastic stable intramedullary nailing assisted reduction and fixation of radial head and neck fractures. Taken from: Prathapkumar KR, Garg, NK, Bruce CE. Elastic stable intramedullary nail fixation for severely displaced fractures of the neck of the radius in children.

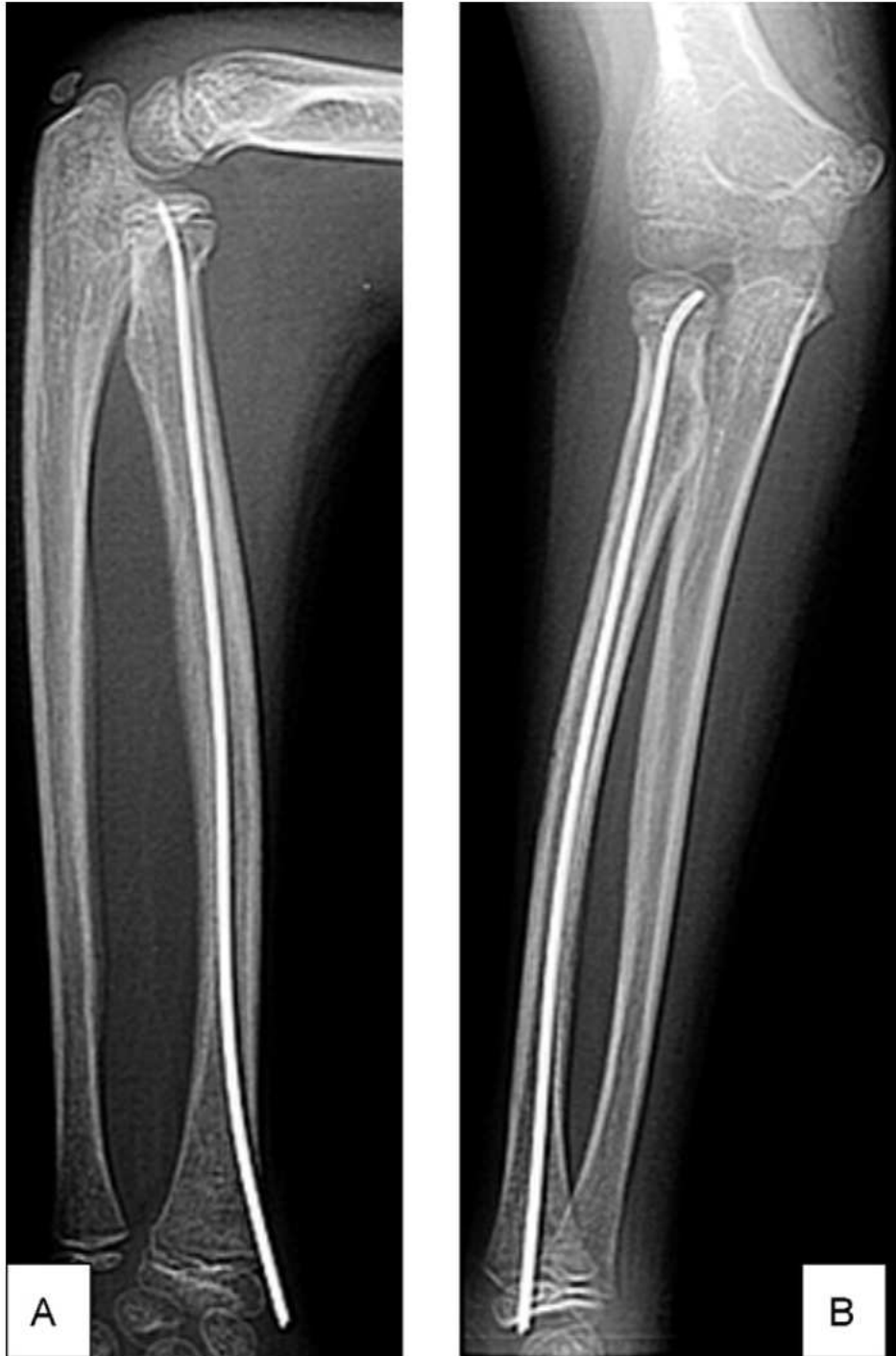

Fig. 7. Lateral (A) and anteroposterior (B) X-rays after closed reduction and fixation using the Métaizeau centromedullary technique. Taken from: Al-Aubaidi Z, Pedersen NW, Nielsen KD. Radial neck fractures in children treated with the centromedullary Métaizeau technique.

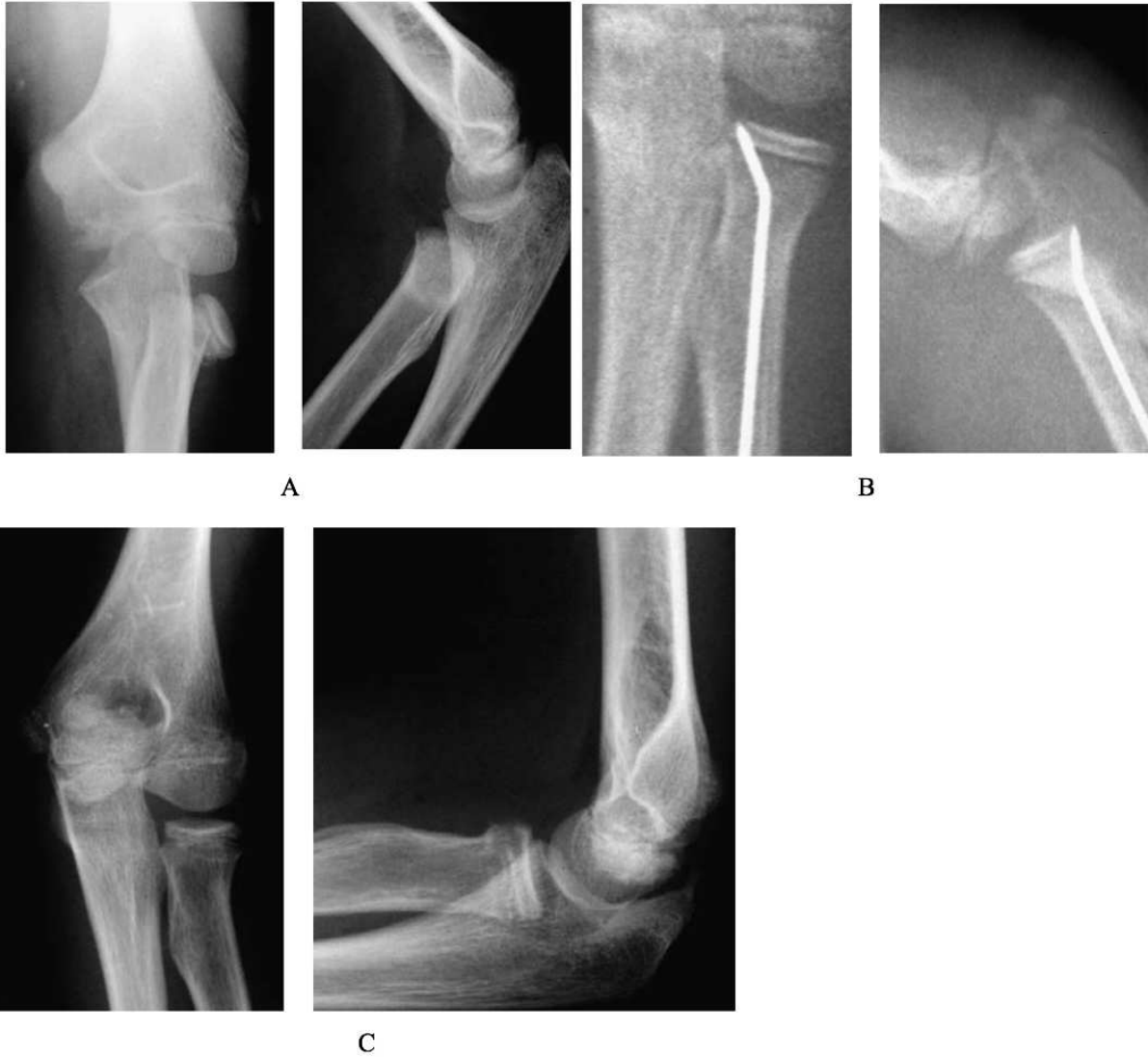

Fig. 8. Radiographs showing anteroposterior (left) and lateral (right) views of the elbow. Figure 8A - Preoperative radiographs showing a grade-IV fracture. Figure 8B - Intraoperative radiographs after closed reduction and intramedullary pinning with a K-wire. Figure 8C – Follow-up radiographs showing an excellent outcome 12 months after the operation. Taken from: Stiefel D, Meuli M, Altermatt S. Fractures of the neck of the radius in children. Early experience with intramedullary pinning.

2. OBJECTIVES OF RESEARCH

Fractures are very common in the pediatric age group and represent some of the most common injuries to children. Children's bones possess a great potential for an excellent and fast remodeling of residual deformities, so in a child's age a smaller number of fractures need to be cured by an operation and the non-operative approach is being chosen more often. However, since its introduction, the method of elastic stable intramedullary nail fixation was imposed as a valuable method in treating long bone fractures in children. ESIN takes advantage of the premature stability of the involved bone segment, enabling early mobilization and returning to patient to his normal activities with a very low complication rate. The flexibility of the titanium elastic nail also allows insertion in a way that avoids the epiphyseal bone growth disorder. With the correct indications and good preoperative preparation of an experienced surgeon in this minimally invasive treatment method, it is possible to achieve the degree of repositioning and stabilization appropriate to the child's age.

The aim of this study is to establish the demographic and clinical characteristics of children operated by the ESIN method due to radial head and neck fractures. The underlying findings of the study are to determine the most common type of fracture, lateralization, fracture mechanism, treatment, associated injury, healing time and complications of treatment, and to compare them with other relevant studies.

Hypothesis :

The ESIN method is an effective method of treating fractures of the radial head and neck in children with excellent healing results and a low complication rate. The method meets criteria for minimally invasive bone surgery.

3. MATERIAL AND METHODS

3.1. PATIENTS

All patients were treated with ESIN method for radial head and neck fractures at the Department of Pediatric Surgery of the University Hospital of Split in the period from May 2011 and May 2017.

Inclusion criteria:

1. Patients of both genders, 3-17 years of age, with a radial head and neck fracture treated by the ESIN method
2. Patients operated in University Hospital of Split by a specialist in pediatric surgery
3. Follow-up at least 3 months after the surgery

Exclusion criteria:

1. Patients under 3 or older than 17 years
2. Patients with a radial head and neck fracture treated conservatively
3. Patients with a radial head and neck fracture treated surgically with another method
4. Patients operated in another institution
5. Patients with incomplete data or that have been followed-up less than 3 months

3.2. ORGANIZATION OF THE STUDY

Historical cross sectional study. Research is a qualitative research according to the organization, while intervention and processing of the data are descriptive, ie descriptive type.

3.3. PLACE OF THE STUDY

The research was conducted at the Department of pediatric surgery of the University hospital of Split.

3.4. METHODS OF DATA COLLECTION AND PROCESSING

Data was collected by research of the written protocol of the Department of pediatric surgery of the University hospital of Split and the archive of the history of the disease. Collected

data were analyzed using Microsoft Word Processing Software and Microsoft Excel for table presentation.

3.5. DESCRIPTION OF RESEARCH

All patients had an urgent surgical procedure, using the ESIN method, due to the radial head and neck fracture. Surgery implied a bloody or closed reposition of bone fragments and osteosynthesis of titanium nails, whose thickness was determined intraoperatively so that both nails must meet at least 2/3 medulla on the highest part of the bone. The following parameters were analyzed for each subject: age, sex, type of fracture, fracture mechanism, lateralization, mode of repositioning, associated injury, healing time and complications of treatment. For each patient clinical and radiological outcomes and DASH score were measured.

3.6. FOLLOW-UP

All patients were kept in hospital care after the operation. During their stay at the hospital, physical therapy was started, which continued as ambulatory therapy after discharge. Each patient was subjected to intraoperative X-ray imaging after bone repositioning and titanium elastic nail fixation. Surveillance X-ray imaging was performed 7 days after surgery and after 1, 3 and 6 months, or until complete bone healing. After complete bone healing has been achieved, osteosynthesis was removed under general anesthesia. Median follow up was 38 (range, 3 -73) months.

The disability of the arm, shoulder, and hand (DASH) scoring was used to evaluate the subjective clinical results. It is a disability scoring instrument measuring symptoms and functional status and consists of 30 questions, scoring from 0 as the best to 5 as the worst (41). The percentage can be calculated as follows:

$$\text{DASH} = \frac{(\text{sum of n responses}) - 1}{n} \times 25$$

The evaluation comprised a full clinical examination of the elbow. Any axis deviation was registered. The ROM of the elbow (flexion/extension) and forearm (supination/pronation)

was measured, compared to the contralateral side and the result was classified according to Métaizeau (41) as follows:

- Perfect: if normal and full range of movements.
- Good: if the sum of movement's limitation is less than 20°
- Acceptable: if the sum of movement's limitation is between $20-40^{\circ}$
- Bad: if the sum of movement's limitation $> 40^{\circ}$

The radiological result was evaluated according to Ursei (42) as following:

- Perfect: anatomical reduction was achieved
- Good: translation or angulations $< 20^{\circ}$
- Acceptable: angulations $20^{\circ}-40^{\circ}$
- Bad: angulations $> 40^{\circ}$

4. RESULTS

In the selected study period (2011–2017), the study included 26 patients (15 girls, 11 boys) operated by the ESIN method due to radial head and neck fractures. The median age at the time of the operation was 9 years (5-16 years). Demographic and clinical data are presented in **Table 2**.

Fig. 9 shows the distribution of children by gender. Out of a total of 26 patients treated with the ESIN method for radial head and neck fractures, there were 11 boys, which makes up 42.3% and 15 girls, which is 57.7% and gives us an approximate 1.36:1 ratio to the girls. This relationship is valid overall, with variations of the year-to-year ratio.

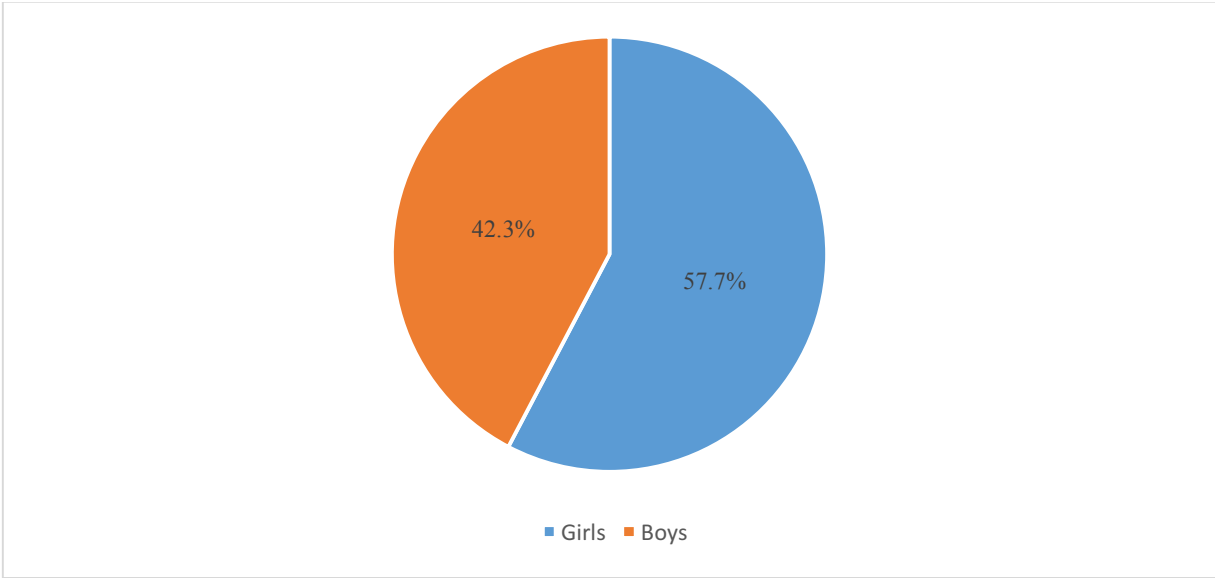


Fig. 9. Distribution of operated children due to radial head and neck fractures by gender (n=26).

Table 2. Demographic and clinical data, and outcomes of treatment.

Demographic data of the patients		(n=26)
GENDER (n, %)		
Girls		15 (57.7%)
Boys		11 (42.3%)
AGE (Years)		
Median		9
Range		5-16
LATERALIZATION (n, %)		
Left		14 (53.8%)
Right		12 (46.2%)
Clinical data and treatment outcomes		
Days before surgery (median, IQR)		1 (1-1.75)
Duration of surgery; min (median, IQR)		25 (21-35)
Complications (n, %)		3 (11.5%)
Healing time; weeks (median, IQR)		5 (3-7)
Nail removal; months (median, IQR)		4 (1-9)
Associated injuries (n, %)		6 (23%)

Of the total number of 26 fractures, there were 9 falls from the same level, 5 falls from the trampoline, 5 falls from the bike, 4 sport injuries, 1 fall from a horse, 1 fall from a ladder and 1 motorcycle crash (**Fig. 10**). The most common mechanism of injury was a fall on ground floor, which was the cause of 9 fractures in this study, ie. 34.6%.

The nails were removed at a median of 4 months (range, 1 to 9) (**Fig. 11**).

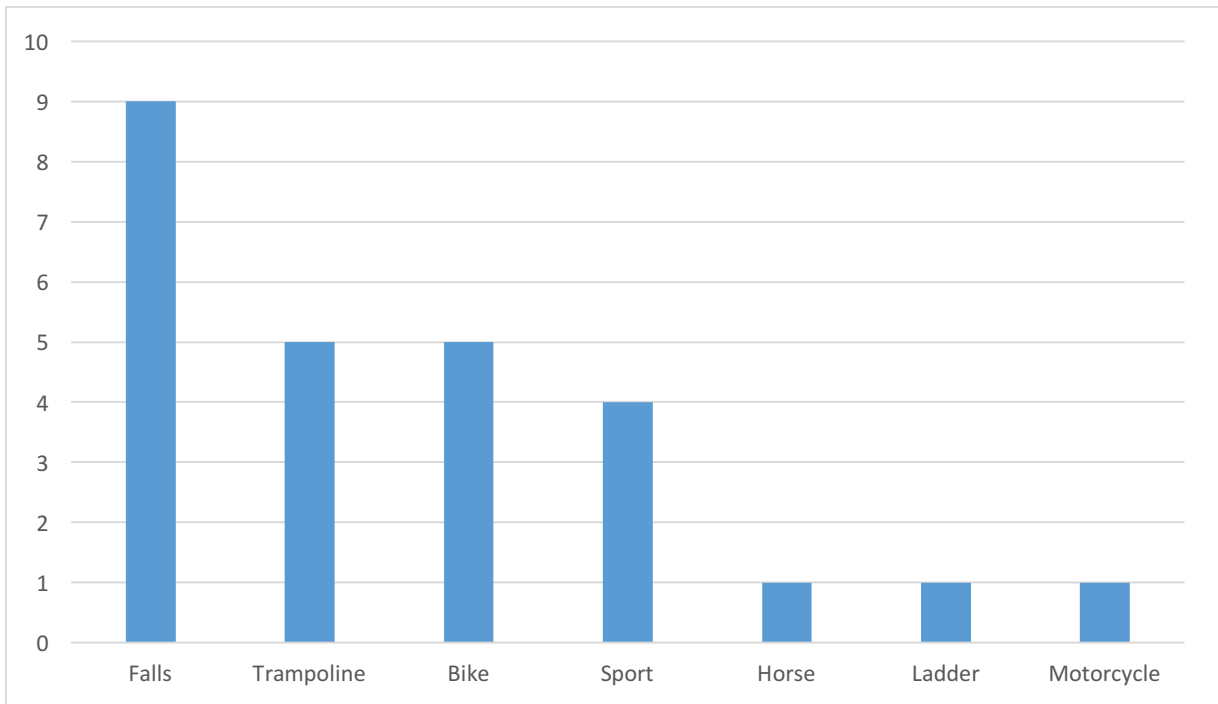


Fig. 10. Distribution of operated children by fracture mechanism (n=26).

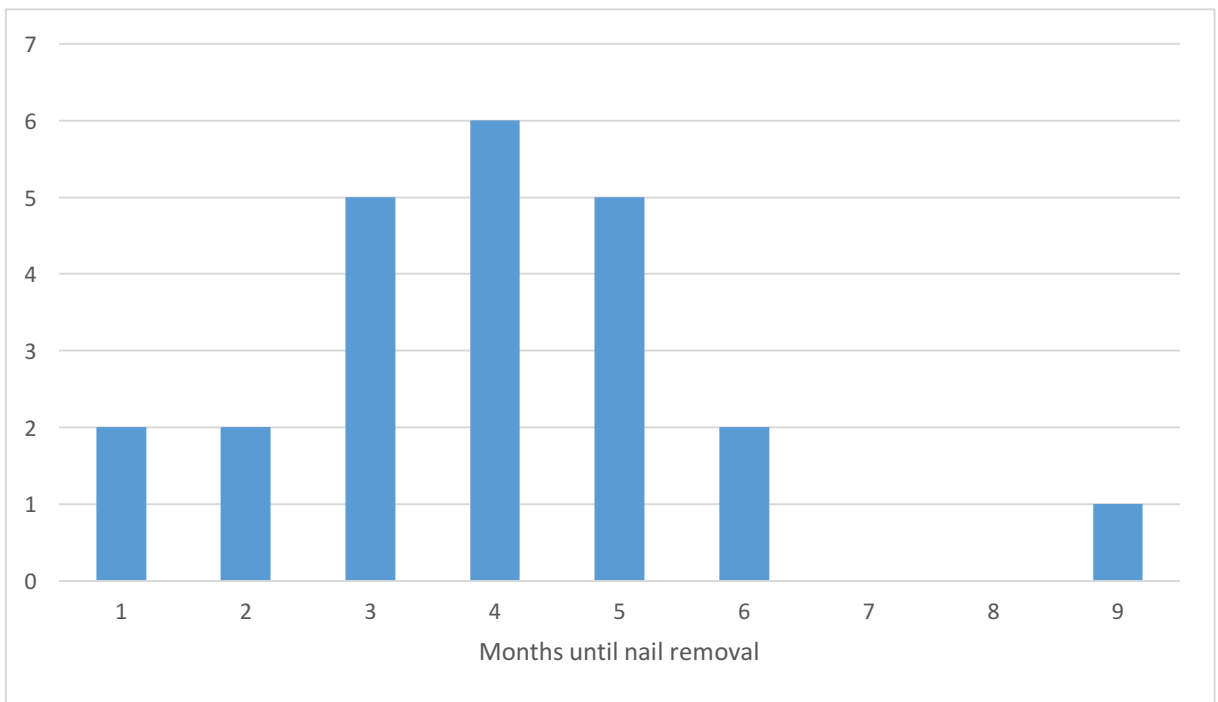


Fig. 11. Distribution of months until the nails got removed.

Fig. 12 shows the distribution of operated children by age. From this figure it is evident that the most of the children were between 9 and 11 years of age. The lowest number of fractures was found in adolescents (n=4, 15.4%) and the highest in elementary school age (n=20, 76.9%).

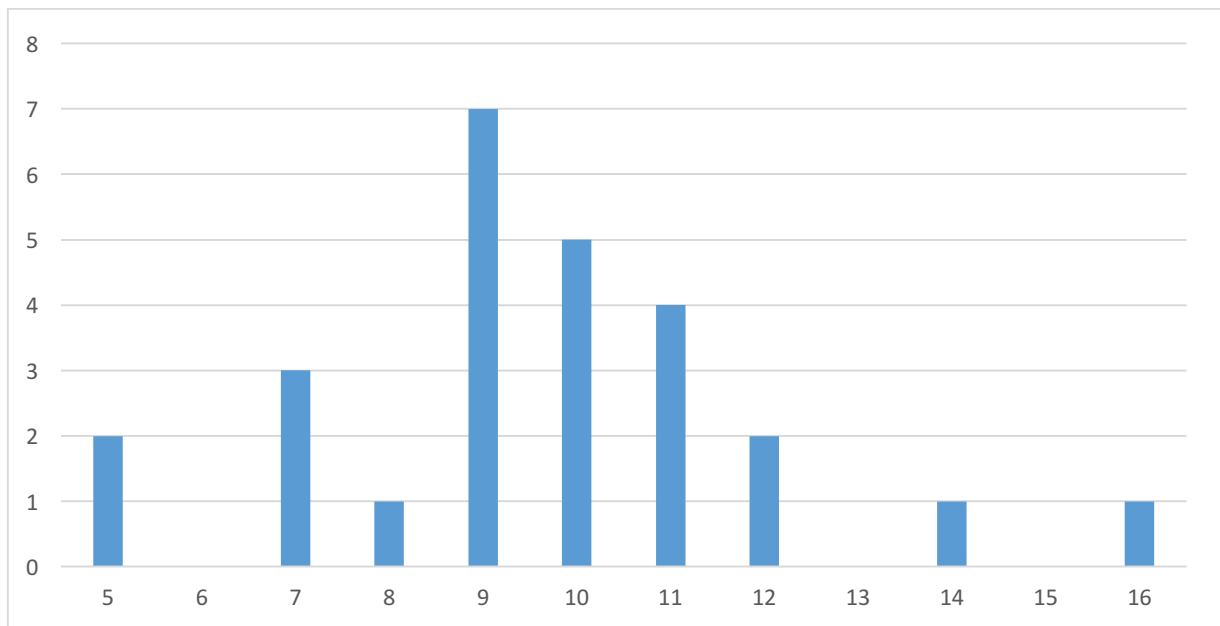


Fig. 12. Distribution of operated children by age (n = 26).

The fractures of the head and neck of the radius were classified according to the Judet's classification (**Table 3**).

Table 3. Distribution of Judet's classification.

Judet Classification	n=26
I	0
II	0
III	15
IV a	6
IV b	5

In 15 (57.69%) of the patients, the fracture was treated with closed reduction. Due to difficulty in reduction and soft tissue interposition, in 6 (23.07%) the fracture was reduced with percutaneous K-wire assistance and in 5 (19.23%) with an open reduction (**Fig. 13**).

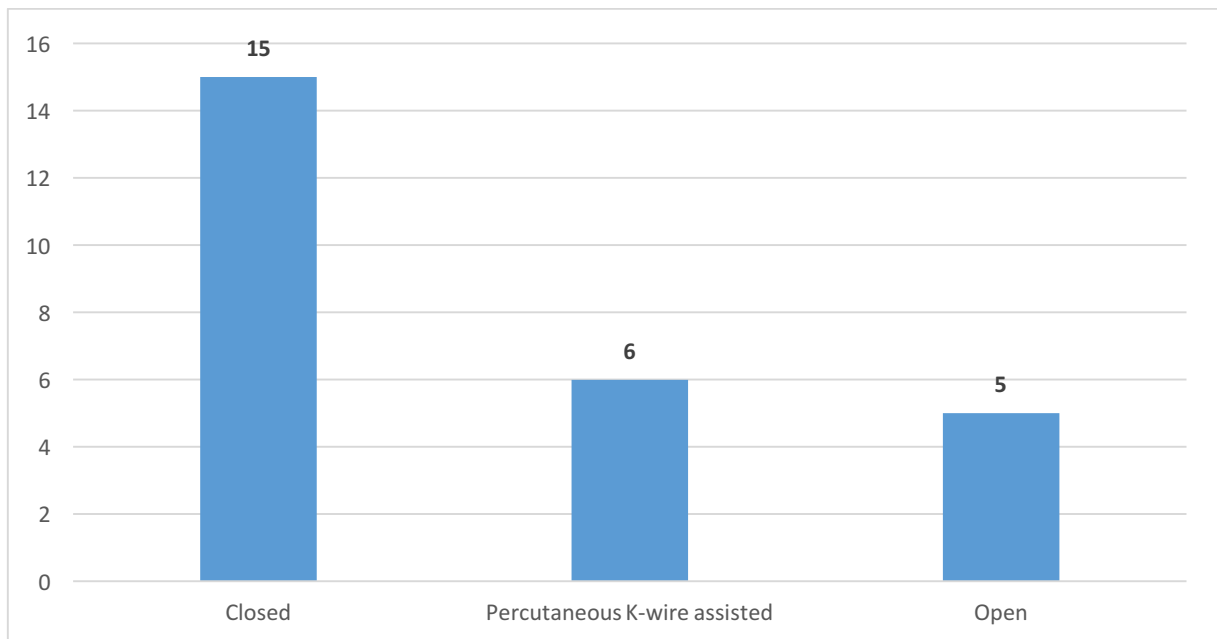


Fig. 13. Distribution of operated children by fracture reduction mode (n = 26).

Six of the patients with radial head and neck fractures had associated injuries. The appearance and severity of the associated injuries was most dependent on the mechanism of fracture. As the circumstances of the fracture were more difficult, the appearance and severity of the associated injuries was greater. Associated injuries were most commonly occurring after a fall from the same level. Specifically, in 3 cases of fractures of the radial head and neck occurring after a fall from the same level, there were some associated injuries. The exact nature and severity of the associated injury were individual in each case and dependent on the severity of the accident itself. Of the other fracture mechanisms associated with injuries, there were 2 cases of injuries on the trampoline and one case after a sports accident.

The most commonly associated injury was an olecranon fracture (n=4, 66.67%). Associated injuries are presented in **Table 4**.

Table 4. Associated injuries.

Associated Injury	n	percentage
Olecranon fracture	4	66.67%
Elbow luxation	1	16.67%
Monteggia fracture	1	16.67%

Table 5. shows the complications that occurred in children treated with the ESIN method due to radial head and neck fractures. In this study a total of 3 complications were recorded.

Table 5. Complications after the ESIN method.

Complication	(n = 3)
Radial head necrosis	1
Posterior angulation of 15°	1
Dislocation of the radial head	1

Out of all patients, 20 (76.92%) achieved a clinically perfect, 5 (19.23%) achieved a clinically good and 1 (3.85%) a clinically bad presentation. Of all 26 patients, 23 (88.46%) patients achieved a radiologically perfect presentation, while 2 (7.69%) achieved a good and 1 (3.85%) achieved a bad radiological presentation. Out of all 26 patients, 3 (11.54%) patients with an outcome less than perfect, had an open reduction, another 3 (11.54%) had a closed reduction and 1 (3.85%) had a reduction with percutaneous K-wire assistance (**Table 6**). Only child with dislocation of radial head was reoperated.

Table 6. Clinical and radiological outcome together with the method of reduction.

OUTCOME	All (n=26)	Closed reduction (n=15)	Open reduction (n=5)	Percutaneous K-wire assisted (n=6)
CLINICAL				
Perfect	20	12	2	6
Good	5	2	3	/
Bad	1	1	/	/
RADIOLOGICAL				
Perfect	23	14	4	5
Good	2	/	1	1
Bad	1	1	/	/

There is no correlation between the method of reduction and the DASH score. This can be seen clearly in **Table 7**. The median DASH score was 1.25% with a IQR ranging from 0-3.8.

Table 7. The distribution of sex, age at injury, days before surgery, type according to Judet's classification, method of reduction and the outcomes

N°	Sex	Age ^a	Days ^b	Judet	Method of reduction	Clinical score	Radiological score	DASH
1	F	10	0	III	Closed	Perfect	Perfect	0%
2	F	9	1	IVa	Closed	Perfect	Perfect	0.8%
3	F	10	0	III	Opened	Good	Good	11.7%
4	F	7	0	III	K-wire assisted	Perfect	Perfect	0%
5	M	12	1	IVa	Closed	Perfect	Perfect	0%
6	F	5	3	III	Closed	Perfect	Perfect	0%
7	F	9	2	IVa	Opened	Perfect	Perfect	2.5%
8	M	14	0	III	K-wire assisted	Perfect	Good	4.2%
9	M	10	0	IVb	K-wire assisted	Perfect	Perfect	0%
10	F	9	0	IVb	Closed	Perfect	Perfect	0%
11	M	11	0	III	Closed	Perfect	Perfect	0%
12	M	12	1	IVa	Closed	Good	Perfect	6.7%
13	F	8	0	III	Closed	Perfect	Perfect	0%
14	F	7	0	III	Opened	Perfect	Perfect	0.8%
15	M	10	0	III	K-wire assisted	Perfect	Perfect	1.7%
16	M	11	1	IVa	Closed	Perfect	Perfect	1.7%
17	F	16	1	IVa	Closed	Perfect	Perfect	0%
18	F	11	3	IVb	Closed	Perfect	Perfect	0%
19	M	11	0	III	Opened	Good	Perfect	2.5%
20	F	9	0	III	K-wire assisted	Perfect	Perfect	4.2%
21	F	9	1	III	Closed	Perfect	Perfect	2.5%
22	F	5	2	III	Opened	Good	Perfect	5.0%
23	M	7	4	IVb	K-wire assisted	Perfect	Perfect	2.5%
24	F	9	2	III	Closed	Good	Perfect	6.7%
25	M	10	0	IVb	Closed	Bad	Bad	39.2%
26	M	9	0	III	Closed	Perfect	Perfect	0%

^a Age at injury.

^b Days before operation.

5. DISCUSSION

Most of the emergency situations in trauma centers are fractures of the long bones. Although most fractures of long bones in children can be treated by closed reduction and cast immobilization, sometimes surgical reduction is required. Historically, external fixation was the method of choice, however, the risks involved include infections, dislocation of fragments and refractories. ESIN is now a commonly used method for treating pediatric fractures of long bones and their use has minimized surgical scarring, previously caused by open reduction techniques. This method achieves biomechanical stability by using a divergent “C” configuration that creates 6 points of fixation and allows a structure that acts as an internal splint (55). The ESIN method provides stable and elastic fixation, allowing controlled motion at the site of fracture, resulting in an outer callus. Several studies have shown the safety and effectiveness of this technique (49, 56). Recently, as new implants and techniques become more accessible, there is a growing tendency towards operational fixation, but the closed reduction and application of casts in such fractures should not be neglected. The ESIN method is not without the possibility of complications. The most commonly reported complications associated with this method include infection, granuloma formation, skin irritation at the site of nail entrance and refracture (55).

At the proximal forearm the radial head and the radial collum fractures are dominant in respect to olecranon fractures (9). Most of the fractures of the radial head and neck were historically treated non-operatively. Treatment of fractures with large displacement in children is controversial. Younger children with good potential for remodelling prefer a conservative approach, while the operational approach to achieve and maintain the fracture reduction is recommended in older children with little potential for remodelling. Various operating techniques using bolts, wedges and tiles have been used, but none is without complications (57). There is a general agreement that displaced radial neck fractures with more than 30° angulations (Judet type III and IV fractures) should be surgically treated. There are several treatment possibilities for Judet type III and IV fractures, including percutaneous pin reduction, ESIN, and open reduction with or without internal fixation (41).

Métaizeau reported that the technique (centromedullary pinning) is easy and requires no special training. The manipulations are totally extraarticular and minimally invasive. With initial displacement of less than 80°, reduction is excellent or good in most cases, resulting in a good or excellent outcome. When the initial tilt exceeds 80°, reduction is good or excellent in 75% of cases. In 25% reduction is insufficient or impossible and open reduction is needed. If the tilt is between 20° and 60°, bad results are seen in 20% of cases after conservative treatment and in 40% after open reduction. In conclusion, conservative treatment should be used in all

tilts of less than 45°, as long as any residual angulation is less than 20°. Because of the innocuous nature of ESIN and the excellent results obtained so far, Métaizeau recommends this method for all residual tilts greater than 20° (43).

Eberl et al. described 42 patients at the age of 3 to 13 years with a fracture of the radial neck that were treated by the ESIN method. After follow-up with a median of 4 months, 38 patients were found to have perfect results, 2 patients achieved good results with a loss of 10° of forearm rotations and 2 patients achieved bad results with a loss of forearm rotation of 40° associated with residual pain. Loss of reduction was seen in 7 (16.7%) patients, but spontaneous fracture remodeling during the further growth process of anatomic axis of the proximal radius was observed until implant removal in these patients. Complications associated with the retrograde nailing technique occurred in just one patient (2.4%). They recommend stabilization using the ESIN method in the treatment of radial neck dislocations. They concluded that the ESIN method in pediatric patients is a simple, short and safe procedure (58).

Al-Aubaidi et al. described 19 patients aged 6.7 to 17 years treated with the ESIN method for displaced radial neck fractures, of which 16 stayed until the end of the study. The functional outcome of the treatment was evaluated using the DASH questionnaire to evaluate the disability of the arm, shoulder, and hand. The median DASH score was 1.25%, the clinical examination revealed excellent axis in all patients. The ROM evaluation revealed excellent results in 15 patients (94%) and bad in one patient (6%). On radiological examination, 14 patients (88%) healed in an anatomical position, one healed with malunion (6%) and one had pseudoarthrosis (6%). The use of Métaizeau centromedullary technique for the treatment of displaced radial neck fractures is described as the golden standard in pediatric radial neck fracture care. It is a simple and minimally invasive technique, and the results in the study are excellent (41).

Radial head and neck fractures are the result of both direct and indirect violence, after a fall on an outstretched arm, driving the capitellum against the outer side of the head of the radius, tilting and displacing it (7, 15). Radial head and neck fractures account for 5-10 per cent of injuries to the elbow region (10).

Prathapkumar et al. described 14 children operated due to displaced fractures of the neck of the radius in children aged 4 to 13 years. The patients were grouped according to Judet's classification. Six patients suffered a type IVb injury, 5 patients a type IVa and 3 patients suffered a type III injury. Three patients had associated injuries, two with fractures of the olecranon and one of the shaft of ulna. These were also treated surgically. All 14 patients were initially treated by closed manipulation to improve the position of the fracture, followed by

ESIN. All were closed injuries with severely displaced fractures. The nails were removed at a median of 4 months. One patient with an open reduction had a neuropraxia of the posterior interosseous nerve, which recovered completely after six weeks, and later developed asymptomatic avascular necrosis of the radial head. The functional outcome showed 13 excellent and one good. The ESIN method has the advantage of achieving acceptable indirect reduction without disturbing the blood supply. Rotational movements can be regained after a short period of immobilisation. They recommended ESIN for severely displaced radial neck fractures in children because of excellent results and low rate of complications (18).

Devgan et al. studied the treatment outcome of 12 children aged 7 to 9 years. All had a history of a fall on an outstretched hand with the elbow extended. No patient developed any postoperative complications. Radiographs did not reveal any complications including avascular necrosis of radial head, premature fusion of proximal radial epiphysis, radioulnar synostosis, or myositis ossificans. All children achieved normal carrying angle. The treatment with ESIN was successful in all their cases. When closed reduction with intramedullary pin fails, an additional joystick technique using a percutaneous wire can be used to fully reduce the radial head (43, 54). They recommend closed reduction using intramedullary pinning because it is a simple, indirect, minimally invasive method that is easy to perform, and obtains exciting results with few complications. Intramedullary pin also achieves fixation of the radial head after reduction and prevents its secondary displacement (54).

Klitscher et al. described 33 children below 16 years of age with Judet type III and IV radial neck fractures that were treated with ESIN. From the total number of patients 28 were available for evaluation. Twenty-six patients were treated using closed reduction, 4 with percutaneous K-wire assistance and 2 had an open reduction followed by ESIN. Twenty-three patients subjectively rated the treatment outcome as being excellent, 3 patients as good and 2 patients as satisfactory. According to the MEPS rating index, there were 23 (82%) excellent results, 5 (18%) good results and no fair or poor results. The conclusion was that ESIN is a minimally invasive technique, allowing stable fixation, early mobilization and anatomical reduction in most cases. The complication rate is low and good-to-excellent results can be expected (59).

Stiefel et al. described 6 patients treated for a type IV fracture of the neck of the radius. In all six patients, the postoperative course was uneventful. Radiologic signs of consolidation were noted at four weeks and healing of the fracture was complete at three months after the injury. After removal of the pin, 5 patients (83.3%) showed complete clinical and radiological recovery with a normal ROM. The patient showing bad clinical and radiological recovery and

whose outcome was graded as bad, also had suffered dislocation of the elbow. Two years after injury the radiograph showed a healed, but bulb-shaped head, angulated at 20°. ESIN offers satisfactory stabilization of the head of the radius while healing of the fracture occurs. They concluded that the technique is safe, easy to perform and minimally invasive. It avoids additional surgical damage and prevents redisplacement and repeated manipulations of the head (36).

In our study, 26 patients were treated with the ESIN method for fracture of the radial head and neck. The average age of the patient was 10 years (5 to 16 years). The most common mechanism of fracture was a fall from ground level. In 15 patients the fracture was reduced by closed reduction, in 6 with percutaneous K-wire assistance and in 5 with open reduction. In this study three complications were recorded (11.54%), including radial head necrosis, a posterior angulation of 15° and one case of radial head displacement. This gives a total complication rate of 11.54%. All complications were resolved without long-term effects and did not affect the results of the treatment. A child with a displacement of radial head was reoperated. 20 patients (76.92%) achieved a perfect clinical healing, while 23 patients (88.46%) achieved a perfect radiological healing. The median DASH score was 1.25% (range, 0 to 39.20%).

The healing results and the rate of complications follow the ESIN method from our study coincide with the above-mentioned data from other studies. The ESIN method is an effective method of treating fractures of the radial head and neck in children with excellent healing results and a low rate of complications. The method meets all criteria for minimally invasive bone surgery.

6. CONCLUSION

1. The ratio of girls to boys was 1.36: 1 in favor of girls (15 girls (57,7%) and 11 boys (42.3%)).
2. The median age at the time of surgery for all patients was 9 years. The lowest number of fractures is found in adolescents (n=4, 15.4%) and the highest in elementary school age (n=20, 76.9%).
3. The distribution of the patients with respect to the lateralization of the fracture was almost symmetrical, the left arm was affected in 53.85% of the patients, and the right in 46.15%.
4. The highest number of fractures was a result from a fall on ground level (n = 9). Other fracture mechanisms include falls from horses or ladders, sports injuries, traffic accidents, motorcycle accidents and cycling.
5. Most of the fractures 15 (57.69%) were treated by closed reduction. Open reduction was needed in 5 (19.23%) fractures. The rest, 6 (23.08%), was treated by percutaneous K-wire assistance.
6. The rate of complications was 11.54%. There was one radial head necrosis, one posterior angulation of 15° and one dislocation of the radial head. All complications were resolved without long-term effects and did not affect the results of the treatment.
7. After removing of the intramedullary nails, all patients returned to full function.
8. ESIN shows very good functional and cosmetic results and allows early functional mobilization with rapid pain reduction.
9. ESIN has many advantages over traditional techniques, shorter treatment time and easier removal of implants.
10. ESIN for radial head and neck fractures is a minimally invasive, simple and reproducible technique with low complication rate.

7. LIST OF LITERATURE

1. Moore KL, Dalley AF, Agur AMR. Clinically Oriented Anatomy. 6th ed. Philadelphia: Lippincott Williams & Wilkins; 2009. p. 678-9.
2. Weiss AP, Hastings H 2nd. The anatomy of the proximal radioulnar joint. *J Shoulder Elbow Surg.* 1992;1(4):193-9.
3. McCarthy SM, Ogden JA. Radiology of postnatal skeletal development. VI. Elbow joint, proximal radius, and ulna. *Skeletal Radiol.* 1982;9(1):17-26.
4. Nussbaum AJ. The off-profile proximal radial epiphysis: another potential pitfall in the x-ray diagnosis of elbow trauma. *J Trauma.* 1983;23(1):40-6.
5. Silberstein MJ, Brodeur AE, Graviss ER. Some vagaries of the radial head and neck. *J Bone Joint Surg Am.* 1982;64(8):1153-7.
6. Evans EM. Rotational deformity in the treatment of fractures of both bones of the forearm. *J Bone Joint Surg Am.* 1945;27(3):373-9.
7. Ogden JA. *Skeletal Injury in the Child.* 3rd ed. New York: Springer-Verlag; 2000. p. 1216.
8. Gaillard F. Salter-Harris classification [Internet]. radiopaedia.org: Radiopaedia; 2016 [updated June 2016; cited June 2017]. Available from: <https://radiopaedia.org/articles/salter-harris-classification>
9. Benz G, Roth H. Fractures of the elbow joint by children and adolescent. *Unfall-Chir.* 1985;11(3):128-35.
10. Kaufman B, Rinott MG, Tanzman M. Closed reduction of fractures of the proximal radius in children. *J Bone Joint Surg Br.* 1989;71(1):66–7.
11. Falciglia F, Giordano M, Aulisa AG, et al. Radial neck fractures in children: results when open reduction is indicated. *J Pediatr Orthop.* 2014;34(8):756-62.
12. Lindham S, Hugosson C. The significance of associated lesions including dislocation in fractures of the neck of the radius in children. *Acta Orthop Scand.* 1979;50(1):79-83.
13. Von Laer L. *Pediatric Fractures and Dislocations.* 4th ed. Stuttgart: Georg Thieme Verlag; 2001. p. 518.
14. Bohrer JV. Fractures of the head and neck of the radius. *Ann Surg.* 1933;97(2):204–8.
15. Vanderhave K. Orthopedic Surgery. In: Doherty GM. *Current Diagnosis and Treatment Surgery.* 14th ed. New York: McGraw Hill Medical; 2015. p. 1061-147.
16. Métaizeau JP, Lascombes P, Lemelle JL, et al. Reduction and fixation of displaced radial neck fractures by closed intramedullary pinning. *J Pediatr Orthop.* 1993;13(3):355-60.
17. Schmittenebecher PP, Havernick B, Harold A, et al. Treatment decision, method of osteosynthesis and outcome in radial neck fractures in children. *J Pediatr Orthop.* 2005;25(1):45-50.

18. Prathapkumar KR, Garg NK, Bruce CE. Elastic stable intramedullary nail fixation for severely displaced fractures of the neck of the radius in children. *J Bone Joint Br.* 2006;88(3):358-61.
19. Jones ERL, Esah M. Displaced fractures of the neck of the radius in children. *J Bone Joint Surg Br.* 1971;53(3):429-39.
20. Steele JA, Graham HK. Angulated radial neck fractures in children. A prospective study of percutaneous reduction. *J Bone Joint Surg Br.* 1992;74(5):760-4.
21. Kiefer GN. Fractures of the Radial Head and Neck. In: Letts RM. *Management of pediatric fractures.* New York: Churchill Livingstone; 1993. p. 369.
22. Vocke AK, Von Laer L. Displaced fractures of the radial neck in children: long-term results and prognosis of conservative treatment. *J Pediatric Orthop B.* 1998;7(3):217–22.
23. Young S, Letts M, Jarvis J. Avascular necrosis of the radial head in children. *J Pediatr Orthop.* 2000;20(1):15-8.
24. von Laer L. Die zusätzliche radiale Traumatisierung des distalen Humerus bei der kindlichen Ellbogenluxation: Häufigkeit und Bedeutung für die Spätprognose. *Orthop Prax.* 1978;14:114.
25. von Laer L, Pirwitz A, Vocke AK. Posttraumatische Problemfälle am kindlichen Ellbogen. *Orthopade.* 1997;26(12):1030-6.
26. Waters PM, Stewart SL. Radial neck fracture nonunion in children. *J Pediatr Orthop.* 2001;21(5):570.6.
27. Dougall AJ. Severe fracture of the neck of the radius in children. *J R Coll Surg Edinb.* 1969;14(4):220-5.
28. von Laer L. Posttraumatische Wachstumsstörungen am kindlichen Ellbogen. *Unfallheilkunde.* 1981;84:101.
29. von Laer L. The fracture of the proximal end of the radius in adolescence. *Arch Orthop Trauma Surg.* 1982;99(3):167-74.
30. Kaps HP, Niethart FU. Die Radiusköpfchenresektion als wiederherstellende Massnahme am Ellenbogengelenk. *Akt Traumat.* 1982;12:263-8.
31. Anderson TE, Breed AL. A proximal radial metaphyseal fracture presenting as wrist pain. *Orthopedics.* 1982;5(4):425-7.
32. Wedge JH. Fractures of the neck of the radius in children. In: Morrey, editors: *The Elbow and its Disorders.* Philadelphia: Saunders; 1985. p. 237.
33. Jeffery CC. Fractures of the neck of the radius in children. Mechanism of causation. *J Bone Joint Surg Br.* 1972;54(4):717-9.

34. Alexander CJ. Effect of growth rate on the strength of the growth plate-shaft junction. *Skeletal Radiol.* 1976;1(2):67-76.
35. Wilson P. Fractures and dislocation in the region of the elbow. *Surg Gynecol Obstet.* 1933;53:335-54.
36. Stiefel D, Meuli M, Altermatt S. Fractures of the neck of the radius in children. Early experience with intramedullary pinning. *J Bone Joint Surg Br.* 2001;83(4):536-41.
37. Fowles JV, Kassab MT. Observations concerning radial neck fractures in children. *J Pediatr Orthop.* 1986;6(1):51-7.
38. Akatsu T. Percutaneous reduction in the treatment of radial neck fracture in children. *Orthop.* 1957;8:269-71.
39. Feray C. Méthode originale de réduction "peu sanglante" des fractures graves de la tête radiale chez l'enfant. *La Presse Medicale.* 1969;77(56):2155-6.
40. Böhler J. Die konservative behandlung von brüchen des radiushalses. *Chirurg.* 1950;21:687-8.
41. Al-Aubaidi Z, Pedersen NW, Nielsen KD. Radial neck fractures in children treated with the centromedullary Métaizeau technique. *Injury.* 2012;43(3):301-5.
42. Okcu G, Aktuglu K. Surgical treatment of displaced radial neck fractures in children with Métaizeau technique. *Ulus Travma Acil Cerrahi Derg.* 2007;13(2):122-7.
43. Métaizeau JP. Reduction and osteosynthesis of radial neck fractures in children by centromedullary pinning. *Injury.* 2005;36(1):75-7.
44. Goldenbert RR. Closed manipulation for the reduction of fractures of the neck of the radius in children. *J Bone Joint Surg.* 1945;27:267-73.
45. Patterson RF. Treatment of displaced fracture of the neck of the radius in children. *J Bone Joint Surg.* 1934;16(3):695-8.
46. Svinukhov NP. The outcomes of operative treatment of fractures of the neck of the radius in children. *Ortop Travmatol Protez.* 1965;26:13-29.
47. Lewis RW, Thibodeau AA. Deformity of the wrist following resection of the radial head. *Surg Gynecol Obstet.* 1937;64:1079-82.
48. Prevot J, Lascombes P, Ligier JN. L'embrochage centromedullaire elastique stable: methode d'osteosynthese des fractures des membres chez l'enfant. Principe et application au femur. A propos de 250 fractures suivies depuis 1979. *Chirurgie.* 1994;119(9):473-6.
49. Li Y, Stabile KJ, Shilt JS. Biomechanical analysis of titanium elastic nail fixation in a pediatric femur fracture model. *J Pediatr Orthop.* 2008;28(8):874-8.

50. McKibbin B. The biology of fracture healing in long bones. *J Bone Joint Surg Br.* 1978;60-B(2):150-162.
51. Furlan D, Pogorelić Z, Biočić M, et al. Elastic stable intramedullary nailing for pediatric long bone fractures: experience with 175 fractures. *Scand J Surg.* 2011;100(3):208-15.
52. Ugutmen E, Ozkan K, Ozkan FU, et al. Reduction and fixation of radius neck fractures in children with intramedullary pin. *J Pediatric Orthop B.* 2010;19(4):289-93.
53. Steinberg EL, Golomb D, Salama R, et al. Radial head and neck fractures in children. *J Pediatr Orthop.* 1988;8(1):35-40.
54. Devgan A, Singh R, Kumar S, et al. Indirect Reduction and Intramedullary Pinning in Severely Displaced Radial Neck Fractures in Children. *Int J Clin Med.* 2011;2(2):75-8.
55. Sankar WN, Jones KJ, David Horn B, Wells L. Titanium elastic nails for pediatric tibial shaft fractures. *J Child Orthop.* 2007;1(5):281-6.
56. Garcia-Mata S, Hidalgo-Ovejero A. Triplane fracture of the distal radius. *J Ped Orthop B.* 2006;15:298–301.
57. Helenius I, Lamberg TS, Kääriäinen S, Impinen A, Pakarinen MP. Operative treatment of fractures in children is increasing. A population-based study from Finland. *J Bone Joint Surg Am.* 2009;91(11):2612–2616.
58. Eberl R, Singer G, Fruhmann J, et al. Intramedullary Nailing for the Treatment of Dislocated Pediatric Radial Neck Fractures. *Eur J Pediatr Surg.* 2010;20(4):250-2.
59. Klitscher D, Richter S, Bodenschatz K, et al. Evaluation of Severely Displaced Radial Neck Fractures in Children Treated With Elastic Stable Intramedullary Nailing. *J Pediatr Orthop.* 2009;29(7):698-703.

8. SUMMARY

Objective: The aim of the study was to establish the demographic and clinical characteristics of children operated by the ESIN method for radial head and neck fractures, analyze the outcomes of treatment and the rate of complications, and compare them with other relevant studies.

Subjects and Methods: From May 2011 to May 2017, 26 children treated with the ESIN method for radial head and neck fracture, in the Department of pediatric surgery of the University hospital of Split, were retrospectively reviewed. The following parameters were analyzed for each subject: age, sex, fracture mechanism, lateralization, method of reduction, associated injury, healing time, clinical / radiological outcomes, DASH score and complications of treatment.

Results: The study covered 26 patients (15 girls, 11 boys) treated with ESIN method for fractures of radial head and neck. The average age was 9 years (5 to 16 years). The distribution of the patient with regard to the lateralization of the fracture was almost symmetric, the left arm was affected in 53.85% of the patients, and the right at 46.15%. The most common fracture mechanism was a fall on ground level (n = 9). All patients achieved healing in 5 weeks of average duration (3 – 7). The nails were removed at a median of 4 months (range, 1 to 9). The rate of complications was 11.54%, including one radial head necrosis, one angulation of 15° and one displacement of the radial head. Twenty patients (76.92%) achieved a perfect clinical healing, while 23 patients (88.46%) achieved a perfect radiological healing. The median DASH score was 1.25% (0 to 39.20%). There were no cases of delayed healing. There was one case of healing in bad position, this child was reoperated. After removing the intramedullary nails, all patients returned to full function of the extremity and all complications were resolved.

Conclusion: The ESIN method for treating fractures of the radial head and neck in children shows very good functional and cosmetic results. It allows mobilization with rapid pain reduction. The ESIN method for radial head and neck fractures is a minimally invasive, simple and reproducible technique with a low rate of complications. Due to these excellent objective and subjective results, the surgical stabilization of radial head and neck fractures using the ESIN method is recommended in children and adolescents.

9. SUMMARY IN CROATIAN

Cilj istraživanja: Cilj ovog istraživanja je ustanoviti demografske i kliničke karakteristike djece operirane ESIN metodom zbog prijeloma glavice i vrata palčane kosti, analizirati ishode liječenja i stopu komplikacija, te ih usporediti s ostalim relevantnim studijama.

Ispitanici i metode: U vremenskom razdoblju od svibnja 2011. do svibnja 2017. retrospektivno su pregledane povijesti bolesti 26 djece liječene ESIN metodom zbog prijeloma glavice i vrata palčane kosti u Klinici za dječju kirurgiju Kliničkog bolničkog centra Split. Svakom ispitaniku analizirani su sljedeći parametri: dob, spol, mehanizam prijeloma, lateralizacija, način repozicije, pridružene ozljede, vrijeme cijeljenja, klinički/radiološki rezultati, DASH score i komplikacije liječenja.

Rezultati: Istraživanjem je obuhvaćeno 26 bolesnika (15 djevojčica i 11 dječaka) liječenih ESIN metodom zbog prijeloma glave i vrata palčane kosti. Prosječna dob bila je 9 godina (5-16 godina). Raspodjela bolesnika obzirom na lateralizaciju prijeloma bila je gotovo simetrična, lijeva ruka bila je zahvaćena u 53.85% bolesnika, a desna u 46.15%. Najčešći mehanizam prijeloma bio je pad u razini (n=9). Svi bolesnici postigli su cijeljenje u srednjem vremenu od 5 tjedana (raspon 3-7). Čavli su bili uklonjeni u prosjeku od 4 mjeseca (raspon, 1-9). Stopa komplikacija bila je 11.54% uključujući jednu nekrozu glavice palčane kosti, jednu angulaciju od 15° te jedan potpuni pomak glavice palčane kosti. Dvadeset pacijenata (76.92%) postiglo je odlično kliničko cijeljenje, dok je u 23 pacijenta (88.46%) postignuto odlično radiološko cijeljenje. Srednji DASH score bio je 1.25% (raspon, 0-39.20%). Nije bilo slučajeva odgođenog cijeljenja. Dijete s potpunim pomakom glavice palčane kosti je reoperirano. Nakon uklanjanja intramedularnih čavala, svi bolesnici vratili su potpunu funkciju ekstremiteta i sve komplikacije su razriješene.

Zaključci: ESIN metoda za liječenje prijeloma glavice i vrata palčane kosti u djece pokazuje jako dobre funkcionalne i kozmetičke rezultate. Omogućava mobilizaciju sa brzim smanjenjem boli. ESIN za prijelome glavice i vrata palčane kosti je minimalno invazivna, jednostavna i reproducibilna tehnika, s niskom stopom komplikacija. Zbog ovih izvrsnih objektivnih i subjektivnih rezultata, operacijska stabilizacija prijeloma glavice i vrata palčane kosti pomoću ESIN metode preporuča se u djece i adolescenata.

PERSONAL INFORMATION

NAME AND SURNAME: André Capitain

DATE AND PLACE OF BIRTH: March 28th 1991, Frankfurt-Hoechst, Germany

NATIONALITY: German

RESIDENCE ADDRESS: Soltanska 20, 21000 Split, Croatia

TELEPHONE: +385 95 5032 063

E-MAIL: andre.capitain@gmail.com

EDUCATION

1997 – 2000 Taubenbergschule Idstein (Elementary School)

2000 – 2001 Grundschule Wiechs (Elementary School)

2001 – 2007 Montfort Realschule-Zell

2007 – 2010 Mathilde-Planck-Schule Lörrach (Abitur)

2011 – 2017 Faculty of Medicine, University of Split

SCIENCE AND SKILLS

Category B driver

Fluent english knowledge