

The effect of physical therapy treatment on shoulder pain, mobility and functional index in the working population

Dirkwinkel, Johanna Sophie

Master's thesis / Diplomski rad

2017

Degree Grantor / Ustanova koja je dodijelila akademski / stručni stupanj: **University of Split, School of Medicine / Sveučilište u Splitu, Medicinski fakultet**

Permanent link / Trajna poveznica: <https://um.nsk.hr/um:nbn:hr:171:764395>

Rights / Prava: [In copyright](#)/[Zaštićeno autorskim pravom.](#)

Download date / Datum preuzimanja: **2024-11-25**



Repository / Repozitorij:

[MEFST Repository](#)



**UNIVERSITY OF SPLIT
SCHOOL OF MEDICINE**

Johanna Dirkwinkel

**THE EFFECT OF PHYSICAL THERAPY TREATMENT ON
SHOULDER PAIN, MOBILITY AND FUNCTIONAL INDEX
IN THE WORKING POPULATION**

Diploma thesis

Academic year:

2016/2017

Mentor:

Assistant Professor Jure Aljinovic, MD, PhD

Split, June 2017

**UNIVERSITY OF SPLIT
SCHOOL OF MEDICINE**

Johanna Dirkwinkel

**THE EFFECT OF PHYSICAL THERAPY TREATMENT ON
SHOULDER PAIN, MOBILITY AND FUNCTIONAL INDEX
IN THE WORKING POPULATION**

Diploma thesis

Academic year:

2016/2017

Mentor:

Assistant Professor Jure Aljinovic, MD, PhD

Split, June 2017

1. Introduction.....	6
1.1. Anatomy of the shoulder	7
1.1.1. Bones of the shoulder girdle	7
1.1.2. Joints of the shoulder girdle.....	8
1.1.3. Muscles of the shoulder girdle.....	10
1.1.3.1. Dorsal muscles of the shoulder with insertion at the humerus	10
1.1.3.2. Ventral muscles of the shoulder with insertion at the humerus	12
1.1.3.3. Dorsal muscles of the trunk with insertion at the shoulder girdle	13
1.1.3.4. Ventral muscles of the trunk with insertion at the shoulder girdle.....	14
1.1.3.5. Muscles of the head with attachment at the shoulder girdle	14
1.2. Pathology of the shoulder	15
1.2.1. Adhesive capsulitis	16
1.2.2. Rotator cuff syndrome	17
1.2.3. Bicipital tendinitis.....	17
1.2.4. Calcific tendinitis of the shoulder.....	18
1.2.5. Impingement syndrome of shoulder	18
1.2.6. Shoulder instability	18
1.2.7. Shoulder dislocations.....	19
1.3. Clinical examination of the shoulder complex.....	19
1.3.1. History	20
1.3.2. Inspection.....	20
1.3.3. Palpation	20
1.3.4. Range of motion	20
1.3.5. Specialized tests.....	21
1.3.5.1. Tests for impingement	21
1.3.5.2. Tests for instability	22
1.3.5.3. Tests for labral lesions	22
1.3.5.4. Tests for biceps tendon	22
1.3.5.5. Tests for scapular winging	22
1.3.5.6. Tests for thoracic outlet syndrome.....	23
1.3.5.7. Neurologic evaluation.....	23
1.4. Diagnostic procedures for the shoulder joint	23
1.4.1. Plain radiography in shoulder pain work-up.....	23
1.4.2. Ultrasonography of the shoulder.....	24
1.4.3. Magnetic resonance imaging and magnetic resonance angiogram.....	24
1.5. Shoulder pathology in the working population	25

1.5.1. Occupational mechanical risk factors	25
1.5.2. Psychosocial occupational risk factors	25
2. Objectives of research.....	27
3. Material and methods.....	29
3.1. Structure and protocol of research	30
3.2. Subjects of research.....	30
3.3. Interventions, measures and other observations	30
3.4. Statistics Analysis.....	31
4. Results	32
5. Discussion	38
6. Conclusion	42
7. List of Literature	44
8. Summary in English	49
9. Summary in Croatian	51
10. Curriculum Vitae.....	53
11. Appendix.....	56

Acknowledgements

I would like to thank my mentor Assist. Prof. Jure Aljinovic, MD, PhD, for his continuous advice and encouragement during the times of writing my thesis.

Mindestens ebenso viel Dank den Schniepies, Team Molat und Familie Hagenberg für die Unterstützung vor Ort in den vergangenen Jahren.

Dank an Angela, die Berliner Truppe und die Lünis - ohne Eure Besuche und die Skypedates wäre es mitunter etwas einsam gewesen.

Mama, Papa, Lea und Jan, ihr seid die beste Familie, die ich mir vorstellen kann. Vielen Dank für alles.

1. Introduction

1.1. Anatomy of the shoulder

The shoulder can be considered as one of the largest and most flexible joints in the human body. It functions as a ball and socket joint, in which the head of the humerus articulates with the glenoid fossa of the scapula. The sternoclavicular, acromioclavicular and scapulothoracic articulations can furthermore be described as parts of the shoulder complex. Stability is added by several bony and especially non-bony structures: The acromion of the scapula forms the upper bony border of the joint, whereas the coracoid process of the scapula acts as an anterior margin. The musculo-tendinous rotator cuff surrounds the shoulder, thus stabilizing the joint. The four main tendons involved in the shoulder complex are the coracoglenoid, coracohumeral, coracoacromial and the glenohumeral tendons (1).

1.1.1. Bones of the shoulder girdle

The bony part of the pectoral or shoulder girdle consists of two paired bones, the scapulae and the clavicles, linked to the axial skeleton by the sternoclavicular joints.

The Clavicle

The clavicles are two long bones that lie approximately horizontal and have a slight s-shaped curve. They articulate medially with the sternum forming the sternoclavicular joint and laterally with the acromion of the scapula in the acromioclavicular joint. At the inferior side of the clavicle large tendons attach at a medial and lateral site.

The Scapula

The scapular bones are roughly triangular, flat bones with a relatively smooth, slightly curved ventral side, also known as the blade and a rough dorsal surface. The blade has three borders: the medial, lateral and superior border. The spine of the scapula is a prominent bony ridge at the dorsal side of the bone dividing it into the supraspinous and infraspinous fossa. It arises medially at the trigonum spinae and ends laterally in a flat, angular bony projection known as the acromion. The acromion stands free from the rest of the bone. At the acromial tip, the clavicle articulates with the scapula. Lateral to the acromion, the articulation for the clavicle can be found. The glenoid fossa can be found at the neck of the scapula in its lateral angle. It is a slightly concave cavity and the articular surface for the shoulder joint. Below and

above the glenoid fossa are the infra- and supraglenoid tubercles, where tendons attach. A ring of fibrous cartilage known as the glenoid labrum runs around the glenoid fossa and extends the shoulder joint, rendering it deeper and wider. Above the glenoid cavity, the coracoid process arises ventro-laterally. It protects the underlying shoulder joint and serves as attachment for muscles and tendons. Together with the acromion and the coracoacromial ligament, which connects the coracoid process and the acromion, it forms the superior border of the shoulder joint.

1.1.2. Joints of the shoulder girdle

The joints of the pectoral girdle are the medial and lateral clavicular articulations (sternoclavicular and acromioclavicular joint respectively), as well as the glenohumeral joint, which is commonly referred to as the shoulder joint.

The Sternoclavicular joint

The bony parts of the sternoclavicular joint are formed by the medial end of the clavicle and the manubrium of the sternum. Between these structures lies the articular disc, which separates the joint space in two compartments thus compensating for surface irregularities. The sternoclavicular joint is protected and stabilized by the anterior and posterior sternoclavicular ligaments. Furthermore, the costoclavicular ligament connects the clavicle to the first rib and the interclavicular ligament joins the sternal ends of both clavicles. Functionally speaking, the medial clavicular joint is a ball and socket joint, though with very decreased motility and flexibility in all degrees of freedom.

The Acromioclavicular joint

The bony articulations of the acromioclavicular joint are the lateral end of the clavicle and the acromion of the scapula. An articular disc incompletely separates the joint space into two compartments. Four ligaments secure the joint capsule:

The coracoclavicular ligament extends from the coracoid process to the clavicle and is separated into a medial and lateral part.

The conoid ligament fans out from the base of the coracoideus to the conoid tubercle of the clavicle.

The trapezoid ligament spreads from the upper boarder of the coracoid process to the trapezoid line of the clavicle.

Last but not least, the acromioclavicular ligament reinforces the joint capsule in the upper part.

The acromioclavicular articulation is a plane joint, however with three degrees of freedom. The movements are coupled with those of the sternoclavicular joint. Elevation and depression as well as protraction and retraction of the shoulder are possible. Furthermore, circumduction and rotation can be performed.

The Glenohumeral joint

The glenohumeral joint or shoulder joint is known to be the most flexible joint in the human body with the greatest range of motion. It is a ball and socket joint with three degrees of freedom: ante- and retroversion, internal and external rotation as well as ab- and adduction. Elevation is only possible by movement of the scapula. Circumduction of the upper arm can also be performed in the shoulder joint. The range of motion in the glenohumeral joint is as follows: external rotation: 80°, internal rotation: 100°, flexion: 90°, extension: 90°, abduction: 90° and adduction: 40°. The range of motion can be largely increased, however, by changing position of the socket when elevating the arm. The so called scapulohumeral rhyth enables us to perform abduction as well as anteflexion to 160°. Up to one third of the humerus' movement in respect to the body is performed by movement of the scapula.

The head of humerus is almost four times as big as the cartilage covered part of the glenoid fossa. In order to increase the articulating surface, it is framed by the fibro-cartilaginous ring of the glenoid labrum. The joint capsule of the shoulder spreads from the neck of the scapula over the glenoid cavity to the humerus, including its anatomical neck.

When the arm is hanging loosely downwards, the capsule shows a reserve fold called the recessus axillaris at the inferior margin. The increased width of the capsule leads to an increased range of motion. Furthermore, the intertubercular tendon sheath can be found. It surrounds the long tendon of biceps and runs through the joint capsule.

The ligaments of the shoulder joint are the coracoacromial ligament between the coracoid process and the acromion above the actual joint, the coracohumeral ligament, which stretches from the coracoid process to the greater and lesser tubercle of the humerus and

reinforces the capsule anteriorly, and the glenohumeral ligament for further reinforcement of the anterior aspect of the capsule.

The shoulder joint is surrounded by a group of muscles referred to as the rotator cuff, which add further stability. The most important synovial bursae of the shoulder joint are the subacromial and the subdeltoid bursa.

1.1.3. Muscles of the shoulder girdle

The great flexibility of the upper limb is made possible by numerous muscles. Topographically, the muscles of the trunk and shoulder girdle can be allocated into ventral and dorsal groups.

Furthermore, we can divide them as follows: Muscles of the shoulder girdle that insert at the humerus, muscles of the trunk that insert at the pectoral girdle and muscles of the head and neck with insertion at the shoulder girdle.

1.1.3.1. Dorsal muscles of the shoulder with insertion at the humerus

These muscles arise dorsally and insert at the major tubercle or at the deltoid tuberosity of the humerus.

Musculus supraspinatus

The supraspinatus arises at the supraspinous fossa of the scapula and extends to the major tubercle of the humerus. It performs abduction and external rotation in the shoulder joint. It furthermore acts as a reinforce of the joint capsule and holds the humerus in space. It is part of the rotator cuff and is innervated by the suprascapular nerve arising from C4-C6. In case of a lesion of the supraspinatus, the head of humerus is at risk of displacement resulting in a subluxation.

Musculus infraspinatus

As its name suggests, the infraspinatus arises in the infraspinous fossa of the scapula. It inserts at the major tubercle of the humerus and its major task is to perform external rotation. It works as an abductor on the elevated arm and as an adductor on the lowered arm.

Just as the supraspinous muscle, the infraspinatus is part of the rotator cuff reinforcing the capsule of the shoulder joint and is innervated by the suprascapular nerve.

Musculus teres minor

Teres minor is the most important external rotator in the shoulder joint. It arises at the lateral border of the scapula and inserts at the major tubercle of the humerus. Besides external rotation, it also performs adduction in the shoulder joint. It is innervated by the axillary nerve, which arises from C5-C6. Teres minor belongs to the rotator cuff muscles.

Musculus subscapularis

The subscapular muscle is the fourth muscle to form the rotator cuff. It arises on the ventral side of the scapula and inserts at the minor tuberosity and the minor tubercular crest of the humerus. Its main movements are internal rotation, abduction and adduction. It is innervated by the subscapular nerve. Close to its insertion, the subtendinous bursa and the subcoracoid bursa can be found.

Musculus deltoideus

The deltoid muscle consists of three parts: the clavicular part, the acromial part and the spinal part. All muscle fibres join together and form a muscle coat that overrides the shoulder joint and inserts at the deltoid tuberosity of the humerus. Like a cap it covers the entire shoulder joint as well as the muscles and tendons of the rotator cuff. With its three parts, it is associated with different movements. It mainly acts in the shoulder joint in abduction and pendular movement. Likewise, it carries the weight of the arm and participates in adduction, flexion and extension. The deltoid is innervated by the axillary nerve (C4-C6). Paralysis can lead to subluxation and limited abduction.

Musculus teres major

Teres major originates at the lateral border and the inferior angle of the scapula. It inserts at the minor tubercular crest of the humerus. It is bordered by the subscapular muscle ventro-cranially, the teres minor dorso-cranially and the scapular part of the latissimus dorsi caudally. The teres major muscle enables internal rotation, adduction and retroversion in the

shoulder joint. If it is injured, the arm is fixed in external rotation. Teres major is innervated by the thoracodorsal nerve (C6-C7) and / or by the subscapular nerve. It is separated from the latissimus dorsi muscle by the subtendinous bursa of latissimus dorsi.

Musculus latissimus dorsi

Latissimus dorsi consists of four parts with different origins: The vertebral part originates at the spinous processes of the 7th till 12th thoracic vertebrae, the iliac part arises at the thoracolumbar fascia and the iliac crest, the costal part originates at ribs ten to twelve and the scapular part arises at the inferior angle of the scapula. The fibres of all parts unite and insert at the minor tubercular crest. Latissimus dorsi enables internal rotation, adduction and retroversion in the shoulder joint and is innervated by the thoracodorsal nerve (C6-C7). Paralysis of this muscle leads to medial and caudal subluxation. Latissimus dorsi covers almost the entire back. It contracts in forceful expiration and can be used as accessory muscle for deep breathing.

1.1.3.2. Ventral muscles of the shoulder with insertion at the humerus

Musculi pectoralis minor and major and musculus coracobrachialis originate at the shoulder girdle and insert at the humerus.

Musculus pectoralis minor

The pectoralis minor muscle arises at the 3rd to 5th rib and inserts at the coracoid process. It fixes the scapula to the trunk and can act as accessory muscle of respiration. It is located underneath pectoralis major on the ventral thoracic wall. It is innervated by the pectoralis nerves (C6-C8).

Musculus pectoralis major

Pectoralis major consists of three parts: The clavicular part originates ventrally on the medial part of the clavicle. The sternocostal part arises at the 2nd till 7th costal cartilage. The abdominal part has its origin at the rectus sheath. The muscle fibres cross over and attach at the major tubercular crest of the humerus. Different functions of the muscle can be enabled by interaction of the three parts: Adduction and internal rotation, flexion of the abducted arm and

anterior lowering of the shoulder. It acts as an important accessory muscle of respiration and is innervated by the pectoral nerves. It is covered by two fasciae: the pectoral fascia ventrally and the clavipectoral fascia dorsally.

Musculus Coracobrachialis

The coracobrachial muscle arises at the coracoid process alongside the short head of biceps. The muscle fibres insert at the medial side of the humerus. The coracobrachialis is pierced by the musculocutaneous nerve. Its main function is internal rotation, adduction and anteversion in the shoulder joint. The coracobrachial muscle is innervated by the musculocutaneous nerve (C5-C7).

1.1.3.3. Dorsal muscles of the trunk with insertion at the shoulder girdle

Musculi rhomboideus major and minor, musculus levator scapulae, and musculus serratus anterior originate at the trunk and insert at the shoulder girdle.

Musculus rhomboideus major and musculus rhomboideus minor

The rhomboid muscles arise at the spinous processes of the 1st - 4th thoracic (major) and 6th - 7th cervical (minor) vertebrae and insert at the medial border of the scapula. Their task is retraction of the scapula and its fixation to the thoracic wall. They are innervated by the dorsal scapular nerve (C4-C5).

Musculus levator scapulae

As its name suggests, the levator scapulae elevates the scapula. It originates at the posterior tubercles of the transverse processes of the 1st – 4th cervical vertebrae and extends to the superior angle and sometimes to the medial margin of the scapula. It is situated ventrally to the scalenus muscle and is innervated by the dorsal scapular nerve (C4-C5)

Musculus serratus anterior

The serratus anterior muscle consists of three parts (superior, intermediate and inferior), that originate from the first nine ribs. They attach at the scapula at the superior angle, the medial border and the inferior angle respectively. The muscle enables movement of

the scapula anteriorly, anteversion of the arm, outwards movement of the scapula and elevation of the arm. Together with the rhomboids it fixes the scapula to the chest wall. Failure of the muscle leads to wing like protrusion of the scapula, called scapula alata. Serratus anterior is innervated by the long thoracic nerve (C5-C7).

1.1.3.4. Ventral muscles of the trunk with insertion at the shoulder girdle

The musculus subclavius und the omohyoideus belong into this group. As the omohyoid is of little importance for this study, it shall not be discussed any further.

Musculus subclavius

The subclavius muscle originates at the first rib at the costochondral border and extends to the clavicle, where it attaches at the inferior side at the subclavian sulcus. It pulls the clavicle in the direction of the sternum, thus securing the sternoclavicular joint. It is innervated by the subclavian nerve.

1.1.3.5. Muscles of the head with attachment at the shoulder girdle

The trapezius and sternocleidomastoid are paired muscles of the head and neck region. As they attach at the shoulder girdle, they shall shortly be mentioned for the sake of completeness.

Musculus sternocleidomastoideus

The sternocleidomastoid has a medial and a lateral head that originate at the medial clavicle and the manubrium of the sternum, respectively. It inserts at the mastoid process of the temporal bone and the superior nuchal line. It is innervated by the accessory nerve and is involved in movement of the head.

Musculus trapezius

The trapezius consists of a descending, horizontal and ascending part. Its origin is located at the external occipital protuberance, and at the spinous processes of the 7th cervical till 12th thoracic vertebrae. It attaches to the lateral third of the clavicle, the acromion and the spine of the scapula. It is innervated by the accessory nerve. The trapezius can move the

scapula upwards, downwards and dorsally. Furthermore, it enables turning of the head to the contralateral side and it can pull the clavicle dorsally and lift the arm slightly above horizontal level (1).

1.2. Pathology of the shoulder

Given the mere complexity of the shoulder joint and the various movements it enables, the high incidence of shoulder pain and the variability of aetiology becomes understandable (2). The shoulder's great flexibility and the nature of daily demands on it render it more prone to injuries, strains and other articular and periarticular pathologies (2). Especially repetitive and excessive movements as well as frequent over-head activities seem to be associated with an increased risk of local injuries to the shoulder complex (3,4).

With increasing patient age, the prevalence of shoulder pain increases suggesting progressive weakening and degeneration (4). High demand on the shoulder girdle by strenuous and repetitive exercises and movements, female sex and psychosocial stress were also described as risk factors (5). Differential diagnosis of shoulder pain includes inflammatory rheumatic diseases, systemic diseases such as malignancy or infection, referred pain from the neck, intra-abdominal, pulmonary and diaphragmatic area, cardiovascular insult, articular pathology, bone pathology and soft tissue local pathology (2). Intrinsic causes of shoulder pain are more common than pain resulting from extrinsic pathologies, however the latter need to be included in finding differential diagnosis, as they may be signs of underlying, potentially life-threatening disease (6). The majority of shoulder disorders can be grouped into three categories: arthritis, soft tissue disorders and articular injury or instability (7). Grouping can also be based on chronicity or on the affected anatomic structures (8). The WHO's "International Classification of Diseases" categorizes shoulder lesions as follows:

Table 1. ICD M75 Shoulder lesions (9)

M75	Shoulder lesions
M75.1	Rotator cuff syndrome
	Rotator cuff or supraspinatus tear or rupture (complete) (noncomplete), not specified as traumatic
	Supraspinatus Syndrome
M75.2	Bicipital tendinitis
M75.3	Calcific tendinitis of shoulder
	Calcified bursa of shoulder
M75.4	Impingement syndrome of the shoulder
M75.5	Bursitis of shoulder
M75.8	Other shoulder lesions
M75.9	Shoulder lesions, unspecified

ICD: International Classification of Diseases

The following paragraphs will evaluate the most common shoulder pathologies, putting the main emphasis on non-traumatic, non-arthritic causes of shoulder pain. The categorization will stick to M75.O-M75.4 of the WHO's ICD, adding shoulder instability as well as shoulder dislocations.

1.2.1. Adhesive capsulitis

Adhesive capsulitis of the shoulder, also termed frozen shoulder is a disabling condition with decreased range of motion without structural lesion. It usually occurs in the middle age and, in the general population, has an estimated prevalence of 2% (10). Dias, Cutts and Massoud have established the three hallmarks of true frozen shoulder (11). These include: severe pain, even at night time, almost complete loss of external rotation of the shoulder – both active and passive – and insidious onset of shoulder stiffness (11). Duration of this condition is about 30 months and recovery can be accelerated, though complete regain of range of motion may never occur. Frozen shoulder syndrome, according to Dias et al. can

be divided into three phases: the painful freezing phase, lasting 10-36 weeks and the adhesive phase at 4-12 months, which usually is followed by the resolution phase which leads to spontaneous improvement of the disorder (11). As for pathogenesis, there are three theories regarding the underlying mechanisms: inflammatory, fibrosing and algoneurodystrophic processes have all been discussed (11).

1.2.2. Rotator cuff syndrome

According to Holmes, Barfield and Woolf, the most common cause for a patient with shoulder pain to visit their doctor is pathology of the rotator cuff (>60%) (12). However, Walker-Bone, Palmer, Reading et al. found capsulitis to be the most common, with a prevalence almost twice the one of rotator cuff syndrome (13). This discrepancy may be due to the fact, that definition of rotator cuff pathology and the conditions to be included in this diagnosis, is inconsistent throughout literature. For instance, some studies describe impingement syndrome as a type of rotator cuff disorder, whereas others see it as a distinct entity (6,8,12,14).

Description of the clinical picture does not vary greatly, though. The pain in rotator cuff pathologies is often described as dull, extending over the shoulder and the lateral arm. Its onset is gradual and the pain is usually worse at night, which might awaken the patient from sleep. It is exacerbated by overhead activities. In advanced cases, weakness may be noticed as well as the inability to elevate and abduct the arm. If the onset of weakness occurs suddenly, it may suggest an acute tear of muscle fibres or tendons of the rotator cuff (8).

1.2.3. Bicipital tendinitis

The term bicipital tendinitis defines an inflammatory condition of the tendon around the caput longus of the biceps. It can be divided into primary tendinosis describing inflammation within the bicipital groove and secondary bicipital tendinitis, which makes up a vast majority of cases (95%) and is associated with tear of either the rotator cuff or the superior labrum, more precisely a SLAP (superior labrum anterior to posterior) lesion (15). Bicipital tendinosis can be caused by degenerative processes either associated with normal aging, or with excessive overhead work of the arm in certain sports or professions. It is characterized by throbbing and deep pain in the anterior shoulder which is exacerbated by repetitive overhead movement (15).

1.2.4. Calcific tendinitis of the shoulder

The term calcific tendinitis describes an inflammatory tendinopathy associated with depositions of calcium oxalate in or near the tendon. It can occur anywhere in the body, however the shoulder is most commonly involved. The prevalence peaks in the age group of 40-60 years and females are more commonly affected (16).

Calcific tendinitis of the shoulder clinically presents with severe pain, which arises spontaneously and most often in the morning. Stiffness may occur as well as contracture of the rhomboids and the trapezius. In many cases, the condition resolves spontaneously. There still does not seem to be a consensus on the aetiology, but the two most popular theories suggest degenerative processes and a multiphasic pattern of disease involving spontaneous resorption of calcium deposits after deposition of calcium in the tissues (17,18).

1.2.5. Impingement syndrome of shoulder

Impingement syndrome is a painful and disabling condition of the shoulder due to narrowing of the subacromial space and consequent mechanical irritation of the rotator cuff. According to Greenberg, it is the most common reason for shoulder pain (19). Two main theories of aetiology are the extrinsic theory, stating that repetitive mechanical trauma of the tendons of the rotator cuff against the coracoacromial arch causes tissue damage and shoulder limitation, as well as the intrinsic theory, which explains pathological changes within the rotator cuff to be the reason for impingement (20,21).

1.2.6. Shoulder instability

The great motility and flexibility of the shoulder joint comes with the price of instability. The glenohumeral joint is the least stable ball and socket joint in the human body, making it susceptible to dislocations. As the bony articulations do not correlate in size, the labrum is needed to deepen the socket for the head of humerus thus adding some stability. The joint capsule, the rotator cuff muscles as well as the surrounding ligaments and tendons are the structures that provide the major stability. Instability syndromes occur when one or more of these structures are injured or malfunctioning. At the same time, dislocations can lead to their injury. Anterior glenohumeral dislocation may most commonly result in glenoid labral

tears, compression fracture of the humeral head known as Hill-Sachs deformity, capsular stripping and tear of the glenoid labrum with associated fracture.

Tears or ruptures of the rotator cuff tendons may cause joint dysfunction and shoulder instability. The most common tendon tear in the shoulder is tear of the supraspinatus. In case of subscapularis tear, dislocation of the biceps tendon due to concurrent tear of the transverse ligament often occurs (22).

1.2.7. Shoulder dislocations

More than 95% of all shoulder dislocations are anterior dislocations (23). They commonly are caused by violent external rotation in abduction and are often associated with trauma and high energy injuries. They are most prevalent in tall adult men. In anterior shoulder dislocation, the humeral head is levered out of the glenoid socket commonly resulting in avulsion of neighbouring structures. Hill-Sachs and Bankart lesions are commonly associated with anterior subluxation.

The patient will present with an abducted and externally rotated arm. While the normal shape of the deltoid will be lost, the acromion will be prominent posterolaterally. The head of humerus may be palpable and vascular injuries as well as bone fractures and nerve injuries may be associated with anterior dislocation. Whereas bone fractures have been reported to be extremely common (54%) in shoulder dislocations, vascular injuries seem to occur infrequently (in 1-2%) (24). Rotator cuff tears also are frequently associated with anterior subluxation (24).

1.3. Clinical examination of the shoulder complex

Considering the high number of possible conditions affecting the shoulder, physical examination is of paramount importance in finding the diagnosis and hence the right therapy. Good clinical examination and history taking will aid the practitioner in choosing the most appropriate diagnostic tool or may even render further diagnostic work-up obsolete (6). After taking detailed history, physical examination should begin with thorough inspection followed by palpation.

Afterwards, both active and passive range of motion should be tested. Provocative tests for certain conditions as well as functional tests will complete physical examination (10).

During clinical examination, the physician should keep in mind both systemic cause of pain as well as referred local pain especially of spinal (radiculopathy) or internal organ origin (cholecystitis, Pancoast tumour).

1.3.1. History

Thorough history taking will contribute in finding the right diagnosis. The examiner should pay attention to onset and duration of pain as well as to its quality and location. Additionally, exacerbating factors and potential mechanisms of injury should be evaluated for better understanding of the condition. A complete history will narrow down differential diagnoses and may lead to a presumptive diagnosis thus saving both time and money for costly diagnostic procedures.

1.3.2. Inspection

Depending on the pathology, gross difference may be visible e.g. muscle atrophy, unusual positioning of the arm, joint swelling or visible protrusion of a bony part, that is usually not seen. Anterior, lateral and posterior part of the shoulder joint should be analysed.

1.3.3. Palpation

Palpation may reveal point tenderness. Furthermore, crepitus may be felt in case of fracture or in snapping scapula syndrome (6).

1.3.4. Range of motion

Range of motion needs to be assessed both actively and passively. During examination, the patient may be seated, standing or in supine position. Evaluation of active range of motion should precede passive range of motion testing and painful movements should be saved till the end of examination, if possible. Throughout active movement, the patient needs to be observed for obvious signs of pain as well as for substituting of movements. If active range of motion is found to be abnormal, question should be raised, whether this is due to weakness or pain (6). For correct interpretation of joint flexibility, the examiner should compare range of motion of the affected shoulder with the other side. This way, the patient can serve as her or his own control.

Normal ranges of motion in the shoulder joint are as follows: external rotation: 80°, internal rotation: 100°, anteflexion: 90°, retroflexion: 40°, abduction: 90° and adduction: 40° from anatomical position. Ante- and retroflexion can be increased if the position of the joint socket is changed by elevation of the arm (1). A more practical approach is to evaluate complete range of motion, not only of the glenohumeral joint, but of the whole shoulder complex. Namdari et al. defined these as follows: anteflexion: 167°, extension: 62°, abduction: 184°, cross-body adduction: 140° and external rotation: 104°. In their study on functional range of motion they further defined the degrees of movement, that are needed to perform tasks of daily living as follows: forward flexion: 120°, extension: 45°, abduction: 130° cross-body adduction: 115°, internal rotation: 100° and external rotation: 60° (25).

When testing range of motion, the examiner should keep in mind interpersonal differences. Asynchrony of movement should be noted and if the examiner identifies a physical barrier during passive movement, differentiation between soft tissue or bony structure should be made.

1.3.5. Specialized tests

Numerous specialized tests have been introduced to identify impingement syndromes and instability of the shoulder as well as labral lesions, scapular winging, thoracic outlet syndrome and biceps tendon pathologies. Some of these tests are the following:

1.3.5.1. Tests for impingement

Neer and Hawkins-Kennedy impingement test as well as Yocum and cross-body adduction test all work in the way that certain movement elicits pain in the shoulder and hence indicates certain pathology. Neer impingement test, Hawkins-Kennedy impingement test and Yocum test all indicate supraspinatus tendinopathy, whereas reproduction of the patient's pain in cross-body adduction is consistent with pathology of the acromioclavicular joint. During impingement injection test, a local anaesthetic is injected into the subacromial space. The test is considered positive, if pain relief is at least 50%, usually resulting in ameliorated range of motion. This test is not specific, as not only supraspinatus, but also subacromial bursa, acromioclavicular joint and biceps tendon may be anaesthetized. It is useful, however, in those cases, when pain inhibits proper assessment of strength of the shoulder girdle structures. Weakness that persists after injection, suggests either a neurology deficit or rotator cuff tear of full thickness (6).

1.3.5.2. Tests for instability

Load and shift, anterior apprehension and anterior and posterior drawer all are tests for instability of the shoulder girdle. Load and shift test measures multidirectional instability. However, it rather indicates normal laxity than pathologic instability. In anterior apprehension test, the patient's anticipation of imminent shoulder subluxation during stressed external rotation and abduction. If the test produces pain or apprehension, a relocation test, with an attempt to reduce subluxation, should be performed afterwards. If pain or apprehension can be reduced with the relocation test, instability can be suspected, whereas pain that does not ameliorate with relocation indicates primary impingement. With the drawer tests, anterior and posterior laxity can be assessed (6).

1.3.5.3. Tests for labral lesions

Tests for labral lesions comprise O' Brien test and anterior sliding test for tears of the superior glenoid labrum, as well as Crank and Clunk test which also have been shown to have high positive predictive value for labral tears (6).

1.3.5.4. Tests for biceps tendon

To diagnose biceps tendinopathy, Speed's, Yergason's and Ludington's tests can all be used. Positive Speed's test may also indicate SLAP lesions (6). In Yergason's test, tear of the transverse humeral ligament can be suspected, if the biceps tendon moves out of the bicipital groove in resisted supination and external rotation of the arm after pronation and flexion of the elbow. Pain elicited when the patient puts both arms behind the head and contracts the biceps isometrically, is consistent with a positive Ludington's test (6).

1.3.5.5. Tests for scapular winging

Tests for scapular winging include serratus anterior and trapezius winging. Whereas weakness of serratus anterior leads to outward flaring of the inferior scapular angle at rest, in weakness of the trapezius, winging of the whole medial scapular border can be anticipated in abduction.

1.3.5.6. Tests for thoracic outlet syndrome

Adson manoeuvre, elevated arm stress test, supraclavicular pressure test and costoclavicular manoeuvre all can be used if thoracic outlet syndrome is suspected. However, none of them is reliable enough on its own, so several tests should be combined for evaluation (6).

1.3.5.7. Neurologic evaluation

Many neurological conditions can present in a way that mimics one or another shoulder pathology. Therefore, every physical examination of a patient with suspected pathology of the shoulder should include assessment of neurological status with testing for upper and lower motor neuron dysfunctions and evaluation of muscle strength, sensation and reflexes.

1.4. Diagnostic procedures for the shoulder joint

Despite thorough physical examination, further diagnostic work-up and procedures should be considered in many cases of shoulder pain in order to confirm the diagnosis. However, literature does not suggest that imaging is always superior to clinical examination (26). Nevertheless, plain radiography, ultrasound, magnetic resonance imaging (MRI) and magnetic resonance arthrogram (MRA) have all been shown to have high diagnostic accuracy in detection of various shoulder pathologies (12,27). In the following, these modes of imaging shall be evaluated and their flaws and benefits shall be discussed.

1.4.1. Plain radiography in shoulder pain work-up

According to Bradley, Tung and Green, the majority of shoulder disorders can be diagnosed with history, clinical examination and plain radiograph series (28). Burbank, Stevenson, Czarnecki et al. suggest radiographic work-up for all patients with chronic shoulder pain (29). Plain x-ray of the shoulder is of particular use in trauma settings as it is both fast and cost-efficient. In a standard shoulder series, axillary lateral, anteroposterior and supraspinatus outlet view should be included (12). With its high specificity for bony structures, clavicular or humeral fractures as well as separation of the acromioclavicular joint can be detected relatively easily (19). It is furthermore useful in evaluating glenohumeral arthritis or adhesive capsulitis in patients with decreased range of motion, in shoulder pain

patients with rheumatoid arthritis and in the work-up of acromioclavicular arthritis. Chronicity of pain, repetitive instability and recurrent conditions or those unresponsive to conservative treatment also warrant plain x-ray shoulder series (12). Even though the extent of radiation is acceptably low, it should, when possible, be avoided especially in children and pregnant women.

1.4.2. Ultrasonography of the shoulder

Ultrasonography is an inexpensive and fast way to image certain shoulder pathologies, that does not impose the patient to radiation. However, it is highly operator dependent. It can readily be used to diagnose shoulder dislocations and subluxations of the long head of biceps with 100% specificity and 96% sensitivity according to Armstrong et al. (30). For diagnosis of complete biceps tendon tears, ultrasonography is a reliable tool, however, it was shown to be of less value in partial thickness tears. In the hands of an experienced and well-trained operator, it can be used to detect rotator cuff tears and has been found to be as good as MRI in the detection of full and partial thickness tears (31). With ultrasonography, dynamic imaging and guided procedures can be performed, whereas with x-ray and MRI only static imaging is possible.

1.4.3. Magnetic resonance imaging and magnetic resonance angiogram

MRI is by far the most cost-intensive procedure of the ones mentioned. Still, in certain conditions it should be the diagnostic tool of choice. It can be useful in determining the extent of rotator cuff pathology, glenohumeral changes of the cartilage, acromioclavicular arthritis and labral injuries (12). Evaluation of the shoulder with MRI is more global and comprehensive compared to other imaging modalities, as it visualizes areas, that cannot be seen with ultrasonography or plain radiography. MRI has proven to be superior to ultrasonography in evaluating intraarticular structures, deep soft tissues and bone marrow (32). Combined with arthrogram, MRI scan with contrast enhancement is the modality of choice for assessing labral lesions in patients with shoulder instability. For bony Bankart lesions as well as Hill Sachs injuries, MRI also provides the best results (33).

1.5. Shoulder pathology in the working population

Considering the high occurrence with greatest prevalence in the age group of 45-55 years of age, the burden of shoulder pain becomes apparent (5). Gartsman et al. concluded that patients with different shoulder conditions scored significantly lower when compared with the general U.S. population on the SF-36 Health Survey on physical functioning, bodily pain, social functioning, physical role functioning and emotional role functioning (34).

Alongside the decreased well-being of the patient, economic aspects of shoulder pain need to be considered. Despite the fact that sick leaves for more than a few days were found to be uncommon in patients with non-traumatic shoulder pain, its economic burden due to decreased performance seems to be undeniable (35, 36, 37).

In the following, the main work-related risk factors found in literature will be discussed.

1.5.1. Occupational mechanical risk factors

Various occupational exposure have been suggested to cause or exacerbate shoulder disorders (38). Biomechanical risk factors, that result in higher incidence of shoulder pain have been identified in numerous studies, many of them focusing on work-place exposure in specific jobs and others on daily tasks and activities at work. Most of these studies found manual work to be linked to higher occurrence of shoulder pain (2,39). Especially handling heavy weights (carrying, pulling, pushing, lifting and holding) has been found to increase the risk of developing shoulder problems, but also repetitive work, vibration and overhead work as well as working in awkward positions seem to be strongly associated with the occurrence of shoulder pain (2,40,41). Van Rijn, Huisstede, Koes et al. further implicated the combined effect of different occupational exposures to increase the risk of shoulder pathology (39).

1.5.2. Psychosocial occupational risk factors

Alongside biomechanical factors, psychosocial aspects of the work environment have increasingly been made responsible for causing stress and leading to health problems such as musculoskeletal pain (2,4,40). In their prospective study of newly employed workers, Harkness, Macfarlane, Nahit et al. found monotonous work to be the strongest psychosocial predictor for new onset shoulder pain (40). Other psychosocial items that were investigated in the study were job satisfaction, stress, work pace, control over work, support from coworkers and the ability to acquire new knowledge and skills. Contribution of these factors to onset of

shoulder pain was only modest, though. However, another study by Nahit, Hunt, Lunt et al. concluded, that psychological distress could double the risk of self-reported musculoskeletal pain, including shoulder pain (42). According to Bodin, Ha, Petit Le Manac'h et al. low coworker support was associated with increased incidence of rotator cuff syndrome in males (43). Furthermore, in permanently employed females, an association was found between incidence of rotator cuff syndrome and working with temporarily employed workers. It is not yet understood, how psychosocial workplace factors can influence musculoskeletal health, however, in their study on shoulder pain and occupation, Linaker and Walker-Bone point out, that high psychological stress at work can lead to increased muscle tension and activity thus causing fatigue which, may result in awkward posture on the one hand and at the same time a change of personal pain perception and the tendency to report this pain (2).

2. Objectives of research

Shoulder pain is reported to be one of the most common musculoskeletal pains (5,0). It is described as often recurring, long lasting pain of high intensity (44). Shoulder pain can be disabling, causing numerous days of sick leave in the working population and thus great expenses of the health care system. Due to the great burden to both well-being of the patient and health-care economics, finding appropriate treatment for shoulder pain is of high interest, especially in the working population.

The treatment options of shoulder pain are as diverse as its aetiology. Common modalities of treatment are oral anti-inflammatory drugs and paracetamol medication and physical therapy. Furthermore, glucocorticosteroid medication – both orally or as injection, manipulation under anaesthesia and surgery are treatment options that are frequently used (45).

Whereas pharmacologic treatment comes with numerous side effects, physiotherapy is considered a treatment option that is well tolerated (46). Surgery of the shoulder joint should be considered as last treatment option in non-traumatic shoulder pain due to both high costs and major inconvenience of surgical procedures to the patient.

The primary objective of this thesis is to investigate the effect of physical therapy treatment on shoulder pain, mobility and functional index in the working population and evaluate its therapeutic effectivity.

Secondary objectives were to find out, whether the full range of diagnostic tools is used in the work-up of shoulder pain and whether any correlations can be made between smoking or alcohol intake and the pathologies described above.

3. Material and methods

3.1. Structure and protocol of research

The study has been conducted from March till June 2017 as a prospective study with patients at the Department for physical medicine and rehabilitation (University hospital KBC Split). The research was set as a clinical trial with an aim to evaluate the effect of physical therapy treatment on shoulder pain, mobility and functional index in the working population. In this primary research, 18 subjects were examined and their medical history was taken.

The majority of patients (15) were examined twice – before beginning and after completing 10 or more sessions of physical therapy. In three cases, data was retrospectively collected after completing the set of therapy.

Considering the short amount of time and the lack of suitable subjects, a convenience sample, without control group or randomization was used.

The research was registered with the Department of physical medicine rehabilitation and rheumatology and approved by the Ethics committee of the University of Split School of Medicine.

3.2. Subjects of research

The study included 18 patients with shoulder pain, 16 of which were female and two were male. All subjects were in the working population and currently on sick leave undergoing physical therapy at one of two locations of Krizine hospital, department of physical medicine and rehabilitation and Toplice. Diagnoses included were: subacromial impingement syndrome, tendinitis, sublaxations, calcifications, bursitis, partial rupture of tendons and frozen shoulder. Patients with post traumatic shoulder complaints after fractures were excluded from the study.

The patients' average age was 46 years with the youngest patient being 38 and the oldest 61 years of age. There were no drop outs.

3.3. Interventions, measures and other observations

Data was collected using goniometry, a translated version of the Oxford shoulder scale and an anamnestic history questionnaire (see Appendix 1 for Croatian version of Oxford shoulder scale and Appendix 2 for questionnaire).

Every subject underwent at least one cycle of physical therapy at either Krizine or Toplice location of KBC Split. Each cycle consisted of 10 sessions on 10 consecutive working days. Modalities of applied therapy were: transcutaneous electrical nerve stimulation (TENS), ultrasound, cryotherapy, heat therapy, individual and group kinesiotherapy. Combinations of different modalities of therapy were used in all but one patient.

Half the patients had more than one cycle due to either repetitive or continuous shoulder pain.

Diagnostics were performed for most patients before the therapy cycles. They usually consisted of plain radiographs or ultrasound and, in a few cases, MRI.

3.4. Statistics Analysis

Descriptive data analysis was conducted using Excel. Data were presented as absolute numbers and some were clustered in age groups. Improvement of range of motion was presented in delta percentages.

4. Results

Clustering of patients into age groups showed that in our sample, shoulder pain was most common in the years of 40-44 with every third patient belonging into this group. No patient was younger than 38 (Figure 1).

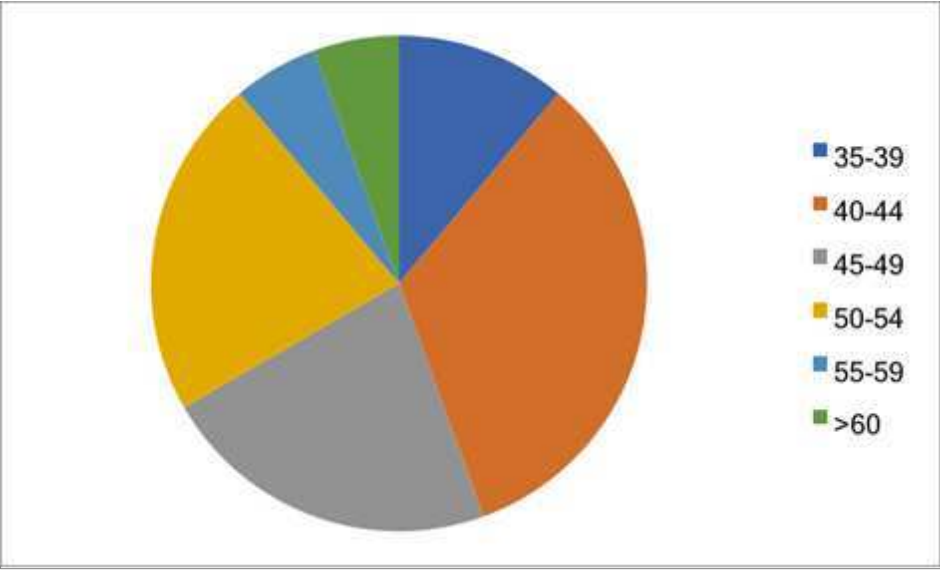


Figure 1. Age distribution

Most common diagnosis of shoulder pain in our study was calcific tendinitis with 39% followed by frozen shoulder and tendinitis (both 17%). Dislocation was only seen in one patient (Figure 2).

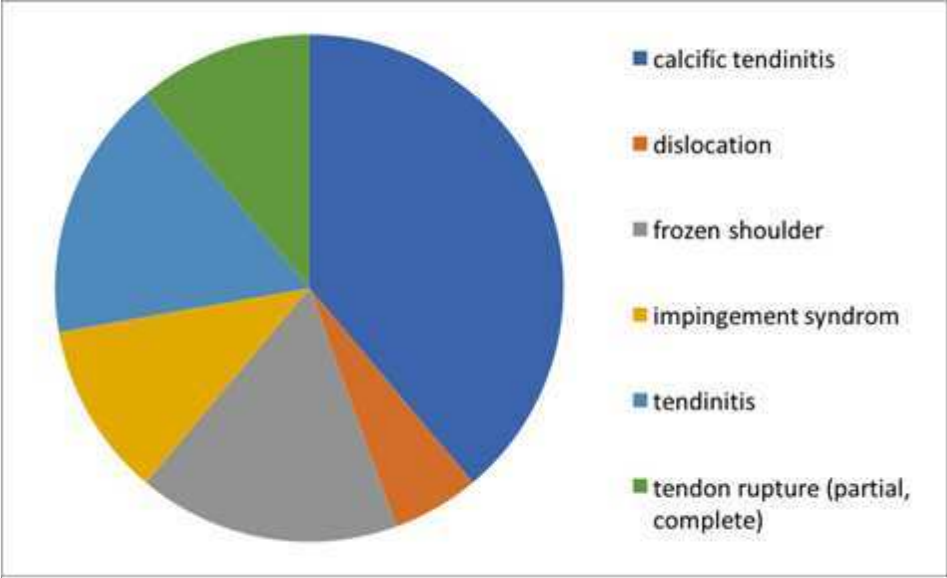


Figure 2. Diagnosis

Calcific tendinitis occurred most often between 40-44 years of age and made up half the patients in this group. Tendinitis also was most common in this age group, whereas the other conditions were relatively evenly distributed throughout the groups (Figure 3).

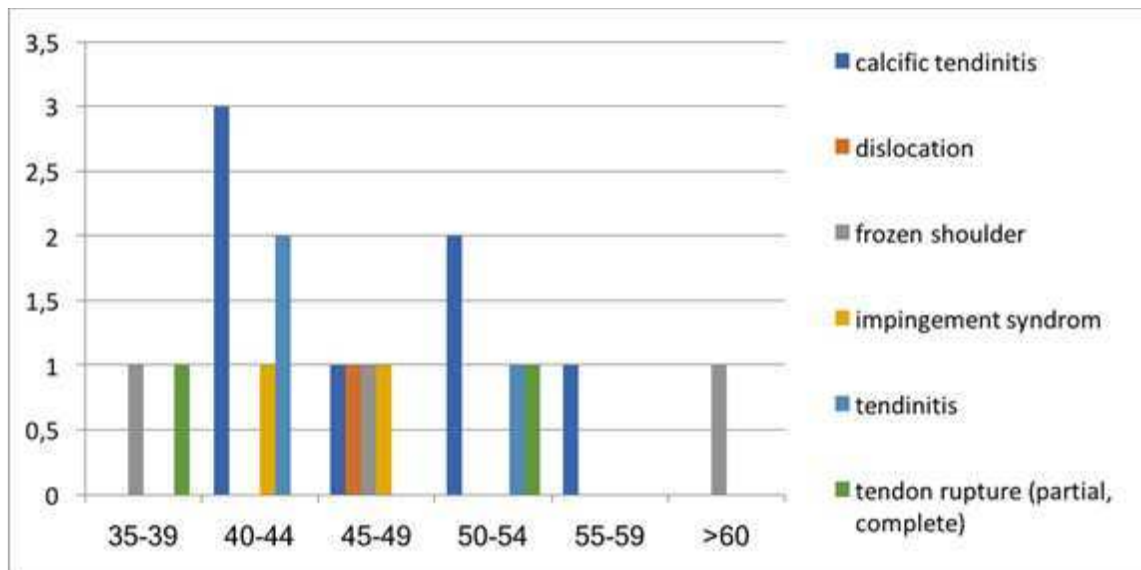


Figure 3. Diagnosis according to age

We formed three groups according to the patients' physical demands at their workplace: sedentary, moderately active and physically active and compared each group's average NRS pain score before beginning of therapy. The group that was moderately physically active at their workplace showed lower average pain than the other two groups (Figure 4).

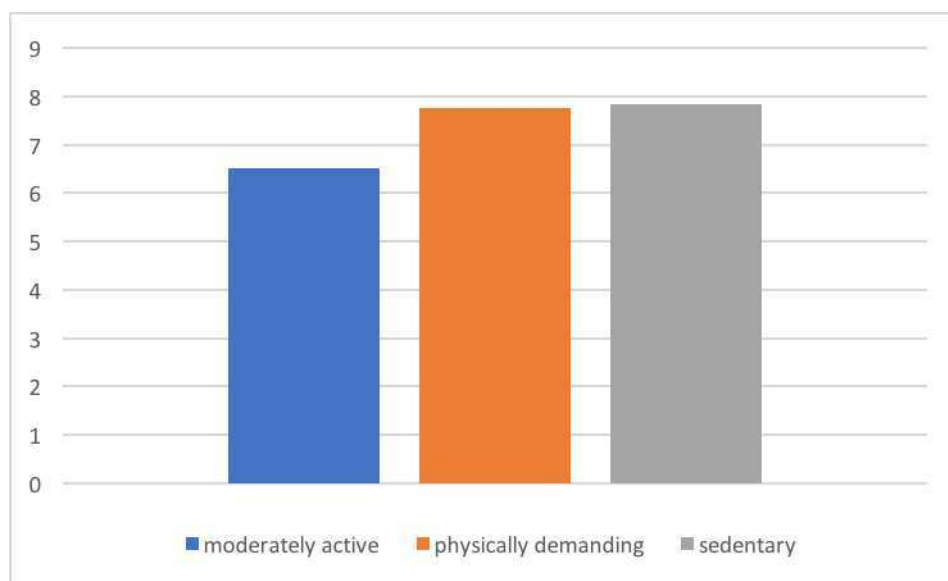


Figure 4. Average NRS pain levels according to physical demands at the workplace

No positive correlation could be found between smoking and shoulder pain.

Only five patients admitted to drinking alcohol, all of which in moderate amounts, so correlation could not be established between the consumption of alcohol and shoulder pathology either.

As for diagnostics, plane radiograph was used most often (14 times), directly followed by ultrasound (13 times), whereas MRI was only used in two patients, neither of which received an X-ray before (Figure 5). One patients did not receive any of these diagnostics prior to therapy.

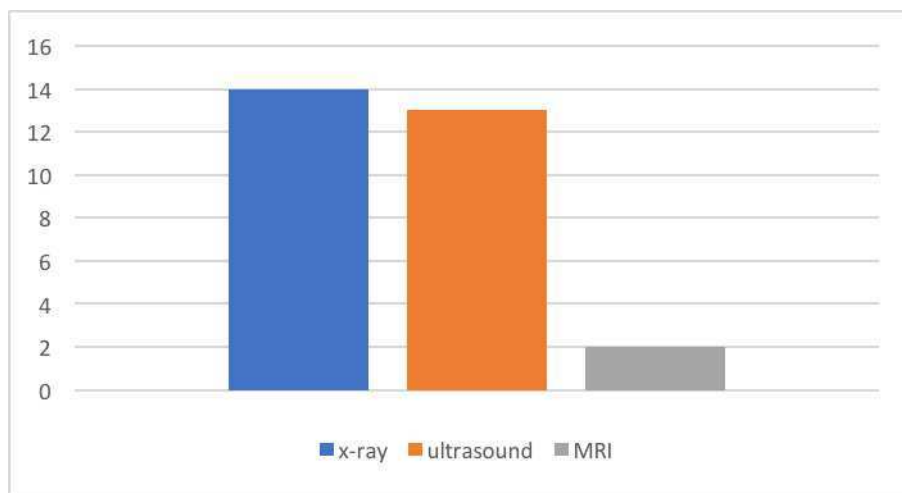


Figure 5. Diagnostic tools

Data analysis revealed that both pain on numeric rating scale (NRS) as well as range of motion improved with physical therapy. After a complete cycle of physical therapy, pain improved by approximately 3 NRS points in average. One patient stated there was no improvement of pain whereas two patients reported pain relief to be as high as 6 NRS points (Figure 6).

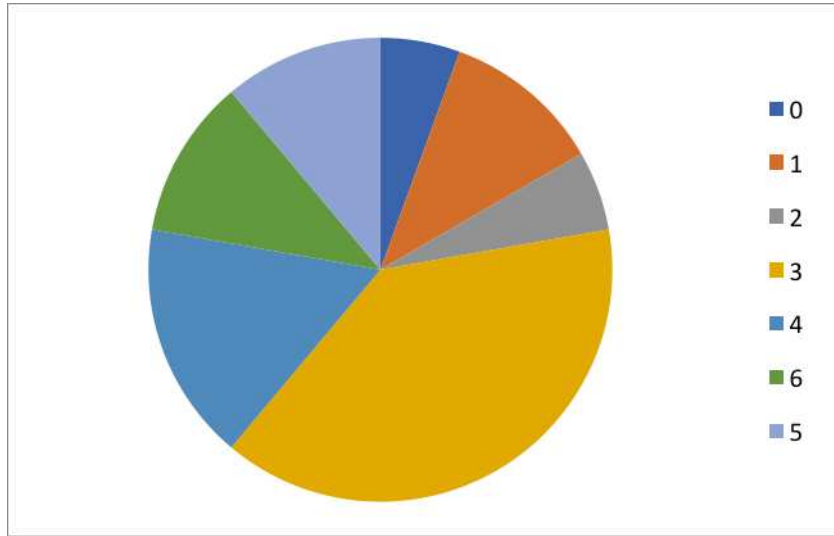


Figure 6. Pain relief on NRS after completed cycle of physical therapy

Analysis of the subjects' Oxford shoulder scales, revealed that most of our patients have a score of less than 20, thus indicating severe shoulder arthritis (Figure 7). This is not surprising, as the subjects were on sick leave during the length of their therapy.

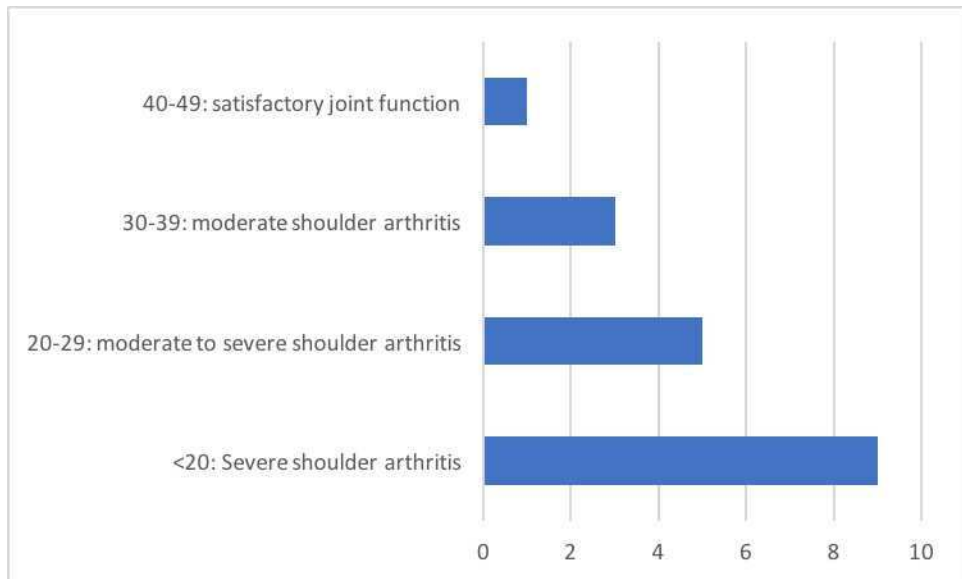


Figure 7. Oxford shoulder scale grouping

All subjects with decreased range of motion improved during therapy. Of the patients examined, most were limited in several movements. Two patients did not have restriction of movement. Average increase in range of motion was between 20 and 25% for all movements. It was greatest in external rotation (24,7%) and least in abduction (20,6%) (Figure 8).

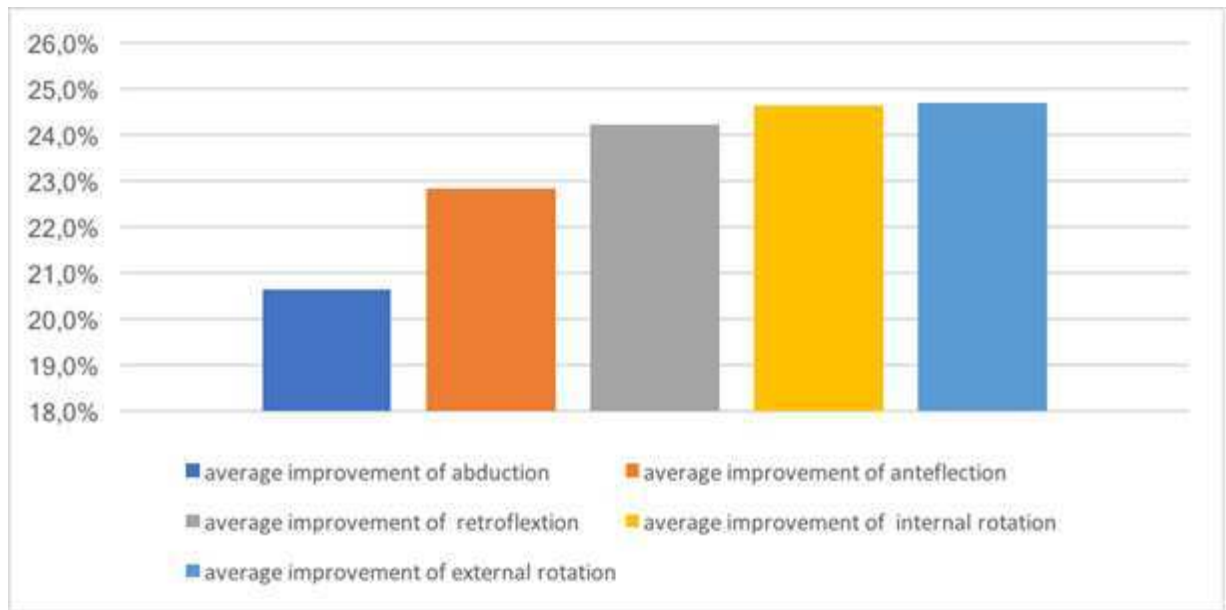


Figure 8. Improvement of range of motion

Most patients were using pharmacologic treatment alongside physical therapy. Per os ibuprofen was used by eight patients, followed by per os diclofenac, which four patients used on a regular basis. Whereas some patients reported to use these analgesics only occasionally, maximum doses in some of our patients were as high as 1200mg Ibuprofen per day and 225mg of diclofenac daily. Three patients stated to take other pills against their shoulder pain and four patients did not use any per os medication.

Other treatments, that the patients used regularly can be found in figure 9.

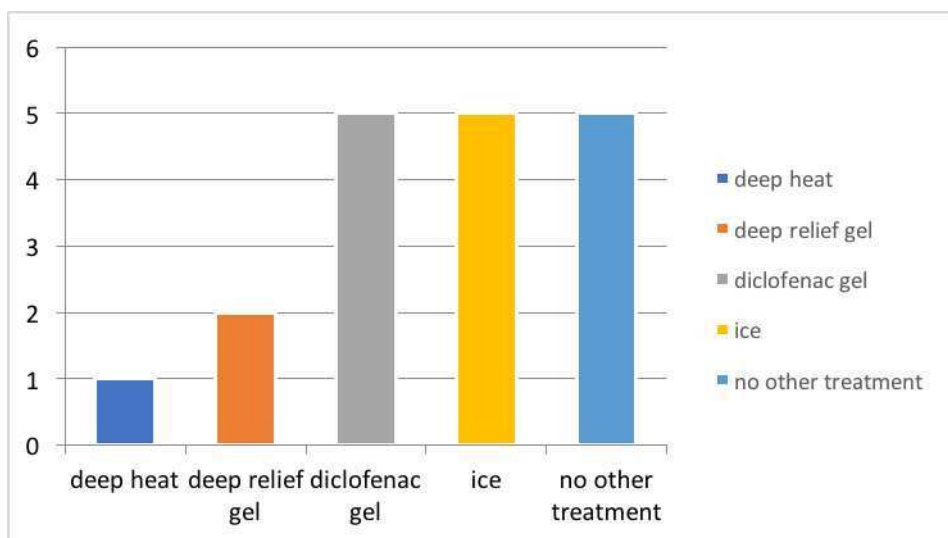


Figure 9. Adjunctive therapies

5. Discussion

As one of the most common musculoskeletal pains, shoulder pain with its potential of causing chronic disability needs to be considered a great burden to both patient's well-being and health care economics. Physical therapy has long been used in the treatment of various shoulder conditions.

The main findings of our study were, that physical therapy improves both pain and range of motion in the patients with shoulder pain. This has been shown in several studies already and, due to small sample size, no generalization can be made in our case. Nevertheless, our study can be seen as valuable evaluation of physical therapy in KBC hospital Split being performed in an intensive and condensed regimen of 10 consecutive working days.

Many studies focused on either specific conditions or modalities of therapy. Our study, on the other hand, cannot make such specific statement due to small sample number but shows, that in general, physical therapy performed at our ward has helped in reducing pain and increasing range of motion significantly, which can be seen as a success in the treatment of shoulder pathologies.

More specific data had for instance been obtained by Greenberg in 2014, who concluded that exercise therapy is universally recommended for rotator cuff syndrome, as well as for subacromial impingement syndrome, as it can significantly improve pain and function (19).

Haik, Albuquerque-Sendin, Moreira et al. systematically reviewed 64 RCTs on the effectiveness of physical therapy and came to the conclusion, that exercise therapy improves shoulder pain, function and range of motion and should thus be first-line treatment in clearly defined subacromial pain (47). They furthermore state, that addition of mobilisations to exercises may speed up pain reduction in the short term.

As for frozen shoulder, Jain and Sharma concluded in their systematic review, that exercises as well as mobilization are strongly recommended in patients with stages 2 and 3 as it has been shown to reduce pain and improve both function and range of motion (48). Deep heat as well as acupuncture with therapeutic exercises also helped in improving both pain and range of motion, whereas other modalities were only found to provide pain relief.

In their systematic review, Hawk, Minkalis, Khorsan et al. found evidence, that manual therapies especially in combination with protocols for physical therapy were beneficial for adhesive capsulitis and subacromial impingement syndrome (14). They furthermore concluded that physical therapy was beneficial in rotator cuff disorders, however not superior to surgery and that there was moderate evidence for extracorporeal shockwave therapy in calcific tendinitis. Moderate evidence was furthermore found for the treatment with low-level laser in rotator cuff disorder, calcific tendinitis, subacromial impingement syndrome and adhesive capsulitis.

According to Millar, Lasheway, Eaton et al. patients with shoulder pain improved in functional and clinical measures after completing physical therapy (49). They stated though, that conclusions on whether improvements were due to time or interventions were not possible. The same goes for our study. However, the fact that physical therapy in our case was performed within two weeks and patients who suffered for several months before, reported great improvement after the therapy, highly suggests the effectiveness of intervention in our case. A randomized controlled trial (RCT) would help to support this further.

Other studies found that females were more likely to suffer from shoulder pain (5). With only two male and 16 female patients, our study supports this statement. Older age has been shown to be associated with higher prevalence of shoulder pain (4). Our study could not support such association. This can be explained though, by the fact, that we only included patients in the working population, thus filtering the elderly population most affected by degenerative changes.

The work at hand failed to show a correlation between smoking or alcohol intake and pathologies of the shoulder, however, due to the small sample size, this is not surprising. This work should be seen as a test run for a larger study, as we encountered several problems, that we were not aware of at the start of our trial. First of all, acquisition of patients was more difficult and took much longer than expected. Many subjects in our clinic had to be excluded prior to the study as they were either not part of the working population or had pre-existing traumatic shoulder pathologies. From an originally planned number of 60 patients, only 18 could be generated.

Another flaw of the study design is the fact, that three patients were only examined retrospectively, thus leaving space for recall bias. Several physiotherapists were contributing to collect data on range of motion. Interpersonal differences in measuring range of motion can thus not be excluded.

This study's results in general cannot be considered to be representative. For statistical reliability, a far greater study sample would be needed. In their Cochrane Review, Green, Buchbinder and Hetrick concluded that little overall evidence of treatment guidance for shoulder pain can be given as other studies were facing the same flaws (45).

6. Conclusion

The study at hand could confirm the effectiveness of physical therapy in shoulder pain patients on both decrease of pain and increase in range of motion.

However, in order to decrease the burden on shoulder pain patients and health care system, further investigation is needed in the field of physical therapy to find the most appropriate modality for each condition.

Furthermore, a more thorough investigation of underlying, avoidable risk factors seems reasonable. As to our knowledge, there has not yet been found conclusion on the effects of smoking or alcohol intake. This also should be investigated further, as both are modifiable factors.

7. List of Literature

1. Bommas-Ebert, U., Teubner, P., Voß, R. (2005). *Kurzlehrbuch Anatomie und Embryologie: 46 Tabellen*. Marburg, Thieme. p.181-96
2. Linaker, C. H., Walker-Bone, K. Shoulder disorders and occupation. *Best practice & research. Clinical rheumatology*. 2015 29(3): 405-23.
3. Bodin, J., Ha, C., Chastang, J. F., et al. Comparison of risk factors for shoulder pain and rotator cuff syndrome in the working population. *American journal of industrial medicine*. 2012 55(7): 605-15.
4. Roquelaure, Y., Bodin, J., Ha, C., et al. Personal, biomechanical, and psychosocial risk factors for rotator cuff syndrome in a working population. *Scandinavian journal of work, environment & health*. 2011 37(6): 502-11.
5. Engebretsen, K. B., Grotle, M., Natvig, B. Patterns of shoulder pain during a 14-year follow-up: results from a longitudinal population study in Norway. *Shoulder & elbow*. 2015 7(1): 49-59.
6. Schultz, J. S. Clinical evaluation of the shoulder. *Physical medicine and rehabilitation clinics of North America*. 2004 15(2): 351-71.
7. Dinnes, J., Loveman, E., McIntyre, L., et al. The effectiveness of diagnostic tests for the assessment of shoulder pain due to soft tissue disorders: a systematic review. *Health Technol Assess*. 2003 7(29): iii, 1-166.
8. Gomoll, A. H., Katz, J. N., Warner, J. J., et al. Rotator cuff disorders: recognition and management among patients with shoulder pain. *Arthritis and rheumatism*. 2004 50(12): 3751-61.
9. Table taken from: World Health Organization, ICD Chapter XIII, Diseases of the musculoskeletal system and connective tissue M75)
10. Lee, S. H., Yoon, C., Chung, S. G., et al. Measurement of Shoulder Range of Motion in Patients with Adhesive Capsulitis Using a Kinect. *PloS one*. 2015 10(6): e0129398.
11. Dias, R., Cutts, S., Massoud, S. Frozen shoulder. *BMJ (Clinical research ed.)*. 2005 331(7530): 1453-6.
12. Holmes, R. E., Barfield, W. R., Woolf, S. K. Clinical evaluation of nonarthritic shoulder pain: Diagnosis and treatment. *The Physician and sportsmedicine*. 2015 43(3): 262-8.
13. Walker-Bone, K., Palmer, K. T., Reading, I., et al. Prevalence and impact of musculoskeletal disorders of the upper limb in the general population. *Arthritis and rheumatism*. 2004 51(4): 642-51.
14. Hawk, C., Minkalis, A. L., Khorsan, R., et al. Systematic Review of Nondrug, Nonsurgical Treatment of Shoulder Conditions. *Journal of manipulative and physiological therapeutics*. 2017.

15. Churgay, C. A. Diagnosis and treatment of biceps tendinitis and tendinosis. *American family physician*. 2009 80(5): 470-6.
16. De Carli, A.,Pulcinelli, F.,Rose, G. D., et al. Calcific tendinitis of the shoulder. *Joints*. 2014 2(3): 130-6.
17. Refior, H. J.,Krodel, A.,Melzer, C. Examinations of the pathology of the rotator cuff. *Archives of orthopaedic and traumatic surgery. Archiv fur orthopadische und Unfall-Chirurgie*. 1987 106(5): 301-8.
18. Uthoff, H. K.,Loehr, J. W. Calcific Tendinopathy of the Rotator Cuff: Pathogenesis, Diagnosis, and Management. *The Journal of the American Academy of Orthopaedic Surgeons*. 1997 5(4): 183-91.
19. Greenberg, D. L. Evaluation and treatment of shoulder pain. *The Medical clinics of North America*. 2014 98(3): 487-504.
20. Mayerhoefer, M. E.,Breitenseher, M. J.,Wurnig, C., et al. Shoulder impingement: relationship of clinical symptoms and imaging criteria. *Clinical journal of sport medicine : official journal of the Canadian Academy of Sport Medicine*. 2009 19(2): 83-9.
21. Tagg, C. E.,Campbell, A. S.,McNally, E. G. Shoulder impingement. *Seminars in musculoskeletal radiology*. 2013 17(1): 3-11.
22. Chen, M.,Pope, T.,Ott, D. (2010). *Basic Radiology, Second Edition*, Mcgraw-hill. p.197-8.
23. Cutts, S.,Prempeh, M.,Drew, S. Anterior shoulder dislocation. *Annals of the Royal College of Surgeons of England*. 2009 91(1): 2-7.
24. Hovelius, L.,Augustini, B. G.,Fredin, H., et al. Primary anterior dislocation of the shoulder in young patients. A ten-year prospective study. *The Journal of bone and joint surgery. American volume*. 1996 78(11): 1677-84.
25. Namdari, S.,Yagnik, G.,Ebaugh, D. D., et al. Defining functional shoulder range of motion for activities of daily living. *Journal of shoulder and elbow surgery*. 2012 21(9): 1177-83.
26. O'Kane, J. W.,Toresdahl, B. G. The evidenced-based shoulder evaluation. *Current sports medicine reports*. 2014 13(5): 307-13.
27. Lenza, M.,Buchbinder, R.,Takwoingi, Y., et al. Magnetic resonance imaging, magnetic resonance arthrography and ultrasonography for assessing rotator cuff tears in people with shoulder pain for whom surgery is being considered. *Cochrane Database Syst Rev*. 2013 (9): Cd009020.
28. Bradley, M. P.,Tung, G.,Green, A. Overutilization of shoulder magnetic resonance imaging as a diagnostic screening tool in patients with chronic shoulder pain. *Journal of shoulder and elbow surgery*. 2005 14(3): 233-7.

29. Burbank, K. M.,Stevenson, J. H.,Czarnecki, G. R., et al. Chronic shoulder pain: part I. Evaluation and diagnosis. *American family physician*. 2008 77(4): 453-60.
30. Armstrong, A.,Teefey, S. A.,Wu, T., et al. The efficacy of ultrasound in the diagnosis of long head of the biceps tendon pathology. *Journal of shoulder and elbow surgery*. 2006 15(1): 7-11
31. Greenberg, D. L. Evaluation and treatment of shoulder pain. *The Medical clinics of North America*. 2014 98(3): 487-504.
32. Levine, B. D.,Motamedi, K.,Seeger, L. L. Imaging of the shoulder: a comparison of MRI and ultrasound. *Current sports medicine reports*. 2012 11(5): 239-43.
33. Pavic, R.,Margetic, P.,Bensic, M., et al. Diagnostic value of US, MR and MR arthrography in shoulder instability. *Injury*. 2013 44 Suppl 3: S26-32.
34. Gartsman, G. M.,Brinker, M. R.,Khan, M., et al. Self-assessment of general health status in patients with five common shoulder conditions. *Journal of shoulder and elbow surgery*. 1998 7(3): 228-37.
35. Kuijpers, T.,van der Windt, D. A.,van der Heijden, G. J., et al. A prediction rule for shoulder pain related sick leave: a prospective cohort study. *BMC Musculoskelet Disord*. 2006 7: 97.
36. Kuijpers, T.,Vergouwe, Y.,van der Heijden, G. J., et al. Generalizability of a prediction rule for sick leave due to shoulder pain. *Scandinavian journal of work, environment & health*. 2007 33(6): 440-6.
37. Feleus, A.,Miedema, H. S.,Bierma-Zeinstra, S. M., et al. Sick leave in workers with arm, neck and/or shoulder complaints; defining occurrence and discriminative trajectories over a 2-year time period. *Occupational and environmental medicine*. 2017 74(2): 114-22.
38. Mayer, J.,Kraus, T.,Ochsmann, E. Longitudinal evidence for the association between work-related physical exposures and neck and/or shoulder complaints: a systematic review. *International archives of occupational and environmental health*. 2012 85(6): 587-603.
39. van Rijn, R. M.,Huisstede, B. M.,Koes, B. W., et al. Associations between work-related factors and specific disorders of the shoulder--a systematic review of the literature. *Scandinavian journal of work, environment & health*. 2010 36(3): 189-201.
40. Harkness, E. F.,Macfarlane, G. J.,Nahit, E. S., et al. Mechanical and psychosocial factors predict new onset shoulder pain: a prospective cohort study of newly employed workers. *Occupational and environmental medicine*. 2003 60(11): 850-7.
41. Leclerc, A.,Chastang, J.-F.,Niedhammer, I., et al. Incidence of shoulder pain in repetitive work. *Occupational and environmental medicine*. 2004 61(1): 39-44.

42. Nahit, E. S., Hunt, I. M., Lunt, M., et al. Effects of psychosocial and individual psychological factors on the onset of musculoskeletal pain: common and site-specific effects. *Annals of the Rheumatic Diseases*. 2003 62(8): 755-60.
43. Bodin, J., Ha, C., Petit Le Manac'h, A., et al. Risk factors for incidence of rotator cuff syndrome in a large working population. *Scandinavian journal of work, environment & health*. 2012 38(5): 436-46.
44. Luime JJ, Koes BW, Hendriksen IJ, et al. (2004). Prevalence and incidence of shoulder pain in the general population; a systematic review. *Scand J Rheumatol* 2004; 33: 73–81
45. Green, S., Buchbinder, R., Hetrick, S. Physiotherapy interventions for shoulder pain. *Cochrane Database Syst Rev*. 2003 (2): CD004258.
46. Sun, Y., Chen, J., Li, H., et al. Steroid Injection and Nonsteroidal Anti-inflammatory Agents for Shoulder Pain: A PRISMA Systematic Review and Meta-Analysis of Randomized Controlled Trials. *Medicine*. 2015 94(50): e2216.
47. Haik, M. N., Albuquerque-Sendin, F., Moreira, R. F., et al. Effectiveness of physical therapy treatment of clearly defined subacromial pain: a systematic review of randomised controlled trials. *British journal of sports medicine*. 2016 50(18): 1124-34.
48. Jain, T. K., Sharma, N. K. The effectiveness of physiotherapeutic interventions in treatment of frozen shoulder/adhesive capsulitis: a systematic review. *Journal of back and musculoskeletal rehabilitation*. 2014 27(3): 247-73.
49. Millar, A. L., Lasheway, P. A., Eaton, W., et al. A retrospective, descriptive study of shoulder outcomes in outpatient physical therapy. *The Journal of orthopaedic and sports physical therapy*. 2006 36(6): 403-14.

8. Summary in English

The effect of physical therapy treatment on shoulder pain, mobility and functional index in the working population

Objectives: Shoulder pain is reported to be one of the most common types of musculoskeletal pain and known for causing numerous days of sick leave in the working population. Thus the aim of this study was to evaluate the effect of physical therapy on pain, mobility and functional index in order to find an appropriate treatment regimen to lessen the significant burden for the well-being of the patient and the health-care economics.

Methods: A clinical trial was performed between March and June 2017 with 18 patients of the Department for physical medicine and rehabilitation of the University hospital KBC Split. The patients were from the working population and currently on sick-leave, who with the exception of two patients, were all females. Subjects were between the ages of 38 and 61. We included patients with subacromial impingement syndrome, tendinitis, subluxations, calcifications, bursitis, partial rupture of tendons and frozen shoulder and excluded patients with post traumatic shoulder complaints after fractures. Every subject underwent at least one cycle of physical therapy. Each cycle consisted of 10 sessions on 10 consecutive working days. Modalities of applied therapy were: TENS, ultrasound, cryotherapy, heat therapy, individual and group kinesiotherapy. Combinations of different modalities of therapy were used in all but one patients. Data was collected using goniometry, a translated version of the Oxford shoulder scale and an anamnestic history questionnaire. Descriptive data analysis was conducted using Excel. The research was registered with the department and accepted by the ethics committee.

Results: All 18 patients completed the trial. Our results revealed that shoulder pain was most common in the years of 40-44. The most common cause of shoulder pain in our study group was calcified tendinitis. Data analysis revealed that both pain on numeric rating scale (NRS) and range of motion improved with physical therapy.

Conclusion: The primary objective of our study was proven: physical therapy lessens the pain and increases the mobility in almost all patients, while secondary objectives are not statistically relevant because of the small number of patients. Further studies should be conducted.

9. Summary in Croatian

Učinak fizikalne terapije na bol, pokretljivost i funkcionalne indekse kod boli ramena u radno aktivne populacije

Cilj istraživanja: Bol u ramenom zglobu vrlo je čest odgovorana za izostanak s posla u radno aktivne populacije. Cilj ovog rada bio je pratiti pacijente prije i poslije fizikalne terapije i utvrditi njen učinak na osjet boli, pokretljivost ramenog zgloba te funkcionalne indekse. Time bi se mogao osmisliti najbolji algoritam korištenja modaliteta fizikalne terapije i omogućiti boljitak zdravlja pacijenta kao i bolje korištenje zdravstvenog sustava.

Metode istraživanja: Istraživanje za ispitivanje teze diplomskog rada je provedeno na Zavodu za fizikalnu medicinu i rehabilitaciju s reumatologijom KBC Split u razdoblju od ožujka do lipnja 2017. Ispitivanje je odobreno od Etičkog odbora Medicinskog fakulteta u Splitu, a provedeno je uz suglasnost pacijenata. Ukupno je uključeno 20 pacijenata koji su ispunili upitnik te Oxfordsku ljestvicu za ramenu bol a goniometrijski su im mjerene vrijednosti pokretljivosti ramenog zgloba prije i poslije terapije. Deskriptivna statistička analiza provedena je u Excelu.

Rezultati istraživanja: Ukupno 20 ispitanika uključeno je u istraživanje. Ispitaici od 40-44 godine najčešće su su trpjeli bol u ramenom zglobu. Najčešća dijagnoza koja je uzrokovala stanje koje je zahtijevalo fizikalnu terapiju bio je kalcificirajući tendinitis tetiva rotatorne manžete. Podaci dobiveni da se u 18 pacijenta smanjio osjet boli na vizualno analognoj skali, dok je pokretljivost poboljšana u svih pacijenata koji su proveli fizikalnu terapiju.

Zaključak: Ovo istraživanje potvrdilo je primarni cilj istraživanja a to je učinkovitost fizikalne terapije na bol i pokretljivost u ramenom zglobu. Za ostale parametre kao što su pušenje ili alkohol te vrstu posla koje pacijent obavlja nije se pokazalo statistički značajne povezivosti s bolom u ramenu jer je uzorak bio premalen. Daljnja istraživanja na ovom području bila bi korisna da se razrade sekundarni ciljevi ovog istraživanja.

10. Curriculum Vitae

Curriculum Vitae

Johanna Dirkwinkel

Cimbernstraße 24

14129 Berlin

Tel: +49 163 603 9619

E-Mail: jojodirkwinkel@hotmail.com

Personal data

Name:	Johanna Sophie Dirkwinkel
Date of Birth:	07/07/1988
Place of Birth:	Berlin
Citizenship:	German

Education

Since 10/2011	University of Split , School of Medicine, Croatia
10/2007-02/2011	Bachelor of Science: Business Psychology at Leuphana Universität Lüneburg , Germany
2010	Stellenbosch University , South Africa as an international student
2000-2007	Droste-Hülshoff-Oberschule , Berlin, Germany
2005	Royal Alexandra and Albert School , Surrey, England as an exchange student
2004	Lycée Paul-Langevin , Suresnes, France as an exchange student
1994-2000	Dreilinden-Grundschule Zehlendorf , Berlin, Germany

Extracurricular Activities

Work experiences:	<p>Nursing internship at Waldfriede Hospital, Berlin</p> <p>Practical work in the laboratory of TIB molbiol</p> <p>Project management for Contact&Cooperation</p> <p>Internships as a medical assistant at:</p> <ul style="list-style-type: none"> - Schlossparkklinik Berlin, ward for psychiatry - AVK Klinikum Berlin, ward for emergency surgery, traumatology and orthopedic surgery - Westklinik Berlin for orthopaedic surgery - Schwerpunktpraxis für Diabetologie und Rheuma, Wilmersdorf, Berlin, medical practice - DRK Westendklinikum Berlin: ward for diabetology ward for gynecology
Voluntary work:	<p>United Nations Association of South Africa (UNASA):</p> <ul style="list-style-type: none"> - HIV-testing campaigns - Legacy Centre
Interests:	<p>English, German and French Literature, skiing, choir singing, photography, diving, hiking, free climbing, hiking and running</p>

Skills:

Languages:	<p>German: mother tongue</p> <p>English: fluent</p> <p>French: fluent</p> <p>Croatian: advanced</p> <p>Spanish: basics</p> <p>Afrikaans: basics</p> <p>Latin: Philosophicum</p>
Computer:	<p>Microsoft Office, Quincy, Agfa HealthCare: Orbis</p>

Split, 29.06.2017

11. Appendix

Appendix 1: Oxford Shoulder scale, translated

Molim vas odgovorite na ovih 12 pitanja.

U posljednja četiri (4) tjedna....

- 1) Kako biste opisali svoju najgoru bol u području ramena?
Nisam imao/la neke bolove
Samo blaga
Osrednja
Jaka
Nepodnošljiva
- 2) Jeste li imali probleme pri oblačenju zbog vašeg ramena?
Nisam imao/la probleme
Samo male probleme
Osrednji problemi
Velike poteškoće
Nisam mogao/la se obući
- 3) Jeste li imali neke probleme pri ulasku i izlasku iz auta ili pri korištenju javnog prijevoza zbog vašeg ramena?
Nisam imao/la probleme
Samo male probleme
Osrednji problemi
Velike poteškoće
Nisam mogao/la koristiti prijevoz
- 4) Jeste li bili u mogućnosti koristiti nož i vilicu istovremeno?
Da, lako
S malim teškoćama
S umjerenim teškoćama
Sa velikim poteškoćama
Nemoguće
- 5) Jeste li mogli obavljati kupovinu kućnih potrepština samostalno?
Da, lako
S malim poteškoćama
S umjerenim poteškoćama
Sa velikim poteškoćama
Nemoguće
- 6) Jeste li bili u mogućnosti nositi tanjur hrane hodajući?
Da, lako
Sa malim poteškoćama
Sa umjerenim poteškoćama
Velike poteškoćama
Nemoguće

7) Jeste li se mogli očešljati bolnom rukom?

- Da, lako
- S malim poteškoćama
- S umjerenim poteškoćama
- Sa velikim poteškoćama
- Nemoguće

8) Kako biste opisali svoju uobičajenu bol u ramenu?

- Nikakva
- Vrlo blaga
- Blaga
- Osrednja
- Jaka

9) Jeste li bili u stanju objesiti odjeću u ormaru koristeći bolnu ruku?

- Da, lako
- S malim poteškoćama
- S umjerenim poteškoćama
- Sa velikim poteškoćama
- Nemoguće

10) Jeste li u mogućnosti oprati se i osušiti s obje strane?

- Da, lako
- Sa malim poteškoćama
- Sa umjerenim poteškoćama
- S velikim poteškoćama
- Nemoguće

11) Kako je vaša bol u ramenu utjecala na vas svakodnevni rad uključujući i rad po kući?

- Nimalo
- Samo malo
- Osrednje
- Značajno
- U potpunosti

12) Jeste li imali bolove u ramenu tokom noći kod ležanja u krevetu?

- Nikad noću
- Samo 1 ili 2 puta
- Nekoliko noći
- Većinu noći
- Svaku noć

Appendix 2: Questionnaire

UPITNIK (QUESTIONNAIRE)

Pacijent broj (number):
Godina rođenja (YEAR OF BIRTH):
Spol (SEX):
Zanimanje (OCCUPATION):

Povijest bolesti (Anamnesis):
Sportske aktivnosti (Sport activities):
Bolesti ramena u obitelji (Shoulder pain in family):
Uputna dijagnoza (Diagnosis):
Pretrage RTG, UZV, MRI (Performed diagnostic procedures):
Koliko traje bol (Pain since):
Prva ili rekurentna ataka boli (First or repetitive shoulder pain):
Uporaba analgetika koji, koja doza, koliko često (Use of analgesics):
Nefarmakološki tretman –led, masti: (Other treatment (icing, gels etc):
Pušenje Da ili NE (smoking):
Konzumacija alkohola koliko i koji tip: (Alcohol Intake):
Koji je ciklus terapije (How many cycles of therapy did you use):
Koji su modaliteti terapije: (Physical modalities of therapy- individual exercises, individualized exercises- group, ultrasound therapy- cryotherapy, paraffin, IFS, TENS, magnetotherapy or other):
Nepodnošenje terapije: (Therapy side-effects):

Klinički funkcionalni nalaz i indeksi (Clinical movement measurement and indeks):

Pokretljivost ramena 10 dana terapija (shoulder movement 10 days of therapy):

Abdukcija ramena (Shoulder abduction):	Prije (before):	Poslije (After):
Addukcija ramena (Shoulder adduction):	Prije (before):	Poslije (After):
Antefleksija ramena (Shoulder anteflexion):	Prije (before):	Poslije (After):
Retrofleksija ramena (Retroflexion):	Prije (before):	Poslije (after):
Unutrašnja rotacija (Internal rotation):	Prije (before):	Poslije (after):
Vanjska rotacija (External rotation):	Prije (before):	Poslije (after):

Bol prije terapije (VAS of pain before):

Poslije (after):

Oxford shoulder score: