

# Expression of hypoxia-inducible factor-1 alpha (HIF-1 $\alpha$ ) in high grade and low grade endometrial carcinomas

---

**Schmid, Leon Romeo**

**Master's thesis / Diplomski rad**

**2017**

*Degree Grantor / Ustanova koja je dodijelila akademski / stručni stupanj:* **University of Split, School of Medicine / Sveučilište u Splitu, Medicinski fakultet**

*Permanent link / Trajna poveznica:* <https://um.nsk.hr/um:nbn:hr:171:747080>

*Rights / Prava:* [In copyright](#)/[Zaštićeno autorskim pravom.](#)

*Download date / Datum preuzimanja:* **2024-11-04**



*Repository / Repozitorij:*

[MEFST Repository](#)



**UNIVERSITY OF SPLIT  
SCHOOL OF MEDICINE**

**Leon Schmid**

**EXPRESSION OF HYPOXIA-INDUCIBLE FACTOR-1 ALPHA  
(HIF-1 $\alpha$ ) IN HIGH GRADE AND LOW GRADE ENDOMETRIAL  
CARCINOMAS**

**Diploma thesis**

**Academic year:**

**2016/2017**

**Mentor:**

**Sandra Zekic Tomas, MD,PhD**

**Split, July 2017**

**UNIVERSITY OF SPLIT  
SCHOOL OF MEDICINE**

**Leon Schmid**

**EXPRESSION OF HYPOXIA-INDUCIBLE FACTOR-1 ALPHA  
(HIF-1 $\alpha$ ) IN HIGH GRADE AND LOW GRADE ENDOMETRIAL  
CARCINOMAS**

**Diploma thesis**

**Academic year:**

**2016/2017**

**Mentor:**

**Sandra Zekic Tomas, MD,PhD**

**Split, July 2017**

## **Acknowledgments**

I would like to express my gratitude towards the Mentor of my thesis, Sandra Zekic-Tomas MD, PhD for her continuing support of our work and all the time she has invested into it.

Also I would like to thank the many other Professors, teaching and non-teaching staff of University of Split, School of Medicine that enabled me to follow my dream to pursue a carrier as a Doctor of Medicine

Last, but not least my sincerest thanks to my family, my father Manfred Schmid and my mother Lana Schmid without their tireless support and devotion I could have never reached the point where I am now.

## Table of content

1. INTRODUCTION.....	1
1.1. Epidemiology of endometrial carcinoma.....	2
1.2. Etiology of endometrial carcinoma.....	2
1.3. Risk factors for endometrial carcinomas.....	3
1.4. Pathology of endometrial carcinoma.....	3
1.4.1. Gross morphology of endometrial carcinoma.....	3
1.4.2. Histology of endometrial carcinomas.....	4
1.4.2.1. Endometrioid carcinoma.....	4
1.4.2.2. Mucinous carcinoma.....	6
1.4.2.3. Serous carcinomas.....	6
1.4.2.4. Clear cell carcinoma.....	7
1.4.2.5. Undifferentiated carcinoma.....	7
1.5. Hypoxia-inducible factor 1 alpha.....	7
1.5.1. HIF-1 $\alpha$ in endometrial carcinomas.....	9
2. OBJECTIVES.....	10
3. MATERIAL AND METHODS.....	12
3.1.1. Material .....	13
3.1.2. Immunohistochemical analysis .....	13
3.1.3. Statistical analysis.....	15
4. RESULTS.....	16
5. DISCUSSION.....	19
6. CONCLUSION.....	22
7. REFERENCES.....	24
8. SUMMARY.....	27
9. CROATIAN SUMMARY.....	29
10. CURRICULUM VITAE.....	31

## **1. INTRODUCTION**

## 1.1. Epidemiology of endometrial carcinoma

Endometrial carcinoma is the second most common malignancy of the female reproductive system after cancer of the uterine cervix (1). There were 320.000 newly diagnosed cases worldwide in 2012, with an estimated 60.050 new cases to be diagnosed in 2017 in the USA and 10.470 estimated fatalities. It is the sixth most common cancer in women overall. Women of white race are at highest risk, while incidence is lowest in Asian women (2).

The lifetime risk for women developing endometrial carcinoma is approximately 2-3% and unlike many other cancers the number of new cases is still increasing (3, 4). The majority (75%), of endometrial carcinomas develop in post-menopausal women with an average age of 60 years at the time of diagnosis (5).

## 1.2. Etiology of endometrial carcinoma

Bokhman classified endometrial carcinomas in type I and type II tumors based on clinical, metabolic and endocrine characteristics of the carcinoma (6). Although that classification was made almost 35 years ago it is still valid in greater extent. The frequency of type I vs. type II carcinomas is 70% to 30% respectively.

Type I endometrial carcinoma occur most often in obese/hyperlipidemic women and is associated with hyperestrogenism. They tend to be diagnosed in lower stages of the disease and have a less aggressive clinical course, with rare metastasis at the time of diagnosis and usually less than 50% depth of invasion in the uterine wall compared to type II tumors. Therefore, they carry a more favorable prognosis and higher survival rates (7). Histologically, type I endometrial carcinomas are endometrioid adenocarcinomas and less often mucinous carcinomas. It was noted, that endometrioid carcinomas often exhibit a loss of *PTEN* gene. This is a negative regulator of PI3K/AKT/mTOR pathways, whose uncontrolled stimulation leads to neocarcinogenesis. The same was observed in endometrial hyperplasia. It is postulated that this loss of function may play a pivotal role in the pathogenesis of endometrioid carcinomas and therefore type I endometrial carcinomas (8, 9). Furthermore, it is believed that precursor lesion for development of type I endometrial carcinoma is endometrial intraepithelial neoplasia (EIN) (10).

Type II endometrial carcinomas are less common than type I carcinomas and are usually less differentiated. They have a more severe clinical course, with deeper invasion of the uterine wall, more frequent metastasis and diagnosis often made in more advanced stages than type I tumors (1,11). Those tumors tend to be associated with atrophic endometrium, arise in non-obese women and are independent of metabolic or endocrine disturbances. Furthermore, they have different

molecular characteristics, such as *HER2* amplification and *TP53* mutations. *TP53* is a tumor suppressor gene, the product of which conserves stability in the human genome. Mutations of *TP53* are present in up to 90% of serous carcinomas. *HER2* is an oncogene and a member of the human epidermal growth factor receptor family (12). Type II endometrial carcinomas comprises the following histological subtypes: serous carcinoma, clear-cell carcinoma, undifferentiated carcinoma. Mixed carcinomas are also included in the type II carcinoma group if they include one of the components from those listed above.

### **1.3. Risk factors for endometrial carcinomas**

Several risk factors are implied in the development of endometrial carcinoma, most notably those are: nulliparity, exposure to high levels of circulating estrogens, high age, breast cancer and its associated intake of Tamoxifen, obesity, early menarche and late menopause. The minority of 10% of endometrial carcinomas are hereditary (13).

One of the genetic conditions associated with endometrial cancer is Lynch syndrome. This is an autosomal dominant genetic disorder, also known as hereditary non-polyposis colorectal cancer (HNPCC), which is caused by germline transmission of defective mismatch repair genes *MSH1/6*, *MLH1* and *PMS2*. It is most known for its tendency to cause colorectal carcinoma, but it also causes endometrial carcinoma in 40-60% of cases. Endometrial carcinoma caused by Lynch syndrome accounts especially for those cases that present before menopause, which is the less frequent subtypes of patients (3,14).

Another genetic syndrome that can cause endometrial carcinoma is Cowden syndrome. It is also an autosomal dominant disorder, caused by a germline mutation of *PTEN*. The lifetime risk of patients with Cowden syndrome to develop endometrial carcinoma is 28% and its median age of diagnosis is in the forties (14). Smoking, use of birth control pills and intrauterine devices are protective factors. Smoking can induce weight loss and early menopause, likewise it alters the body's metabolism of estrogen, thus is thought to reduce incidence of endometrial carcinoma (15).

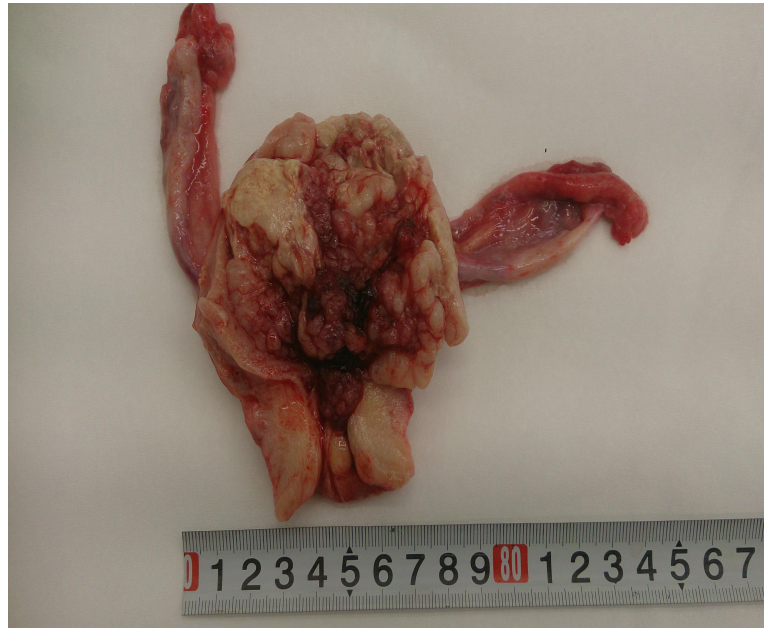### **1.4. Pathology of endometrial carcinoma**

#### **1.4.1. Gross morphology of endometrial carcinoma**

Type I endometrial carcinomas arise as localized polypoid masses or as a diffusely infiltrative tumor involving endometrial surface (Figure 1). The tumor usually spreads by direct myometrial invasion and can encompass adnexal structures, broad ligament or eventually can



involve urinary bladder or colon. Regional lymph node involvement occurs in late stages of the disease (16).



**Figure 1.** Gross appearance of endometrial carcinoma type I, presented as a large polypoid tumor with myometrial invasion in great extent. (Image taken from the archive of Pathology Department, Clinical Hospital Centre Split).

Type II endometrial carcinomas arise in small atrophic uterus and often present as large bulky tumors or they show deep myometrial invasion. Likewise, in the time of diagnosis they are usually at more advance stage than type I endometrial carcinomas, with vascular invasion and lymph node involvement (16).

## **1.4.2. Histology of endometrial carcinomas**

### **1.4.2.1. Endometrioid carcinoma**

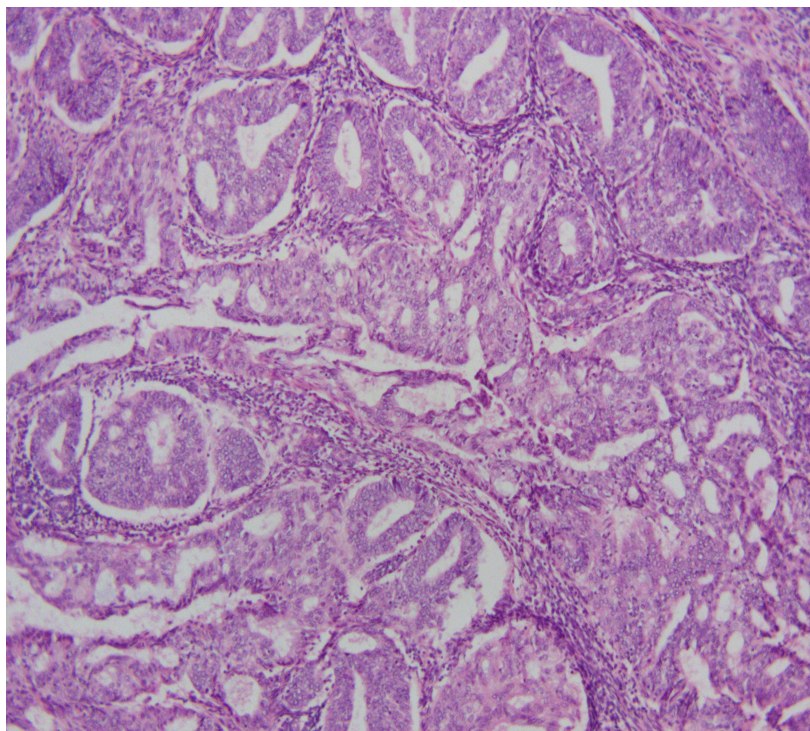
Endometrioid carcinoma is also known as estrogen-dependent endometrial carcinoma. Histologically endometrioid carcinoma has a glandular or villoglandular architecture. It is lined by columnar epithelium, which forms smoothly contoured glandular lumina (Figure 2). Neoplastic cell's cytoplasm is eosinophilic and granular with mild to moderate nuclear atypia, except in poorly differentiated forms (14).

Contrary to well-differentiated endometrial carcinomas, the poorly differentiated forms show stromal invasion, altered endometrial stroma or papillary architecture. Endometrioid carcinomas are often accompanied by atypical endometrial hyperplasia.

Endometrioid carcinomas are histologically graded from grade 1 to grade 3, based on their proportion of solid growth. Grade 1 has less than 5%, grade 2 between 6 and 50% and grade 3 more than 50% of solid growth. Endometrioid carcinomas grade 1 and 2 are considered low grade carcinomas, while endometrioid carcinomas grade 3 are considered high grade carcinomas (14).

The most common forms of differentiation in endometrioid carcinomas show squamous and secretory differentiation patterns. Squamous type of differentiation is the most common, with 10-25%, while the latter comprises only about 2%. Even less common patterns of differentiation are villoglandular, sertoli-form and microglandular types (14).

FIGO stage and grade of the tumor, age, histological grade, myometrial and lymphatic invasion are predictive for the course of the disease and apply to all variants of endometrial carcinoma. Notably outer-half myometrial invasion is associated with significant decrease in survival (14).



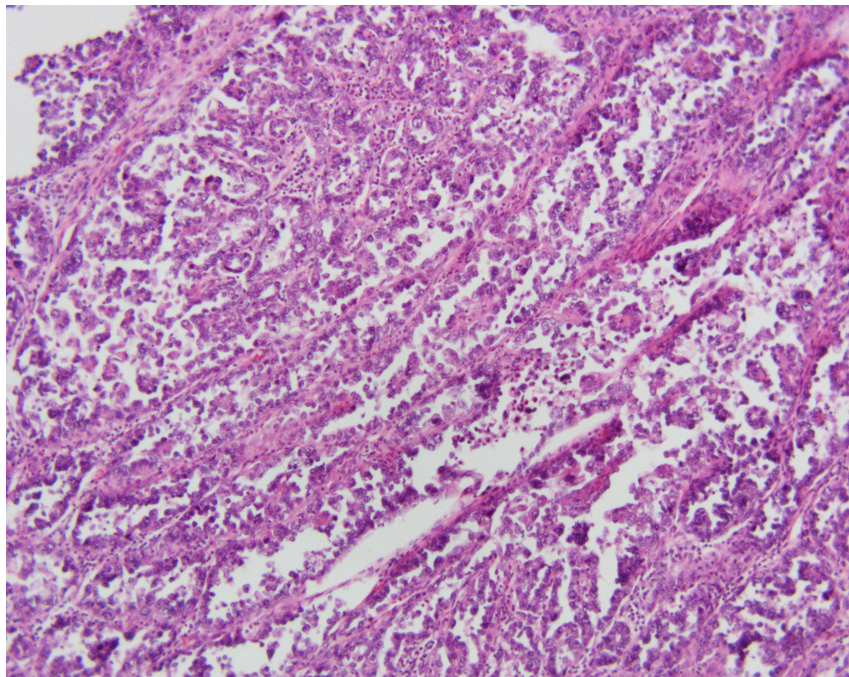
**Figure 2.** Microscopic image of well differentiated endometrioid endometrial carcinoma (H&E, magnification 100x; Olympus BX41) (*image taken by candidate at the Pathology Department*).

#### 1.4.2.2. Mucinous carcinoma

When an endometrial carcinoma comprises more than 50% of mucinous cells, it is considered a mucinous carcinoma. Clinically, mucinous carcinomas behave similarly to the more common endometrioid carcinoma, however they are almost always well differentiated and have a relatively good prognosis. Histologically mucinous carcinomas are (villo)glandular, lined by uniform mucinous cells with little stratification. They often show squamous differentiation, mild to moderate nuclear atypia and low mitotic activity. Typically myometrial invasion is limited to the inner-half of myometrium (14). Mucinous carcinomas are considered low grade endometrial carcinomas (14).

#### 1.4.2.3. Serous carcinomas

Serous carcinoma exhibits a papillary and/or a glandular architecture with diffuse, marked nuclear pleomorphism (Figure 3). Serous carcinomas are typical type II tumors. Histologically speaking, they are always considered as high grade endometrial carcinomas. Serous carcinomas, confined to the endometrium have an overall good prognosis, while those that have reached extra-uterine spread almost always end with the death of the patient (14).



**Figure 3.** Histology of serous endometrial carcinoma (H&E, magnification 100x; Olympus BX41) (image taken by candidate at the Pathology Department).

#### **1.4.2.4. Clear cell carcinoma**

Clear cell carcinomas are made up of polygonal or hobnail-shaped cells with clear or eosinophilic cytoplasm and often high grade nuclear atypia. They are uncommon and comprise only about 2% of endometrial carcinomas. They are also categorized as type II endometrial carcinoma and high grade carcinomas, have a mean age of diagnosis in the late sixties, and the most common presenting symptom is also post-menopausal bleeding. The overall survival varies between 21-75%, with an assumed 50% mean 5-year survival reported by most studies (14).

#### **1.4.2.5. Undifferentiated carcinoma**

Undifferentiated carcinoma arising in the endometrium is considered a rare neoplasm with only a few studies published thus far. This limited number of studies is most likely a reflection of the under-recognition of this tumor because of a lack of diagnostic criteria to separate it from poorly differentiated endometrial carcinomas (17).

### **1.5. Hypoxia-inducible factor 1 $\alpha$**

Hypoxia-inducible factor 1 $\alpha$  (HIF-1 $\alpha$ ) is encoded by the *HIF1* gene and plays an essential role in the adaptive cellular response to hypoxia. HIF-1 is a transcription factor and consists of an  $\alpha$  and a  $\beta$ -subunit, which together form a heterodimer and undergo conformational changes in response to variations of oxygen levels (18).

HIF-1 expression is regulated by enzymatic hydroxylation of conserved proline residues that causes the degradation under normoxia via the ubiquitin E3 ligase complex. There are two pathways involved in the expression of HIF-1 : synthesis of its  $\alpha$  -subunit functions via an oxygen dependent pathway and increases with falling oxygen levels. Contrary to that, the expression of the  $\beta$ -subunit is oxygen independent (18).

HIF-1 $\alpha$  is expressed in relatively low quantities in cells in normoxic conditions, but markedly increases in hypoxic cellular environments, one can therefore conclude, that HIF-1 $\alpha$  induces transcription of genes, which increase oxygen delivery to hypoxic tissues, increase cell survival and proliferation in hypoxia, and alter glucose and iron metabolism (19). HIF-1 $\alpha$  is responsible for the increased production of insulin-like growth factor-2 (IGF2) and transforming growth factor- $\alpha$  (TGF- $\alpha$ ). This also promotes cell survival and proliferation. Furthermore, it is implicated in the glucose metabolism. HIF-1 $\alpha$  regulates expressions of all enzymes in the glycolytic pathway, as well as expression of the glucose transporters GLUT1 and GLUT3, which mediate cellular glucose uptake (18). Hypoxia was found to increase the expression of transferrin, probably

to enhance the iron transport to erythroid tissues. The transferrin receptor is a hypoxia-inducible HIF-1 $\alpha$  target gene, enabling cellular transferrin uptake. Another HIF-1 $\alpha$  target for iron metabolism is ceruloplasmin, which is needed to oxidise ferrous to ferric ion. Ferric ion is the form that can be bound by transferrin. Hypoxic ceruloplasmin induction is likely to support iron supply to erythroid tissue (18).

### **1.5.1. HIF-1 $\alpha$ in endometrial carcinomas**

HIF-1 $\alpha$  is implicated in several aspects of tumor growth: It activates the transcription of various genes, like those responsible for the production of VEGF and erythropoietin. In that way it promotes oxygen delivery to hypoxic tissue by neoangiogenesis and increased erythropoiesis in hypoxic conditions. Overexpression of HIF-1 $\alpha$  was noted in tumors from various anatomical locations such as cervical squamous cell carcinomas, head and neck cancers, soft tissue tumors and colon cancer (20, 21). Overexpression of HIF-1 $\alpha$  has also been noted in endometrial carcinomas. Sivridis et al studied HIF-1 $\alpha$  expression in type I endometrial carcinoma only and found it to be overexpressed (22). Pansare et al found the HIF-1 $\alpha$  expression to be higher in type II carcinomas compared to type I carcinomas (23). To the best of my knowledge, none of the studies investigated HIF-1 $\alpha$  immunohistochemical expression in endometrial carcinomas based on histological grading into low grade and high grade endometrial carcinomas and compared them.

## **2. OBJECTIVES**

The aim of this research was to investigate the immunohistochemical expression of HIF-1 $\alpha$  in low grade and high grade endometrial carcinomas and to compare them. Since hypoxia is a key factor in cell survival in circumstances of uncontrolled growth, which carcinomas represent, we hypothesize that the expression of HIF-1 $\alpha$  is going to be greater in endometrial carcinomas of higher grade compared to the lower graded cases. Likewise, we hypothesize that high grade tumors are going to be larger, with deeper myometrial invasion and more frequent vascular invasion and lymph node involvement.



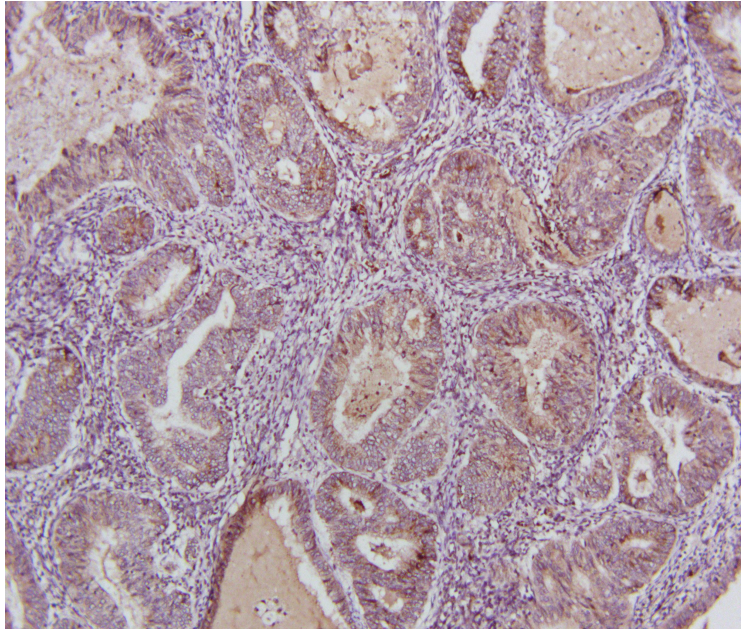
### **3. MATERIAL AND METHODS**

### 3.1.1. Material

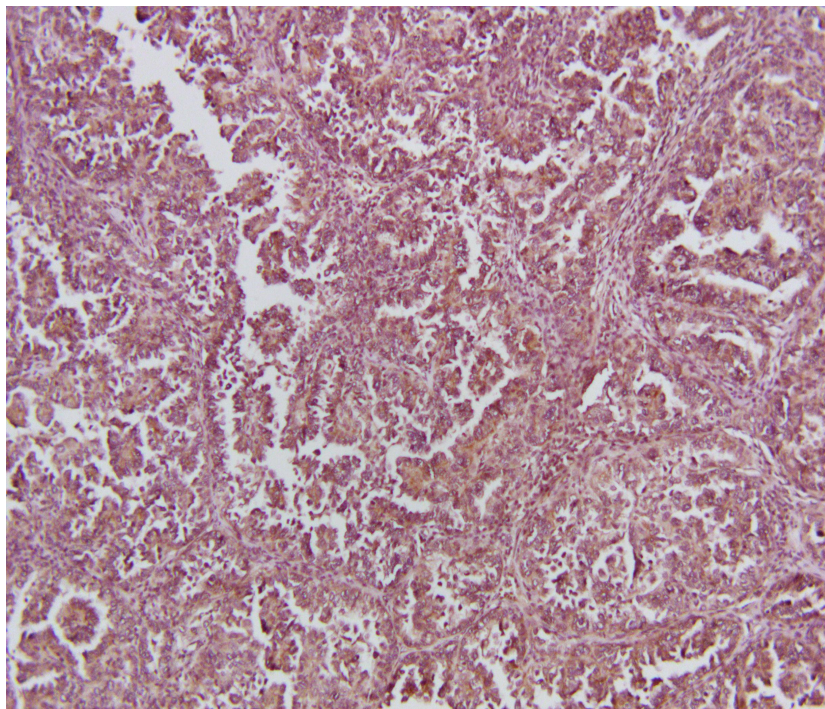
Our study included 10 cases of high grade endometrial carcinoma and 10 cases of low grade endometrial carcinoma. All of the samples included in the study were obtained from Pathology Department archive. They included surgical material that was sent for gross and histology assessment at the Pathology Department, University Hospital Split in the period from January 2015 till January 2017. Grading of endometrial carcinoma was done based on their histologic appearance according to WHO 2014 (14). Low grade group of endometrial carcinomas included well differentiated endometrioid carcinomas (histological grade 1), while high grade carcinomas were serous carcinomas and endometrioid carcinomas of histological grade 3. The age of the patients at the time of diagnosis was obtained from the pathology report. From the pathology report additional data were noted: depth of myometrial invasion, presence of vascular invasion and lymph node involvement.

### 3.1.2. Immunohistochemical analysis

Immunohistochemistry was performed on one tumor representative section for each sample as follows: paraffin sections were mounted on super frost slides (Thermoscientific, Darmstadt, Germany) and processed in an autostainer (Ventana Bench Mark Ultra Autostainer, Ventana Roche, Tucson, Arizona, USA). As primary antibody HIF-1 $\alpha$  (rabbit polyclonal IgG antibody, clone H-206, Santa Cruz Biotechnology Inc., Dallas, Texas, USA) was used, followed by Ultra view Universal DAB detection kit (Ventana, Tucson, Arizona, USA) (Figure 4&5). Brown membranous and cytoplasmic staining was considered positive and sample of normal colonic mucosa served as positive control. The immunohistochemical expression of HIF-1 $\alpha$  was assessed with Olympus BX41 microscope (Olympus, Tokyo, Japan) using semi-quantitative HSCORE method. HSCORE was calculated by the following formula:  $HSCORE = \sum P_i (i+1)$ , where "I" is the staining intensity marked with 1, 2 or 3 (weak (+), moderate (++) , or strong (+++)), and  $P_i$  is the percentage of cells of each staining category in the total cell count (24).



**Figure 4.** Immunohistochemical expression of HIF-1 $\alpha$  in low-grade endometrial carcinoma (magnification 100x, Olympus BX41) (image taken by candidate at the Pathology Department).



**Figure 5.** Immunohistochemical expression of HIF-1 $\alpha$  in high-grade endometrial carcinoma (magnification 100x, Olympus BX41) (image taken by candidate at the Pathology Department).

### **3.1.3. Statistical analysis**

MedCalc software (MedCalc software, Mariakerke, Belgium) was used for statistical analysis of the data. Following statistical tests were performed:  $\chi^2$ -test, t-test for independent samples and Mann-Whitney test, depending on the result distribution. Statistical significance was set at  $p < 0.05$ . Results were expressed as mean with standard deviation or median with minimum and maximum value, depending on the result distribution determined by Kolmogorov-Smirnov test.

## **4. RESULTS**

Our study included 10 cases of high grade endometrial carcinoma and 10 cases of low grade endometrial carcinomas based on the histological grading according to WHO 2014 (14). All of the cases were diagnosed after gross and microscopic examination on operative material at Pathology Department, Clinical Hospital Center Split in the period from January 2015 till January 2017.

In high grade endometrial carcinoma group there were 5 cases of serous carcinomas and the same number of endometrioid carcinomas of histological grade 3, while in low grade group all of the adenocarcinomas were of endometrioid type histological grade 1.

The following results are presented in Table 1. Immunohistochemical expression of HIF-1 $\alpha$  was higher in high grade endometrial carcinomas compared to low grade endometrial carcinomas, however that difference wasn't statistically significant ( $z=0.541$ ,  $P=0.589$ ). Carcinomas in high grade group were significantly larger compared to the ones in low grade group ( $t=2.572$ ,  $DF=18$ ,  $P=0.019$ ). At the time of diagnosis 9 patients from high grade group had lymphadenectomy and in 3 cases (30%) lymph node involvement was recorded, compared to 3 lymphadenectomies in low grade group, all of them without lymph node involvement ( $\chi^2=8.5$ ,  $DF=2$ ,  $P=0.014$ ). There was no statistically significant difference in the depth of myometrium invasion and presence of vascular invasion between studied groups ( $t=1.273$ ,  $DF=18$ ,  $P=0.219$ ) ( $\chi^2=1.879$ ,  $DF=1$ ,  $P=0.170$ ).

**Table 1.** Immunohistochemical expression of HIF-1 $\alpha$ , tumor size, depth of myometrium invasion, presence of vascular invasion and lymph node involvement in high grade (HG) and low grade (LG) endometrial carcinomas

	HG endometrial carcinomas N=10	LG endometrial carcinomas N=10	<i>P</i>
HIF-1 alpha (HSCORE)	3.9 (3.1-4)	3.75 (2.1-4)	0.589*
Tumor size (cm)	4.95 $\pm$ 1.36	2.95 $\pm$ 1.23	0.019 <sup>†</sup>
Depth of myometrium invasion (cm)	1.2 $\pm$ 0.77	0.75 $\pm$ 0.81	0.219 <sup>†</sup>
Presence of vascular invasion	5 (50%)	2 (20%)	0.170 <sup>††</sup>
Presence of lymph node involvement	3 (30%)	0	0.014 <sup>††</sup>

\*Mann-Whitney test; <sup>†</sup>Student t-test; <sup>††</sup>Chi-squared test

Values are presented as arithmetic mean  $\pm$  standard deviation, median with minimum and maximum value and as general numbers

At the time of diagnosis average age of patient with high grade endometrial carcinoma was 66.9  $\pm$  9.81 years compared to 65.8  $\pm$  8.03 years in low grade endometrial carcinoma group. The age difference wasn't statistically significant ( $t=0.274$ ,  $DF= 18$ ,  $P=0.787$ ).

## **5. DISCUSSION**



The availability of oxygen is a necessity for survival of all human cells, unaltered and malignant ones alike. HIF-1 $\alpha$  helps cells to adapt to hypoxia in various ways. Deduced from the fact of the fast growth of many carcinomas, it seems obvious that tumor cells possess mechanisms which enable them not only to multiply faster, but also to tolerate hypoxia better than non-malignant cells. High graded carcinomas often grow faster than an organism manages to provide adequate nutrition and oxygenation through e.g. neoangiogenesis, hypoxia is a common environment for individual cells. This is met with, beside other coping mechanisms, increased production of HIF-1 $\alpha$  resulting in upregulation of VEGF and increased blood supply to tumor cells, which fastens their dissemination and results in higher malignancy. Tumor hypoxia through activation of angiogenesis helps in tumor progression and metastasis and makes solid tumors resistant to radiation and chemotherapy (23). All of the facts listed above negatively affects the outcome of treated cancer patients. Studies of the cervical squamous cell carcinomas have shown that low-pO<sub>2</sub> tumors exhibited larger tumor extensions and more frequent (occult) parametrial spread, as well as lymph-vascular space involvement, compared to well-oxygenated tumors of similar clinical stage and size (20).

We postulated that immunohistochemical expression of HIF-1 $\alpha$  will be higher in high grade carcinomas, since histological grade correlates well with tumor aggressive behavior and therefore indirectly with the amount of hypoxia the tumor creates. Indeed, our results showed higher HIF-1 $\alpha$  expression in high grade carcinomas compared to low grade carcinomas. However this difference was not statistically significant ( $z=0.541$ ,  $P=0.589$ ). We believe the main reason for this statistical insignificance lies in the number of the studied samples, which we consider the main limitation of our study. In a study similar to ours, by Pansare et al which had bigger sample size, a statistically significant higher expression of HIF-1 $\alpha$  was found in type II endometrial carcinomas compared to type I carcinomas (23). The mentioned study observed 108 cases of type I and 48 cases of type II carcinomas. Unlike our study where we made distinct difference between high grade and low grade carcinomas based on histology, their study included 19 cases of high grade carcinomas (histological grade 3 according to WHO) in type I carcinomas.

However, both of our findings suggest HIF-1 $\alpha$ 's function as an important anti-hypoxia adaptation mechanism of carcinomatous cells. Furthermore, it potentially identifies it as a target for future therapy strategies. Development and successful clinical results of the anti-VEGF Antibody Bevacizumab, which inhibits neoangiogenesis, thereby decreasing blood supply of tumor cells and reducing their available oxygen and nutrients, proves the effectiveness of the concept of taking advantage of the altered characteristics of malignant compared to healthy tissue in oncology.

A similar concept could be envisioned targeting HIF-1 $\alpha$ . If cellular tolerance for hypoxia could be lowered, either by decreasing or stopping HIF-1 $\alpha$ 's expression, or by blocking its action, this might become another milestone in our repertoire of cancer treatment, which is yet underutilized. Several efforts have been made to exploit this, but so far none led to the development of a certified clinical drug with that mechanism of action (25). Further investigation and research in this matter should therefore be encouraged.

Our study also found that high grade carcinoma are significantly larger in size with higher frequency of lymph node involvement at the time of diagnosis compared to low grade carcinomas. Likewise, vascular invasion was more common in high grade carcinomas and myometrial invasion was greater compared to low grade carcinomas. These findings are consistent with previous knowledge on clinical behavior and morphological characteristic of endometrial carcinomas (14).

## **6. CONCLUSION**

1. Our study has shown, that endometrial carcinomas of high grade are significantly larger compared to their lower graded counterparts and have a higher frequency of lymph node involvement.
2. Immunohistochemical expression of HIF-1 $\alpha$  is greater in high grade endometrial carcinomas compared to low grade carcinomas, however that difference wasn't statistically significant. We assume the missing statistical significance to be founded in the small sample size examined. Further investigation regarding this matter should be performed.
3. HIF-1a could be an exploitable target in yet to be developed pharmacologic treatment of endometrial carcinomas and possibly other malignancies as well.

## **7. REFERENCES**

1. Wilczynski M, Danielska J, Wilczynski J. An update of the classical dualistic model of endometrial cancer. *Menopause Rev.* 2016;15(2):63-8.
2. American cancer society. Cancer statistics center [Internet]. [cited 2017 Jul 3]. Available from: URL [https://cancerstatisticscenter.cancer.org/?\\_ga=1.89291291.169398270.1480339447#/cancer-site/Uterine%20corpus](https://cancerstatisticscenter.cancer.org/?_ga=1.89291291.169398270.1480339447#/cancer-site/Uterine%20corpus).
3. Ma J, Ledbetter N, Glenn L. Testing women with endometrial cancer for lynch syndrome: should we test all?. *Journal of the Advanced Practitioner in Oncology.* *J Adv Pract Oncol.* 2013;4(5):322-30.
4. Galaal K, Al Moundhri M, Bryant A, Lopes AD, Lawrie TA. Adjuvant radiotherapy for stage I endometrial cancer. *Cochrane Database Syst Rev.* 2012;4:CD003916.
5. American Cancer Society: Endometrial-cancer [Internet] [cited 2017 Jul 3]. Available from <http://www.cancer.org/cancer/endometrialcancer/detailedguide/endometrial-uterine-cancer-key-statistics>.
6. Bokhman JV. Two pathogenetic types of endometrial carcinoma. *Gynecol Oncol.* 1983;15:10-7.
7. Sorosky JI. Endometrial Cancer. *Obstet Gynecol.* 2012;120:383-97.
8. Markowska A, Pawałowska M, Lubin J, Markowska J. Signalling pathways in endometrial cancer. *Contemp Oncol (Pozn).* 2014;18:143-8.
9. Mutter GL, Lin MC, Fitzgerald JT, et al. Altered PTEN expression as a diagnostic marker for the earliest endometrial precancers. *J Natl Cancer Inst.* 2000;92:924-30.
10. Hecht JL, Ince TA, Baak JP et al. Prediction of endometrial carcinoma by subjective endometrial intraepithelial neoplasia diagnosis. *Mod Pathol.* 2005;18:324-30.
11. Kafshdooz L, Tabrizi AD, Mohaddes SM, Kafshdooz T, Akbarzadeh A, Ghojzadeh M, Gharesouran J. The Polymorphism of Hypoxia-inducible Factor- 1a Gene in Endometrial Cancer. *Asian Pac J Cancer Prev.* 2014;15(23):10393-6.
12. Prat J, Gallardo A, Cuatrecasas M, Catusus L. Endometrial carcinoma: pathology and genetics. *Pathology.* 2007;39:1-7.
13. Reinbolt ER, Hays JL. The Role of PARP Inhibitors in the Treatment of Gynecologic Malignancies. *Front Oncol.* 2013;3:237.
14. Kurman RJ, Caranglu ML, Herrington CS, Young RH. WHO Classification of Tumors of

- Female Reproductive Organs. 4<sup>th</sup> edition. Lyon International Agency for Research on Cancer (IARC) 2014. pp. 126-131.
15. Hoffman BL, Schorge JO, Schaffer JI, Halvorson LM, Bradshaw KD, Cunningham FG, eds. (2012). Endometrial Cancer. Williams Gynecology (2nd ed.). McGraw-Hill. p. 818.
  16. Di Cristofano A, Ellenson LH. Endometrial carcinoma. *Annu Rev Pathol.* 2007;2:57.
  17. Altrabulsi B, Malpica A, Deavers MT, et al. Undifferentiated carcinoma of the endometrium. *Am J Surg Pathol.* 2005;29(10):1316-21.
  18. Lee JW, Bae SH, Jeong JW, et al. HIF-1 $\alpha$  its protein stability and biological functions. *Exp Mol Med.* 2004;36(1):1-12.
  19. Greg L Semenza Targeting HIF-1 for cancer therapy. *Exp Mol Med.* 2004;36(1):1-12.
  20. Hockel M, Schlenger K, Aral B, et al. Association between tumor hypoxia and malignant progression in advanced cancer of the uterine cervix. *Cancer Res.* 1996;56:4509-15.
  21. Brizel DM, Sibley GS, Prosnitz LR, et al. Tumor hypoxia adversely affects the prognosis of carcinoma of the head and neck. *Int J Radiat Oncol Biol Phys.* 1997;38:285-9.
  22. Sivridis B, Giatromanolaki A, Gatter K et al. Association of hypoxia-inducible factors 1 $\alpha$  and 2 $\alpha$  with activated angiogenic pathways and prognosis in patients with endometrial carcinoma. *Cancer.* 2002;95:1055-63.
  23. Pansare V, Munkarah AR, Schimp V, Haitham Arabi M, Saed GM, Morris RT, Ali-Fehmi R. Increased expression of hypoxia-inducible factor 1 $\alpha$  in type I and type II endometrial carcinomas. *Mod Pathol.* 2007;20(1):35-43.
  24. Allaire AD, Ballenger KA, Wells SR, et al. Placental apoptosis in preeclampsia. *Obstet Gynecol.* 2000;96:271-6.
  25. Barbara Onnis, Annamaria Rapisarda, Giovanni Melillo. Development of HIF-1 inhibitors for cancer therapy. *J Cell Mol Med.* 2009;13(9a):2780-6.

## **8. SUMMARY**



**Objectives:** to investigate HIF-1 $\alpha$  immunohistochemical expression in high grade and low grade endometrial carcinomas and to compared the results. Patient's age at the time of diagnosis, tumor size, depth of myometrial invasion, presence of vascular invasion and lymph node involvement was also noted for each studied group and compared.

**Subject and method:** 10 cases of high grade endometrial carcinoma and 10 cases of low grade endometrial carcinoma were enrolled in the study. Histological grading of endometrial carcinomas was done according to WHO 2014. Immunohistochemistry with primary antibody HIF 1 $\alpha$  was used. For the assessment of HIF1 $\alpha$  immunohistochemical expression HSCORE method was applied. Patient's age at the time of diagnosis, tumor size, depth of myometrial invasion, presence of vascular invasion and lymph node involvement were noted from pathology reports.

**Results:** Our results showed higher HIF-1 $\alpha$  immunohistochemical expression in high grade carcinomas compared to low grade carcinomas, however this difference wasn't statistically significant. High grade carcinomas had statistically significantly larger tumors and more frequently involved lymph nodes. Likewise high grade tumors had deeper myometrial invasion, more frequent vascular invasion and older patients at the time of diagnosis then low grade carcinomas, however these differences weren't statistically significant.

**Conclusion:** Our study has shown the higher immunohistochemical expression of HIF-1 $\alpha$  in high grade endometrial carcinomas compared to low grade carcinomas, however that difference wasn't significant.

## **9. CROATIAN SUMMARY**

**Ciljevi:** odrediti imunohistokemijsku razinu HIF1 $\alpha$  u karcinomima endometrija (EK) visokog i niskog gradusa te dobivene rezultate međusobno usporediti. Nadalje, dodatni cilj bio je utvrditi postoji li razlika u dobi pacijentica u vrijeme postavljanja dijagnoze, veličini tumora, dubini invazije miometrija, prisutnosti vaskularne invazije i zahvaćenosti limfnih čvorova između ispitivanih skupina.

**Ispitanici i metode:** 10 uzoraka EK visokog gradusa i isti broj uzoraka EK niskog gradusa je uključen u studiju. Gradus tumora je određen prema WHO kriterijima iz 2014. godine. Za imunohistokemijsku analizu korišteno je primarno protutijelo HIF1 $\alpha$ , imunohistokemijska razina istog procijenjena je uporabom HSCORE metode. Podatci o dobi pacijentica, veličini tumora, dubini invazije miometrija, prisutnosti vaskularne invazije i zahvaćenosti limfnih čvorova zabilježeni su iz patohistoloških nalaza.

**Rezultati:** Imunohistokemijska razina HIF1 $\alpha$  je bila veća u skupini EK visokoga gradusa u odnosu na skupinu EK niskoga gradusa, ali taj rezultat nije bio statistički značajan. Tumori iz skupine visokoga gradusa su bili značajno veći i imali su učestaliju zahvaćenost limfnih čvorova u odnosu na EK niskoga gradusa. Pacijentice s EK visokoga gradusa su bile starije u odnosu na pacijentice s EK niskoga gradusa, imale su veću učestalost vaskularne invazije i dublju invaziju miometrija ali navedeni rezultati nisu bili statistički značajni.

**Zaključak:** Rezultati ove studije su pokazali veću imunohistokemijsku razinu HIF1 $\alpha$  u EK visokoga gradusa u odnosu na EK niskoga gradusa ali bez statističke značajnosti, najvjerojatnije zbog male veličine uzorka, stoga je potrebno ponoviti studiju na većem broju uzoraka.

## **10. CURRICULUM VITAE**

<b>Name</b>	Leon Schmid
<b>Address</b>	Im Vogelsang 9, 53343, Wachtberg, Germany
<b>Date of Birth</b>	05/07/1991
<b>Place of Birth</b>	Marburg, Germany
<b>High School</b>	Konrad-Adenauer-Gymnasium Bonn (2001-2010)
<b>Civil service</b>	Hospital Maria Stern, Remagen
<b>University</b>	University of Split, School of medicine (2011-2017)
<b>Memberships</b>	Mensa in Deutschland e.V, Junge Alternative Deutschland