

Morphological characteristics of placentas with villitis of unknown etiology

Narloch, Charlotte

Master's thesis / Diplomski rad

2018

Degree Grantor / Ustanova koja je dodijelila akademski / stručni stupanj: **University of Split, School of Medicine / Sveučilište u Splitu, Medicinski fakultet**

Permanent link / Trajna poveznica: <https://um.nsk.hr/um:nbn:hr:171:138554>

Rights / Prava: [In copyright](#) / [Zaštićeno autorskim pravom.](#)

Download date / Datum preuzimanja: **2024-08-27**



Repository / Repozitorij:

[MEFST Repository](#)



**UNIVERSITY OF SPLIT
SCHOOL OF MEDICINE**

Charlotte Narloch

**MORPHOLOGICAL CHARACTERISTICS OF PLACENTAS
WITH VILLITIS OF UNKNOWN ETIOLOGY**

Diploma thesis

Academic year:

2017/2018

Mentor:

Sandra Zekić Tomaš, MD, PhD

Split, July 2018

**UNIVERSITY OF SPLIT
SCHOOL OF MEDICINE**

Charlotte Narloch

**MORPHOLOGICAL CHARACTERISTICS OF PLACENTAS
WITH VILLITIS OF UNKNOWN ETIOLOGY**

Diploma thesis

Academic year:

2017/2018

Mentor:

Sandra Zekić Tomaš, MD, PhD

Split, July 2018

TABLE OF CONTENTS

1. INTRODUCTION	1
1.1. Development of Human Placenta: from the blastocyst until birth	2
1.2. Villitis of Unknown Etiology (VUE)	3
1.3. Morphological characteristics of Placenta in various conditions	6
1.3.1. Maternal Blood Flow Disturbances	6
1.3.2. Maternal Vascular Malperfusion (MVM)	9
1.3.3. Fetal Blood Flow Disturbances	9
1.3.4. Fetal Vascular Malperfusion (FVM)	10
1.3.5. Noncirculatory Lesions	11
2. OBJECTIVES	12
3. MATERIALS AND METHODS	14
4. RESULTS	16
5. DISCUSSION	24
6. CONCLUSIONS	28
7. REFERENCES	30
8. SUMMARY	33
9. CROATIAN SUMMARY	36
10. CURRICULUM VITAE	38

ACKNOWLEDGMENT

*I am grateful for the chance to accomplish this diploma thesis thanks to my Sandra Zekić
Tomaš, MD, PhD, who helped me and inspired me about the field of Pathology.*

*I want to thank my family for the opportunity to study medicine especially my 'Ziehvater'
Dr. med. Jürgen Kuchlin.*

Thank you, Pierre Sanchis, for your unconditional love.

1. INTRODUCTION

1.1. Development of Human Placenta: from the blastocyst until birth

The fusion of two gametes induces the development of fetus and placenta. After fertilization, the zygote gives rise to a newly formed blastocyst. The blastocyst is composed of an outer layer termed trophoblast, which are precursors of the placenta, and an inner cell mass termed embryoblast, forming embryo, umbilical cord and amnion (1).

Six days after fertilization, implantation also termed nidation starts by blastocyst attachment with the embryonic side upfront on the endometrium. The implantation phase is characterised by progressive invasion of the blastocyst into maternal endometrium. The nidation process takes approximately three days and involves mainly the trophoblast cells, which differentiate into the outer syncytiotrophoblast (STB) or syncytium and the inner cytotrophoblast (CTB) layer (1,2).

The multinucleated STB invades deeply the stroma of the endometrium. During this process two new cavities develop the yolk sac and the amnion. Those two cavities are separated by the embryonic disc, which will become the embryo. Following implantation, the whole endometrium attains the term decidua due to endometrial changes (1,2).

The primary chorionic plate lies over the blastocyst cavity and forms later the fetal side. During the lacunar stage, the formation of vacuoles inside the STB takes place. These vacuoles fuse and give rise to lacunae. Trabeculae separate the lacunae and are the first villous extensions termed villous stems. Eventually the lacunae system fills with maternal blood and forms the intervillous space, which becomes the primary nutrient pool in between mother and child (1).

Arising from the trabeculae, the trophoblastic shell (later replaced by the term basal plate) delimits the maternal side. The trophoblastic shell surrounds the whole embryo complex and is in contact with maternal decidua cells (1).

The villous stages are characterised by the differentiation between primary, secondary and tertiary villi. As mentioned above, villi are formed by CTB migrating into trabeculae. Thus, primary villi consist of an inner layer of CTB and an outer layer of STB. Mesenchymal cells from the primary chorionic plate migrate towards the villi forming secondary villi. Fetal capillaries inside the villi characterise the tertiary villi. At the terminal portion of tertiary villi, trophoblastic cell columns form, attaching the villi to the trophoblastic shell and forming anchoring villi. Individual villi experience substantial branching inside the intervillous space (1).

Extravillous trophoblasts (EVTB), originating from CTB of the terminal portion of the villi, erode and transform spiral arteries inside the decidua. By this means, maternal blood empties into the intervillous space between fetal chorionic plate and maternal basal plate (1).

The placenta consists of chorion frondosum, the fetal part, and decidua basalis, the maternal part. Chorion frondosum forms when villi on the placental site grow and extend. When the villi along the rest of chorion regress with time, this anatomical part is termed chorion laeve. The decidua basalis is the part of decidua lying over chorion frondosum. On the maternal side of placenta, decidua septa form and penetrate into intervillous space covered by syncytial cells. These septa form compartments termed cotyledons, visible on gross examination of maternal side (3).

The formation of a primitive umbilical ring in a 5-week old embryo characterises the beginning of the umbilical cord development. It contains one connecting stalk; which includes umbilical vessels (two umbilical arteries and one umbilical vein) and allantois; the yolk stalk and a canal between intra- and extraembryonic cavities. The two stalks become enveloped by amnion and stuffed closely together forming the primitive umbilical cord. During the growth of the fetus, a physiological umbilical hernia forms due to a temporary small abdominal cavity. Next, the extra-embryonic cavity closes with repositioning of abdominal organs into fetus abdomen and additional regression of allantois and yolk stalk. The remaining umbilical arteries and vein become enclosed by Wharton's jelly and complete the umbilical cord development (3).

The continuous enlargement of uterus and growth of fetus leads to an increase in placental size. A full-term placenta usually accomplishes about 15-25 cm in diameter and 3 cm in thickness. It generally weighs approximately 500-600g. The placenta is an important organ providing a place of exchange for oxygen, carbon dioxide, nutrients and waste in between mother and fetus. It plays also an immunologic role, transferring Immunoglobulin G transplacental to provide passive immunity for the fetus especially for the postnatal period. Additional endocrine function of the placenta provides human chorionic gonadotropin, progesterone, estrogenic hormones and somatomammotropin (2,3).

1.2. Villitis of Unknown Etiology (VUE)

VUE belongs to the group of chronic villitis, which can be divided into two groups regarding the etiology, either infectious or unknown. Chronic villitis is defined by a chronic inflammatory state of villi inside the placenta (1).

VUE presents commonly in 5-10% of all afterbirths usually affecting placentas of third trimester. The possible etiology of VUE supports strongly an underlying immune-mediated process rather than a potential infectious cause by a yet unknown or unidentified agent (1,4).

The theory of an infectious cause is suggested due to similar histology of VUE compared to other known viruses causing chronic villitis. Infections often proceed without clinical symptoms and eventually are undetected without diagnosis (1).

The following suggest an immune-mediated reaction as a cause of VUE: histiocyte infiltration on histology, its common reappearance, the inclination to run in families and the affected site of inflammation at the interface between mother and child (1). It is believed that VUE resembles an allograft rejection and dominantly precipitated by infiltration of maternal T lymphocytes into fetal tissue. The maternal T lymphocytes, CD4+ and CD8+, are suggested to be present in VUE, as well as CD 68+ macrophages of maternal and fetal origin (5).

All in all, VUE resembles a host-versus-graft reaction with fetal villous stroma destruction and resulting into interruption of maternal-fetal interface. It can be promoted by multiparity or ovum donation concerning in assisted reproductive technology or less relatable diseases as in diabetes or obesity (4).

Placenta rigidity and smaller size on gross examination in VUE can be present. Mottling among necrotic villi appears in severe cases. All in all, there are no explicit changes determining VUE on gross examination (1).

The diagnosis of VUE is determined by histological examination. Microscopically, inflammatory cells especially histiocytes and lymphocytes are identified. The inflammatory cell infiltration causes damage of villi vasculature, resulting into obliteration of blood flow (6). Associated destruction of villi due to necrosis causes the formation of avascular villi. The representation is either local or diffuse. The predominant involvement includes the villi of maternal basal plate (1). The inflammation location of affected villi in VUE can be differentiated in between maternal parabasal/paraseptal side, along in the midparenchyma, fetal subchorionic side or a combination of all (7).

An important tool for VUE diagnosis is a grading schema (7). VUE is classified as low grade or high grade. Low grade VUE (Figure 1a) involves less than 10 villi per focus affected. According to an older grading scheme, low grade VUE can be further subclassified into focal, which includes less than 10 villi per focus on one microscopic slide, compared to multifocal, which can be demonstrated on multiple microscopic slides. On the other hand, high grade VUE (Figure 1b) is defined by the involvement of more than 10 villi per focus and can be subclassified according to an older grading schema into patchy, on multiple microscopic slides,

or diffuse, on all microscopic slides (8). Likewise, the Amsterdam Placental Workshop Group Consensus Statement published in 2016 a general grading model for VUE placentas, which included the classification of VUE into high grade and low grade without required further subclassification into focal, multifocal, patchy or diffuse (7).

A single focus of infiltrated villi is rarely seen. In those cases the diagnosis is described as being ungradable with possible classification of low or high grade depending on the degree of affected villi described above (5,7). The differentiation between low grade VUE and high grade VUE is of utmost importance due to certain association in between high grade VUE and intrauterine growth restriction (IUGR), neurodevelopmental delay of fetus and high recurrence rate of high grade VUE in subsequent pregnancies (7).

The impaired parts of the placenta, caused by VUE, undermine the nutrient and waste exchange between mother and child. Other events as prematurity, stillbirth or recurrent abortions can also present concomitantly with VUE (1).

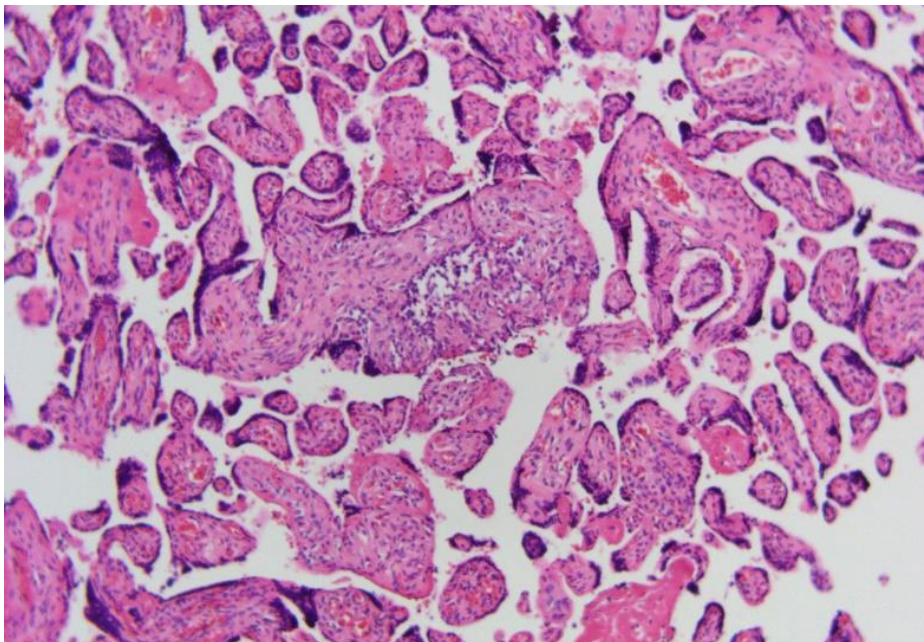


Figure 1a. Low grade villitis of unknown etiology (VUE), H&E, magnification 100X (Figure taken from Mentor's archive).

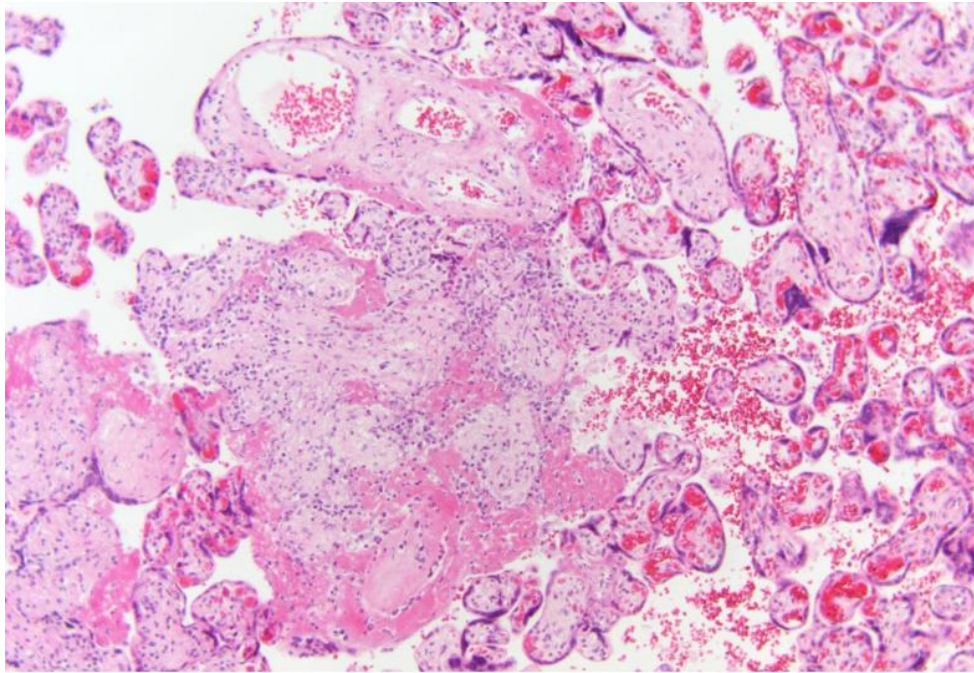


Figure 1b. High grade villitis of unknown etiology (VUE), magnification 100X (Image taken from Mentor’s archive).

1.3. Morphological characteristics of Placenta in various conditions

Pathological abnormalities of the placenta can be divided into maternal blood flow abnormalities, fetal blood flow abnormalities and noncirculatory pathologies. Many of the following pathologies appear in healthy placentas and may have no clinical implication (6).

1.3.1. Maternal Blood Flow Abnormalities

These include perivillous and subchorionic fibrin deposition, subchorial thrombosis (Figure 2), retroplacental and marginal hematoma, and placental infarction (6).

Firstly, Perivillous fibrin deposition can be found in a minority of investigated full-term placentas on gross examination but in nearly all placentas on histological examination. Presenting most commonly around the border of the placenta with solid, demarcated, discoloured yellowish or brownish white plaques. Histology shows on recent lesions, fibrin depositions followed by fibrosis surrounding the villi inside the intervillous space and finally vascular occlusion of affected villi. Older lesions present with disintegration of the outer placental membrane, the STB layer, surrounding the villi (6).



Figure 2. Massive subchorial thrombosis (Brues' mole) (Image taken from Mentor's archive).

Secondly, subchorionic fibrin deposition, which presents on gross examination with solid, laminated, white plaques. On histology, laminated fibrin deposition spares the villi but infiltrate the chorionic plate. Subchorionic and perivillous fibrin deposition share the same pathogenesis of sudden maternal blood flow currents and stasis causing fibrosis in different anatomic locations (6).

Subchorial thrombosis (Figure 2) presents on fetal surface with a protruding bulge composed of nodules and red thrombus on gross examination. Mainly fibrin and erythrocyte deposition can be found on histology. It can appear in some fatal pathologies as in abortion. Subchorial thrombosis should be distinguished from subamniotic hematoma, which affects a different anatomic zone lying more superficial and presents without thrombus formation on histology (6).

Retroplacental hematoma presents usually with a crater-like depression and hematoma on maternal side of placenta. Recent hematomas appear soft, reddish and detach easily from specimen. Commonly the hematoma arrives already separated from the placenta inside the transport medium. Fibrin strands and polymorphonuclear cell deposition on histology can lead to recent retroplacental hematoma. However, older hematoma presents on gross examination brown and solid and on histology with infiltration of hemosiderin and macrophages. Additionally, a very fresh hematoma presents without any depression of placenta but with a

large portion of blood clot. Secondary infarction in retroplacental hematoma of the subjacent part of the placenta often occurs and if present could be seen on histology. The underlying pathological mechanism is based on diseased decidual blood supply, as it occurs in hypertension during pregnancy and detachment of placenta. The precise pathogenesis is not certain. A small retroplacental hematoma may not have any clinical significance due to placental blood reserve withstanding a villous surface loss of $\leq 30\%$ (6).

In comparison to marginal hematoma, which presents with a blood clot on the lateral margin of the placenta. It has no known clinical consequences on the placental function (6).

Finally, placental infarction (Figure 3) occurs when maternal decidual arterioles become occluded most commonly by a thrombotic mass. It occurs in healthy term placentas involving less than 5% parenchyma but also in severe diseased placentas simultaneously affecting more parenchyma. Severe placental infarction is related to fetal hypoxia and even intrauterine fetal demise. A recent infarct is characterised by demarcated, dark reddish, hard lesions mostly at the periphery. An old infarct presents with harder, brown-yellowish or white lesions. On histology, infarcts differ in stages. Firstly, shrinkage of the intervillous space and packed villi can be found, followed by villous blood flow congestion and STB layer necrosis. Later on, nuclear shrinkage and fragmentation of STB and capillary collapse of affected villi with polymorphonuclear accumulation around the infarct are found. Finally, eosinophilic hyaline substance replaces syncytium with degeneration of stroma and capillaries. Old infarcts are marked by empty villi (6).

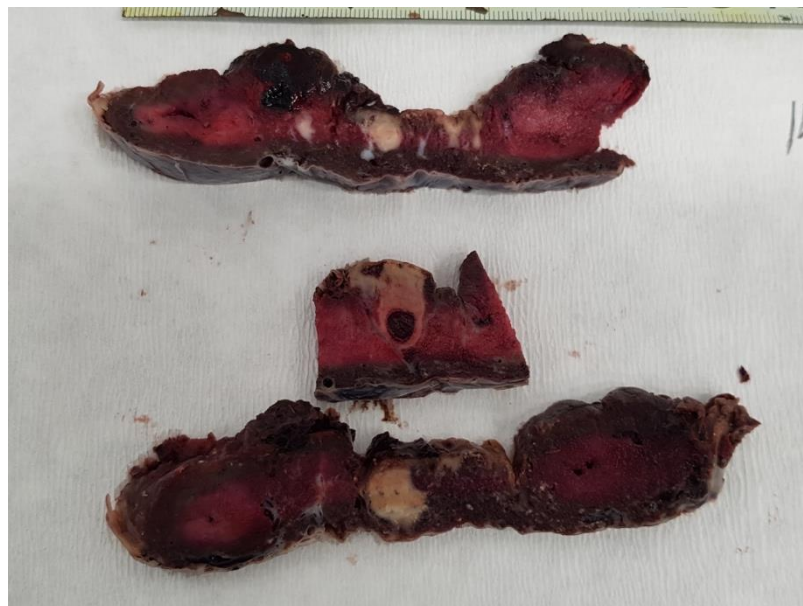


Figure 3. Multiple chronic villi infarction of placenta (Image taken from Mentor's archive).

1.3.2. Maternal Vascular Malperfusion (MVM)

Recent literature proposed in 2016 a differentiation between maternal blood flow disturbances in placenta and maternal vascular malperfusion of placental bed (7). The following pathologies are part of MVM. Placental hypoplasia, is defined by placental weight below tenth centile and/or by the presence of a thin umbilical cord. On gross examination the placenta weights less than for the estimated gestational age appropriate (7).

Two other pathologies belong additionally to MVM. Distal villous hypoplasia and accelerated villous maturation, part of abnormal villous development, are microscopic findings. Both findings can be found in placental insufficiency resulting into fetal growth restriction (FGR) and other pregnancy complications. In the end, many of the mentioned findings coexist in placentas (7).

1.3.3. Fetal Blood Flow Disturbances

The following pathologies are caused due to abnormalities of blood flow in fetus.

Intervillous thrombosis presents with a size of 2-5 cm on gross examination with circular, soft and dark reddish lesions anywhere in the placenta, compared to older thrombi, which appear hard, whitish and stratificated. Additionally, thrombi of median age, present with a soft core and a firm outer zone. On histology fibrin lamellae with nucleated erythrocytes, which disappear with time, can be found. Intervillous thrombosis etiology is based on fetal capillary bleeding into the intervillous space due to STB rupture, resulting into mixture of maternal and fetal blood and thrombus formation. The incidence has no negative effect on placental action (6).

Kline's hemorrhage is a precursor of intervillous thrombosis and presents with nodular or bloody foci on gross examination (6).

Another pathology of abnormal fetal blood supply is the fetal artery thrombosis characterised by a triangular pallor shape inside the placenta. The thrombosis cannot be shown on gross examination. The histology shows inside the pallor triangular form avascular villi with augmented stromal tissue. Additional STB knots can be found and the thrombosis of the fetal artery can be demonstrated on the tip of stem villi. Specialists should be aware of this pathology because of the possibility to miss those lesions. In rare cases when 40-50% of villi are affected the outcome can be intrauterine fetal demise (6).

As mentioned in the section of abnormal maternal blood supply of placenta, subamniotic hematoma describes a collection of blood between chorion and amnion and is usually caused by trauma during the delivery of fetus. Mostly, it does not affect the function of placenta but should be differentiated from subchorionic hematoma (6).

1.3.4. Fetal Vascular Malperfusion (FVM)

As mentioned above, the Amsterdam Placental Workshop Group Consensus Statement proposed a differentiation between fetal blood flow disturbances in placentas and fetal vascular malperfusion (7).

The following pathologies are part of FVM: Umbilical cord lesions, segmental avascular villi, intramural fibrin deposition, villous stromal-vascular karyorrhexis and stem vessel obliteration (7).

Umbilical cord lesions include hypertorsion of umbilical cord (Figure 4), presence of true knots and velamentous umbilical cord insertion. Avascular villi manifest due to a thrombosis of villi and downstream stem vessel obliteration visible on microscopic examination (7).

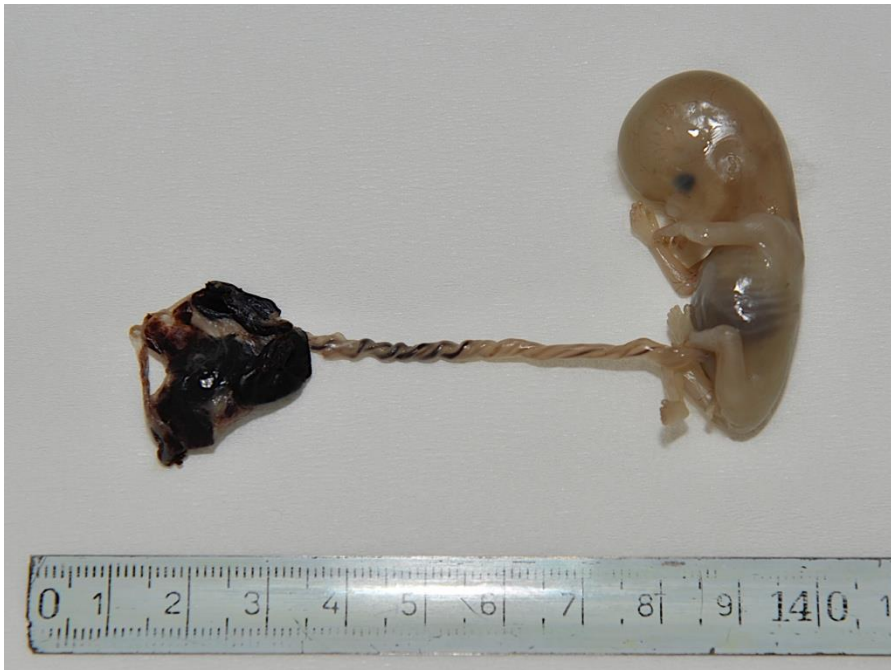

Figure 4. Demonstration of pregnancy loss due to hypertorsion of umbilical cord (Image taken from Mentor's archive).

Intramural fibrin deposition can affect the placenta globally with the possible result of placental insufficiency. Segmental fibrin deposition and its complication is yet unknown. Villous stromal-vascular karyorrhexis can also be termed hemorrhagic endovasculitis. In the end, stem vessel obliteration manifest with thickening of vessel wall and closure of vascular lumen on histological examination (7).

1.3.5. Noncirculatory Lesions

The noncirculatory lesions include calcifications of the placenta and chorionic cysts. Placental calcifications present along maternal placental side with widely distributed small whitish plaques with a hard rough-grained feel when sectioned.

Chorionic cysts, which measure a size of 5-10 mm and contain a soft gelatinous substance on the inside with a membrane covered. They are located in the subchorionic area or among septa. Both lesions present with no known pathological consequences (6).

2. OBJECTIVES

The primary objective of this study is to compare placental morphological findings of placentas affected by VUE and healthy term placentas.

The secondary objective of presented study is the comparison of morphological findings of placentas with high grade VUE with those from placentas with low grade VUE.

3. MATERIALS AND METHODS

Data collection has been withdrawn from the department of Pathology, Forensic and Cytology and department of Gynaecology and Obstetrics of University Hospital of Split. The study included 50 placentas diagnosed with VUE and 50 placentas from normal term pregnancies. All of the placentas included in the presented study were examined at the department of Pathology, Forensic and Cytology from the first of January 2016 until the first of April 2018.

Inclusion criteria for placentas with VUE was the diagnosis of VUE based on histological examination of placental sample. The grading model for VUE placentas used in this study included the classification of VUE into high grade VUE and low grade VUE without required further subclassification into focal, multifocal, patchy or diffuse VUE. Low grade VUE involves less than 10 villi per focus affected and high grade VUE is defined by the involvement of more than 10 villi per focus (7). In case basal villitis was demonstrated, it was noted. The control group included placentas from term pregnancies without VUE diagnosis. The following data were obtained from the archive at department of Gynaecology and Obstetrics: birth weight, gender, gestational age and mother's age. From the placental pathological reports, the following gross criteria were noted: the size of the placenta, including largest placental diameter and thickness, the umbilical cord insertion and umbilical cord length, hypertorsion of umbilical cord and true umbilical knots. The variations of umbilical cord insertion were noted on gross examination with following grouping: central insertion, paracentral insertion, paramarginal insertion, marginal insertion and velamentous insertion. Additionally, following pathohistological findings, if present, were included into the study: placental infarction, intervillous thrombosis, retroplacental hematoma, chorioamnionitis, funiculitis, deciduitis, fetal thrombotic vasculopathy, villous immaturity and accelerated villous maturation. Likewise noted lesions were furthermore grouped into MVM and FVM lesions and lesions due to maternal and fetal blood flow disturbances.

Statistical analysis was done with the use of MedCalc software (MedCalc software, Mariakerke, Belgium) applying the chi-square-test, Student's t-test and Mann-Whitney test, depending on the data distribution following Kolmogorov-Smirnov test. The statistical significance value was set at $P < 0.05$.

4. RESULTS

Our study included 100 placentas. The study group comprised 50 placentas with VUE diagnosis, while the control group included 50 term placentas without VUE diagnosis. In 30 (60.0%) of the VUE placentas were diagnosed as low grade VUE, while remaining 20 (40.0%) placentas were characterized as high grade VUE. In 11 (22.0%) VUE placentas additional finding was villitis basalis, which was noted in 7 placentas with high grade VUE and 4 placentas with low grade VUE.

There was no statistically significant difference in the gender between two investigated placental groups ($P=0.772$; $\chi^2=0.084$; $DF=1$). The placentas with VUE had statistically significant lower gestational age than the control group ($P<0.001$; $Z=5.209$). The age of mothers in the VUE placenta group were higher than in the control group, which was a statistically significant finding ($P=0.005$; $t=-2.889$). Birth weight was statistically significant lower in the VUE group compared to the controls ($P<0.001$; $t=6.044$). IUGR was noted in 42.9% of all cases in VUE group, while it was absent in the control group (Table 1).

Table 1. Clinical information

	Placentas with VUE (N=50)	Control placentas (N=50)	<i>P</i>
Male gender (n(%))	22 (49.4)	27 (55.1)	0.772*
Gestational age (weeks)	36 (27-41)	39 (37-42)	<0.001†
Mother's age (years)	31±4.71	28±5.18	0.005‡
Birth weight (grams)	2568±780	3364±491	<0.001‡
IUGR ^a	21 (42.9)	0	<0.001*

Data are presented as mean±standard deviation, general number (%) or median with minimum to maximum values

* chi-square test

† Mann-Whitney test

‡ Student's t-test

^a Intrauterine growth restriction

Table 2. Gross morphological findings

	VUE group (N=50)	Control group (N=50)	<i>P</i> *
Largest placental diameter (cm)	17 (8-24)	18 (14-22)	0.073†
Placental thickness (cm)	2.5 (2-4)	3 (2-5)	<0.001†
UC ^a insertion			
Central	4 (8.2)	17 (14)	
Paracentral	26 (53.1)	18 (36)	0.187
Paramarginal	9 (18.4)	15 (20)	
Marginal	9 (18.4)	6 (12)	
Velamentous	1 (2)	4 (8)	
UC ^a length (cm)	35.4±11	46.5±10	<0.001‡
Presence of UC ^a Hypertorsion	15 (36.5)	12 (25)	0.539
Presence of UC ^a true knot	2 (4)	2 (4)	1

Data are presented as mean±standard deviation, general number (%) or median with minimum to maximum values

* chi-square test

† Mann-Whitney test

‡ Student's t-test

^a Umbilical Cord

There was no statistically significant difference in the placental diameters ($P=0.073$; $Z=1.790$), however, placentas in VUE group were statistically significant thinner than placentas in the control group ($P<0.001$; $Z=4.795$) (Table 2).

Paracentral umbilical cord insertion was the most common type of insertion in presented groups, there was no statistically significant difference in the type of umbilical cord insertion between VUE placentas and the control group ($P=0.187$; $\chi^2=0.277$; $DF=4$). Umbilical cord from VUE group were statistically significant shorter than umbilical cord from the control group ($P<0.001$; $t=5.103$). Hypertorsion of umbilical cord was noted in 15 placentas from VUE group and 12 placentas from the control group, this finding was not statistically significant

($P=0.539$; $\chi^2=0.376$; $DF=4$). True umbilical cord knots were recorded in two placentas in the VUE group and two placentas in the control group ($P=1$; $\chi^2=0.00$; $DF=1$) (Table 2).

Table 3. Pathohistological findings

	VUE group (N=50)	Control group (N=50)	<i>P</i> *
Accelerated villous maturation	5 (10)	6 (12)	0.751
Chorioamnionitis	9 (18)	15 (30)	0.162
Deciduitis	1 (2)	1 (2)	1
Fetal thrombotic vasculopathy	5 (10)	0	0.023
Funiculitis	8 (16)	0	0.003
Intervillous thrombosis	8 (16)	7 (14)	0.781
Placental infarction	9 (18)	6 (12)	0.403
Retroplacental hematoma	1 (2)	1 (2)	1
Villous immaturity	3 (6)	5 (10)	0.463

Data are presented as general number (%)

* chi-square test

Funiculitis was noted in 16.0% of VUE placentas and none of the placenta from the control group, likewise 10.0% of VUE placentas had fetal thrombotic vasculopathy that was not found among placentas from the control group. Both of the presented findings were statistically significant ($P=0.003$; $\chi^2=8.609$; $DF=1$ and $P=0.023$; $\chi^2=5.211$; $DF=1$) (Table 3).

There was no statistically significant difference in the presence of placental infarction ($P=0.403$; $\chi^2=0.699$; $DF=1$), intervillous thrombosis ($P=0.781$; $\chi^2=0.078$; $DF=1$), retroplacental hematoma ($P=1$; $\chi^2=0.00$; $DF=1$), chorioamnionitis ($P=0.162$; $\chi^2=1.954$; $DF=1$), deciduitis ($P=1$; $\chi^2=0.00$; $DF=1$), villous immaturity ($P=0.463$; $\chi^2=0.538$; $DF=1$) and accelerated villous maturation ($P=0.751$; $\chi^2=0.101$; $DF=1$) between both investigated groups (Table 3).

In 16 (32.0%) VUE placentas and 13 (26.0%) placentas from the control group signs of maternal vascular malperfusion were present and the difference was not statistically significant ($P=0.433$; $\chi^2=0.511$; $DF=1$).

In 5 (10.0%) VUE placentas and none of placentas from the control group had signs of fetal vascular malperfusion, the finding was statistically significant ($P=0.023$; $\chi^2=5.211$; $DF=1$).

Lesions due to maternal blood flow disturbances were noted in 11 (22.0%) of VUE placentas and 6 (12.0%) of placentas from the control group, the difference was not statistically significant ($P=0.185$; $\chi^2=1.754$; $DF=1$).

Lesions due to fetal blood flow disturbances were noted in 12 (24.0%) of VUE placentas and 7 (14.0%) of placentas from the control group, the difference was not statistically significant ($P=0.205$; $\chi^2=1.608$; $DF=1$).

Table 4. Gross morphological findings in placentas with high grade VUE (HG VUE) and low grade VUE (LG VUE)

	HG VUE group (N=20)	LG VUE group (N=30)	<i>P</i> *
Largest placental diameter (cm)	16 (8-24)	17 (15-23)	0.083‡
Placental thickness (cm)	2.5 (2-3.5)	2.5 (2-4)	0.838†
UC ^a insertion			
Central	1 (5.3)	3 (10)	
Paracentral	10 (52.6)	16 (53.3)	0.293
Paramarginal	2 (10.5)	7 (23.3)	
Marginal	6 (31.6)	3 (10)	
Velamentous	0	1 (3.3)	
UC ^a length (cm)	32.2±1.71	37.6±10.40	0.094‡
Presence of UC ^a Hypertorsion	7 (35)	8 (27.6)	0.584
Presence of UC ^a true knot	0	2 (6.7)	0.243

Data are presented as mean±standard deviation, as general number (%) or as median with minimum to maximum values

*chi-square test

‡ Student's t-test

† Mann-Whitney test

^a Umbilical Cord

There was no statistically significant difference in the placental diameters ($P=0.083$; $t=1.773$) or placental thickness between placentas with high grade VUE and low grade VUE ($P=0.838$; $Z=0.204$). The most common umbilical cord insertion site for both VUE placental groups was paracentral ($P=0.293$; $\chi^2=4.942$; $DF=1$). Although the umbilical cord length was longer in low grade VUE placentas, the finding was not statistically significant ($P=0.094$; $t=1.712$). Umbilical cord hypertorsion was noted in 7 high grade VUE placentas and 8 low grade VUE placentas, the finding was not statistically significant ($P=0.584$; $\chi^2=0.300$; $DF=1$).

In the low grade VUE group two placentas had true knots of the umbilical cord and none were present the high grade VUE placentas ($P=0.243$; $\chi^2=1.361$; $DF=1$).

Table 5. Pathohistological findings in placentas with high grade VUE (HG VUE) and low grade VUE (LG VUE)

	HG VUE (N=20)	LG VUE (N=30)	<i>P</i> *
Accelerated villous maturation	3 (15)	2 (6.7)	0.341
Chorioamnionitis	5 (25)	4 (13.3)	0.298
Deciduitis	0	1 (3.3)	0.414
Fetal thrombotic vasculopathy	1 (5)	4 (13.3)	0.341
Funiculitis	3 (15)	5 (16.7)	0.876
Intervillous thrombosis	3 (15)	5 (16.7)	0.876
Placental infarction	5 (25)	4 (13.3)	0.298
Retroplacental hematoma	1 (5)	0	0.221
Villous immaturity	2 (10)	1 (3.3)	0.336

Data are presented as general number (%)

*chi-square test

There was no statistically significant difference in the presence of placental infarction ($P=0.298$; $\chi^2=1.084$; $DF=1$), intervillous thrombosis ($P=0.876$; $\chi^2=0.024$; $DF=1$), retroplacental hematoma ($P=0.221$; $\chi^2=1.5$; $DF=1$), chorioamnionitis ($P=0.298$; $\chi^2=1.084$; $DF=1$), funiculitis ($P=0.876$; $\chi^2=0.024$; $DF=1$), deciduitis ($P=0.414$; $\chi^2=0.667$; $DF=1$), fetal thrombotic vasculopathy ($P=0.341$; $\chi^2=0.907$; $DF=1$), villous immaturity ($P=0.336$; $\chi^2=0.927$; $DF=1$) and accelerated villous maturation ($P=0.341$; $\chi^2=0.907$; $DF=1$) between investigated groups (Table 5).

In 9 (45.0%) high grade VUE placentas compared to 7 (23.3%) low grade VUE placentas had signs of MVM, the difference was not statistically significant ($P=0.111$; $\chi^2=2.537$; $DF=1$).

FVM was noted in 1 (5.0%) high grade VUE placentas and 4 (13.3%) low grade VUE placentas, the difference was not statistically significant ($P=0.341$; $\chi^2=0.907$; $DF=1$).

Lesions due to maternal blood flow disturbances were noted in 6 (30.0%) of high grade VUE placentas and 5 (16.7%) of placentas from low grade VUE group, the difference was not statistically significant ($P=0.270$; $\chi^2=1.218$; $DF=1$).

Lesions due to fetal blood flow disturbances were noted in 4 (20.0%) of high grade VUE placentas and 8 (26.7%) of placentas from low grade VUE group, the difference was not statistically significant ($P=0.592$; $\chi^2=0.287$; $DF=1$).

5. DISCUSSION

VUE belongs to the group of chronic villitis in placenta and can be defined as infiltration of chorionic villi with chronic inflammatory cells (1). The diagnosis of VUE follows after pathohistological examination. Studies have shown that 80% of VUE cases mostly affect pregnancies after the 37th gestation week, while affected placentas before the 22nd gestational week suggest a chronic villitis of an infectious etiology (9). If an infectious cause is excluded, the suggestive diagnosis is an idiopathic etiology, hence the name- villitis of unknown etiology. The majority believes that VUE is caused by an immune-mediated reaction (1).

The results in this study show that placentas from older mothers are more often diagnosed with VUE placentas than from younger women. It is generally known that older women are more prone to various complications related to pregnancy, therefore one would expect a higher risk for VUE development in older women. Lower gestational age was noted in the VUE placental group compared to normal placentas. Although it is known that VUE is more common in term placentas (>37 weeks of gestation), results of this study suggest that median gestational age of VUE affected placentas is 36 weeks of gestation compared to 39 weeks of gestation in the control group (1). From 21 newborn out of 50 within VUE placental group present with Intrauterine growth restriction (IUGR), not a single case was recorded in the control group. The findings of IUGR only in placentas from VUE group suggest IUGR as a single most common adverse pregnancy outcome in VUE affected pregnancies. The presented finding is in accordance with previously published studies, in fact some of the authors suggests that VUE is highly associated with Small for gestational age (SGA) babies and that VUE is an independent risk factor for the development of SGA (10). Presented result is valuable considering that IUGR is one of the most important adverse pregnancy outcomes (11). Additionally, Boog *et al.* mention in their study that 24-31% of all idiopathic IUGR cases could be caused by VUE (12).

This study shows that placentas with VUE have shorter umbilical cord length than the control group and the most common umbilical cord insertion type was paracentral in both groups. From all mentioned umbilical cord insertion types, the velamentous type is pathologic and the rarest type. In the velamentous type the cord inserts into the membranes exposing the umbilical vessels without the protective Wharton's jelly causing them to be prone to trauma and disruption (1). According to this study the umbilical cord insertion is most commonly paracentral in both studied groups, while the velamentous umbilical cord insertion is the least common umbilical cord insertion type. There is no suggestion that an association of VUE and type of umbilical cord insertion exist according to this study.

Our study showed that the umbilical cord length is decreased in our placentas with VUE compared to the normal term placentas, but still within the normal range, which is defined with a short umbilical cord length of <35 cm and a long cord of >70-80 cm. Umbilical cord length increases with gestational age as found in a Finnish retrospective study suggesting it (13). Likewise, the mentioned study found also that other variables as birth weight, maternal age, placental weight, pregravid maternal BMI and parity correlate with umbilical cord length (13). In general, literature explains that the entire umbilical cord is not submitted to the Pathology department. Short umbilical cord diagnosis should be considered with caution. Another unfortunate disadvantage is that the umbilical cord shrinks after the first few hours after delivery. Therefore, accurate recordings of umbilical cord length immediately after delivery is recommendable (1,14).

Funiculitis and fetal thrombotic vasculopathy are statistically significant more frequent in placentas with VUE than in the control group. Acute funiculitis describes the inflammation of the umbilical cord and is part of an fetal inflammatory response following microbial ascending infection. Acute funiculitis typically presents with acute chorioamnionitis, which is a common pathology. Chronic chorioamnionitis, on the other hand, a recently described pathology, presents in 79% of cases with VUE. The presence of chronic chorioamnionitis should alert the pathologist to search for foci of chronic villitis (1). This study shows, not surprisingly, the presence of chorioamnionitis and placental infarction in both groups. Placental infarction is the most common and distinct MVM lesion on gross examination (1).

On the other hand, fetal thrombotic vasculopathy is part of lesions due to FVM (1). The control group being unaffected by fetal thrombotic vasculopathy implicates that FVM are present in the pathogenesis of VUE. With regard to the location of VUE in more than half of cases the distal villi are affected. With a higher degree of VUE the stem villi are affected, and occasionally the chorionic plate. As a result, it causes thrombosis of stem villi vasculature and leads to fetal thrombotic vasculopathy (9).

The second objective of this study includes the morphological characteristics of high grade VUE versus low grade VUE. There is no statistically significant difference regarding the gross morphological findings and pathohistological findings of low grade VUE compared to high grade VUE. A possible explanation could be the small sample size of comparison with 20 high grade VUE placentas and 30 low grade VUE placentas. For further studies concerning the morphological differences in VUE grades, we recommend a larger sample size of placentas (15).

VUE is an important finding, especially high grade VUE due to its adverse impact on pregnancy outcome. Overweight females present often with recurrent high grade VUE and in those cases the complications of the fetus can range from mild neurological abnormalities to intrauterine fetal death. Other contributing factors to develop high grade VUE are diabetes, multiparity and in ovum donation according to Redline *et al.* (4). Those females carry a higher recurrence risk of VUE and those pregnancies should be considered as high-risk (9).

The study contained a sample size of 100 placentas, 50 with diagnosed with VUE and 50 healthy term placentas. One of the study limitation is the small sample size of placentas, especially among the investigated high grade VUE placentas and low grade VUE placentas. Another limitation to mention is the inability to include the mass of investigated placentas in this study. Unfortunately, it was impossible due to technical reasons encountered in the Pathology, Forensic and Cytology department.

In the end, Boog *et al.* investigate treatment options with acetylsalicylic acid, immunosuppressants and Immunoglobulins in prevention of recurrent VUE in pregnant women. This research presents a clinical interest for further understanding of VUE (17).

6. CONCLUSIONS

1. This study shows on gross examination a thinner placenta and a shorter umbilical cord length in VUE placentas compared to the healthy term placentas. On pathohistological exam, the presence of funiculitis and fetal thrombotic vasculopathy was more frequent in VUE placentas than in the control group. From clinical point of view, the study implies that VUE is associated with IUGR. Likewise, a lower gestational age, older mother's age and lower birth weight was found in placentas with VUE compared to healthy term placentas.

2. There is no statistically significant difference found among investigated placental findings in the VUE group regarding VUE grading. We propose for the future further studies in high grade and low grade VUE with a larger sample size.

7. REFERENCES

1. Baergen RN. Manual of Benirschke and Kaufmann's Pathology of the Human Placenta. New York: Springer; 2005.
2. Mescher AL. The Female Reproductive System. In: Weitz M, Kearns B, editors. Junqueira's Basic Histology Text and Atlas. 13th ed. New York: Mc Graw Hill; 2013. p. 467–470.
3. Sadler TW. Third Month to Birth: The fetus and Placenta. In: Taylor C, editor. Langman's Medical Embryology. 12th ed. Philadelphia: Lippincott Williams & Wilkins; 2012. p. 96–109.
4. Redline RW. Placental pathology: Is it time to get serious? [Internet]. Modern Medicine Network; 2014 May 1 [cited 2018 July 1]. Available from: <http://www.contemporaryobgyn.net/modern-medicine-cases/placental-pathology-it-time-get-serious>
5. Benzon S, Zekić Tomaš S, Benzon Z, Vulić M, Kuzmić Prusac I. Involvement of T lymphocytes in the placentae with villitis of unknown etiology from pregnancies complicated with preeclampsia. J Matern Fetal Neonatal Med. 2016;29:1055–60.
6. Joshi VV. Handbook of Placental Pathology. New York: IGAKU-SHOIN; 1994.
7. Khong TY, Mooney EE, Ariel I, Balmus NCM, Boyd TK, Brundler MA, et al. Sampling and definitions of placental lesions Amsterdam placental workshop group consensus statement. Arch Pathol Lab Med. 2016;140:698-713.
8. Ziadie M. Villitis of unknown etiology (VUE). [Internet]. PathologyOutlines.com, Inc; 2015 [updated 2015 Dec 19; cited 2018 July 1]. Available from: <http://www.pathologyoutlines.com/topic/placentavillitisunknown.html>
9. Feist H, Blöcker T, Hussein K. [Massive perivillous fibrin deposition, chronic histiocytic intervillitis and villitis of unknown etiology: Lesions of the placenta at the fetomaternal interface with risk of recurrence]. Pathologie. 2015;36:355-61.
10. Kovo M. Villitis of unknown etiology – prevalence and clinical associations. J Matern Fetal Neonatal Med. 2016;29:3110-4.
11. Redline RW, Heller D, Keating S, Kingdom J. Placental diagnostic criteria and clinical correlation--a workshop report. Placenta. 2005;26:114-7.
12. Boog G. Chronic villitis of unknown etiology. Eur J Obstet Gynecol Reprod Biol. 2008;1:9-15.
13. Georgiadis L, Keski-Nisula L, Harju M, Räisänen S, Georgiadis S, Hannila ML, et al. Umbilical cord length in singleton gestations: A Finnish population-based retrospective register study. Placenta. 2014;35:275-80.

14. Balkawade NU, Shinde MA. Study of length of umbilical cord and fetal outcome: A study of 1,000 deliveries. *J Obstet Gynecol India*. 2012;62:520-5.
15. Redline RW. The clinical implications of placental diagnoses. *Semin Perinatol*. 2015;39:2-8.
16. Boog G, Le Vaillant C, Alnoukari F, Jossic F, Barrier J, Muller J-Y, et al. Combining corticosteroid and aspirin for the prevention of recurrent villitis or intervillitis of unknown etiology. *J Gynecol Obs Biol Reprod*. 2006;35:396-404.

8. SUMMARY

Objectives: To investigate morphological characteristics of placentas with villitis of unknown etiology (VUE) and to compare them to normal term placentas without VUE, likewise, to compare placental morphological characteristics within the VUE group with regard to VUE grade.

Materials and Methods: This study included 50 placentas diagnosed with VUE and 50 normal term placentas without VUE. Data collection and placental examination was carried out at the University Hospital of Split. VUE was diagnosed based on histological examination of the placentas and graded into low grade VUE and high grade VUE. Following lesions due to maternal and fetal blood flow disturbances and fetal and maternal vascular malperfusion were noted together with placental site, umbilical cord insertion and length.

Statistical significance was tested using chi-square test, Student's t-test and Mann-Whitney test. Statistical significance was proved by the P value ≤ 0.05 .

Results: From 100 placentas, there was a statistically significant result among clinical findings VUE placentas ($n=50$) and the control group ($n=50$) concerning gestational age ($P<0.001$; $Z=5.209$) and birth weight ($P<0.001$; $t=6.044$). In 42.9% placentas with VUE presented with IUGR ($P<0.001$; $\chi^2=26.923$; $DF=1$). Gross morphological findings manifested significantly a thinner placental thickness in cm ($P<0.001$; $Z=4.795$) and a shorter umbilical cord length in cm ($P<0.001$; $t=5.103$) in VUE placentas compared to healthy term placentas. Pathohistological findings manifested a statistically significant difference among funiculitis ($P=0.003$; $\chi^2=8.609$; $DF=1$) and fetal thrombotic vasculopathy ($P=0.023$; $\chi^2=5.211$; $DF=1$). Secondly, no statistically significant result differentiating morphological characteristics regarding gross and pathohistological findings in between high grade VUE ($n=20$) and low grade VUE ($n=30$) was found.

Conclusions: On gross examination a thinner placental thickness and shorter umbilical cord length was found in placentas with VUE compared to healthy term placentas. On pathohistological exam funiculitis and fetal thrombotic vasculopathy implicate a finding of placentas in VUE. Secondly, there is no statistically significant result found among investigated placental findings in the VUE group regarding VUE grading.

9. CROATIAN SUMMARY

Naslov: MORFOLOŠKE KARAKTERISTIKE POSTELJICA S VILITISOM NEPOZNATE ETIOLOGIJE

Ciljevi: Istražiti morfološke karakteristike posteljica s vilitisom nepoznate etiologije (VUE) te dobivene rezultate usporediti s kontrolnom skupinom posteljica. Također, istražiti morfološke karakteristike u skupini VUE posteljica obzirom na histološki gradus vilitisa.

Materijali i metode: 50 posteljica s VUE i 50 posteljica iz urednih terminskih trudnoća bez VUE dijagnoze je uključeno u istraživanje. Podatci su prikupljeni na Klinika za ženske bolesti i porode i Klinički zavod za patologiju, citologiju i sudsku medicinu KBC Split. Dijagnoza VUE u posteljicama je postavljena na temelju histološkog pregleda istih, te je VUE gradiran kao VUE niskog gradusa i VUE visokoga gradusa. Sve lezije nastale kao posljedica poremećaja cirkulacije majke i djeteta te lezije koje su posljedica majčine vaskularne malperfuzije (MVM) i fetalne vaskularne malperfuzije (FVM) su zabilježene. Također su prikupljeni podatci o veličini posteljice, dužini i mjestu insercije pupčane vrpce kao i o majčinom i fetalnom upalnom odgovoru.

Results: Niža gestacijska dob ($P < 0,001$; $Z = 5,209$), niža porođajna težina ($P < 0,001$; $t = 6,044$), te starija dob majke ($P = 0,005$; $t = -2,889$) su bili učestaliji u posteljicama s VUE nego u posteljicama kontrolne skupine. 42,9% novorođenčadi u VUE skupini je imalo intrauterini zastoje rasta (IUGR), dok u kontrolnoj skupini nijedno novorođenče nije imalo IUGR ($P < 0,001$; $\chi^2 = 26,923$; $DF = 1$). VUE posteljice su bile tanje ($P < 0,001$; $Z = 4,795$) i imale su kraću pupčanu vrpču u usporedbi s posteljicama kontrolne skupine ($P < 0,001$; $t = 5,103$). Funikulitis ($P = 0,003$; $\chi^2 = 8,609$; $DF = 1$) i fetalna trombotična vaskulopatija (FTV) ($P = 0,023$; $\chi^2 = 5,211$; $DF = 1$) su bili učestaliji u VUE skupini nego u kontrolnoj skupini posteljica. Nije bilo statistički značajne razlike u morfološkim karakteristikama u VUE skupini posteljica obzirom na histološki gradus VUE.

Zaključak: VUE je učestao histološki nalaz posteljica trećeg tromjesečja. Naše istraživanje je pokazalo da posteljice s dijagnozom VUE imaju određene morfološke karakteristike kao i kliničke nalaze u smislu gestacijske dobi, porođajne težine te dobi majke koje su učestalije nego kod posteljica bez VUE. Kako bi se utvrdila točna povezanost navedenih razlika između VUE posteljica i posteljica kontrolne skupine potrebna su daljnja istraživanja.

10. CURRICULUM VITAE

Name Charlotte Narloch
Address Ekhofstraße 35, 22087 Hamburg
Date of Birth 11.06.1993
Place of Birth Hamburg, Germany
E-Mail charlotte.narloch@gmx.de

Education

2012- 2017 Medical Studies in English, University of Split School of Medicine
2012 High School Diploma (A-level), Sankt-Ansgar-Schule, Hamburg

Internships

2018 Pathology Department, University Hospital Hamburg
2018 General Surgery Department, Asklepios Nord, Hamburg
2016 Internal Medicine Department, Wilhelmsburger Hospital, Hamburg
2011 Neonatology, Asklepios Klinik Nord, Hamburg
2008 Nursing Internship, Michaelis Krankenhaus, Hamburg

University Involvement

2017-2018 Treasurer, International Student Association USSM, Split

Languages: English (C2), Croatian (A1)