

Incidence of nasal polyps at the Department of ear, nose and throat, head and neck surgery, University Hospital of Split between 2013-2018 : a retrospective study

Milin, Marija

Master's thesis / Diplomski rad

2018

Degree Grantor / Ustanova koja je dodijelila akademski / stručni stupanj: **University of Split, School of Medicine / Sveučilište u Splitu, Medicinski fakultet**

Permanent link / Trajna poveznica: <https://urn.nsk.hr/urn:nbn:hr:171:901956>

Rights / Prava: [In copyright](#)/[Zaštićeno autorskim pravom.](#)

Download date / Datum preuzimanja: **2024-11-29**



Repository / Repozitorij:

[MEFST Repository](#)



**UNIVERSITY OF SPLIT
SCHOOL OF MEDICINE**

Marija Milin

**INCIDENCE OF NASAL POLYPS AT THE DEPARTMENT OF EAR, NOSE AND THROAT,
HEAD AND NECK SURGERY,
UNIVERSITY HOSPITAL OF SPLIT BETWEEN 2013-2018; A RETROSPECTIVE STUDY**

Diploma Thesis

Academic year:

2017-2018.

Mentor:

Assist. Prof. Nikola Kolja Poljak, MD, PhD

Split, September 2018

**UNIVERSITY OF SPLIT
SCHOOL OF MEDICINE**

Marija Milin

**INCIDENCE OF NASAL POLYPS AT THE DEPARTMENT OF EAR, NOSE AND THROAT,
HEAD AND NECK SURGERY,
UNIVERSITY HOSPITAL OF SPLIT BETWEEN 2013-2018; A RETROSPECTIVE STUDY**

Diploma Thesis

Academic year:

2017-2018.

Mentor:

Assist. Prof. Nikola Kolja Poljak, MD, PhD

Split, September 2018

CONTENTS

1. INTRODUCTION.....	1
1.1 Nasal Anatomy	2
1.1.1. Skin-Soft Tissue Envelope.....	2
1.1.2. Nasal Bony Framework.....	3
1.1.3. Nasal Septum.....	4
1.1.4. Turbinates.....	4
1.1.5. Blood supply and sensory innervation.....	5
1.1.6. Paranasal Sinus.....	6
1.1.7. Osteomeatal Complex.....	7
1.2. Nasal Polyps.....	8
1.3. EPIDEMIOLOGY of Nasal Polyps	10
1.4. ETIOPATHOGENESIS of nasal polyposis	11
1.4.1. Inflammatory Pathway of Nose.....	11
1.5. Diagnosis.....	14
1.5.1. Differential diagnosis.....	16
1.6. Treatment.....	17
1.6.1. Medical treatment.....	19
1.6.2. Surgical Treatment.....	20
1.6.2.1. Intranasal polypectomy.....	20
1.6.2.2. Intranasal Ethmoidectomy.....	20
1.6.2.3. External Ethmoidectomy.....	20
1.6.2.4. Caldwell-Luc.....	21
1.6.2.5. Functional Endoscopic Sinus Surgery (FESS).....	21
2. OBJECTIVES OF RESEARCH.....	22
3. MATERIALS AND METHODS.....	24
3.1. Organization of the study.....	25
3.2. Place of the study	25
3.3. Methods of data collection and processing	26
3.4. Description of research	26
4. RESULTS.....	27
5. DISCUSSION.....	34
6. CONCLUSION.....	37
7. REFERENCES.....	39
8. SUMMARY.....	43
9. CROATIAN SUMMARY.....	45
10. CURRICULUM VITAE.....	47

ACKNOWLEDGEMENT

First and foremost of all, I would like to express my deepest gratitude to my family, friends and my mentor for their continuous support.

1. INTRODUCTION

Nasal Polyps (NP) are common benign noncancerous lesions that arise from the mucosa of the nasal or paranasal sinuses, usually at the outflow tract of sinuses, or from the cavity of the nasal mucosa (1,2). NP are usually associated with systemic diseases and characterized by nasal obstruction, rhinorrhoea, anosmia or loss of smell, post nasal drip, as well as headache and facial pain that leads to poor quality of life. NP can be bilateral or unilateral and in situations where NP are unilateral other possibilities, although not as common, such as benign and malignant pathologies as well as congenital nasal anomalies must be ruled out (1).

NP diagnosis and treatment can possess a challenge for the otolaryngologists due to its obscure and sometimes vague etiology and high rate of recurrence. Consensus in regards to what constitute a standard therapy is controversial and currently, there is no agreement on specific algorithm or approach. Hitherto, management of NP has been primarily based on medical treatment and focused on reducing symptoms and improving patients

forms the surface inside of the nasal cavity. Nasal cavity also has an abundant number of seromucinous gland (5,6).

1.1.2. Nasal Bony Framework

The framework of the nose is divided into three parts; the upper third which includes the osseous nasal vault made up by the nasal bones, the middle third defined by the upper lateral cartilage, and the lower third defined by the lower lateral cartilages. The osseous vault makes a pyramidal shaped structure and is composed of the paired nasal bones which attaches superiorly to the frontal bone and laterally to the frontal process of the maxilla. The principle support of the nose comes from the bone framework along with the bony septum. The caudal or free edge of the osseous vault comprises the superior portion of the pyriform aperture, (Figure 1), (5,6).

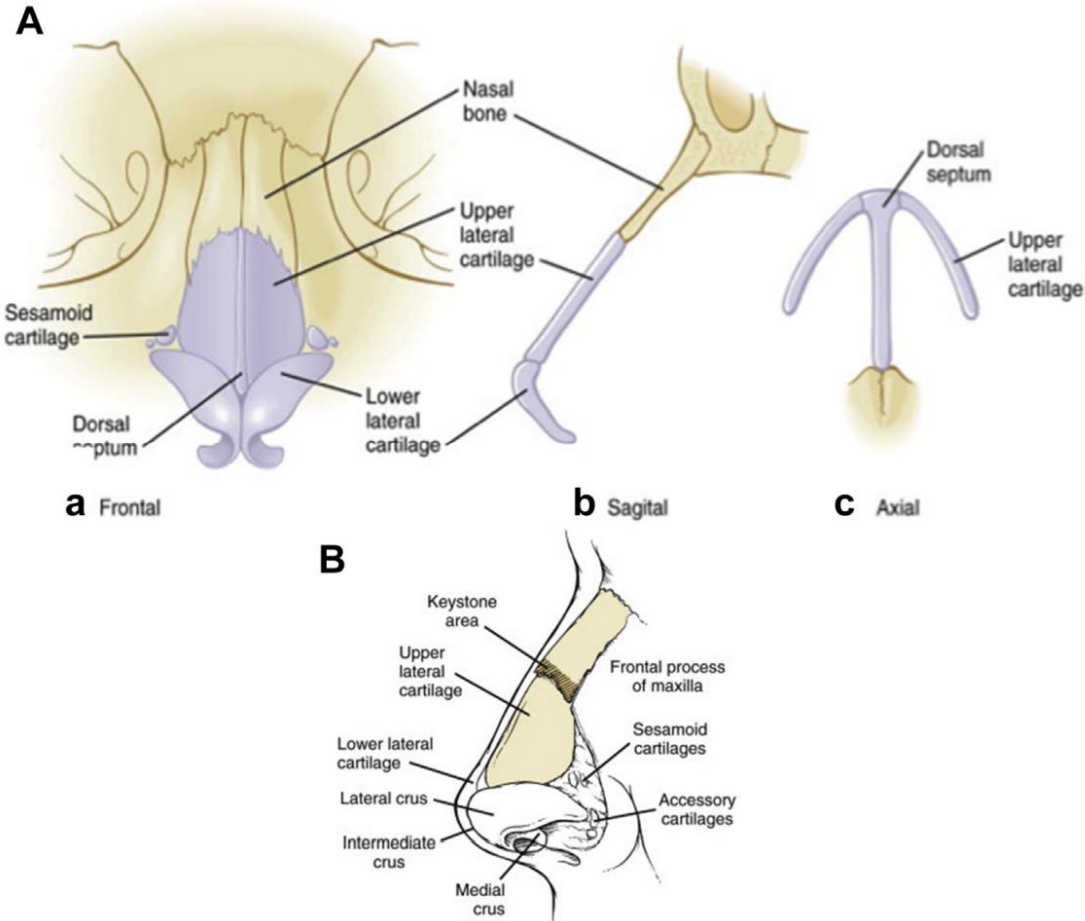


Figure 1. Showing anatomical landmarks where nasal bones and cartilage meet. Taken from: Hsu DW, Suh JD. Anatomy and Physiology of Nasal Obstruction, Otolaryngologic Clinic of North America 2018.

1.1.3. Nasal Septum

The nasal septum supports the structure of the nose and may be the cause of nasal obstruction if significant deformity occurs, which is very common, but usually asymptomatic. Birth trauma or micro-fractures early in life may also cause aberrant growth of the septum. The anatomy of the nasal septum is made of membranous, cartilaginous, and osseous component (from anterior to posterior). The membranous component of the septum consist of fibro-fatty tissue and situated between the quadrangular cartilage columella. Quadrangular cartilage is the primary constituent of septal cartilage. The posterior nasal septum is made from the perpendicular plate of ethmoid, the nasal crest of palatine and maxillary bones, and the vomer (5,8,9).

1.1.4. Turbinates

Lateral nasal wall has three paired nasal turbinates with their respective meati. The ethmoid bone gives rise to the superior and middle turbinates, and the inferior turbinates are made of a separate bony structure. The turbinates are thin bones with muco-periosteum surface. The inferior turbinate

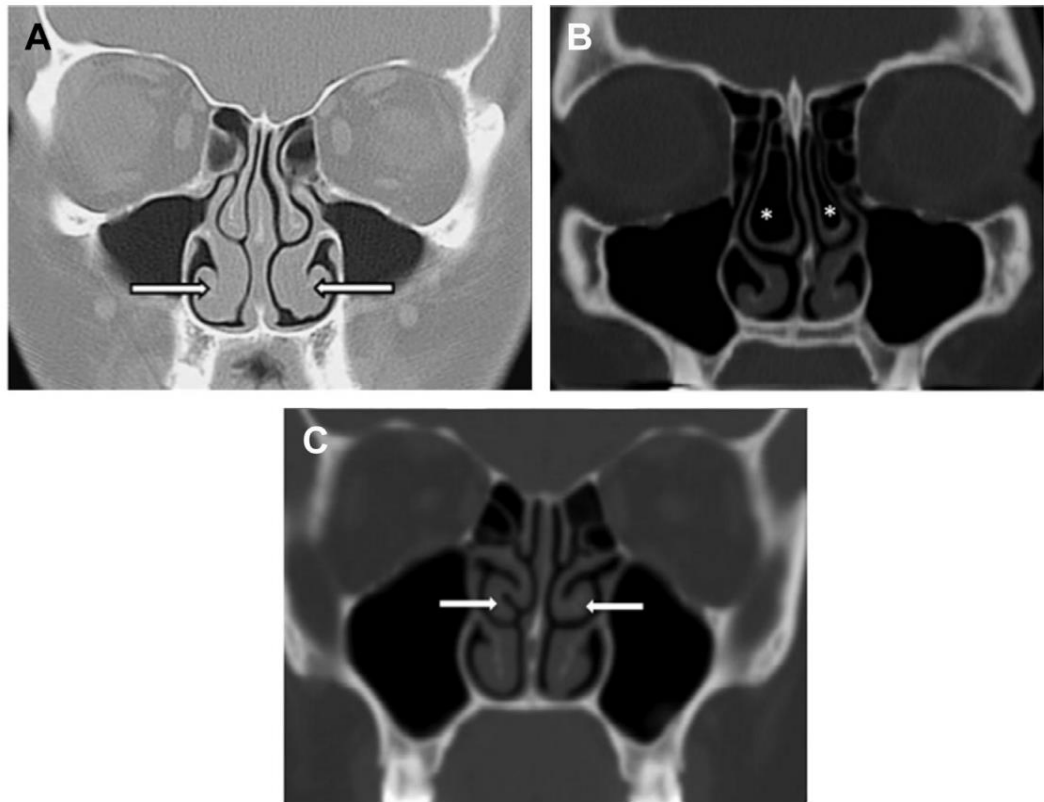


Figure 2. (A) Coronal computed tomography (CT) showing bilateral inferior turbinate with mostly soft tissue hypertrophy (white arrows). (B) Coronal CT showing bilateral concha bullosa (white asterisks). (C) Coronal CT showing bilateral paradoxical middle turbinate (white arrows). Taken from: Hsu DW, Suh JD. *Anatomy and Physiology of Nasal Obstruction*, Otolaryngologic Clinic of North America 2018.

1.1.5. Blood supply and sensory innervation

The nasal cavity receives its rich blood supply from the terminal branches of the external and internal carotid arteries (Fig. 3A). Facial artery, which is the terminal branch of external carotid artery, gives off the small superior labial artery to supply the anterior nasal septum, and the internal maxillary artery, coursing within the pterygopalatine fossa to give the main blood supply to the nasal cavity. The internal maxillary artery gives off the sphenopalatine, descending palatine, and infraorbital arteries. Conchal and septal branches arise from the sphenopalatine artery. The descending palatine artery, after passing the greater palatine canal, becomes the greater palatine artery and enters the nose through the incisive foramen and supplies the anterior inferior septum. The anterior and posterior ethmoid branches of the ophthalmic artery which are terminal branches of the carotid artery supply the

septum and found along the base of the skull. The terminal branches of internal and external carotid arteries anastomose to form Kiesselbach area (Fig. 3B) (11).

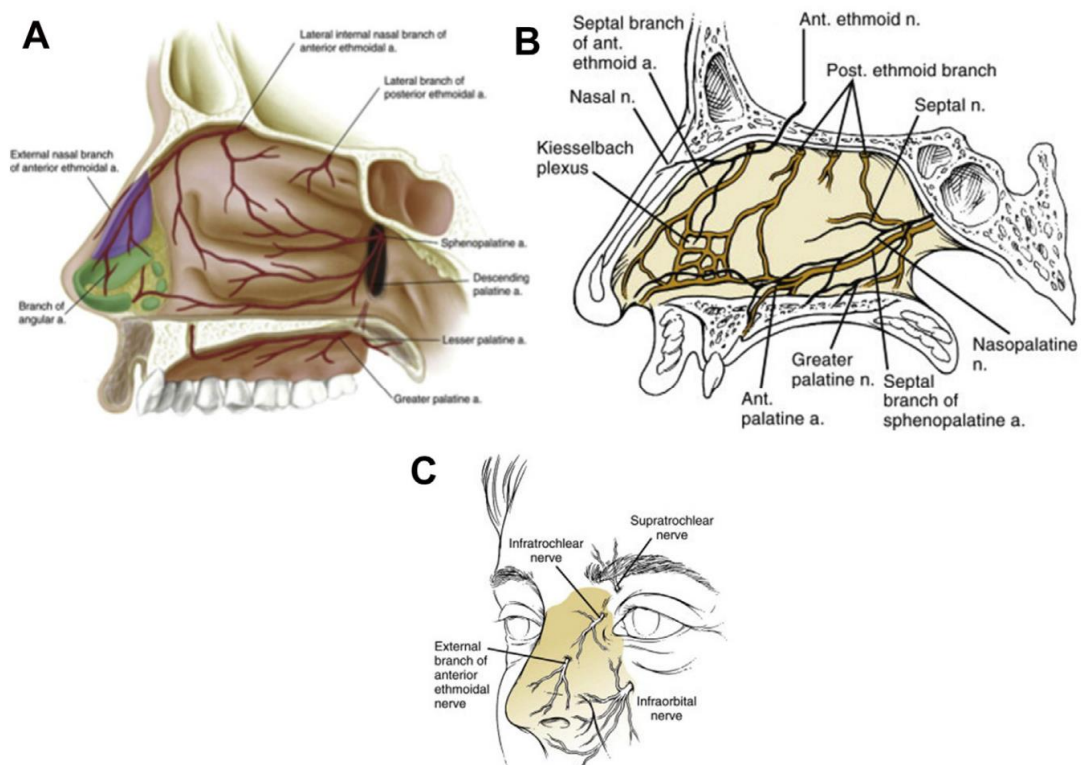


Figure 3. (A) Nasal cavity blood supply. (B) Internal nasal cavity sensory innervation and vasculature. (C) External nasal sensory innervation. Taken from: Hsu DW, Suh JD. *Anatomy and Physiology of Nasal Obstruction*, Otolaryngologic Clinic of North America 2018.

Terminal branches of the first two divisions of the trigeminal nerve - the ophthalmic (V1) and maxillary (V2) nerves innervate the nose. These fibers provide sensation of pain, temperature and touch. Superior lateral nasal wall is innervated by the anterior and posterior ethmoid nerves (V1). The posterior nasal cavity and lateral nasal wall is supplied by the sphenopalatine ganglion (V2). V1 and V2 branches of the internal nasal cavity provide the septum. Autonomic nervous system in the nasal cavity is responsible for level of congestion, vasculature tone and production of secretions. Cranial nerve I (special sensory branches) at the cribriform plate provide olfaction (12).

1.1.6. Paranasal Sinus

The paranasal sinuses (ethmoid, frontal, maxillary and sphenoid) are air filled spaces located within the bones of the skull and form developmentally through excavation of bone by pneumatic diverticula from the nasal cavity (figure 4). They also protect the facial bones and serve as a crumple zone to protect the more vital structures in the event of facial trauma.

These sinuses are joined to the nasal cavity via small orifices called ostia. Inflammation, or swelling in the nasal lining that occurs with a cold can easily block these openings, leading to disruption of normal drainage of mucus within the sinuses and can lead to sinusitis (13).

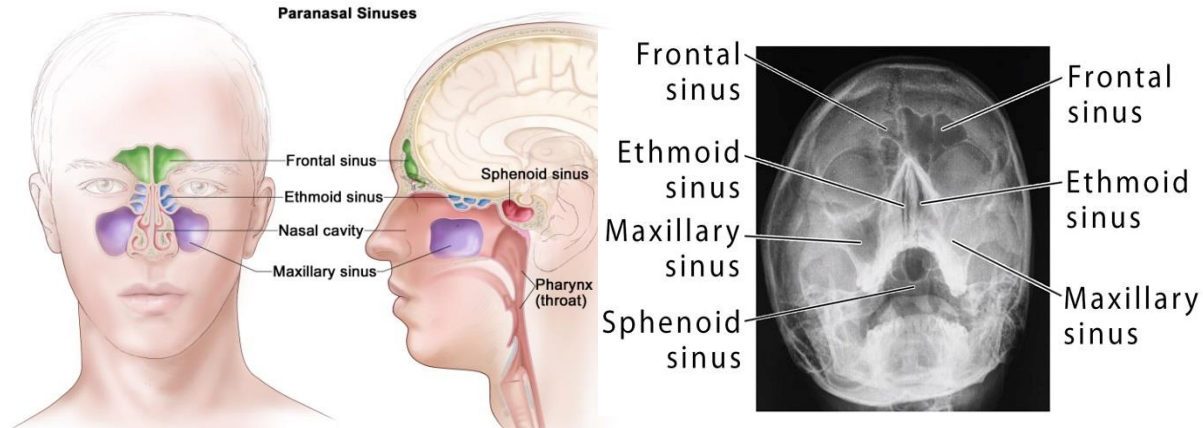


Figure 4. Paranasal sinuses. Image on the right shows paranasal sinuses with x-ray. Taken from: Reddy UDMA, Dev B. Pictorial essay: Anatomical variations of paranasal sinuses on multidetector computed tomography-How does it help FESS surgeons? The Indian Journal of Radiology & Imaging Sciences 2012;22(4):317-24.

1.1.7. Osteomeatal Complex

The osteomeatal unit (OMU) includes the maxillary sinus ostium, ethmoid infundibulum, frontal recess and the anterior ethmoid air cells. The OMU (Figure 5) is the key factor in the pathogenesis of chronic sinusitis. The ethmoid sinus is the key sinus in the drainage of the anterior sinuses. Extreme care is needed during surgery to avoid trauma to the OMU due to its close relationship with the orbit and the anterior skull base (13).

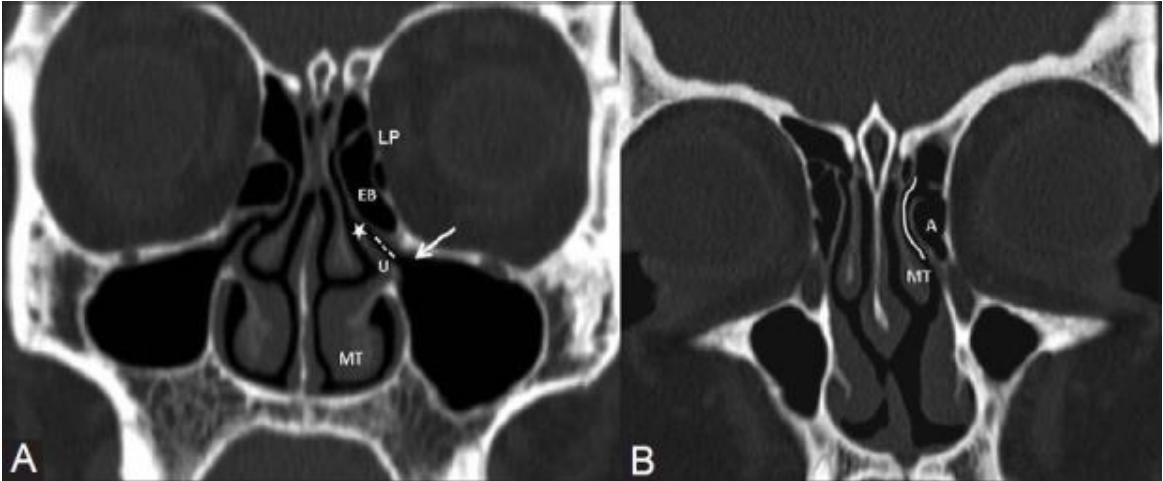


Figure 5. Coronal CT scan. (A) Shows the osteomeatal complex which consists of the following structures: infundibulum (dotted line), hiatus semilunaris (asterisk), maxillary ostium (arrow) and the ethmoidal bulla (EB). Middle turbinate (MT), Lamina papyracea (LP). (B) Shows agger nasi cell (A) which are inferior and lateral to the nasofrontal recess (solid white curved line). The middle turbinate (MT) forms the medial relationship of the recess. Taken from: Reddy UDMA, Dev B. Pictorial essay: Anatomical variations of paranasal sinuses on multidetector computed tomography-How does it help FESS surgeons? The Indian Journal of Radiology & Imaging Sciences 2012;22(4):317-24.

1.2. NASAL POLYPS

NP originate from any part of the nasal mucosa or paranasal sinuses and are an end result of different disease processes in the nasal cavities. Patients with chronic sinusitis, allergic rhinitis, and cystic fibrosis (CF) can develop multiple polyps. Single polyps could be an antralchoanal polyp, a benign polyp, or any benign or malignant tumor such as encephaloceles, gliomas, haemangiomas, juvenile nasopharyngeal angiofibromas, papillomas, lymphoma, sarcoma, chordoma, or nasopharyngeal carcinoma. All children with benign multiple nasal polyps must be evaluated for CF and asthma (1).

There are two primary types of NP: ethmoidal which arises from the ethmoid sinuses and antrochoanal which usually arise in the maxillary sinus. The paranasal sinuses, have several functions including; reducing weight of the head, air humidification and aiding in voice resonance, and consist of four air filled spaces. Total agenesis of paranasal sinuses are rare (Figure 6) , however, isolated frontal sinus agenesis can occur (14).

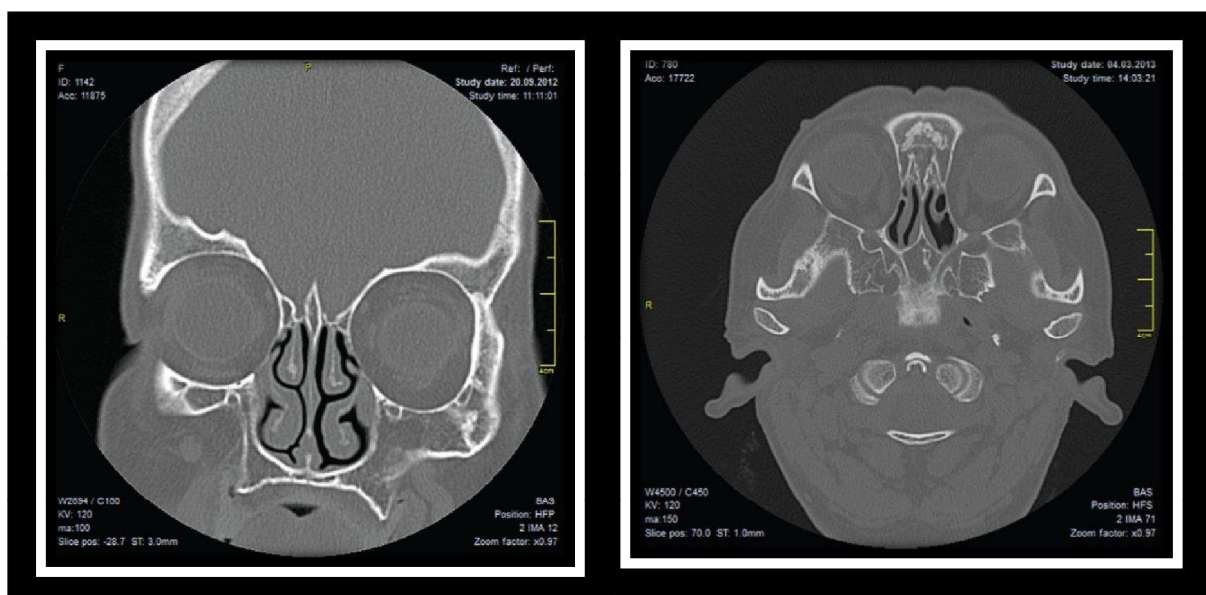


Figure 6. CT scans showing total agenesis of all paranasal sinuses with normal appearing nasal septum and conchae. Taken from: Korkmaz H, Korkmaz M. Total aplasia of the paranasal sinuses.. *Allergy & rhinology* 2013;4(2):e105-9.

NP that extend to the choana, are referred as choanal polyps, constituting roughly 3-6% of all nasal polyps. There are three main types of nasal choanal polyps (sphenchoanal, antrochoanal, and ethmoido-choanal polyps), which exhibit very similar symptoms. The rarest of the three is sphenchoanal polyps, while most frequent is antrochonal polyps originating from the inflamed sinus mucosa. The sphenchoanal polyps having an unclear etiology, is most frequent in adolescents and young adult and can occur concomitantly with other NP (Table-1). It is uncommon to see isolated sphenoid sinus pathology. NP symptoms are the same (nasal obstruction, nasal discharge, and frequent headaches). Anterior rhinoscopy can detect NP, whereas sphenchoanal polyps

1.3. EPIDEMIOLOGY OF NASAL POLYPS

The prevalence of NP widely varies globally and estimated to be around 1-4% in western populations, however, in autopsy studies it has been shown to be almost 40%. The usual presenting age for NP in adults is between the ages of 20 and 60 years. NP in children under 10 years of age may indicate other pathologies such as cystic fibrosis or asthma. In fact, NP without other pathologies is rare.

Frequency of NP varies in different diseases, reaching 85% in allergic fungal sinusitis. Churg-Strauss syndrome (asthma, fever, eosinophilia vasculitis, and granuloma) is associated with 50% of NP cases, while in patients with cystic fibrosis there is 20% frequency of NP. It is quite common in patients with asthma (adult, intrinsic, atopic, childhood), with chronic rhinosinusitis, allergic and nonallergic rhinitis. Aspirin intolerance has a high frequency of NP, 36%, (19). NP has a male predominance, with a ratio of 2-4:1. The frequency of NP increases with age, peaking at 50 years of age and older. In children, it is extremely low (about 0.1 %), (19,20).

Individuals affected by chronic rhinosinusitis (CRS) (with or without NP) can have significantly poor quality of life,

1.4. ETIOPATHOGENESIS OF NASAL POLYPOSIS

1.4.1. Inflammatory Pathway of Nose

Nasal immune system is imperative in identifying and combating inhaled particles such as allergens, toxins, and microbes. Innate and adaptive immunity mediate a complex immune response. Innate immunity is the first-line nonspecific defense against foreign pathogens. This response consists of neutrophils, monocytes, mast cells, dendritic cells, and eosinophils. These immune cells act collectively to eliminate infection through the activation of a cascade of complement system, natural killer cells, and toll-like receptor (TLR) pathways. The adaptive immune response is more specific and acts to combat pathogens through immunoglobulin and T-cells. Allergens play a vital role in the pathogenesis of aberrant and chronic inflammatory responses in the nose, which can manifest as acute and/or chronic rhinosinusitis with nasal polyps. Immunoglobulin E (IgE) hypersensitivity (type I hypersensitivity) response is initiated by allergens. Mast cell degranulation and releases of histamine and proteases as part of early response causes vasodilation and glandular stimulation. Cytokine-mediated influx of eosinophils and activation of TH2 cells constitute a late response. Nasal congestion and rhinorrhea occurs as a result (22).

The exact pathogenesis of nasal polyposis is uncertain. Chronic inflammation, autonomic dysfunction and genetic predisposition are linked to polyp development. Most literature consider polyps the end result of chronic inflammation and thus conditions that lead to chronic inflammation in the nasal cavity can lead to polyp formation. It is mostly believed that polyps are strongly associated with non-allergic than allergic diseases. More than 13% of non-allergic asthma patients have nasal polyps compare to 5% in allergic asthma patients. Some researchers believe NP to be exvagination of nasal or sinus mucosa others class them as distinct entities (23,24).

CRS is a common condition (10.9% of European adult population is estimated to be affected), and more than 2.7% of some population have reported NP with CRS. Four cardinal symptoms of CRS are nasal obstruction, post nasal drip, anosmia and facial pain that lasts at

least three months. Many patients with CRS present with hyperplastic inflammatory growth of the nasal polyps in their nasal airways (25). CRS with NP (CRSwNP) is more prevalent in male than female (ratio 1.3 to 12.2) and incidence peaks between the ages of 45-65 (26,27).

Aspirin-exacerbated respiratory disease (AERD) also known as Samter

function of epithelial layer is to form tight junctions between cells to create a physical barrier between the airway lumen and the underlying submucosal tissue. It is widely accepted that defects in the airway epithelial barrier function are responsible for chronic airway diseases such as asthma (24,33).

Sinonasal epithelial barrier damage in CRSwNP patients has also been observed such as diminished expression of tight junction proteins with increased epithelial permeability. Type 2 cytokines, such as IL-4 and IL-13, and pro-inflammatory cytokines, such as oncostatin M (OSM), seen to play a role in decreasing function of tight junction and increasing epithelial permeability. These defects in barrier function may play a critical role in the pathogenesis of CRSwNP by letting in foreign antigens into the submucosa and triggering inflammatory response, as has been shown in patients with asthma. Production of mucus and motility of cilia, which is essential for prevention of interaction of luminal antigens and pathogenic organisms with underlying tissue, is also defective in CRSwNP. Inadequate clearance of foreign antigens contribute to development of inflammation (23,33,34).

Some of the molecules that are altered in CRSwNP, and may cause dysfunction in the formation of nasal lining fluid, include Pendrin, periostin and PLUNC family member molecules are important in formation of nasal lining fluids and are altered in CRSwNP. Carriers of one mutated CFTR gene that do not have CF, are high risk of developing CRSwNP, further supporting the idea that the components of the nasal lining fluid is disturbed in CRS. The epithelial cells in the airways also have inducible innate immune function that are responsible for recognizing pathogens, and activating immune cells. Pattern recognition receptors (PRRs), such as toll-like receptors (TLRs), are responsible for pathogens recognition and initiate downstream immune responses, are expressed by the airways. Evidence in regards to TLR defect in the pathogenesis of NP or CRS are conflicting, some suggests TLR are increased and thus lead to unnecessary inflammatory response while others TLR level is decreased and the disease fail to control the pathogenic organism (35,36).

In NP formation and CRS, level of various cytokines and chemokines have been reported to be altered. Chemokines are important protein molecules for the attraction of neutrophils, eosinophils, macrophages, dendritic cells, T and B cells. Eotaxin 1 (CCL11), eotaxins 2 (CCL24) and 3 (CCL26), are the main CCR3 activating chemokines that is responsible for recruitment of eosinophils, which is highly elevated in NP. Moreover, NP derived fibroblasts or airway epithelial cells express CCL11 which is increased by the

combination of IL-4, or IL-13, and TNF in vitro which indicates that there might be a positive feedback loop for eosinophil accumulation that is further increased in a pro-inflammatory type-2 inflammatory domain (37-39).

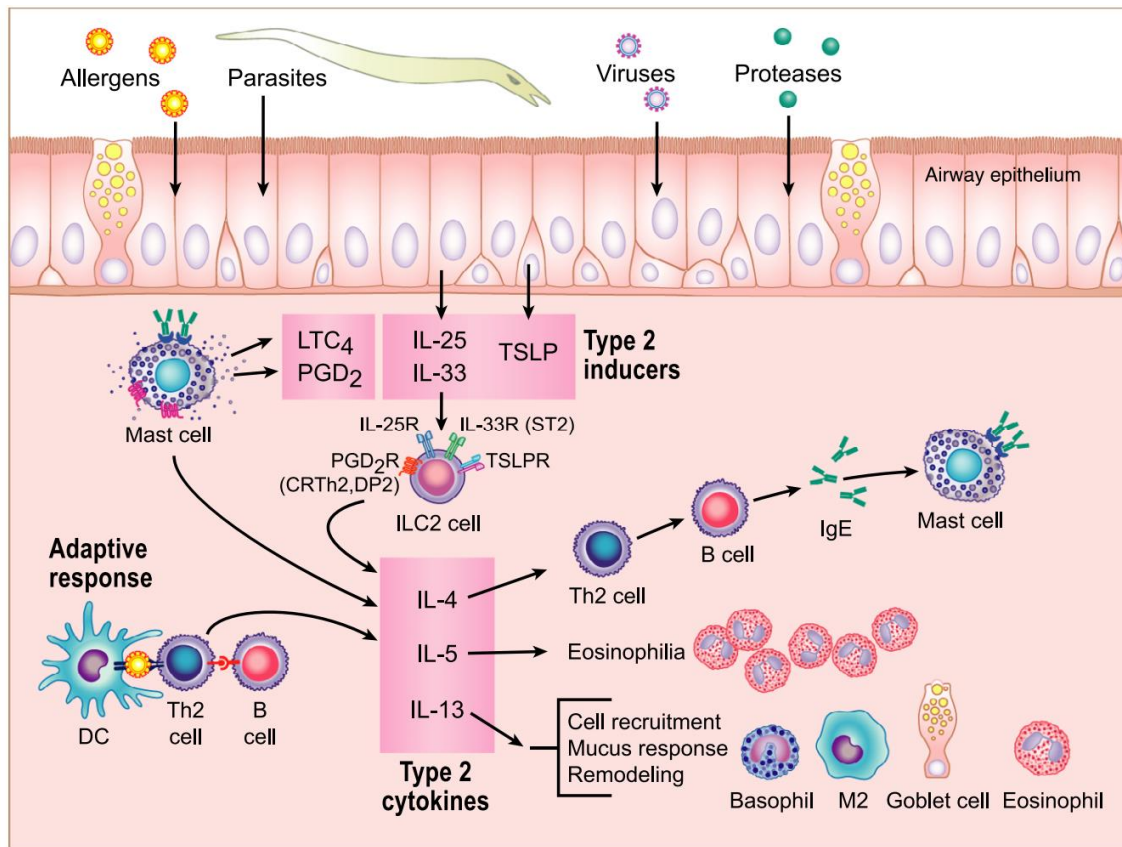


Figure 7. Role of type-2 inflammation in the mediation of CRS and NP formation. Type 2 cytokines are derived from Th2 which are activated by antigen-presenting cells (APC), including Dendritic Cells, B cells and others. IL-4, IL-5 and IL-13 drive the recruitment and activation of mast cells, eosinophils, basophils, goblet cells, M2 macrophages, and B cells. Taken from: Hulse KE, Stevens WW, Tan BK, Schleimer RP. Pathogenesis of nasal polyposis. *Clinical and experimental allergy*.: Journal of the British Society for Allergy and Clinical Immunology 2015;45(2):328-46.

1.5. DIAGNOSIS

The evaluation of NP begins with a detailed personal history. Nasal obstruction is the most common symptom, which depends on the size of the NP. Rhinorrhea, postnasal drainage, anosmia or hyposmia, headache, facial pain, changes in quality of the voice and sense of taste are other frequent symptoms. Benign multiple polyps almost never cause epistaxis and if present may suggest a more serious nasal cavity lesion. Polyps may block the outflow tract of the sinuses and cause chronic or recurrent acute sinusitis.

NP can be single or multiple, bilateral, mobile, smooth and semi-translucent polypoid masses in the nasal cavity, which can be seen in physical examination and anterior rhinoscopy. Middle meatus is the most frequent site for NP but can also occur in the mucosa of the ostia, anterior and posterior ethmoidal clefts, as well as the frontal and sphenoidal recesses. Nasal endoscopic examination provides excellent visualization of the polyps in the middle meatus. Endoscopic visualization of the polyps and adjacent regions of the nasal and sinus cavities is absolutely necessary for an accurate diagnosis and staging of the disease. Lildhodt

1.5.1. Differential diagnosis

Patients with unilateral NP must undergo further tests to rule out other clinical pathologies (Table 4). Similarities of benign and malignant disorders presentation should be kept in mind and must not delay the diagnosis of malignancy. NP symptoms unresponsive to medical treatment, orbital symptoms, epistaxis, severe and unilateral frontal headache, focal neurological signs must alert the physicians of other more distinct diseases (2).

Table 4. Differential diagnosis of nasal polyposis

Children
Turbinate hypertrophy
Congenital
Nasolacrimal duct cysts
Nasal gliomas
Encephaloceles
Tumors
Juvenile nasopharyngeal angiofibroma (JNA)
Rhabdomyosarcoma
Hemangioma
Chordoma
Adults
Inverted Papilloma
Tumors
Squamous cell carcinoma
Nasal lymphomas
Nasal melanoma
Esthesioneuroblastoma
Hemangiopericytoma

1.6. TREATMENT

Management of NPs involves combination of observation, medical, and surgical, or both medical and surgical therapy, depending on individual case assessment. The treatments aim to eliminate and reduce the size of the NP, thus, improving sinus drainage, relief of nasal obstruction and restoration of olfaction and taste (20). Topical or systemic steroid regimens, nasal saline lavage and allergen immunotherapy are used as part of medical therapy. Current guidelines (Figure 8) recommend benign NP should be initially treated conservatively, as surgery may not be necessary in many patients. Surgery should only be attempted if medical therapy fails to control symptoms and also to remove the fungal debris if Allergic Fungal sinusitis exists. Surgery can also help to prevent the complications in cases with erosion of the lamina papyracea and the skull base. Surgery is not utterly curative and usually long term medical therapy is required, because NP cannot be excised completely. Recurrence rate is high, in particular, in asthmatic patients (40,41).

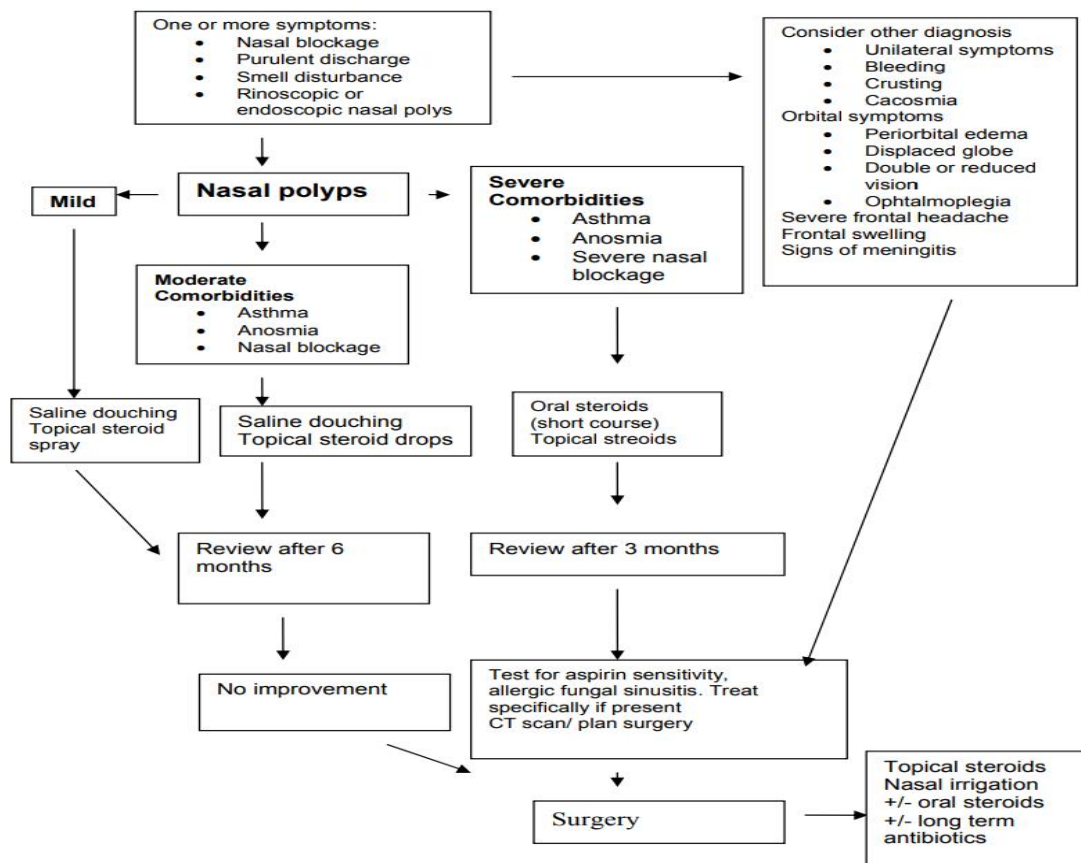


Figure 8. Management of chronic rhinitis with nasal polyps (1). Taken from: Cingi C, Demirbas D, Ural A. Nasal polyposis: an overview of differential diagnosis and treatment. Recent patents on inflammation & allergy drug discovery. 2011;5(3):241-52.

1.6.1. Medical treatment

Medical treatment approach should be based on individual bases. Treatment options consists of topical and systemic steroids, nasal lavage, antibiotic therapy, antifungal therapy, antileukotrienes, antihistamines, as well as aspirin desensitization. Currently, intranasal glucocorticoids (GC) is the best treatment of NP. Steroids are able to decrease polyp size, improve nasal airway patency, improve rhinorrhoea, and nasal blockage. Steroids constitute an imperative part of post-op therapy and delay the recurrence of polyps after surgery. GC have excellent anti-inflammatory property and exert their effect by reducing secretion of chemotactic cytokines, inhibiting the activity of T-cells and eosinophils (42,43).

Non-steroidal treatment includes: antibiotic, antifungal, antihistaminic, antileukotrienes and saline nasal irrigation. Antibiotic therapy is used if chronic or recurrent acute sinusitis, due to sinus obstruction, occurs and should be directed against *Staphylococcus*, *Streptococcus*, species and anaerobes as well as *Pseudomonas aeruginosa* (common in CF). Macrolides use exert anti-inflammatory rather than anti-microbial effect, inhibit expression of adhesion molecules, which are involved in inflammatory cells recruitment, and diminish IL-8 in nasal lavage and decrease the size of NP. Fungi and their spores are part of inspired air and is commonly present in the nose. Some studies suggested fungi to be the cause of chronic sinusitis and NP (allergic fungal sinusitis). Lund-Mackay staging is used to measure diseases severity. Aggressive surgical procedure is required in cases of perceived fungal invasion (44,45).

Antihistamines are not the first choice in NP but can be used for seasonal allergy or when there is exposure to and allergen (46). Antileukotrienes have shown significant efficacy, particularly with the use of zafirlukast and zileuton, in reducing symptoms NP symptoms (47). Aspirin desensitization therapy is shown to reduce symptoms in NP patients with AERD and also improvement in olfaction, reduction in sinus infection and asthma exacerbation and decreased sinus and polyp operations were reported (48). Baudoin *et al.* reported reduction in massive polyposis after five days of increasing dose of topical capsaicin but its unpleasant burning sensation is limiting its use (49). In NP patients with aspirin intolerance, topical administration of lysine acetylsalicylate (LAS) is reported to be effective, in particular those with the Samter

1.6.2. Surgical Treatment

Primarily, conservative medical therapy with steroids is the preferred choice, but due to the side effects of steroids and high recurrence rate, surgery is often necessary. For complicated cases, persistent infections, and unilateral NP surgery is the mainstay treatment. Surgery significantly reduces the size of NP, improves sinus drainage and can restore olfaction and taste. Asthmatic patients, in particular, tend to benefit more from surgical excision of polyps. Surgical techniques have been significantly improved over the years and FESS has become the main method for NP excision (51).

1.6.2.1. Intranasal polypectomy

Nasal polypectomy is indicated for uncontrolled symptoms and those that failed optimum medical therapy. After development of endoscope, this procedure has become safe and mortality is very rare nowadays. It is performed using forceps and by cutting or avulsion of the polyps (52).

1.6.2.2. Intranasal Ethmoidectomy

Intranasal ethmoidectomy historically had high mortality due to poor visualisation of the anteriori cranial fossa during surgery. Current ethmoidectomies are carried out under endoscopic approach and middle turbinate is totally excised to provide exposure to the ethmoids. Most surgeon no longer perform this surgery due to the risk of damage to the orbit and or base of the skull (53).

1.6.2.3. External Ethmoidectomy

External ethmoidectomy is performed under general anaesthesia and an incision is made between the medial canthus and the midline of the nose. The surgeon then lifts the periosteum posteriorly into the orbit until the anterior ethmoidal artery is identified. In the posterior ethmoids the skull base is identified. Limits of the dissection is guided by the basal lamella. Any diseased mucosa, polyps, or tumours should be removed, once the ethmoids are opened. Then the orbit is displaced laterally and all ethmoid cells are removed (53).

1.6.2.4. Caldwell-Luc

In Caldwell-Luc method an incision is made in the gingivobuccal sulcus, above the canine fossa, and extended through the periosteum over the maxilla. Then the periosteum is lifted superiorly and the infraorbital nerve is identified. Using osteotome, an outline window is made in the maxillary antrum. The window can be enlarged using a drill if required. Care must be taken to avoid injury to the secondary dentition and the infraorbital nerve. The Caldwell-Luc is used in polypoid disease, fungal sinusitis, antrochoanal polyps, and benign tumors (53).

1.6.2.5. Functional Endoscopic Sinus Surgery (FESS)

FESS is the cornerstone of modern surgical treatment for NP. It is a minimally invasive technique, which uses an endoscope and its advantages over surgery without an endoscope includes: a better view of the surgical field, precise and thorough clearance of inflamed tissue, far less complications and, lower recurrence rates (54).

Two approaches are common in FESS. Messerklinger technique (front to back) begins with visualization with a zero-degree (0°) endoscope. The procedure includes: uncinectomy, removal of the ethmoid bulla, exposure of the frontal sinus ostium, and identification of the roof of the ethmoid. After identifying the skull base, the dissection continues posteriorly and anterior ethmoid cells and the posterior ethmoid cells are removed, and finally sphenoid sinus is opened. With a 30-degree telescope, the ostium of the maxillary sinus is identified. In Wigand technique (back to front), the sphenoid sinus is identified first. The skull base and lateral wall is used as landmarks, then the ethmoid sinuses are cleaned from posterior-anteriorly. Giving an early exposure to the skull base, which is a major advantage of this procedure (2,55).

The microdebrider enables accurate removal of NP whilst preserving normal anatomical structures and also functions as suction and keeps the surgical field clear. Microdebrider reduces the blood loss and improve the visualization with a rapid removal of polyps. Serious complications of ESS are rare but the patient must be counseled preoperatively about the potential risks such as loss of vision, damage to the internal carotid artery, and cerebrospinal fluid leakage after inadvertent trauma to the skull base (1,2).

2. OBJECTIVES OF RESEARCH

The aims of this study are to establish the demographic and characteristics of patients operated by the FESS method due to nasal polyposis. The objectives of the study are to determine what age group of patients mostly underwent NP surgery, which gender undergoes FESS method more and in which season of the year the most surgical procedures take place and to compare them with other relevant studies.

Hypothesis: the FESS method is an effective method of treating nasal polyposis with excellent healing results and a low complication rate. The method meets criteria for minimally invasive ENT surgery.

3. MATERIALS AND METHODS

Inclusion criteria:

1. Patients of both genders, any age group, with nasal polyposis treated by the FESS method
2. Patients operated in University Hospital of Split by a specialist in otolaryngologist surgery
3. Patients treated by the FESS method in the period from January 2013 to January 2018.

Exclusion criteria:

1. Patients with nasal polyposis treated surgically with another method than ESS method
2. Patients operated in another institution
3. Patients with incomplete data

3.1. Organization of the study

Historical retrospective study. Research is a quantitative research according to the organization, while intervention and processing of the data are descriptive, ie descriptive type. All patients were treated with FESS method for nasal polyposis at the Department of ENT, head and neck surgery of the University Hospital of Split in the period from January 2013 to January 2018.

3.2. Place of the study

The research was conducted at the Department of ENT, head and neck surgery of the University Hospital of Split.

3.3. Methods of data collection and processing

Data was collected by research of the written protocol of the Department of ENT, head and neck surgery, University Hospital of Split, and the archive of the history of the disease. Collected 371 patient data and were analyzed using Microsoft Word Processing Software, version 14 (Microsoft Word Software, Redmond, Washington, USA), Microsoft Excel, version 14 (Microsoft Excel Software, Redmond, Washington, USA) and the statistical software MedCalc for Windows, version 14.8.1 (MedCalc Software, Mariakerke, Belgium) for table presentation.

3.4. Description of research

All 371 patients underwent surgical procedure in the period from 1st January 2013 to 1st January 2018 due to nasal polyposis and the FESS method was used.

Surgery implied removal of polyps through nostrils with the help of nasal endoscope. The FESS method enlarges the drainage pathways of the sinuses and fixes any other issues interfering with drainage, thus preventing any further build-up of mucus. The following parameters were analyzed for each subject: age, gender, season and the year of the surgical procedure.

Statistical analysis was done by the statistical software MedCalc for Windows, version 14.8.1. (MedCalc Software, Mariakerke, Belgium), using chi-squared-test. Statistical significance was set at $p < 0.05$.

4. RESULTS

In the selected study period (2013

Table 5. Number of subjects from each year

Year	No. of Subjects
2013	101 (27.2)
2014	75 (20.2)
2015	56 (15.1)
2016	76 (20.5)
2017	63 (17.0)

Among the 371 patients with nasal polyps who underwent the FESS operative procedure, 121 were female (32.6%) and 250 were male (67.4%). The average age of the patients with nasal polyps included in the study was 54 years old, with a range of 12 to 77 years old. In respect to age, nasal polyps were most common in the fifth decade of life. Most of the ESS operative procedures occurred in the spring, followed by winter and summer, and it was rarest in the fall. Most of the patients were operated in 2013.

Figure 8 shows the distribution of patients by gender. Out of a total of 371 patients treated with the FESS method for nasal polyposis, there were 121 female, which makes up 32.6% and 250 male, which is 67.4% (approximate 2:1 male to female). This relationship is valid overall, with variations of the year-to-year ratio.

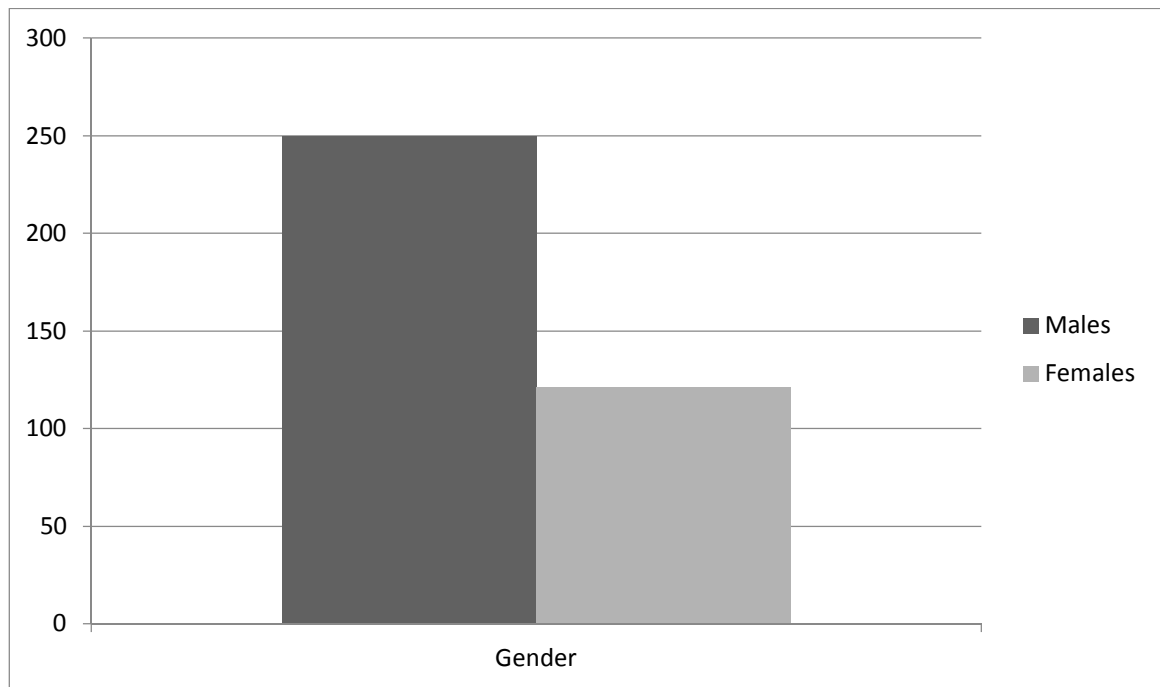


Figure 8. Gender distribution of the patient sample (n= 371).

Figure 9 shows the age distribution of the patient sample. The 371 patients treated with FESS method due to nasal polyposis were between 12 and 77 years of age. Median age of the sample was 54 (95 CI 52-56) years. Female median age was 52 (47-55), and the male median age was 54 (52-57).

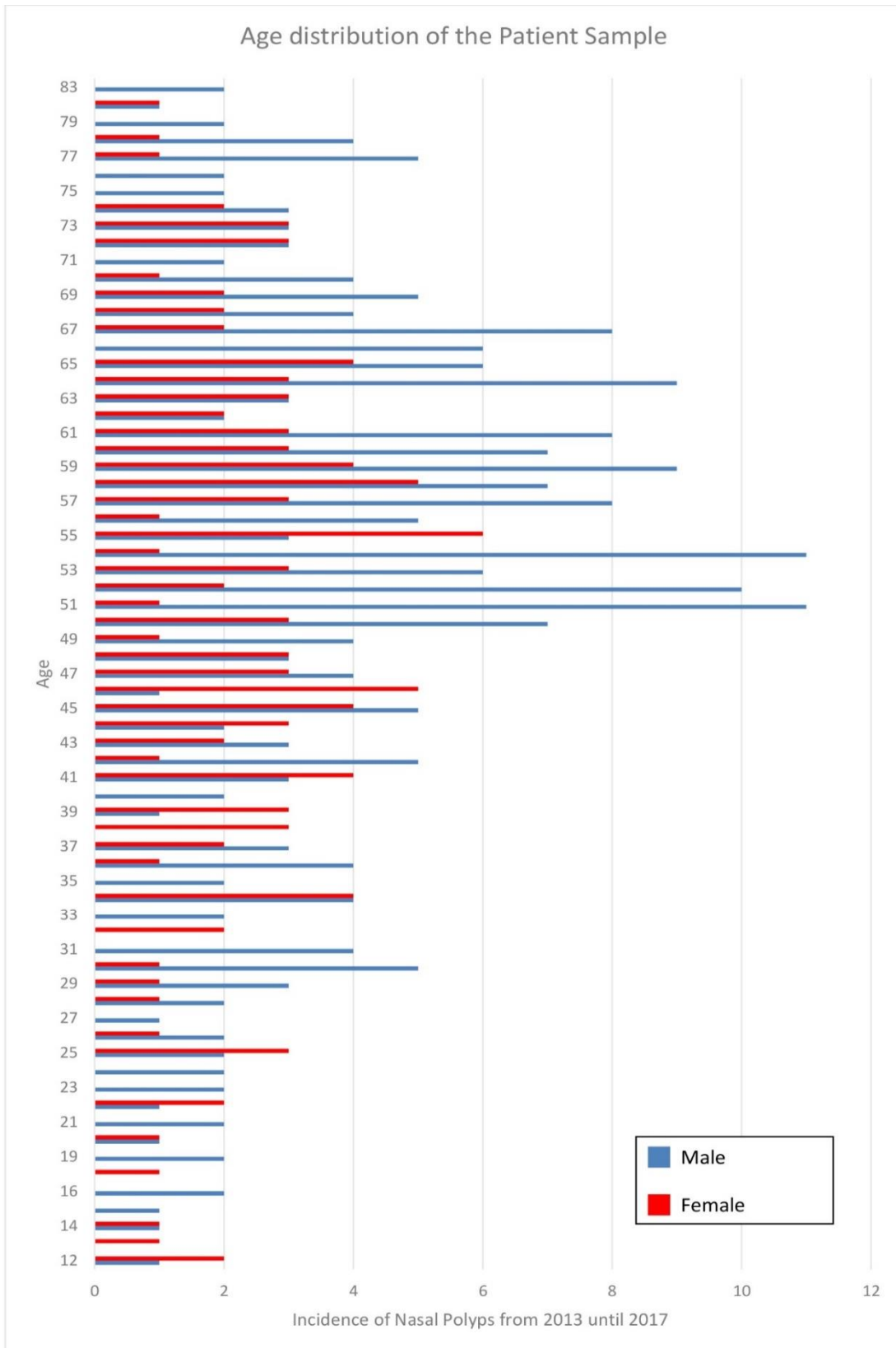


Figure 9. Age distribution of the patient sample (n= 371).

Figure 10 shows distribution of patients by the season of the year. Out of total 371 patients, 77 male were operated in winter (30.8%), making it the season with the most male patients being operated. For females, spring was the season when 42 of them were operated, making it the highest season distribution of the female patient sample (34.7%). Overall, spring season had the highest incidence of FESS operative procedure with total of 118 (31.8%) patients, followed by winter 102 (27.5%). The number of ESS procedure decreased in fall, with 81 (21.8%) patients, and the lowest number of patients were operated in the summer season, with 70 patients being operated (18.9%).

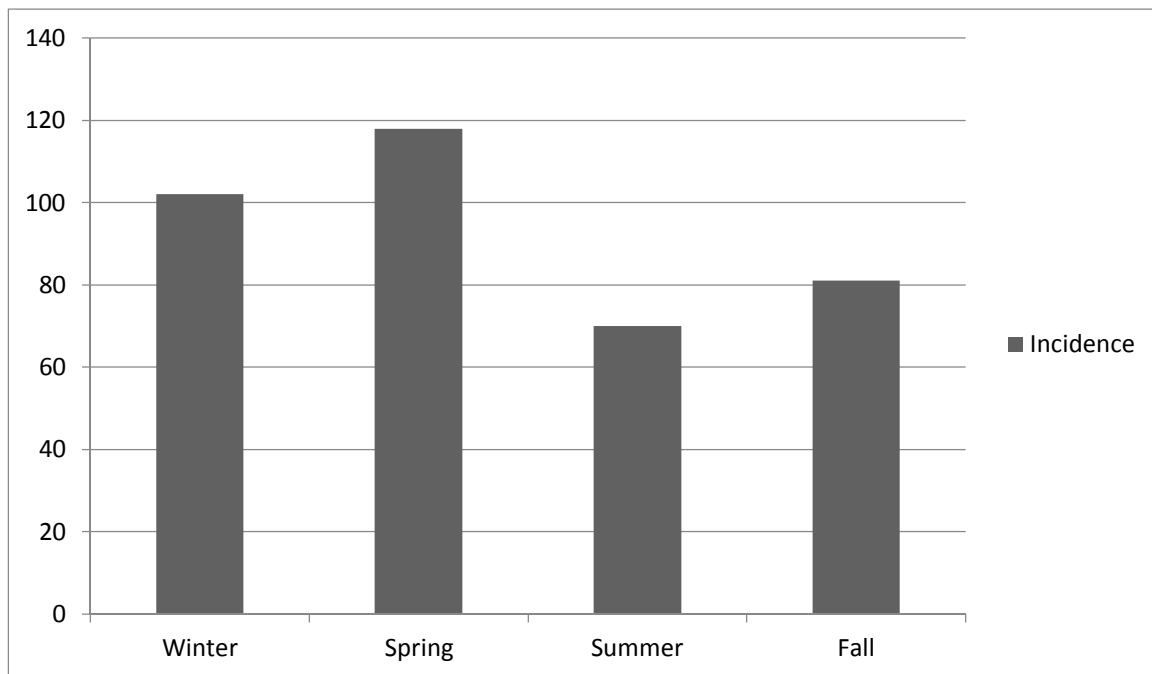


Figure 10. FESS operative procedure distribution by the season of the year.

Figure 11 shows the incidence of nasal polyposis FESS surgical treatment in the study sample between 2013-2018 year. Out of 371 patients who underwent FESS surgical method, 101 were operated in 2013, which makes up 27.2% of total FESS procedures and the year with highest occurrence of FESS procedure. There was a slight decrease in the number of FESS preformed in the following two years, 2014 and 2015, followed by an increase in 2016, with 76 patients (20.5%) who underwent operation. In 2017 there was again a slight decrease in the number of operated patients, with 17 FESS procedures (17.0%). From this figure we can conclude that there was a decrease in incidence of nasal polyposis ESS surgical method observed in this study period.

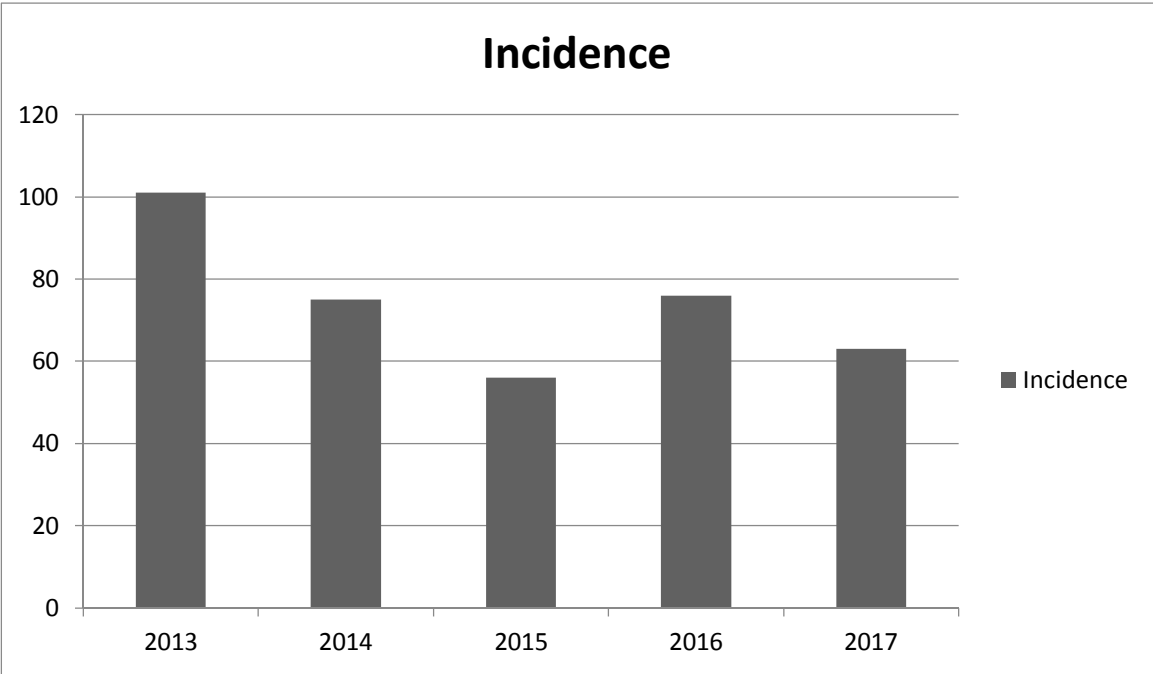


Figure 11. The incidence of FESS surgical method in the study period between 2013-2018.

5. DISCUSSION

Nasal polyposis is one of the common diseases in the Ear, Nose and Throat (ENT) department. The etiology and formation of NP, however, are uncertain, despite decades of research. The current knowledge is that chronic inflammation and nasal allergy are the two most important factors associated with this lesion. The level and type of inflammatory markers have been observed to vary greatly across the globe. This potential difference in pathogenesis is probably due to the variability in patients

with median of 7.0%). Nevertheless, the major complications were low (0-01.5%), which included: CSF leak, injury to the internal carotid artery, and meningitis and orbital penetration. Most frequent complications entailed: hemorrhage, rhinorrhea and orbital fat exposure (55).

Data obtained from the University Hospital of Split (KBC) shows very similar pattern to those of other Caucasian countries. The data shows NP to be more common in male, than female in all age groups, and the incidence peaks around the age of 50-65 years (figure 9). There are also seasonal variation in regards to the number of surgeries performed. Number of surgeries performed are lowest in the summer and highest during spring (Figure 10).

The study had some limitations, like data collection process from the written protocol, which was sometimes impossible to read. Split is a small town, so the study period of 5 years (2013-2018) included 371 patients, which is a quite low sample size for that time period..

6. CONCLUSION

The data obtained from the Department of ENT, head and neck surgery, University Hospital of Split, shows very similar nasal polyp demographic pattern to the data obtained from other countries. In the selected study period (2013

7. REFERENCES

1. Cingi C, Demirbas D, Ural A. Nasal polyposis: an overview of differential diagnosis and treatment. *Recent patents on inflammation & allergy drug discovery*. 2011;5(3):241-52.
2. Newton JR, Ah-See KW. A review of nasal polyposis. *Therap and Clin Risk Manage*. 2008;4(2):507-12.
3. Vancil ME. A historical survey of treatments for nasal polyposis. *The Laryngos*. 1969;79(3):435-45.
4. Aukema AA, Mulder PG, Fokkens WJ. Treatment of nasal polyposis and chronic rhinosinusitis with fluticasone propionate nasal drops reduces need for sinus surgery. *The J of allerg and clin immun*. 2005;115(5):1017-23.
5. Hsu DW, Suh JD. Anatomy and Physiology of Nasal Obstruction. *Otolaryngologic Clin of North Am*. 2018.
6. Numa W, Johnson JCM. Surgical anatomy and physiology of the nose. *Master Tech in Rhinopl*. 2011:21-30.
7. Mark RPF, Bruce H, Valerie, John Niparko, K. Robbins, J. *et al*. Cummings Otolaryngology - Head and Neck Surgery, 3-Vol Set. 5th ed: Mosby; 2010.
8. Fettman N, Sanford T, Sindwani R. Surgical Management of the Deviated Septum: Techniques in Septoplasty. *Otolaryngologic Clin of North Am*. 2009;42(2):241-52.
9. Keeler J, Most SP. Measuring Nasal Obstruction. *Facial Plastic Surgery Clin of North Am*. 2016;24(3):315-22.
10. Jourdy D. Inferior turbinate reduction. *Operative Techniques in Otolaryngology-Head and Neck Surgery*. 2014;25(2):160-70.
11. Simmen D, Heinz B. [Epistaxis strategy--experiences with the last 360 hospitalizations]. *Laryngorhino*. 1998;77(2):100-6.
12. Chegar BE, Tatum SA. Nasal fractures. *Commings CW, Et Al Commings Otolaryngology Head And Neck Surgery 4th Edition Philadelphia*. 2005:962-80.
13. Reddy UDMA, Dev B. Pictorial essay: Anatomical variations of paranasal sinuses on multidetector computed tomography-How does it help FESS surgeons? *The Ind J of Radio & Imag*. 2012;22(4):317-24.
14. Korkmaz H, Korkmaz M. Total aplasia of the paranasal sinuses. *Aller & rhino*. 2013;4(2):e105-9.
15. Frosini P, Picarella G, De Campora E. Antrochoanal polyp: analysis of 200 cases. *Acta Otorhino Ital*. 2009;29(1):21-6.
16. Kumral TL, Yildirim G, Uyar Y. Sphenchoanal polyps and the optic nerve. *Clin and Pract*. 2012;2(1):e10.
17. Al-Qudah MA. Sphenchoanal polyp: current diagnosis and management. *Ear, nose, & throat J*. 2010;89(7):311-7.
18. Robert M, Kliegman BFS, Joseph G III, Nina FS. *Nelson Textbook of Pediatrics*. 20 ed: Elsev; 2016.
19. Settipane GA. Epidemiology of nasal polyps. *Allerg and asth proceedings*. 1996;17(5):231-6.
20. Lund VJ. Diagnosis and treatment of nasal polyps. *BMJ*: 1995;311(7017):1411-4.

21. Chaaban MR, Walsh EM, Woodworth BA. Epidemiology and differential diagnosis of nasal polyps. *Am J of rhino & aller.* 2013;27(6):473-8.
22. Seidman MD, Gurgel RK, Lin SY, Schwartz SR, Baroody FM, *et al.* Clinical practice guideline: Allergic rhinitis. *Otolaryngology--head and neck surgery : official J of Am Academ of Otolaryngology-Head and Neck Surgery.* 2015;152(1 Suppl):S1-43.
23. Bernstein JM, Gorfien J, Noble B. Role of allergy in nasal polyposis: A review. *Otolaryngology - Head and Neck Surgery.* 1995;113(6):724-32.
24. Hulse KE, Stevens WW, Tan BK, Schleimer RP. Pathogenesis of nasal polyposis. *Clinical and experimental allergy : J of the Brit Soci for Aller and Clin Immun.* 2015;45(2):328-46.
25. Fokkens WJ, Lund VJ, Mullol J, Bachert C, Alobid I, *et al.* EPOS 2012: European position paper on rhinosinusitis and nasal polyps 2012. A summary for otorhinolaryngologists. *Rhinol.* 2012;50(1):1-12.
26. Larsen K, Tos M. The estimated incidence of symptomatic nasal polyps. *Acta otolaryngol.* 2002;122(2):179-82.
27. Tan BK, Chandra RK, Pollak J, Kato A, Conley DB, *et al.* Incidence and associated premorbid diagnoses of patients with chronic rhinosinusitis. *The J of aller and clin immun.* 2013;131(5):1350-60.
28. Chang JE, White A, Simon RA, Stevenson DD. Aspirin-exacerbated respiratory disease: burden of disease. *Aller and asthm proceedings.* 2012;33(2):117-21.
29. White AA, Stevenson DD. Aspirin-exacerbated respiratory disease: update on pathogenesis and desensitization. *Seminars in resp and critica care med.* 2012;33(6):588-94.
30. Akdis CA, Bachert C, Cingi C, Dykewicz MS, Hellings PW, *et al.* Endotypes and phenotypes of chronic rhinosinusitis: a PRACTALL document of the Euro Acad of Aller and Clin Immun and the Am Acad of Aller, Asthm & Immun. *The J of aller and clin immun.* 2013;131(6):1479-90.
31. Bachert C, Zhang N, Patou J, van Zele T, Gevaert P. Role of staphylococcal superantigens in upper airway disease. *Current opinion in aller and clin immun.* 2008;8(1):34-8.
32. Sasama J, Sherris DA, Shin SH, Kephart GM, Kern EB, *et al.* New paradigm for the roles of fungi and eosinophils in chronic rhinosinusitis. *Current opinion in otolaryngol & head and neck surgery.* 2005;13(1):2-8.
33. Xiao C, Puddicombe SM, Field S, Haywood J, Broughton-Head V, *et al.* Defective epithelial barrier function in asthma. *The J of aller and clin immun.* 2011;128(3):549-56.e1-12.
34. Yasuda M, Niisato N, Miyazaki H, Iwasaki Y, Hama T, *et al.* Epithelial Na⁺ channel and ion transport in human nasal polyp and paranasal sinus mucosa. *Biochemical and biophysical research communications.* 2007;362(3):753-8.
35. Gudis D, Zhao KQ, Cohen NA. Acquired cilia dysfunction in chronic rhinosinusitis. *Am J of rhinol & aller.* 2012;26(1):1-6.
36. Seshadri S, Lin DC, Rosati M, Carter RG, Norton JE, *et al.* Reduced Expression of Antimicrobial PLUNC Proteins in Nasal Polyp Tissues of patients with Chron Rhinosin. *Aller.* 2012;67(7):920-8.

37. Matsukura S, Stellato C, Georas SN, Casolaro V, Plitt JR, *et al.* Interleukin-13 upregulates eotaxin expression in airway epithelial cells by a STAT6-dependent mechanism. *Am J of resp cell and molecuol biol.* 2001;24(6):755-61.
38. Bartels J, Maune S, Meyer JE, Kulke R, Schluter C, *et al.* Increased eotaxin-mRNA expression in non-atopic and atopic nasal polyps: comparison to RANTES and MCP-3 expression. *Rhinol.* 1997;35(4):171-4.
39. Bachert C, Gevaert P, Holtappels G, Johansson SG, van Cauwenberge P. Total and specific IgE in nasal polyps is related to local eosinophilic inflammation. *The J of allergy and clinic immun.* 2001;107(4):607-14.
40. Mygind N. Advances in the medical treatment of nasal polyps. *Aller.* 1999;54 Suppl 53:12-6.
41. Dinis PB, Gomes A. Sinusitis and asthma: how do they interrelate in sinus surgery? *Am J of rhinol.* 1997;11(6):421-8.
42. Stjarne P, Blomgren K, Caye-Thomasen P, Salo S, Soderstrom T. The efficacy and safety of once-daily mometasone furoate nasal spray in nasal polyposis: a randomized, double-blind, placebo-controlled study. *Acta oto-laryngologica.* 2006;126(6):606-12.
43. Pujols L, Alobid I, Benitez P, Martinez-Anton A, Roca-Ferrer J, *et al.* Regulation of glucocorticoid receptor in nasal polyps by systemic and intranasal glucocorticoids. *Aller.* 2008;63(10):1377-86.
44. Ragab SM, Lund VJ, Scadding G. Evaluation of the medical and surgical treatment of chronic rhinosinusitis: a prospective, randomised, controlled trial. *The Laryngoscop.* 2004;114(5):923-30.
45. Houser SM, Corey JP. Allergic fungal rhinosinusitis. *Otolaryngol Clin of North Am.* 2000;33(2):399-408.
46. Haye R, Aanesen JP, Burtin B, Donnelly F, Duby C. The effect of cetirizine on symptoms and signs of nasal polyposis. *The J of laryngol and otol.* 1998;112(11):1042-6.
47. Peters-Golden M, Henderson WR, Jr. The role of leukotrienes in allergic rhinitis. *Annals of allergy, asthma & immunology : official publication of the Am Col of Aller, Asthm, & Immun.* 2005;94(6):609-18; quiz 18-20, 69.
48. Spies JW, Valera FCP, Cordeiro DL, Mendonça TNd, Leite MGJ, *et al.* The role of aspirin desensitization in patients with aspirin-exacerbated respiratory disease (AERD). *Brazil J of Otorhinolaryng.* 2016;82:263-8.
49. Baudoin T, Kalogjera L, Hat J. Capsaicin significantly reduces sinonasal polyps. *Acta oto-laryngolog.* 2000;120(2):307-11.
50. Nucera E, Schiavino D, Milani A, Del Ninno M, Misuraca C, *et al.* Effects of lysine-acetylsalicylate (LAS) treatment in nasal polyposis: two controlled long term prospective follow up studies. *Thora.* 2000;55(Suppl 2):S75-S8.
51. Stammberger H, Posawetz W. Functional endoscopic sinus surgery. Concept, indications and results of the Messerklinger technique. *Europ archives of oto-rhino-laryngology : official J of the Europ Fed of Oto-Rhino-Laryngological Societies (EUFOS) : affiliated with the German Society for Oto-Rhino-Laryngol - Head and Neck Surgery.* 1990;247(2):63-76.

52. Guilemany JM, Alobid I, Mullol J. Controversies in the treatment of chronic rhinosinusitis. *Exp rev of resp med*. 2010;4(4):463-77.
53. Blomqvist EH, Lundblad L, Anggard A, Haraldsson PO, Stjarne P. A randomized controlled study evaluating medical treatment versus surgical treatment in addition to medical treatment of nasal polyposis. *The J of aller and clin immun*. 2001;107(2):224-8.
54. Slack R, Bates G. Functional endoscopic sinus surgery. *Am family physician*. 1998;58(3):707-18.
55. Dalziel K, Stein K, Round A, Garside R, Royle P. Endoscopic sinus surgery for the excision of nasal polyps: A systematic review of safety and effectiveness. *Am J of rhinolog*. 2006;20(5):506-19.
56. Kakoi H, Hiraide F. A histological study of formation and growth of nasal polyps. *Acta oto-laryngolog*. 1987;103(1-2):137-44.

Incidence of nasal polyps at the Department of ENT, head and neck surgery, University Hospital of Split, between 2013

9. CROATIAN SUMMARY

Naslov: Incidencija operacije nosnih polipoza na Klinici za bolesti uha, nosa i grla s kirurgijom glave i vrata, Klini

10. CURRICULUM VITAE

PERSONAL INFORMATION:

Name and Surname: Marija Milin

Date of Birth: 23.11.1969.

Address: Vukovarska 117

Email: dafimilin@gmail.com

Mobile: 0955843907

Nationality: Croatian

EDUCATION

1985-1989 Ekonomsko-birotehni