

# Fas Ligand expression on Extravillous Trophoblast in placentas from pregnancies complicated with HELLP syndrome

---

**Kurtz, Marie**

**Master's thesis / Diplomski rad**

**2019**

*Degree Grantor / Ustanova koja je dodijelila akademski / stručni stupanj:* **University of Split, School of Medicine / Sveučilište u Splitu, Medicinski fakultet**

*Permanent link / Trajna poveznica:* <https://um.nsk.hr/um:nbn:hr:171:136962>

*Rights / Prava:* [In copyright](#)/[Zaštićeno autorskim pravom.](#)

*Download date / Datum preuzimanja:* **2025-01-28**



*Repository / Repozitorij:*

[MEFST Repository](#)



**UNIVERSITY OF SPLIT  
SCHOOL OF MEDICINE**

**Marie Kurtz**

**FAS LIGAND EXPRESSION ON EXTRAVILLOUS TROPHOBLAST  
IN PLACENTAS FROM PREGNANCIES COMPLICATED WITH  
HELLP SYNDROME**

**Diploma Thesis**

**Academic Year:**

**2018/2019**

**Mentor:**

**Sandra Zekić Tomaš, MD, PhD**

**Split, July 2019**

## **ACKNOWLEDGEMENTS**

*In the past six years at the Medical School in Split I was lucky to have some really ambitious and inspiring teachers, one of them being the mentor of my thesis: Sandra Zekić Tomaš.*

*I want to thank her, the other teaching staff of the University as well as the nurses and residents at the hospital for sharing their passion in medicine with students like me.*

*I also managed to get to know some people I don't want to miss out anymore. Without you, Split would have been pretty boring! Moreover, I want to also thank my friends at home for their continuous visits and support.*

*Last, but not least I want to thank my family for their support already while applying and then throughout those years. I especially want to mention my mom and sister who were always just a phone call away.*

## **LIST OF ABBREVIATIONS**

DC – decidual cells

EVTB – extravillous trophoblast

IUGR – intrauterine growth restriction

PE – preeclampsia

VEGFR-1 – vascular endothelial growth factor receptor 1

VTB – villous trophoblast

## Table of Contents

<b>1. INTRODUCTION</b> .....	<b>1</b>
1.1 PLACENTAL DEVELOPMENT .....	2
1.2 HELLP SYNDROME .....	5
1.2.1 <i>Definition and epidemiology of HELLP</i> .....	5
1.2.2 <i>Risk Factors and Pathophysiology</i> .....	5
1.2.3 <i>Histologic Findings</i> .....	8
1.3 FAS LIGAND.....	9
1.4 FAS LIGAND AND ITS ASSOCIATION WITH HELLP SYNDROME.....	10
<b>2. OBJECTIVES</b> .....	<b>11</b>
<b>3. MATERIAL AND METHODS</b> .....	<b>13</b>
3.1. MATERIAL .....	14
3.2 IMMUNOHISTOCHEMICAL ANALYSIS .....	15
3.3 STATISTICAL ANALYSIS .....	15
<b>4. RESULTS</b> .....	<b>16</b>
<b>5. DISCUSSION</b> .....	<b>19</b>
<b>6. CONCLUSIONS</b> .....	<b>22</b>
<b>7. REFERENCES</b> .....	<b>24</b>
<b>8. SUMMARY</b> .....	<b>31</b>
<b>9. CROATIAN SUMMARY</b> .....	<b>33</b>
<b>10. CURRICULUM VITAE</b> .....	<b>37</b>

## **1. INTRODUCTION**

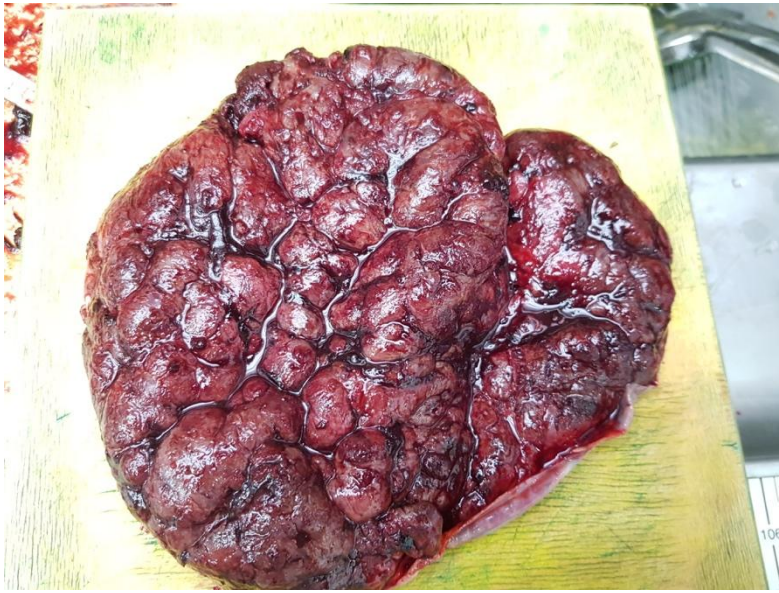## 1.1 Placental development

While the derivation of the word placenta from Latin meaning cake, as well as the German term “*Mutterkuchen*“ and the cake-shaped gross anatomy could indicate a fairly easy structure the placenta is in fact a functionally highly complex organ. A proper vascular development inside the placenta is therefore a key feature to maintain a pregnancy (1). Increasing nutritional needs of the blastocyst entering the uterus around the 5th day post fertilization requires its implantation into the uterine wall. Apposition, adhesion and invasion are the chronological steps of this process (2). The outer layer of the blastocyst will differentiate into trophoblast, which will later on be further subdivided in villous trophoblast (cytotrophoblast and syncytiotrophoblast) and EVTB (interstitial and endovascular). While the villous trophoblast, as their name already indicates will form the chorionic villi, the EVTB will further penetrate the decidua and spiral arteries (1). At around 11 days’ post fertilization primary villi, which are fingerlike protrusions consisting of cytotrophoblast covered by syncytiotrophoblast into the maternal decidua, are formed. Their invasion with extraembryonic mesoderm by day 16 is differentiating them into secondary villi (2). These mesenchymal cells will differentiate into hemangioblastic cell cords and perivascular cells, precursors of capillary endothelial cell (1). Furthermore, Hofbauer cells, which are macrophages expanding during the first and second trimester in the villi, are also of mesenchymal origin (1). Hofbauer cells are linked to trophoblast differentiation, migration and angiogenesis by producing various growth factors and cytokines (1). The result after three weeks are tertiary villi which are floating in a maternal blood space and can be subdivided into stem villi (connected to the chorionic plate, supportive function for the villi structure), terminal villi (floating within the intervillous space, functional unit of the placenta) or anchoring villi (2). The placenta is not perfused with maternal blood until about 12 weeks due to the blockage of the spiral arteries by endovascular trophoblast (3). Another theory states that the nonperfusion is simply caused by the time endovascular trophoblast need migrating and replacing the smooth muscle along the decidual spiral arteries (1). The remodeling of the spiral artery is an indispensable event for placental development. This process is creating a high-flow, low-resistance environment for adequate nutrition. The first changes of this process are independent of trophoblast and may be due to a paracrine-autocrine set of interactions between smooth muscle and endothelial cells (3).

The reduction of number of smooth muscle cells is then further accelerated by the NO production and deposition of fibrinoid material inside the vessel wall by invading trophoblast (3). Impaired trophoblast invasion as well as insufficient conversion of spiral arteries leads to decreased placental blood flow and is associated with several pregnancy diseases (2, 3). At term the placenta presents a disc like shaped organ with a diameter of about 22 cm, a thickness of 2,5 cm in the middle and an average weight of 470 g. The placenta at term consists of a chorionic plate at the fetal and a basal plate at the maternal site (Figure 1). The chorionic plate is covered by amnion consisting of a single layered epithelium and avascular connective tissue (4). Accumulations of fibrin in the intervillous space gives the fetal surface a white mottled appearance (5). The umbilical cord containing the vessels merges with the chorionic mesenchyme inserting the chorionic plate usually at a slightly eccentric point (Figure 2). Forming from the villous trees, the chorionic arteries will give rise to two umbilical arteries while the single umbilical vein intersects underneath the chorionic arteries. Whereas the fetal site manifests on gross anatomy shiny and transparent the maternal site rather displays a fine granular appearance due to the separation of the placenta from the uterine wall during delivery. The basal site is subdivided into 10-40 lobes called cotyledons by placental septa (4). A mixture of trophoblast, decidual cells, extracellular debris, fibrinoid and blood clots forms the basal plate. On a microscopic view the variation of the width in the intervillous space increased from first to third trimester reaching an average width of 16-32 mm. Significant variations from this mean indicate increased branching or deficiency of terminal villi and is associated with disease. In normal at term placentas the terminal villi make up nearly 50% of the total villous surface, despite their small diameters (5). Their separation of fetal vessel and syncytiotrophoblast only by a thin basement membrane makes them the superior villi for diffusive exchange compared to the other forms (4). Mesenchymal villi, which were the first villous type present at the development of the placenta, are still found but in low numbers at the time of the delivery. The bulbous, peripheral immature villi that are abundant between weeks 8 and 22 will decrease parallel to the number of mesenchymal villi found at term (5).

Immature intermediate villi are differentiated by their loose stroma, Hofbauer cells (placental macrophages), more prominent vessels and a discontinuous cytotrophoblast layer (4). The villi with the largest diameter and an anchoring function are the stem villi, developed from differentiating immature villi by fibrinization of the stroma (5). The fifth subtype of placental villi are long, slender precursors of terminal villi called mature intermediate villi.





**Figure 1.** Gross appearance of maternal side of the placenta

(Figure taken from mentor's archive)



**Figure 2.** Gross appearance of placental cut surface with umbilical cord

(Figure taken from mentor's archive)

## **1.2 HELLP syndrome**

### **1.2.1 Definition and epidemiology of HELLP**

Weinstein described HELLP syndrome as a new spectrum of the preeclamptic/eclamptic disorder in order to raise awareness and make earlier recognition possible (6). The acronym H (hemolysis), EL (elevated liver enzymes), and a low platelet count (LP) is still used today and refers to the abnormal laboratory variants in the syndrome. In the Tennessee Classification System diagnostic criteria for HELLP are hemolysis, increased LDH (>600 U/L) and platelets (< 100x10<sup>9</sup>/L). The HELLP syndrome can be further divided into a complete form (requiring all three characters of the triad) or incomplete (consisting of only 1 or 2 elements).

There is also one more classification called the Mississippi triple class system dividing HELLP syndrome into three classes based on their platelet count (7).

The majority of cases of HELLP syndrome seem to develop rather ante partum (70%) with a peak frequency between the 27th and 37th gestational weeks (8, 9). In total 0,5-0,9% of all pregnancies and 10-20% of cases of severe preeclampsia are affected by HELLP syndrome (7). According to a review article from Curtin and Weinstein the maternal mortality ranges from 0-4% (10).

### **1.2.2 Risk Factors and Pathophysiology**

HELLP syndrome seems to be more common in Caucasian women, while African American women demonstrate higher levels of hypertension in severe preeclampsia (11, 12). A previous pregnancy with preeclampsia or HELLP syndrome means a relative high risk of recurrence of HELLP in the second pregnancy (7, 13, 14). Chronic hypertension, multiple pregnancies, nulliparous and age over 35 are additional risk factors, while a BMI above 30 and diabetes seem to only influence the risk of the first pregnancy (13, 15). Furthermore, HELLP syndrome seems to have a higher incidence in patients with antiphospholipid syndrome (16, 17). Interestingly regarding our further work HELLP syndrome seems also to be associated with some genetic variations, like FAS gene (18).

While a high BMI and metabolic syndrome 6 months postpartum as well as a greater risk at the first pregnancy are associated with preeclampsia, those factors seem not to influence HELLP pathogenesis (19).

Moreover, some differences in the clinical manifestations of HELLP syndrome and preeclampsia raised the question in several papers whether HELLP syndrome is a variant of preeclampsia or an entity of its own. A study from the Dutch genome-wide scan proposed for example that HELLP syndrome and preeclampsia might have different backgrounds due to their linkages on chromosomes (preeclampsia on chromosomes 10q and 22q, HELLP on 12q) (20).

Further differences were found in the vascular reactivity of patients with PE or HELLP and might be due to distinct alterations of the vasculature (21). If we take a closer look into the maternal blood values, we will recognize higher levels of fetal mRNA coding for Flt1 (VEGFR-1) and Eng as well as soluble HLA-DR (sHLA-DR) compared to preeclampsia (19). Moreover, we would detect a more enhanced inflammatory response with higher concentrations of CRP, Interleukin 6 and TNF-alpha in the maternal blood sample (19). There also seems to be a higher consumption of coagulation inhibitors and activation of fibrinolysis in patients with HELLP syndrome displaying its greater endothelial damage (22). This result matches with the higher incidence of DIC in this group (23). Proliferation markers in cytotrophoblastic cells and placental expression of FAS Ligand (FasL) are higher in HELLP (24, 25). In addition, decidual dendritic cells stained differently in HELLP and displayed interaction with natural killer cells and VEGFR-1 and -2 (26). Vinnars found higher rates of infarction, intervillous thrombosis, abruption and placental weight in the preeclampsia group and concluded this might be due to different underlying pathogenic mechanisms (27). However, in a later study in 2010 she did not find the differences in intervillous thrombosis, placental abruption or placental weight again (28).

In contrast to the first thesis of Vinnars, Smulian and Weiner describe most placental histopathological lesions in preeclampsia and HELLP as similar and suspect that they share similar placental injuries (11, 29). They therefore concluded to see severe preeclampsia and HELLP syndrome not as separated conditions and instead see them as variations of one disease. In accordance to the previous discussion some researchers suspect that HELLP syndrome as a variant of preeclampsia shares most of its pathophysiological features (10, 11, 19, 29).

The main pathophysiological mechanism of preeclampsia seems to be ischemia and endothelial dysfunction (30). In one hypothesis immune maladaptation between decidual leukocytes and invading cytotrophoblast is suspected to be the cause for the shallow invasion of spiral arteries (31).

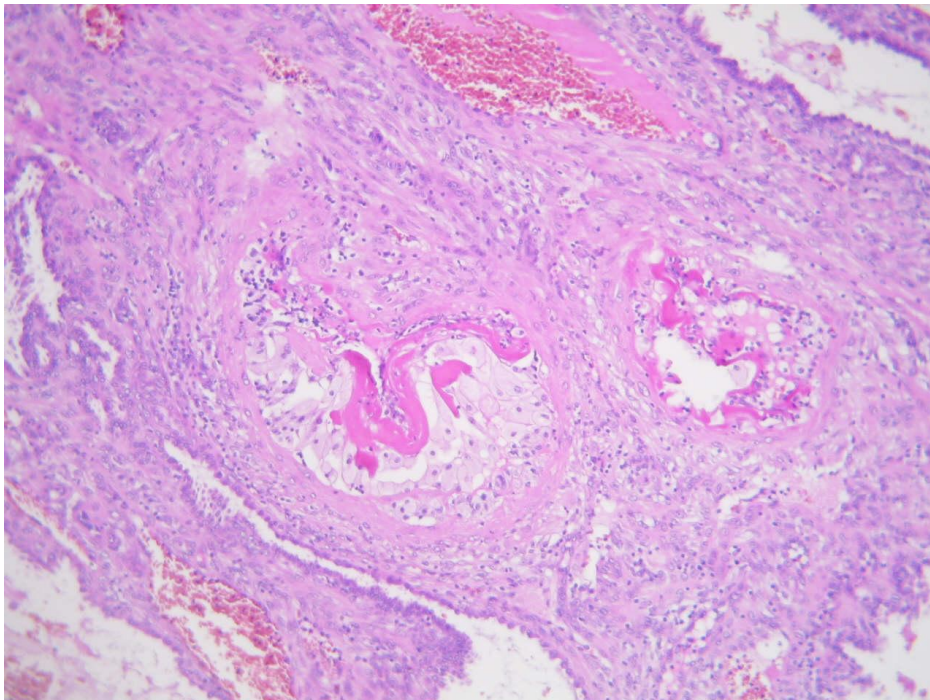
The insufficient trophoblast invasion and unconverted narrow spiral arteries are suspected as cause for the hypoxia (32). The placenta releases as response angiogenic agents, cytokines, products of lipid peroxidation, autoantibodies and placental cell debris. Later on anti-angiogenic factors causing an imbalance between anti-angiogenic factors and angiogenic factors are raising (33). Clinical symptoms like hypertension and proteinuria are supposed to be due to increased circulating antiangiogenic proteins like sFlt-1 (= VEGFR-1), endoglin (34). These factors cause an enhanced inflammatory immune response by triggering the vascular endothelium (19). Furthermore, lipid peroxidation and leukocyte activation may be attributed key roles in the mechanism of endothelial dysfunction (35). It is suspected that the resulting angiopathy involves circulating platelets, causing hemolysis in affected microvessels and by narrowing of the vessel lumen causing reduced hepatic blood flow. Hepatic injury seems also to be caused by placenta-derived FasL (CD95L) which is toxic to human hepatocytes (36).

Recent findings showed evidence of a complement system dysregulation in preeclampsia and HELLP syndrome (37, 38). The maladaptation between decidual leukocytes and invading cytotrophoblast offers one explanation to the theory of an immunologically mediated cause of the disease. Another theory suggests a dysfunctional lipid metabolism as contributing factor to HELLP syndrome, recognizing the negative correlation of maternal platelet counts and serum TG levels (39). Additionally, the higher frequency of preeclampsia-related conditions in long chain 3-hydroxyacylcoenzyme A deficient fetus further supports the idea of an involvement of fatty acid accumulation in the pathogenesis of preeclampsia (40).

### 1.2.3 Histologic Findings

Higher rates of decidual arteriopathy (both hypertrophic and atherosclerosis), uterine pattern of chronic placental injury, villous infarctions and clusters of maternal floor multinucleate trophoblast are characteristic for preeclamptic lesions as well as HELLP syndrome (29, 41) (Figure 3). On a microscopic view the spiral and basal arteries are in a denser distribution pattern than usual, with smaller-caliber lumens and thicker walls (42), and increased numbers of immature villous trophoblast are also found (43).

Maternal liver biopsy displays periportal and /or centrally localized parenchymal lesions with fibrin deposits (44). On hepatic imaging subcapsular hematoma and intraparenchymal hemorrhage might be seen (45).



**Figure 3.** Microscopic image of acute atherosclerosis in placenta from pregnancies complicated with preeclampsia, H&E staining, magnification x200

(Figure taken from mentor's archive)

### 1.3 Fas ligand

The Fas/ Fas Ligand (also named Apo-1 or CD95) are members of the tumor necrosis factor family and play an important role in the regulation of cell death. The trimerization of the Fas receptor by Fas ligand results in the activation of caspase 8 and as a final consequence to an apoptotic cell death via the extrinsic pathway. Activation-induced cell death and the resulting T-cell homeostasis is a fundamental function of the Fas/Fas Ligand system. This limits T cell clone expansion and furthermore inactivates self-reactive T cells in the periphery.

Lymphoproliferative disorders caused by defects in the genes encoding Fas and FasL clearly underline this modulatory function and its importance (46). While CD95 is abundantly expressed in various tissues, the expression of CD95L is limited to a few cell types, like activated T-cells, natural killer cells and cells of tissues of immune-privileged sites like testis and eye (47). In literature immune-privileged is defined as the capacity of a tissue to actively modulate the immune response in that specific location (48). The intervillous space as well as the placental bed sites present maternal fetal interfaces where trophoblastic cells and maternal lymphocytes meet. FasL expression in trophoblast plays also an important role in maintenance of immune-privilege of the placenta by inducing apoptosis of Fas-expressing lymphocytes of maternal origin. Several studies displayed FasL in microvesicles stored in cytoplasm of syncytiotrophoblast and secreted via exosomes. FasL expression was further detected in Hofbauer cells (49). One possible advantage of the exosome-associated secretion of FasL, opposite to the previous concept of membrane bound FasL, is the protection against an inflammatory response due to distance. It might additionally serve as a mechanism to induce apoptosis in fetus-sensitized Fas expressing effector cells further away from the placenta (49). FasL in trophoblast may also have the additional role of inducing apoptosis in the decidua and enable maternal invasion and implantation (50).

#### **1.4 Fas ligand and its association with HELLP syndrome**

Since preeclampsia and HELLP syndrome seem both to be associated with a higher rates of trophoblast apoptosis than normal pregnancies and Fas/ FasL expression seems to be modified in preeclamptic patients, it seems that this alteration influences the pathogenesis of PE (11, 24, 35, 51, 52). The detection of specific polymorphisms encoding for Fas Ligand bearing a higher risk for the development of PE (18, 53) further enhances the theory of a possible causality between altered FasL expression and the development of PE. Moreover, the data by Strands suggested a pivotal role of placental derived FasL in liver damage of HELLP syndrome (36). In PE there seems to be an altered distribution of Th1/Th2 cells in comparison to normal pregnancy with a predominance of the more inflammation causing Th1 type (54).

Latest findings also underlined the role of Treg/Th17 cells in immune tolerance in normal pregnancy (55) and displayed their lower numbers in preeclampsia (56). Interestingly Treg cells are highly sensitive to CD95-mediated apoptosis in comparison to other T cells (57).

Literature search revealed a decreased FasL expression (51, 58, 59) and increased Fas expression in villous trophoblast of preeclamptic patients (51). While Petsas found FasL positive decidual macrophages only in preeclamptic patients (60), Eide claimed that FasL expressing decidual cells are also found in normal placentas and that they are reduced in preeclamptic patients. They further mention a higher reduction of FasL expressing decidual cells than EVTB in association with preeclampsia (59). This is contradictory to the finding of Mendilcioglu who found an increased expression of FasL in the decidua of patients with preeclampsia (61). In addition, a lower expression of CD95 on decidual Natural killer cells in the background of their ability to undergo Fas/FasL mediated apoptosis (62), could explain a higher inflammatory response in preeclamptic patients. Studies about an increase of soluble FasL concentrations in maternal blood seem inconsistent (59). Based on a review of previous studies we would suspect an increase in FasL expression in maternal decidual cells and hypothesize that this is the reason of an increase in apoptosis of trophoblast and prolonged survival of natural killer cells in the decidua, causing enhanced inflammation and corresponding symptoms in HELLP patients.

## **2. OBJECTIVES**



The purpose of our study was to compare of the immunohistochemical staining for Fas Ligand on EVTB and DC in placentas with and without HELLP syndrome.

According to our hypothesis the percentage of Fas Ligand expression should be higher in placentas with HELLP syndrome. We reason this increase with an enhanced apoptosis of trophoblast and prolonged survival of natural killer cells in the decidua.

### **3. MATERIAL AND METHODS**

### **3.1. Material**

As sample ten placentae from women with HELLP syndrome were compared to the same number of normal placentae. HELLP syndrome was defined as follows: platelets  $<100 \times 10^9/L$ , aspartate aminotransferase (AST) and alanine transaminase (ALT)  $>70U/L$  as well as lactic acid dehydrogenase (LDH)  $>600U/L$ . All of the examined placentae were collected within 20 minutes after cesarean section and fixed in 10% formalin. The central part of the macroscopically normal placental disc, next to the umbilical cord was chosen for examination. The chorionic plate and the decidua were visible in each of the samples. To evaluate Fas Ligand expression we used immunohistochemistry and the semiquantitative HSCORE method. The assessment of the Fas Ligand distribution among the placentae was done manually using a x40 objective (Olympus BX41 microscope).

### 3.2 Immunohistochemical analysis

All placenta-derived samples were prepared in the following way: the tissue was dewaxed in xylene, rehydrated in graded concentrations of alcohol and heated in a microwave oven for 20 minutes at 700W with TRIS/EDTA (pH 9; DAKO). After cooling to room temperature, samples were washed in distilled water and phosphate-buffered saline (PBS) solution (pH 7.5). By the usage of 3% H<sub>2</sub>O<sub>2</sub> for 10 minutes' endogenous peroxidase was blocked. Later on the samples were washed in distilled water to be prepared for immunohistochemical detection of FasL. Primary monoclonal mouse antibody (clone 5D1; Novocastra, Newcastle, UK), previously diluted 1: 50 was applied for one hour and then washed in PBS solution (pH 7.5). Additionally, EnVision HRP anti-mouse (K 4001; DAKO) was used as a secondary antibody; time of incubation was 30 minutes. After applying chromogen diaminobenzidine-hydrogen (DAB; code no. K 3468; DAKO) for 10 minutes, the samples were washed in distilled water. The sections were counterstained in hematoxylin, dehydrated, cleared and mounted on silanized slides. The expression of FasL was characterized by a diffuse or granular brown staining of the cytoplasm (Figure 4 and 5). As control a sample of prostatic tissue and a sample of melanoma was used. We considered positive cells as cells with nuclei surrounded by positive cytoplasm. We graded the expression of FasL for EVTB by the HSCORE method using the equation  $HSCORE = \sum Pi(i+1)$ . In this equation the variable *i* should represent the intensity of staining with the following characteristics 1 (weak), 2 (moderate) or 3 (strong). *Pi* displays the percentage of stained trophoblast cells of each intensity (51).

### 3.3 Statistical analysis

Our data was analyzed for statistical purposes with MedCalc software (MedCalc software, Mariakerke, Belgium). Data distribution was assessed by the Kolmogorov-Smirnov test. Afterwards statistical significance was assessed by the usage of the t-test for normally distributed values, while the Mann-Whitney test was used to study not normally distributed samples. Additionally, with the Chi-Square test we interpret the statistical significance of sampling distribution following a chi-squared curve. The data were displayed as means  $\pm$ SD, or as medians with minimum and maximum range. Statistical significance was set at  $P < 0.05$ .

## **4. RESULTS**

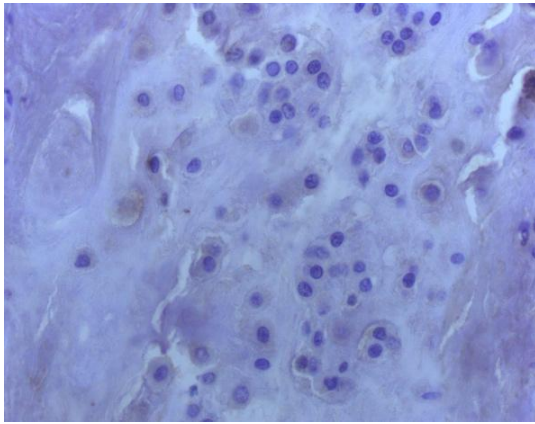
The samples in our study did not show any significant difference between studied groups in maternal age ( $t=1,417$ ;  $P=0,173$ ) and parity ( $Z=1,205$ ;  $P=0,228$ ). Gestational age was significantly lower in HELLP group compared with control group ( $Z=3,679$ ;  $P=0,0002$ ), as well as the birth weight ( $t=8,172$ ;  $P<0,0001$ ) IUGR was noted in 5 HELLP cases while here was none in control group which was statistically significant ( $\chi^2=6,333$ ;  $DF=1$ ;  $P=0,012$ ) (Table 1).

**Table 1.** Demographic and clinical characteristics of the study groups

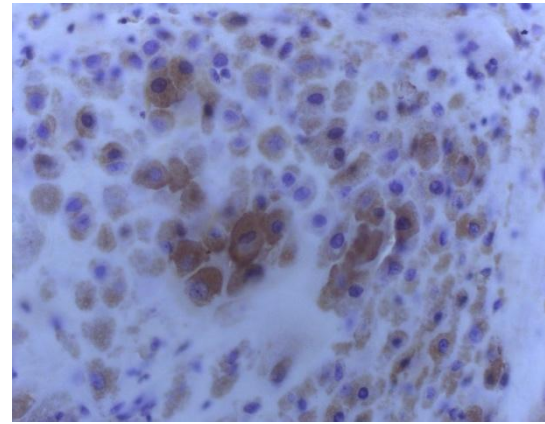
	<b>HELLP (n=10)</b>	<b>Control group (n=10)</b>	<b>P</b>
Maternal age (years)	29 ±8	33±4	0,173 <sup>†</sup>
Parity	1(1-6)	1(1-2)	0,228*
Gestational age (weeks)	33 (28-37)	38 (37-39)	0,0002*
Fetal weight (g)	1695±558	3550±450	<0,0001 <sup>†</sup>
IUGR	5	0	0,012**

The results are presented as mean value ± SD for maternal age and fetal weight, and as median value (minimum and maximum value) for parity and gestational weeks. \*Mann-Whitney test; \*\* Chi-Square test, <sup>†</sup>t-test

EVTB FasL immunohistochemical expression was significantly higher in HELLP group compared to control group ( $Z=3,425$ ;  $P=0,0006$ ), as well as on DC ( $t=5,130$ ;  $P=0,0001$ ) (Figure 4&5). There was no statistically significant difference in FasL immunohistochemical expression between EVTB (3,9 (3-4)) and DC (3,85 (3-4)) in the HELLP group ( $Z=0,460$ ;  $P=0,645$ ). This correlates with the results of the control group where a significant difference between EVTB (2,5 (2-3,5)) and DC (2,8 (2-3,5)) FasL immunohistochemical expression could also not been shown ( $Z=0,229$ ;  $P=0,818$ ) (Table 2).



**Figure 4.** Immunohistochemical expression of Fas ligand on extravillous trophoblast and decidual cells in placenta from normal pregnancies, magnification x400  
(Image taken by candidate)



**Figure 5.** Immunohistochemical expression of Fas ligand on extravillous trophoblast and decidual cells in placenta from pregnancy complicated with HELLP syndrome, magnification x400  
(Image taken by candidate)

**Table 2.** Immunohistochemical expression of Fas ligand in extravillous trophoblast (EVTB) and decidual cells (DC) of placentas complicated by HELLP syndrome and control groups placentas.

	<b>HELLP (n=10)</b>	<b>Control group (n=10)</b>	<b>P</b>
EVTB	3,9 (3-4)	2,5 (2-3,5)	0,0006*
DC	3,6 ± 0,39	2,7 ± 0,44	0,0001 <sup>†</sup>

The results are presented as mean value ± SD for DC, and as median value (minimum and maximum value) for EVTB. Results are presented as HSCORE. \*Mann-Whitney test, <sup>†</sup>t-test

## **5. DISCUSSION**



We were able to display a significantly higher FasL expression of the EVTB of placentae complicated by HELLP syndrome in our study. The insignificant difference in maternal age and parities between the two study groups confirmed an appropriately chosen sample. Meanwhile the significantly lower gestational age, birth weight and the IUGR in the HELLP group can be attributed as part of the clinical expression of HELLP syndrome and its consequence of preterm delivery. GA- matching between groups was not possible which might lead to an altered estimation of the observed difference in FasL expression (59). The expression of FasL on trophoblast supports the theory of their role as immune privileged cells maintaining the fetal allograft via the Fas/ FasL pathway (50). Higher levels of FasL in maternal blood serum seem to be connected to an enhanced inflammatory immune response in HELLP syndrome (19). Moreover, the hepatic injury, which is a characteristic part of HELLP syndrome, seems also to be caused by placenta-derived FasL (CD95L) which is toxic to human hepatocytes (36). Therefore, we interpret the increase in FasL expression on EVTB in placenta with HELLP syndrome as a possible cause for an increased immune response and the following damage. The increased expression of FasL in EVTB is coherent with previous findings of increased FasL in villous trophoblast (24).

To the best of our knowledge, this study is the first one to reveal information regarding the expression of FasL on EVTB of HELLP syndrome placentae.

The higher expression of FasL on EVTB and decidual cells in patients with HELLP seems to be in contrast to the findings of reduced FasL /Fas expression in both decidual cells and EVTB in patients with preeclampsia found by Eide, Darmochwal-Kolarz (59, 62). This might indicate that preeclampsia and HELLP syndrome differ in their pathophysiological mechanisms and should be treated as different entities and not as variations of the same syndrome. Higher expression of FasL together with a rise in trophoblast turnover could be a cause for more severe symptoms and disastrous outcomes in HELLP syndrome than in PE.

In regard to clinical practice this study and its finding of higher FasL expression in EVTB may offer a way of early detection of the syndrome by determination of higher FasL expression in the placentae and sera of the mother. Another study was able to display significantly higher ATI-AAAs in the HELLP group of pregnant rats and correlate with them with an increased level of TNF-alpha and ET-1 in plasma (41).

ATI-AAs are agonistic autoantibodies (Aas) binding to the angiotensin II type 1 (AT) receptor, offering another approach to the pathophysiological mechanism of HELLP syndrome and another possibility for early detection of immunologic markers in blood samples of patients with HELLP syndrome which offer a way of prompt detection in clinical practice (41).

The major limitation of the present study is the number of the placental samples, as well as the gestational age mismatch between the HELLP and control group. Additionally, further methods than immunohistochemistry, like Western blot or PCR could have been used to verify the results.

Nevertheless, we were able to find a significantly higher immunohistochemical expression of FasL on EVTB and DC in HELLP group patients compared to the control group in our study, while there was no statistically significant difference in FasL expression between EVTB and decidual cells for each studied placental group. In addition, we recognized different immunohistochemical staining patterns for FasL expression between our HELLP syndrome samples and the in literature described staining pattern of preeclampsia with a higher staining for FasL in HELLP syndrome. The results of our study offer a possibility of further research in new diagnostic tool for early detection of HELLP syndrome.

## **6. CONCLUSIONS**

1. In our study we were able to display a significantly higher immunohistochemical expression of FasL on EVTB and DC in HELLP group patients compared to the control group. However, we were not able to reveal a statistically significant difference in FasL immunohistochemical expression between EVTB and decidual cells for each studied placental group.
2. The results of our study are in coherence with previous studies of FasL expression in placentae complicated by HELLP syndrome.
3. The immunohistochemical staining of FasL differs between HELLP syndrome and preeclampsia.
4. Increased FasL expression in decidual cells and EVTB are an indicator for the pathology of HELLP syndrome and in further research may offer a way of early detection of the syndrome due to soluble FasL in maternal serum as clinical marker.

## **7. REFERENCES**

1. Wang Y, Zhao S. *Vascular Biology of the Placenta*. San Rafael (CA)2010.
2. Joan W. Witkin P. Dept. Anatomy & Cell Biology.
3. Huppertz B, Peeters LL. Vascular biology in implantation and placentation. *Angiogenesis*. 2005;8:157-67.
4. Huppertz B. The anatomy of the normal placenta. *Journal of clinical pathology*. 2008;61:1296-302.
5. Benirschke K, KPN, Baergen R. N. *Pathology of the human placenta*. 2006;5th 13-25.
6. Weinstein L. It has been a great ride: The history of HELLP syndrome. *American journal of obstetrics and gynecology*. 2005;193:860-3.
7. Haram K, Svendsen E, Abildgaard U. The HELLP syndrome: clinical issues and management. A Review. *BMC pregnancy and childbirth*. 2009;9:8.
8. Magann EF, Martin JN, Jr. Twelve steps to optimal management of HELLP syndrome. *Clinical obstetrics and gynecology*. 1999;42:532-50.
9. Sibai BM, Ramadan MK, Usta I, Salama M, Mercer BM, Friedman SA. Maternal morbidity and mortality in 442 pregnancies with hemolysis, elevated liver enzymes, and low platelets (HELLP syndrome). *American journal of obstetrics and gynecology*. 1993;169:1000-6.
10. Curtin WM, Weinstein L. A review of HELLP syndrome. *Journal of perinatology : official journal of the California Perinatal Association*. 1999;19:138-43.
11. Smulian J, Shen-Schwarz S, Scorza W, Kinzler W, Vintzileos A. A clinicohistopathologic comparison between HELLP syndrome and severe preeclampsia. *The journal of maternal-fetal & neonatal medicine : the official journal of the European Association of Perinatal Medicine, the Federation of Asia and Oceania Perinatal Societies, the International Society of Perinatal Obstet*. 2004;16:287-93.
12. Goodwin AA, Mercer BM. Does maternal race or ethnicity affect the expression of severe preeclampsia? *American journal of obstetrics and gynecology*. 2005;193:973-8.
13. Malmstrom O, Morken NH. HELLP syndrome, risk factors in first and second pregnancy: a population-based cohort study. *Acta obstetrica et gynecologica Scandinavica*. 2018;97:709-16.
14. Sullivan CA, Magann EF, Perry KG, Jr., Roberts WE, Blake PG, Martin JN, Jr. The recurrence risk of the syndrome of hemolysis, elevated liver enzymes, and low platelets (HELLP) in subsequent gestations. *American journal of obstetrics and gynecology*. 1994;171:940-3.
15. Fitzpatrick KE, Hinshaw K, Kurinczuk JJ, Knight M. Risk factors, management, and

outcomes of hemolysis, elevated liver enzymes, and low platelets syndrome and elevated liver enzymes, low platelets syndrome. *Obstetrics and gynecology*. 2014;123:618-27.

16. Tsirigotis P, Mantzios G, Pappa V, Girkas K, Salamalekis G, Koutras A, et al. Antiphospholipid syndrome: a predisposing factor for early onset HELLP syndrome. *Rheumatology international*. 2007;28:171-4.

17. Koenig M, Roy M, Baccot S, Cuilleron M, de Filippis JP, Cathebras P. Thrombotic microangiopathy with liver, gut, and bone infarction (catastrophic antiphospholipid syndrome) associated with HELLP syndrome. *Clinical rheumatology*. 2005;24:166-8.

18. Sziller I, Hupuczi P, Normand N, Halmos A, Papp Z, Witkin SS. Fas (TNFRSF6) gene polymorphism in pregnant women with hemolysis, elevated liver enzymes, and low platelets and in their neonates. *Obstetrics and gynecology*. 2006;107:582-7.

19. Abildgaard U, Heimdal K. Pathogenesis of the syndrome of hemolysis, elevated liver enzymes, and low platelet count (HELLP): a review. *European journal of obstetrics, gynecology, and reproductive biology*. 2013;166:117-23.

20. Lachmeijer AM, Arngrimsson R, Bastiaans EJ, Frigge ML, Pals G, Sigurdardottir S, et al. A genome-wide scan for preeclampsia in the Netherlands. *European journal of human genetics : EJHG*. 2001;9:758-64.

21. Fischer T, Schneider MP, Schobel HP, Heusser K, Langenfeld M, Schmieder RE. Vascular reactivity in patients with preeclampsia and HELLP (hemolysis, elevated liver enzymes, and low platelet count) syndrome. *American journal of obstetrics and gynecology*. 2000;183:1489-94.

22. Paternoster DM, Stella A, Simioni P, Mussap M, Plebani M. Coagulation and plasma fibronectin parameters in HELLP syndrome. *International journal of gynaecology and obstetrics: the official organ of the International Federation of Gynaecology and Obstetrics*. 1995;50:263-8.

23. Visser W, Wallenburg HC. Temporising management of severe pre-eclampsia with and without the HELLP syndrome. *British journal of obstetrics and gynaecology*. 1995;10:111-7.

24. Prusac IK, Zekic Tomas S, Roje D. Apoptosis, proliferation and Fas ligand expression in placental trophoblast from pregnancies complicated by HELLP syndrome or pre-eclampsia. *Acta obstetrica et gynecologica Scandinavica*. 2011;90:1157-63.

25. Jeschke U, Schiessl B, Mylonas I, Kunze S, Kuhn C, Schulze S, et al. Expression of the proliferation marker Ki-67 and of p53 tumor protein in trophoblastic tissue of preeclamptic, HELLP, and intrauterine growth-restricted pregnancies. *International journal of*

gynecological pathology : official journal of the International Society of Gynecological Pathologists. 2006;25:354-60.

26. Scholz C, Toth B, Santoso L, Kuhn C, Franz M, Mayr D, et al. Distribution and maturity of dendritic cells in diseases of insufficient placentation. *Am J Reprod Immunol.* 2008;60:238-45.
27. Vinnars MT, Wijnaendts LC, Westgren M, Bolte AC, Papadogiannakis N, Nasiell J. Severe preeclampsia with and without HELLP differ with regard to placental pathology. *Hypertension.* 2008;51:1295-9.
28. Vinnars MT, Nasiell J, Ghazi S, Westgren M, Papadogiannakis N. The severity of clinical manifestations in preeclampsia correlates with the amount of placental infarction. *Acta obstetrica et gynecologica Scandinavica.* 2011;90:19-25.
29. Weiner E, Schreiber L, Grinstein E, Feldstein O, Rymer-Haskel N, Bar J, et al. The placental component and obstetric outcome in severe preeclampsia with and without HELLP syndrome. *Placenta.* 2016;47:99-104.
30. van Beck E, Peeters LL. Pathogenesis of preeclampsia: a comprehensive model. *Obstetrical & gynecological survey.* 1998;53:233-9.
31. Dekker GA, Sibai BM. Etiology and pathogenesis of preeclampsia: current concepts. *American journal of obstetrics and gynecology.* 1998;179:1359-75.
32. Goldman-Wohl D, Yagel S. Regulation of trophoblast invasion: from normal implantation to pre-eclampsia. *Molecular and cellular endocrinology.* 2002;187:233-8.
33. Gupte S, Wagh G. Preeclampsia-eclampsia. *Journal of obstetrics and gynaecology of India.* 2014;64:4-13.
34. Mutter WP, Karumanchi SA. Molecular mechanisms of preeclampsia. *Microvascular research.* 2008;75:1-8.
35. Gupta S, Agarwal A, Sharma RK. The role of placental oxidative stress and lipid peroxidation in preeclampsia. *Obstetrical & gynecological survey.* 2005;60:807-16.
36. Strand S, Strand D, Seufert R, Mann A, Lotz J, Blessing M, et al. Placenta-derived CD95 ligand causes liver damage in hemolysis, elevated liver enzymes, and low platelet count syndrome. *Gastroenterology.* 2004;126:849-58.
37. Alrahmani L, Willrich MAV. The Complement Alternative Pathway and Preeclampsia. *Current hypertension reports.* 2018;20:40.
38. Vaught AJ, Gavriilaki E, Hueppchen N, Blakemore K, Yuan X, Seifert SM, et al. Direct evidence of complement activation in HELLP syndrome: A link to atypical hemolytic uremic syndrome. *Experimental hematology.* 2016;44:390-8.



39. Wetzka B, Winkler K, Kinner M, Friedrich I, Marz W, Zahradnik HP. Altered lipid metabolism in preeclampsia and HELLP syndrome: links to enhanced platelet reactivity and fetal growth. *Seminars in thrombosis and hemostasis*. 1999;25:455-62.
40. Tyni T, Ekholm E, Pihko H. Pregnancy complications are frequent in long-chain 3-hydroxyacyl-coenzyme A dehydrogenase deficiency. *American journal of obstetrics and gynecology*. 1998;178:603-8.
41. Stanek J. Placental pathology varies in hypertensive conditions of pregnancy. *Virchows Archiv : an international journal of pathology*. 2018;472:415-23.
42. Starzyk KA, Salafia CM, Pezzullo JC, Lage JM, Parkash V, Vercruysse L, et al. Quantitative differences in arterial morphometry define the placental bed in preeclampsia. *Human pathology*. 1997;28:353-8.
43. Redline RW, Patterson P. Pre-eclampsia is associated with an excess of proliferative immature intermediate trophoblast. *Human pathology*. 1995;26:594-600.
44. Roberts JM, Cooper DW. Pathogenesis and genetics of pre-eclampsia. *Lancet*. 2001;357:53-6.
45. Barton JR, Sibai BM. Hepatic imaging in HELLP syndrome (hemolysis, elevated liver enzymes, and low platelet count). *American journal of obstetrics and gynecology*. 1996;174:1820-5.
46. Waring P, Mullbacher A. Cell death induced by the Fas/Fas ligand pathway and its role in pathology. *Immunology and cell biology*. 1999;77:312-7.
47. Li-Weber M, Krammer PH. Function and regulation of the CD95 (APO-1/Fas) ligand in the immune system. *Seminars in immunology*. 2003;15:145-57.
48. Stein-Streilein J, Caspi RR. Immune privilege and the philosophy of immunology. *Frontiers in immunology*. 2014;5:110.
49. Frangmyr L, Baranov V, Nagaeva O, Stendahl U, Kjellberg L, Mincheva-Nilsson L. Cytoplasmic microvesicular form of Fas ligand in human early placenta: switching the tissue immune privilege hypothesis from cellular to vesicular level. *Molecular human reproduction*. 2005;11:35-41.
50. Uckan D, Steele A, Cherry, Wang BY, Chamizo W, Koutsonikolis A, et al. Trophoblasts express Fas ligand: a proposed mechanism for immune privilege in placenta and maternal invasion. *Molecular human reproduction*. 1997;3:655-62.
51. Allaire AD, Ballenger KA, Wells SR, McMahon MJ, Lessey BA. Placental apoptosis in preeclampsia. *Obstetrics and gynecology*. 2000;96:271-6.
52. Yue XY, Zhang X, Cui SH, Wang XQ. [Expression of Fas antigen and ligand,

placental growth factor in placenta of pregnant women with pre-eclampsia]. *Zhonghua fu chan ke za zhi*. 2005;40:320-2.

53. Allaire AD, D'Andrea N, Truong P, McMahan MJ, Lessey BA. Cervical stroma apoptosis in pregnancy. *Obstetrics and gynecology*. 2001;97:399-403.

54. Salimi S, Moudi B, Farajian Mashhadi F, Tavilani H, Hashemi M, Zand H, et al. Association of functional polymorphisms in FAS and FAS Ligand genes promoter with pre-eclampsia. *The journal of obstetrics and gynaecology research*. 2014;40:1167-73.

55. Saito S, Nakashima A, Ito M, Shima T. Clinical implication of recent advances in our understanding of IL-17 and reproductive immunology. *Expert review of clinical immunology*. 2011;7:649-57.

56. Hafeez NA, Fouda Mel T, Abdel Gawad ER, Assar T, Mansour AI. The role of regulatory T cells in preeclampsia. *The Egyptian journal of immunology*. 2014;21:45-55.

57. Fritzsching B, Oberle N, Eberhardt N, Quick S, Haas J, Wildemann B, et al. In contrast to effector T cells, CD4+CD25+FoxP3+ regulatory T cells are highly susceptible to CD95 ligand- but not to TCR-mediated cell death. *J Immunol*. 2005;175:32-6.

58. Resic Karara J, Zekic Tomas S, Marusic J, Roje D, Kuzmic Prusac I. Fas and FasL expression in placentas complicated with intrauterine growth retardation with and without preeclampsia. *The journal of maternal-fetal & neonatal medicine : the official journal of the European Association of Perinatal Medicine, the Federation of Asia and Oceania Perinatal Societies, the International Society of Perinatal Obstet*. 2016;29:1154-9.

59. Eide IP, Isaksen CV, Salvesen KA, Langaas M, Gunther CC, Iversen AC, et al. Fetal growth restriction is associated with reduced FasL expression by decidual cells. *Journal of reproductive immunology*. 2007;74:7-14.

60. Petsas G, Jeschke U, Richter DU, Minas V, Hammer A, Kalantaridou S, et al. Aberrant expression of corticotropin-releasing hormone in pre-eclampsia induces expression of FasL in maternal macrophages and extravillous trophoblast apoptosis. *Molecular human reproduction*. 2012;18:535-45.

61. Mendilcioglu I, Karaveli S, Erdogan G, Simsek M, Taskin O, Ozekinci M. Apoptosis and expression of Bcl-2, Bax, p53, caspase-3, and Fas, Fas ligand in placentas complicated by preeclampsia. *Clinical and experimental obstetrics & gynecology*. 2011;38:38-42.

62. Darmochwal-Kolarz D, Rolinski J, Leszczynska-Gorzalak B, Oleszczuk J. Fas antigen expression on the decidual lymphocytes of pre-eclamptic patients. *Am J Reprod Immunol*. 2000;43:197-201.

63. DiFederico E, Genbacev O, Fisher SJ. Preeclampsia is associated with widespread

apoptosis of placental cytotrophoblasts within the uterine wall. *The American journal of pathology*. 1999;155:293-301.

## **8. SUMMARY**

**Objectives:** to compare the staining for Fas Ligand receptor on EVTB in placentas with and without HELLP syndrome. Maternal and gestational age, as well as parity, fetal weight and IUGR were also investigated and analyzed for differences.

**Subject and method:** 10 placentae with HELLP syndrome and 10 control placentae were enrolled in the study. Both groups were immunohistochemically stained with antibody to FasL. We used the HSCORE method for assessment of the immunohistochemical staining of FasL in each sample group.

**Results:** We were able to show a statistically significant increase in FasL expression on EVTB and DC in the placentae of patients with HELLP syndrome compared to the control group. No statistically difference in the immunohistochemical expression between EVTB and DC could be found in the HELLP or control group.

**Conclusion:** Our study has shown a higher occurrence of FasL in placentae of pregnancies complicated by HELLP syndrome. Possibly this is causing higher rates of apoptosis and following inflammatory response at the decidual side and thereby leading to the clinical picture of HELLP syndrome. Further investigations with larger sample are required to confirm the results of the presented study.

## **9. CROATIAN SUMMARY**

**Ciljevi:** usporediti imunohistokemijski izražaj Fas liganda (FasL) na ekstraviloznom trofoblastu (EVTB) i decidualnim stanicama (DC) u posteljicama kompliciranim HELLP sindromom te rezultate usporediti s posteljicama normalnih trudnoća. Dob majke, gestacijska dob, paritet, porođajna masa te intruterini zastoj rasta (IUZR) su također analizirani i uspoređeni između istraživanih skupina.

**Ispitanici i metode:** 10 posteljica iz trudnoća kompliciranim HELLP sindromom i jednak broj posteljica urednih trudnoća je uključen u studiju. Semikvantitativna HSCORE metoda je korištena za procjenu FasL imunohistokemijskog izražaja, zasebno za EVTB i DC.

**Rezultati:** imunohistokemijski izražaj FasL je bio statistički značajno veći u EVTB i DC u posteljicama trudnoća kompliciranim HELLP sindromom u usporedbi s kontrolnom skupinom posteljica. Nije bilo statistički značajne razlike u FasL izražaju između EVTB i DC u svakoj ispitivanoj grupi posteljica.

**Zaključak:** veći imunohistokemijski izražaj FasL na EVTB i DC u posteljicama kompliciranim HELLP sindromom mogao bi doprinjeti razvoju kliničkih karakteristika HELLP sindroma. Potrebne su daljnje studije s većim uzorkom posteljica kako bi se rezultati ovog istraživanja potvrdili.

## **10. CURRICULUM VITAE**



### *Personal Data*

<b><i>Name</i></b>	Marie Kurtz
<b><i>Address</i></b>	Spinčićeva 25c 21000 Split
<b><i>Date of Birth</i></b>	18/06/1992
<b><i>Place of Birth</i></b>	Stuttgart-Bad Cannstatt

### *Education*

<b><i>2013 - 2019</i></b>	University of Split, School of Medicine
<b><i>2002 - 2011</i></b>	High School Ellentalgymnasien I & II

### *Internships*

<b><i>02.01 – 02.03.2019</i></b>	Erasmus at the Internal Medicine department at the hospital in Bietigheim, Germany
<b><i>06.08 – 26.08.2018</i></b>	Internship at the Traumatology department at the hospital in Bietigheim, Germany
<b><i>04.09 – 24.09.2017</i></b>	Internship at the Internal Medicine department at the hospital in Bietigheim, Germany
<b><i>01.04 – 30.06.2013</i></b>	Internship at the hospice in Bietigheim, Germany
<b><i>19.02 – 22.03.2013</i></b>	Internship in nursing at the hospital in Bietigheim, Germany
<b><i>27.12 – 28.03.2012</i></b>	Internship in nursing at the hospital in Bietigheim, Germany
<b><i>23.01 – 17.02.2012</i></b>	Internship at the psychiatry department for children and young adults at the hospital in Weinsberg, Germany
<b><i>05.12 – 08.01.2012</i></b>	Internship in nursing at the hospital in Winnenden, Germany