

Clinical and radiological outcome after TMT-I- Arthrodesis with medial insertion of angle-stable plates in comparison to a TMT-I arthrodesis with plantar insertion of angle stable plates

Krause, Niklas Marc

Master's thesis / Diplomski rad

2020

Degree Grantor / Ustanova koja je dodijelila akademski / stručni stupanj: **University of Split, School of Medicine / Sveučilište u Splitu, Medicinski fakultet**

Permanent link / Trajna poveznica: <https://urn.nsk.hr/urn:nbn:hr:171:218363>

Rights / Prava: [In copyright](#)/[Zaštićeno autorskim pravom.](#)

Download date / Datum preuzimanja: **2024-07-23**



Repository / Repozitorij:

[MEFST Repository](#)



**UNIVERSITY OF SPLIT
SCHOOL OF MEDICINE**

NIKLAS KRAUSE

**CLINICAL AND RADIOLOGICAL OUTCOME AFTER TMT-I-
ARTHRODESIS WITH MEDIAL INSERTION OF
ANGLE-STABLE PLATES IN COMPARISON TO A TMT-I
ARTHRODESIS WITH PLANTAR INSERTION OF ANGLE
STABLE PLATES**

Diploma thesis

Academic year: 2019/2020

Mentor:

Assist. Prof. Fabijan Čukelj, MD, PhD

Split, July 2020

Table of Contents

1. INTRODUCTION	1
1.1. ANATOMY AND BIOMECHANISM	3
1.1.1. ANATOMY	3
1.1.2 BIOMECHANISM	4
1.2. MECHANISM OF HALLUX VALGUS	4
1.2.1. PRIMARY HALLUX VALGUS.....	5
1.2.1. SECONDARY HALLUX VALGUS	7
1.3. CLASSIFICATION	7
1.4 CLINICAL PRESENTATION	9
1.5. IMAGING AND DIAGNOSIS	10
1.5.1 RADIOGRAPHIC IMAGING.....	10
1.5.2 COMPUTED TOMOGRAPHY (CT) IMAGING.....	10
1.6. TREATMENT	11
1.6.1 CONSERVATIVE THERAPY FOR HALLUX VALGUS	11
1.6.2. SURGICAL TREATMENT	15
2. OBJECTIVE	22
3. MATERIALS AND METHODS	24
3.1. Study design.....	25
3.2. Study population	25
3.3. Methods of collecting and analysing data	26
4. RESULTS	29
.....	39
5. DISCUSSION	41
6. CONCLUSION	45
7. REFERENCES	47
8. SUMMARY	52
9. SUMMARY IN CROATIAN	56
10. CURRICULUM VITAE	59

ACKNOWLEDGMENT

Firstly, I would like to express my profound gratitude and indebtedness to my mentor Assis. Prof. Fabijan Čukelj, MD, PhD for the consistent help, guidance and contributions, throughout this research project.

I wish to thank Prof. Dr. med. Christina Stukenborg-Colsman for her help and wisdom throughout this process and for the providence of the Data

I wish to thank Florian Siermann and the rest of the Annastift team who have helped me with the data collection of this study

I would like to thank my family and especially my mother Dr. Stefanie Rothenberger-Krause, for the support and love they offered me throughout this study

Finally, I would like to thank to all my friends and my Norwegian family, especially my girlfriend Thale Berggren, who have helped me carry some weight throughout this thesis.

LIST OF ABBREVIATIONS

MTP - Metatarsophalangeal

TMT-1 - Tarsometatarsal-I

IMA - Intermetatarsal angle

HVA - Hallux Valgus Angle

VRS - Verbal Rating Scale

FAOS - Foot and Ankle Outcome Score

1. INTRODUCTION

Hallux valgus is the most common foot deformity seen in practice today [1]. Hallux valgus is defined as the subluxation of the first metatarsophalangeal (MTP) joint, which results in first medial prominence and lateral deviation of the proximal phalanx on the first metatarsal [2]. Hallux finds its origin in the Latin word *hallus* which in turn originates from the Greek term hallesthai meaning jumping, due to its property of covering the second digit or jumping on it [3]. It is not just described clinically by the valgisation of the above mention hallux, but can also be described by its appearance in which it is commonly referred to as bunion meaning “bump on the head” (Figure 1) [3]. Hallux valgus is not a problem only our generation and the one before us is faced with, but reaches far into the antique. The closest mentioning of an anatomical description of hallux valgus was during the hellenistic period (323BC - 31BC). Galenos von Pergamon described hallux valgus as an imbalance of muscle forces. He explained that there is no balance between the metatarsals abductors and adductors but an overpowering abduction force [3]. Not only did these early anatomists and scholars try to find an explanation for the pathophysiology of the disease, but also tried to describe its aetiology. The Hippocratic collection, namely the “de fracturis” and “de articulis reponendis” tries to explain why the hallux deformity might occur. The first theory states that a pregnant woman might have had a traumatic incidence to her abdomen, in the second theory they assume that there might be too little space within the uterus of the mother and finally the third theory states that pre and post-natal joint inflammation are responsible [3].

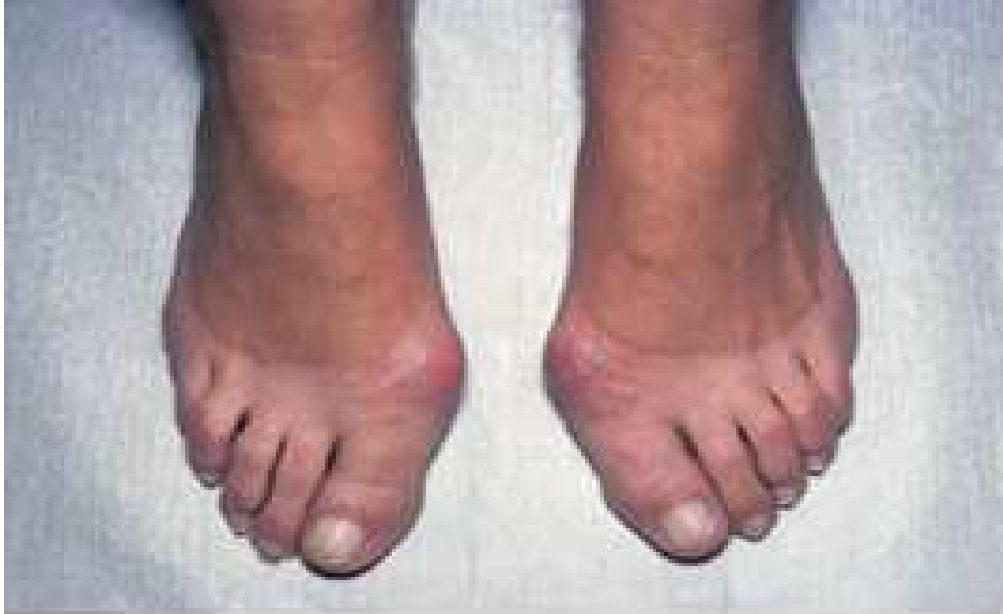

Figure 1. Showing bunion bilaterally, seen as a medially prominence above the Tarsometatarsal-1 (TMT-I) Joint [1].

1.1. ANATOMY AND BIOMECHANISM

1.1.1. ANATOMY

The first MTP joint is an articulation between the head of the first metatarsal bone and the base of the first proximal phalanx. Movements at this joint include flexion, extension, abduction, adduction and circumduction [4]. The first metatarsal is a little different as the head is also transversely convex, allowing for a wider degree of abduction/adduction relative to the other toes. Furthermore, the plantar articular surface of the first metatarsal head is unique as it bears two well defined facets which articulate with the sesamoid bones found within the plantar ligament of the big toe [4]. The joint is surrounded by a joint capsule lined by synovial membrane. The joint capsule is reinforced by three ligamentous structures. These include the collateral, plantar and deep transverse metatarsal ligaments. The plantar ligament of the first MTP joint is replaced by the sesamoid bones which form a channel through which the tendon of the flexor *hallucis longus* runs [4]. Movements at this joint are controlled by the various muscles that run alongside it. Flexion is controlled by the flexor *hallucis longus*, the flexor *hallucis brevis* and partly by the adductor *hallucis* muscle. Extension is controlled by the extensor *hallucis longus* muscle, adduction by the Adductor *hallucis*, and Abduction by the Abductor *hallucis* muscle [4].

1.1.2 BIOMECHANISM

The hallux valgus deformity is defined by a lateral deviation and rotation of the first toe leading to a medial prominence at the level of the MTP joint termed bunion [3]. The lateral deviation of the phalanges may lead to other forefoot abnormalities due to its laterally directed force onto the second to fifth phalanges. This may result in overriding of the adjacent toes. In more severe hallux valgus deformity, the first toe rotates into a pronated position (nail faces medially), leading to displacement of the sesamoid bones of the flexor *halluces brevis* laterally [1]. The flexor and extensor *halluces longus* are also displaced laterally which results in tendon misalignment along the joint and an excess lateral pull on the phalanx [1]. James Kuhn divides hallux valgus deformity into four stages [6];

- Stage 1: Lateral displacement of the hallux at the MTP joint
- Stage 2: Progression of the hallux abduction (hallux pressing against the second toe)
- Stage 3: Increased intermetatarsal angle (IMA), possible associated second hammertoe deformity
- Stage 4: Partial/Complete hallux dislocation at the MTP joint.

A comparative retrospective study was performed in Hong Kong. This study included patients with symptomatic hallux valgus between 2008 and 2013, the radiologic degree of deformity was analysed at presentation and pre-operatively. The study suggests that severe hallux valgus deformity progresses over time [7].

The bunion is created by subluxation of the MTP joint, and increased pressure due to shoes may lead to bursa formation and soft tissue thickening above the joint. Complications of MTP joint subluxation and deformity of the first toe include osteoarthritis and osteophytes as well as long standing hallux rigidus (painful first toe) [1,8].

1.2. MECHANISM OF HALLUX VALGUS

Hallux valgus has a very ambiguous aetiology. There is a variety of studies that show associations between certain social behaviours as well as medical conditions and hallux valgus. Perera et al. fittingly mention a variety of possible causes including; Genetic predispositions

for a nonlinear osseous alignment or laxity of the static stabilisers disrupting muscle balance, poor footwear, as well as inherent or acquired biomechanical abnormalities [9]. They state however that these associations are incomplete and nonlinear, and the cause for hallux valgus could be a combination of the former mentioned. Further on, they suggest that a clear aetiology could aid in a more individualised treatment (conservative or surgical) of the patient with hallux valgus [9]. When studying the possible aetiologies' and the associated studies, it appears they can be organised into two major groups. The primary aetiologies' including footwear, hereditary causes and metatarsus primus varus, as well as the secondary aetiologies' including polyarthritis associated hallux valgus.

1.2.1. PRIMARY HALLUX VALGUS

1.2.1.1. Footwear

There is a common association between modern footwear and the formation of hallux valgus. According to Solomon, Warwick and Nayagam there is a predisposition in those wearing shoes, even more so in those wearing high heels [1]. The first metatarsal is forced into a valgus position and the phalanges are deviated laterally, due to the pointed nature of the shoes. In high heels, the first toe is pushed with greater force into the pointed shoe, thus leading to a higher likelihood of deformity [1]. Kato and Watanebe studied the effect of footwear on the formation of hallux valgus. They observed that before April 1979 there has been no report of hallux valgus at the annual meetings of the Japanese orthopaedic association. They believe to see a relationship between the six-fold increase in leather shoe production between 1960 and 1975 in Japan and the proportionate increase in hallux valgus, often severe hallux valgus, in the Japanese population [10]. Klein et. al. studied the relationship between children wearing shoes of insufficient length and congruent lateral deviation of the hallux in the Austrian population. The study found a significant increase in the relative risk in children wearing shoes of insufficient length [10]. Finally, Soemmarko et al. studied the incidence of hallux valgus in sales promotion women wearing high heels versus those wearing flat shoes. They found that the subjects wearing high heel shoes are 2.77 times (95%CI: 1.25-6.15; $P = 0.01$) more likely to develop hallux valgus [12].

1.2.1.2. Metatarsus Primus Varus

Metatarsus Primus Varus is defined as a medial angulation of the first metatarsal, increasing the angle between the first and second metatarsal, and is associated with pes transversoplanus. It may be congenital or due to loss of muscle tone in the elderly [1]. Lapidus who promoted the lapidus or tarsometatarsal-1 (TMT-1) arthrodesis for hallux valgus between 1930-1960 stated that metatarsus primus varus is one of the main causes and most prominent factors of hallux valgus [13]. Kilmartin, Wallace and Barrington performed a survey on 6000 school children, in which they found that metatarsus primus varus was found not only in the early stages of hallux valgus but in the unaffected feet of children with unilateral hallux valgus as well [14]. This may suggest that Metatarsus Primus Varus predisposes to hallux valgus and is not merely associated with it.

1.2.1.3. Hereditary

Heredity has been proven to be an important factor for the development of hallux valgus. Solomon, Warwick, and Nayagam suggest that 60% of patients with hallux valgus have positive family history for the disease [1]. Pique-Vidal et al. found that in his 350 patients with hallux valgus, 90% had a positive family history for the disease [15]. This number is supported by Coughlin and Jones, who found that 83% of the 103 patients included in his study, had a positive family history [16]. Even though the mode of inheritance and the genes involved are still to be determined, studies have tried to find associations. Pique-Vidal et al. have discovered that in this patient group there is vertical transmission, affecting some family members across three generations, suggesting an autosomal dominant inheritance with incomplete penetrance [15]. In a genome wide meta-analysis, the researchers have identified a novel locus in the intrinsic region of CLCA2 on chromosome 1, which is an expression quantitative trait locus for COL24A1, a member of the collagen gene family. The functional role of this locus is yet to be determined, but suggests that heredity is a determining factor in the development of hallux valgus [17].

1.2.1. SECONDARY HALLUX VALGUS

Secondary hallux valgus is a hallux valgus that is the result of other diseases. The most common of which is rheumatoid arthritis [1]. Solomon, Warwick and Nayagam explain that rheumatoid arthritis may lead to weakness of the MTP joint capsule and ligaments, leading to hallux valgus deformity [1].

Other secondary causes include neurological disorders [18]. Klingensmith suggests that in diabetic patients, peripheral motor neuropathy is associated with abnormal weight bearing of the foot. Specifically, weight bearing is shifted more proximally, where normally it lies on the metatarsal head. This abnormal weight bearing can lead to hallux valgus [18].

Primarily one can conclude that if there is no clear secondary cause of hallux valgus deformity, the formation of hallux valgus seems to be multifactorial with no clear single aetiology.

1.3. CLASSIFICATION

The classification of hallux valgus is based on radiologic findings and is divided into 3 groups; mild, moderate and severe (Table 1). The classification is based on two angles. The IMA and the hallux valgus angle (HVA) [19,20]. The IMA is the angle between the first and second metatarsal shaft on an axial view (Figure 3). The HVA is formed by drawing a line through the shaft of the first metatarsal, which intersects with that drawn through the shaft of the first proximal phalanx, the angle at the intersection between those two lines is measured (Figure 3). Dohle et al. explains that the classification of hallux valgus is part of the decision making process of clinicians when deciding which surgical technique to use (Figure 2) [19].

Algorithmus

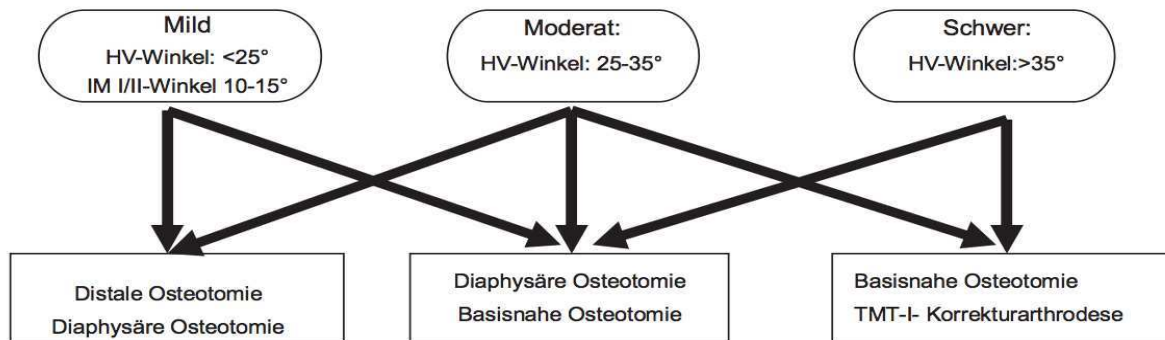


Figure 2. The algorithm in which surgeons chose which surgical procedure to perform on patients with hallux valgus based on the HVA and IMA (Winkel = angle, Algorithmus = Algorithm, Schwer = severe, Basisnahe osteotomie = osteotomy that is close to the base of the metatarsal, Korrekturarthrodese = correctional arthrodesis, Diaphysaere =diaphysial, Distale = distal) [19].

Table 1. Classification of Hallux valgus deformity based on the IMA and HVA [6].

	Normal	Mild	Moderate	Severe
IMA	< 9°	9°-13°	13°-20°	>20°
HVA	< 15°	15-30°	30°-40°	>40°

Abbreviations: IMA-Intermetatarsal angle; HVA – hallux valgus angle

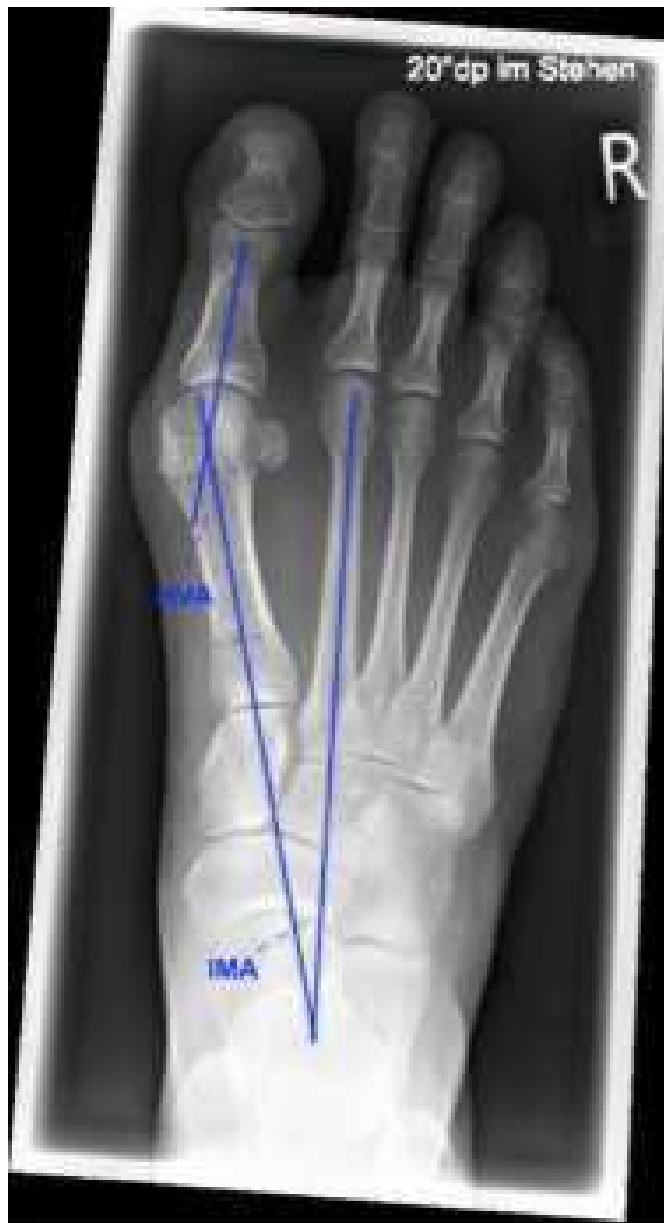

Figure 3. HVA and IMA measurement as described in complication section of introduction. Source is a radiologic image from study.

1.4 CLINICAL PRESENTATION

The primary complaints associated with hallux valgus can be subdivided into three parts. First of all, the cosmetic character, where the patient may have problems due to the former mentioned bunion. Cosmetics however should not be an indication for surgery, as the risk benefit ratio is too high [20]. Secondly there is difficulty fitting shoes and the pain when wearing

the wrong shoes due to the friction and pressure it creates above the bunion. Finally, the most severe complaint is pain. The characteristic pain is medial plantar and dorsal above the MTP-I-joint. As a result of the deformity the patient starts transferring the main force exerted by the bodies weight laterally onto the other four toes. This results in transfer metatarsalgia at the height of the metatarsal heads of digits one to four [21]. The second reason for pain in patients with hallux valgus may be the development of hallux rigidus which is essentially osteoarthritis in the MTP-I-Joint, leading to pain especially when walking [1].

1.5. IMAGING AND DIAGNOSIS

1.5.1 RADIOGRAPHIC IMAGING

In current practice radiographs are the imaging technique of choice for the diagnosis of hallux valgus [22]. The classic radiographs used, are those of anteroposterior (AP), lateral and oblique view. There are two angles which are utilised from the images gained, which are important for the classification of hallux valgus. These are the HVA and the IMA [19,20]. The validity of radiographic imaging in the diagnosis of hallux valgus, was confirmed by a study performed by Coughlin, Freund and Roger. The purpose of the study was to see how accurate different physicians measure the HVA and IMA on the same radiologic images. The physicians in this study were given black and white photographs of radiographs with a hallux valgus deformity. Three different sets of randomly ordered photographs were sent to the participants. The study found that for the IMA, 96.7% of the measurements were within a range of five degrees. They found that HVA measurement was less reliable, where 86.2% of the measurements were within five degrees. Coughlin and Freund concluded that their study validates the use of radiologic measurement of HVA and IMA in clinical practice [23].

1.5.2 COMPUTED TOMOGRAPHY (CT) IMAGING

According to Welck and Al-Khudairi, conventional CT can provide more information in complex cases of hallux valgus [22]. They state however that conventional CT is non weight bearing. In order to overcome this issue three-dimensional, weight-bearing cone beam CT was implemented, which offers three-dimensional imaging while weight bearing. They propose that traditional radiographs have problems accurately imagining sesamoids in hallux valgus, which

are essential for pre-surgical determination of the rotational component of the first metatarsal [22]. Axial radiologic views can determine the sesamoid position, but in order to do so must be dorsiflexed variably between 40° and 75°. According to Welck and Al-Khudairi the position of the sesamoids changes with dorsiflexion [22]. Welck et al. propose that all the existing methods for the evaluation of the sesamoid displacement in hallux values have limitations. In their study they evaluated the reproducibility of accurate sesamoid displacement in standing CT. They found that the standing CT has shown to be a reproducible and accurate method for the assessment of sesamoid displacement [24]. In a third study by Collan, Kankare and Mattila weight bearing two-dimensional and three-dimensional CTs were produced, in order to determine the HVA and IMA in 10 patients with hallux valgus and five asymptomatic controls. The measured angles in the weight bearing CTs were compared to angles measured on plain radiographs. The results of their study suggest, that weight bearing CT offers a true alternative to plain radiographs [25].

1.6. TREATMENT

1.6.1 CONSERVATIVE THERAPY FOR HALLUX VALGUS

The three main goals in non-operative treatment of hallux valgus are; preventing the progression of the deformity, cushioning and stabilising of the present deformity and redistribution of weight onto the rest of the foot [26]. Conservative therapy, with the goal of stopping or slowing the lateralisation of Hallux valgus is still seen as the first option. There are a variety of conservative therapies available. A survey was conducted comparing the different conservative measures prescribed by Australian podiatrists (Figure 4) [27]. Some of the more common prescribed therapies seem to be;

1. Custom made orthosis (Hallux orthosis, toe separator, Insoles)
2. Prefabricated orthosis (Hallux orthosis, toe separator, Insoles)

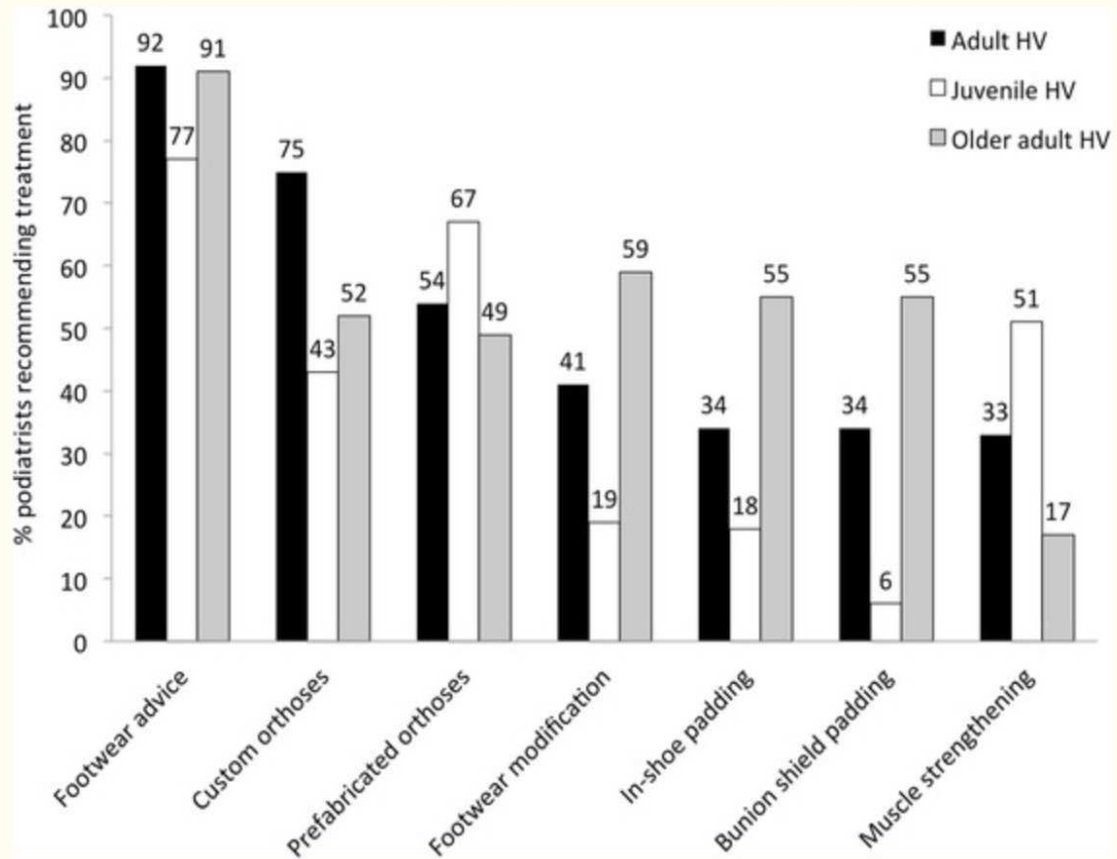


Figure 4. Showing the most common prescribed conservative measure for hallux valgus (HV) in three separate population groups (Adult, Juvenile, Older Adult) in a study performed by Australian podiatrists [27].

There is a high prevalence of these techniques in general practice and one or a combination of these, are generally used as primary therapy for hallux valgus. Its efficacy however is still questionable. The primary role seems to be symptomatic relief and especially in juvenile cases, slowing the process of the development of symptomatic hallux valgus [28].

1.6.1.1 Hallux Orthosis

The specific goal of orthotic treatment is to support the weight bearing function of the medial column and diminish the shear and bending movements at the TMT-I joint [26]. There are a variety of hallux orthosis available, but typically practitioners start with a Morton extension orthosis (Figure 5). As the deterioration of the joint and the pain progresses, they switch to a more rigid material such as fibreglass [26]. Orthotic devices however, still seem to have little therapeutic value compared to surgery. A randomised control trial conducted in

Finland measuring the improvement in pain in patients with a painful bunion, showed that orthotic devices were inferior in the treatment of hallux valgus compared to surgical treatment. It found that surgical osteotomy is an effective treatment for primary Hallux valgus, whereas orthosis only provides a short-term symptomatic relief [29].

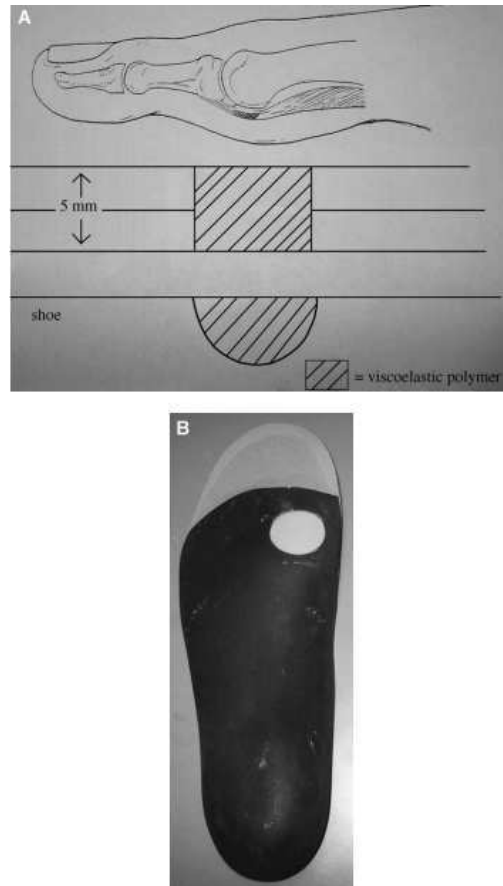


Figure 5. (A) Showing the mechanism of the Morton extension orthosis in that it extends the first phalanx during gait and thus limits the motion at the first MTP joint, limiting pain with walking. (B) Morton extension orthosis with the white spot being the point of elevation [26].

6.1.1 Insoles and Toe separators

Custom made insoles and toe separators are a viable option in the treatment of Hallux valgus. Toe separators are aimed at preventing the progression of deformity and alleviate symptoms [26]. Commonly toe separators are made from silicone, these can be both prefabricated or custom made (Figure 6) [26]. In order to test for the efficacy of custom made silicone toe separators, a randomised single-blinded controlled trial was completed. The study found that patients using toe separators, had a reduction in both the HVA and pain [30]. Insoles

are a further option in the conservative therapy of hallux valgus. Wülker and Mittag suggest that insoles are effective for reducing pain in metatarsalgia [20]. They function by pushing the metatarsals upward proximal to the pressure-sensitive heads, alleviating pain [20]. In order to measure the efficacy of toe separators and insoles, a comparative was performed. In this, night splints, insoles and toe separators were compared based on post treatment pain and improvement in the HVA. It found that night splints seem to have no effect on pain reduction and Hallux valgus deformity, whereas insoles and toe separators were shown to have a significant effect on pain reduction, however also no effect on the HVA [31].

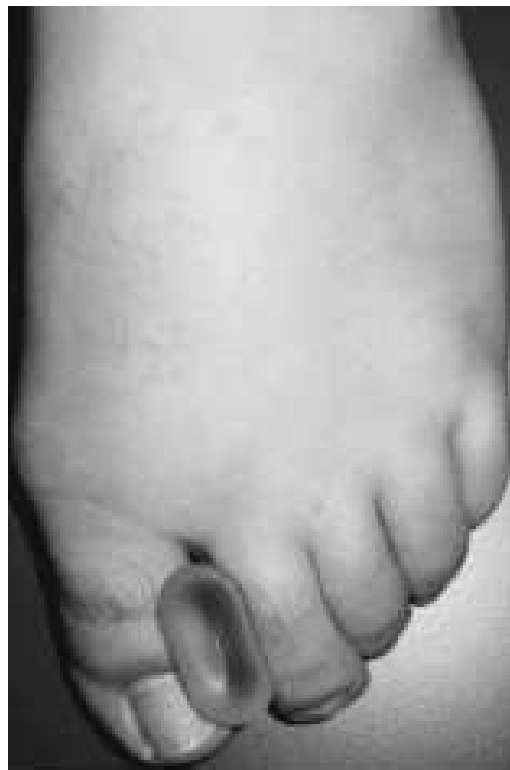

Figure 6. This image shows a toe separator used for the conservative therapy of hallux valgus [26].

From all this it can be concluded that there is no concrete evidence pointing towards conservative therapy as a sole entity for the treatment of Hallux Valgus. However, it may lead to significant pain reduction and in some cases even to a decrease in the HVA [30].

1.6.2. SURGICAL TREATMENT

The indications for surgery are typically of clinical origin. The patient complains of pain that is not alleviated by a change in shoes or by other, earlier mentioned, conservative therapy. The patient must also complain of pain that is regular in occurrence and impairs function. If the pain arises from other digits, as in the case of transfer metatarsalgia, both the hallux valgus and the digit deformity must be corrected [20]. The foot, especially the distal foot, is the part of the body that is furthest from the heart [4]. Impaired healing and postoperative complications due to impaired perfusion may occur. The major complications of hallux valgus surgery are typically related to either healing impairment or abnormal correction of the hallux valgus [20]. The first complication to mention is non-union or pseudoarthrosis. Non-union occurs if two bones fail to consolidate, there is an arrest in the repair process which can be visualised on radiographic imaging. This can occur after TMT-I arthrodesis surgery for hallux valgus [32]. Pseudoarthrosis is caused by formation of fibrous tissue in the space between the bones that failed to fuse, resembling a fibrous joint [1,5]. Delayed Union in turn is defined as progression towards union, but it has not healed in the expected amount of time [33]. Other complications include osteonecrosis of the Metatarsal-I head, overcorrection leading to hallux varus, decreased mobility of the TMT-I joint, and lesions of the muscle tendons with function impairment [20]. Willegger et al. found that in a systematic search of twenty-nine studies with a total amount of 1,470 operated feet, the complication rate was 16.05 % and the non-union rate was 4.01 % [34]. Secondly a study by Kromuszczynska, Kolodziej and Jurewicz found that there is no significant difference in complications of hallux valgus surgery between healthy individuals and those with systemic disease (hypertension, hypothyroidism and diabetes). However, they also expressed that 19.4% of the patients undergoing hallux valgus surgery had post-surgical complications such as wound dehiscence and surgical site infections [35]. This is also expressed by Wülker and Mittag, who state that systemic disease such as diabetes is not a definite contraindication for surgery. They suggest that the most common contraindication is arterial occlusive disease due to the increased risk for the former mentioned perfusion related complications [20].

There are more than 100 operations described for Hallux valgus in literature [36]. The most common of these can be divided into three groups according to their indication (Figure 5). This is based on objective findings in the form of the IMA and HVA, stating that the higher the angles the more proximal the operation [20]. There are different kinds of correctional operations which may be performed in addition to those corresponding to hallux valgus. A study

performed by Iselin et al. explored the surgical management of hallux valgus of Swiss orthopaedic surgeons. It found that in moderate hallux valgus distal chevron was the most commonly chosen with 41%. Scarf osteotomy with 36%, was the second most commonly chosen. In severe hallux valgus, TMT-I (lapidus) arthrodesis was the most commonly chosen, with 31%, whereas 21% preferred the MTP-I arthrodesis [37].

Solomon, Warwick, and Nayagam propose that surgical treatment of hallux valgus can be divided into two major groups. Those patients with a mild hallux valgus should undergo soft tissue realignment also termed lateral release. In this procedure the tight structures on the lateral side (*adductor hallucis*, transverse metatarsal ligament, and lateral joint capsule) are lysed, the prominent bone on the medial side of the metatarsal head is removed and the capsule on the medial side is sutured [1]. In moderate to severe hallux valgus, if the MTP joint is congruent, a distal osteotomy in combination with an akin osteotomy should be performed [1]. For greater deformities, if there is subluxation of the joint, a proximal metatarsal osteotomy is indicated [1].

1.6.2.1. Metatarsal osteotomies

Typically, osteotomies are combined with the formerly mentioned lateral release. The osteotomy is reinforced by a plates, screws or osteo-sutures [36]. The two most commonly used osteotomies, as stated by Iselins et al. study, are scarf osteotomy and chevron osteotomy [37]. These procedures are commonly combined with akin osteotomy [36].

1.6.2.1.1 Scarf osteotomy

Scarf osteotomy was popularised in the 1990s by Weil and later by Barouk. The term originates from the English translation of “le trait de Jupiter des charpentiers”. This technique was originally used by carpenters and reveals a Zeus like lightning spear (in French Jupiter is Zeus) [36]. Scarf osteotomy is a combination of procedures, which includes median eminence resection and medial capsular plication, metatarsal osteotomy, lateral soft tissue release and if required Akin osteotomy [38]. The osteotomy results in a Z shaped bone fragment which offers good stability and requires fixation with two screws (Figure 7). It can be manipulated allowing lateralisation of the head-shaft fragment to reducing IMA. In addition, it maintains joint congruence and thus motion of the first MTP joint [36]. The applicability of Scarf osteotomy

for surgery of hallux valgus was portrayed by a study performed by Choi et al.. She studied the outcome of Scarf osteotomy with soft tissue realignment in 51 patients (53 feet), who were followed for at least 1 year. She found that Visual Analogue Scale pain scores decreased from 5.8 preoperatively to 1.1 postoperatively and the mean preoperative HVA decreased from 29 degrees preoperatively to 10.6 degrees after the last follow up. She concluded that Scarf osteotomy is a reliable technique for the treatment of moderate to severe hallux valgus [39].

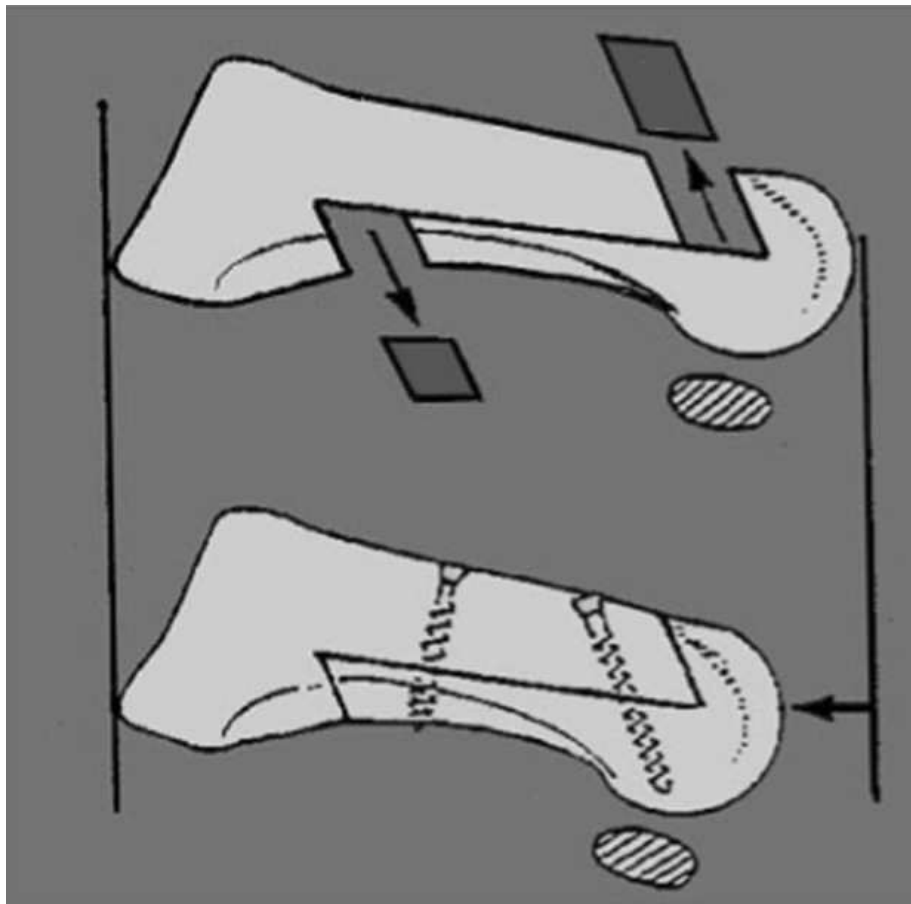


Figure 7. Scarf Osteotomy. The image is showing how on both ends of the metatarsal a piece is cut out and the reattached forming a Z shaped alignment [40]

1.6.2.1.2. Chevron osteotomy

Chevron osteotomy was proposed in 1962 by Austin. The metatarsal head is shifted laterally and is stabilised with a screw in order to prevent mal-union or non-union (Figure 8). Chevron osteotomy was considered the gold standard for surgical treatment of hallux valgus by the American Academy of Orthopaedic Surgeons in 2007 [36]. Hendrix and Davis found that

in their retrospective study of 50 chevron osteotomies, satisfactory subjective cosmetics was achieved in 98% of patients and excellent or good pain relief in 84% of patients. They found that the complications were generally mild and asymptomatic and usually iatrogenic. From this study they concluded that distal chevron osteotomy is a recommendable operative technique [40].

Deenik et al. randomly divided two patient groups of a total of 83 patients with hallux valgus. The two groups consisted of 49 patients who got a scarf osteotomy and 47 patients who got a chevron osteotomy. They measured the Orthopaedic Foot and Ankle Society Hallux Valgus Scale and radiographic HVA and IMA at 27 months follow up. They found that there were no differences of statistical significance measured between the groups. They however state that they favour the chevron osteotomy because the procedure is technically less demanding [41]. This may explain why in the previously mentioned study of Iselin et al. there was slightly more Chevron osteotomies being performed than Scarf osteotomies [37].

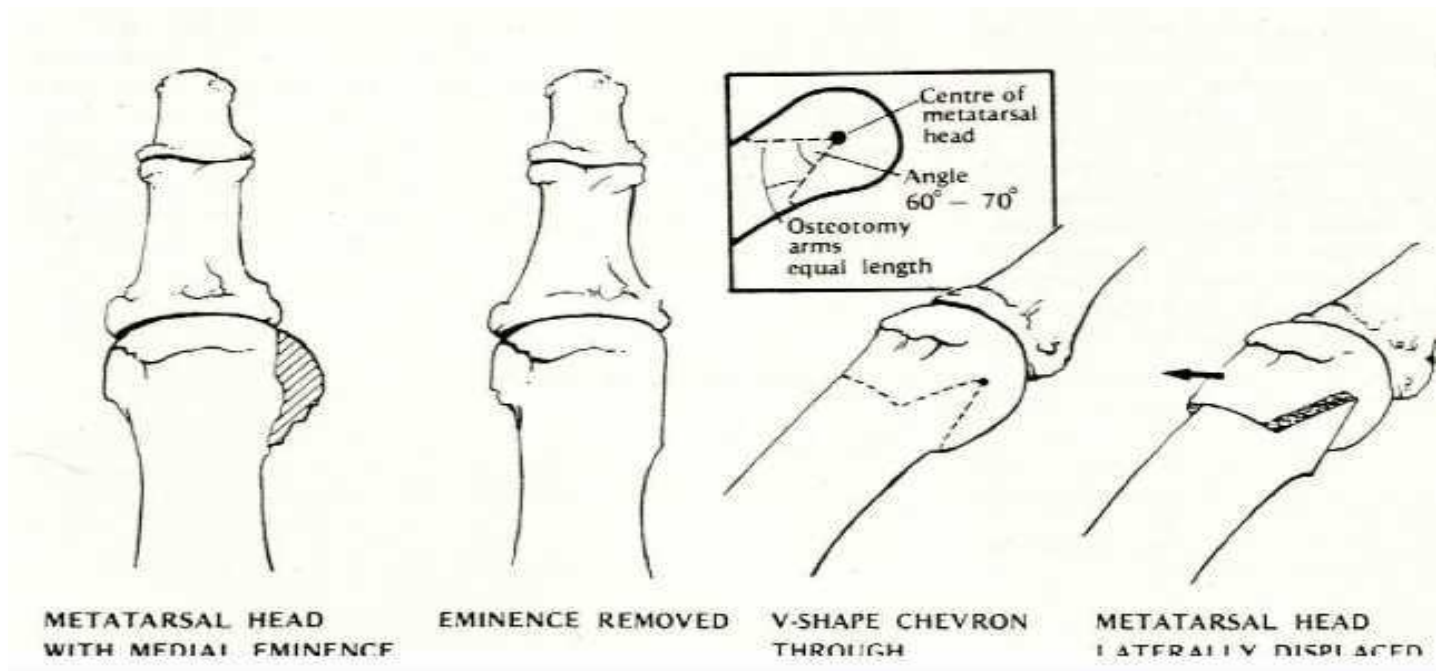


Figure 8. The 5 steps in the distal chevron osteotomy procedure. The first image from the left shows the metatarsal head with a medial eminence. The first step in the procedure is to remove the medial eminence (image 2 from the left). Next A v shaped cut is performed below the metatarsal head (image 3 from the left) and the head is displaced laterally in order to realign the MTP joint (image 4 from the left) [40].

1.6.2.2 TMT-I-arthrodesis (*lapidus arthrodesis*)

The TMT-I-arthrodesis was first described by Paul Lapidus in 1931. As formerly mentioned it is used in severe hallux valgus deformity (Figure 5) and with concomitant Metatarsus Primus Varus and an increased IMA. Lapidus originally described the procedure as a fusion between the base of the first and second metatarsal in addition to a fusion of the first TMT joint [42]. The modified lapidus procedure (TMT-I-arthrodesis), consists of an isolated fusion of the TMT-I joint [36]. The efficacy of modified lapidus arthrodesis was described by Grace et al., who assessed both radiologic and clinical presentation 61 months' post-surgery. They found that 27 of the 30 assessed feet (90%) had either a good or excellent results [43]. Complications of the lapidus arthrodesis include Pain, wound healing related complications and pseudoarthrosis [20]. Taylor and Metcalfe studied the outcome of 18 patients who underwent a lapidus arthrodesis. They found that only two patients had complications, one had poor pain control and the other had post-operative bleed. They found that in all 18 patients there was

osseous union. They came to the conclusion that lapidus arthrodesis is a procedure with few complications [44].

There are a variety of fixation techniques for TMT-I arthrodesis. The use of plating constructs has been shown to provide increased stability compared to screw only constructs [45]. A variety of plating techniques exist, including medial, dorsal and plantar plates. A study by Burchard et al. compared dorsal locking plates, plantar locking plates and intra-medullary fixation devices. They found that the plantar locking plates showed the best overall stability during weight-bearing simulation [46]. A study by Klos et al. assessed the biomechanics of both medial and plantar locking plates on a cadaver. They suggested that any significant differences observed were in favour of the plantar constructs. It displayed a smaller range of motion ($P = 0.028$), and a greater load to failure ($P = 0.043$). Thus the biomechanics of the plantar plate seem to be superior in this study [47].

1.6.2.3 Akin osteotomy

Akin osteotomy was first described in 1925 as a proximal phalanx medial closing-wedge osteotomy with minimal fixation (Figure 9). Nowadays multiple fixation techniques exist including suture, wire, screw and staple fixation [36]. Akin osteotomy is often performed in addition to other hallux valgus surgeries [36]. Kaufmann et al. compared the radiological outcome of a 184 patients undergoing a scarf osteotomy without Akin osteotomy to 63 patients where Akin osteotomy was performed in addition to scarf osteotomy. He found that the radiological outcome suggested that scarf osteotomy is superior when having a concomitant Akin osteotomy [48].

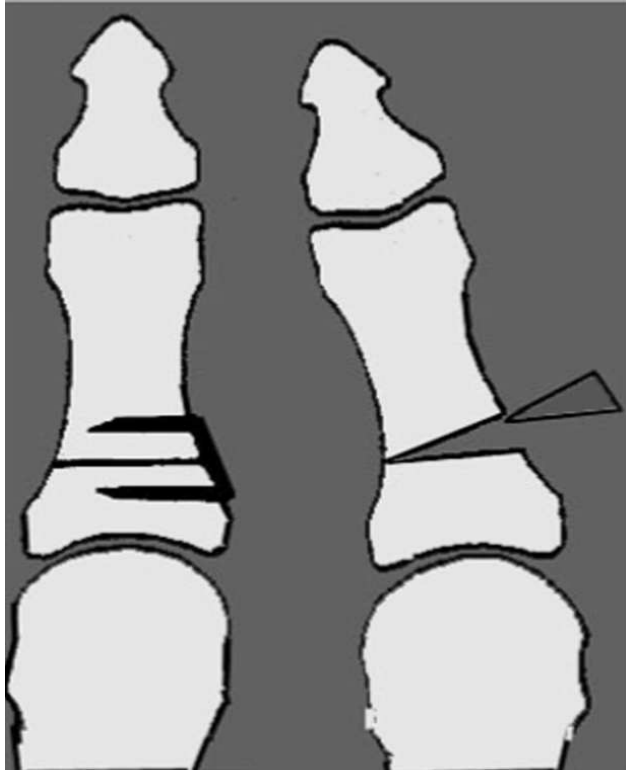


Figure 9. Akin osteotomy Image shows the wedge shaped cut and removal of the piece of that piece of the proximal phalanx of the first metatarsal in order to realign the toe distal to the MTP joint (right image). Then this osteotomy is fixed (left image) [36].

2.OBJECTIVE

In this prospective study the goal was to determine whether there is a difference in outcome when performing larpidus arthrodesis with plantar tri-lock plates versus medial tri-lock plates, based on:

1. Differences in Radiologic findings including IMA, HVA and the degree of consolidation (no consolidation (non-union), delayed consolidation and complete consolidation)
2. Foot and ankle outcome score (FAOS)
3. Verbal Rating Scale (VRS) for pain

3. MATERIALS AND METHODS

3.1. Study design

This study is a prospective, non-randomised study. Each patient was given a case number and the initials of the patient were added to allow for the integrity of the patient. The recruitment of the patients occurred during a workday, before the operation during the admission at the Diakovere Annastift Hannover. Before the recruitment patients were selected based on their patient file. During the admission, patients were tested for presence of the inclusion and exclusion criteria. After agreement of the patient to be included in this study, the patient signed a form of consent.

3.2. Study population

In the department for foot and ankle surgery of the Diakovere Annastift Hannover over a time period between November 2018 and December 2019, 13 patients were included into this study, based on the inclusion and exclusion criteria listed below. The study population included 12 females and 1 male, with patients having an average age of 53. There were 7 patients who's lapidus arthrodesis was performed with a plantar plate. This patient group included 1 male and 6 females with an average age of 54. There were 6 patients who's lapidus arthrodesis was performed with a medial plate. This patient group included 6 females with an average age of 52.

3.2.1. Inclusion criteria

- Symptomatic Hallux Valgus that will be surgically corrected using a TMT-I-Arthrodesis
- Primary surgical intervention

3.2.2. Exclusion criteria

- Age below 18
- Constraint to a wheelchair
- Further diagnosed arthrosis (TMTII/III, navicular-calcaneal (NC) joint, talonavicular (TN joint))
- Relevant deformity of the midfoot or hindfoot
- Previous operative intervention for the correction of the hallux valgus
- Previous revision surgeries

3.3. Methods of collecting and analysing data

The radiologic and clinical assessment in this study included four separate points in time, when data was collected. The first data was gathered the work day before the operation during the admission. The other three points in time when data was collected for this study were the follow up examinations, which were performed after 6 weeks, 12 weeks and 1 year. All follow ups included an anamnesis, inspection and physical examination. Radiologic images were evaluated and the questionnaires were filled out in the waiting room.

3.3.1. Operation

The operation included exposing the MTP-I joint and removal of the articular cartilage of both the base of the MT-I and cuneiform using an oscillating saw. Next the operation included repositioning and temporary fixation of the TMT-I joint using kirshner wires. The repositioning was then confirmed using an intra-operative radiologic imaging device. After confirmation of correct positioning, a cannulated screw was introduced over the kirschner wire. The kirshner wires were removed and a medial or plantar plate was used to connect the base of the MT-I to the cuneiform. These plates were APTUS[®] foot trilock TMT-1 Mediale fusionplate 2.8 or the APTUS[®] foot trilock TMT-1 plantar fusionplate 2.8 of the Medartis company. Finally, the capsule was closed, the muscle tendon of the abductor hallucis, which was cut for exposure of the TMT-I joint, is reattached accordingly and the wound was closed. Based on

preoperative and intraoperative findings an Akin osteotomy as well as correction of other toe abnormalities, with their according operations, was performed.

3.3.2. Questionnaires

The questionnaire was given to the patient at the former mentioned 4 timeframes. These questionnaires were helpful for the patient to give his/her subjective opinion on his/her well-being. This was achieved by two separate findings, the FAOS and the VRS for pain.

3.3.3. FAOS:

FAOS consists 42 question divided into 5 sub-scales;

1. Pain
2. Symptoms other than pain
3. Activities of daily living
4. Sport and recreational function
5. Foot and ankle related quality of life

Each question gets a score from 0 to 4. Each sub-scale is converted into a normalised score giving a number between 0 and 100. 100 indicates no problems and 0 indicates extreme problems. Chen et al. confirmed the validity of using FAOS for assessment of treatment outcome. They included 195 patients with non-arthritic hallux valgus into their study and found that the FAOS is reliable, valid and responsive and is thus a good tool in testing outcome of orthopaedic interventions [49].

3.3.4. VRS

The VRS is a subjective finding that was used in this study, to assess pain in the timeframes mentioned earlier. Patients were given a choice between 0 and 10, 0 being no pain and 10 being the strongest pain imaginable. For this the patient was asked to put a cross on a 10-centimetre-long line, where on one end it said “keine schmerzen” (no pain) and on the other “stärkster vorstellbarer schmerz” (strongest pain imaginable). In addition to this we asked the patient if he/she uses any analgesics for pain relief.

3.3.5 Radiologic assessment:

This study included a weight bearing radiograph in two planes, anteroposterior (AP) and lateral. Imaging was performed preoperative and postoperative after 6 weeks, 12 weeks and 1 year. The analysis and archiving of the images was done with the computer program called picture archiving and communication system (PACS). The analysis of the images included the HVA, IMA and the Consolidation of the TMT-I joint adjacent to the plate. The HVA and IMA were obtained as explained in the earlier section and interpreted according to Table 1. Consolidation is divided into 3 groups; non-union or pseudoarthrosis, delayed union and complete consolidation. Pseudoarthrosis or non-union is defined as failure of the fracture to heal within 6-8 months, whereas delayed union is defined as a fracture that is not completely healed within 6 months [50]. The presence of non-union and delayed union was established within this study through a clinical examination, in which the stability of the TMT-I joint was established, in addition to searching for radiologic signs of non-union. These include a lucent line that is persistently present between the bone fragments as well as callus either trying to bridge the gap but failing or not being present at all [1]. Within this study the level of consolidation was measured 1 year after surgery and then grouped into 0,1 and 2 according the former mention 3 groups of consolidation respectively.

3.4. Statistical analysis

By using former mentioned data and further analysis of the data, figures and tables were fabricated to fulfil the objective of this study. Microsoft Excel, version 2016 (Microsoft Excel Software, Redmond, Washington, USA) and Numbers 10.0 (Apple Numbers software, Cupertino, California, USA) were used to make the analysis, tables and figures for this study. Variables were presented as whole numbers or as mean \pm SD. For testing the difference between continuous variables the t-test was used, from which the p-value was deducted. Statistical significance of this study was defined as $P < 0.05$.

4. RESULTS

Between November 2018 and December 2019 Thirteen patients with hallux valgus were indicated for lapidus arthrodesis by the department for foot and ankle surgery of the Diakovere Annastift Hannover and included into this study.

4.1. FAOS

The foot and ankle outcome score (FAOS) displays subjective patient satisfaction in 5 different categories ranging from 0-100. In all 5 categories both the patients receiving the medial plates (Table 2) and the patients receiving the plantar plates (Table 3) showed improvement in the mean outcomes comparing preoperative findings with those found in the 1 year follow up. For the patients receiving the plantar plates the preoperative mean pain score was 61.90 ± 20.45 ($P = 0.325$), the mean symptom score was 74.49 ± 22.22 ($P = 0.285$), the mean activities of daily living score was 72.27 ± 22.60 ($P = 0.76$), the mean sport and recreational function score was 55.71 ± 28.46 ($P = 0.746$) and finally the mean quality of life score was 37.50 ± 11.57 ($P = 0.79$) (Table 2). In the one year follow up these scores improved, the mean pain score improved to 91.67 ± 6.96 ($P = 0.179$), the mean symptom score improved to 90.31 ± 22.22 ($P = 0.593$), the mean activities of daily living score improved to 93.71 ± 22.60 ($P = 0.38$), the mean sport and recreational function score improved to 81.43 ± 15.59 ($P = 0.891$) and finally the mean quality of life score improved to 84.82 ± 16.66 ($P = 0.347$) (Table 3). For the patients receiving the medial plates the preoperative mean pain score was 51.39 ± 16.33 ($P = 0.325$), the mean symptom score was 85.12 ± 9.88 ($P = 0.285$), the mean activities of daily living score was 68.38 ± 22.12 ($P = 0.76$), the mean sport and recreational function score was 50.83 ± 24.57 ($P = 0.746$) and finally the mean quality of life score was 39.58 ± 15.17 ($P = 0.79$) (Table 4). In the one year follow up these scores showed improvement, the mean pain score improved to 84.72 ± 9.72 ($P = 0.179$), the mean symptom score improved to 86.9 ± 9.15 ($P = 0.593$), the mean activities of daily living score improved to 96.81 ± 22.12 ($P = 0.38$) the mean sport and recreational function score improved to 82.5 ± 11.81 ($P = 0.891$) and finally the mean quality of life score improved to 76.04 ± 15.49 ($P = 0.347$) (Table 5). Even though both groups showed improvements in all FAOS subgroups the patients receiving the plantar plate had higher scores in most categories and higher scores in pain and quality of life in the one year follow up (Figure 10). The patients receiving the medial plates however showed better outcomes in activities of daily life and sport and recreational function (Figure 10).

Table 2. Preoperative FAOS in patients receiving the plantar tri-lock plates

Patient	Preoperative FAOS				
	Pain	Symptoms other than pain	Activities of daily living	Sport and recreational function	Foot and ankle related quality of life
1	55.56	85.71	69.12	45.00	31.25
2	58.33	82.14	70.59	60.00	43.75
3	61.11	78.57	94.12	75.00	50.00
4	36.11	89.29	27.94	5.00	18.75
5	100.00	96.43	100.00	100.00	50.00
6	80.56	64.29	85.29	70.00	43.75
7	41.67	25.00	58.82	35.00	25.00
Mean ± SD	61.90 ± 20.45	74.49 ± 22.22	72.27 ± 22.60	55.71 ± 28.46	37.50 ± 11.57
<i>P</i> *	0.325	0.285	0.76	0.746	0.79

Data is presented as whole number and mean ± SD.

* t-test for independent samples

Table 3. FAOS in the one year follow up in patients receiving plantar tri-lock plates

Patient	FAOS score in one year follow up				
	Pain	Symptoms other than pain	Activities of daily living	Sport and recreational function	Foot and ankle related quality of life
1	80.56	85.71	89.71	75.00	56.25
2	100.00	100.00	100.00	100.00	100.00
3	100.00	100.00	100.00	100.00	100.00
4	88.89	100.00	91.18	45.00	87.50
5	97.22	92.86	100.00	100.00	93.75
6	86.11	60.71	75.00	65.00	62.50
7	88.89	92.86	100.00	85.00	93.75
Mean ± SD	91.67 ± 6.96	90.31 ± 13.05	93.70 ± 8.07	81.43 ± 15.59	84.82 ± 16.66
<i>P</i> *	0.179	0.593	0.38	0.891	0.347

Data is presented as whole number and mean ± SD.

* t-test for independent samples

Table 4. Preoperative FAOS in patients receiving the medial tri-lock plates

Patient	Preoperative FAOS				
	Pain	Symptoms other than pain	Activities of daily living	Sport and recreational function	Foot and ankle related quality of life
8	52.78	78.57	76.47	35.00	31.25
9	25.00	96.43	26.47	10.00	18.75
10	41.67	67.86	75.00	50.00	25.00
11	47.22	85.71	54.41	50.00	56.25
12	66.67	85.71	92.65	80.00	50.00
13	75.00	96.43	85.29	80.00	56.25
Mean \pm SD	51.39 \pm 16.33	85.12 \pm 9.88	68.38 \pm 22.12	50.83 \pm 24.57	39.58 \pm 15.17
<i>P</i> *	0.325	0.285	0.76	0.746	0.79

Data is presented as whole number and mean \pm SD.

* t-test for independent samples

Table 5. FAOS in the one year follow up in patients receiving medial tri-lock plates

Patient	FAOS score in one year follow up				
	Pain	Symptoms other than pain	Activities of daily living	Sport and recreational function	Foot and ankle related quality of life
8	75.00	78.57	97.06	60.00	62.50
9	88.89	89.29	97.06	95.00	87.50
10	91.67	82.14	89.71	85.00	87.50
11	80.56	96.43	97.06	80.00	75.00
12	72.22	75.00	100.00	80.00	50.00
13	100.00	100.00	100.00	95.00	93.75
Mean \pm SD	84.72 \pm 9.72	86.90 \pm 9.15	96.81 \pm 3.44	82.50 \pm 11.81	76.04 \pm 15.49
<i>P</i> *	0.179	0.593	0.38	0.891	0.347

Data is presented as whole number and mean \pm SD.

* t-test for independent samples

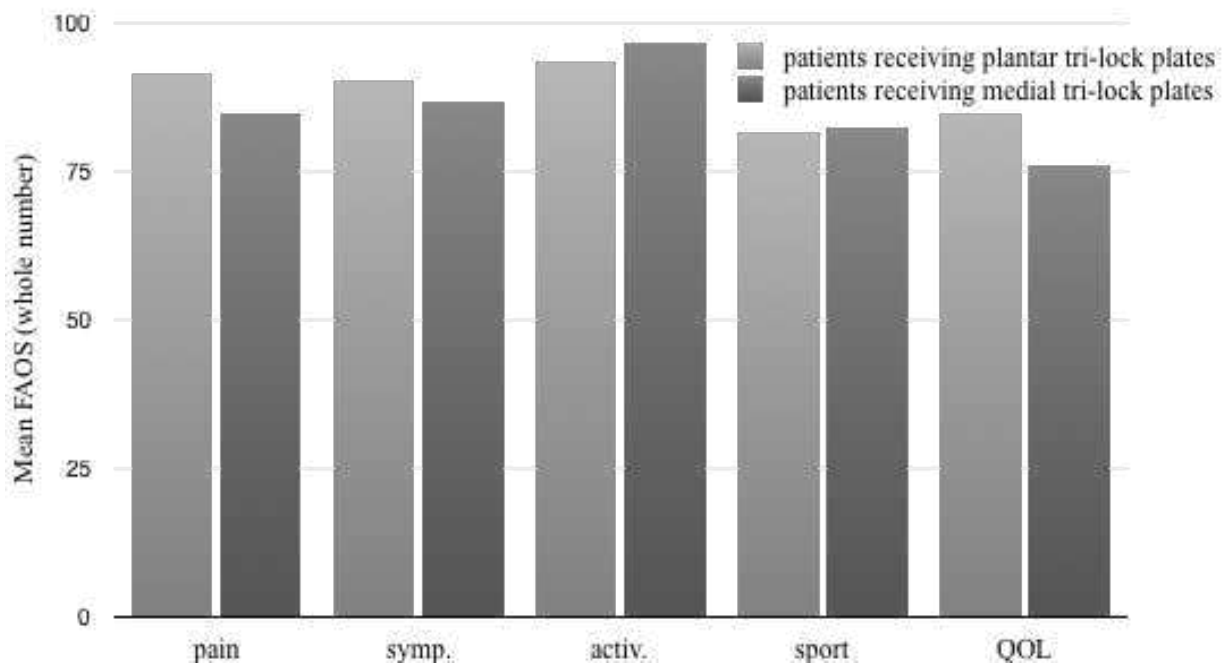


Figure 10. FAOS score in patients receiving plantar tri-lock plates versus patients receiving medial tri-lock plates. **Abbreviations:** symp. - Symptoms other than pain; activ-Activities of daily living; sport- Sport and recreational function; QOL- Foot and ankle related quality of life

4.2.HVA and IMA

The values for a normal and abnormal HVA and IMA are described in Table 1. The HVA decreased between the preoperative period and the 1-year check-up in both patients who received plantar plates (Table 6) and medial plates (Table 7). The mean HVA decreased from $36.58^{\circ} \pm 4.75$ ($P = 0.087$) preoperatively to $4.32^{\circ} \pm 6.10$ ($P = 0.044$) after the 1 year follow up in patients who received plantar plates (Table 6). The mean HVA decreased from $32.41^{\circ} \pm 3.15$ ($P = 0.087$) preoperatively to $11.29^{\circ} \pm 4.96$ ($P = 0.044$) after 1 year in patients who received medial plates (Table 7). When comparing both groups however, there was a smaller HVA in the postoperative 1 year check up in the patients who received the plantar plate, then those who received the medial plate (Figure 11).

When looking at the IMA, again one can observe that the angles decreased between the preoperative period and the 1-year check-up in both patients who received plantar plates (Table 8) and medial plates (Table 9). In this case the mean IMA decreased from $15.50^{\circ} \pm 2.41$ ($P = 0.097$) preoperatively to $4.54^{\circ} \pm 2.24$ ($P = 0.584$) after the 1-year check-up in patients who

received plantar plates (Table 8). The mean IMA decreased from $13.52^{\circ} \pm 1.42$ ($P = 0.097$) preoperatively to $5.63^{\circ} \pm 4.18$ ($P = 0.584$) after 1 year in patients who received medial plates (Table 9). Again when comparing both groups, there was a smaller IMA in the postoperative 1 year check up in the patients who received the plantar plate, then those who received the medial plates (Figure 12).

Table 6. HVA for patients receiving plantar angle-stable plates.

Patient	HVA in ° for patients receiving plantar angle-stable plates			
	Preoperative	6w	12w	1 year
1	37.80	8.93	12.62	8.70
2	30.74	0.00	0.00	-6.92
3	42.75	3.75	14.51	8.27
4	32.36	13.39	9.14	10.60
5	43.33	3.34	0.56	-2.86
6	32.01	16.49	17.67	5.61
7	37.06	7.56	16.36	6.87
Mean ± SD	36.58 ± 4.75	7.64 ± 5.41	10.12 ± 6.72	4.32 ± 6.10
<i>P</i> *	0.087	0.977	0.928	0.044

Data is presented as whole number and mean ± SD. **Abbreviations:** HVA – hallux valgus angle

* t-test for independent samples

Table 7. HVA for patients receiving medial angle-stable plates.

Patient	HVA in ° for patients receiving medial angle-stable plates			
	Preoperative	6 weeks	12 weeks	1 year
8	32.20	10.03	9.61	8.59
9	37.02	6.76	11.81	14.51
10	27.68	2.04	3.83	8.99
11	35.42	5.13	5.99	4.70
12	29.92	13.81	17.79	20.27
13	32.21	7.62	9.94	10.65
Mean ± SD	32.41 ± 3.15	7.57 ± 3.07	9.83 ± 4.44	11.29 ± 4.96
<i>P</i> *	0.087	0.977	0.928	0.044

Data is presented as whole number and mean ± SD. **Abbreviations:** HVA – hallux valgus angle

* t-test for independent samples

Table 8. IMA for patients receiving plantar angle-stable plates

Patient	IMA in ° for patients receiving plantar angle-stable plates			
	Preoperative	6 weeks	12 weeks	1 year
1	15.69	6.82	5.24	5.97
2	15.28	1.09	1.32	0.61
3	17.34	5.73	6.66	5.02
4	12.21	1.96	5.77	6.26
5	13.04	0.17	0.27	1.55
6	14.93	5.36	6.77	6.24
7	19.98	7.55	8.25	6.13
Mean ± SD	15.50 ± 2.41	4.10 ± 2.74	4.90 ± 2.75	4.54 ± 2.24
<i>P</i> *	0.097	0.98	0.921	0.584

Data is presented as whole number and mean ± SD. **Abbreviations:** IMA – intermetatarsal angle

* t-test for independent samples

Table 9. IMA for patients receiving plantar angle-stable plates

Patient	IMA in ° for patients receiving medial angle-stable plates			
	Preoperative	6 weeks	12 weeks	1 year
8	13.14	4.93	3.16	3.97
9	11.78	2.10	3.32	5.37
10	13.35	5.89	6.16	6.70
11	15.78	2.27	2.37	1.52
12	14.89	9.27	13.11	14.10
13	12.16	0.39	2.39	2.13
Mean ± SD	13.52 ± 1.42	4.14 ± 2.93	5.09 ± 3.81	5.63 ± 4.18
<i>P</i> *	0.097	0.98	0.921	0.584

Data is presented as whole number and mean ± SD. **Abbreviations:** IMA – intermetatarsal angle

* t-test for independent samples

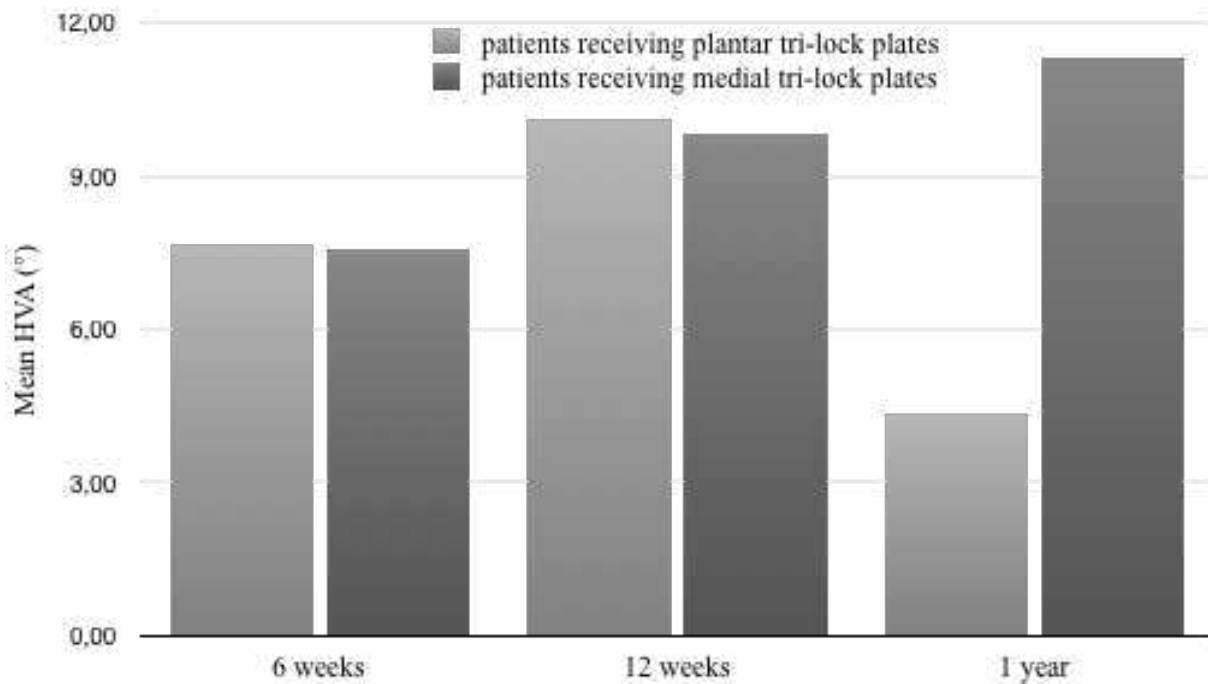


Figure 11. Mean HVA in ° for patients receiving plantar tri-lock plates versus in patients receiving medial tri-lock plates

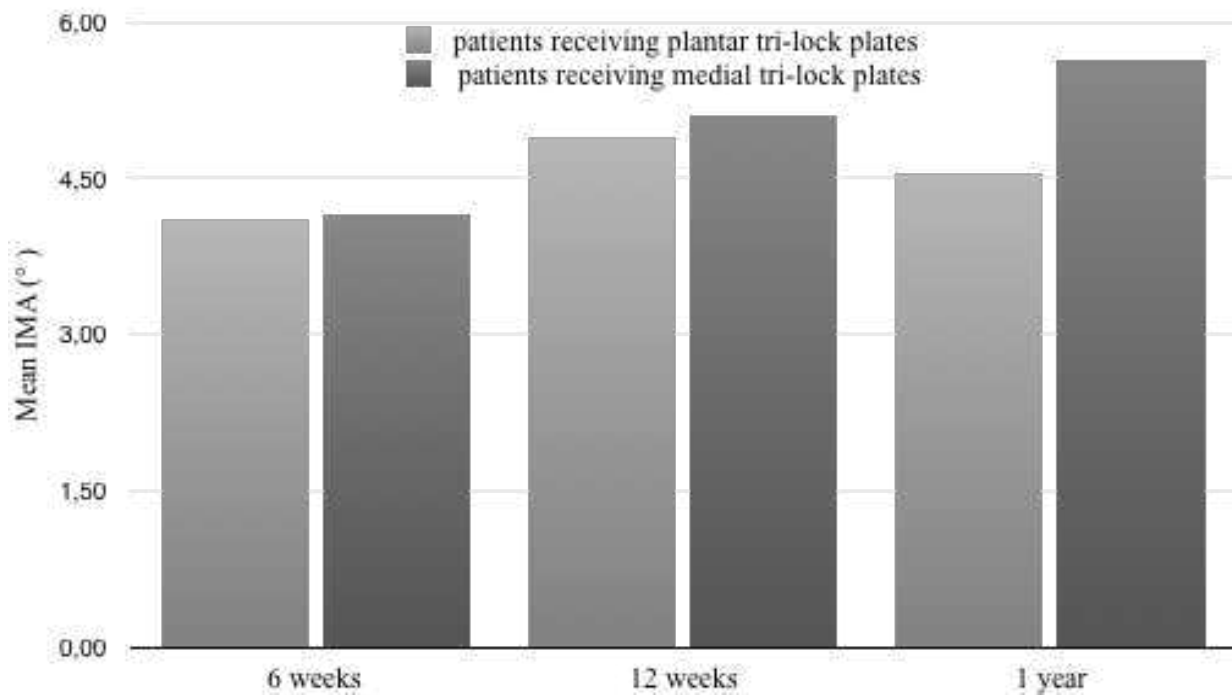


Figure 12. Mean IMA for patients receiving plantar tri-lock plates versus in patients receiving medial tri-lock plates

4.3. Consolidation:

The consolidation was established as formerly mentioned. It was grouped into non-union, delayed or beginning consolidation and complete consolidation and marked as 0,1 and 2 respectively. The results show that the majority of the arthrodesis surgeries underwent consolidation after 1 year. However, in two patients receiving the medial plate, the TMT-I joint adjacent to the plate did not undergo consolidation (Table 10). Patient 9 presented with delayed consolidation and patient 10 presented with non-union (Table 10)

Table 10. Level of Consolidation in patients receiving the plantar angle-stable plates versus level of consolidation in patients receiving the medial angle-stable plates

Plantar angle-stable plates		Medial angle-stable plates	
Patient	Consolidation after 1 year	Patient	Consolidation after 1 year
1	2	8	2
2	2	9	1
3	2	10	0
4	2	11	2
5	2	12	2
6	2	13	2
7	2		

Data is presented as whole numbers

4.4. VRS

The VRS pain scale measuring pain from 1-10 was documented in the 13 patients preoperatively and postoperatively at 6 weeks, 12 weeks and 1 year. The pain in both the patient groups who received plantar plates and those who received medial plates decreased from preoperative results. In patients receiving plantar plates the pain decreased from a mean value of 4.96 ± 2.27 ($P = 0.879$) preoperatively to 1.40 ± 1.55 ($P = 0.236$) after 1 year (Table 11). In patients receiving the medial plates the pain decreased from a mean value of 5.15 ± 2.11 ($P = 0.879$) preoperatively to 0.60 ± 0.5 ($P = 0.236$) after 1 year (Table 12). Even though both groups showed a decrease in pain, patients receiving the medial plate had a smaller amount of pain then those receiving the plantar plate after 1 year (Figure 13). Even though the pain after 1 year was smaller in patients receiving the medial plate, after 6 weeks' patients with the medial plate had higher pain then those receiving the plantar plate (Figure 13).

Table 11. VRS for patients receiving plantar angle-stable plates

Patient	VRS (1-10)			
	Preoperative	6 weeks	12 weeks	1 year
1	7.70	0.50	2.30	0.40
2	4.70	4.00	1.70	0.00
3	5.30	0.20	0.60	0.50
4	7.50	1.60	4.20	4.70
5	2.50	0.30	2.50	1.20
6	1.10	1.50	2.40	2.50
7	5.90	4.00	0.00	0.50
Mean ± SD	4.96 ± 2.27	1.73 ± 1.52	1.96 ± 1.27	1.40 ± 1.55
<i>P</i> *	0.879	0.096	0.606	0.236

Data is presented as whole number and mean ± SD. **Abbreviations:** VRS – verbal rating score

* t-test for independent samples

Table 12. VRS for patients receiving medial angle-stable plates

Patient	VRS (1-10)			
	Preoperative	6 weeks	12 weeks	1 year
8	7.50	8.50	1.50	0.70
9	7.00	4.70	1.70	1.70
10	2.90	2.60	2.40	0.00
11	5.40	2.00	2.80	0.60
12	6.30	1.30	0.30	0.50
13	1.80	4.00	1.20	0.10
Mean ± SD	5.15 ± 2.11	3.85 ± 2.38	1.65 ± 0.81	0.60 ± 0.5
<i>P</i> *	0.879	0.096	0.606	0.236

Data is presented as whole number and mean ± SD. **Abbreviations:** VRS – verbal rating score

* t-test for independent samples

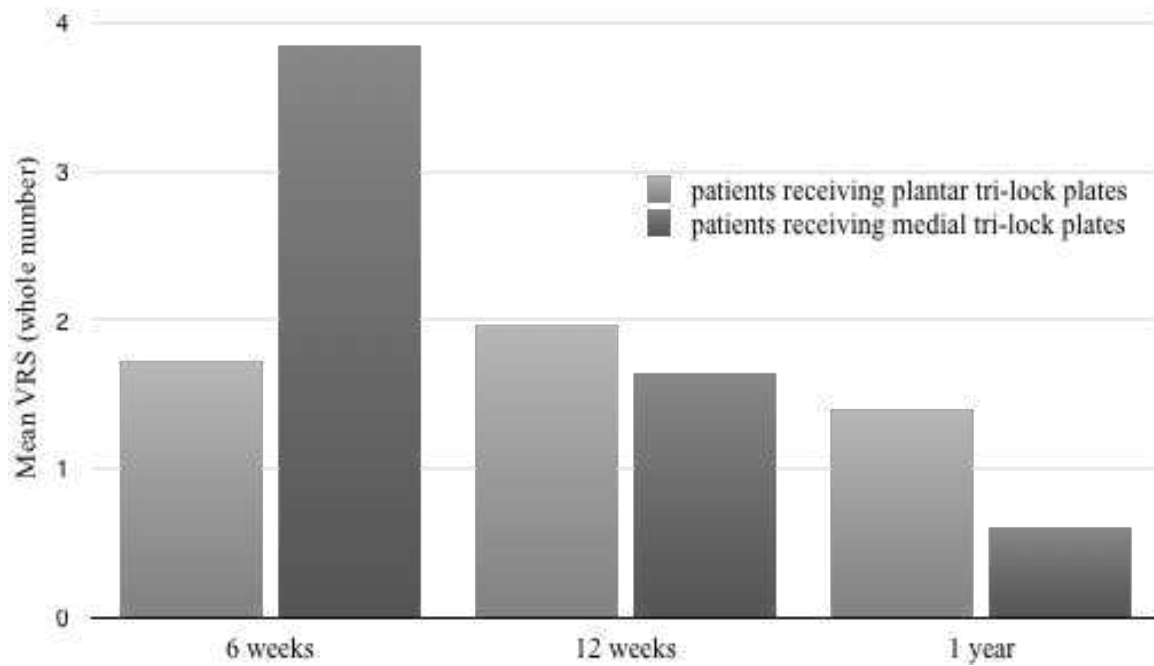


Figure 13. Mean VRS in patients receiving a plantar angle-stable plate versus in patients receiving a medial angle-stable plate

5.DISCUSSION

This was a prospective non-randomised study aimed at determining whether there is a difference in the clinical and radiological outcome when performing lapidus arthrodesis with plantar tri-lock plates compared to medial tri-lock plates, on patients with hallux valgus, indicated for this surgery, and meeting the inclusion and exclusion criteria of the study. The variables for this study included the Foot and Ankle Outcome Score (FAOS), the Verbal Rating Scale (VRS) for pain, and the radiologic findings including IMA, HVA and the degree of consolidation.

Based on Doherty, hallux valgus is defined as the subluxation of the first MTP joint, which results in first medial prominence and lateral deviation of the proximal phalanx on the first metatarsal [2]. Hallux valgus is quite apparent clinically through the formation of a so called bunion in these patients [3]. In order to assess the degree of hallux valgus, imaging is the major tool of choice, specifically radiologic imaging [22]. The classic radiographs used, are those of anteroposterior (AP), lateral and oblique view. It is then classified into severity based on the HVA and IMA [19]. The indication for surgery is classically made on clinical findings [20]. The radiologic images and the corresponding classification of the hallux valgus based on HVA and IMA defines the surgical technique used [20]. Severe hallux valgus requires lapidus arthrodesis.

In this study the data of 13 patients was used, in which 7 patients underwent lapidus arthrodesis with a plantar tri-lock plate and 6 patients underwent lapidus arthrodesis with a medial tri-lock plate. The study population included 12 females and 1 male, with patients having an average age of 53. Patients receiving the plantar tri-lock plate included 1 male and 6 females with an average age of 54. Patients receiving the medial tri-lock included 6 females with an average age of 52.

Both the patients receiving plantar plates and the patients receiving medial plates showed improvement in all former mentioned clinical and radiologic outcomes when comparing the preoperative results to those of the 1 year follow up.

In the FAOS, when comparing both patient groups based on results of the 1 year follow up, patients receiving the plantar plate had better outcomes in 3 of the 5 categories, namely pain, symptoms other than pain, and quality of life (graph 2). The patients receiving the medial plates however showed better outcomes in two of the subgroups, namely the sports and recreational activities score and activities of daily life score (graph 2). Looking at the results of the FAOS, both techniques are very similar with minor benefits seen in patients receiving

plantar plates. The patients receiving plantar plates showed more advantages in the 3 formerly mentioned groups compared to the 2 other groups where the mean score was more similar in both groups. This strengthens the suggestions that the FAOS shows minor benefits in outcome when undergoing the lapidus arthrodesis with a plantar plate. However, this has no statistical significance.

The radiologic analysis, namely the HVA, IMA and level of consolidation all showed better outcomes for patients receiving the plantar plate compared to patients receiving the medial plate. However, this had no statistical significance, except for the mean HVA outcome in the one year follow up. The mean HVA in the 1 year follow up, in the group of patients receiving plantar plates ended up being $4.54^\circ \pm 6.10$ ($P = 0.044$), whereas in those receiving medial plates, it ended up being $11.29^\circ \pm 4.96$ ($P = 0.044$) (Figure 11). The mean IMA in the 1 year follow up, in the group of patients receiving plantar plates ended up being $4.54^\circ \pm 2.24$ ($P = 0.584$), whereas in those receiving medial plates it ended up being $5.63^\circ \pm 4.18$ ($P = 0.584$) (Figure 12). Finally, the group of patients receiving the plantar plate showed complete consolidation in all cases in the one year follow up. In the group of patients receiving the medial plates, one patient showed non-union and the other showed delayed or beginning consolidation (Table 10). The better radiologic outcomes in patients receiving plantar plates is especially portrayed by the better mean HVA after one year in this patient group compared to the other. In addition to this, the fact that there were no adverse outcomes in terms of consolidation for patients receiving plantar plates and in patients receiving medial plates there were, one can predict that the progression towards angles seen in the preoperative stages and remission surgery due to failed consolidation is more likely in the patients receiving plantar plates. More detailed research is needed however to support this claim.

Finally, when looking at the VRS pain scale ranging from 1-10, the pain in patients receiving medial plates seems to be smaller in the one year follow up compared to those receiving plantar plates (Graph 5). This seems to be contradicting with the FAOS score which stated that pain in patients that received plantar plates is smaller. The FAOS score however does not necessarily ask about the average intensity of pain, but the intensity of pain when performing certain activities and how often the pain occurred within the week prior to filling out the survey. This means that the intensity of pain may still be higher in patients receiving plantar plates however the pain does not occur with certain movement or more often than those receiving medial plates. However, these outcomes do not portray statistical significance

In this study the difference in clinical and radiologic outcome based on the above mentioned criteria in patients with hallux valgus receiving plantar tri-lock plates compared to those receiving medial tri-lock plates for lapidus arthrodesis was to be determined. We can see that based on the FAOS score there seem to be only mild benefits in using the plantar tri-lock plates. The radiologic outcome shows benefits in using the plantar tri-lock plates compared with the medial tri-lock plates. Finally, when one looks at the VRS score there are slight benefits to using the medial tri-lock plates compared to using plantar tri-lock plates. Thus we can conclude that there is a difference in clinical and radiologic outcome when using plantar tri-lock plates versus medial tri-lock plates when performing the lapidus arthrodesis on patients with hallux valgus. However, one must consider that besides the outcome for the 1 year follow up of HVA, there is no statistically significance in these results.

There are some limitations to the study. The p-value showed to be above 0.05 in all cases except for the 1-year follow-up of HVA. One must mention that there was a limited amount of participants in this study, which may explain the p-value. This leaves the question on applicability of this study towards a larger population open for discussion. Thus it is advised that further research is conducted with a larger study population.

6.CONCLUSION

1. We can see that there is a difference in clinical and radiological outcome when using medial tri-lock plates compared to using plantar tri-lock plates, however this does not seem to be statistically significant.
2. The FAOS score showed mild benefits towards using plantar tri-lock plates versus medial tri-lock plates when performing the lapidus arthrodesis on patients with hallux valgus.
3. The radiologic outcome comparing HVA, IMA and level of consolidation showed mild benefits towards using plantar tri-lock plates versus medial tri-lock plates when performing the lapidus arthrodesis on patients with hallux valgus.
4. The VRS pain score showed mild benefits towards using medial tri-lock plates versus plantar tri-lock plates when performing the lapidus arthrodesis on patients with hallux valgus.

7. REFERENCES

1. Bowyer G. The Ankle and Foot. In: Solomon L, Warwick D, Nayagam S, Solomon L. Apley and Solomon's concise system of orthopaedics and trauma. 9th ed. Hodder Arnold; 2010. p. 603-5
2. Vanderhave K. Orthopedic surgery. In: Doherty G. Current diagnosis & treatment. 14th ed. Lange; 2015. p. 1145
3. Michler M. Zum hallux valgus der Antike. In: Blauth W. Hallux valgus. Berlin: Springer; 1986. p.1-6
4. Moore K, Agur A, Dalley A. Lower Limb. In: Moore K, Agur A, Dalley A. Clinically oriented anatomy. 7th ed. LWW.2013 p. 609-26
5. Horvai A. Bones, joints and soft tissue tumors. In: Kumar V, Abbas A, Aster J, Robbins S. Robbins basic pathology. 10th ed. Elsevier 2018; 2017. p. 806
6. Kuhn J, Alvi F. Hallux Valgus [Internet]. Ncbi.nlm.nih.gov. 2020 [Updated 2020 May 23; cited 15 July 2020]. Available from: <https://www.ncbi.nlm.nih.gov/books/NBK553092/>
7. Koo K, Tse L, Cheng H, Ho K. The progression of hallux valgus in the oriental Chinese population in Hong Kong. *The Foot*. 2017;32:15-21.
8. Lam A, Chan J, Surace M, Vulcano E. Hallux rigidus: How do I approach it?. *World Journal of Orthopedics*. 2017;5:364.
9. Perera A, Mason L, Stephens M. The Pathogenesis of Hallux Valgus. *The Journal of Bone and Joint Surgery-American Volume*. 2011;17:1650-61.
10. Kato T, Watanebe S. The etiology of hallux valgus in Japan. *Clinical Orthopaedics and Related Research*. 1981;157:78-81.
11. Klein C, Groll-Knapp E, Kundi M, Kinz W. Increased hallux angle in children and its association with insufficient length of footwear: A community based cross-sectional study. *BMC Musculoskeletal Disorders*. 2009;1.
12. Soemarko D, Rahmasari F, Kamal A, Cahayadi S, Herqutanto. Hallux valgus among sales promotion women wearing high heels in a department store. *Journal of Orthopaedic Surgery*. 2019;1:23-45.
13. Schon C, Adams S. Lapidus procedure for hallux valgus deformity. In: Kitaoka H. *Master Techniques in Orthopaedic Surgery*. 3rd ed. Philadelphia: Wolters Kluwer Health; 2014. p. 103
14. Kilmartin T, Barrington R, Wallace W. Metatarsus primus varus. A statistical study. *The Journal of Bone and Joint Surgery British volume*. 1991;6:937-40.

15. Piqué-Vidal C, Solé M, Antich J. Hallux Valgus Inheritance: Pedigree Research in 350 Patients With Bunion Deformity. *The Journal of Foot and Ankle Surgery*. 2007;3:149-54.
16. Coughlin M, Jones C. Hallux Valgus: Demographics, Etiology, and Radiographic Assessment. *Foot & Ankle International*. 2007;7:759-77.
17. Arbeeva L, Yau M, Mitchell B, Jackson R, Ryan K, Golightly Y et al. Genome-wide meta-analysis identified novel variant associated with hallux valgus in Caucasians. *Journal of Foot and Ankle Research*. 2020;1.
18. Neumann R, Tung T, Kirby J. Wound healing and care. In: Klingensmith M. *The Washington manual of surgery*. 5th ed. Spiral manual; 2008. p.113
19. Dohle J, Fuhrmann R, Hamel J, Rammelt S, Richter M, Thomas M. Revised guidelines for foot and ankle surgery. *Fuß&Sprunggelenk*. 2010;4:275
20. Wülker N, Mittag F. The Treatment of Hallux Valgus. *Deutsches Aerzteblatt Online*. 2012;49:857-68.
21. Arie E, Moreira N, Freire G, dos Santos B, Yi L. Study of the metatarsal formula in patient with primary metatarsalgia. *Revista Brasileira de Ortopedia (English Edition)*. 2015;4:438-44.
22. . Welck M, Al-Khudairi N. Imaging of Hallux Valgus. *Foot and Ankle Clinics*. 2018;2:183-92.
23. Coughlin M, Freund E. The Reliability of Angular Measurements in Hallux Valgus Deformities. *Foot & Ankle International*. 2001;5:369-79.
24. Welck M, Singh D, Cullen N, Goldberg A. Evaluation of the 1st metatarso-sesamoid joint using standing CT — The Stanmore classification. *Foot and Ankle Surgery*. 2018;4:314-19.
25. Collan L, Kankare J, Mattila K. The biomechanics of the first metatarsal bone in hallux valgus: A preliminary study utilizing a weight bearing extremity CT. *Foot and Ankle Surgery*. 2013;3:155-61.
26. Sammarco V, Nichols R. Orthotic Management for Disorders of the Hallux. *Foot and Ankle Clinics*. 2005;1:191-209.
27. Hurn S, Vicenzino B, Smith M. Non-surgical treatment of hallux valgus: a current practice survey of Australian podiatrists. *Journal of Foot and Ankle Research*. 2016;1.
28. Groiso J. Juvenile hallux valgus. A conservative approach to treatment. *The Journal of Bone & Joint Surgery*. 1992;9:1367-74.

29. Torkki M, Malmivaara A, Seitsalo S, Hoikka V, Laippala P, Paavolainen P. Surgery vs Orthosis vs Watchful Waiting for Hallux Valgus. *JAMA*. 2001;19:2474.
30. Chadchavalpanichaya N, Prakotmongkol V, Polhan N, Rayothee P, Seng-Iad S. Effectiveness of the custom-mold room temperature vulcanizing silicone toe separator on hallux valgus: A prospective, randomized single-blinded controlled trial. *Prosthetics and Orthotics International*. 2017;2:163-70.
31. Tehraninasr A, Saeedi H, Forogh B, Bahramizadeh M, Keyhani M. Effects of insole with toe-separator and night splint on patients with painful hallux valgus: A comparative study. *Prosthetics and Orthotics International*. 2008;1:79-83.
32. Mallette J, Glenn C, Glod D. The Incidence of Nonunion after Lapidus Arthrodesis Using Staple Fixation. *The Journal of Foot and Ankle Surgery*. 2014;3:303-6.
33. Baumgaerner M, Tornetti P. Nonunions and Malunions. In: Baumgaerner M, Tornetti P. *Orthopedic knowledge update: Trauma 3. Bone and Joint Decade*; 2005. p.128-29
34. Willegger M, Holinka J, Ristl R, Wanivenhaus A, Windhager R, Schuh R. Correction power and complications of first tarsometatarsal joint arthrodesis for hallux valgus deformity. *International Orthopaedics*. 2014;3:467-76.
35. Kromuszczyńska J, Kołodziej Ł, Jurewicz A. Wound healing complications in patients with and without systemic diseases following hallux valgus surgery. *PLOS ONE*. 2018;6.
36. Galois L. History of surgical treatments for hallux valgus. *European Journal of Orthopaedic Surgery & Traumatology*. 2018;8:1633-39.
37. Iselin L, Klammer G, Espinoza N, Symeonidis P, Iselin D, Stavrou P. Surgical management of hallux valgus and hallux rigidus: an email survey among Swiss orthopaedic surgeons regarding their current practice. *BMC Musculoskeletal Disorders*. 2015;1.
38. Suresh S. Scarf osteotomy - Is it the procedure of choice in hallux valgus surgery? A preliminary report. *Oman Medical Journal*. 2007;3:47-50.
39. Choi J, Zide J, Coleman S, Brodsky J. Prospective Study of the Treatment of Adult Primary Hallux Valgus With Scarf Osteotomy and Soft Tissue Realignment. *Foot & Ankle International*. 2013;5:684-90.
40. Hendrix MR, Davis BL. Chevron osteotomy of the first metatarsal for hallux valgus. *S Afr Med J*. 1989;8:413-16.

41. Deenik A, Pilot P, Brandt S, van Mameren H, van Geesink R, van Draijer W. Scarf versus Chevron Osteotomy in Hallux Valgus: A Randomized Controlled Trial in 96 Patients. *Foot & Ankle International*. 2007;5:537-41.
42. Lapidus P. The author's bunion operation from 1931 to 1959. *Clin Orthop*. 1960;16:119-35.
43. Grace D, Delmonte R, Catanzariti A, Hofbauer M. Modified lapidus arthrodesis for adolescent hallux abducto valgus. *The Journal of Foot and Ankle Surgery*. 1999;1:8-13.
44. Taylor N, Metcalfe S. A review of surgical outcomes of the Lapidus procedure for treatment of hallux abductovalgus and degenerative joint disease of the first MCJ. *The Foot*. 2008;4:206-10.
45. Cottom J, Vora A. Fixation of Lapidus Arthrodesis with a Plantar Interfragmentary Screw and Medial Locking Plate: A Report of 88 Cases. *The Journal of Foot and Ankle Surgery*. 2013;4:465-69.
46. Burchard R, Massa R, Soost C, Richter W, Dietrich G, Ohrndorf A et al. Biomechanics of common fixation devices for first tarsometatarsal joint fusion—a comparative study with synthetic bones. *Journal of Orthopaedic Surgery and Research*. 2018;1:176.
47. Klos K, Simons P, Hajduk A, Hoffmeier K, Gras F, Fröber R et al. Plantar versus Dorsomedial Locked Plating for Lapidus Arthrodesis: A Biomechanical Comparison. *Foot & Ankle International*. 2011;11:1081-85.
48. Kaufmann G, Hofmann M, Ulmer H, Putzer D, Hofer P, Dammerer D. Outcomes after scarf osteotomy with and without Akin osteotomy a retrospective comparative study. *Journal of Orthopaedic Surgery and Research*. 2019;1:193.
49. Chen L, Lyman S, Do H, Karlsson J, Adam S, Young E et al. Validation of Foot and Ankle Outcome Score for Hallux Valgus. *Foot & Ankle International*. 2012;12:1145-55.
50. Hierholzer C, Buehren V. Treatment principles of nonunion. In: Oestern H, Trentz O, Uranues S, Arnold W, Ganzer U. *General Trauma Care and Related Aspects: Trauma Surgery II*. Springer; 2014. p. 229

8.SUMMARY

Background: There are more than 100 surgeries described for hallux valgus with different indications. Severe hallux valgus can be operated with TMT-I (lapidus) arthrodesis. This can be performed with either plantar tri-lock plates or medial tri-lock plates. The study was aimed at determining whether there is a difference in the clinical and radiological outcome when performing lapidus arthrodesis with plantar tri-lock plates compared to medial tri-lock plates on patients with hallux valgus, indicated for this surgery.

Methods: In the department for foot and ankle surgery of the Diakovere Annastift Hannover over a time period between November 2018 and December 2019, 13 patients were operated with a TMT-I arthrodesis, and included into this study. The group of patients included 12 females and 1 male with a mean age of 53. 7 were operated with a plantar tri-lock plate and 6 were operated with a medial tri-lock plate. The follow up exams were performed preoperatively, after 6 weeks, 12 weeks and 1 year. The follow up exam included a questionnaire and radiologic images. The questionnaire included the Foot and Ankle Outcome Score (FAOS), which included 5 subgroups each ranging from 1-100 with 100 being the best outcome possible, and the VRS pain scale which ranged from 1 to 10 with 10 being the worst pain imaginable and 1 being no pain. The radiologic analysis included the HVA, IMA and consolidation. The mean values for each of these outcomes was then compared between patients receiving the plantar plates and those receiving the medial plates.

Results: In the FAOS, when comparing both patient groups based on results of the 1 year follow up, patients receiving the plantar plate had better outcomes in 3 of the 5 categories, namely pain score (91.67 ± 6.96 ($P = 0.179$) in plantar tri-lock plates vs. 84.72 ± 9.72 ($P = 0.179$) in medial tri-lock plates), symptoms other than pain score (90.31 ± 22.22 ($P = 0.593$) in plantar tri-lock plates compared to 86.9 ± 9.15 ($P = 0.593$) in medial tri-lock plates), and finally in the quality of life score (84.82 ± 16.66 ($P = 0.347$) in plantar tri-lock plates compare to 76.04 ± 15.49 ($P = 0.347$) in medial tri-lock plates). The patients receiving the medial plates however showed better outcomes in two of the subgroups, namely the sports and recreational activities score (81.43 ± 15.59 ($P = 0.891$) in patients receiving plantar plates compared to 82.5 ± 11.81 ($P = 0.891$) in patients receiving medial plates) and activities of daily life score (93.71 ± 22.60 ($P = 0.38$) in plantar plates compared to 96.81 ± 22.12 ($P = 0.38$) in medial plates). The radiologic analysis after one year (HVA, IMA and level of consolidation) all showed better outcomes for patients receiving the plantar plate compared to patients receiving the medial plate. The mean

HVA was $4.32^\circ \pm 6.10$ ($P = 0.044$) for patients receiving plantar plates, whereas it ended up being $11.29^\circ \pm 4.96$ ($P = 0.044$) for patients receiving medial plates. The mean IMA in the group of patients receiving plantar plates ended up being $4.54^\circ \pm 2.24$ ($P = 0.584$), whereas in those receiving medial plates, it ended up being $5.63^\circ \pm 4.18$ ($P = 0.584$). The group of patients receiving the plantar plate showed complete consolidation in all cases in the one year follow up. In the group of patients receiving the medial plates, one patient showed non-union and the other showed delayed or beginning consolidation. Finally, the VRS pain scale value in the one year follow up showed that for patients receiving plantar plates the mean value was 1.40 ± 1.55 ($P = 0.236$), whereas in patients receiving the medial plates it was 0.60 ± 0.5 ($P = 0.236$).

Conclusion: Patients receiving plantar plates have better 1 year outcomes in 3 of the 5 categories of the FAOS score (pain score, symptoms other than pain score and quality of life score) and better 1 year radiological outcomes (HVA, IMA and level of consolidation). Patients receiving the medial plates have better 1 year outcomes in 2 of the 5 categories of the FAOS score (sports and recreational activities score and activities of daily life score) and the VRS pain score. We can see that there is a difference in clinical and radiological outcome when using medial tri-lock plates compared to using plantar tri-lock plates, however this does not seem to be statistically significant.

9. SUMMARY IN CROATIAN

Cilj istraživanja: Postoji više od sto opisanih operacijskih metoda glede korigiranja problema nastalih zbog patoloških odnosa u prvom metatarzofalangealnom zglobu a koji dovode do promjena u smislu nastajanja halux valgusa . Najteži oblici hallux valgusa mogu se operirati korektivnom metodom osteotomije i artrodeze prvog transmetatarzalnog zgloba (lapidus operacijska tehnika). To se može izvesti bilo s podložnom pločom na zaključavanje sa tri zaključana vijka ili s medijalnim pločama na zaključavanje sa tri zaključana vijka. Ispitivanje je imalo za cilj utvrditi postoji li razlika u kliničkom i radiološkom ishodu pri izvođenju lapidusne artrodeze s plantarnom pločicom na zaključavanje u usporedbi s medijalnim pločicama na zaključavanje pacijentima s najtežim oblicima hallux valgusa.

Ispitanici i metode: Na odjelu za kirurgiju stopala i gležnjeva Diakovere Annastift Hannover u vremenskom razdoblju između studenog 2018. i prosinca 2019. Trinaest pacijenata operirano je artrodezom TMT-I i uključeno je u ovu studiju. U skupini bolesnika bilo je dvanaest žena i jedan muškarac prosječne dobi od 53 godine. Sedam pacijenata je operirano s plantarnom , a šestero su operirani s medijalnom pločicom na zaključavanje. Pacijenti su pregledani prijeoperacijski , nakon šest tjedana, dvanaest tjedana i nakon jedne godine. Pregled se sastojao od upitnika i radioloških slika učinjenih godinu dana nakon operacijskog zahvata. Upitnik je uključivao ocjenu ishoda stopala i gležnja (FAOS-skor), koja je uključivala 5 podskupina pitanja u rasponu od 1 do 100, pri čemu je 100 bio najbolji mogući ishod, te VRS ljestvica boli koja se kretala od 1 do 10, a 10 je bila najgora bol koja se može zamisliti i 1 bez boli. Radiološka analiza uključuje HVA, IMA i razinu konsolidacije. Srednje vrijednosti za svaki od ovih ishoda zatim su uspoređene između pacijenata koji su operirani plantarnom pločicom na zaključavanje i onih koji su operirani medijalnom pločicom na zaključavanje.

Rezultati: U FAOS-u, kada se uspoređuju obje skupine bolesnika na temelju rezultata praćenja od jedne godine, pacijenti koji su operirani plantarnom pločicom imali su bolje rezultate u tri od pet kategorija. Metoda primjene plantarne pločice bila je bolja u skorima boli (91.67 ± 6.96 ($P = 0.179$) u plantarna pločica vs. 84.72 ± 9.72 ($P = 0.179$) u medijalna pločica), simptomatologiji vezanih za problematiku halux valgusa (90.31 ± 22.22 ($P = 0.593$) vs 86.9 ± 9.15 ($P = 0.593$)) i na kraju u kvaliteti života (84.82 ± 16.66 ($P = 0.347$) vs 76.04 ± 15.49 ($P = 0.347$)). Pacijenti koji su operirani s medijalnom pločicom, pokazali su, međutim, bolje rezultate u ostale dvije podskupine .Rezultat sportskih i rekreativnih aktivnosti (81.43 ± 15.59 ($P = 0.891$) plantarna pločica vs 82.5 ± 11.81 ($P = 0.891$) medijalna pločica) i aktivnosti dnevnog života (93.71 ± 22.60 ($P = 0.38$) vs 96.81 ± 22.12 ($P = 0.38$) u medijalnim pločama) bila je bolja u pacijenata

operiranih medijalnom pločicom na zaključavanje. Radiološka analiza nakon godinu dana (HVA, IMA i razina konsolidacije) pokazala je bolje rezultate za pacijente koji su imali plantarnu ploču u odnosu na bolesnike koji su imali medijalnu ploču. Srednja vrijednost HVA iznosila je $4.32^\circ \pm 6.10$ ($P = 0.044$) stupnja za pacijente koji su imali plantarnu ploču, dok je na kraju bila $11.29^\circ \pm 4.96$ ($P = 0.044$) stupnjeva za pacijente koji su imali medijalne pločice. Prosječni IMA u skupini bolesnika koji su imali plantarnu ploču završio je $4.54^\circ \pm 2.24$ ($P = 0.584$) stupnja, dok je kod onih koji su imali medijalne ploče iznosio $5.63^\circ \pm 4.18$ ($P = 0.584$) stupnja. Skupina pacijenata koja su imala plantarnu ploču pokazala je potpunu konsolidaciju u svim slučajevima tijekom jednogodišnjeg praćenja. U skupini bolesnika koji su imali medijalne ploče jedan je pacijent imao komplikaciju u smislu nastajanja pseudoartroze, a drugi je imao produženo cijeljenje kosti. Napokon, vrijednost ljestvice boli zbog VRS-a tijekom jednogodišnjeg praćenja pokazala je da je za pacijente koji su imali plantarne ploče srednja vrijednost 1.40 ± 1.55 ($P = 0.236$), dok je za bolesnike koji su imali medijalne ploče 0.60 ± 0.5 ($P = 0.236$).

Zaključci: Pacijenti koji su bili operirani sa plantarnim pločicama imali su bolje rezultate u tri od pet kategorija FAOS-ovog skora. Plantarne pločice na zaključavanje imaju bolje rezultate od jedne godine u 3 od 5 kategorija FAOS-ovog rezultata (rezultat boli, simptomi koji nisu rezultat boli i kvalitete života) i bolji radiološki ishod nakon prve godine od operacijskog zahvata (HVA, IMA i razina konsolidacije). Pacijenti koji su operirani sa medijalnim pločicama na zaključavanje imaju bolje rezultate nakon prve godine od operacijskog zahvata u dvije od pet kategorija FAOS-ovog skora (rezultat sportskih i rekreativnih aktivnosti i aktivnosti iz svakodnevnog života) i VRS-ocjene boli. Vidimo da postoji razlika u kliničkom i radiološkom ishodu pri korištenju medijalnih pločica na zaključavanje sa tri zaključana vijka u usporedbi s uporabom plantarnih pločica na zaključavanje sa tri zaključana vijka, međutim, čini se da to nije statistički značajno

10. CURRICULUM VITAE

PERSONAL INFORMATION

NAME AND SURNAME: Niklas Krause

DATE AND PLACE OF BIRTH: March 25th 1995, Frankfurt am Main

NATIONALITY: German

CURRENT ADDRESS: Güldensöllerweg 79, 61350 Bad Homburg

E-MAIL: niklas.krausegke@gmail.com

EDUCATION

2000-2013. Pre-school, Mid-School, High school at the Frankfurt International School

2013. Obtained the International Baccalaureate Diploma

2013. Obtained the High School Diploma

2013. Obtained the German Abitur 2013

OTHER

Languages: English, German

Category „B” Driving licence

MEFST futsal team 2014-2020